International Journal of Dermatology

Review

The possible role of human papillomavirus infection in the development of lichen sclerosus

Anna K. Hald[1], MD and Jan Blaakaer[2], DMSc

[1]Aarhus University, Aarhus, Denmark, and [2]Department of Obstetrics and Gynaecology, Odense University Hospital, Odense, Denmark

Correspondence
Jan Blaakaer, DMSC
Skaering Egager 20
8250 Egaa
Denmark
E-mail: jab@dadlnet.dk

Conflicts of interest: None.

doi: 10.1111/ijd.13697

Abstract

Lichen sclerosus (LS) is a chronic inflammatory skin disease of unknown origin predominantly affecting the anogenital area that causes pruritus and pain and is associated with an increased risk of malignancy. In some cases, LS vanishes after application of imiquimod, raising the question whether human papillomavirus (HPV) may have an etiopathogenic role in anogenital LS. The databases MEDLINE and Embase were systematically searched using the PRISMA guidelines. Twenty-seven papers were included that reported the prevalence of HPV in LS and in LS associated with neoplasia. HPV was identified in 0–80% (median 22%) of all LS cases. The prevalence of HPV was higher among male patients with LS (median 29%) than among female patients (median 8%). HPV16 was the most prevalent genotype, but the distribution of genotypes indicates that even low-risk HPV can cause LS. The diverging detection rates are probably due to small sample sizes in the reviewed papers and different detection methods. Factors possibly underestimating the prevalence of HPV are a selective search for high-risk HPV, DNA destruction in fixed tissue, focally residing HPV, and possibly a clearing of HPV before the time of biopsy. Seventy-five percent of sexually active people acquire HPV during their lifetime, thus HPV alone is not a cause of LS. Genetic and immunological host factors and viral factors other than type are likely to contribute. Future studies should include patients with a short duration of symptoms, and biopsies should be multiple and fresh.

Introduction

Lichen sclerosus (LS) is a chronic inflammatory skin disease predominantly affecting the anogenital area in both sexes. Symptoms range from none to pruritus and pain, with a possible progression to scars and anatomic disfigurement and 5% increased risk of squamous cell carcinoma (SCC) in the genital area.[1] It is more common in women than in men, with a ratio between 10 : 1 and 6 : 1, and is estimated to affect between 1/300 and 1/1000 in both sexes. LS occurs at all ages but with a bimodal age incidence peaking in prepubertal children, middle-aged men, and postmenopausal women.[2]

The exact etiology of LS remains unknown, although several mechanisms have been sought. Cases of familial occurrence have been reported, suggesting a genetic contribution, but studies have been unable to establish the inheritance pattern.[3] Because of the prepubertal and postmenopausal peaks in incidence seen in women, hormonal factors have been investigated as a contributing factor to the development of LS but without conclusive results. A significant association between HLA-DQ7 antigen and LS has been demonstrated in one study,[4] and another study[5] found 22% of women with LS to have another autoimmune disorder (most frequently thyroid disease). However, a recent publication questions the causative role of autoimmune factors.[6] In some studies, the lymphogenic infiltrate in LS biopsies has been shown to contain monoclonal rearranged T-cell receptors, advocating for a specific local immune reaction to an antigen.[7] Several infectious factors, including *Borrelia Burgdorferi*, Epstein-Barr virus, and human papillomavirus (HPV), have been investigated as external triggers,[8] but the exact cause of LS has not been identified, suggesting a multifactorial etiology.

This lack of a causal link complicates targeting of the treatment, and for that reason only symptomatic treatment is available at present. Current first-line treatment is topical corticosteroids that relieve symptoms in 75–90% of patients.[1] Although spontaneous remission is seen, for most cases the treatment is lifelong.

Interestingly, Vignale *et al.*[9] found that the immunomodulatory drug imiquimod (ordinarily used to treat HPV-induced condylomas and cutaneous neoplasms) could be an effective treatment of LS. They reported clinical improvement in two HPV-positive female patients with LS after adding imiquimod for 3 months to topical corticoid treatment. We had the same experience at the Department of Obstetrics and Gynaecology in Aarhus University Hospital, Denmark, in three patients with vulvar LS in whom the symptoms of LS vanished after application of

© 2017 *The International Society of Dermatology*

imiquimod (J. Blaakaer, unpublished data). This led us to suspect that HPV could be directly linked to the development of LS, followed by a hypothetical immune response triggered by viral antigens. If this is the case, HPV vaccine could possibly prevent LS. Thus, the purpose of this article is to summarize all the current published data on the prevalence of HPV in LS in order to evaluate whether HPV could possibly play a role in the development of LS.

Materials and methods

Sources

A systematic literature search up to September 23, 2016, was performed. The databases MEDLINE (PubMed) and Embase were searched using a combination of the following MESH terms or Emtree words: "lichen sclerosus", "etiology", "HPV", "human papillomavirus", "vulvar cancer", "vulvar intraepithelial neoplasia", "VIN", "penile cancer", "penile intraepithelial neoplasia", and "PeIN".

Only English-language literature was included in the search.

Study selection

Eligible studies met the following criteria: (i) reports concerning the prevalence of HPV in histologically verified LS, (ii) studies on the prevalence of HPV in LS associated with invasive genital cancer, carcinoma *in situ*, or intraepithelial neoplasia of the male or female genitalia. Preferably, the papers should provide information on the distribution of specific genotypes of HPV in LS, although this information was not always available. Articles not providing information on specific HPV genotypes were also included because of the low number of articles on the subject. Included studies had to provide clear information on HPV detection and genotyping methods. Meta-analyses and reviews were not included.

A total of 774 articles were identified through the database search previously described. Of these, 27 papers met the stated criteria and were included for review (Tables 1 and 2, Fig. 1). Each paper was critically reviewed

Table 1 Detailed information on the 16 papers on female genital lichen sclerosus included for review

Author and year	Country	Sample size	Histology	HPV-positive samples	DNA source	HPV detection method	Primers
Aidé *et al.* 2010	Brazil	34	LS	0%	Fresh	PCR and electrophoresis	MY09/MY11
Ansink *et al.* 1994	The Netherlands	19	LS+SCC	37%	Fixed	PCR and Southern blotting	General primer
Gardner *et al.* 2011	USA	50	LS+dVIN	22%	Fixed	PCR, ISH, and IHC	GP5+/GP6+
Guerrero *et al.* 2011	Spain	12 21	LS+SCC LS	8% 24%	Fixed	PCR and RLB	GP5+/GP6+
Haefner *et al.* 1995	USA	6	LS+VIN	50%	Fixed	PCR, RFLP, and ISH	Broad-spectrum primers, not specified
Hørding *et al.* 1993	Denmark	36	LS+SCC	0%	Fixed	PCR and ISH	HPV-6, -11, -16, -18 and -33 type-specific primers, not specified
Kagie *et al.* 1997	The Netherlands	30	LS+SCC	7%	Fixed	PCR and sequencing	CPI/CPIIG
Kiene *et al.* 1991	Germany	18	LS	22%	Fixed	PCR and ISH	HPV-6, -11, -16, and -18 type-specific primers, not specified
Lerma *et al.* 1999	Spain	21	LS	0%	Fixed	PCR	VPHFast
Powell *et al.* 2003	UK	32	LS	25%	Vulvar scrapes and urine	PCR and electrophoresis	MY11/MY09 and GP5+/GP6+
Regauer *et al.* 2002	Austria	22 21	LS LS+SCC	36% 52%	Fixed	PCR and electrophoresis	HPV-16 specific primer
Skapa *et al.* 2007	Czech Republic	32	LS	0%	Fixed	PCR and RLB or sequencing	GP5+/GP6+
Ueda *et al.* 2004	Japan	6	LS	0%	Fixed	PCR and electrophoresis	pU-1M, pU-31B, pU-2R
van der Avoort *et al.* 2005	The Netherlands	10	LS	0%	Fixed	PCR and LiPA	SPF
van der Avoort *et al.* 2009	The Netherlands	9	LS, dVIN and SCC	0%	Fixed	PCR and LiPA	SPF10
van Seters *et al.* 2007	The Netherlands	26	LS+uVIN	31%	Fixed	PCR and RLB	GP5+/GP6+

HPV, human papillomavirus; LS, lichen sclerosus; VIN, vulvar intraepithelial neoplasia; dVIN, differentiated vulvar intraepithelial neoplasia; SCC, squamous cell carcinoma; PCR, polymerase chain reaction; ISH, in situ hybridization; IHC, immunohistochemistry; RFLP, restriction fragment length polymorphism; RLB, reverse line blot hybridization; LiPA, reverse hybridization line probe assay.

 © 2017 *The International Society of Dermatology*

Table 2 Detailed information on the 11 papers on male genital lichen sclerosus included in this review

Author and year	Country	Sample size	Histology	HPV-positive samples	DNA source	HPV detection method	Primers
Drut *et al.* 1998	Argentina	23	LS	70%	Fixed	PCR and ISH	MY11/MY09 and GP5+/GP6+
Guerrero-Setas *et al.* 2013	Spain	27	LS	4%	Fixed	PCR and RLB	GP5+/GP6+
Nasca *et al.* 1999	Italy	5	3LS+SCC, LS+EQ, LS+VC	80%	Fixed	PCR	Not specified
Nasca *et al.* 2006	Italy	46	LS	17%	Fixed	PCR and sequencing	MY11/MY09 and GP5+/GP6+
Paolino *et al.* 2013	Italy	7	LS+SCC	29%	Fixed	PCR	MY11/MY09 and GP5+/GP6+
Perceau *et al.* 2003	France	8	LS+SCC	13%	Fixed	PCR	GP5+/GP6+primers
Prowse *et al.* 2008	England	18	LS	33%	Fixed	PCR and LiPA	SPF10
		13	LS+SCC	54%			
Shim T. *et al.* 2013	England	25	LS	32%	Fixed	PCR and reverse hybridization	Broad-spectrum primers, not specified
Shim T. *et al.* 2014	England	88	LS	38%	Fixed	PCR and reverse hybridization	Broad-spectrum primers, not specified
von Krogh *et al.* 2001	Sweden	19	LS	21%	Fixed	PCR and Southern blotting	GP5+/GP6+
Zhang *et al.* 2016	China	47	LS	0%	Fixed	rtPCR	Commercialized test kits, TCTATCTATGCATACGTTGC and CCATTTTGTATATGATTGGT

HPV, human papillomavirus; LS, lichen sclerosus; SCC, squamous cell carcinoma; EQ, erythroplasia of Queyrat (unifocal SCC *in situ*); VC, verrucous carcinoma; PCR, polymerase chain reaction; ISH, *in situ* hybridization; RLB, reverse line blotting; LiPA, reverse hybridization line probe assay; rtPCR, real time polymerase chain reaction.

and assessed for potential bias and confounding and for external validity.

The following data were collected from each paper: first author, year of publication, country of sample, sample size, gender of included patients, histologically verified diagnosis (lichen sclerosus, lichen sclerosus associated with squamous cell carcinoma, verrucous carcinoma, vulvar intraepithelial neoplasia (usual or differentiated type), or penile intraepithelial neoplasia) source of DNA (fixed/fresh biopsy, scrapes, or urine), prevalence of HPV in LS, HPV genotypes (when available), and detection method of HPV and HPV genotypes.

Results

A total of 27 papers published from 1991 to 2016 were included in this study, compromising 731 LS lesions.[8,10–34] Of these, 489 cases represented LS not associated with neoplasia, and 242 cases represented LS associated with neoplasia (i.e., intraepithelial neoplasia, carcinoma *in situ*, squamous cell carcinoma, or verrucous carcinoma) distributed among 405 females and 326 males. The cases originated from Europe (77.8%), Southern America (7.4%), Northern America (7.4%), and Asia (7.4%). Detailed data on the included papers are given in Table 1 (female patients with LS) and Table 2 (male patients with LS).

Prevalence of HPV in LS

In general, the studies displayed very diverging results. In only eight of 27 (30%) studies were patients with LS to be completely negative for HPV.[8,28–34] In the 18 studies with HPV-positive patients, the prevalence of HPV ranged from 4 to 80%.[10–27,35] A calculation of the median, which allowed elimination of outliers, showed that the overall prevalence of HPV in LS is 22%. By further dividing the studies into subgroups based on gender and calculating the gender-specific median, the prevalence of HPV is 8% (range 0–52%) in female patients with LS and 29% (range 0–80%) in male patients with LS, suggesting a stronger correlation in men than in women. Histological change compatible with HPV infection or detection of HPV by *in situ* hybridization (ISH) are the most important evidence that HPV is present in epithelial cells; however, only five of 27 studies[10,11,13,15,22] used ISH or histological change as validation of HPV infection.

Looking at the HPV prevalence in LS not associated with neoplasia, 6/17 (35%) study populations were completely negative for HPV. On the other hand, only 2/12 (17%) study populations of LS associated with neoplasia were completely negative for HPV DNA. However, the difference is less apparent when medians are calculated, as the median of HPV in LS not associated with neoplasia is 21% (range 0–70%) compared to 22% (range 0–80%) in LS associated with neoplasia.

© 2017 *The International Society of Dermatology*

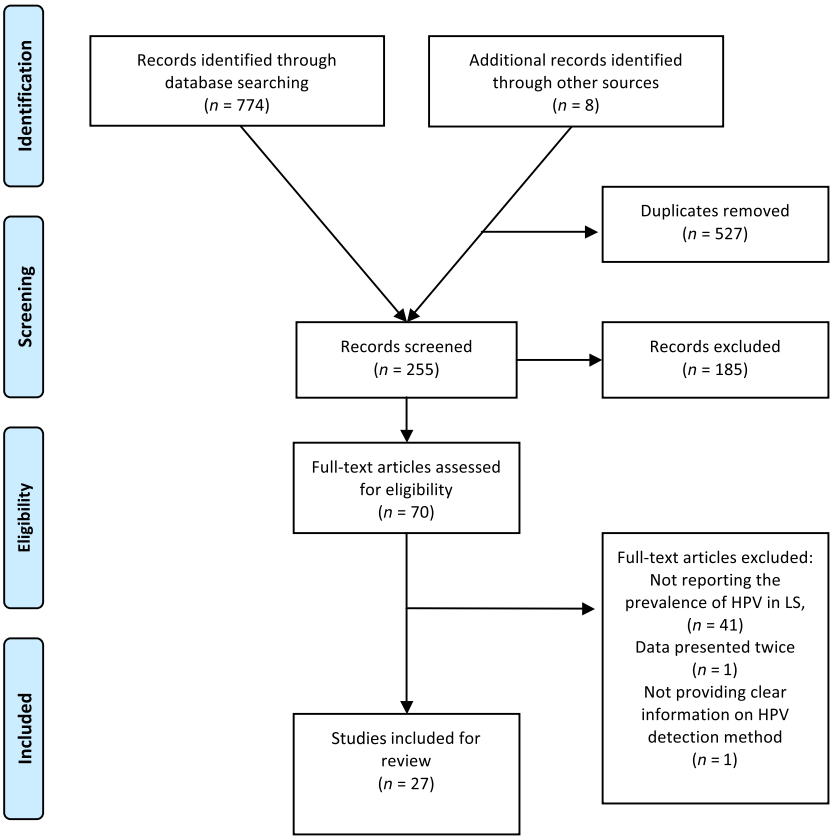

Figure 1 Flowchart demonstrating the selection of the included papers. Adjusted from Moher D. *et al.*, The PRISMA Group (2009). Preferred Reporting Items for Systematic Reviews and Meta-Analyses: The PRISMA Statement

HPV genotypes

Of the 19 papers that detected HPV DNA in LS lesions, 14 provided information on specific genotypes.[10,12–14,16,18–21,23–27] The identified HPV genotypes were divided into low-risk (lr) HPV or high-risk (hr) HPV. The lrHPV subgroup contains genotypes 6 and 11, and hrHPV was further divided into two subgroups containing genotypes 16 and 18, and genotypes 31, 33, 45, 52, and 58, respectively. The remaining HPV genotypes were filed under "others".

The division of lrHPV and hrHPV into subgroups is based upon the HPV vaccines currently available on the market. The bivalent HPV vaccine targets genotypes 16 and 18, whereas the quadrivalent vaccine extends its coverage by additionally targeting genotypes 6 and 11. A new 9-valent HPV vaccine includes five additional oncogenic HPV genotypes (31, 33, 45, 52, and 58) in addition to the four HPV genotypes (6, 11, 16, and 18) found in the quadrivalent vaccine.[36] This division allows calculation of to what extent the vaccines could prevent LS, given that HPV is a significant contributing cause of LS.

HPV-16 is by far the most prevalent genotype observed in this review, contributing to 64% of the detected HPV genotypes in the overall estimation including both LS associated and not associated with neoplasia. Adding the prevalence of HPV-18, the combined prevalence of HPV is 69%. HPV-6 and -11 account for an additional 11% and HPV-31, -33, -45, -52, and/or -58 for 7%. There is a similar pattern of HPV genotype distribution when only LS not associated with neoplasia is considered. However, regarding LS associated with neoplasia, the pattern shifts toward a greater dominance of oncogenic HPV-16 and -18. Here, HPV-16 and -18 account for 86% of the HPV genotypes, whereas HPV-6, -11, -31, -33, -45, -52, and -58 were not identified (Fig. 2).

Discussion

This review demonstrated a prevalence of HPV in LS patients ranging from 0 to 80%. The diverging detection rates are probably due to the small sample sizes in most of the reviewed papers and the use of different techniques for detection of HPV.

The data presented in this review are solely on genital LS, as there are no published papers on HPV prevalence in extragenital LS. Though cutaneotropic HPV and mucosotropic HPV are different types, one could assume that the results on HPV in genital LS are transmissible to extragenital LS, as host factors are similar and viral factors other than type (such as viral load and viral integration) are likely to also be active.

Human papillomavirus is the most prevalent sexually transmitted genital infection in the world, with a lifetime risk of infection of around 75%,[37] raising the question whether detection of HPV in a given case is causal or incidental. In women, the

 © 2017 *The International Society of Dermatology*

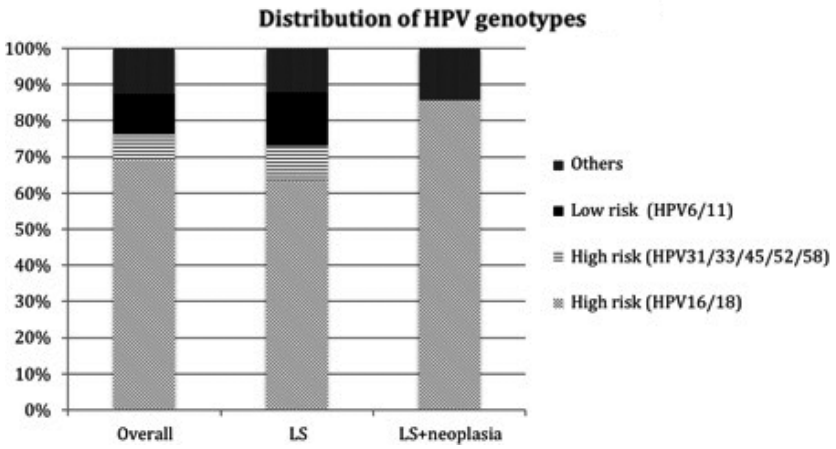

Figure 2 Human papillomavirus (HPV) genotype distribution identified in this review

estimated global prevalence of HPV in the general population is 11.7%,[38] compared to a prevalence of 12.4% in European men.[39] This meta-analysis underlines that if only papers published after 2000 are considered, the HPV prevalence in men is significantly higher (28.5%). Comparing these prevalences of HPV in the general population to the median prevalence of HPV in LS demonstrated in this review (overall, 22%; female only, 8% and male only, 29%), the present results seem less notable. The apparent greater correlation between HPV and LS in men could reflect different etiopathogenesis in men and women or that the included men belong to a high-risk population. Very little information is available on the included patients, both men and women, as most papers only report age and pathological and clinical signs of LS. It would be highly relevant to explore the sexual behavior of these patients, including age at first intercourse, number of sexual partners, anal intercourse, and other risk factors of acquiring HPV infection to evaluate whether they have a high-risk behavior. Only Zhang *et al.*[34] report the number of sexual partners.

In contrast to the apparent rise in HPV prevalence in the general population, some papers[12,20,31,33,35] demonstrated a diminishing prevalence of HPV in LS in time. Originating from the same region and using similar detection methods, Ansink *et al.*[35] collected tissue blocks from the period 1952 to 1982, Kagie *et al.*[12] from 1984 to 1993, and van der Avoort *et al.*[31,33] from 1992 to 2009 and found prevalences of HPV in LS of 37%, 7%, and 0%, respectively. A similar pattern is observed in the papers from the United States[11,21] and partly in the papers from Italy,[14,19,24] while the papers from England[21,26,27] and Spain[23,29] do not show this association. Overall, study populations are small, and this possible association could be by chance.

Hypothetically, HPV infection could trigger an immune response giving rise to LS and afterward clear before the time of biopsy, resulting in HPV-negative cases. LS has often been present for many years prior to the development of neoplasia, and furthermore there is an estimated delay of diagnosis of LS of 5 years, a period during which HPV could have resolved.

On the other hand, one could argue that patients with genital LS might be at higher risk for HPV infection as a consequence of prolonged immunosuppressive treatment or that the altered immune response seen in LS itself favors HPV infection. In other words, HPV infection might be the secondary phenomenon to LS. Only one paper divided cases into early- and late-stage LS,[34] thereby considering what comes first as well as the possible clearing of HPV before time of biopsy. It is arguable whether these early-stage patients actually represent an early stage, as they required surgery for their LS, but there is no information on the duration of symptoms. HPV was not detected in the patients in this study, either in early-stage or late-stage LS patients or in controls, raising uncertainty about the extraction and detection process. The authors validated the detection process by performing two runs, and in both runs positive and negative controls were normal, indicating sufficient processing. However, the study only tested for hrHPV and larger studies on early-stage and preferably untreated LS is needed to determine what comes first – HPV or LS.

Another possible reason for the absence of HPV in some cases is that HPV can reside focally. Thus, the prevalence of HPV could be underestimated if the biopsy was taken in an area without HPV. Of the included papers, only Regauer *et al.*[16] address this issue by taking topographically oriented biopsies and analyzing up to nine different areas within a single LS lesion.

All papers except two[8,18] examined fixed tissue. One paper used smear and urine as a source of DNA,[18] though this is not suitable material to detect HPV DNA in epithelial cells. The quality of DNA extracted from formalin-fixed and paraffin-embedded (FFPE) tissue is the main limiting step in HPV detection because formalin fixation may cause extensive damage to the DNA.[40] The steps taken prior to fixation cannot be taken into account, as most studies collected stored tissue blocks. By amplifying the human β-globulin gene, the DNA quality is verified in the papers. PCR has been recognized as the most sensitive method, but the sensitivity and specificity of PCR vary

© 2017 *The International Society of Dermatology*

depending on primer sets, size of the amplified PCR product, and DNA polymerase.[41] Applied consensus broad-spectrum primers like MY09/MY11, GP5+/6+, VPH, and CPI/II (Tables 1 and 2) amplify a rather big fragment and therefore demand a bigger piece of intact DNA, whereas the broad-spectrum primer SPF10 amplifies a much smaller fragment, increasing the odds of amplifying possibly damaged DNA in FFPE tissue. Hence, the quality of the available tissue and the applied detection method contribute to the diverging detection rate of HPV in this review.

hrHPV 16 was the most prevalent genotype observed in this review. The identified distribution of genotypes also partly depends on the applied HPV typing methods used because some studies only analyze for a limited number of HPV genotypes[10,11,16,28,30] or primarily focus on the oncogenic genotypes.[34] In LS without concomitant neoplasia, a mixture of lr and hrHPV is represented (Fig. 2), suggesting that even lrHPV could trigger the immune response seen in LS. Because of the selective search for hrHPV in some studies, the prevalence of HPV in LS is possibly underestimated in this review.

HPV-16 and -18 were the only common genotypes occurring in LS associated with neoplasia (Fig. 2). This contradicts the hypothesis suggested by Bilenchi *et al.*[42] that lrHPV plays an oncogenic role in LS. Our finding indicates that HPV-16 and -18 are more likely to contribute to the carcinogenic process in these cases, similarly to the HPV-dependent pathway of genital cancer or perhaps accelerate the carcinogenic mechanism of LS.

As a result of the widespread vaccination against HPV, one could expect a decline in the incidence of LS as an interesting side effect, if indeed HPV antigens are a necessary cause of LS. Considering the genotype distribution demonstrated in this review, approximately 63% of LS could be prevented using the bivalent vaccine (Cervarix®) as implemented in the Danish childhood vaccination programme at age 12. This could be extended further to a coverage of 78% and 88% by vaccination with the quadrivalent (Gardasil®) and the nonavalent vaccine (Gardasil 9®), respectively. Unfortunately, the vaccine is only a part of the childhood vaccination program in girls, and many of the patients with childhood LS develop the disease prior to the age of 12. It is well established that children can acquire anogenital HPV infection in a nonsexual manner, for instance through vertical transmission or close contact.[18] Evidence to date suggests that immunity lasts at least 10 years,[43] but it is unknown whether immunity could last into adulthood and possibly protect against adult LS.

The paradox of treating a possibly infection-induced disease with immunosuppressive medicine has been addressed in multiple studies, and treatment of LS with topical corticosteroids in the prescribed manner is generally considered safe regarding steroid side effects and opportunistic infections.[44] However, von Krogh *et al.*[15] argue that prolonged use of topical corticosteroids (mean: 7 weeks) could potentially reactivate latent or subclinical HPV infection. They detected an increase in HPV positivity and histopathological and clinical signs of HPV in four patients with LS after dermovat therapy, though not significant. Similarly, Bilenchi *et al.*[42] report two cases of HPV reactivation after application of tacrolimus in anogenital LS. Both papers consider it as a reactivation, indicating that the patients had been infected earlier, consistent with HPV being present prior to LS. Overall, this is in line with the paper published by Virginale *et al.*[9] that found an improvement in symptoms of LS after application of the virucide agent imiquimod. Data are scarce and inconclusive but implicate a pattern of HPV involvement.

As previously discussed, at least 75% of individuals acquire HPV at some point during their lifetime. The fact that 75% of the population do not develop LS nor do the partners of patients with LS, indicates that factors other than HPV infection have to contribute to the development of LS. Genetic and immunological host factors and viral factors other than type (such as viral load and viral integration) are likely to also be active. This review demonstrated that HPV in LS ranges from 0 to 80%, but larger studies are needed to clarify whether this association is a chance occurrence or whether HPV may really have an etiopathogenic role in anogenital LS. Future studies should preferably include patients with a short duration of symptoms, addressing the problem of possible clearing of HPV in older lesions. Biopsies should be fresh, multiple, and topographically oriented to circumvent the possible HPV DNA destruction in FFPE tissue and focally residing HPV. Furthermore, studies should focus on histologic change compatible with HPV infection or use ISH for detection of HPV, because these are important evidence that HPV is present in epithelial cells.

References

1 Kirtschig G. Lichen sclerosus – presentation, diagnosis and management. *Dtsch Arztebl Int* 2016; **113**: 337–343.
2 Bunker CB, Shim TN. Male genital lichen sclerosus. *Indian J Dermatol* 2015; **60**: 111–117.
3 Sherman V, McPherson T, Baldo M, *et al.* The high rate of familial lichen sclerosus suggests a genetic contribution: an observational cohort study. *J Eur Acad Dermatol Venereol* 2010; **24**: 1031–1034.
4 Marren P, Yell J, Charnock FM, *et al.* The association between lichen sclerosus and antigens of the HLA system. *Br J Dermatol* 1995; **132**: 197–203.
5 Cooper SM, Ali I, Baldo M. The association of lichen sclerosus and erosive lichen planus of the vulva with autoimmune disease: a case-control study. *Arch Dermatol* 2008; **144**: 1432–1435.
6 Higgins CA, Cruickshank ME. A population-based case–control study of aetiological factors associated with vulval lichen sclerosus. *J Obstet Gynaecol* 2012; **32**: 271–275.
7 Regauer S. Immune dysregulation in lichen sclerosus. *Eur J Cell Biol* 2005; **84**: 273–277.
8 Aidé S, Lattario FR, Almeida G, *et al.* Epstein-barr virus and human papillomavirus infection in vulvar lichen sclerosus. *J Low Genit Tract Dis* 2010; **14**: 319–322.

 © 2017 *The International Society of Dermatology*

9 Vignale R, Acosta G, Paciel J, *et al.* Presencia del virus del papiloma humano en lesiones de liquen escleroso y atrófico vulvar. Estudio por inmunohistoquímica e hibridización in situ. *Actas Dermosifiliogr* 2002; **93**: 389–392.
10 Kiene P, Milde-Langosch K, Löning T. Human papillomavirus infection in vulvar lesions of lichen sclerosus et atrophicus. *Arch Dermatol Res* 1991; **283**: 445–448.
11 Haefner HK, Tate JE, McLachlin CM, *et al.* Vulvar intraepithelial neoplasia – age, morphological phenotype, papillomavirus DNA, and coexisting invasive carcinoma. *Hum Pathol* 1995; **26**: 147–154.
12 Kagie MJ, Kenter GG, Zomerdijk-Nooijen Y, *et al.* Human papillomavirus infection in squamous cell carcinoma of the vulva, in various synchronous epithelial changes and in normal vulvar skin. *Gynecol Oncol* 1997; **67**: 178–183.
13 Drut RM, Gomez MA, Drut R, *et al.* Human papillomavirus is present in some cases of childhood penile lichen sclerosus – an in situ hybridization and SP-PCR study. *Pediatr Dermatol* 1998; **15**: 85–90.
14 Nasca MR, Innocenzi D, Micali G. Penile cancer among patients with genital lichen sclerosus. *J Am Acad Dermatol* 1999; **41**: 911–914.
15 von Krogh G, Dahlman-Ghozlan K, Syrjänen S. Potential human papillomavirus reactivation following topical corticosteroid therapy of genital lichen sclerosus and erosive lichen planus. *J Eur Acad Dermatol Venereol* 2002; **16**: 130–133.
16 Regauer S, Reich O, Beham-Schmid C. Monoclonal γ-T-cell receptor rearrangement in vulvar lichen sclerosus and squamous cell carcinomas. *Am J Pathol* 2002; **160**: 1035–1045.
17 Perceau G, Derancourt C, Clavel C, *et al.* Lichen sclerosus is frequently present in penile squamous cell carcinomas but is not always associated with oncogenic human papillomavirus. *Br J Dermatol* 2003; **148**: 934–938.
18 Powell J, Strauss S, Gray J, *et al.* Genital carriage of human papilloma virus (HPV) DNA in prepubertal girls with and without vulval disease. *Pediatr Dermatol* 2003; **20**: 191–194.
19 Nasca MR, Innocenzi D, Micali G. Association of penile lichen sclerosus and oncogenic human papillomavirus infection. *Int J Dermatol* 2006; **45**: 681–683.
20 van Seters M, ten Kate FJ, van Beurden M, *et al.* In the absence of (early) invasive carcinoma, vulvar intraepithelial neoplasia associated with lichen sclerosus is mainly of undifferentiated type: new insights in histology and aetiology. *J Clin Pathol* 2007; **60**: 504–509.
21 Prowse DM, Ktori EN, Chandrasekaran D, *et al.* Human papillomavirus-associated increase in p16INK4A expression in penile lichen sclerosus and squamous cell carcinoma. *Br J Dermatol* 2008; **158**: 261–265.
22 Gardner JA, Cooper K, Rajendran V, *et al.* Investigation of human papillomavirus infections in vulvar intraepithelial neoplasia by polymerase chain reaction, chomogenic in situ hybridization and immunohistochemistry. *Lab Invest* 2011; **91**: 246A–247A.
23 Guerrero D, Guarch R, Ojer A, *et al.* Differential hypermethylation of genes in vulvar cancer and lichen sclerosus coexisting or not with vulvar cancer. *Int J Cancer* 2011; **128**: 2853–2864.
24 Paolino G, Panetta C, Cota C, *et al.* Lichen Sclerosus and the risk of malignant progression: a case series of 159 patients. *G. Ital Dermatol Venereol* 2013; **148**: 673–678.
25 Guerrero-Setas D, Perez-Janices N, Ojer A, *et al.* Differential gene hypermethylation in genital lichen sclerosus and cancer: a comparative study. *Histopathology* 2013; **63**: 659–669.
26 Shim T, De Koning M, Muneer A, *et al.* HPV in male genital lichen sclerosus, penile carcinoma in-situ and penile squamous cell carcinoma. *J Invest Dermatol* 2013; **133**: S195.
27 Shim TN, De Koning MN, Goolamali SI, *et al.* Prevalence of human papillomavirus in male genital lichen sclerosus, penile carcinoma in situ and penile carcinoma: correlation with p16INK4a expression and immune status. *Br J Dermatol* 2014; **171**: 34–35.
28 Hørding U, Junge J, Daugaard S, *et al.* Vulvar squamous cell carcinoma and papillomaviruses – indications for two different etiologies. *Gynecol Oncol* 1994; **52**: 241–246.
29 Lerma E, Matias-Guiu X, Soon JL, *et al.* Squamous cell carcinoma of the vulva – study of ploidy, HPV, p53, and pRb. *Int J Gynecol Pathol* 1999; **18**: 191–197.
30 Ueda Y, Enomoto T, Miyatake T, *et al.* Analysis of clonality and hpv infection in benign, hyperplastic, premalignant, and malignant lesions of the vulvar mucosa. *Am J Clin Pathol* 2004; **122**: 266–274.
31 van der Avoort IAM, Shirango H, Hoevenaars BM, *et al.* Vulvar squamous cell carcinoma is a multifactorial disease following two separate and independent pathways. *Int J Gynecol Pathol* 2006; **25**: 22–29.
32 Skapa P, Zamecnik J, Hamsikova E, *et al.* Human papillomavirus (HPV) profiles of vulvar lesions. Possible implications for the classification of vulvar squamous cell carcinoma precursors and for the efficacy of prophylactic HPV vaccination. *Am J Surg Pathol* 2007; **31**: 1834–1843.
33 van der Avoort IA, van de Nieuwenhof HP, Otte-Holler I, *et al.* High levels of p53 expression correlate with DNA aneuploidy in (pre)malignancies of the vulva. *Hum Pathol* 2010; **41**: 1475–1485.
34 Zhang Y, Fu Q, Zhang X. The presence of human papillomavirus and Epstein-Barr virus in male Chinese lichen sclerosus patients: a single center study. *Asian J Androl* 2016; **18**: 650–653.
35 Ansink AC, Krul MR, De Weger RA, *et al.* Human papillomavirus, lichen sclerosus, and squamous cell carcinoma of the vulva – detection and diagnostic significance. *Gynecol Oncol* 1994; **52**: 180–184.
36 McNamara M, Batur P, Walsh JME, *et al.* HPV update: vaccination, screening, and associated disease. *J Gen Intern Med* 2016; **31**: 1360–1366.
37 Walhart T. Human papillomavirus biology, pathogenesis, and potential for drug discovery: a literature review for HIV nurse clinical scientists. *J Assoc Nurses AIDS Care* 2015; **26**: 693–702.
38 Bruni L, Diaz M, Castellsague X, *et al.* Cervical human papillomavirus prevalence in 5 continents: meta-analysis of 1 million women with normal cytological findings. *J Infect Dis* 2010; **202**: 1789–1799.
39 Hebnes JB, Olesen TB, Duun-Henriksen AK, *et al.* Prevalence of genital human papillomavirus among men in Europe: systematic review and meta-analysis. *J Sex Med* 2014; **11**: 2630–2644.
40 Van Doorslaer K, Chen Z, McBride AA. Detection and genotyping of human papillomaviruses from archival formalin-fixed tissue samples. *Curr Protoc Microbiol* 2016; **43**: 14B.9.1–14B.9.20.
41 Chung SH. Cervical cancer screening after perimenopause: how is human papillomavirus test performed? *J Menopausal Med* 2016; **22**: 65–70.
42 Bilenchi R, Poggiali S, De Padove LA, *et al.* Human papillomavirus reactivation following topical tacrolimus therapy

of anogenital lichen sclerosus. *Br J Dermatol* 2007; **156**: 405–406.

43 Dunne EF, Koch A. HPV vaccines for circumpolar health: summary of plenary session, "Opportunities for Prevention: global HPV Vaccine" and "Human Papillomavirus Prevention: The Nordic Experience". *Int J Circumpolar Health* 2013; **72**: 21070. https://org.doi.10.3402/ijch.v72i0.21070.

44 Kai A, Lewis F. Long-term use of an ultrapotent topical steroid for the treatment of vulval lichen sclerosus is safe. *J Obstet Gynaecol* 2016; **36**: 276–277.

 © 2017 *The International Society of Dermatology*