Clinical Microbiology and Infection 24 (2018) 246–250

Contents lists available at ScienceDirect

Clinical Microbiology and Infection

journal homepage: www.clinicalmicrobiologyandinfection.com

Systematic review

Acute disseminated candidiasis with skin lesions: a systematic review

M. Guarana [1], M. Nucci [2,*]

[1] University Hospital, Universidade do Estado do Rio de Janeiro, Brazil
[2] University Hospital, Universidade Federal do Rio de Janeiro, Brazil

ARTICLE INFO

Article history:
Received 16 May 2017
Received in revised form
15 August 2017
Accepted 19 August 2017
Available online 25 August 2017

Editor: I. Gyssens

Keywords:
Candidaemia
Cutaneous
Invasive candidiasis
Neutropenia
Skin lesions

ABSTRACT

Background: Neutropenic patients developing acute disseminated candidiasis may present with skin lesions.
Aims: To evaluate the epidemiology of acute disseminated candidiasis with skin lesions in neutropenic patients, taking into consideration changes caused by different prophylactic strategies.
Sources: A systematic review of English-language articles found via PubMed (1963–2016) was performed. We asked the following questions: (a) What *Candida* species are more frequently involved in this syndrome? (b) Has antifungal prophylaxis changed the species causing skin lesions? (c) What are the typical patterns of skin lesions? (d) What is the frequency of skin lesions in neutropenic patients with candidaemia or acute disseminated candidiasis? (e) Has antifungal prophylaxis decreased the incidence of acute disseminated candidiasis with skin lesions?
Content: Among 183 studies, 33 were selected, reporting 100 cases of acute disseminated candidiasis with skin lesions in neutropenic patients. It occurred more frequently in the setting of induction therapy for *de novo* or relapsed acute leukaemia, and the most frequent *Candida* species were *C. tropicalis* (68%) and *C. krusei* (15%). Diffuse maculopapular lesions predominated in cases caused by *C. tropicalis* and nodular and papular lesions in cases caused by *C. krusei.* Prophylaxis with fluconazole was reported in six cases, *C. krusei* in five and *C. ciferrii* in one. The death rate was 45.4%.
Implications: Two patterns were recognized: disseminated maculopapular lesions caused by *C. tropicalis* in patients not receiving fluconazole prophylaxis, occurring in 39% to 44% of neutropenic patients with acute disseminated candidiasis, and nodular lesions caused by *C. krusei* in patients receiving fluconazole prophylaxis, occurring less frequently. **M. Guarana, Clin Microbiol Infect 2018;24:246**
© 2017 European Society of Clinical Microbiology and Infectious Diseases. Published by Elsevier Ltd. All rights reserved.

Introduction

Acute disseminated candidiasis is a serious complication of haematologic patients with neutropenia [1]. The incidence of this complication has greatly reduced with the introduction of fluconazole prophylaxis in the 1990s, with a relative decrease in infection caused by *Candida albicans* and *Candida tropicalis,* and an increase in infection caused by the less fluconazole-susceptible species *Candida glabrata* and *Candida krusei* [2].

While the majority of cases of acute disseminated candidiasis do not present with any specific clinical signs, some neutropenic patients may present with disseminated skin lesions [3,4], usually in the setting of candidaemia caused by *C. tropicalis* [5]. Two series published in the 1970s reported skin lesions in 13% of cancer patients with candidaemia (neutropenic and nonneutropenic) [6] and 44% in neutropenic haematologic patients with candidaemia [5], respectively. However, with the introduction of fluconazole (and more recently posaconazole) in prophylaxis [7,8], the incidence may have decreased. Furthermore, the species causing acute disseminated candidiasis with skin lesions may have changed.

We performed a systematic review of the literature to evaluate the frequency and epidemiology of acute disseminated candidiasis with skin lesions in neutropenic patients, taking into consideration possible changes caused by different prophylactic strategies.

Patients and methods

Data source

A computerized search of the Medline database via PubMed was performed for articles published from 1963 through September

* Corresponding author: M. Nucci, Hospital Universitário Clementino Fraga Filho, R. Prof. Rodolpho Paulo Rocco, 2455 Sala 4A 12 – Cidade Universitária, Rio de Janeiro, RJ, 21941-913, Brazil.
E-mail address: mnucci@hucff.ufrj.br (M. Nucci).

https://doi.org/10.1016/j.cmi.2017.08.016
1198-743X/© 2017 European Society of Clinical Microbiology and Infectious Diseases. Published by Elsevier Ltd. All rights reserved.

2016 in the English language using the following keywords: 'candidiasis,' 'neutropenia or leukaemia' and 'skin or cutaneous.' Subsequently, hand searching was performed in the reference lists of all identified studies to find relevant articles.

Study selection

We selected all types of studies that included haematologic patients with neutropenia and candidaemia or acute disseminated candidiasis and provided a description of the clinical presentation, frequency and type of skin lesion, documentation of skin involvement by *Candida* and species causing infection. Reports with limited information (including abstracts), duplicate records, review papers or articles reporting skin lesions associated with infections caused by other pathogens were excluded. We asked the following questions: (a) What *Candida* species are more frequently involved in this syndrome? (b) Has antifungal prophylaxis changed the species causing skin lesions? (c) What are the typical patterns of skin lesions? (d) What is the frequency of skin lesions in neutropenic patients with candidaemia or acute disseminated candidiasis? (e) Has antifungal prophylaxis decreased the incidence of acute disseminated candidiasis with skin lesions?

Data extraction

The following data were extracted from the articles: underlying disease and its treatment, type of treatment (induction, consolidation, therapy of relapse, other), clinical presentation, frequency, pattern and site of skin lesions, species causing invasive candidiasis, information about culture and histopathology of the skin, antifungal prophylaxis, primary treatment and outcome. Special attention was devoted to the type of skin lesion, species causing acute disseminated candidiasis and antifungal prophylaxis. We also looked at missing information in each study and the potential limitations caused by the lack of information. The data were extracted independently by one author (MG) and reviewed by the other (MN).

Results

A total of 175 articles were identified using the keywords, and eight other relevant articles were identified by manual searching of the reference lists. Among the 183 articles, 43 met the eligibility criteria. Of those, ten were excluded for the following reasons: lack of detailed clinical description ($n = 4$), cases with skin lesions from other causes ($n = 2$), cases without cutaneous involvement ($n = 2$), case reports in nonneutropenic patients ($n = 1$) and review papers ($n = 1$) (Fig. 1).

Among the 33 studies analysed, 22 were case reports and 11 were case series [3–6, 9–11, 13–15, 24–46]. Details of the studies are shown in Supplementary Table S1.

Five studies reported the frequency of skin lesions. The first was published in 1974 and evaluated 77 cases of disseminated candidiasis in a 5-year period at a cancer hospital. Skin lesions were present in ten cases (13%) [6]. Another study evaluated 89 consecutive haematologic patients with neutropenia and found 18 cases of acute disseminated candidiasis, eight of which (44.4%) presented with skin lesions [5]. A third study reported 23 cases of candidaemia with skin lesions among 200 episodes of candidaemia at a cancer centre (11.5%) [9]. The fourth study evaluated 28 patients with acute leukaemia who developed candidaemia. Eleven (39.3%) had skin lesions [10]. The fifth study evaluated 53 consecutive patients with candidaemia and positive cultures from other sites. Nineteen (35.8%) presented with skin lesions [11].

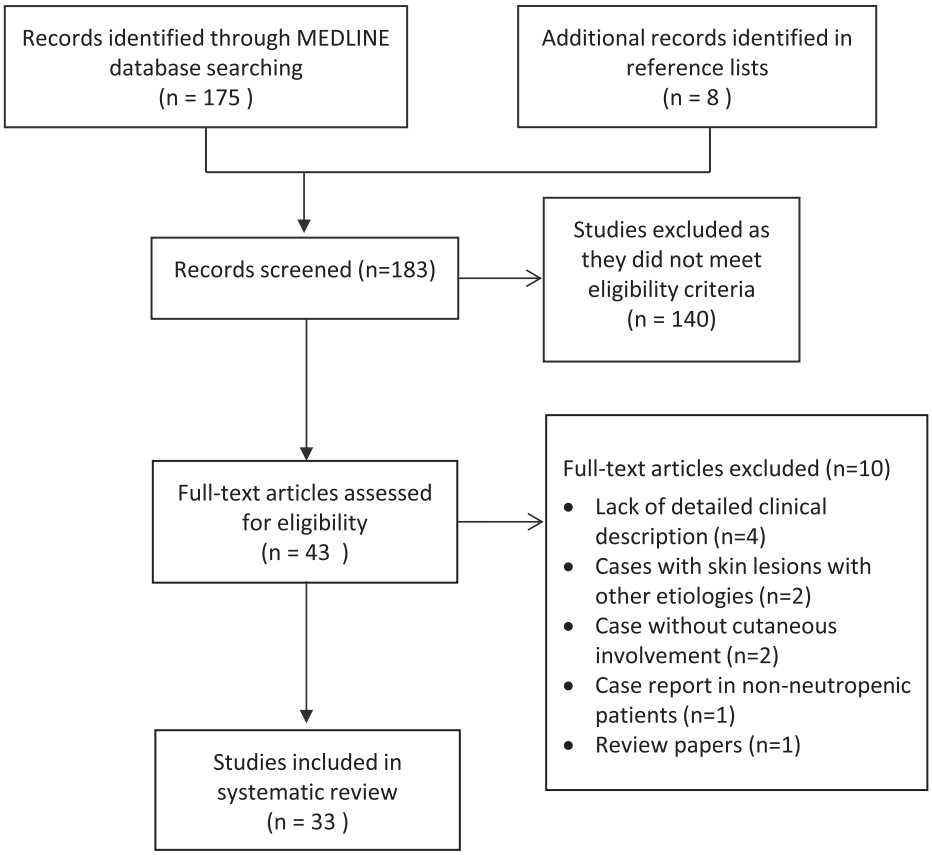

Fig. 1. Flowchart showing article selection.

A total of 100 cases of acute disseminated candidiasis with skin lesions were identified. A summary of the characteristics of the cases, including the number of cases with missing information in each variable, is shown in Supplementary Table S2. The most frequent underlying disease was acute leukaemia, comprising 86% of cases (54 acute myeloid leukaemia and 32 acute lymphoid leukaemia). Other underlying conditions were chronic myeloid leukaemia in blastic phase ($n = 8$), aplastic anaemia ($n = 3$), and myelodysplastic syndrome, non-Hodgkin lymphoma and post-transplantation lymphoproliferative disease ($n = 1$ patient each). The majority of cases occurred during induction chemotherapy for recently diagnosed (31%) or relapsed (25%) patients. Of note, only three cases occurred during consolidation chemotherapy. The information was not available in 32 cases.

The most frequent *Candida* species was *C. tropicalis* (68%), followed by *C. krusei* (15%) and *C. albicans* (10%). For two patients, histopathologic diagnosis was attempted, but no organism was recovered. The remaining five cases were caused by *C. guilliermondii* (two cases), and *C. ciferrii, C. glabrata* and *C. albicans* plus *C. tropicalis* (one case each).

The most frequent pattern of the skin lesions reported was erythematous or purpuric maculopapular lesions (44%), followed by purpuric or erythematous papular lesions, sometimes with a pale centre (22%), nodules (17%) and subcutaneous abscess (6%). Some patients presented with a mixture of different types of lesions, such as papules and nodules (7%). The site of lesion was reported in 72 cases: in 44 the lesions were located in the extremities, and in 28 they were disseminated.

Skin biopsy results with description of histopathology were available in 51 cases. In 35 cases (68.6%), fungal elements (pseudohyphae, hyphae and yeasts) were present in the dermis as well as within blood vessels. In four cases, the pattern was that of an abscess. Granulomas, necrosis within the wall of a blood vessel, leukocytoclastic vasculitis, and perivascular infiltrates and thrombi in small vascular structures were also described. Positive cultures of skin biopsy samples were reported in 41 (71.9%) of 57 cases. The most frequent species recovered in cultures of skin biopsy samples was *C. tropicalis* (35 cases), followed by *C. krusei* (five cases).

Involvement of other organs was reported in 44 patients, with multiple organs such as spleen, liver, kidneys and lungs involved in the majority of cases. Involvement of more than two organs was reported in 26 of the 44 cases.

Positive blood cultures were reported in 67 of the 68 cases caused by *C. tropicalis*. The most frequent type of skin lesion in such cases was diffuse maculopapular lesions, reported in 39 (57.3%) of the 68 cases. The most frequent clinical presentations among the 15 cases caused by *C. krusei* were nodular (seven cases) or papular (seven cases) lesions.

Information about antifungal prophylaxis was not available in the majority of cases (55%). Prophylaxis with fluconazole was reported in six cases. The species involved in these cases were *C. krusei* in five and *C. ciferrii* in one.

The majority of cases were treated with deoxycholate amphotericin B either alone (83%) or combined with fluconazole (6%). Other therapies included liposomal amphotericin B (4%), amphotericin B lipid complex (2%), miconazole (1%) and an echinocandin plus voriconazole (1%). Three patients did not receive antifungal treatment. The outcome was not reported in only one case. Among the remaining 99 cases, the death rate was 45.4%.

Discussion

Our review of the literature yielded several findings. Firstly, acute disseminated candidiasis with skin lesions occurs predominantly in the setting of neutropenia after induction therapy for acute leukaemia. Secondly, the typical clinical presentation is that of maculopapular erythematous lesions disseminated through the trunk and extremities. Thirdly, *C. tropicalis* was the likely agent recovered in blood cultures and/or in the culture of skin biopsy samples if the patient was not receiving fluconazole prophylaxis. In contrast, in patients receiving fluconazole prophylaxis, *C. krusei* was the most frequent agent. These two species accounted for 83% of the 100 cases. Fourthly, the mortality rate of this presentation of acute disseminated candidiasis was high (45.4%).

In this review, we sought to answer some specific questions related to the presence of skin lesions in patients with acute disseminated candidiasis. We found a broad range of terms in the different published articles, such as cutaneous septic emboli, cutaneous fungal infections, cutaneous manifestations, skin rashes and candida vasculitis, many of them without definitions. Therefore, we used broad terms in our search strategy in order to identify articles that used different terminology. The first set of questions was related to the most frequent *Candida* species causing the syndrome of acute disseminated candidiasis with skin lesions, and if antifungal prophylaxis with fluconazole changed this scenario. *Candida tropicalis* was by far the leading agent, accounting for more two thirds of cases, followed by *C. krusei,* accounting for 15% of cases. A remarkable finding was the strong association between fluconazole prophylaxis and *Candida* species: none of 68 patients with infection by *C. tropicalis* had received fluconazole prophylaxis, while five of six cases reported in patients receiving fluconazole prophylaxis were caused by *C. krusei.*

Candida krusei emerged as a pathogen causing acute disseminated candidiasis in neutropenic patients after the introduction of antifungal prophylaxis, especially fluconazole. A retrospective study at a cancer centre in the United States analysed the epidemiology of 491 episodes of candidaemia diagnosed between 1988 and 1992. *Candida krusei* was the agent in only 20 episodes (4%). Multivariate analysis showed a strong association between infection by *C. tropicalis* and no fluconazole prophylaxis, and between infection by *C. krusei* and fluconazole prophylaxis [2]. Another study analysed 2019 episodes of candidaemia from North American centres in a 4-year period (2004–2008). *Candida krusei* accounted for 2.5% of cases (51 episodes), and it occurred more frequently in patients with haematologic malignancies, neutropenia and prior exposure to antifungal agents [12].

The association between *C. krusei* fungemia and skin lesions was first reported in 1980 [13]. The first case series was published in 1992, with the description of seven patients with acute myeloid leukaemia who presented with embolic skin lesions in the setting of candidaemia due to *C. krusei* [14]. Another case series reported 13 episodes of candidaemia due to *C. krusei* and compared them to 39 episodes caused by *C. albicans.* Skin lesions were more frequent in cases caused by *C. krusei* (23% vs. 5%). Prior exposure to antifungal agents was the only variable associated with *C. krusei* fungemia by multivariate analysis [15].

The third question was related to the typical patterns of skin lesions. In our literature review, we established two patterns of clinical presentation. The first occurred in patients not receiving fluconazole prophylaxis who presented with disseminated maculopapular lesions, with positive blood and skin cultures for *C. tropicalis.* The second was that of patients receiving fluconazole prophylaxis who presented with nodular or papular skin lesions, and with *C. krusei* growing from the blood and/or skin biopsy samples.

The other two questions were related to the frequency of skin lesions in neutropenic patients with candidaemia and the influence of antifungal prophylaxis on the incidence. We found only five studies [5,6,9–11], with incidence rates varying from 11.5% to 44.4%. This wide variation in the frequency of skin lesions is

probably a reflection of the heterogeneity of the studies, since some studies included patients with and without neutropenia, with haematologic and nonhematologic diseases. Of note, the two studies evaluating only neutropenic patients with candidaemia reported incidences of 39.3% and 44.4% [5,10]. In both studies, the patients were not receiving fluconazole prophylaxis. Therefore, we can estimate that in neutropenic patients not receiving fluconazole prophylaxis who develop candidaemia, the incidence of skin lesions is between 39% and 44%. Regarding the impact of prophylaxis on the incidence of skin lesions, we did not find any study to answer this question. However, we can speculate that the incidence of candidaemia with skin lesions in neutropenic patients receiving prophylaxis might have reduced substantially. If we consider that no case of candidaemia with skin lesions caused by *C. tropicalis* will occur in patients receiving fluconazole prophylaxis (as we observed in this systematic review), and that the large majority of cases will be caused by *C. krusei,* the incidence will be very low, even if we consider that 75% to 100% of neutropenic patients with *C. krusei* fungemia will developed skin lesions [14,15]. For example, a large epidemiologic study of 333 episodes of fungemia in 145030 cancer patients from eight European countries reported 20 cases of *C. krusei* fungemia among 140 haematologic patients (14.3%), and skin involvement was reported in only 5% [16]. Therefore, considering that antifungal prophylaxis with an azole agent is common practice in patients with acute myeloid leukaemia, acute disseminated candidiasis with skin lesions is much less likely to occur.

Another finding of our systematic review was the high mortality rate of acute disseminated candidiasis with skin lesions. The outcome of acute disseminated candidiasis in neutropenic patients is largely dependent on the immune status of the host, specifically recovery of neutropenia [17,18]. Because this information was not available in the majority of cases, we cannot appreciate the influence of host factors on the poor outcome observed. Another factor that may have contributed to the poor outcome was the drug used as primary therapy. The large majority of patients received deoxycholate amphotericin B, and only one patient received an echinocandin, which is considered the first option for the treatment of candidaemia according to different guidelines [19–21]. Indeed, the outcome of candidaemia has improved after the introduction of echinocandins in the treatment of candidaemia [22,23]. Therefore, it is possible that the outcome would be better if patients were treated with an echinocandin.

Our study has some important limitations. Firstly, it includes mostly case reports; secondly, the analysis is derived mostly from older studies, which are not representative of current standards of antifungal prophylaxis in haematologic patients and treatment of acute disseminated candidiasis; and thirdly, some articles did not include important information such as antifungal prophylaxis, details of culture and histopathology of skin lesions. Despite these limitations, our findings have important implications for clinical management. Patients with acute leukaemia and febrile neutropenia who develop disseminated maculopapular or nodular lesions should have blood samples collected for culture and should undergo immediate biopsy of one of these lesions. Appropriate antifungal therapy should be initiated, taking into consideration the antifungal prophylaxis and the most likely species.

In conclusion, invasive candidiasis with skin lesions in neutropenic patients occurs mostly in patients with acute leukaemia, with two patterns: disseminated maculopapular lesions caused by *C. tropicalis* in patients not receiving fluconazole prophylaxis, and nodular or papular lesions caused by *C. krusei* in patients on fluconazole prophylaxis. The first occurs in about 40% of neutropenic patients with invasive candidiasis and the second seems to occur much less frequently. The mortality observed in this review was high.

Transparency Declaration

MN reports grants and personal fees from Pfizer, personal fees from Merck, personal fees from Astellas, personal fees from Gilead, personal fees from Basilea, personal fees from United Medical and personal fees from Teva outside the submitted work. MG reports no conflicts of interest relevant to this article.

Appendix A. Supplementary data

Supplementary data related to this article can be found at https://doi.org/10:1016/j.cmi.2017.08.016.

References

[1] Gamaletsou MN, Walsh TJ, Zaoutis T, Pagoni M, Kotsopoulou M, Voulgarelis M, et al. A prospective, cohort, multicentre study of candidaemia in hospitalized adult patients with haematological malignancies. Clin Microbiol Infect 2014;20:O50–7.
[2] Abi-Said D, Anaissie E, Uzun O, Raad I, Pinzcowski H, Vartivarian S. The epidemiology of hematogenous candidiasis caused by different *Candida* species. Clin Infect Dis 1997;24:1122–8.
[3] Grossman ME, Silvers DN, Walther RR. Cutaneous manifestations of disseminated candidiasis. J Am Acad Dermatol 1980;2:111–6.
[4] Grabowski R, Dugan E. Disseminated candidiasis in a patient with acute myelogenous leukemia. Cutis 2003;71:466–8.
[5] Wingard JR, Merz WG, Saral R. *Candida tropicalis*: a major pathogen in immunocompromised patients. Ann Intern Med 1979;91:539–43.
[6] Bodey GP, Luna M. Skin lesions associated with disseminated candidiasis. JAMA 1974;229:1466–8.
[7] Cornely OA, Maertens J, Winston DJ, Perfect J, Ullmann AJ, Walsh TJ, et al. Posaconazole vs. fluconazole or itraconazole prophylaxis in patients with neutropenia. N Engl J Med 2007;356:348–59.
[8] Slavin MA, Osborne B, Adams R, Levenstein MJ, Schoch HG, Feldman AR, et al. Efficacy and safety of fluconazole prophylaxis for fungal infections after marrow transplantation—a prospective, randomized, double-blind study. J Infect Dis 1995;171:1545–52.
[9] Horn R, Wong B, Kiehn TE, Armstrong D. Fungemia in a cancer hospital: changing frequency, earlier onset, and results of therapy. Rev Infect Dis 1985;7:646–55.
[10] Ribeiro P, Sousa AB, Nunes O, Aveiro F, Fernandes JP, Gouveia J. Candidemia in acute leukemia patients. Support Care Cancer 1997;5:249–51.
[11] Bae GY, Lee HW, Chang SE, Moon KC, Lee MW, Choi JH, et al. Clinicopathologic review of 19 patients with systemic candidiasis with skin lesions. Int J Dermatol 2005;44:550–5.
[12] Horn DL, Neofytos D, Anaissie EJ, Fishman JA, Steinbach WJ, Olyaei AJ, et al. Epidemiology and outcomes of candidemia in 2019 patients: data from the prospective antifungal therapy alliance registry. Clin Infect Dis 2009;48:1695–703.
[13] Jacobs MI, Magid MS, Jarowski CI. Disseminated candidiasis. Newer approaches to early recognition and treatment. Arch Dermatol 1980;116:1277–9.
[14] McQuillen DP, Zingman BS, Meunier F, Levitz SM. Invasive infections due to *Candida krusei*: report of ten cases of fungemia that include three cases of endophthalmitis. Clin Infect Dis 1992;14:472–8.
[15] Munoz P, Sanchez-Somolinos M, Alcala L, Rodriguez-Creixems M, Pelaez T, Bouza E. *Candida krusei* fungaemia: antifungal susceptibility and clinical presentation of an uncommon entity during 15 years in a single general hospital. J Antimicrob Chemother 2005;55:188–93.
[16] Cornely OA, Gachot B, Akan H, Bassetti M, Uzun O, Kibbler C, et al. Epidemiology and outcome of fungemia in a cancer cohort of the infectious diseases group (IDG) of the European organization for research and treatment of cancer (EORTC 65031). Clin Infect Dis 2015;61:324–31.
[17] Anaissie EJ, Rex JH, Uzun O, Vartivarian S. Predictors of adverse outcome in cancer patients with candidemia. Am J Med 1998;104:238–45.
[18] Nucci M, Silveira MI, Spector N, Silveira F, Velasco E, Akiti T, et al. Risk factors for death among cancer patients with fungemia. Clin Infect Dis 1998;27:107–11.
[19] Nucci M, Thompson-Moya L, Guzman-Blanco M, Tiraboschi IN, Cortes JA, Echevarria J, et al. Recommendations for the management of candidemia in adults in Latin America. Latin America invasive mycosis network. Rev Iberoam Micol 2013;30:179–88.
[20] Pappas PG, Kauffman CA, Andes DR, Clancy CJ, Marr KA, Ostrosky-Zeichner L, et al. Clinical practice guideline for the management of candidiasis: 2016 update by the infectious diseases society of america. Clin Infect Dis 2016;62.e1–50.
[21] Tissot F, Agrawal S, Pagano L, Petrikkos G, Groll AH, Skiada A, et al. ECIL-6 guidelines for the treatment of invasive candidiasis, aspergillosis and mucormycosis in leukemia and hematopoietic stem cell transplant patients. Haematologica 2017;102:433–44.

[22] Andes DR, Safdar N, Baddley JW, Playford G, Reboli AC, Rex JH, et al. Impact of treatment strategy on outcomes in patients with candidemia and other forms of invasive candidiasis: a patient-level quantitative review of randomized trials. Clin Infect Dis 2012;54:1110–22.
[23] Diekema D, Arbefeville S, Boyken L, Kroeger J, Pfaller M. The changing epidemiology of healthcare-associated candidemia over three decades. Diagn Microbiol Infect Dis 2012;73:45–8.
[24] Marina NM, Flynn PM, Rivera GK, Hughes WT. *Candida tropicalis* and *Candida albicans* fungemia in children with leukemia. Cancer 1991;68:594–9.
[25] Flynn PM, Marina NM, Rivera GK, Hughes WT. *Candida tropicalis* infections in children with leukemia. Leuk Lymphoma 1993;10:369–76.
[26] Klingspor L, Stintzing G, Tollemar J. Deep Candida infection in children with leukaemia: clinical presentations, diagnosis and outcome. Acta Paediatr 1997;86:30–6.
[27] Leung AY, Chim CS, Ho PL, Cheng VC, Yuen KY, Lie AK, et al. *Candida tropicalis* fungaemia in adult patients with haematological malignancies: clinical features and risk factors. J Hosp Infect 2002;50:316–9.
[28] Sendid B, Caillot D, Baccouch-Humbert B, Klingspor L, Grandjean M, Bonnin A, et al. Contribution of the Platelia *Candida*-specific antibody and antigen tests to early diagnosis of systemic *Candida tropicalis* infection in neutropenic adults. J Clin Microbiol 2003;41:4551–8.
[29] Kressel B, Szewczyk C, Tuazon CU. Early clinical recognition of disseminated candidiasis by muscle and skin biopsy. Arch Intern Med 1978;138:429–33.
[30] Jarowski CI, Fialk MA, Murray HW, Gottlieb GJ, Coleman M, Steinberg CR, et al. Fever, rash, and muscle tenderness. A distinctive clinical presentation of disseminated candidiasis. Arch Intern Med 1978;138:544–6.
[31] Slater DN, Wylde P, Harrington CI, Worth R. Systemic candidiasis: diagnosis from cutaneous manifestations. J R Soc Med 1982;75:875–8.
[32] Arena FP, Perlin M, Brahman H, Weiser B, Armstrong D. Fever, rash, and myalgias of disseminated candidiasis during antifungal therapy. Arch Intern Med 1981;141:1233.
[33] Hager JL, Mir MR, Hsu S. *Candida krusei* fungemia in an immunocompromised patient. Dermatol Online J 2010;16:5.
[34] Kothari A, Shalin SC, Rico Crescencio JC, Burgess MJ. Skin lesion with splenic microabscesses in a patient with acute myeloid leukemia. Am J Med 2016;129:e325–7.
[35] Gregory RK, Powles RL, Treleaven JG, Smith ML, Mortimer PS, Wotherspoon A, et al. Systemic candidiasis with candida vasculitis due to *Candida kruzei* in a patient with acute myeloid leukaemia. Bone Marrow Transplant 1999;23:103–4.
[36] Sun HY, Chiu YS, Tang JL, Wang JL, Chang SC, Chen YC. The usefulness of the Platelia *Candida* antigen in a patient with acute lymphocytic leukemia and chronic disseminated candidiasis. Med Mycol 2006;44:647–50.
[37] Tse E, Lie A, Ng IO, Kwong YL. Fatal skin rashes and myalgia in a leukaemic patient. Haematologica 2003;88. EIM02.
[38] Marcus J, Grossman ME, Yunakov MJ, Rappaport F. Disseminated candidiasis, *Candida* arthritis, and unilateral skin lesions. J Am Acad Dermatol 1992;26:295–7.
[39] Balandran L, Rothschild H, Pugh N, Seabury J. A cutaneous manifestation of systemic candidiasis. Ann Intern Med 1973;78:400–3.
[40] Held JL, Berkowitz RK, Grossman ME. Use of touch preparation for rapid diagnosis of disseminated candidiasis. J Am Acad Dermatol 1988;19:1063–6.
[41] Sharon V, Eisen DB, Fung MA. Cutaneous septic emboli from *Candida tropicalis*. Lancet Infect Dis 2010;10:652.
[42] Pedraz J, Delgado-Jimenez Y, Perez-Gala S, Nam-Cha S, Fernandez-Herrera J, Garcia-Diez A. Cutaneous expression of systemic candidiasis. Clin Exp Dermatol 2009;34:106–10.
[43] Fine JD, Miller JA, Harrist TJ, Haynes HA. Cutaneous lesions in disseminated candidiasis mimicking ecthyma gangrenosum. Am J Med 1981;70:1133–5.
[44] Booth LV, Collins AL, Lowes JA, Radford M. Skin rash associated with *Candida guilliermondii*. Med Pediatr Oncol 1988;16:295–6.
[45] Gunsilius E, Lass-Florl C, Kahler CM, Gastl G, Petzer AL. *Candida ciferrii*, a new fluconazole-resistant yeast causing systemic mycosis in immunocompromised patients. Ann Hematol 2001;80:178–9.
[46] Lindblad R, al-Obaidy A, Mobacken H, Rodjer S. Diagnostically usable skin lesions in *Candida septicaemia*. Mycoses 1989;32:416–20.