Clinic Rev Allerg Immunol
DOI 10.1007/s12016-017-8649-9

Skin Manifestations Associated with Autoimmune Liver Diseases: a Systematic Review

Benedetta Terziroli Beretta-Piccoli[1] · **Pietro Invernizzi**[2] · **M. Eric Gershwin**[3] · **Carlo Mainetti**[4]

© Springer Science+Business Media, LLC 2017

Abstract Autoimmune liver diseases, which include mainly autoimmune hepatitis, primary biliary cholangitis, primary sclerosing cholangitis, and the variant syndromes, are often associated with extrahepatic autoimmune diseases. However, the association with cutaneous diseases is less well described. In the present article, we provide a systematic literature review on skin manifestations linked to each of these four autoimmune liver diseases, excluding skin manifestations of systemic diseases. The association of autoimmune hepatitis with vitiligo is well known, with a particular striking association with type 2 autoimmune hepatitis, a condition occurring almost entirely in children and adolescents, much rarer and more aggressive than type 1 autoimmune hepatitis; probable associations are also identified with alopecia areata, psoriasis, and pyoderma gangrenosum. Primary biliary cholangitis is not linked to lichen planus as previously assumed, but to vitiligo, psoriasis and the very rare amicrobial pustulosis of the folds. The proposed diagnostic criteria for this latter condition include the presence of anti-mitochondrial autoantibodies, the serological hallmark of primary biliary cholangitis. The very strong association of primary sclerosing cholangitis with inflammatory bowel diseases hampers the search for an association with skin diseases, since inflammatory bowel diseases have a strong association with various dermatological condition, including neutrophilic dermatoses and erythema nodosum. Nevertheless, a probable association of primary sclerosing cholangitis with psoriasis is identified in this review. Variant syndromes, also called overlap syndromes, are likely associated with vitiligo as well, which is not surprising, since autoimmune hepatitis is a feature of these conditions and they may share regions of the MHC.

Keywords Autoimmune hepatitis · Primary biliary cholangitis · Primary sclerosing cholangitis · Variant syndrome · Vitiligo · Alopecia areata · Psoriasis · Pyoderma gangrenosum

Abbreviations

DRESS	Drug reaction with eosinophilia and systemic symptoms
AIH	Autoimmune hepatitis
PBC	Primary biliary cholangitis
PSC	Primary sclerosing cholangitis
CREST	Calcinosis, Raynaud phenomenon, esophageal dysmotility, sclerodactyly, and telangiectasia
ANA	Anti-nuclear antibodies
LKM	Liver kidney microsomal
LC	Liver cytosol
IBD	Inflammatory bowel disease
PG	Pyoderma gangrenosum
AMA	Anti-mitochondrial antibodies
IIF	Indirect immunofluorescence
MND	Multiple nuclear dots

✉ Benedetta Terziroli Beretta-Piccoli
benedetta.terziroli@hin.ch

[1] Epatocentro Ticino, Lugano, Switzerland

[2] Division of Gastroenterology and Program for Autoimmune Liver Diseases, International Center for Digestive Health, University of Milan-Bicocca, San Gerardo Hospital, Monza, Italy

[3] Division of Rheumatology Allergy and Clinical Immunology, The University of California School of Medicine, Davis, California, USA

[4] Dermatologia Ente Ospedaliero Cantonale, Ospedale Regionale Bellinzona e Valli, Bellinzona, Switzerland

Published online: 09 October 2017

Introduction

Acute and chronic liver diseases are associated with many, unspecific dermatological signs and symptoms. Acute liver injury is frequently associated with jaundice and pruritus. In addition, more specific dermatological manifestations linked to the underlying cause of liver disease may be present, such as drug-induced hypersensitivity reactions characterized by fever, lymphadenopathy, eosinophilia, hepatic damage, and cutaneous reactions, referred to as drug reaction with eosinophilia and systemic symptoms (DRESS) (Fig. 1). Other cutaneous changes linked to the cause of the liver disease include brown discoloration of the skin in hemochromatosis (bronze diabetes) and bluish discoloration of nail lunulae in Wilson's disease (azure lunulae).

Liver cirrhosis is the shared final result of any chronic liver injury, and its dermatological stigmata are well recognized. A recent series from Russia of 368 patients with chronic liver diseases of different etiologies reported some kind of coexisting skin conditions in 86.4% [1]. Cutaneous changes associated with liver cirrhosis include jaundice and scleral icterus, pruritus and prurigo nodularis, excoriations, gynecomastia, alopecia, xanthelasma, nail lesions, and vascular changes such as spider telangiectases, palmar erythema, paper money skin, and dilated abdominal wall veins [2, 3]. Another large series again from Russia of patients with chronic liver disease of different origin found 72/660 (11%) of the patients being affected by cutaneous vasculitis, mainly cirrhotic patients, and the authors propose that this cutaneous disorder may suggest a diagnosis of chronic liver disease [4]. Nail changes associated with hypoalbuminemia of liver cirrhosis include Muehrcke nails [5], characterized by transverse white bands, koilonychias, clubbed nails, and Terry nails [6]. The latter are characterized by a white opaque nail plate with only the distal part retaining its normal pink color. All these cutaneous and nail findings are not related to the specific cause of liver cirrhosis. Their presence should prompt the clinicians to search for an underling liver disease.

The most frequent and best-characterized autoimmune liver diseases are autoimmune hepatitis (AIH), primary biliary cholangitis (PBC), and primary sclerosing cholangitis (PSC). A subgroup of patients presents with clinical, biochemical, serological, and histological features of both AIH and PBC, or AIH and PSC. These conditions are referred to as overlap syndromes, although some experts suggest the name "variant syndromes," to point out that they should be classified according to the predominant disease, rather than be considered separate entities [7]. The pathologies can present either simultaneously or consecutively.

Methodology

This article provides a systematic review of reported skin diseases associated with PBC, AIH, PSC, and variant syndromes. Immunoglobulin-4-associated cholangitis is not

Fig. 1 Patient with ceftriaxone-induced drug reaction with eosinophilia and systemic symptoms (DRESS). **a**, **b** Acral diffuse erythematous exfoliative dermatitis and legs morbillform eruption; **c** facial edema, erythema, scaling, and neck morbilliform eruption

discussed in this review. Cutaneous infections, skin cancer, and skin manifestations associated with unspecific liver disease are not included. Concomitant systemic autoimmune diseases with skin manifestations such as systemic lupus erythematosus, systemic sclerosis, CREST syndrome, Sjögren's syndrome and dermatomyositis, or sarcoidosis (Fig. 2) were not considered in this article as being skin diseases. Inaccurate reports of concomitant diseases, such as "vasculitis," were not included in the review.

For the purpose of the systematic review of the literature, publications cited in PubMed (http://www.ncbi.nlm.nih.gov/pubmed) were selected using the search words "autoimmune hepatitis" and "skin," "primary biliary cirrhosis/cholangitis" and "skin," and "primary sclerosing cholangitis" and "skin." Citations were chosen on the basis of their relevance to the aim of this article. Fundamental characteristics of the abstracts judged pertinent to the review were noted, and full-length original articles were selected from the abstracts.

Autoimmune Hepatitis

AIH is a rare chronic inflammation of the liver characterized by elevated transaminase and immunoglobulin G levels, positive autoantibodies, histological evidence of interface hepatitis, and a striking response to steroid treatment [8]. If untreated, AIH has a severe prognosis, with a 5-year survival rate below 25% [9], but if adequately treated, the 10-year survival rate is about 90% [10]. Its pathogenesis is unknown: it is believed that the disease is initiated by the presentation of a liver autoantigen to a naïve CD4 effector T cell by antigen presenting cells within the liver, in a genetically predisposed subject [11, 12]. Potential viral triggers include hepatitis C virus, hepatitis B virus, hepatitis E virus, cytomegalovirus, and herpes simplex virus [11]. Non-viral environmental triggers include drugs and herbal remedies, the best documented being nitrofurantoin, minocycline, statins, and anti-tumor necrosis factor (TNF) agents [8]. It affects all ages and races, and has, as many autoimmune diseases, a female preponderance, with a reported female-to-male ratio of 4:1 [10]. The precise incidence and prevalence of AIH is unknown, due to the retrospective nature of many studies, many of them performed before the publication of standardized diagnostic criteria [13]. The reported annual incidence ranges between 1.9 per 100,000 inhabitants in Norway [14] and 3 per 100,000 inhabitants in the UK [15]. The reported prevalence ranges from 11.6 per 100,000 inhabitants in Spain [16] to 35.9 per 100,000 inhabitants in Alaskan natives [17]. The reported disease frequency is increasing in recent years, probably reflecting a true increase of disease frequency, and not only a better case ascertainment [8]. Presenting symptoms are unspecific in 40–60% of adult patients, including fatigue, nausea, arthralgia, amenorrhea, and abdominal pain [18]. Twenty to thirty percent of patients present with an acute icteric hepatitis [19], and infrequently, acute liver failure is the first manifestation of autoimmune hepatitis [20]. According to the serological profile, autoimmune hepatitis is divided into type 1, positive for anti-nuclear (ANA) and/or anti-smooth muscle autoantibodies (anti-SMA), and type 2, positive for anti-liver kidney type 1 (anti-LKM-1) and/or anti-liver cytosol type 1 (anti-LC-1) autoantibodies [12]. Type 2 affects mostly children, adolescents, and young adults, accounting for one third of pediatric cases and has a more aggressive course [21]. In pediatrics, AIH is associated with macroscopic biliary tree changes in up to half of the patients [22], a condition known as autoimmune sclerosing cholangitis. Treatment of AIH is based on corticosteroids, with azathioprine used as a steroid-sparing agent [8]. The recommended initial dose of systemic steroids is 1 mg/kg in adults and 2 mg/kg in children (up to 60 mg/day) [8, 9], which has to be rapidly tapered to a maintenance dose of 2.5–7.5 mg/day, depending on age, comorbidities, and disease severity. Azathioprine should be added only after a few weeks, particularly in jaundiced patients, because of its potential hepatotoxicity [8, 9]. Eighty to ninety percent of patients achieve complete disease control with this standard treatment, based on trials performed in the 1970 [23–25]. Second-line treatments include mycophenolate mofetil, calcineurine inhibitors, and other immunosuppressive drugs. A minority of patients has resistant disease and ultimately need liver transplantation.

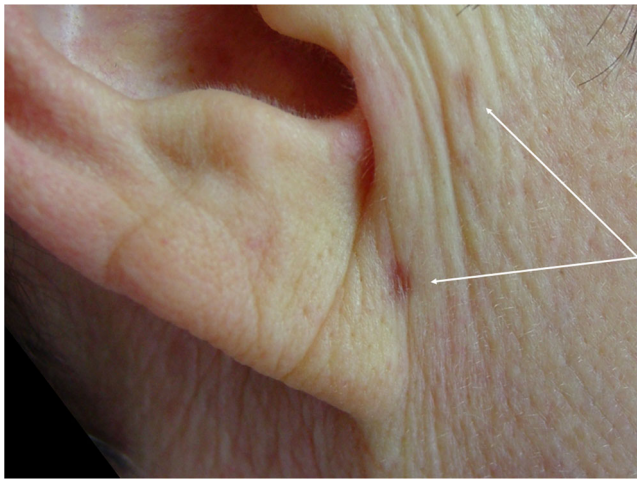

Fig. 2 Preauricular cutaneous sarcoidosis (arrows) in a patient with autoimmune hepatitis treated with mycophenolate mofetil

Both types 1 and 2 AIH are associated with extrahepatic autoimmune disorders in about 20–40% of the patients, the most frequent being Hashimoto thyroiditis, Grave's disease, inflammatory bowel disease (IBD), and type I diabetes [8, 19]. Females are more often affected by extrahepatic autoimmune conditions [26–30]. The presence of extrahepatic autoimmune diseases does not affect the prognosis of AIH [30]. The coexistence of concomitant personal or family autoimmunity

is highly characteristic in AIH, being part of the original and revised scoring systems prosed by the International Autoimmune Hepatitis Group [13, 31]. One recent retrospective large study from the UK reported an association between positive family history for autoimmunity and presence of extrahepatic autoimmune diseases in AIH patients [30]. The prevalence of concomitant autoimmune skin diseases has been evaluated in different cohorts of AIH patients (Table 1). In addition, sporadic case reports have been published (Table 1). There are also series of patients with dermatological diseases reporting concomitant extra-cutaneous diseases [32–34].

Since the treatment of AIH is based on immunosuppression, skin infections frequently occur in AIH patients but will not be discussed here. In addition, immunosuppressed patients have an increased incidence of skin cancer. A recent retrospective study from the USA [35] showed an increased risk of non-melanoma skin cancer in AIH patients on immunosuppressive treatment, the risk being also independently associated with age and age at diagnosis. A retrospective large cohort from Sweden also reported an increased risk of non-melanoma skin cancer in AIH patients, reported in 7/467 cases, 5 of them being exposed to azathioprine for years [36].

Autoimmune polyendocrinopathy-candidiasis-ectodermal dystrophy is a rare genetic autosomal recessive disorder with variable phenotype, including liver involvement resembling type 2 autoimmune hepatitis in 10–20% of patients and cutaneous autoimmune and infectious involvement, particularly chronic mucocutaneous candidiasis [37] and also alopecia areata and vitiligo [38]. Awareness of this rare condition is important, particularly in pediatrics [39] [40]. This rare syndrome is not included in this review.

An interesting population-based study from Denmark reported a higher incidence of AIH in patients with psoriasis [41]. The authors speculated a common pathogenetic role of tissue resident memory T cells in both diseases: however, this has been demonstrated for psoriasis but not for AIH. In addition, the methodology to identify AIH patients was suboptimal, basing only on the diagnostic code: for psoriasis, patients were identified also according to the prescribed treatment, but this was not the case for AIH patients. Psoriasis is treated with anti-TNF agents, which are known to trigger AIH: therefore, in this case, AIH is linked to the drug and not to psoriasis [42, 43]. In the aforementioned Danish study, the three patients with psoriasis were not treated by anti-TNF. A series of 158 AIH patients from Greece [44] found a prevalence of psoriasis of 2.5%, slightly higher than the expected prevalence in Southern Europe. Further studies are needed before an association between psoriasis and AIH can be confirmed, which is possible according to these data.

In cohorts of AIH patients, the most frequent skin disorders reported in association with AIH are vitiligo, psoriasis, and alopecia areata. Skin diseases are probably underdiagnosed and underreported in AIH: as an example, a large cohort from Japan [29] including 866 patients did not report any case of coexisting skin disease. A cohort from the UK including 164 AIH adult patients reported concomitance of vitiligo, alopecia areata, "vasculitis," and erythema nodosum, but the exact number of patients affected is not reported [45].

A prospective case collection from a large Indian gastroenterology center identified 41 AIH cases, of which 2 (5%) had concomitant vitiligo, a tenfold higher vitiligo prevalence than in the general population. Of note, not all patients underwent liver biopsy and anti-LC-1 antibodies were not assessed, therefore the cohort was not accurately characterized. Another retrospective series from India including 79 AIH patients, reported one case of vitiligo and three cases of erythema nodosum [46]. A series of AIH patients from a single Italian center found that 13/327 (3.8%) patients had a concomitant skin disease including alopecia, vitiligo, and psoriasis, but the exact number of patients affected by each disease was not reported [27]. A series of 143 patients from Brazil is of particular interest, since 82% of them had pediatric onset AIH: patients with concomitant extrahepatic autoimmune diseases were older than patients without such conditions (median age 24 years in the group with extrahepatic manifestations, 11 years in the group without, $p = 0.02$) [47]. Vitiligo was reported in 1/115 type 1 AIH patient (1%) and in 1/28 type 2 patients (4%), discoid lupus was found in 2/115 type 1 patients, and in none of the 28 type 2 AIH patients. Scleroderma was reported in 1/115 type 1 AIH, and Weber panniculitis in 1/28 type 2 AIH patients. Overall, extrahepatic autoimmune diseases were less frequent in this cohort in comparison with adult cohorts, pointing out that such conditions could be due to the longer life span in adults and can occur after the diagnosis of AIH. This finding was confirmed by a cohort from Argentina comparing children ($n = 122$) and adults ($n = 84$) with AIH: 13% of the pediatric cases had concomitant extra-hepatic autoimmune diseases, as compared with 39% of the adult cases ($p = 0.0002$). In this cohort, 5/122 (4%) children and 3/84 (3.6%) had concomitant skin diseases including psoriasis and vitiligo, but the exact number of patients affected by either disease was not reported. Another pediatric, prospective study from the UK identified the only case of concomitant urticaria pigmentosa [22]. A very recent report on concurrent extrahepatic autoimmunity in a large cohort of 562 AIH patients from the UK [30] reported a frequency of 8% for autoimmune skin diseases, with 6 cases each of vitiligo and alopecia areata (1%), a frequency higher than in the general population, where vitiligo affects 0.5 of the population [48] and alopecia areata 0.1–0.2% [49]. In this series, the precise dermatological diagnosis of the remaining 33 identified cases was not reported, the only information available being that patients with AIH type 2 were more frequently affected by concurrent autoimmune skin diseases than patients

Table 1 Cutaneous diseases associated with AIH in cohorts of AIH patients

Skin disease	Age and sex	Dermatological cases/AIH cases (%)	Year	Country	Reference
Autoimmune bullous diseases					
Pemphigus vulgaris	55, F		2008	Tunisia	Khaled et al. [122]
Dermatitis herpetiformis	NR		1997	USA/UK	Czaja et al. [123]
	65, F	1/86	2009	USA	Knoell [124]
Vitiligo	44% pediatric	6/65 (9.2)	1987	France	Homberg et al. [50]
	7, M	+ Alopecia and nail dystrophy	1990	Germany	Sacher et al. [125]
	40, F	+ Scar sarcoidosis	1996	Italy	Marzano et al. [126]
	16% pediatric	2/41 (4.9)	2005	India	Choudhuri et al. [127]
	Adult	1/79	2007	India	Amarapurkar et al. [46]
	82% pediatric	2/143 (1.4)	2008	Brazil	Bittencourt et al. [47]
	Adult	5/278 (1.8)	2010	Germany	Teufel et al. [128]
	14, M		2016	Turkey	Keskin et al. [129]
	Adult	6/562 (1)	2017	UK	Wong et al. [30]
Psoriasis	Adult	5*	2012	USA	Binus et al. [32]
	Adult	4/158 (2.5)	2016	Greece	Zachou et al. [44]
	65, M		2017	Korea	Jo et al. [130]
Alopecia areata	14, F	Type 2 AIH	1991	Switzerland	Chaves et al. [131]
	Adult	2/163 (1.2)	2009	Italy	Muratori et al. [132]
	Adult	6/562 (1)	2017	UK	Wong et al. [30]
Lichen planus	57, F	1/5 (20) Type 2 AIH	2000	USA	Duchini et al. [133]
Morphea	40, F		2006	Tunisia	Khalifa et al. [134]
Discoid lupus	NR	2/143	2008	Brazil	Bittencourt et al. [47]
Cutaneous vasculitis					
Purpura	1 adult		1998	USA	Powers et al. [135]
Vasculitis	Adult	3/11	2001	Spain	Gómez de la Torre et al. [136]
Exercise-induced vasculitis	65, F		2009	USA	Knoell [124]
Necrotizing vasculitis	42, F		2001	Spain	Gómez de la Torre et al. [136]
Cutaneous polyarteritis nodosa	26, F		2009	Korea	Lee et al. [137]
Neutrophilic dermatoses					
Amicrobial pustulosis of the folds	51, F	Anti-LKM positive	2013	Mexico	Méndez-Flores et al. [57]
Sweet's syndrome	32, F		1999	USA	Kumar et al. [56]
	24, F		2016	Canada	Cinats et al. [54]
	18, F		2016	Greece	Xenophontos et al. [55]
Pyoderma gangrenosum	20, 51, F		1976	UK	Byrne et al. [138]
	25, M		1978	Australia	Marshall et al. [139]
	34, M		1978	USA	Norris et al. [140]
	51, F		1979	USA	Burns et al. [141]
	30, F		1982	Australia	Sampson et al. [142]
	Adult	2***	1985	USA	Powell et al. [64]
	34, F		1990	UK	Banerjee et al. [143]
	30, F		2005	USA	Goldenberg et al. [58]
	14, F	Type 2 AIH	2010	Canada	Binus et al. [33]
	Adult	2****	2011	USA	Halac et al. [59]

Table 1 (continued)

Skin disease	Age and sex	Dermatological cases/AIH cases (%)	Year	Country	Reference
	17, F		2014	Canada	Wat et al. [144]
	19, F		2015	Greece	Androutsakos et al. [61]
	40, F		2017	France	Vandermergel et al. [62]
	25, F		2017	Brazil	Dantas et al. [63]
Other conditions					
Weber panniculitis	7, F		1976	UK	Allen-Mersh [145]
	NR	1/143	2008	Brazil	Bittencourt et al. [47]
Erythema nodosum	NR	1/86**	1997	USA/UK	Czaja et al. [123]
	Adult	1/85	2002	USA	Czaja et al. [26]
	3 adults	3/79	2007	India	Amarapurkar et al. [46]
	8, F		2012	Iran	Kavehmanesh et al. [52]
Pustular dermatosis of the scalp	36, F		1989	Japan	Watanabe et al. [146]
Cheeks teleangiectasia	Adult	3/11	2001	Spain	Gómez de la Torre et al. [136]
Pityriasis lichenoides chronica	13, M		2007	Turkey	Saltik-Temizel et al. [147]
Erythema annulare centrifugum	1, M		2004	India	Gulati et al. [148]
	24, F		2010	Turkey	Aygun et al. [149]
Prurigo nodularis	54, F		2011	Italy	Savoia et al. [150]
	1 adult		2014	Spain	Rodrigo-Nicolas et al. [151]
Urticaria	27, F		1998	Germany	Greving et al. [152]
	Adult	2/278 (0.7)	2010	Germany	Teufel et al. [128]
Urticaria pigmentosa	Pediatric series	1/55 (1.8)	2001	UK	Gregorio et al. [22]
Acne	1, sex and age NR	1/49	1998	Spain	Bruguera et al. [153]

AIH, autoimmune hepatitis; NR, not reported

*Series of 146 patients with psoriasis

**Probably the same case reported in two different studies carried out by the same author

***Series of 83 patients with pyoderma gangrenosum

****Series of 103 patients with pyoderma gangrenosum

with the more frequent type 1 AIH, and that the most frequent dermatological diagnosis in AIH type 2 were vitiligo, leukocytoclastic vasculitis, urticarial, and alopecia areata. That in type 2 AIH the frequency of concurrent autoimmune skin diseases may be higher than in type 1 AIH despite an overall more frequent presence of concurrent extrahepatic autoimmune diseases in type 1 as compared with type 2, has been suggested also by the Brazilian cohort [47], which, consistently with the English cohort, found a particularly high vitiligo frequency in type 2 AIH, 4%. A hallmark paper by the Daniel Alagille group in Paris reported for the first-time type 2 AIH [50], describing a series of 65 cases of "chronic active hepatitis" positive for anti-LKM-1 antibodies, 44% of them aged between 2 and 14 years: 2/65 patients had a first-degree relative affected by vitiligo. Vitiligo was also found in 6 of the 65 described cases (10.5%), and no other skin conditions were reported. In the same paper, anti-LKM-1-positive patients were compared with 60 patients with "chronic active hepatitis" positive for anti-SMA, none of which had vitiligo. Taken together, these data suggest a particularly high prevalence of vitiligo in type 2 AIH, much higher than the vitiligo prevalence in the general population of 1, and 0.25% under the age of 10 years (Fig. 3) [51].

A lot of case reports of cutaneous diseases in AIH patients have been published (Table 1), pointing out the clinician's awareness of the frequent coexistence of several autoimmune diseases in the same patient but not allowing any information about the frequency of the reported skin conditions in AIH patients. Erythema nodosum has been reported in five AIH patients, one adult [26], one child [52], and three adults from India [46]. A pediatric case of familial autoimmune enteropathy

associated with AIH and circulating anti-bullous pemphigoid antibodies without cutaneous disease has been reported [53]. Three case reports of coexisting Sweet's syndrome have been published [54–56]. Interestingly, one case of amicrobial pustulosis of the folds, a rare neutrophilic dermatosis often associated with lupus erythematosus, has been reported in association with AIH [57]. Of note, in another small dermatological series of five patients affected by amicrobial pustulosis of the folds [34], one patient has positive anti-SMA and ANA, and raised transaminase levels, suggesting a possible concomitant AIH. However, the report focused on dermatological aspects, and no more information about extra-cutaneous disease is provided.

Pyoderma gangrenosum (PG) is a severe neutrophilic dermatosis classically associated with IBD. Several cases have been reported in association with AIH [58–63], both in children and in adults. The concomitant diseases are not systematically reported, so that it cannot be excluded that some patients were also affected by IBD. In addition to the case reports, the prevalence of AIH has been assessed in two large cohorts of PG patients. The first series of 86 patients seen at the Mayo Clinic between 1970 and 1983 found two cases with concomitant AIH (2.3%) [64]; the second series which included 103 PG patients seen at the Massachusetts General Hospital between 2000 and 2007 found two cases of concomitant AIH (1.9%) [33]. These findings suggest an association between PG and AIH.

In conclusion, the present literature review highlights a probable association of vitiligo with AIH, particularly type 2. Other possible associations of AIH are with alopecia areata, psoriasis, and pyoderma gangrenosum.

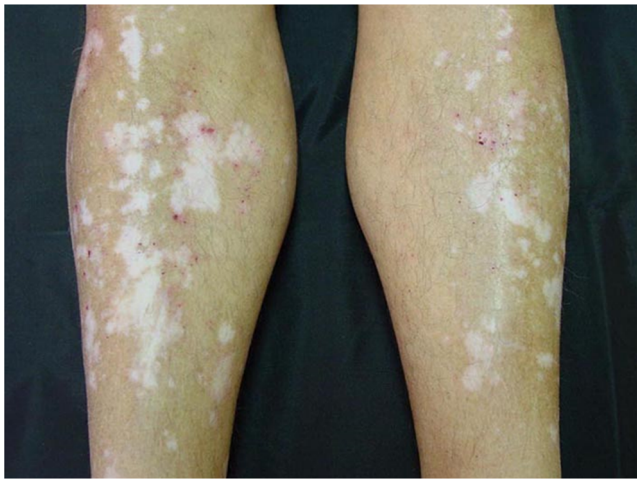

Fig. 3 Leg depigmented skin lesions in a vitiligo patient with autoimmune hepatitis

Primary Biliary Cholangitis

PBC, formerly called primary biliary cirrhosis [65–72], is a chronic autoimmune inflammation of the small and medium intrahepatic bile ducts [73] with variable clinical course, mainly affecting women with a female-to-male ratio of 10:1 [74] and a median age at diagnosis around 50 years [75]. It is considered a rare disease, but reported incidence and prevalence are rising, probably due to various reasons [76]. The disease is virtually absent in children. The two more prevalent symptoms, affecting up to 80% of patients, are pruritus and fatigue [77]. The serological hallmarks of PBC are anti-mitochondrial antibodies (AMA), which are found in 90–95% of the cases and are disease specific [75]. ANA are detected by indirect immunofluorescence (IIF) in about half of the patients [77]. Two IIF patterns are disease specific: the rim-like and the multiple nuclear dot (MND) patterns. They are generated by autoantibody reaction mainly with glycoprotein 210 or nucleoporin 62 and with Sp100 or the promyelocytic leukemia antigen, respectively [78]. The presence of these PBC-specific ANA is associated with a more severe disease course [79, 80]. The diagnosis is based on the presence of at least two of the following criteria: elevation of alkaline phosphatase of hepatic origin for at least 6 months, positive AMA and/or PBC-specific ANA, and diagnostic or compatible liver histology [81–83]. First-line treatment is ursodeoxycholic acid, 13/15 mg/kg lifelong. Patients normalizing or nearly normalizing the biochemical cholestasis in absence of advanced disease at diagnosis, have a normal life expectancy [84]. Second-line treatments are obeticholic acid or fibrates.

PBC is associated with concomitant extrahepatic diseases, including skin diseases, in up to 60% of the cases [27, 85]. The most frequent extrahepatic autoimmune diseases are Sjögren's syndrome and Hashimoto thyroiditis, their presence is not associated to a different clinical course, except for a decreased tendency to liver fibrosis in association with scleroderma [86].

Skin manifestations in PBC have been recognized since long time, particularly pruritus, which is a typical presenting symptom in PBC [81]. Butterfly sign has been reported as a typical skin finding in PBC, secondary to pruritus: it is characterized by normal skin on the upper back surrounded by hyperpigmentation secondary to scratching [87]. Hyperlipidemia is frequent in PBC patients but not associated with an increased cardio-vascular risk [88]. As a consequence, xanthomata are a common finding in PBC. In this context, it is worthy to remember that the first name used for PBC was "xantomathous biliary cirrhosis" [89, 90]. Xanthelasma (Fig. 4) and xanthoma striatum palmare are additional xanthomatoses reported in association with PBC [91–94]. Increased cutaneous pigmentation is a frequent clinical finding in PBC patients [95, 96].

The most frequently reported skin disease associated with PBC is lichen planus [97] (Fig. 5; Table 2). However, this high incidence rate is probably partially induced by D-penicillamine exposure [98, 99], a drug that has been used in the past to treat PBC [100] for its slightly immunosuppressive action. This drug is still used for Wilson's disease and is known to induce skin rash in up to 5% of the patients, including lichen planus. The association of lichen planus with chronic hepatitis C is well established, and this recognition has contributed to the recognition of the association between liver disease and lichen planus [101]. On this background, one series of 54 patients with oral lichen planus found only one case of PBC [102], and another large series of 577 patients with lichen planus only found one PBC case [102, 103]. Subsequently, a subanalysis of the 50 patients with liver disease included in the latter series did not report any PBC case, but only biopsy-proven PBC was considered, and only 12 out of the 50 patients underwent liver biopsy. A very interesting study looked for anti-MND autoantibodies in sera of a large cohort of patients with autoimmune diseases with predominantly cutaneous features. Nine-thousand-eighty-nine sera from 6240 patients were analyzed, 15 patients were positive for anti-MND autoantibodies, 2 of which affected by lichen planus and 1 by telogen effluvium [104]. None of the positive patients had PBC (normal liver biochemistry). Although 2/15 may appear a high frequency, it should be kept in mind that anti-MND autoantibodies are found in a small proportion of patients with autoimmune diseases other than PBC [78], as the population included in the study was. Taken together, all these data confirm that lichen planus is not significantly associated with PBC.

AMA are part of the proposed diagnostic criteria for amicrobial pustulosis of the folds, a rare neutrophilic dermatosis occurring almost only in young female patients in association with various autoimmune diseases [57]. However, only two cases have been reported so far, both without a reported diagnosis of PBC but only AMA positivity [34]. Of note, AMA positivity is reported in the only published case of amicrobial pustulosis of the folds associated with AIH [57]. More joint efforts between hepatologists and dermatologists are needed to establish a link between the two conditions.

Fig. 4 Xanthelasmas in a patient with primary biliary cholangitis

Fig. 5 Lichen planus of oral mucosa in a patient with chronic hepatitis C

A questionnaire-based study from France in a cohort of 222 PBC patients and 509 controls found a significantly higher number of PBC patients affected by vitiligo (4/205 versus 0/509, $p = 0.0067$) than controls, but no difference in the number of patients affected by psoriasis [105]. A case-control study from the UK, again questionnaire-based, found that a personal history of psoriasis was associated with an increased risk of PBC (Fig. 6) [106], confirming a previous study by the same group, which had found a significantly higher prevalence of psoriasis in PBC patients than controls (13 versus 3%, odds ratio 4.6). A large questionnaire-based study from the USA [107] did not report psoriasis among risk factors for PBC. Therefore, the association of PBC with psoriasis is still to be confirmed.

Vitiligo was found in 1.9% of 205 PBC patients in one series [105] and in 9% in a small series of 22 PBC patients [108]; however, in a large Italian series of 281 PBC patients, no case of concomitant skin diseases was found. These conflicting data on associated dermatological conditions need further evaluation [97].

In conclusion, the available literature does not allow to draw reliable conclusions on any skin disease associated with PBC, although some data suggest a possible association with vitiligo, psoriasis, and the very rare amicrobial pustulosis of the folds.

Primary Sclerosing Cholangitis

PSC is a rare chronic cholestatic liver disease, with progressive inflammation and fibrosis of the medium and large,

Table 2 Reported cutaneous diseases associated with primary biliary cholangitis

Skin condition	Dermatological cases/PBC cases (%) or number of cases	Year	Country	Reference
Autoimmune bullous diseases				
Pemphigus superficialis	1	1985	USA	Gibson et al. [154]
Bullous pemphigoid	1	1978	UK	Hamilton et al. [155]
	1	1983	France	Grange et al. [156]
	1	1985	USA	Singhal et al. [157]
	1	2002	France	Marcet et al. [158]
	1	2016	Mexico	Guerra-Uribe et al. [159]
Dermatitis herpetiformis	1	1985	Norway	Gabrielsen et al. [160]
	1	1987	UK	Walton et al. [161]
Vitiligo	1	1984	Israel	Enat et al. [162]
	1	1986	Italy	Zauli et al. [163]
	2/22	2000	Peru	Lozano et al. [108]
	4/205	2010	France	Corpechot et al. [105]
Psoriasis	1	1993	Japan	Okaniwa et al. [164]
	10/77	2000	UK	Howel et al. [165]
	1	2006	Japan	Iwadate et al. [166]
	1	2008	Poland	Wielosz et al. [167]
	13/205 in a cohort of PBC patients	2010	France	Corpechot et al. [105]
	1	2007	India	Amarapurkar et al. [46]
Lichen planus	Report of 6** cases	1981	USA	Seehafer et al. [98]
	5 case reports	1982	UK	Graham-Brown et al. [168]
	Report of 24* cases	1983	USA	Powell et al. [169]
	1	1984	UK	Epstein et al. [170]
	1 case in a series of 54 lichen patients	1984	Sweden	Mobacken et al. [102]
	1	1986	UK	Graham-Brown et al. [171]
	1***	1986	Sweden	Weismann et al. [99]
	1	1989	USA	Strauss et al. [172]
	1	1989	UK	Sowden et al. [173]
	1	1990	UK	Mc Donagh et al. [174]
	1 case in a series of 577 lichen planus patients	1990	Italy	GISED [103]
	1	1994	USA	Gart et al. [175]
	1	1995	Spain	Oleaga et al. [176]
	1	2000	Taiwan	Chu et al. [177]
	1 (AMA-positive)	2004	Germany	Müller et al. [178]
	2/50	2012	Italy	Cozzani et al. [104]
	1	2014	Japan	Nagao et al. [179]
Lichen sclerosus et atrophicus	1	1985	Northern Ireland	Lavery et al. [180]
	1	1986	UK	Graham-Brown et al. [171]
	1	1986	UK	Natarajan et al. [181]
	1	1986	UK	Meyrick et al. [182]
	1	1987	Sweden	Irestdt et al. [183]

Table 2 (continued)

Skin condition	Dermatological cases/PBC cases (%) or number of cases	Year	Country	Reference
Morphea	1	1986	UK	Natarajan et al. [181]
	1	1986	Japan	Suyama et al. [184]
	1	1992	UK	Wong et al. [185]
	1	2000	UK	Reed et al. [186]
	1	2006	Spain	González-López et al. [187]
	1	2015	Japan	Iga et al. [188]
Cutaneous vasculitis				
Purpura Henoch-Schönlein (IgA-vasculitis)	2	2007	Greece	Gatselis et al. [240]
Pustular vasculitis	1	2006	UK	Koulaouzidis et al. [189]
Leukocytoclastic vasculitis	1	1985	Denmark	Diederichsen et al. [190]
Cutaneous IgM immune complexes vasculitis	1	1984	The Netherlands	Reitsma et al. [191]
Circulating immune complexes vasculitis	1	1984	USA	Terkeltaub et al. [192]
Cutaneous necrotizing vasculitis	1	1976	USA	Gilliam et al. [193]
Cutaneous polyarteritis nodosa	1	2000	Japan	Dohmen et al. [194]
Behçet disease	1 in a series of 15 Behçet patients	1992	UK	Jankowski et al. [195]
	1	2006	Japan	Iwadate et al. [166]
Neutrophilic dermatoses				
Amicrobial pustulosis of the folds	1 in a dermatological series of 5 cases, isolated AMA	2008	Italy	Marzano et al. [34]
Sweet's syndrome	1	2008	USA	Owen et al. [196]
	1	2014	USA	Kaminska et al. [197]
Pyoderma gangrenosum	1	1983	USA	Maturi et al. [198]
Non-infectious granulomatoses				
Cutaneous granulomas after liver transplantation	1	2000	Israel	Armali et al. [199]
Cutaneous sarcoidosis	1	1987	USA	Keeffe et al. [200]
	1	1988	USA	Sherman et al. [201]
	1	1992	USA	Harrington et al. [202]
	1	1994	Greece	Asvesti et al. [203]
	2	2008	USA	Kishor et al. [204]
Generalized granuloma annulare	1	1990	Japan	Koizumi et al. [205]
Cutaneous granulomata	1	1977	UK	Byrne et al. [206]
	1	1994	New Zealand	Jardine et al. [207]
Other conditions				
Panniculitis	1	1996	Germany	Herr et al. [208]
Cutaneous amyloidosis	1	2007	Brazil	Tafarel et al. [209]
Scleroderma adultorum Buschke	1	1984	Germany	Goss et al. [210]
Acanthosis nigricans	1	1996	Australia	Pham et al. [211]
Disseminated cutaneous hypomelanosis	1	1997	France	Viraben et al. [212]
Eczema	2/67	2000	UK	Howel et al. [165]
Prurigo pigmentosa	1	2004	Japan	Togawa et al. [213]

Table 2 (continued)

Skin condition	Dermatological cases/PBC cases (%) or number of cases	Year	Country	Reference
Prurigo	1	1959	France	Sallet et al. [214]
Perforating dermatosis	1	2007	USA	Chiu et al. [215]
	1	2017	Switzerland	Terziroli et al. [97]

*17/24 patients exposed to D-penicilliamine

**6/6 patients exposed to D-penicillamine

***Patient exposed to D-penicillamine

intrahepatic and extrahepatic bile ducts [109]. It affects all ages, although it is still not clear if the pediatric condition referred to as autoimmune sclerosing cholangitis is part of the same disease spectrum [22]. In adults, the incidence ranges from 0 to 1.3 per 100,000 inhabitants per year, and the prevalence ranges from 0 to 16.2 per 100,000 inhabitants [109]. There is a strong association with IBD, with up to 80% of PSC patients being affected by IBD as well [109]. Sixty percent of the patients are male, median age at diagnosis is 41 years [110]. The diagnosis is based on bile duct strictures detected by endoscopic retrograde cholangiopancreatography or magnetic resonance cholangiopancreatography, associated with a biochemical cholestatic pattern, after having ruled out secondary forms. Approximately 5–10% of patients have small bile duct PSC, which has a more benign course [109]. Ursodeoxycholic acid is frequently administered to PSC patients, although guidelines are conflicting, due to lack of solid evidence of a survival benefit. PSC is associated, beside IBD, with extrahepatic autoimmune diseases, but literature is scanty on this topic, and provides only case reports, many of them reporting skin diseases in patients affected by both PSC and IBD. In IBD, the association with pyoderma gangrenosum, erythema nodosum, and neutrophilic dermatoses is well established, so that it is difficult to establish an association between PSC and cutaneous diseases, since the vast majority of PSC patients have concomitant IBD. Cutaneous diseases associated with IBD are discussed in a different article of this issue of Clinical reviews in allergy and immunology. Table 3 summarizes the reported cases of PSC patients having cutaneous diseases, excluding patients with concomitant IBD and either pyoderma gangrenosum, erythema nodosum, or neutrophilic dermatoses. Of particular interest is one case report from Japan of a young woman diagnosed with dermatitis herpetiformis at the age of 18 years, who later developed PSC and IBD and died at age 40 because of end-stage liver disease. She did not have celiac disease. In the case of a 1.5-year-old child with cutaneous vasculitis and sclerosing cholangitis in the context of Wiskott-Aldrich syndrome, a genetic disease leading to immunodeficiency and malignancies, bile duct disease was more probably due to the immunodeficiency condition rather than to PSC [111].

Besides case reports, only one series of PSC patients investigating concomitant non-IBD immunological diseases is available. In this prospective cohort of 195 PSC patients from a German tertiary center, psoriasis was found in 3.6% of patients and represented a risk factor for reduced survival [112]. This percentage is similar to the estimated psoriasis prevalence in this country [113], making an association of PSC with psoriasis unlikely.

Variant Syndromes

A subgroup of patients with AIH present with clinical, serological, histological, and radiological features of either PBC or PSC. This condition has been referred to as overlap syndrome and is often difficult to diagnose and treat in clinical practice.

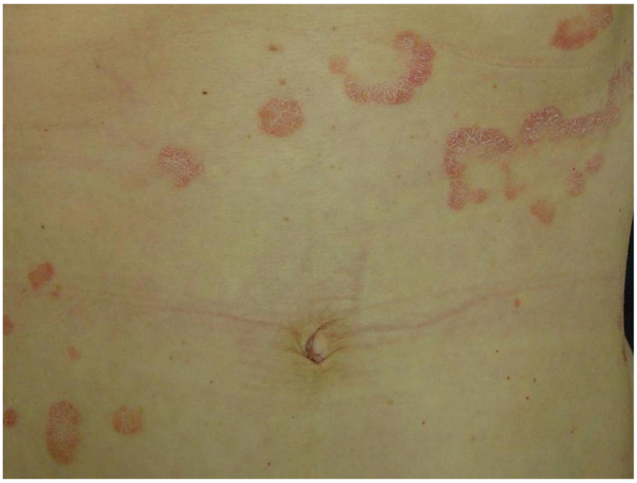

Fig. 6 Abdominal psoriatic plaques in a patient with primary biliary cholangitis

Table 3 Reported cutaneous diseases associated with primary sclerosing cholangitis without concomitant inflammatory bowel disease

Skin condition	Age	Number of cases	Year	Country	Reference
Autoimmune bullous diseases					
Linear immunoglobulin A	Adult	1*	2009	USA	Te et al. [216]
Bullous dermatitis	Adult	1	2002	USA	Hecker et al. [217]
Dermatitis herpetiformis	Adult	1	1993	UK	Lewis et al. [218]
	Adult	1*	1996	Japan	Chiba et al. [219]
	Adult	1	1999	Ireland	Kirby et al. [220]
Psoriasis	Adult	7 in a cohort of 195 PSC patients	2013	Germany	Rupp et al. [112]
Lichen planus	Adult	1	2003	Germany	Friedrich et al. [221]
	Adults	4	2002	New Zealand	Tong et al. [222]
Nail lichen planus	Child	1	2007	Saudi Arabia	Al-Ajroush et al. [223]
Cutaneous vasculitis					
Cutaneous vasculitis	Child	1	2017	Turkey	Vignesh et al. [111]
Leukocytoclastic vasculitis*	Adult	1	2008	Turkey	Akbulut et al. [224]
Pustular vasculitis			1996		Jones et al. [225]
Other conditions					
Perforating dermatosis	Adult	1	2012	USA	Beachkofsky et al. [226]
	Adult	1	1999	UK	Skiba et al. [227]
Elastosis perforans	Adult	1*	2009	Spain	Roldán-Marín et al. [228]
	Adult	1	1992	Ireland	O'Donnell et al. [229]
Perforating folliculitis	Adult	2	1985	USA	Kahana et al. [230]
	Adult	1	2004	India	Mahajan et al. [231]
Skin ulcers*	Child	1	2004	Israel	Fishman et al. [232]

*PSC and IBD

Some experts recommend to identify in every patient a prevalent disease and to classify patients accordingly, avoiding to consider overlap syndrome as a separate entity. The term variant syndrome has been proposed for this purpose [114]. Diagnostic criteria for AIH/PBC variant syndrome have been published [115]. In pediatrics, about half of the children diagnosed with AIH present with abnormal cholangiogram: this condition has been named autoimmune sclerosing cholangitis [22]. Evidence-based treatment for variant syndromes is not available, and patients are empirically treated for both diseases.

One single cohort of patients affected by AIH/PBC variant syndrome has investigated concomitant extrahepatic autoimmunity [116]. A total of 71 adult patients were included from Italy, Turkey, France, and Sweden: two of them (3%) had concomitant vitiligo and three (4.2%) had concomitant psoriasis. The frequency of vitiligo is higher than in the general population, but it is difficult to draw any conclusion for psoriasis, since its frequency is different according to different geographical areas, being as high as 8.5% in Norway and 2.9% in Italy [117], following a North-South gradient.

A few case reports on concomitant autoimmune skin diseases in PSC/AIH patients are available, including one case of cutaneous amyloidosis [118] and two cases of vitiligo [119, 120] (Table 4). One case of psoriasis is also reported in a patient with concomitant PBC and PSC, an extremely rare overlapping condition [121]. Based on these few data, a possible association of vitiligo and variant syndrome exists: this is not surprising, since AIH is part of the variant syndrome.

Genetics

One of the major disappointments in autoimmunity has been the relative failure to identify genetic "smoking guns." Nonetheless, it is clear that various autoimmune diseases tend to cluster. For example, lupus clearly clusters with scleroderma, Sjögren's syndrome, and rheumatoid arthritis. Thus, within a family and within an affected individual, these diseases are more likely to occur. Similarly, the endocrine autoimmune syndromes cluster with vitiligo and often celiac sprue. Multiple sclerosis, on the other hand, does not seem to cluster with any other autoimmune disease.

Table 4 Reported cutaneous diseases associated with autoimmune hepatitis variant syndromes

Skin condition	Age, sex, type of variant syndrome	Number of cases	Year	Country	Reference
Vitiligo	AIH/PBC	2/71	2011	France, Italy, Sweden, Turkey	Efe et al. [116]
	52, M, AIH/PBC	1	2013	Turkey	Aksoy et al. [120]
	35, F AIH/PBC	1	2014	Puerto Rico	Seiglie et al. [119]
Psoriasis	AIH/PBC	3/71	2011	France, Italy, Sweden, Turkey	Efe et al. [116]
	AIH/PBC	2/8	2007	India	Amarapurkar et al. [46]
	PSC/PBC	1	2015	Italy	Floreani et al. [121]
Other conditions					
Cutaneous amyloidosis	36, M AIH/PBC	1	2004	Mexico	González-Moreno et al. [118]

AIH, autoimmune hepatitis; PBC, primary biliary cholangitis; PSC, primary sclerosing cholangitis

To extend this analogy, we suggest that, as deep sequencing expands, particularly in family studies, there will be clearer genetic markers that may identify associated autoimmune manifestations of a given disease, likely to give statistical credence to some of the dermal associations described herein. This is an area beyond the scope of this paper and this special issue, but we will cite a number of recent reviews and cutting edge experimental papers that focus on this subject [233–239].

Conclusions

This systematic literature review on skin diseases associated with autoimmune liver diseases highlights some associations. AIH is probably significantly associated with vitiligo, in particular with the rare pediatric type 2 AIH. Other less strong associations are with alopecia areata, psoriasis, and pyoderma gangrenosum. PBC is not significantly associated with lichen planus. Possible associations are with vitiligo, psoriasis, and the very rare amicrobial pustulosis of the folds. For PSC, it is difficult to identify associations with skin diseases, since 80% of the patients have concomitant IBD, which is associated with neutrophilic dermatoses and erythema nodosum. Based on only one study, there is a possible association with psoriasis. Variant syndromes, which are not a different disease as the predominant autoimmune liver disease, are also associated with vitiligo. Overall, the quantity and quality of the data are scanty, and in the future, epidemiological studies should be more accurate in reporting skin manifestations associated with autoimmune liver diseases.

Compliance with Ethical Standards

Conflicts of Interest The authors declare that they have no conflict of interest.

Ethical Approval Not applicable.

Informed Consent Not applicable.

References

1. Pozdnyakova ON, Nemchaninova OB, Lykova SG, Reshetnikova TB (2017) Clinical features of «metabolism» diseases of the skin in patients with chronic diffuse liver diseases. Ter Arkh 89:49–53
2. Jackson JM, Callen JP, Greer KE (2017) Hepatic disease and the skin. In: Callen JP et al (eds) Dermatological signs of systemic disease, 5rd edn. Elsevier, Edinburgh, UK, pp 255–261
3. Dogra S, Jindal R (2011) Cutaneous manifestations of common liver diseases. J Clin Exp Hepatol 1:177–184
4. Russkikh AV, Kozlovskaia LV, Krivosheev OG, Mukhin NA (2005) Vascular purpura in patients with chronic diffuse hepatic diseases. Klin Med (Mosk) 83:45–48
5. Muehrcke RC (1956) The finger-nails in chronic hypoalbuminaemia; a new physical sign. Br Med J 1:1327–1328
6. Terry R (1954) White nails in hepatic cirrhosis. Lancet Lond Engl 266:757–759
7. Boberg KM, Chapman RW, Hirschfield GM, Lohse AW, Manns MP, Schrumpf E et al (2011) Overlap syndromes: the International Autoimmune Hepatitis Group (IAIHG) position statement on a controversial issue. J Hepatol 54:374–385
8. European Association for the Study of the Liver (2015) EASL clinical practice guidelines: autoimmune hepatitis. J Hepatol 63: 971–1004
9. Lohse AW, Mieli-Vergani G (2011) Autoimmune hepatitis. J Hepatol 55:171–182
10. Liberal R, Krawitt EL, Vierling JM, Manns MP, Mieli-Vergani G, Vergani D (2016) Cutting edge issues in autoimmune hepatitis. J Autoimmun DOI. https://doi.org/10.1016/j.jaut.2016.07.005
11. Longhi MS, Ma Y, Mieli-Vergani G, Vergani D (2010) Aetiopathogenesis of autoimmune hepatitis. J Autoimmun 34:7–14
12. Vergani D, Mackay IR, Mieli-Vergani G (2014) Hepatitis. In: Mackay I (ed) The autoimmune diseases, 5rd edn. Academic Press, Boston, pp 889–907
13. Johnson PJ, McFarlane IG (1993) Meeting report: International Autoimmune Hepatitis Group. Hepatol Baltim Md 18:998–1005
14. Boberg KM, Aadland E, Jahnsen J, Raknerud N, Stiris M, Bell H (1998) Incidence and prevalence of primary biliary cirrhosis, primary sclerosing cholangitis, and autoimmune hepatitis in a Norwegian population. Scand J Gastroenterol 33:99–103
15. Whalley S, Puvanachandra P, Desai A, Kennedy H (2007) Hepatology outpatient service provision in secondary care: a study of liver disease incidence and resource costs. Clin Med Lond Engl 7:119–124

16. Primo J, Merino C, Fernández J, Molés JR, Llorca P, Hinojosa J (2004) Incidence and prevalence of autoimmune hepatitis in the area of the Hospital de Sagunto (Spain). Gastroenterol Hepatol 27: 239–243
17. Hurlburt KJ, McMahon BJ, Deubner H, Hsu-Trawinski B, Williams JL, Kowdley KV (2002) Prevalence of autoimmune liver disease in Alaska Natives. Am J Gastroenterol 97:2402–2407
18. Al-Chalabi T, Underhill JA, Portmann BC, McFarlane IG, Heneghan MA (2008) Impact of gender on the long-term outcome and survival of patients with autoimmune hepatitis. J Hepatol 48:140–147
19. Manns MP, Czaja AJ, Gorham JD, Krawitt EL, Mieli-Vergani G, Vergani D et al (2010) Diagnosis and management of autoimmune hepatitis. Hepatol Baltim Md 51:2193–2213
20. Stravitz RT, Lefkowitch JH, Fontana RJ, Gershwin ME, Leung PSC, Sterling RK et al (2011) Autoimmune acute liver failure: proposed clinical and histological criteria. Hepatol Baltim Md 53:517–526
21. Mieli-Vergani G, Heller S, Jara P, Vergani D, Chang M-H, Fujisawa T et al (2009) Autoimmune hepatitis. J Pediatr Gastroenterol Nutr 49:158–164
22. Gregorio GV, Portmann B, Karani J, Harrison P, Donaldson PT, Vergani D et al (2001) Autoimmune hepatitis/sclerosing cholangitis overlap syndrome in childhood: a 16-year prospective study. Hepatol Baltim Md 33:544–553
23. Cook GC, Mulligan R, Sherlock S (1971) Controlled prospective trial of corticosteroid therapy in active chronic hepatitis. Q J Med 40:159–185
24. Soloway RD, Summerskill WH, Baggenstoss AH, Geall MG, Gitnićk GL, Elveback IR et al (1972) Clinical, biochemical, and histological remission of severe chronic active liver disease: a controlled study of treatments and early prognosis. Gastroenterology 63:820–833
25. Summerskill WH, Korman MG, Ammon HV, Baggenstoss AH (1975) Prednisone for chronic active liver disease: dose titration, standard dose, and combination with azathioprine compared. Gut 16:876–883
26. Czaja AJ, Donaldson PT (2002) Gender effects and synergisms with histocompatibility leukocyte antigens in type 1 autoimmune hepatitis. Am J Gastroenterol 97:2051–2057
27. Muratori P, Fabbri A, Lalanne C, Lenzi M, Muratori L (2015) Autoimmune liver disease and concomitant extrahepatic autoimmune disease. Eur J Gastroenterol Hepatol 27:1175–1179
28. van Gerven NMF, Verwer BJ, Witte BI, van Erpecum KJ, van Buuren HR, Maijers I et al (2014) Epidemiology and clinical characteristics of autoimmune hepatitis in the Netherlands. Scand J Gastroenterol 49:1245–1254
29. Abe M, Mashiba T, Zeniya M, Yamamoto K, Onji M, Tsubouchi H et al (2011) Present status of autoimmune hepatitis in Japan: a nationwide survey. J Gastroenterol 46:1136–1141
30. Wong G-W, Yeong T, Lawrence D, Yeoman AD, Verma S, Heneghan MA (2017) Concurrent extrahepatic autoimmunity in autoimmune hepatitis: implications for diagnosis, clinical course and long-term outcomes. Liver Int Off J Int Assoc Study Liver 37: 449–457
31. Alvarez F, Berg PA, Bianchi FB, Bianchi L, Burroughs AK, Cancado EL et al (1999) International Autoimmune Hepatitis Group Report: review of criteria for diagnosis of autoimmune hepatitis. J Hepatol 31:929–938
32. Binus AM, Han J, Qamar AA, Mody EA, Holt EW, Qureshi AA (2012) Associated comorbidities in psoriasis and inflammatory bowel disease. J Eur Acad Dermatol Venereol 26:644–650
33. Binus AM, Qureshi AA, Li VW, Winterfield LS (2011) Pyoderma gangrenosum: a retrospective review of patient characteristics, comorbidities and therapy in 103 patients. Br J Dermatol 165:1244–1250
34. Marzano AV, Ramoni S, Caputo R (2008) Amicrobial pustulosis of the folds. Report of 6 cases and a literature review. Dermatology 216:305–311
35. Leung J, Dowling L, Obadan I, Davis J, Bonis PA, Kaplan MM et al (2010) Risk of non-melanoma skin cancer in autoimmune hepatitis. Dig Dis Sci 55:3218–3223
36. Werner M, Almer S, Prytz H, Lindgren S, Wallerstedt S, Björnsson E et al (2009) Hepatic and extrahepatic malignancies in autoimmune hepatitis. A long-term follow-up in 473 Swedish patients. J Hepatol 50:388–393
37. Manns MP, Vogel A (2006) Autoimmune hepatitis, from mechanisms to therapy. Hepatol Baltim Md 43:S132–S144
38. Collins SM, Dominguez M, Ilmarinen T, Costigan C, Irvine AD (2006) Dermatological manifestations of autoimmune polyendocrinopathy-candidiasis-ectodermal dystrophy syndrome. Br J Dermatol 154:1088–1093
39. Puzenat E, Bellaud G, Saugier-Veber P, Crémillieux C, Mignot B, Humbert P et al (2014) The challenge for dermatologists of early APECED diagnosis. Ann Dermatol Venereol 141:290–294
40. Perheentupa J (2006) Autoimmune polyendocrinopathy-candidiasis-ectodermal dystrophy. J Clin Endocrinol Metab 91: 2843–2850
41. Jensen P, Egeberg A, Gislason G, Hansen PR, Thyssen JP, Skov L (2016) Increased risk of autoimmune hepatitis in patients with psoriasis: a Danish Nationwide Cohort Study. J Invest Dermatol 136:1515–1517
42. Goujon C, Dahel K, Bérard F, Guillot I, Gunera-Saad N, Nicolas J-F (2010) Autoimmune hepatitis in two psoriasis patients treated with inflixmab. J Am Acad Dermatol 63:e43–e44
43. Fairhurst DA, Sheehan-Dare R (2009) Autoimmune hepatitis associated with infliximab in a patient with palmoplantar pustular psoriaisis. Clin Exp Dermatol 34:421–422
44. Zachou K, Gatselis NK, Arvaniti P, Gabeta S, Rigopoulou EI, Koukoulis GK et al (2016) A real-world study focused on the long-term efficacy of mycophenolate mofetil as first-line treatment of autoimmune hepatitis. Aliment Pharmacol Ther 43:1035–1047
45. Al-Chalabi T, Boccato S, Portmann BC, McFarlane IG, Heneghan MA (2006) Autoimmune hepatitis (AIH) in the elderly: a systematic retrospective analysis of a large group of consecutive patients with definite AIH followed at a tertiary referral centre. J Hepatol 45:575–583
46. Amarapurkar DN, Patel ND (2007) Spectrum of autoimmune liver diseases in western India. J Gastroenterol Hepatol 22:2112–2117
47. Bittencourt PL, Farias AQ, Porta G, Cançado ELR, Miura I, Pugliese R et al (2008) Frequency of concurrent autoimmune disorders in patients with autoimmune hepatitis: effect of age, gender, and genetic background. J Clin Gastroenterol 42:300–305
48. Taïeb A, Picardo M (2009) Clinical practice. Vitiligo. N Engl J Med 360:160–169
49. Safavi K (1992) Prevalence of alopecia areata in the First National Health and Nutrition Examination Survey. Arch Dermatol 128: 702
50. Homberg JC, Abuaf N, Bernard O, Islam S, Alvarez F, Khalil SH et al (1987) Chronic active hepatitis associated with antiliver/kidney microsome antibody type 1: a second type of "autoimmune" hepatitis. Hepatol Baltim Md 7:1333–1339
51. Taïeb A, Seneschal J, Mazereeuw-Hautier J (2017) Special considerations in children with vitiligo. Dermatol Clin 35:229–233
52. Kavehmanesh Z, Beiraghdar F, Saburi A, Hajihashemi A, Amirsalari S, Movahed M (2012) Pediatric autoimmune hepatitis in a patient who presented with erythema nodosum: a case report. Hepat Mon 12:42–45
53. Lachaux A, Bouvier R, Cozzani E, Loras-Duclaux I, Kanitakis J, Chevallier M et al (1994) Familial autoimmune enteropathy with

circulating anti-bullous pemphigoid antibodies and chronic autoimmune hepatitis. J Pediatr 125:858–862
54. Cinats AK, Haber RM (2016) Case report of Sweet's syndrome associated with autoimmune hepatitis. J Cutan Med Surg. https://doi.org/10.1177/1203475416665602
55. Xenophontos E, Ioannou A, Constantinides T, Papanicolaou E (2016) Sweet syndrome on a patient with autoimmune hepatitis on azathioprine and CMV infection. Oxf Med Case Rep 2016:24–27
56. Kumar A, Helwig K, Komar MJ (1999) Sweet's syndrome in association with probable autoimmune hepatitis. J Clin Gastroenterol 29:349–350
57. Méndez-Flores S, Charli-Joseph Y, Saeb-Lima M, Orozco-Topete R, Fernández Sánchez M (2013) Amicrobial pustulosis of the folds associated with autoimmune disorders: systemic lupus erythematosus case series and first report on the association with autoimmune hepatitis. Dermatology 226:1–4
58. Goldenberg G, Jorizzo JL (2005) Use of etanercept in treatment of pyoderma gangrenosum in a patient with autoimmune hepatitis. J Dermatol Treat 16:347–349
59. Halac U, Al Dhaybi R, Powell J, Bouron-Dal Soglio D, Alvarez F (2010) Unusual association between autoimmune hepatitis and severe pyoderma gangrenosum. J Pediatr Gastroenterol Nutr 50: 219–221
60. Wat H, Haber RM (2014) Trends in the association between pyoderma gangrenosum and autoimmune hepatitis: case report and review of the literature. J Cutan Med Surg 18:345–352
61. Androutsakos T, Stamopoulos P, Aroni K, Hatzis G (2015) A case report of successful treatment of pyoderma gangrenosum in a patient with autoimmune hepatitis, and review of the literature. BMC Gastroenterol 15:149
62. Vandemergel X, Lefebvre M, Focant I, Marot L, Ilisei D (2017) Unusual association between auto-immune hepatitis and pyoderma gangrenosum. A case report. Rev Med Brux 38:95–98
63. Dantas SG, Quintella LP, Fernandes NC (2017) Exuberant pyoderma gangrenosum in a patient with autoimmune hepatitis. An Bras Dermatol 92:114–117
64. Powell FC, Schroeter AL, WP S, Perry HO (1985) Pyoderma gangrenosum: a review of 86 patients. Q J Med 55:173–186
65. Beuers U, Gershwin ME, Gish RG, Invernizzi P, Jones DEJ, Lindor K et al (2015) Changing nomenclature for PBC: from "cirrhosis" to "cholangitis". Hepatol Baltim Md 62:1620–1622
66. Beuers U, Gershwin ME, Gish RG, Invernizzi P, Jones DEJ, Lindor K et al (2015) Changing nomenclature for PBC: from "cirrhosis" to "cholangitis". Gastroenterology 149:1627–1629
67. Beuers U, Gershwin ME, Gish RG, Invernizzi P, Jones DEJ, Lindor K et al (2015) Changing nomenclature for PBC: from "cirrhosis" to "cholangitis". Gut 64:1671–1672
68. Beuers U, Gershwin ME, Gish RG, Invernizzi P, Jones DEJ, Lindor K et al (2015) Changing nomenclature for PBC: from "cirrhosis" to "cholangitis". J Hepatol 63:1285–1287
69. Beuers U, Gershwin ME, Gish RG, Invernizzi P, Jones DEJ, Lindor K et al (2015) Changing nomenclature for PBC: from "cirrhosis" to "cholangitis". Clin Gastroenterol Hepatol Off Clin Pract J Am Gastroenterol Assoc 13:1867–1869
70. Beuers U, Gershwin ME, Gish RG, Invernizzi P, Jones DEJ, Lindor K et al (2015) Changing nomenclature for PBC: from "cirrhosis" to "cholangitis". Am J Gastroenterol 110:1536–1538
71. Beuers U, Gershwin ME, Gish RG, Invernizzi P, Jones DEJ, Lindor K et al (2015) Changing nomenclature for PBC: from "cirrhosis" to "cholangitis". Clin Res Hepatol Gastroenterol 39: e57–e59
72. Beuers U, Gershwin ME, Gish RG, Invernizzi P, Jones DEJ, Lindor K et al (2015) Changing nomenclature for PBC: from "cirrhosis" to "cholangitis". Dif Liver Dis Off J Ital Soc Gastroenterol Ital Assoc Study Dif Liver 47:924–926
73. Tanaka A, Leung PSC, Young HA, Gershwin ME (2017) Toward solving the etiological mystery of primary biliary cholangitis. Hepatol Commun 1:275–287
74. Lleo A, Battezzati PM, Selmi C, Gershwin ME, Podda M (2008) Is autoimmunity a matter of sex? Autoimmun Rev 7:626–630
75. Griffiths L, Dyson JK, Jones DEJ (2014) The new epidemiology of primary biliary cirrhosis. Semin Liver Dis 34:318–328
76. Boonstra K, Beuers U, Ponsioen CY (2012) Epidemiology of primary sclerosing cholangitis and primary biliary cirrhosis: a systematic review. J Hepatol 56:1181–1188
77. Selmi C, Bowlus CL, Gershwin ME, Coppel RL (2011) Primary biliary cirrhosis. Lancet Lond Engl 377:1600–1609
78. Invernizzi P, Selmi C, Ranftler C, Podda M, Wesierska-Gadek J (2005) Antinuclear antibodies in primary biliary cirrhosis. Semin Liver Dis 25:298–310
79. Nakamura M, Kondo H, Mori T, Komori A, Matsuyama M, Ito M et al (2007) Anti-gp210 and anti-centromere antibodies are different risk factors for the progression of primary biliary cirrhosis. Hepatol Baltim Md 45:118–127
80. Wesierska-Gadek J, Penner E, Battezzati PM, Selmi C, Zuin M, Hitchman E et al (2006) Correlation of initial autoantibody profile and clinical outcome in primary biliary cirrhosis. Hepatol Baltim Md 43:1135–1144
81. Clinical Practice Guidelines EASL (2017) The diagnosis and management of patients with primary biliary cholangitis. J Hepatol 67: 145–172
82. Lindor KD, Gershwin ME, Poupon R, Kaplan M, Bergasa NV, Heathcote EJ et al (2009) Primary biliary cirrhosis. Hepatol Baltim Md 50:291–308
83. Bowlus CL, Gershwin ME (2014) The diagnosis of primary biliary cirrhosis. Autoimmun Rev 13:441–444
84. Corpechot C, Carrat F, Bahr A, Chrétien Y, Poupon R-E, Poupon R (2005) The effect of ursodeoxycholic acid therapy on the natural course of primary biliary cirrhosis. Gastroenterology 128:297–303
85. Floreani A, Franceschet I, Cazzagon N, Spinazzè A, Buja A, Furlan P et al (2015) Extrahepatic autoimmune conditions associated with primary biliary cirrhosis. Clin Rev Allergy Immunol 48: 192–197
86. Rigamonti C, Shand LM, Feudjo M, Bunn CC, Black CM, Denton CP et al (2006) Clinical features and prognosis of primary biliary cirrhosis associated with systemic sclerosis. Gut 55:388–394
87. Kaplan MM (1996) Primary biliary cirrhosis. N Engl J Med 335: 1570–1580
88. Longo M, Crosignani A, Battezzati PM, Squarcia Giussani C, Invernizzi P, Zuin M et al (2002) Hyperlipidaemic state and cardiovascular risk in primary biliary cirrhosis. Gut 51:265–269
89. Ahrens EH, Kunkel HG (1949) The relationship between serum lipids and skin xanthomata in 18 patients with primary biliary cirrhosis. J Clin Invest 28:1565–1574
90. MacMahon HE (1948) Biliary xanthomatosis (xanthomatous biliary cirrhosis). Am J Pathol 24:527–543
91. Bevans M, Batchelor WH (1950) Cholangiolitic cirrhosis and intrahepatic biliary tract obstruction and xanthomatosis. Am J Med 9:133–140
92. Lever WF, MacLean JG (1950) Primary familial xanthomatosis and biliary xanthomatosis (biliary cirrhosis with xanthomatosis). J Invest Dermatol 15:173–180
93. Hsu J-C, T-C S, Chen M-F, Liau C-S, Lee Y-T (2005) Xanthoma striatum palmare in a patient with primary biliary cirrhosis and hypercholesterolemia. J Gastroenterol Hepatol 20:1799–1800
94. Macías-Rodríguez RU, Torre-Delgadillo A (2006) Xanthelasmas and xanthomatas striatum palmare in primary biliary cirrhosis. Ann Hepatol 5:49

95. Sarin SK, Monga R, Sandhu BS, Sharma BC, Sakhuja P, Malhotra V (2006) Primary biliary cirrhosis in India. Hepatobiliary Pancreat Dis Int HBPD INT 5:105–109
96. Mills PR, Skerrow CJ, MacKie RM (1981) Melanin pigmentation of the skin in primary biliary cirrhosis. J Cutan Pathol 8:404–410
97. Terziroli Beretta-Piccoli B, Guillod C, Marsteller I, Blum R, Mazzucchelli L, Mondino C et al (2017) Primary biliary cholangitis associated with skin disorders: a case report and review of the literature. Arch Immunol Ther Exp 65:299–399
98. Seehafer JR, Rogers RS, Fleming CR, Dickson ER (1981) Lichen planus-like lesions caused by penicillamine in primary biliary cirrhosis. Arch Dermatol 117:140–142
99. Weismann K, Wantzin GL, Christensen E (1986) Lichen planus in primary biliary cirrhosis treated with penicillamine. Ugeskr Laeger 148:456–457
100. James OF (1985) D-penicillamine for primary biliary cirrhosis. Gut 26:109–113
101. Le Cleach L, Chosidow O (2012) Clinical practice. Lichen planus. N Engl J Med 366:723–732
102. Mobacken H, Nilsson LA, Olsson R, Sloberg K (1984) Incidence of liver disease in chronic lichen planus of the mouth. Acta Derm Venereol 64:70–73
103. Gruppo Italiano Studi Epidemiologici in Dermatologia (GISED) (1990) Lichen planus and liver diseases: a multicentre case-control study. BMJ 300:227–230
104. Cozzani E, Drosera M, Riva S, Parodi A (2012) Analysis of a multiple nuclear dots pattern in a large cohort of dermatological patients. Clin Lab 58:329–332
105. Corpechot C, Chrétien Y, Chazouillères O, Poupon R (2010) Demographic, lifestyle, medical and familial factors associated with primary biliary cirrhosis. J Hepatol 53:162–169
106. Prince MI, Ducker SJ, James OFW (2010) Case-control studies of risk factors for primary biliary cirrhosis in two United Kingdom populations. Gut 59:508–512
107. Gershwin ME, Selmi C, Worman HJ, Gold EB, Watnik M, Utts J et al (2005) Risk factors and comorbidities in primary biliary cirrhosis: a controlled interview-based study of 1032 patients. Hepatol Baltim Md 42:1194–1202
108. Lozano A, Vildósola H, Takano J, Vargas G, Uribe R, Moreno C (2000) Clinical and immunological profile in 22 patients with primary biliary cirrhosis. Rev Gastroenterol Peru Organo Of Soc Gastroenterol Peru 20:14–24
109. Lazaridis KN, LaRusso NF (2016) Primary Sclerosing Cholangitis. N Engl J Med 375:1161–1170
110. Molodecky NA, Kareemi H, Parab R, Barkema HW, Quan H, Myers RP et al (2011) Incidence of primary sclerosing cholangitis: a systematic review and meta-analysis. Hepatol Baltim Md 53: 1590–1599
111. Vignesh P, Suri D, Rawat A, Lau YL, Bhatia A, Das A et al (2017) Sclerosing cholangitis and intracranial lymphoma in a child with classical Wiskott-Aldrich syndrome. Pediatr Blood Cancer 64: 106–109
112. Rupp C, Mummelthei A, Sauer P, Weiss KH, Schirmacher P, Stiehl A et al (2013) Non-IBD immunological diseases are a risk factor for reduced survival in PSC. Liver Int Off J Int Assoc Study Liver 33:86–93
113. Griffiths CEM, van der Walt JM, Ashcroft DM, Flohr C, Naldi L, Nijsten T et al (2017) The global state of psoriasis disease epidemiology: a workshop report. Br J Dermatol 177:e4–e7
114. Weiler-Normann C, Lohse AW (2016) Variant syndromes of autoimmune liver diseases: classification, diagnosis and management. Dig Dis 34:334–339
115. Chazouillères O, Wendum D, Serfaty L, Montembault S, Rosmorduc O, Poupon R (1998) Primary biliary cirrhosis-autoimmune hepatitis overlap syndrome: clinical features and response to therapy. Hepatol Baltim Md 28:296–301
116. Efe C, Wahlin S, Ozaslan E, Berlot AH, Purnak T, Muratori L et al (2012) Autoimmune hepatitis/primary biliary cirrhosis overlap syndrome and associated extrahepatic autoimmune diseases. Eur J Gastroenterol Hepatol 24:531–534
117. Parisi R, Symmons DPM, Griffiths CEM, Ashcroft DM, Identification and Management of Psoriasis and Associated ComorbidiTy (IMPACT) project team (2013) Global epidemiology of pdoriasis: a systematic review of incidence and prevalence. J Invest Dermatol 133:377–385
118. González-Moreno EI, Cámara-Lemarroy CR, Borjas-Almaguer DO, Martínez-Cabriales SA, Paz-Delgadillo J, Gutiérrez-Udave R et al (2015) Cutaneous amyloidosis associated with autoimmune hepatitis-primary biliary cirrhosis overlap syndrome. Ann Hepatol 14:416–419
119. Seiglie V, Freire V, Rosado-Carrión B, Bredy R, Lozada C (2014) Vitiligo, jaundice and cholestasis in a middle aged woman: a case report. Bol Asoc Médica P R 106:37–41
120. Aksoy EK, Yilmaz B, Köklü S (2013) Autoimmune hepatitis/primary biliary cirrhosis overlap syndrome developed in a patient with vitiligo and Hashimoto thyroiditis. Eur J Gastroenterol Hepatol 25:121–122
121. Floreani A, Motta R, Cazzagon N, Franceschet I, Roncalli M, Del Ross T et al (2015) The overlap syndrome between primary biliary cirrhosis and primary sclerosing cholangitis. Dig Liver Dis Off J Ital Soc Gastroenterol Ital Assoc Study Liver 47:432–435
122. Khaled A, Fazaa B, Mrabet N, Zeglaoui F, Kamoun MR (2008) Multiple autoimmune syndrome in a patient with pemphigus vulgaris: a new combination. Tunis Med 86:595–597
123. Czaja AJ, Strettell MD, Thomson LJ, Santrach PJ, Moore SB, Donaldson PT et al (1997) Associations between alleles of the major histocompatibility complex and type 1 autoimmune hepatitis. Hepatol Baltim Md 25:317–323
124. Knoell KA (2009) Exercise-induced vasculitis associated with autoimmune disease. Cutis 83:319–322
125. Sacher M, Blümel P, Thaler H, Manns M (1990) Chronic active hepatitis associated with vitiligo, nail dystrophy, alopecia and a new variant of LKM antibodies. J Hepatol 10:364–369
126. Marzano AV, Gasparini LG, Cavicchini S, Brezzi A, Caputo R (1996) Scar sarcoidosis associated with vitiligo, autoimmune thyroiditis and autoimmune chronic hepatitis. Clin Exp Dermatol 21: 466–467
127. Choudhuri G, Somani SK, Baba CS, Alexander G (2005) Autoimmune hepatitis in India: profile of an uncommon disease. BMC Gastroenterol 5:27
128. Teufel A, Weinmann A, Kahaly GJ, Centner C, Piendl A, Wörns M et al (2010) Concurrent autoimmune diseases in patients with autoimmune hepatitis. J Clin Gastroenterol 44:208–213
129. Keskin M, Savaş-Erdeve Ş, Özbay-Hoşnut F, Kurnaz E, Çetinkaya S, Aycan Z (2016) The first childhood case with coexisting Hashimoto thyroiditis, vitiligo and autoimmune hepatitis. Turk J Pediatr 58:432–435
130. Jo W, Suh Y-S, Lee S-I, Cheon Y-H, Hong J, Lee SS et al (2017) Development of autoimmune hepatitis in a psoriasis patient without immunosuppressive therapy. Clin Mol Hepatol. https://doi.org/10.3350/cmh.2016.0035
131. Chaves V, Paunier L, Berclaz R, Delèze G, Abuaf N, Belli DC (1991) Anti-liver-kidney microsome antibody-positive autoimmune hepatitis associated with alopecia. J Pediatr Gastroenterol Nutr 12:288–290
132. Muratori P, Granito A, Quarneti C, Ferri S, Menichella R, Cassani F et al (2009) Autoimmune hepatitis in Italy: the Bologna experience. J Hepatol 50:1210–1218
133. Duchini A, McHutchison JG, Pockros PJ (2000) LKM-positive autoimmune hepatitis in the western United States: a case series. Am J Gastroenterol 95:3238–3241

134. Khalifa M, Ben Jazia E, Hachfi W, Sriha B, Bahri F, Letaief A (2006) Autoimmune hepatitis and morphea: a rare association. Gastroenterol Clin Biol 30:917–918
135. Powers JC, Hill JC, Grabski WJ (1998) Lower extremity purpura associated with new-onset autoimmune hepatitis: an unusual presentation. Cutis 62:109–110
136. Gómez de la Torre R, Florido Mancheño JI, Suárez del Villar R, Rubio Barbón S (2001) Dermatologic manifestations as presentation form of autoimmune hepatitis. An Med Interna Madr Spain 1984(18):558–559
137. Lee WJ, Kim CH, Chang SE, Lee MW, Choi JH, Moon KC et al (2009) A case of cutaneous polyarteritis nodosa in autoimmune hepatitis. Acta Derm Venereol 89:442–443
138. Byrne JP, Hewitt M, Summerly R (1976) Pyoderma gangrenosum associated with active chronic hepatitis: report of two cases. Arch Dermatol 112:1297–1301
139. Marshall AW, Slonim JM, Smallwood RA, Fraser KJ (1978) The association of chronic active hepatitis with pyoderma gangrenosum. Aust NZ J Med 8:656–658
140. Norris DA, Weston WL, Thorne G, Humbert JR (1978) Pyoderma gangrenosum. Abnormal monocyte function corrected in vitro with hydrocortisone. Arch Dermatol 114:906–911
141. Burns DA, Sarkany I (1979) Active chronic hepatitis and pyoderma gangrenosum: report of a case. Clin Exp Dermatol 4:465–469
142. Sampson JA, Harris OD, Van Deth AG (1982) Pyoderma gangrenosum and chronic active hepatitis: a case report. Australas J Dermatol 23:93–96
143. Banerjee AK (1990) Chronic active hepatitis, pyoderma gangrenosum and febrile panniculitis. Br J Clin Pract 44:32–33
144. Wat H, Haber RM (2014) Trends in the association between pyoderma gangrenosum and autoimmune hepatitis: case report and review of the literature. J Cutan Med Surg 18:345–352
145. Allen-Mersh TG (1976) Weber-Christian panniculitis and autoimmune disease: a case report. J Clin Pathol 29:144–149
146. Watanabe S, Takizawa K, Hashimoto N, Ishibashi Y (1989) Pustular dermatosis of the scalp associated with autoimmune diseases. J Dermatol 16:383–387
147. Saltik-Temizel IN, Ersoy-Evans S, Demir H, Yüce A (2007) Pityriasis lichenoides chronica: an association with autoimmune hepatitis? Pediatr Dermatol 24:71–73
148. Gulati S, Mathur P, Saini D, Mannan R, Kalra V (2004) Erythema annulare centrifugum with autoimmune hepatitis. Indian J Pediatr 71:541–542
149. Aygun C, Kocaman O, Gurbuz Y, Celebi A, Senturk O, Hulagu S (2010) Erythema annulare centrifugum: a rare skin finding of autoimmune hepatitis. Gastroenterol Res 3:96–98
150. Savoia F, Casadio C, Tabanelli M, Gaddoni G, Savoia F, Patrizi A et al (2011) Prurigo nodularis as the first manifestation of a chronic autoimmune cholestatic hepatitis. Int J Dermatol 50:1588–1589
151. Rodrigo-Nicolás B, Velasco-Pastor M, Molés-Poveda P, González-López O (2014) Autoimmune chronic hepatitis presenting as prurigo nodularis. Gastroenterol Hepatol 37:462–464
152. Greving I, Monnerjahn C, Schwegler U, Meister V, Tromm A, Müller KM et al (1998) Jaundice and progressive liver failure: delayed diagnosis of autoimmune hepatitis due to abrupt termination of steroid therapy? Z Gastroenterol 36:847–851
153. Bruguera M, Caballería L, Parés A, Rodés J (1998) Autoimmune hepatitis. Clinical characteristics and response to treatment in a series of 49 Spanish patients. Gastroenterol Hepatol 21:375–381
154. Gibson LE, Dicken CH (1985) Pemphigus erythematosus, primary biliary cirrhosis, and D-penicillamine: report of a case. J Am Acad Dermatol 12:883–885
155. Hamilton DV, McKenzie AW (1978) Bullous pemphigoid and primary biliary cirrhosis. Br J Dermatol 99:447–450
156. Grange JD, Mallet L, Nochy D, Petite JP (1983) Bullous pemphigoid in primary biliary cirrhosis. Gastroentérologie Clin Biol 7: 828
157. Singhal PC, Scharschmidt LA (1985) Membranous nephropathy associated with primary biliary cirrhosis and bullous pemphigoid. Ann Allergy 55:484–485
158. Marcet B, Sibaud V, Géniaux M, Taieb A (2002) Bullous pemphigoid, primary biliary cirrhosis and vitiligo: a multiple autoimmune syndrome? Ann Médecine Interne 153:349–350
159. Guerra-Uribe NB, González-Huezo MS (2016) Bullous pemphigoid and primary biliary cirrhosis, an infrequent association: A case report. Rev Gastroenterol Mex 81:174–176
160. Gabrielsen TO, Hoel PS (1985) Primary biliary cirrhosis associated with coeliac disease and dermatitis herpetiformis. Dermatologica 170:31–34
161. Walton C, Walton S (1987) Primary biliary cirrhosis in a diabetic male with dermatitis herpetiformis. Clin Exp Dermatol 12:46–47
162. Enat R, Gilhar A (1984) Vitiligo and primary biliary cirrhosis. Am J Gastroenterol 79:804–805
163. Zauli D, Crespi C, Barzagli M, Bianchi FB, Tosti A, Lama L et al (1986) Vitiligo and biliary cirrhosis. Am J Gastroenterol 81:91
164. Okaniwa S, Takamatsu M, Fujita K, Miyata Y, Koyama T, Yamada S et al (1993) A male case of primary biliary liver cirrhosis found in the course of psoriasis. Nihon Naika Gakkai Zasshi J Jpn Soc Intern Med 82:909–910
165. Howel D, Fischbacher CM, Bhopal RS, Gray J, Metcalf JV, James OF (2000) An exploratory population-based case-control study of primary biliary cirrhosis. Hepatol Baltim Md 31:1055–1060
166. Iwadate H, Ohira H, Saito H, Takahashi A, Rai T, Takiguchi J et al (2006) A case of primary biliary cirrhosis complicated by Behçet's disease and palmoplantar pustulosis. World J Gastroenterol 12: 2136–2138
167. Wielosz E, Majdan M, Zychowska I, Jeleniewicz R (2008) Coexistence of five autoimmune diseases: diagnostic and therapeutic difficulties. Rheumatol Int 28:919–923
168. Graham-Brown RA, Sarkany I, Sherlock S (1982) Lichen planus and primary biliary cirrhosis. Br J Dermatol 106:699–703
169. Powell FC, Rogers RS, Dickson ER (1983) Primary biliary cirrhosis and lichen planus. J Am Acad Dermatol 9:540–545
170. Epstein O (1984) Lichen planus and liver disease. Br J Dermatol 111:473–475
171. Graham-Brown RA, Sarkany I (1986) Lichen sclerosus et atrophicus. With primary biliary cirrhosis and lichen planus. Int J Dermatol 25:317
172. Strauss RA, Fattore L, Soltani K (1989) The association of mucocutaneous lichen planus and chronic liver disease. Oral Surg Oral Med Oral Pathol 68:406–410
173. Sowden JM, Cartwright PH, Green JR, Leonard JN (1989) Isolated lichen planus of the nails associated with primary biliary cirrhosis. Br J Dermatol 121:659–662
174. Mc Donagh AJ, Leyva-Leon F, Gawkrodger DJ, Ward AM (1990) Lichen planus is not commonly a skin marker of primary biliary cirrhosis. Dermatologica 180:111
175. Gart GS, Camisa C (1994) Ulcerative and oral lichen planus associated with sicca syndrome and primary biliary cirrhosis. Cutis 53: 249–250
176. Oleaga JM, Gardeazabal J, Sanz de Galdeano C, Diaz PJ (1995) Generalized lichen planus associated with primary biliar cirrhosis which resolved after liver transplantation. Acta Derm Venereol 75: 87
177. Chu CY, Yang CY, Huang SF, SC L, Wang LF (2000) Lichen planus with xanthomatous change in a patient with primary biliary cirrhosis. Br J Dermatol 142:377–378
178. Müller FB, Groth W, Mahrle G (2004) Multiple autoimmune syndrome. Reynolds-syndrome (acral scleroderma, primary biliary cirrhosis, Sjögren syndrome) associated with the lupus

erythematosus/lichen planus overlap syndrome. Hautarzt 55:465–470
179. Nagao Y, Sata M (2014) Disappearance of oral lichen planus after liver transplantation for primary biliary cirrhosis and immunosuppressive therapy in a 63-year-old Japanese woman. Hepat Mon 14: e16310
180. Lavery HA, Pinkerton JH, Callender M (1985) The association of lichen sclerosus et atrophicus and primary biliary cirrhosis. Br J Dermatol 112:729–730
181. Natarajan S, Green ST (1986) Generalized morphoea, lichen sclerosus et atrophicus and primary biliary cirrhosis. Clin Exp Dermatol 11:304–308
182. Meyrick Thomas RH, Ridley CM, McGibbon DH, Black MM (1986) Association between lichen sclerosus et atrophicus and primary biliary cirrhosis. Br J Dermatol 114:514–515
183. Irestedt M, Svensson A (1987) Genital and extragenital lichen sclerosus et atrophicus in a male patient with hepatosis and anti-mitochondrial antibodies. Br J Dermatol 117:527–528
184. Suyama Y, Murawaki Y, Horie Y, Hirayama C, Kanbe N, Takenaka M et al (1986) A case of primary biliary cirrhosis associated with generalized morphea. Hepato-Gastroenterology 33: 199–200
185. Wong SS, Holt PJ (1992) Generalized morphoea and primary biliary cirrhosis: a rare association and improvement with oxypentifylline. Clin Exp Dermatol 17:371–373
186. Reed JR, De Luca N, McIntyre AS, Wilkinson JD (2000) Localized morphoea, xanthomatosis and primary biliary cirrhosis. Br J Dermatol 143:652–653
187. González-López MA, Drake M, González-Vela MC, Armesto S, Llaca HF, Val-Bernal JF (2006) Generalized morphea and primary biliary cirrhosis coexisting in a male patient. J Dermatol 33:709–713
188. Iga N, Otsuka A, Iwata M, Ueda Y, Kabashima K (2015) Generalized morphea with preceding severe pain and coexistent early primary biliary cirrhosis. Eur J Dermatol 25:365–366
189. Koulaouzidis A, Campbell S, Bharati A, Leonard N, Azurdia R (2006) Primary biliary cirrhosis associated pustular vasculitis. Ann Hepatol 5:177–178
190. Diederichsen H, Sørensen PG, Mickley H, Hage E, Schultz-Larsen F (1985) Petechiae and vasculitis in asymptomatic primary biliary cirrhosis. Acta Derm Venereol 65:263–266
191. Reitsma DJ, Gratama S, Vroom TM (1984) Clinical remission of membranous glomerulonephritis in primary biliary cirrhosis with cutaneous vasculitis. Br Med J Clin Res Ed 288:27–28
192. Terkeltaub R, Esdaile JM, Bruneau C, Danoff D, Watters AK (1984) Vasculitis as a presenting manifestation of primary biliary cirrhosis: a case report. Clin Exp Rheumatol 2:67–73
193. Gilliam JN, Smiley JD (1976) Cutaneous necrotizing vasculitis and related disorders. Ann Allergy 37:328–339
194. Dohmen K, Miyamoto Y, Irie K, Takeshita T, Ishibashi H (2000) Manifestation of cutaneous polyarteritis nodosa during interferon therapy for chronic hepatitis C associated with primary biliary cirrhosis. J Gastroenterol 35:789–793
195. Jankowski J, Crombie I, Jankowski R (1992) Behçet's syndrome in Scotland. Postgrad Med J 68:566–570
196. Owen CE, Malone JC, Callen JP (2008) Sweet-like dermatosis in 2 patients with clinical features of dermatomyositis and underlying autoimmune disease. Arch Dermatol 144:1486–1490
197. Kaminska ECN, Nwaneshiudu AI, Ruiz de Luzuriaga A, Tsoukas M, Bolotin D (2014) Giant cellulitis-like Sweet syndrome in the setting of autoimmune disease. J Am Acad Dermatol 71:e94–e95
198. Maturi MF, Fine JD, Schaffer EH, Minuk GY, Hoofnagle JH (1983) Pyoderma gangrenosum associated with primary biliary cirrhosis. Arch Intern Med 143:1261–1263
199. Armali Z, Bassan L, Bergman R, Baruch Y (2000) Skin granulomas after liver transplantation: unusual presentation of recurrent primary biliary cirrhosis. Transplant Proc 32:717
200. Keeffe EB (1987) Sarcoidosis and primary biliary cirrhosis. Literature review and illustrative case. Am J Med 83:977–980
201. Sherman S, Nieland NS, Van Thiel DH (1988) Sarcoidosis and primary biliary cirrhosis. Coexistence in a single patient. Dig Dis Sci 33:368–374
202. Harrington AC, Fitzpatrick JE (1992) Cutaneous sarcoidal granulomas in a patient with primary biliary cirrhosis. Cutis 49:271–274
203. Asvesti C, Hadziyannis SJ, Papadopoulos S, Giakoumoglou T, Hadziolou E, Trichia E et al (1994) Sweat gland carcinoma in a patient with sarcoidosis and primary biliary cirrhosis. Dermatology 189:198–202
204. Kishor S, Turner ML, Borg BB, Kleiner DE, Cowen EW (2008) Cutaneous sarcoidosis and primary biliary cirrhosis: A chance association or related diseases? J Am Acad Dermatol 58:326–335
205. Koizumi H, Matsumura T, Kumakiri M, Ohkawara A (1990) Generalized granuloma annulare with primary biliary cirrhosis. Nihon Hifuka Gakkai Zasshi Jpn J Dermatol 100:871–878
206. Byrne JP, Cochrane AM, Williams DI, Williams R (1977) Cutaneous granulomata with primary biliary cirrhosis. Proc R Soc Med 70:897–898
207. Jardine DL, Chambers ST, Hart DJ, Chapman BA (1994) Primary biliary cirrhosis presenting with granulomatous skin lesions. Gut 35:564–566
208. Herr W, Lohse AW, Spahn TW, Dienes HP, Trautmann F, Meyer zum Büschenfelde KH et al (1996) Nodular nonsuppurative panniculitis in association with primary biliary cirrhosis and Hashimoto's thyroiditis. Z Für Rheumatol 55:122–126
209. Tafarel JR, Lemos LB, Oliveira PM, Lanzoni VP, Ferraz MLG (2007) Cutaneous amyloidosis associated with primary biliary cirrhosis. Eur J Gastroenterol Hepatol 19:603–605
210. Goss F, Krawietz W, Luderschmidt C, Pape GR (1984) Scleredema adultorum Buschke and primary biliary cirrhosis in a 58-year-old patient. Internist 25:130–134
211. Pham TH, Kaushik S, Lin BP, Jones DB (1996) Case report: acanthosis nigricans in association with primary biliary cirrhosis: resolution after liver transplantation. J Gastroenterol Hepatol 11: 1021–1023
212. Viraben R, Couret B, Gorguet B (1997) Disseminated reticulate hypomelanosis developing during primary biliary cirrhosis. Dermatology 195:382–383
213. Togawa Y, Shinkai H, Utani A (2004) Prurigo pigmentosa in a patient with primary biliary cirrhosis and Sjögren syndrome. J Dermatol 31:815–819
214. Sallet J, Duperrat B, Guilaine J (1959) Prurigo revealing primary biliary cirrhosis. Bull Société Fr Dermatol Syphiligr 4:425–429
215. Chiu MW, Haley JC (2007) Acquired perforating dermatosis associated with primary biliary cirrhosis and hashimoto thyroiditis. Cutis 79:451–455
216. Te CC, le V, Kastens DJ (2009) Linear immunoglobulin a bullous dermatitis, sclerosing cholangitis, and sacroilitis in a young man with ulcerative colitis. Clin Gastroenterol Hepatol Off Clin Pract J Am Gastroenterol Assoc 7:A20–Ae1
217. Hecker MS, Hecker DJ, Weinberg JM (2002) Linear IgA bullous dermatosis in a patient with sclerosing cholangitis. J Eur Acad Dermatol Venereol 16:83–84
218. Lewis HM, Goldin R, Leonard JN (1993) Dermatitis herpetiformis and primary sclerosing cholangitis. Clin Exp Dermatol 18:363–365
219. Chiba M, Tobori F, Yagisawa H, Komatsu M, Maie O, Masamune O (1999) A Japanese case of ulcerative colitis associated with dermatitis herpetiformis and primary sclerosing cholangitis. Inflamm Bowel Dis 2:255–259

220. Kirby B, Keaveney A, Brophy D, O'Donoghue D, Rogers S (1999) Abnormal liver function tests induced by dapsone in a patient with dermatitis herpetiformis and primary sclerosing cholangitis. Br J Dermatol 141:172–173
221. Friedrich RE, Heiland M, El-Moawen A, Dogan A, von Schrenck T, Löning T (2003) Oral lichen planus in patients with chronic liver diseases. Infection 31:383–386
222. Tong DC, Ferguson MM (2002) Concurrent oral lichen planus and primary sclerosing cholangitis. Br J Dermatol 147:356–358
223. Al-Ajroush N, Al-Khenaizan S (2007) Isolated nail lichen planus with primary sclerosing cholangitis in a child. Saudi Med J 28: 1441–1442
224. Akbulut S, Ozaslan E, Topal F, Albayrak L, Kayhan B, Efe C (2008) Ulcerative colitis presenting as leukocytoclastic vasculitis of skin. World J Gastroenterol 14:2448–2450
225. Jones SA, Black MM, Thompson RP (1996) Pustular vasculitis and sclerosing cholangitis. Br J Dermatol 135:662–663
226. Beachkofsky T, Cragun WC (2012) A case of perforating dermatosis in a patient with primary sclerosing cholangitis. J Drugs Dermatol 11:881–882
227. Skiba G, Milkiewicz P, Mutimer D, Burns DA, Marsden JR, Elias E (1999) Successful treatment of acquired perforating dermatosis with rifampicin in an Asian patient with sclerosing cholangitis. Liver 19:160–163
228. Roldán-Marín R, de la Barreda-Becerril F, Toussaint-Caire S, Piñeiro-Acosta E (2009) Ulcerative colitis and sclerosing cholangitis associated with elastosis perforans. A case review. Gac Médica México 145:61–64
229. O'Donnell B, Kelly P, Dervan P, Powell FC (1992) Generalized elastosis perforans serpiginosa in Down's syndrome. Clin Exp Dermatol 17:31–33
230. Kahana M, Trau H, Dolev E, Schewach-Millet M, Gilon E (1985) Perforating folliculitis in association with primary sclerosing cholangitis. Am J Dermatopathol 7:271–276
231. Mahajan S, Koranne RV, Sardana K, Mendiratta V, Damani A (2004) Perforating folliculitis with jaundice in an Indian male: a rare case with sclerosing cholangitis. Br J Dermatol 150:614–616
232. Fishman G, DeRowe A, Wasserman D, Leider-Trejo L, Reif S (2004) Inflammatory bowel disease and sclerosing cholangitis with ulcerative lesions on skin and soft palate. Int J Pediatr Otorhinolaryngol 68:1349–1352
233. Xiang Z, Yang Y, Chang C, Lu Q (2017) The epigenetic mechanism for discordance of autoimmunity in monozygotic twins. J Autoimmun. https://doi.org/10.1016/j.jaut.2017.04.003
234. Marzorati S, Lleo A, Carbone M, Gershwin ME, Invernizzi P (2016) The epigenetics of PBC: the link between genetic susceptibility and environment. Clin Res Hepatol Gastroenterol 40:650–659
235. Bernuzzi F, Marabita F, Lleo A, Carbone M, Mirolo M, Marzioni M et al (2016) Serum microRNAs as novel biomarkers for primary sclerosing cholangitis and cholangiocarcinoma. Clin Exp Immunol 185:61–71
236. Generali E, Ceribelli A, Antonietta Stazi M, Selmi C (2017) Lessons learned from twins in autoimmune and chronic inflammatory diseases. J Autoimmun. https://doi.org/10.1016/j.jaut.2017.04.005
237. Tang R, Wei Y, Li Z, Chen H, Miao Q, Bian Z et al (2016) A common variant in CLDN14 is associated with primary biliary cirrhosis and bone mineral density. Sci Rep 6:19877
238. Cordell HJ, Han Y, Mells GF, Li Y, Hirschfield GM, Greene CS, Xie G, Juran BD, Zhu D, Qian DC, Flloyd JA, Morley KI, Prati D, Lleo A, Cusi D, Canadian-US PBC Consortium, Italian PBC Genetics Study Group, UK-PBC Consortium, Gershwin ME, Anderson CA, Lazaridis KN, Invernizzi P, Seldin MF, Sandford RN, Amos CI, Siminovitch KA (2015) International genome-wide meta-analysis identifies new primary biliary cirrhosis risk loci and targetable pathogenic pathways. Nat Commun 6:8019
239. Aune TM, Crooke PS III, Patrick AE, Tossberg JT, Olsen NJ, Spurlock CF III (2017) Expression of long non-coding RNAs in autoimmunity and linkage to enhancer function and autoimmune disease risk genetic variants. J Autoimmun 81:99–109
240. Gatselis NK, Stefos A, Gioti C, Rigopoulou EI, Dalekos GN (2007) Primary biliary cirrhosis and Henoch-Schonlein purpura: report of two cases and review of the literature. Liver Int 27(2): 280–283