International Journal of Clinical Oncology
https://doi.org/10.1007/s10147-017-1231-x

REVIEW ARTICLE

Incidence, risk and prognostic role of anti-epidermal growth factor receptor-induced skin rash in biliary cancer: a meta-analysis

Fangqiang Wei[1,2] · Donghun Shin[2] · Xiujun Cai[1]

Received: 27 October 2017 / Accepted: 20 December 2017
© Japan Society of Clinical Oncology 2017

Abstract

Background Anti-epidermal growth factor receptor (EGFR)-induced skin rash is a common adverse event and is considered a prognostic factor of various cancers. However, the role of rash is rarely known in biliary cancer, possibly owing to the low incidence of this frequently fatal malignancy. We thus performed a meta-analysis to investigate the incidence, risk and prognostic significance of skin rash related to anti-EGFR treatment for biliary cancer.

Methods Eligible studies were enrolled after a systematic search of electronic databases. A fixed-effects or random-effects model was utilized according to the heterogeneity.

Results Fourteen clinical trials published between 2006 and 2017 comprising 1,106 patients with advanced biliary cancer were included. The overall incidence of all-grade and high-grade (grade ≥3) rash was 78.2% [95% confidence interval (CI) 70.4–84.3] and 11.3% (7.6–16.5), respectively. Anti-EGFR treatment correlates with a significantly increased risk of all-grade [risk ratio (RR) 7.37, 95% CI 5.11–10.64, $p < 0.0001$] and high-grade (RR 6.94, 95% CI 1.89–25.45, $p = 0.0035$) rash compared with control medication. Higher grades of skin rash correlate with a higher objective response rate (RR 3.50, 95% CI 1.47–8.33, $p = 0.0048$), and a longer overall [hazard ratio (HR) 0.47, 95% CI 0.31–0.71, $p = 0.0003$) and progression-free survival (HR 0.51, 95% CI 0.36–0.72, $p = 0.0001$) compared with lower grades or no rash in patients who received anti-EGFR treatment.

Conclusions Anti-EGFR treatment correlates with an increased risk of skin rash in advanced biliary cancer. Stratifying patients by the severity of rash may have major implications for survival benefit regarding anti-EGFR treatment for biliary cancer.

Keywords Skin rash · Anti-EGFR · Biliary cancer · Survival · Meta-analysis

Introduction

Biliary cancer, including gallbladder carcinoma, cholangiocarcinoma and cancer of ampulla of Vater, is the second most common primary liver malignancy after hepatocellular carcinoma [1]. Approximately 52,000 new cases of liver and biliary cancer are diagnosed per year in the United States, of which 15,000 are biliary cancer [2]. Although surgery is the only definitive therapy, few patients are able to undergo surgery because of an invariably late diagnosis at advanced stages. Moreover, frequent recurrence after surgery results in an urgent need for improvement in treatment efficacy, with chemotherapy [3, 4] and target therapy [5–9] being increasingly investigated.

As one of the popular targets, epidermal growth factor receptor (EGFR), a tyrosine kinase receptor, is frequently overexpressed in human cancer [10]. The pharmacological

Electronic supplementary material The online version of this article (https://doi.org/10.1007/s10147-017-1231-x) contains supplementary material, which is available to authorized users.

✉ Xiujun Cai
caixiujunzju@163.com

Fangqiang Wei
wdfwfq@126.com

Donghun Shin
donghuns@pitt.edu

[1] Department of General Surgery, Institute of Minimally Invasive Surgery, Sir Run Run Shaw Hospital, School of Medicine, Zhejiang University, No. 3, Qingchun Road, Hangzhou 310016, Zhejiang, China

[2] Department of Developmental Biology, Pittsburgh Liver Research Center, McGowan Institute for Regenerative Medicine, School of Medicine, University of Pittsburgh, Pittsburgh, PA 15260, USA

Published online: 30 December 2017

blockade of EGFR disrupts cell proliferation, differentiation, migration and survival, through its downstream target including JAK (Janus kinase)/STAT3 (signal transducer and activator of transcription 3), MAPK (mitogen-activated protein kinase) and PI3K (phosphatidylinositol-3-kinase)/AKT (protein kinase B) [11, 12]. Clinical benefit of anti-EGFR treatment has been reported in colorectal cancer [13–15], non-small-cell lung cancer [16] and head and neck squamous cell carcinoma [17, 18]. However, for advanced biliary cancer, the published randomized trials (one phase III [5] and four phase II trials [6–9]) demonstrated no survival benefit of anti-EGFR treatment over chemotherapy. A possible reason for this failure may be the lack of a predictive biomarker that stratifies patients who may acquire survival gain from this novel target therapy.

As is common in novel target therapies, anti-EGFR treatment is associated with numerous adverse events. Skin rash is a major problem that has been confirmed in systematic studies of various cancers [19–23] and is a prognostic factor for solid tumors including colorectal cancer [20, 21], non-small-cell lung cancer [19, 21] and head and neck squamous cell carcinoma [21]. In fact severe skin rash (grade ≥3) has been noted in trials in advanced biliary cancer, with an incidence ranging from 2.2−37.1% [5, 6, 8, 9, 24–32]. However, the role of rash has never been systematically studied in biliary cancer. Considering the importance of searching for an effective treatment strategy for biliary cancer, the potential prognostic role of skin rash and the small sample size in trials, we conducted a meta-analysis of previously published clinical trials to address the incidence, risk and prognostic significance of rash in this setting.

Methods

Data source

The study was performed in accordance with the guidelines of PRISMA [33] and the Cochrane Handbook for Systematic Reviews of Interventions [34]. We carried out a systematic search of PubMed, Web of Science, Cochrane Library databases and abstracts from the American Society of Clinical Oncology annual meetings held between January 2013 and August 2017. Search terms included 'cetuximab', 'erlotinib', 'panitumumab', 'biliary', 'cholangiocarcinoma' and 'gallbladder'. The language was restricted to English. An additional search from relevant references was manually performed for further supplementation.

Study selection

This study aimed to evaluate the incidence, risk and prognostic significance of adverse events of skin rash while undergoing approved anti-EGFR therapies including cetuximab, erlotinib and panitumumab, which are commonly used clinically to treat advanced biliary cancer. Therefore, we included clinical trials and excluded phase I trials that might have relatively variable treatment doses of anti-EGFR therapies. Inclusion criteria were prospective clinical trials (phase II or beyond) comprising at least 10 cases with advanced biliary cancer only; anti-EGFR therapies were applied as the only targeted therapy with or without chemotherapy; and reported events or incidents of toxic effect (i.e., skin rash). Trials reporting the same patient cohort were excluded after inclusion of the more recent trial or the one with sufficient information regarding rash.

Clinical outcomes

The primary clinical outcomes were all-grade and high-grade (grade ≥3) skin rash. Grades of rash were defined according to version 3 or 4 of the Common Terminology Criteria for Adverse Events (CTCAE). Secondary outcomes were the objective response rate (ORR), overall survival (OS) and progression-free survival (PFS) in anti-EGFR-treated patients categorized by the severity of rash.

Statistical analysis

All analyses were performed using the Comprehensive Meta-Analysis program (version 2; Biostat, Englewood, NJ, USA). Data for numbers of all-grade and high-grade skin rash were extracted. The incidence of patients with rash was calculated along with a 95% confidence interval (CI). In the meta-analysis with a control group, the risk ratio (RR) of skin rash was determined. In the meta-analysis among anti-EGFR-treated patients categorized by the severity of rash, the RR of ORR was also calculated; the hazard ratio (HR) for OS and PFS was either directly extracted or estimated based on the methods described by Tierney et al. [35]. Heterogeneity was evaluated by Cochrane's Q statistic. When the p value was < 0.1 the assumption of homogeneity was deemed invalid [36], and a random-effects model was used after meticulous exploration of causes of heterogeneity. Otherwise, when the p value was > 0.1, a fixed-effects model was preferred. Two-tailed $p < 0.05$ was considered statistically significant. The entire study selection process (including literature search, selection and enrollment) was performed by one of the authors (FQW).

Results

We yielded 276 articles after the initial literature search, from which 17 potentially relevant clinical trials [5–9, 24–32, 37–39] were further selected for assessment

(Fig. 1). Three trials were excluded because the number of patients was <10 ($n = 1$) [37]; inclusion of other targeted therapies ($n = 1$) [38]; and inclusion of the same patient cohort from published data ($n = 1$) [39]. Ultimately, 14 trials [5–9, 24–32] (five randomized trials, nine single-arm trials) published between 2006 and 2017 were enrolled in the meta-analysis. Of the total 1,106 patients with advanced biliary cancer, 848 (76.7%) had cholangiocarcinoma and 237 (21.4%) had gallbladder carcinoma. A total of 767 patients received anti-EGFR treatment with or without chemotherapy. Detailed study characteristics are listed in Table 1.

A total of 714 patients who received anti-EGFR treatment from 13 trials were available for analysis of all-grade skin rash, with an incidence ranging from 55.6−94.3%. The heterogeneity of the 13 trials included was detected ($Q = 56.0$, $p < 0.001$). Potential causes for heterogeneity were explored by subgroup analysis of a different type of anti-EGFR treatment. We found that heterogeneity exists in erlotinib- or panitumumab-based trials, although it was not detected in cetuximab-based trials (Fig. 2) in which a relative fixed dose was used with similar chemotherapy regimens. The observed heterogeneity was possibly due to a dose difference and different chemotherapy combinations. Using the random-effects model, we found that all-grade skin rash occurred with an incidence of 78.2% (95% CI 70.4–84.3) in patients who received anti-EGFR treatment.

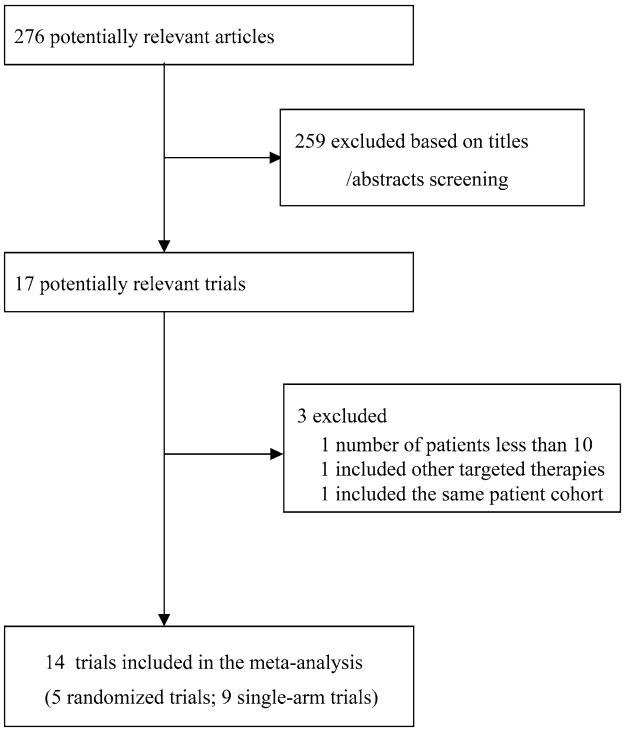

Fig. 1 Study selection for clinical trials included in the meta-analysis

A total of 705 patients who received anti-EGFR treatment from 13 trials were available for analysis of high-grade skin rash, with an incidence ranging from 2.2−37.1%. The heterogeneity of the 13 trials included was detected ($Q = 35.3$, $p < 0.001$). Heterogeneity existed in panitumumab-based studies, but was not detected in erlotinib- or cetuximab-based studies (Figure S1). The random-effects model showed that the incidence of high-grade rash was 11.3% (95% CI 7.6–16.5) in patients who received anti-EGFR treatment.

Five randomized trials were available for the meta-analysis of RR for skin rash in patients with advanced biliary cancer compared with controlled trials. As analyzed by the fixed-effects model, the RR was 7.37 (95% CI 5.11–10.64, $p < 0.0001$) for anti-EGFR therapies versus control medication for all-grade rash, and 6.94 (1.89–25.45, $p = 0.0035$) for high-grade rash (Fig. 3). In addition, we performed subgroup analysis to further understand the risk of anti-EGFR-induced skin rash. As demonstrated in Table S1, higher risks of rash were observed in patients treated with cetuximab (RR 17.17, 95% CI 7.82–37.46) and in those of Asian origin (RR 11.05, 95% CI 3.20–38.17). On the whole, anti-EGFR treatment was associated with an increased risk of rash in patients with advanced biliary cancer when compared with those treated without anti-EGFR therapies, and the risk of rash varied among different drugs and populations.

To better understand the prognostic effects of skin rash in anti-EGFR-treated patients with biliary cancer, a meta-analysis of RR for the ORR, and of HR for the OS and PFS in patients with higher grades of skin rash compared with those with lower grades or no rash, was performed for three randomized trials. Of note, one trial [32] used grade 0 as the control while and the other two [7, 28] used grade 0 or 1 as the control. However, homogeneity of these trials was still achieved (all $p > 0.1$). The fixed-effects model showed an RR of 3.50 (95% CI 1.47–8.33, $p = 0.0048$) for ORR (Fig. 4); the HR was 0.47 (95% CI 0.31–0.71, $p = 0.0003$) for OS and 0.51 (0.36–0.72, $p = 0.0001$) for PFS in patients receiving anti-EGFR treatment with higher grades versus lower grades of rash or no rash (Fig. 5). Collectively, higher grades of skin rash may correlate with a higher ORR and a longer OS and PFS in anti-EGFR-treated patients with biliary cancer in comparison with lower grades or no rash.

Discussion

The reason that anti-EGFR-induced skin rash is rarely studied in biliary cancer might be explained in part by the fact that the occurrence of this frequently fatal malignant disease is relatively low despite its increasing incidence [1, 2], and that fewer patients have been receiving this novel target therapy compared to those with other types of cancer [19–23]. Therefore, we performed this meta-analysis from 14 clinical

Table 1 Study characteristics

Trial	Trial type	Anti-EGFR treatment	Concurrent treatment	Number of patients	CC/GC	Median age, years
Borbath et al. [28]	Single-arm phase II	Cetuximab (400 mg/m^2 at week 1, 250 mg/m^2 at week 2), 2-week cycles	Gemcitabine	44	44/0	61.3[a]
Chen et al. [7]	Randomized phase II	Cetuximab (500 mg/m^2 on day 1), 2-week cycles	Gemcitabine and oxaliplatine	62	53/9	61
	Control arm	–	Gemcitabine and oxaliplatine	60	55/5	59
Gruenberger et al. [25]	Single-arm phase II	Cetuximab (500 mg/m^2 on day 1), 2-week cycles	Gemcitabine and oxaliplatine	30	27/3	68
Malka et al. [6]	Randomized phase II	Cetuximab (500 mg/m^2 on day 1 or 2), 2-week cycles	Gemcitabine and oxaliplatine	76	62/11	61
	Control arm	–	Gemcitabine and oxaliplatine	74	61/11	62
Ole et al. [31]	Single-arm phase II	Cetuximab (500 mg/m^2 on day 1), 2-week cycles	Gemcitabine, oxaliplatine, and capecitabine	53	40/13	64.9
Rubovszky et al. [32]	Single-arm phase II	Cetuximab (250 mg/m^2/week, loading dose: 400 mg/m^2), 3-week cycles	Gemcitabine and capecitabine	57	39/18	59.7[a]
Lee et al. [5]	Randomized phase III	Erlotinib (100 mg/day orally), 2-week cycles	Gemcitabine and oxaliplatine	135	96/35	59
	Control arm	–	Gemcitabine and oxaliplatine	133	84/47	61
Philip et al. [24]	Single-arm phase II	Erlotinib (150 mg/day orally), 4-week cycles	–	42	24/16	67
Ferraro et al. [30]	Single-arm phase II	Panitumumab (9 mg/kg on day 1), 3-week cycles	Gemcitabine and cisplatin	48	25/17	64
Hezel et al. [29]	Single-arm phase II	Panitumumab (6 mg/kg on days 1 and 15), 4-week cycles	Gemcitabine and oxaliplatine	31	28/3	61
Jensen et al. [27]	Single-arm phase II	Panitumumab (6 mg/kg on day 1), 2-week cycles	Gemcitabine, oxaliplatine, and capecitabine	46	38/0	66
Leone et al. [8]	Randomized phase II	Panitumumab (6 mg/kg on day 1), 2-week cycles	Gemcitabine and oxaliplatine	45	42/12	63.9
	Control arm	–	Gemcitabine and oxaliplatine	44	28/16	64.2
Sohal et al. [26]	Single-arm phase II	Panitumumab (9 mg/kg on day 1), 3-week cycles	Gemcitabine and irinotecan	35	29/6	62
Vogel et al. [9]	Randomized phase II	Panitumumab (9 mg/m^2 on days 1 and 8), 3-week cycles	Gemcitabine and cisplatin	63	51/12	62
	Control arm	–	Gemcitabine and cisplatin	28	25/3	59.5

CC cholangiocarcinoma, *GC* gallbladder carcinoma

[a]Ages are presented as means

trials to render greater statistical power to the pooled data. Our study demonstrates a high overall incidence of all-grade rash [78.2% (95% CI 70.4–84.3)] with anti-EGFR treatment for advanced biliary cancer and an overall incidence of high-grade rash of 11.3% (95% CI 7.6–16.5), which is comparable with studies that reported all-grade and high-grade incidents ranging from 59−80% and 5−12%, respectively, in cetuximab-, erlotinib- or panitumumab-treated patients for other cancers [14, 18, 40, 41]. An overall risk of all-grade (RR 7.37, 95% CI 5.11–10.64; $p < 0.0001$) and high-grade (RR 6.94, 95% CI 1.89–25.45; $p = 0.0035$) rash related to anti-EGFR treatment in patients with advanced biliary cancer was also noted. This finding will provide clinicians and patients with more insight into, and a better understanding of, the occurrence and risk regarding anti-EGFR treatment for biliary cancer. Early detection and appropriate management of rash are essential to reduce morbidity, improve patient quality of life and avoid dose reductions or discontinuation of anti-EGFR treatment due to side-effects, which may disrupt the maintenance of an effective dose strategy for anti-tumor efficacy.

The mechanisms underlying the association between anti-EGFR treatment and skin rash might be explained by the direct inhibitory effect on the EGFR receptor. Of note,

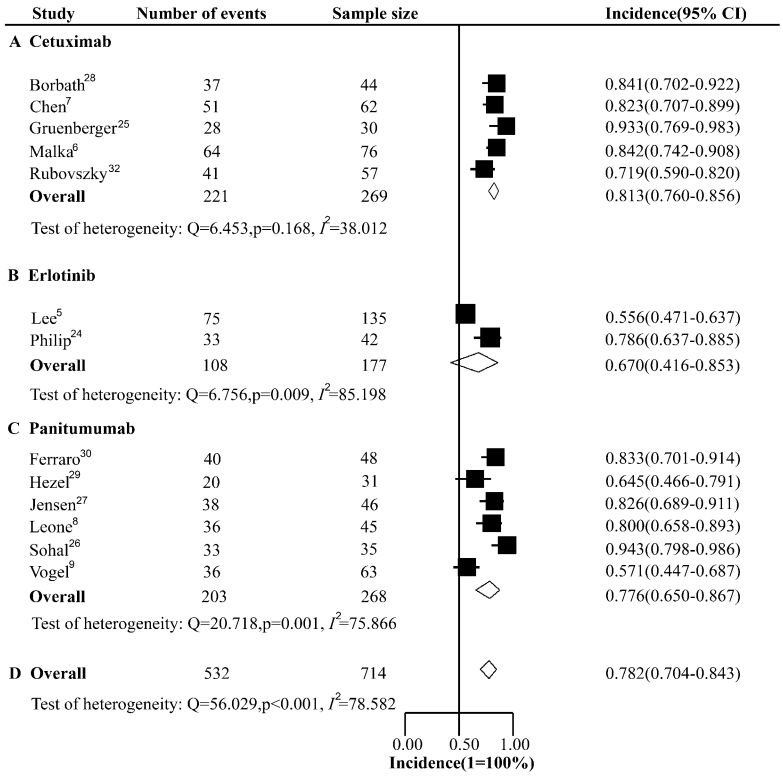

Fig. 2 Forest plot for meta-analysis of incidence of all-grade skin rash in patients with advanced biliary cancers who were treated with anti-EGFR therapies. The fixed-effects model was used for patients treated with cetuximab (**a**). The random-effects model was used for patients treated with erlotinib (**b**), panitumumab (**c**) or overall anti-EGFR therapies (**d**)

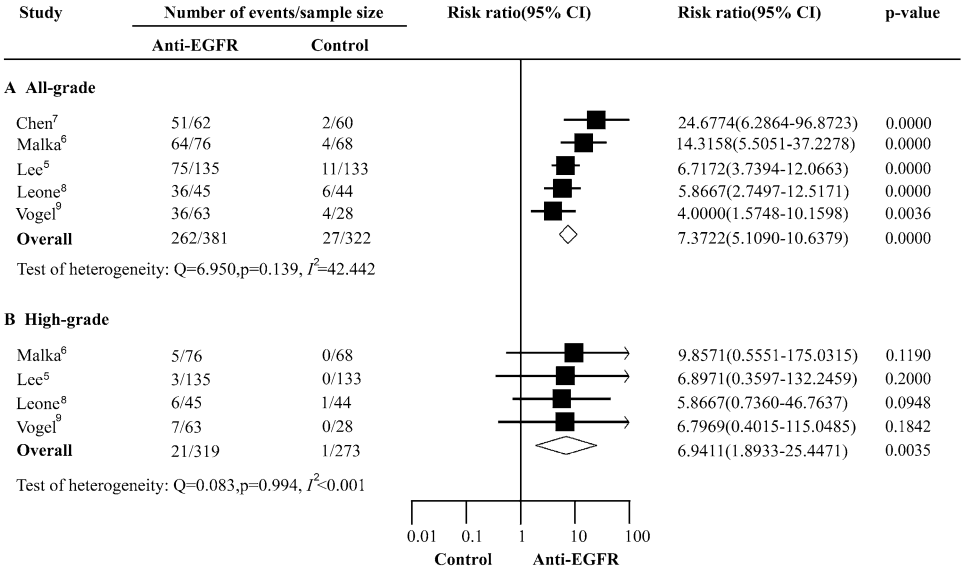

Fig. 3 Risk ratio of skin rash in patients with advanced biliary cancers treated with anti-EGFR therapies for all-grade (**a**) and high-grade (**b**) skin rash calculated using the fixed-effects model

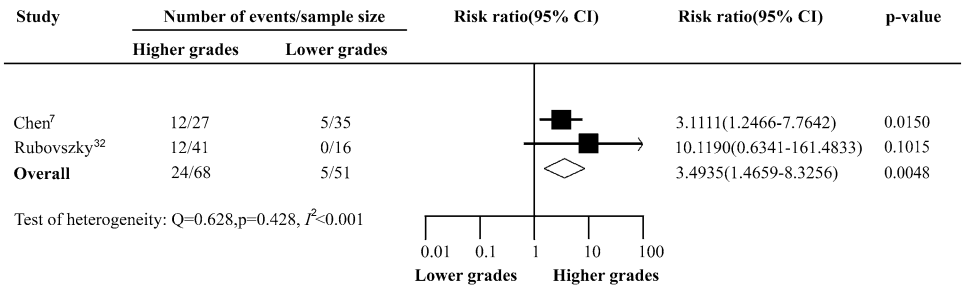

Fig. 4 Risk ratio for the objective response rate in patients receiving anti-EGFR therapies with higher grades versus lower grades skin rash calculated using the fixed-effects model

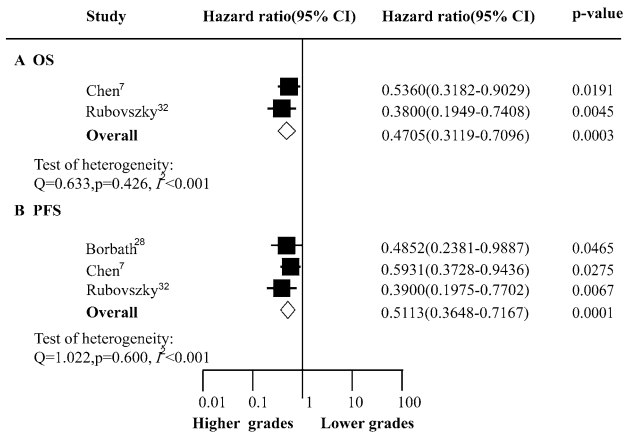

Fig. 5 Hazard ratio for the overall survival (OS, **a**) and progression-free survival (PFS, **b**) in patients receiving anti-EGFR therapies with higher grades versus lower grades of skin rash calculated using the fixed-effects model

EGFR is expressed in proliferating and undifferentiated keratinocytes in the basal epidermal layers and outer layers of hair follicles. Upon inhibition, activated EGFR is abolished in epidermal cells, when an effective dose of drug is believed to reach the skin [42]. This results in growth arrest and premature differentiation of the basal keratinocytes followed by apoptosis and damage as a result of enhanced skin inflammation [43], with interleukin-1 highly expressed in the epidermis and considered a candidate cytokine related to rash development [44]. This induced rash, also termed folliculitis, acneiform rash or acne-like rash, is actually a dermatologic reaction to EGRF inhibition initially occurring as inflammatory papulopustular eruptions on the face and upper trunk as early as 7–10 days after treatment [45], which can extend throughout the body in some patients. The rash peaks at 2–4 weeks and thereafter slowly abates with continuation of anti-EGFR treatment [46].

It is noteworthy that risk factors for skin rash related to anti-EGFR treatment remain equivocal. Patients with a better performance status [47, 48], male gender [49], younger age [48, 49], and less exposure to smoking [47, 49] are considered more likely to develop rash or severe rash. However, a younger age was proposed in another study to negatively correlate with severe rash [50]. In the present analysis, we demonstrated that patients with biliary cancer treated with cetuximab had the highest RR of 17.17 (95% CI 7.82–37.46) of developing skin rash. Interestingly, the highest incidence (81.3%, 95% CI 76.0–85.6) of rash is also noted in cetuximab-treated patients. These findings are supported by the fact that risks might vary according to different EGFR inhibitor types [23]. In addition, we showed that the Asian population had a relatively higher RR (11.05, 95% CI 3.20–38.17) than the European population (RR 6.71, 95% CI 4.07–11.07), which might indicate a better response to EGFR inhibitors in Asian patients with biliary cancer. However, in another study [23] of multiple cancers (mostly lung cancer), the Asian population had an RR (5.85, 95% CI 3.52–9.73) lower than that in non-Asians (RR 8.72, 6.19–12.31), albeit insignificant ($p > 0.05$). A possible explanation for this difference could be that various EGFR inhibitors were applied for different types of tumor in these studies.

Although the incidence and risk of skin rash are high during anti-EGFR treatment, therapies for rash still remain elusive. Guidelines based on evidence are still lacking, with most currently favouring supportive treatment of topical and systemic medications, including moisturizers, corticosteroids and antibiotics. Basic principles including taking drugs on an empty stomach, avoiding alcohol-containing agents and avoiding sun exposure apply to all patients [51]. Vitamin K3 (menadione) was considered an effective therapy based on mechanisms to circumvent EGFR inhibition by increasing re-phosphorylation of the EGFR [43]. However, a recent phase II trial did not show any benefit of vitamin K3 cream for cetuximab-induced rash, and no immunohistochemical findings of restoration of phosphorylated EGFR were found [52]. A recent systematic study focusing on colorectal cancer and lung cancer showed that patients treated with prophylactic antibiotics including tetracycline, minocycline and doxycycline had a lower risk of anti-EGFR-induced rash development (odds ratio 0.53, 95% CI 0.39–0.72, $p < 0.1$) compared with those without antibiotic prophylaxis [22]. The incidence was reduced by 10 and 26% for all-grade and high-grade rash, respectively, in patients treated with prophylactic antibiotics [22]. The effectiveness of these antibiotics might be attributed to their anti-inflammatory effects [53], although microbial pathogens are not usually detected from rash eruptions. Data regarding the effect of prophylactic antibiotics for reducing skin rash are lacking in the biliary cancer setting. Therefore, future attempts are warranted in order to evaluate and develop a better management strategy for preventing and treating skin rash.

Intriguingly, a correlation between skin rash and therapeutic efficacy has been noted. In fact, prognostic factors underlying anti-EGFR treatment for cancer have long been investigated. *KRAS* mutation status was considered a strong predictive factor for efficacy and survival during anti-EGFR treatment. In a phase II trial for colorectal liver metastases, a higher ORR (70 vs 41%, odds ratio 3.42, $p = 0.0080$) was achieved in cetuximab-treated patients with *KRAS* wild-type tumors than in those with *KRAS* mutated tumors [54]. Another study of colorectal cancer showed a better PFS for anti-EGFR treatment over chemotherapy in patients with *KRAS* wild-type tumors (HR 0.68, $p = 0.02$) but not in patients with *KRAS* mutated tumors (HR 1.07, $p = 0.75$) [15]. Incidents of *KRAS* mutation ranged from 6.7–41% [5–7, 25–28, 32] in biliary cancer. The predictive

role of *KRAS* mutation status in biliary cancer patients after anti-EGFR treatment is not definitively known, but several available studies indicated no correlation between *KRAS* mutation status and efficacy or survival benefit during anti-EGFR treatment [6, 7, 26, 27]. Malka et al. [6] reported 65% (24 out of 37) of *KRAS* wild-type patients achieved no disease progression after anti-EGFR treatment for biliary cancer, which was comparable to the proportion (63%, 5/8) of the the *KRAS* mutated patients. Borbath et al. [28] demonstrated that *KRAS* wild-type patients had median PFS (6.7 vs 7.1 months, $p = 0.616$) and OS (14.8 vs 18.8 months, $p = 0.611$) comparable to those *KRAS* mutated subjects during anti-EGFR treatment for cholangiocarcinomas. Of note, our study showed that higher grades of rash might indicate better ORR (RR 3.50, $p = 0.0048$), longer OS (HR 0.47, $p = 0.0003$) and longer PFS (HR 0.51, $p = 0.0001$) than lower grades or absence of rash during anti-EGFR treatment for biliary cancer. These findings are of great interest, considering that the prognosis of biliary cancer is typically dismal and that reliable predictive biomarkers are lacking. Similar significant results were also reported in other cancers, with reported RR ranging from 1.50−2.30 for ORR and HR ranging from 0.30−0.60 and 0.50−0.74 for OS and PFS, respectively [19–21]. Whether there is any correlation between gene mutation status (such as *KRAS*) and grade of rash among biliary cancer after anti-EGFR treatment remains unclear due to a lack of original information from the trials investigating the correlation between gene mutation status and its implication on rash. More future studies are warranted to evaluate survival by stratifying patients according to the severity of rash in a larger cohort to further confirm that higher grades of rash correlate with better response and efficacy among biliary cancer patients, and also to explore potential mechanisms such as gene mutation status underlying this correlation.

This study has several limitations. First, this is a meta-analysis carried out at study level, meaning that different confounding factors from the patient level are unable to be assessed and incorporated into the analysis. Second, the incidents of all-grade and high-grade skin rash demonstrated significant heterogeneity among different studies. This might be explained in part by the fact that differences occur in treatment type, drug dose, concomitant chemotherapy, study population, and CTCAE versions for recording adverse events. Third, some studies did not report a correlation between rash and clinical benefit, which might lead to reduced power of our stratified analysis to reach a definitive conclusion. However, the current results were still significant and encouraging. Fourth, two studies [8, 31] recorded the side-effects as skin toxicity instead of rash, which might overestimate the incidence of anti-EGFR-induced rash, although rash is a classical and indispensable stage of anti-EGFR-induced toxic effects on the skin [43]. Finally, the relatively low incidence of biliary cancer and corresponding small sample sizes involved in the current analysis might limit our findings, although pooled data were already endowed with much more statistical power than individual trials.

Conclusion

A high overall incidence of skin rash was noted in patients during anti-EGFR treatment for advanced biliary cancer. Anti-EGFR treatment correlates with an increased risk of rash in advanced biliary cancer. Patients treated with cetuximab and those from an Asian population are more likely to bear a higher risk. Anti-EGFR-induced rash may also indicate a better therapeutic response and survival. Early detection and proper treatment of rash can not only improve a patient's quality of life but also maintain their compliance with therapy. Future studies are encouraged to identify better treatment strategies and stratify patients by the severity of skin rash during anti-EGFR treatment for biliary cancer.

Acknowledgements This study was supported by the China Scholarship Council (CSC no. 201606320156 to FQ Wei). We are very thankful to Hugh McGonigle, from Edanz Group (http://www.edanzediting.com/ac) for his language support.

Author contributions XJC and FQW contributed to the study concept and design; FQW contributed to the acquisition, analysis and interpretation of data; FQW wrote the manuscript; DHS helped to revise the manuscript.

Compliance with ethical standards

Conflict of interest The authors have no conflict of interest to disclose.

References

1. de Groen PC, Gores GJ, LaRusso NF et al (1999) Biliary tract cancers. N Engl J Med 341(18):1368–1378
2. Siegel RL, Miller KD, Jemal A (2017) Cancer statistics, 2017. CA Cancer J Clin 67(1):7–30
3. Horgan AM, Amir E, Walter T, Walter T et al (2012) Adjuvant therapy in the treatment of biliary tract cancer: a systematic review and meta-analysis. J Clin Oncol 30(16):1934–1940
4. Valle J, Wasan H, Palmer DH et al (2010) Cisplatin plus gemcitabine versus gemcitabine for biliary tract cancer. N Engl J Med 362(14):1273–1281
5. Lee J, Park SH, Chang HM et al (2012) Gemcitabine and oxaliplatin with or without erlotinib in advanced biliary-tract cancer: a multicentre, open-label, randomised, phase 3 study. Lancet Oncol 13(2):181–188
6. Malka D, Cervera P, Foulon S et al (2014) Gemcitabine and oxaliplatin with or without cetuximab in advanced biliary-tract cancer (BINGO): a randomised, open-label, non-comparative phase 2 trial. Lancet Oncol 15(8):819–828

7. Chen JS, Hsu C, Chiang NJ et al (2015) A KRAS mutation status-stratified randomized phase II trial of gemcitabine and oxaliplatin alone or in combination with cetuximab in advanced biliary tract cancer. Ann Oncol 26(5):943–949
8. Leone F, Marino D, Cereda S et al (2016) Panitumumab in combination with gemcitabine and oxaliplatin does not prolong survival in wild-type KRAS advanced biliary tract cancer: a randomized phase 2 trial (Vecti-BIL study). Cancer 122(4):574–581
9. Vogel A, Kasper S, Weichert W et al (2016) Panitumumab in combination with gemcitabine/cisplatin (GemCis) for patients with advanced KRAS WT biliary tract cancer: a randomized phase II trial of the Arbeitsgemeinschaft Internistische Onkologie (AIO). J Clin Oncol 33:4082
10. Yarden Y, Sliwkowski MX (2001) Untangling the ErbB signalling network. Nat Rev Mol Cell Biol 2(2):127–137
11. Pellat A, Vaquero J, Fouassier LAO (2017) Role of ErbB/HER family of receptor tyrosine kinases in cholangiocyte biology. Hepatology. https://doi.org/10.1002/hep.29350 **(epub ahead of print)**
12. Yarden Y, Shilo BZ (2007) SnapShot: EGFR signaling pathway. Cell 131(5):1018
13. Douillard JY, Oliner KS, Siena S et al (2013) Panitumumab-FOLFOX4 treatment and RAS mutations in colorectal cancer. N Engl J Med 369(11):1023–1034
14. Cunningham D, Humblet Y, Siena S et al (2004) Cetuximab monotherapy and cetuximab plus irinotecan in irinotecan-refractory metastatic colorectal cancer. N Engl J Med 351(4):337–345
15. Van Cutsem E, Kohne CH, Hitre E et al (2009) Cetuximab and chemotherapy as initial treatment for metastatic colorectal cancer. N Engl J Med 360(14):1408–1417
16. Mok TS, Wu YL, Ahn MJ et al (2017) Osimertinib or platinum-pemetrexed in EGFR T790M-positive lung cancer. N Engl J Med 376(7):629–640
17. Saloura V, Cohen EE, Licitra L et al (2014) An open-label single-arm, phase II trial of zalutumumab, a human monoclonal anti-EGFR antibody, in patients with platinum-refractory squamous cell carcinoma of the head and neck. Cancer Chemother Pharmacol 73(6):1227–1239
18. Soulieres D, Senzer NN, Vokes EE et al (2004) Multicenter phase II study of erlotinib, an oral epidermal growth factor receptor tyrosine kinase inhibitor, in patients with recurrent or metastatic squamous cell cancer of the head and neck. J Clin Oncol 22(1):77–85
19. Petrelli F, Borgonovo K, Cabiddu M et al (2012) Relationship between skin rash and outcome in non-small-cell lung cancer patients treated with anti-EGFR tyrosine kinase inhibitors: a literature-based meta-analysis of 24 trials. Lung Cancer 78(1):8–15
20. Petrelli F, Borgonovo K, Barni S (2013) The predictive role of skin rash with cetuximab and panitumumab in colorectal cancer patients: a systematic review and meta-analysis of published trials. Target Oncol 8(3):173–181
21. Abdel-Rahman O, Fouad M (2015) Correlation of cetuximab-induced skin rash and outcomes of solid tumor patients treated with cetuximab: a systematic review and meta-analysis. Crit Rev Oncol Hematol 93(2):127–135
22. Petrelli F, Borgonovo K, Cabiddu M et al (2016) Antibiotic prophylaxis for skin toxicity induced by antiepidermal growth factor receptor agents: a systematic review and meta-analysis. Br J Dermatol 175(6):1166–1174
23. Zhang X, Ran YG, Wang KJ (2016) Risk of severe rash in cancer patients treated with EGFR tyrosine kinase inhibitors: a systematic review and meta-analysis. Future Oncol 12(23):2741–2753
24. Philip PA, Mahoney MR, Allmer C et al (2006) Phase II study of erlotinib in patients with advanced biliary cancer. J Clin Oncol 24(19):3069–3074
25. Gruenberger B, Schueller J, Heubrandtner U et al (2010) Cetuximab, gemcitabine, and oxaliplatin in patients with unresectable advanced or metastatic biliary tract cancer: a phase 2 study. Lancet Oncol 1(12):1142–1148
26. Sohal DP, Mykulowycz K, Uehara T et al (2013) A phase II trial of gemcitabine, irinotecan and panitumumab in advanced cholangiocarcinoma. Ann Oncol 24(12):3061–3065
27. Jensen LH, Lindebjerg J, Ploen J et al (2012) Phase II marker-driven trial of panitumumab and chemotherapy in KRAS wild-type biliary tract cancer. Ann Oncol 23(9):2341–2346
28. Borbath I, Ceratti A, Verslype C et al (2013) Combination of gemcitabine and cetuximab in patients with advanced cholangiocarcinoma: a phase II study of the Belgian Group of Digestive Oncology. Ann Oncol 24(11):2824–2829
29. Hezel AF, Noel MS, Allen JN et al (2014) Phase II study of gemcitabine, oxaliplatin in combination with panitumumab in KRAS wild-type unresectable or metastatic biliary tract and gallbladder cancer. Br J Cancer 111(3):430–436
30. Ferraro D, Goldstein D, O'Connell RL et al (2016) TACTIC: a multicentre, open-label, single-arm phase II trial of panitumumab, cisplatin, and gemcitabine in biliary tract cancer. Cancer Chemother Pharmacol 78(2):361–367
31. Ole Larsen F, Taksony Solyom Hoegdall D et al (2016) Gemcitabine, capecitabine and oxaliplatin with or without cetuximab in advanced biliary tract carcinoma. Acta Oncol 55(3):382–385
32. Rubovszky GAO, Budai B, Ganofszky E et al (2017) Predictive value of early skin rash in cetuximab-based therapy of advanced biliary tract cancer. Pathol Oncol Res. https://doi.org/10.1007/s12253-017-0238-y **(epub ahead of print)**
33. Moher D, Liberati A, Tetzlaff J et al (2009) Preferred reporting items for systematic reviews and meta-analyses: the PRISMA statement. J Clin Epidemiol 62(10):1006–1012
34. Higgins JPT, Green S (2011) Cochrane handbook for systematic reviews of interventions (version 5.1.0). http://handbook-5-1.cochrane.org/. Accessed 20 Aug 2017
35. Tierney JF, Stewart LA, Ghersi D et al (2007) Practical methods for incorporating summary time-to-event data into meta-analysis. Trials 8:16
36. Lau J, Ioannidis JP, Schmid CH et al (1997) Quantitative synthesis in systematic reviews. Ann Intern Med 127(9):820–826
37. Paule B, Herelle MO, Rage E et al (2007) Cetuximab plus gemcitabine–oxaliplatin (GEMOX) in patients with refractory advanced intrahepatic cholangiocarcinomas. Oncology 72(1–2):105–110
38. Lubner SJ, Mahoney MR, Kolesar JL et al (2010) Report of a multicenter phase II trial testing a combination of biweekly bevacizumab and daily erlotinib in patients with unresectable biliary cancer: a phase II Consortium study. J Clin Oncol 28(21):3491–3497
39. Rubovszky G, Lang I, Ganofszky E et al (2013) Cetuximab, gemcitabine and capecitabine in patients with inoperable biliary tract cancer: a phase 2 study. Eur J Cancer 49(18):3806–3812
40. Crawford J, Swanson P, Schwarzenberger P et al (2013) A phase 2 randomized trial of paclitaxel and carboplatin with or without panitumumab for first-line treatment of advanced non-small-cell lung cancer. J Thorac Oncol 8(12):1510–1518
41. Waddell T, Chau I, Cunningham D et al (2013) Epirubicin, oxaliplatin, and capecitabine with or without panitumumab for patients with previously untreated advanced oesophagogastric cancer (REAL3): a randomised, open-label phase 3 trial. Lancet Oncol 14(6):481–489
42. Albanell J, Rojo F, Averbuch S et al (2002) Pharmacodynamic studies of the epidermal growth factor receptor inhibitor ZD1839 in skin from cancer patients: histopathologic and molecular consequences of receptor inhibition. J Clin Oncol 20(1):110–124
43. Lacouture ME (2006) Mechanisms of cutaneous toxicities to EGFR inhibitors. Nat Rev Cancer 6(10):803–812

44. Chen CJ, Kono H, Golenbock D et al (2007) Identification of a key pathway required for the sterile inflammatory response triggered by dying cells. Nat Med 13(7):851–856
45. Robert C, Soria JC, Spatz A et al (2005) Cutaneous side-effects of kinase inhibitors and blocking antibodies. Lancet Oncol 6(7):491–500
46. Scope A, Agero AL, Dusza SW et al (2007) Randomized double-blind trial of prophylactic oral minocycline and topical tazarotene for cetuximab-associated acne-like eruption. J Clin Oncol 25(34):5390–5396
47. Wacker B, Nagrani T, Weinberg J et al (2007) Correlation between development of rash and efficacy in patients treated with the epidermal growth factor receptor tyrosine kinase inhibitor erlotinib in two large phase III studies. Clin Cancer Res 13(13):3913–3921
48. Moore MJ, Goldstein D, Hamm J et al (2007) Erlotinib plus gemcitabine compared with gemcitabine alone in patients with advanced pancreatic cancer: a phase III trial of the National Cancer Institute of Canada Clinical Trials Group. J Clin Oncol 25(15):1960–1966
49. Bar-Ad V, Zhang QE, Harari PM et al (2016) Correlation between the severity of cetuximab-induced skin rash and clinical outcome for head and neck cancer patients: The RTOG Experience. Int J Radiat Oncol Biol Phys 95(5):1346–1354
50. Wheatley-Price P, Ding K, Seymour L et al (2008) Erlotinib for advanced non-small-cell lung cancer in the elderly: an analysis of the National Cancer Institute of Canada Clinical Trials Group Study BR. 21. J Clin Oncol 26(14):2350–2357
51. Melosky B (2012) Supportive care treatments for toxicities of anti-egfr and other targeted agents. Curr Oncol 19(Suppl 1):S59–S63
52. Eriksen JG, Kaalund I, Clemmensen O et al (2017) Placebo-controlled phase II study of vitamin K3 cream for the treatment of cetuximab-induced rash. Support Care Cancer 25(7):2179–2185
53. Webster G, Del Rosso JQ (2007) Anti-inflammatory activity of tetracyclines. Dermatol Clin 25(2):133–135
54. Folprecht G, Gruenberger T, Bechstein WO et al (2010) Tumour response and secondary resectability of colorectal liver metastases following neoadjuvant chemotherapy with cetuximab: the CELIM randomised phase 2 trial. Lancet Oncol 11(1):38–47