Disease: Cholecystitis

Caption: A close-up view of an inflamed gallbladder. (Custom Medical Stock Photo. Reproduced by permission.)

Disease: Deep vein thrombosis

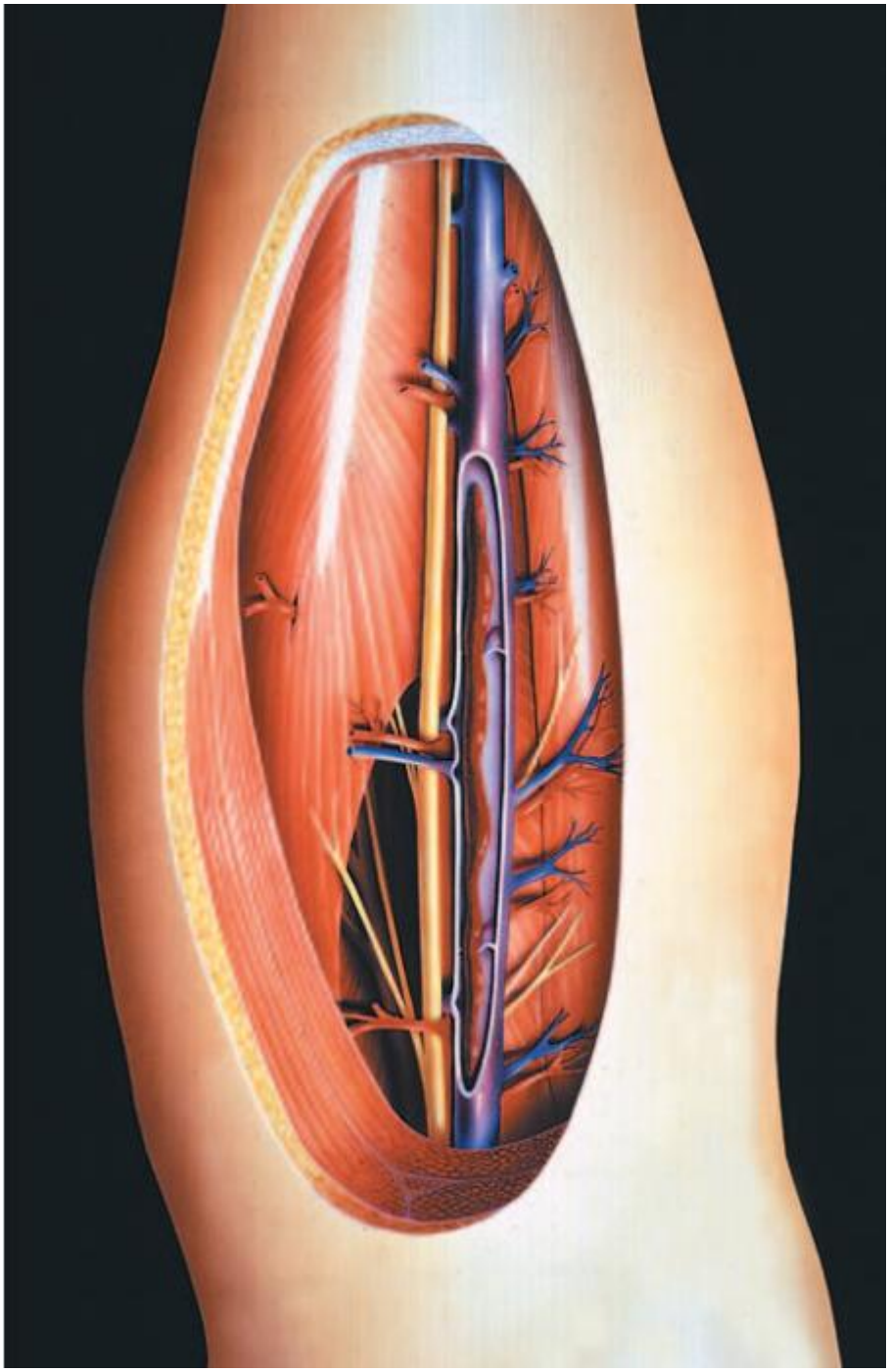

Caption: This illustration features a dissected human lower leg showing clot formation (thrombosis) along the length of a vein. (Custom Medical Stock Photo. Reproduced by permission.)

Disease: Alopecia

Caption: Top of balding male's head. (Photograph by Kelly A. Quin. Reproduced by permission.)

Disease: Alzheimer's disease

Caption: A brain segment affected by Alzheimer's disease on the right compared with a healthy brain segment (left). The diseased brain appears shrunken, and the fissures are noticeably larger. (Simon Fraser/MRC Unit, Newcastle General Hospital/ Science Photo Library. Photo Researchers, Inc. Reproduced by permission.)

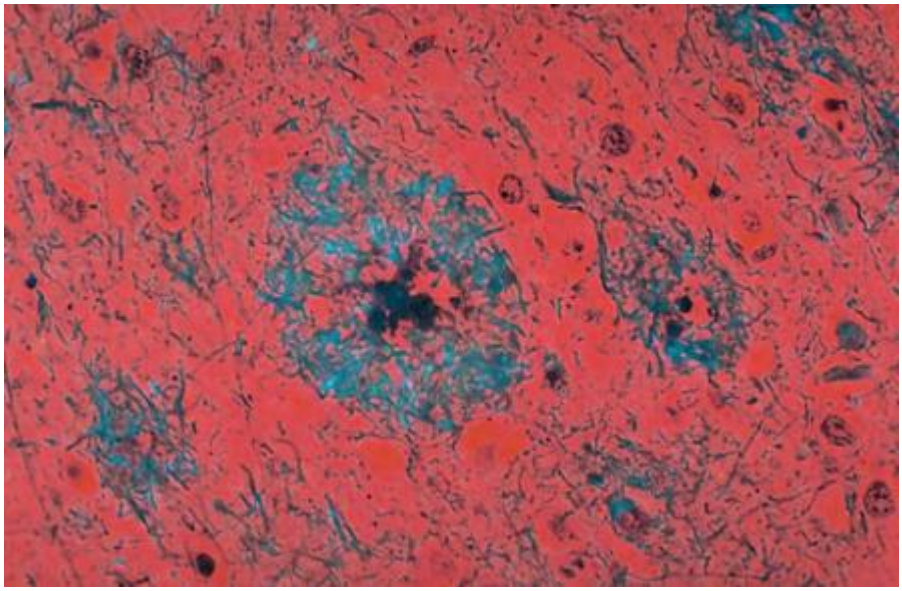

Caption: Diseased tissue from the brain of an Alzheimer's patient showing senile plaques within the brain's gray matter. (Photograph by Cecil Fox, Photo Researchers, Inc. Reproduced by permission.)

Disease: Amyotrophic lateral sclerosis

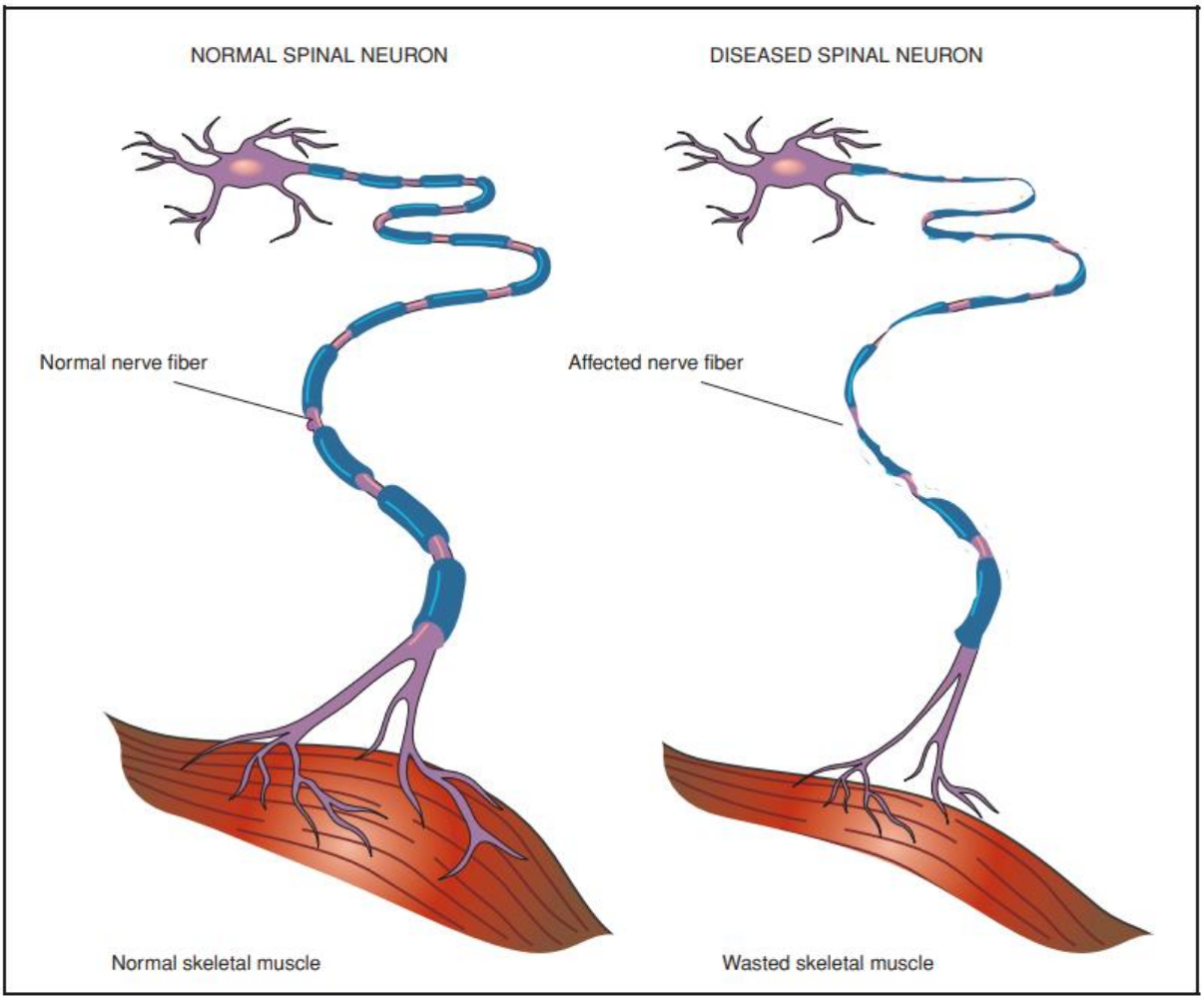

Caption: Amyotrophic lateral sclerosis (ALS) is caused by the degeneration and death of motor neurons in the spinal cord and brain. These neurons convey electrical messages from the brain to the muscles to stimulate movement in the arms, legs, trunk, neck, and head. As motor neurons degenerate, the muscles are weakened and cannot move as effectively, leading to muscle wasting. (Illustration by Electronic Illustrators Group.)

Disease: Aphasia

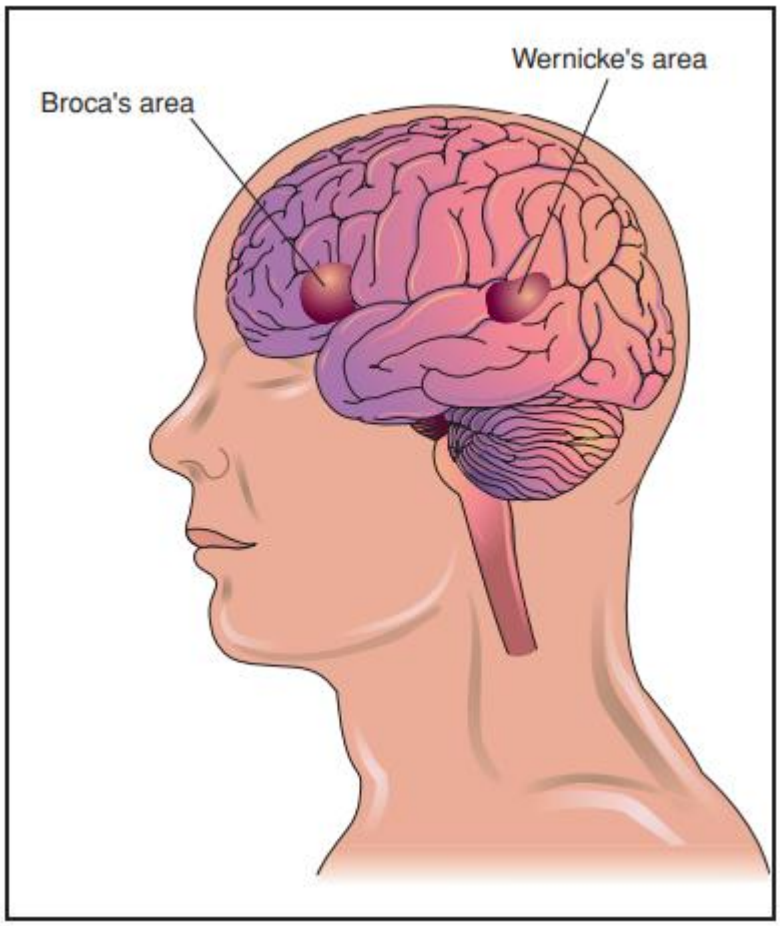

Caption: Broca's aphasia results from damage to the frontal lobe of the language-dominant area of the brain. Individuals with Broca's aphasia may become mute or may be able to use single-word statements or full sentences, although it may require great effort. Wernicke's aphasia is caused by damage to the temporal lobe of the language-dominant area of the brain. People with this condition speak in long, uninterrupted sentences, but the words used are often unnecessary and unintelligible. (Illustration by Electronic Illustrators Group.)

Disease: Aspergillosis

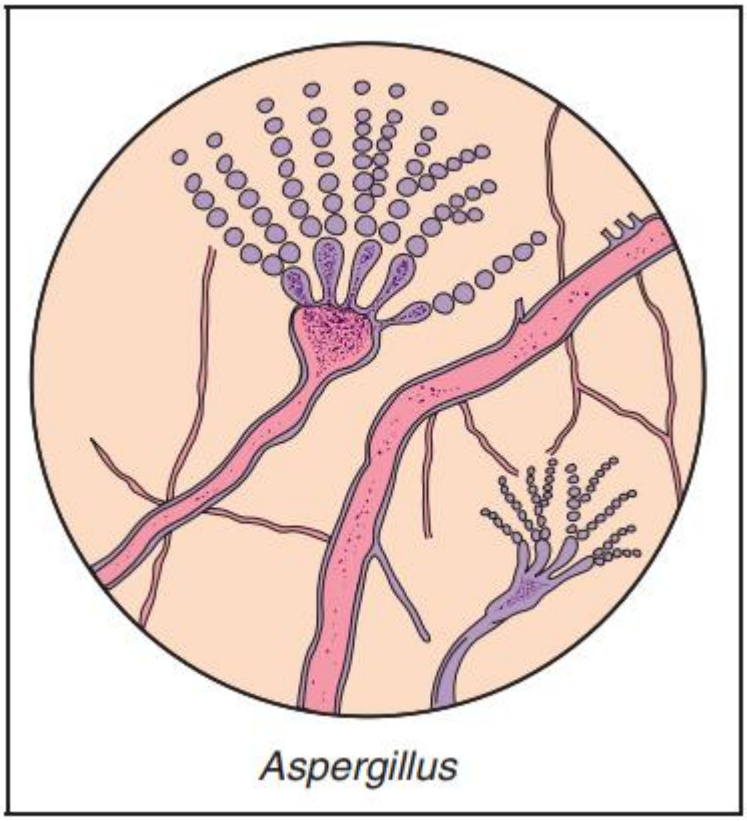

Caption: Aspergillosis is an infection of the lungs caused by inhalation of airborne spores of the fungus Aspergillus. (Illustration by Electronic Illustrators Group).

Disease: Asthma

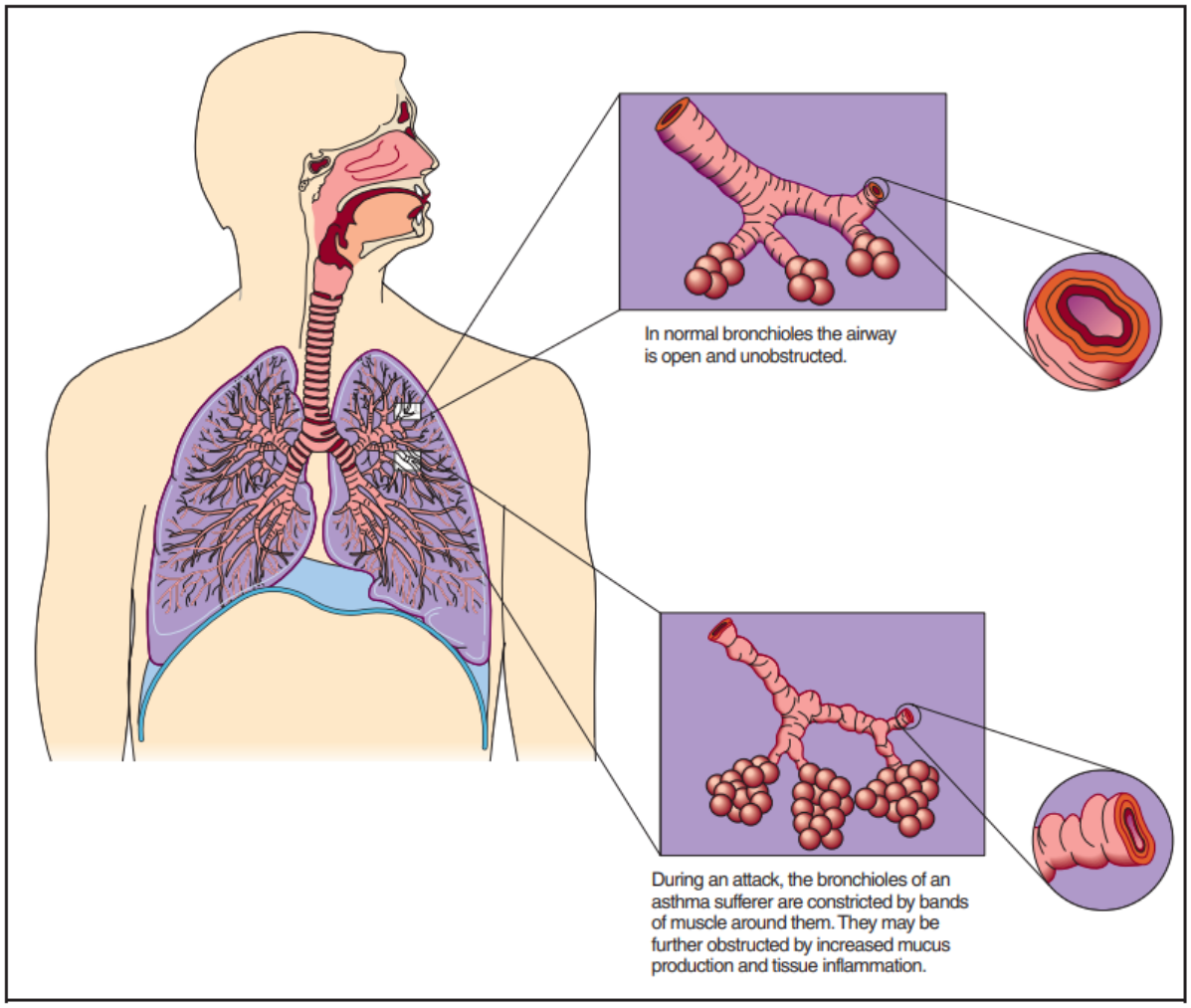

Caption: A comparison of normal bronchioles and those of an asthma sufferer. (Illustration by Hans & Cassady.)

Disease: AIDS

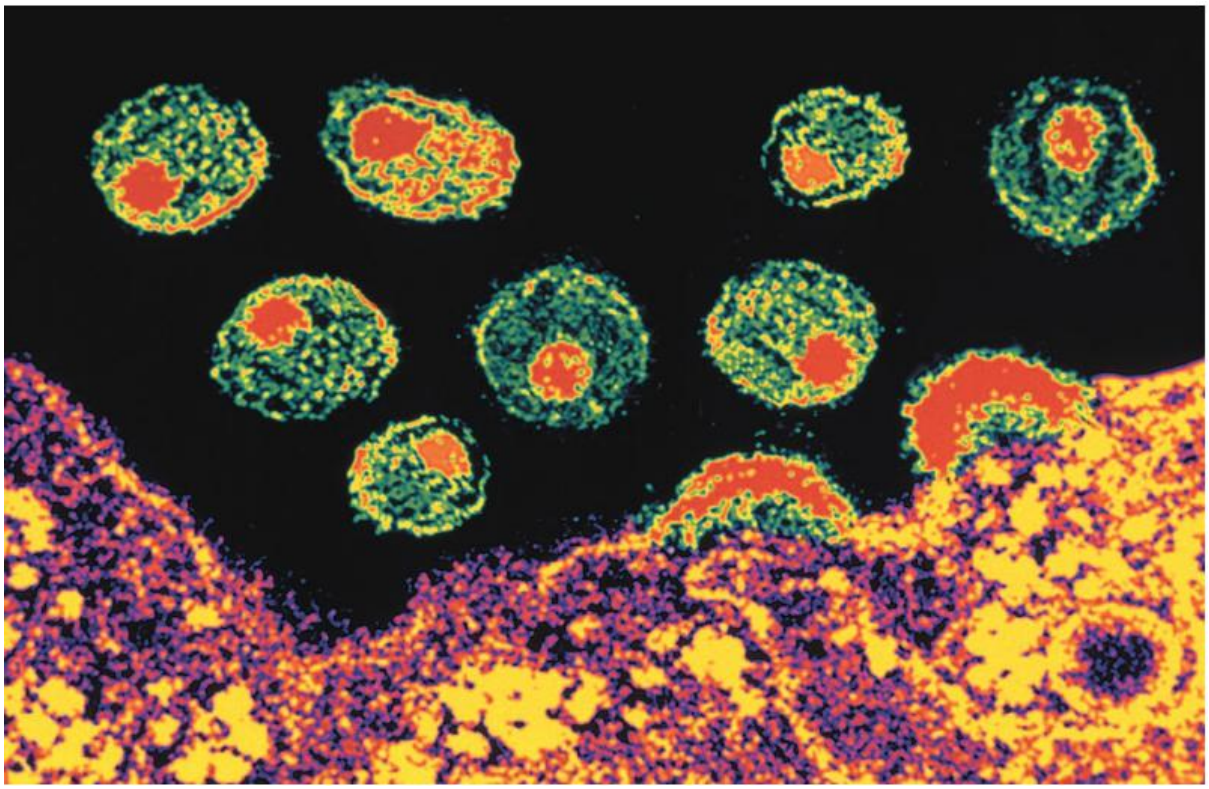

Caption: Mature HIV-1 viruses (above) and the lymphocyte from which they emerged (below). Two immature viruses can be seen budding on the surface of the lymphocyte (right of center). (Photograph by Scott Camazir, Photo Researchers, Inc. Reproduced by permission.)

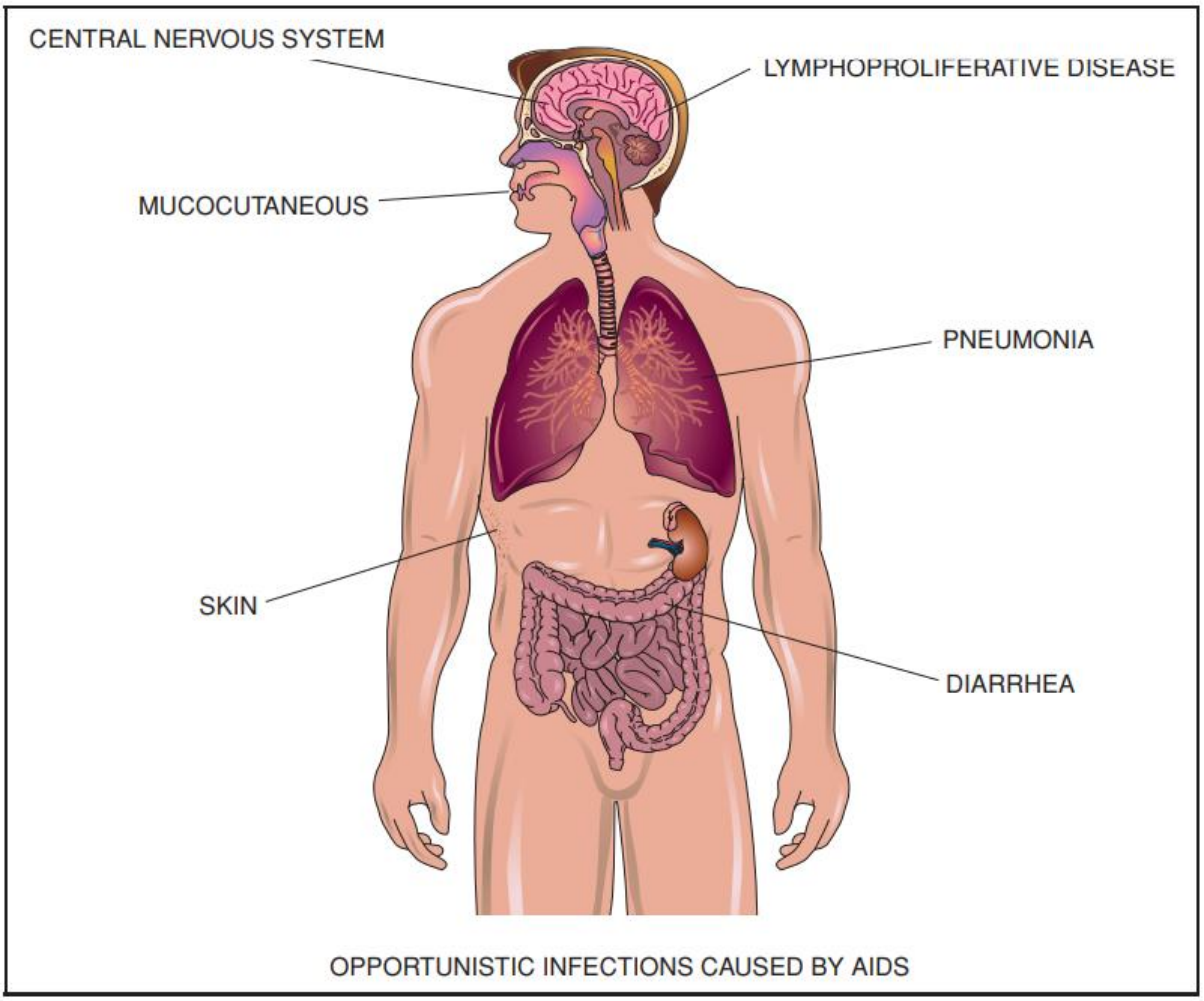

Caption: Because the immune system cells are destroyed by the AIDS virus, many different types of infections and cancers can develop, taking advantage of a person's weakened immune system. (Illustration by Electronic Illustrators Group.)

Disease: Atherosclerosis

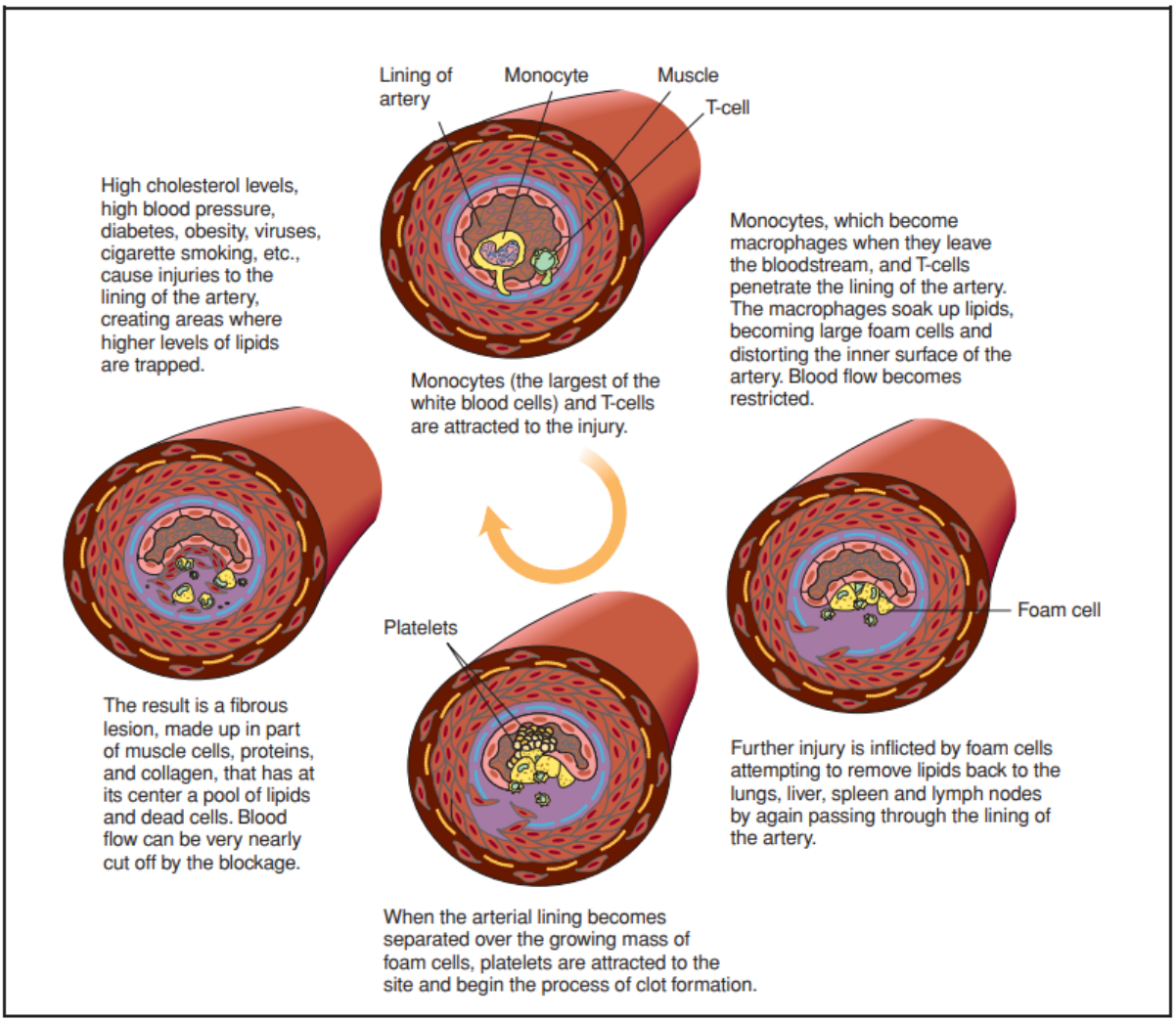

Caption: The progression of atherosclerosis. (Illustration by Hans & Cassady.)

Disease: Autism

Caption: This autistic child is encouraged to interact with the guinea pig in an effort to improve his social interaction. (Helen B. Senisi. Photo Researchers, Inc. Reproduced by permission.)

Disease: Animal bite infections

Caption: This snake breeder shows the scar from his surgery after he was bitten by a venomous West African Gabon viper. His arm was cut open in order to relieve swelling from the snake bite in his middle finger. (Photograph by Joe Crocetta, AP/Wide World Photo. Reproduced by permission.)

Disease: Bone marrow transplantation

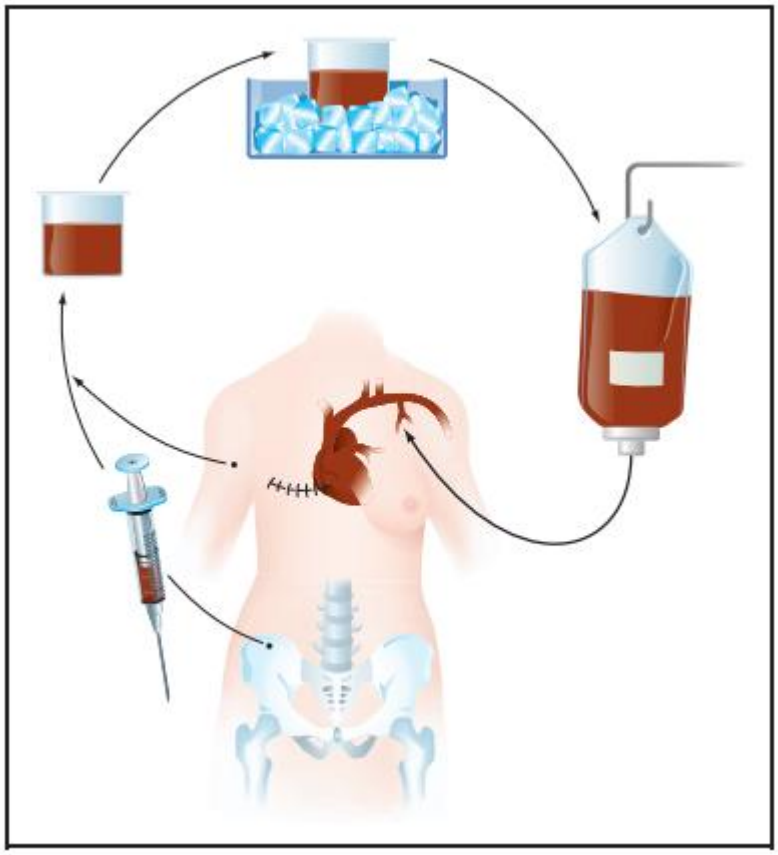

Caption: In autologous bone marrow transplantation, stem cells are collected from the patient. Once the patient has undergone chemotherapy, the cells are replaced in the blood via an intravenous catheter. The cells return to the bone marrow and begin producing healthy new cells. (Illustration by Argosy Inc.)

Disease: Gallstones

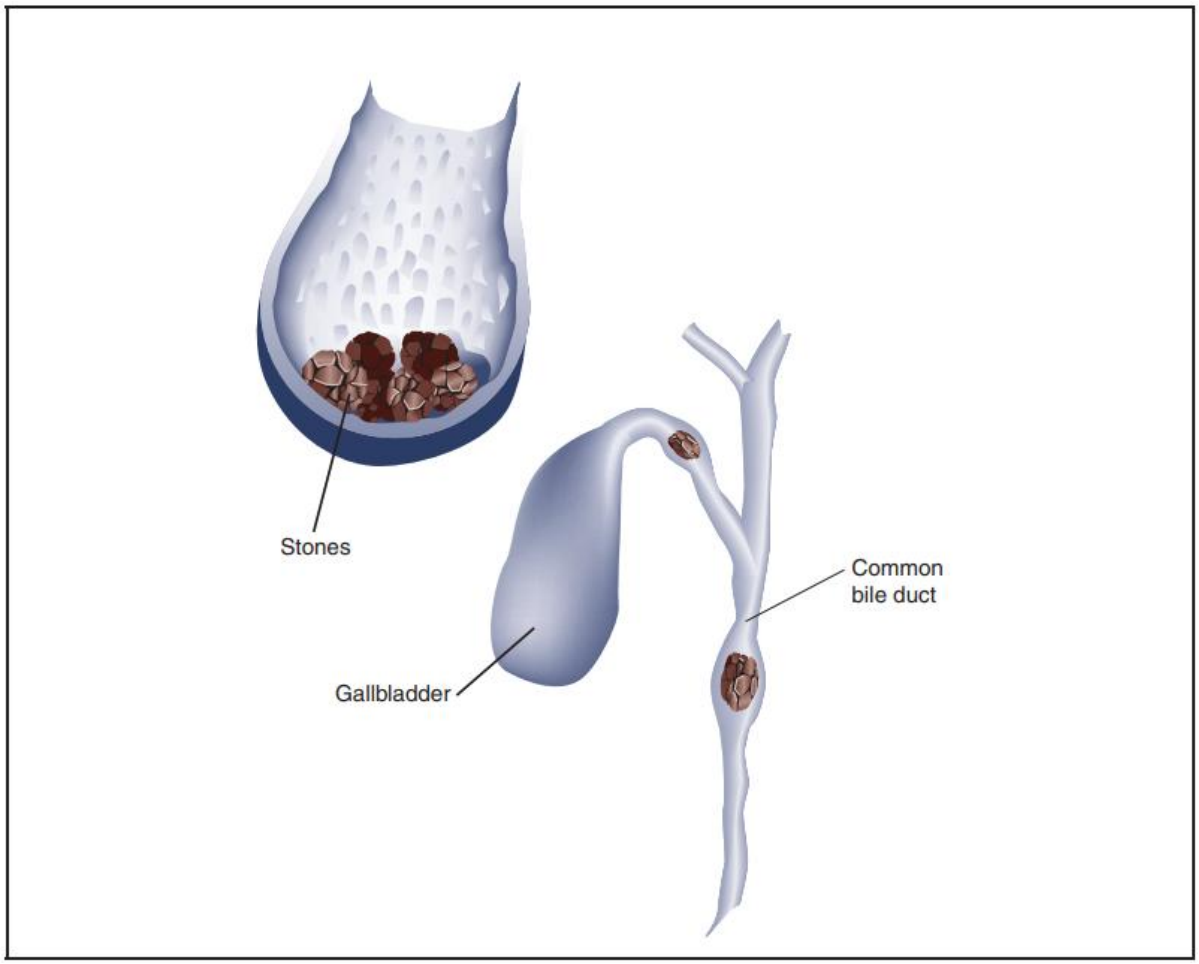

Caption: Gallstones form in the gallbladder but can migrate to other parts of the body via the bile duct. (Illustration by Argosy Inc.)

Disease: Kidney stones

Caption: X ray of kidney stone. (Custom Medical Stock Photo. Reproduced by permission.)

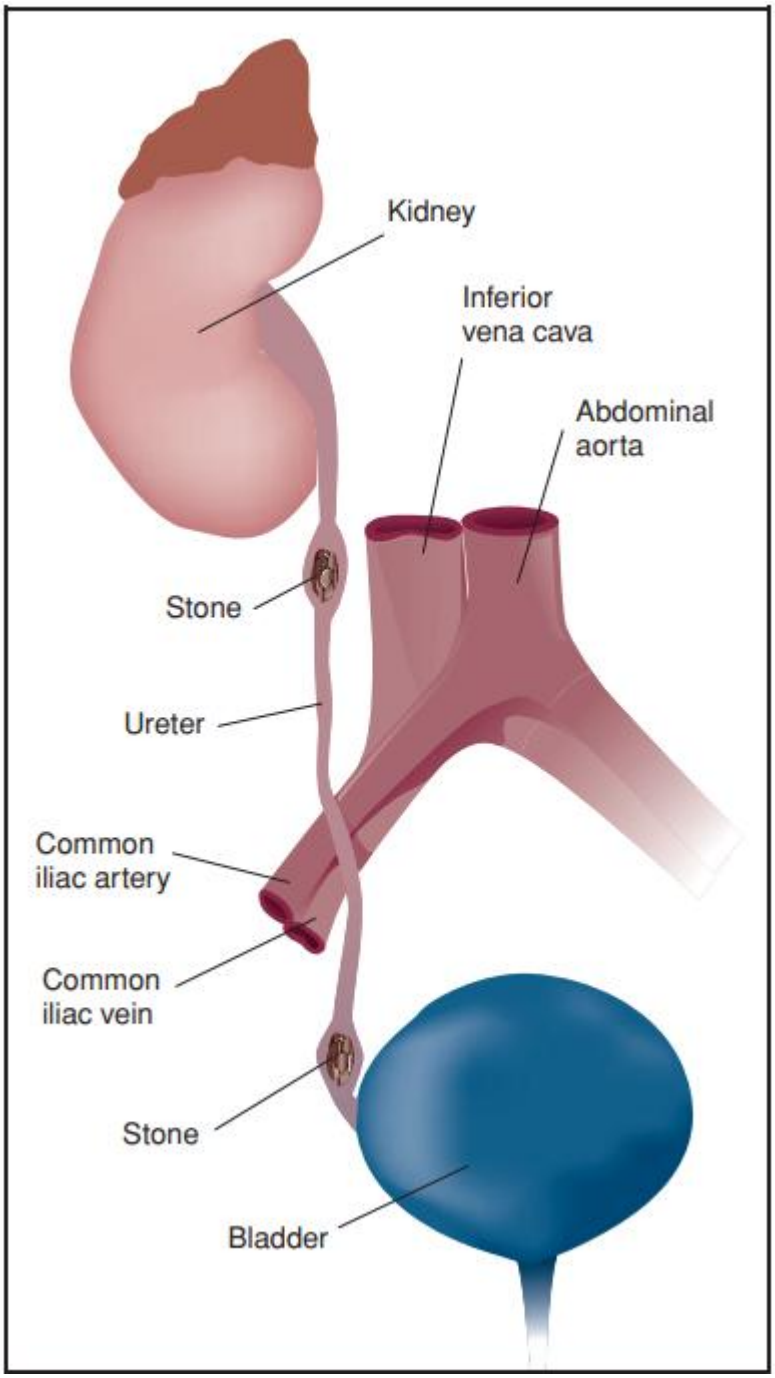

Caption: Kidney stones can occur in the ureter near the bladder or kidney. (Illustration by Argosy Inc.)

Disease: Cardiac catheterization

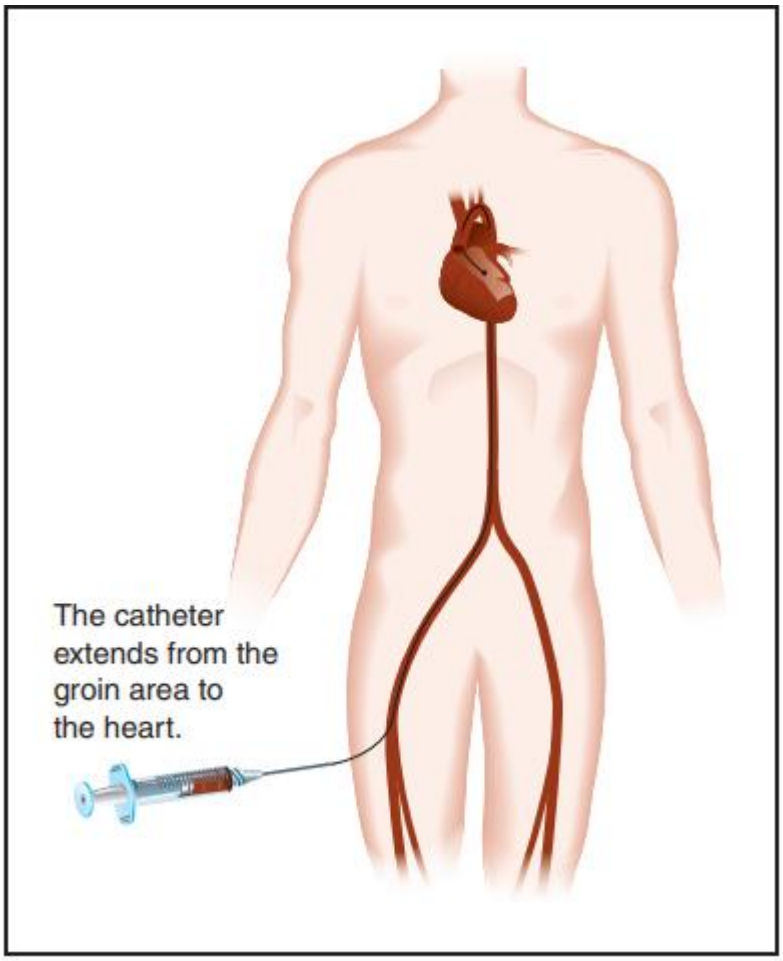

Caption: (Illustration by Argosy Inc.)

Disease: Cellulitis

Caption: This person's lower leg is swollen and inflamed due to cellulitis. Cellulitis is a Streptococcus bacterial infection of the skin and the tissues beneath it. The face, neck, or legs are common sites of cellulitis. (Custom Medical Stock Photo. Reproduced by permission.)

Disease: Cerebral aneurysm

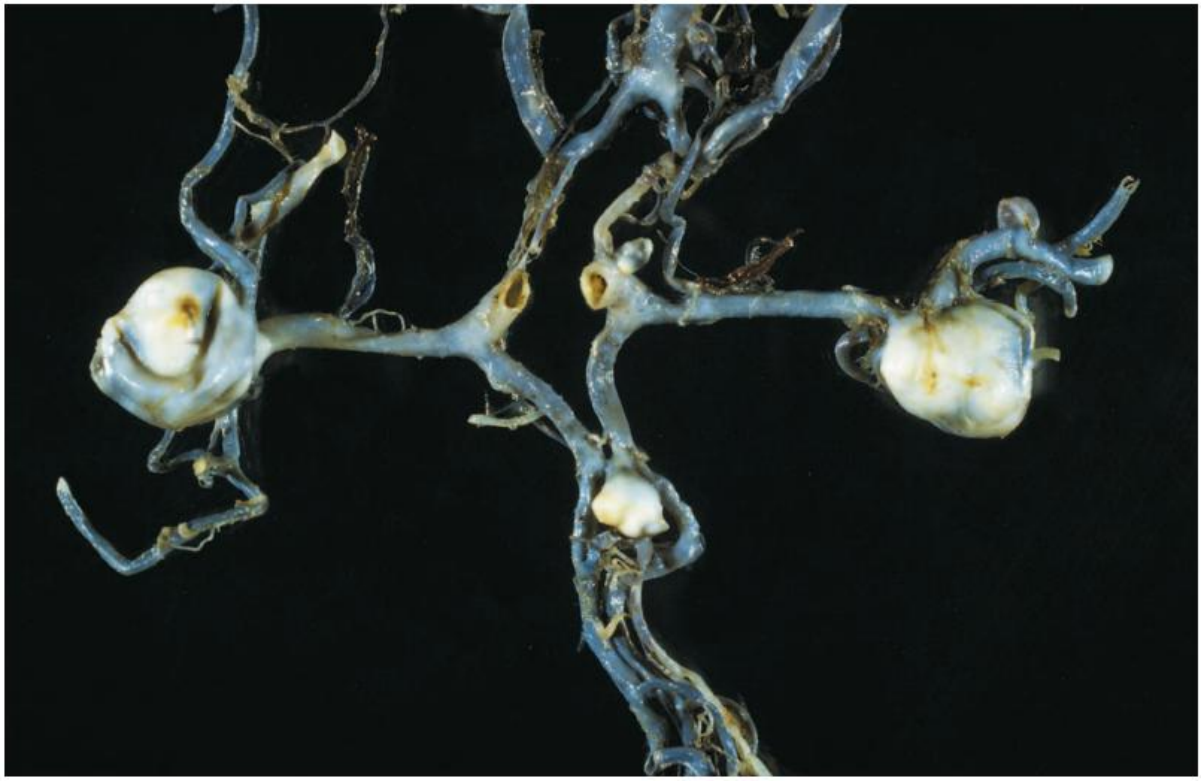

Caption: Three aneurysms can be seen in this section of a cerebral artery removed from a human brain. (Photograph by Martin Rotker, Phototake NYC. Reproduced by permission.)

Disease: Hepatitis B

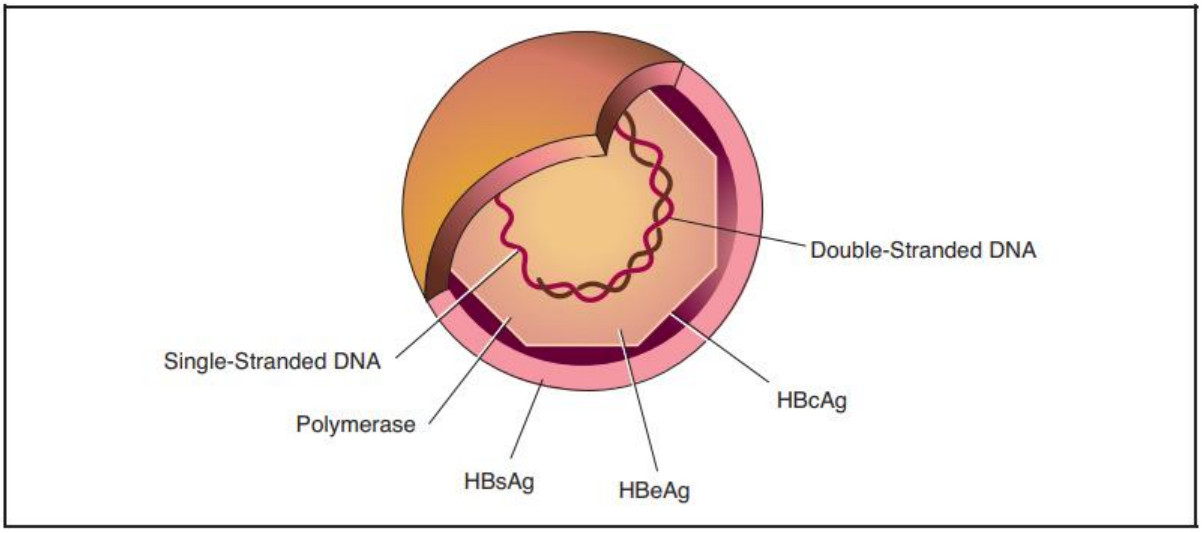

Caption: Hepatitis B virus (HBV) is composed of an inner protein core and an outer protein capsule. The outer capsule contains the hepatitis B surface antigen (HBsAg). The inner core contains HBV core antigen (HBcAg) and hepatitis B e-antigen (HBeAg). This cell also contains polymerase, which catalyzes the formation of the cell's DNA. HBV is the only hepatitis-causing virus that has DNA, instead of RNA. (Illustration by Electronic Illustrators Group.)

Disease: Black lung disease

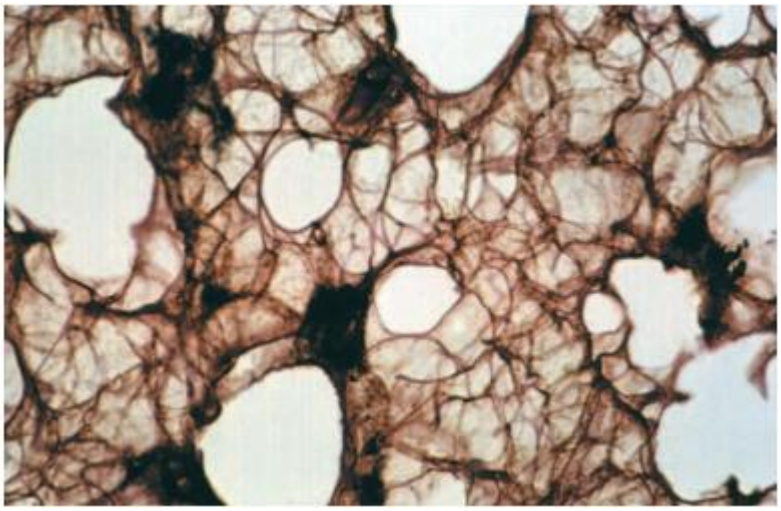

Caption: A light micrograph of a human lung containing particles of inspired coal dust (anthracosis). The black masses shown are groups of coal dust particles. (Photograph by Astrid & Hanns-Frieder Michler, Photo Researchers, Inc. Reproduced by permission.)

Disease: Colostomy

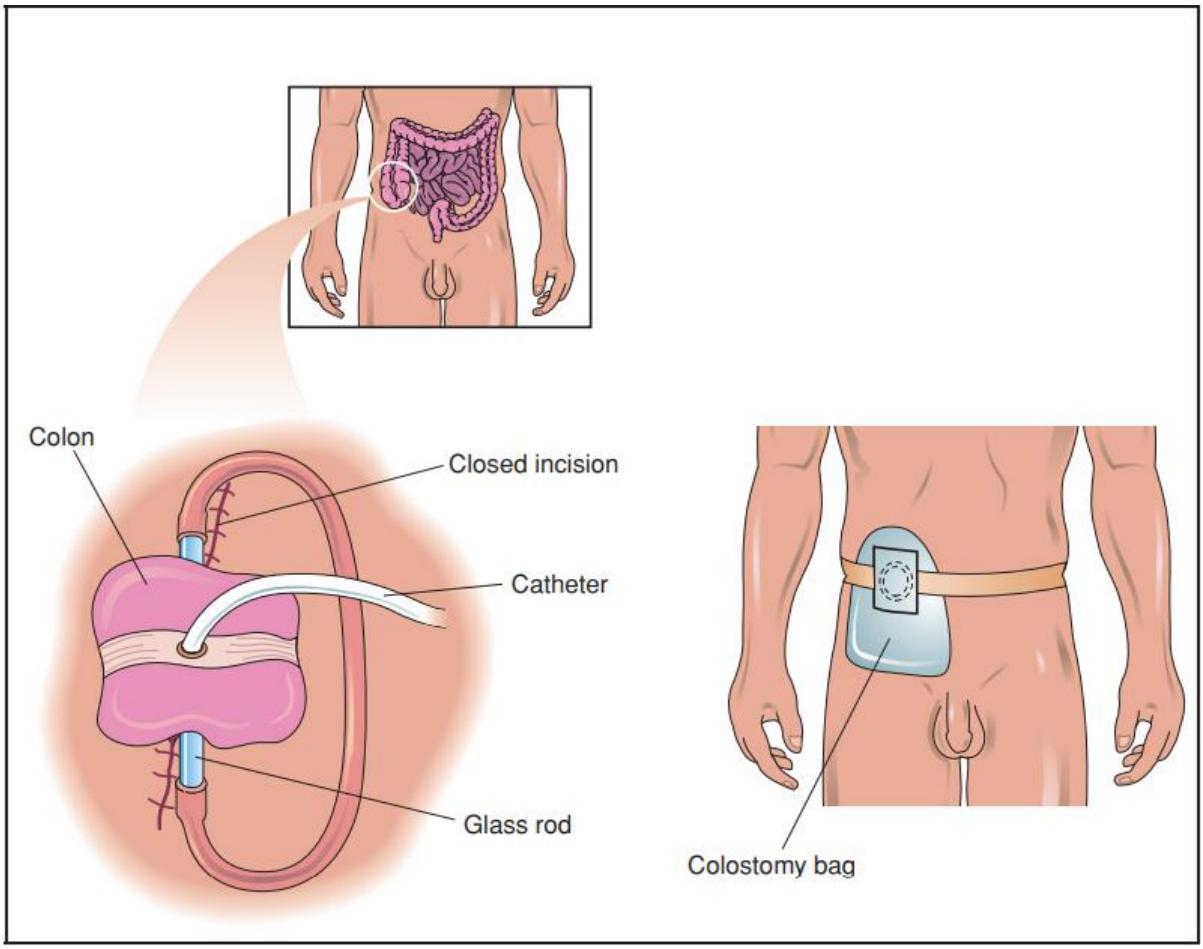

Caption: A colostomy is a surgical procedure in which a portion of the large intestine, or colon, is brought through the abdominal wall to carry feces out of the body. There are three types of colostomies: end colostomy, double-barrel colostomy, and loop colostomy. The loop colostomy is featured in the illustration above. (Illustration by Electronic Illustrators Group.)

Disease: Constipation

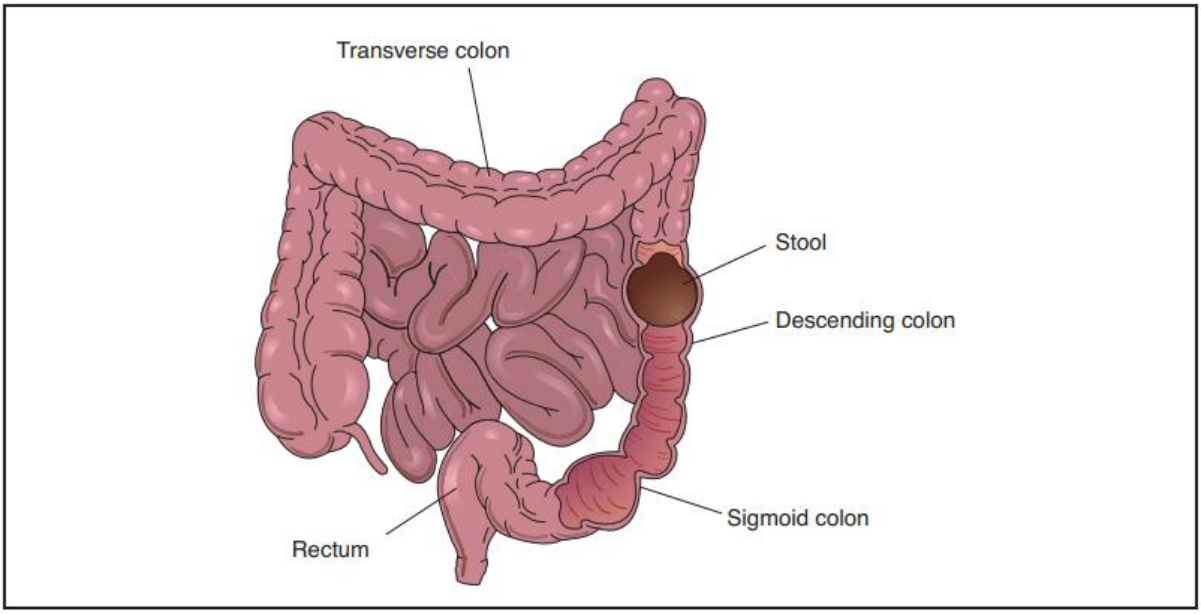

Caption: Constipation is an acute or chronic condition in which bowel movements occur less often than usual or consist of hard, dry stools that are painful or difficult to pass. (Illustration by Electronic Illustrators Group).

Disease: Dialysis, kidney

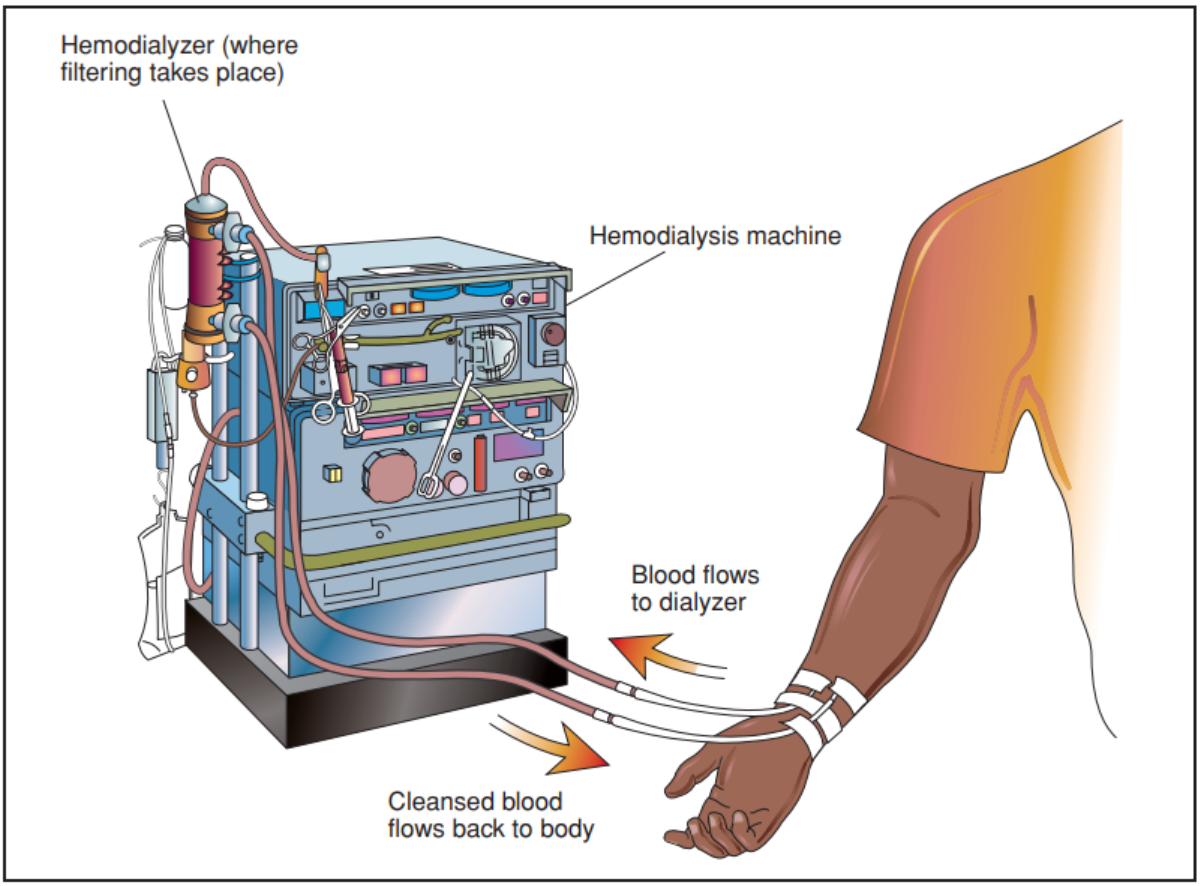

Caption: Hemodialysis is the most frequently prescribed type of dialysis treatment in the United States. This treatment involves circulating the patient's blood outside of the body through a dialysis circuit. The blood is filtered and cleansed inside the hemodialyzer and returned to the body. (Illustration by Electronic Illustrators Group.)

Disease: Depressive disorders

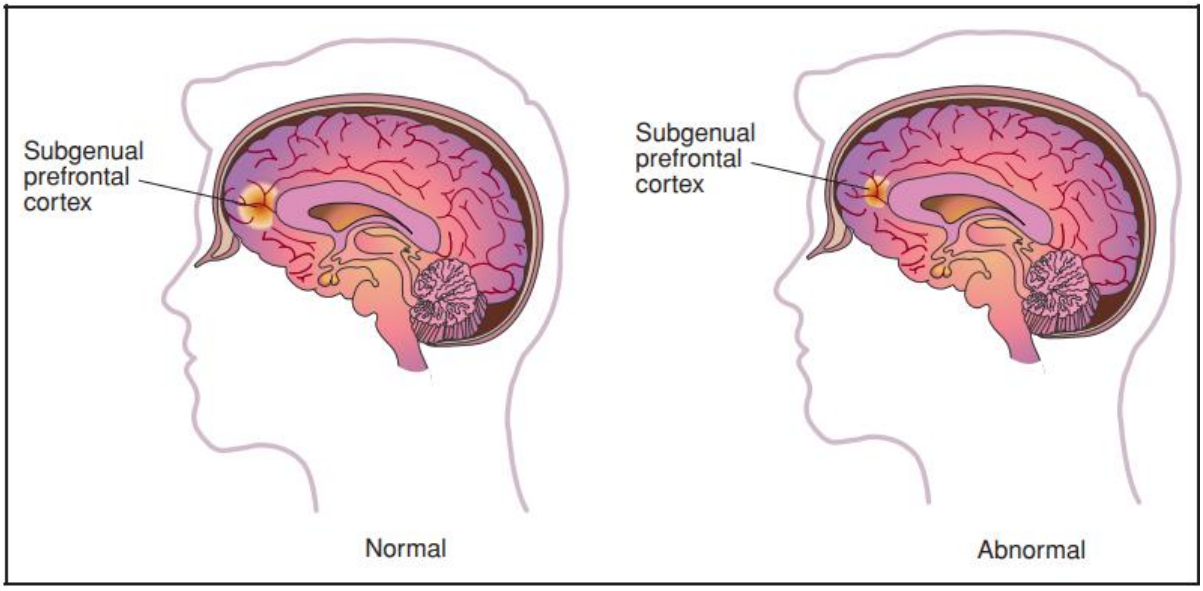

Caption: Recent scientific research has indicated that the size of the subgenual prefrontal cortex of the brain (located behind the bridge of the nose) may be a determining factor in hereditary depressive disorders. (Illustration by Electronic Illustrators Group.)

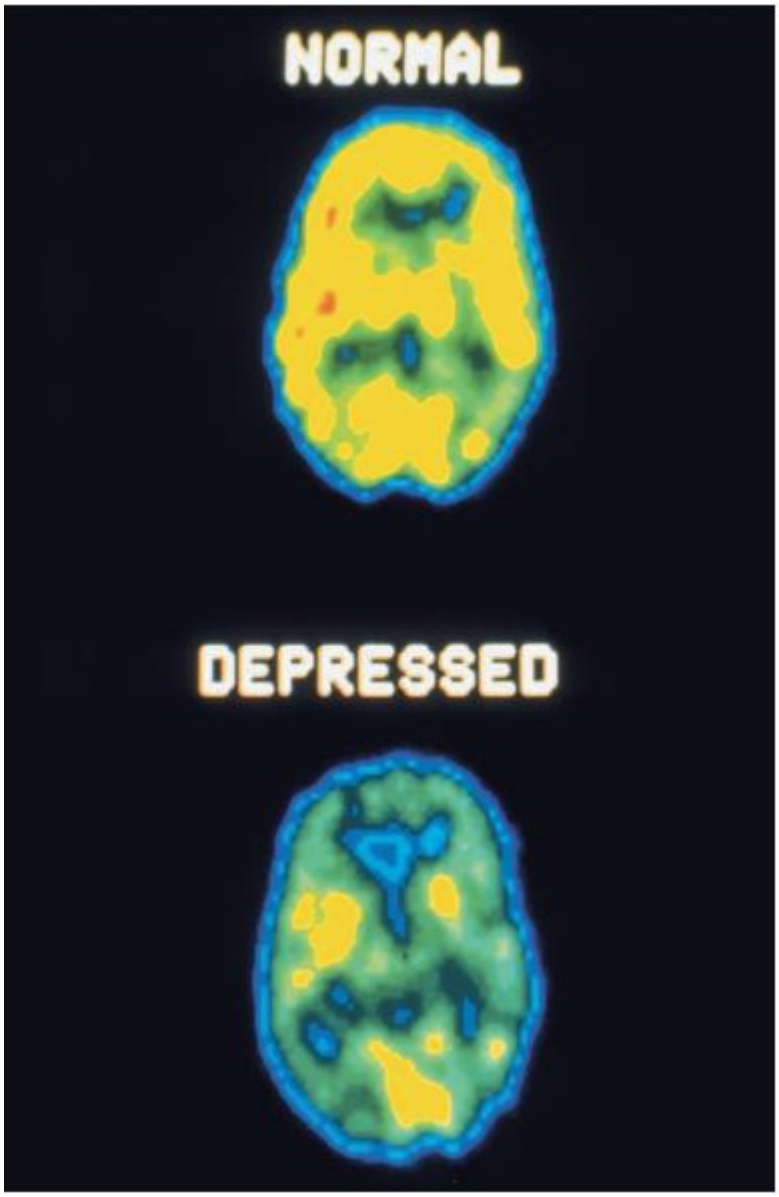

Caption: Positron emission tomography (PET) scans comparing a normal brain with that of someone with a depressed mental disorder. (Photo Researchers, Inc. Reproduced by permission.)

Disease: Discoid lupus erythematosus

Caption: Discoloration of the hands is one characteristic of discoid lupus erythematosus. (Custom Medical Stock Photo. Reproduced by permission.)

Disease: Dislocations and subluxations

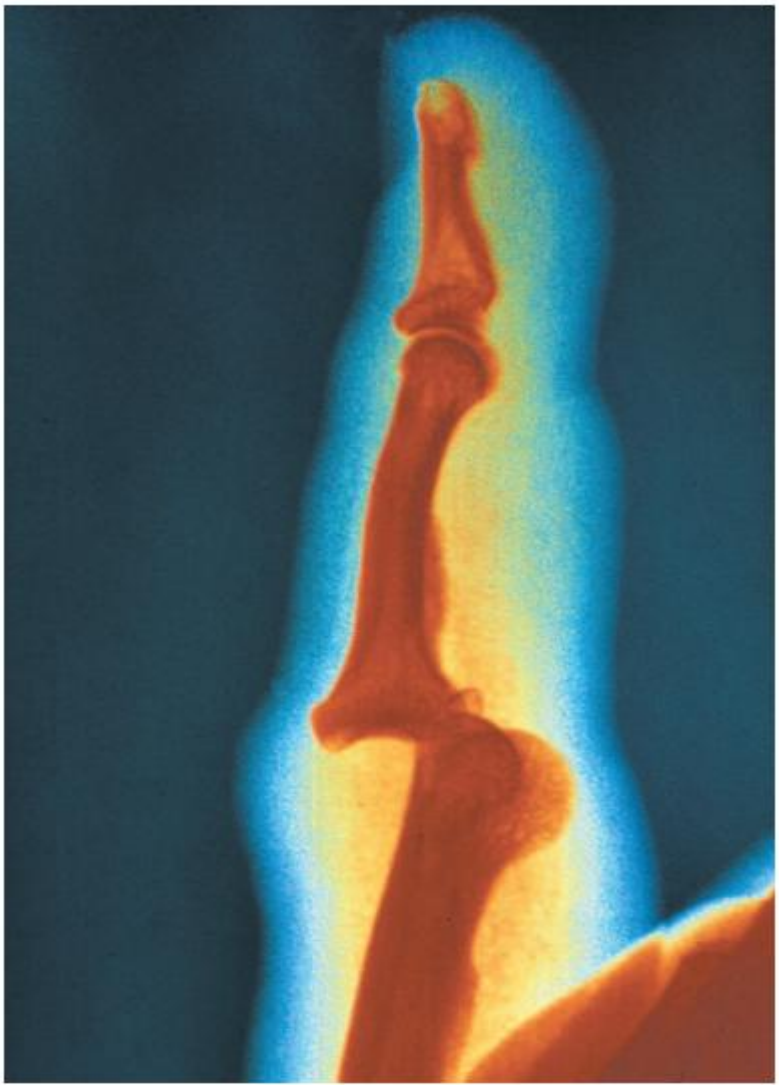

Caption: This x ray shows the dislocation between two bones in a finger. (Photo Researchers, Inc. Reproduced by permission.)

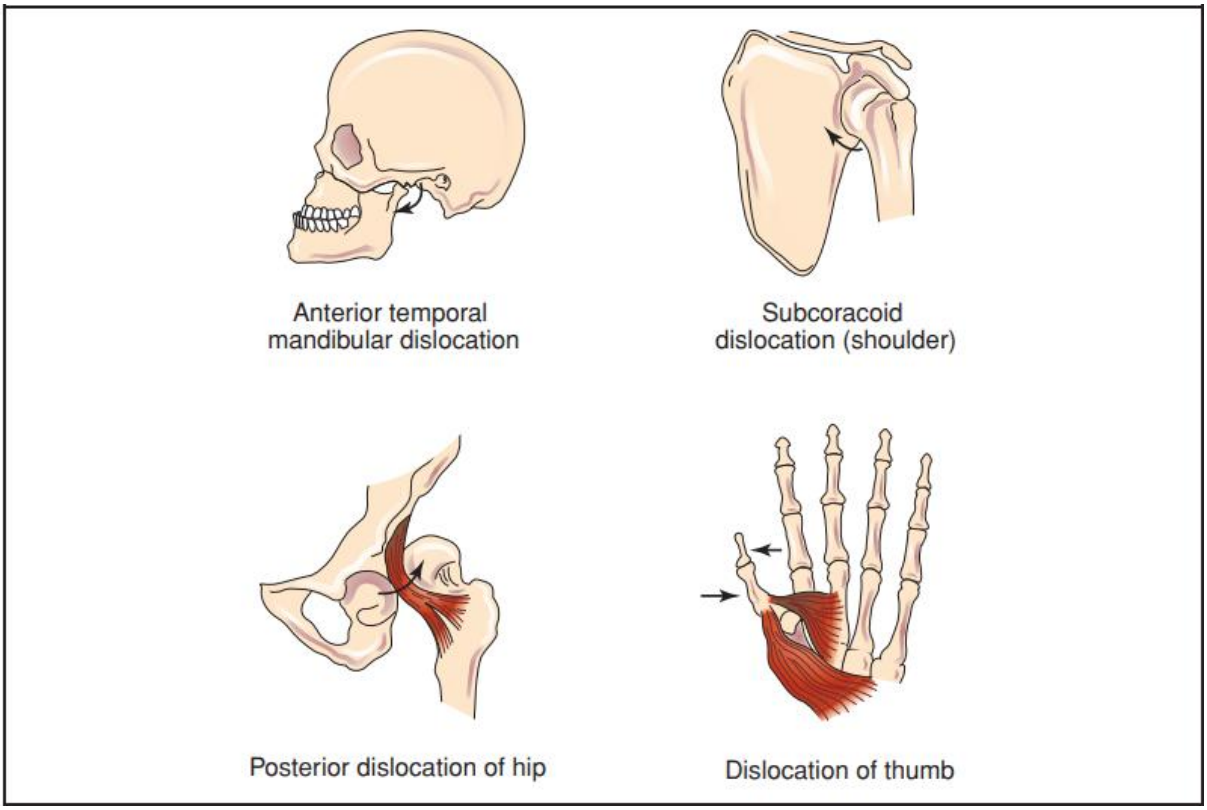

Caption: Dislocations and subluxations refer to the displacement of bones that form a joint. Such conditions most often result from trauma causing adjoining bones to no longer touch each other. A partial or incomplete dislocation is called a subluxation. The illustrations above indicate dislocation of the jawbone, shoulder blade, hip bone, and the thumb. (Illustration by Electronic Illustrators Group.)

Disease: Edema

Caption: Gross lymphedema in the arm of an elderly woman following radiotherapy treatment for breast cancer. (Photograph by Dr. P. Marazzi. Photo Researchers, Inc. Reproduced by permission.)

Disease: Chemotherapy

Caption: Patient undergoing high dose stem cell chemotherapy. (Custom Medical Stock Photo. Reproduced by permission.)

Disease: Gout

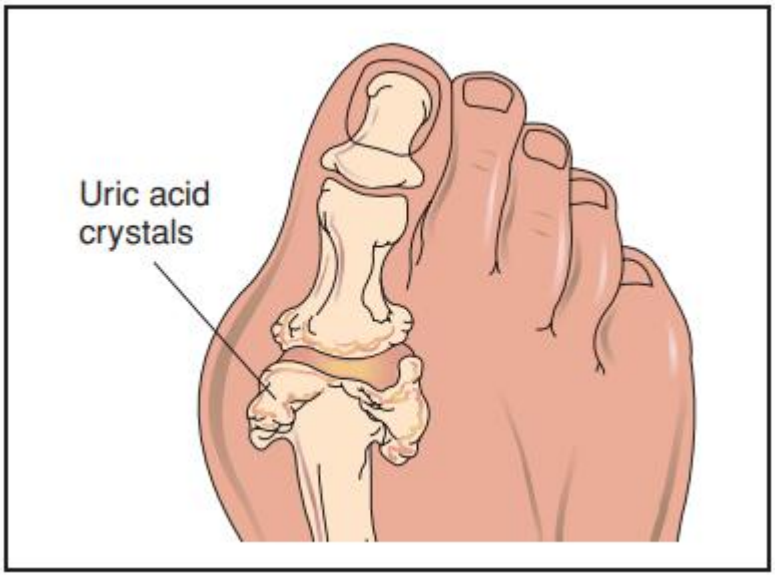

Caption: Gout, a form of acute arthritis, most commonly occurs in the big toe. It is caused by high levels of uric acid in the blood, in which urate crystals settle in the tissues of the joints and produce severe pain and swelling. (Illustration by Electronic Illustrators Group.)

Disease: Hallucinations

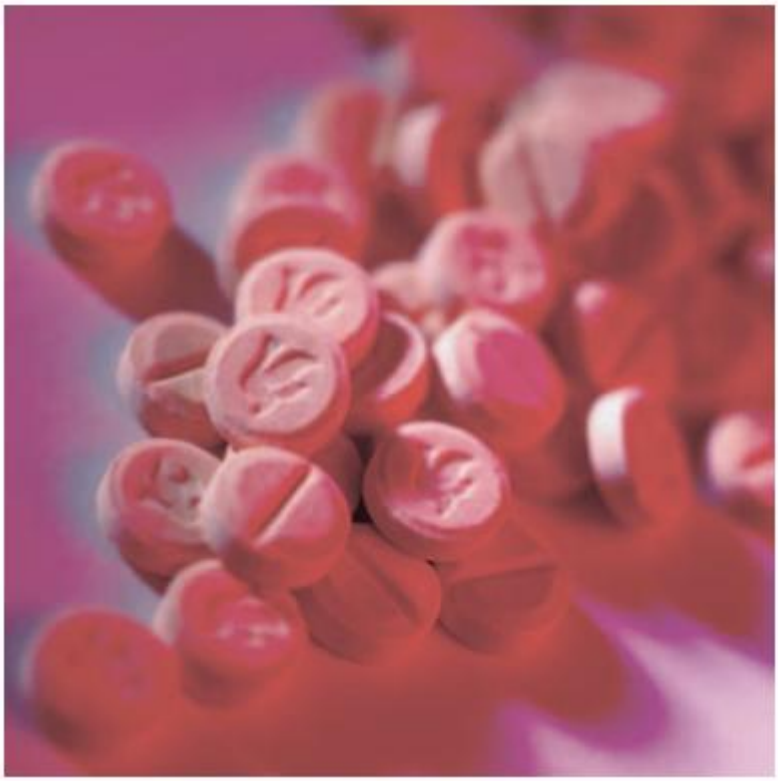

Caption: Ecstasy tablets. (Corbis. Reproduced by permission)

Disease: Heartburn

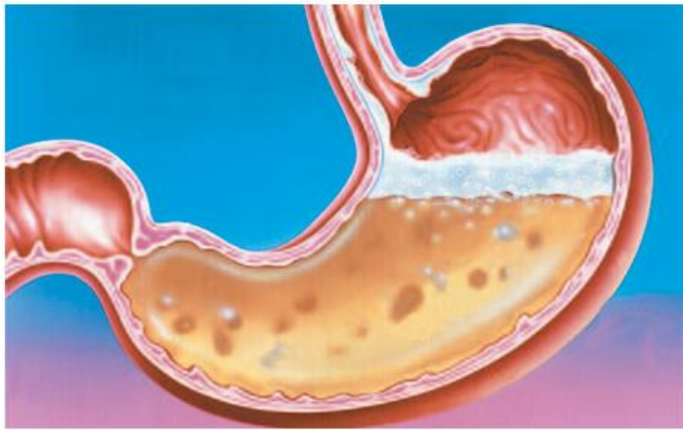

Caption: An illustration of foaming antacid on top of the contents of a human stomach. Heartburn is caused by a backflow of the stomach's acidic contents into the esophagus, causing inflammation and a sense of pain that can rise to the throat. (Illustration by John Bavosi, Custom Medical Stock Photo. Reproduced by permission.)

Disease: Hypospadias and epispadias

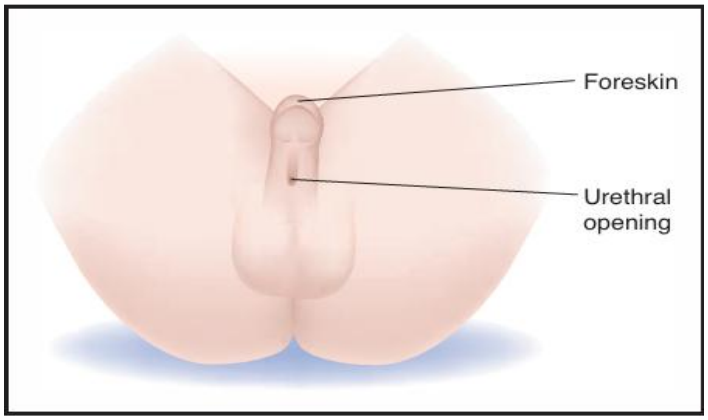

Caption: In hypospadias, the urethra opens along the penile shaft rather than at the penile tip. (Illustration by Argosy Inc.)

Disease: Cerumen impaction

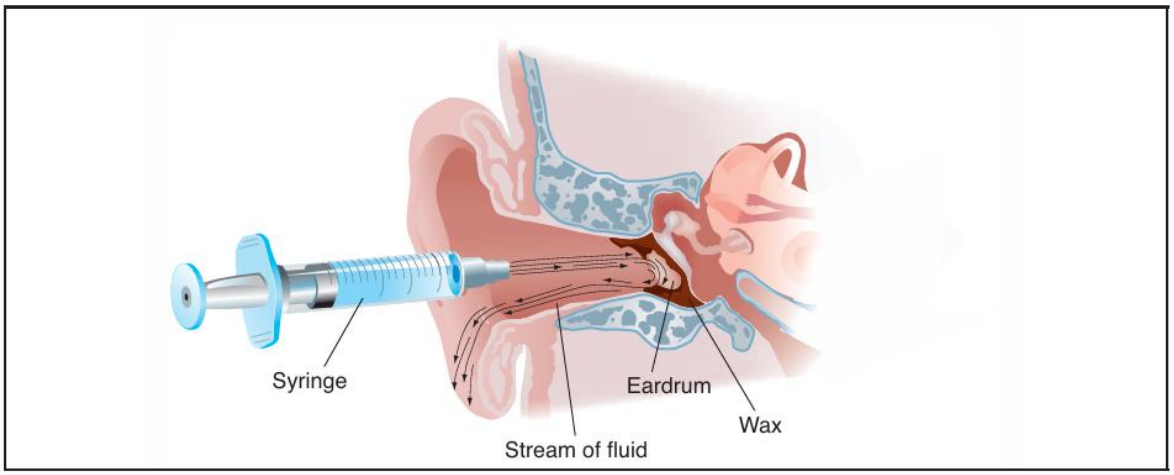

Caption: Ear wax is removed by flushing the ear canal with warm fluid. (Illustration by Argosy, Inc.)

Disease: Otitis externa

Caption: A close-up image of the ear of an elderly man suffering from non-infectious otitis externa. The skin in the ear canal and outer ear is scaly. (Photograph by Dr. P. Marazzi, Custom Medical Stock Photo. Reproduced by permission.)

Disease: Irritable bowel syndrome

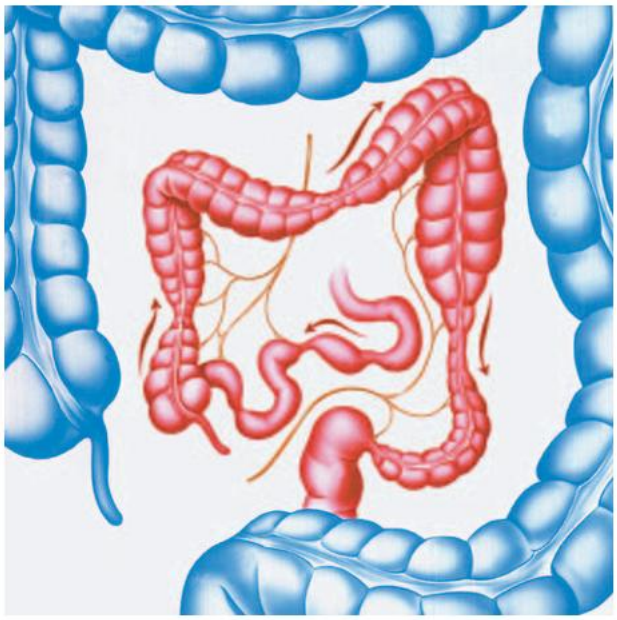

Caption: Normal and diseased(center) colons. Areas of constriction in the colon cause constipation, while areas of distention cause diarrhea. (John Bavosi/Science Photo Library. Custom Medical Stock Photo. Reproduced by permission.)

Disease: Substance abuse and dependence

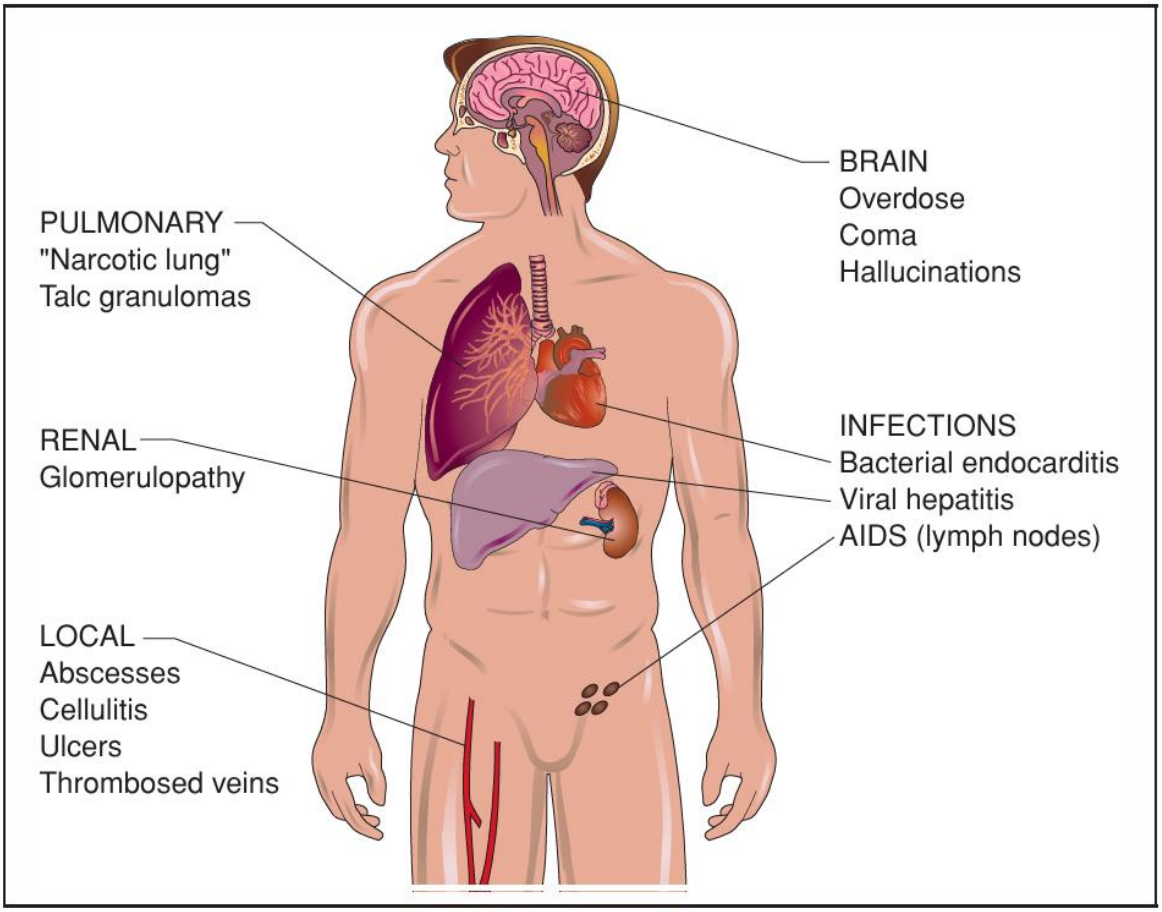

Caption: Substance abuse often causes a variety of medical abnormalities and conditions throughout the body, as shown in the illustration above. (Illustration by Electronic Illustrators Group.)

Disease: Low back pain

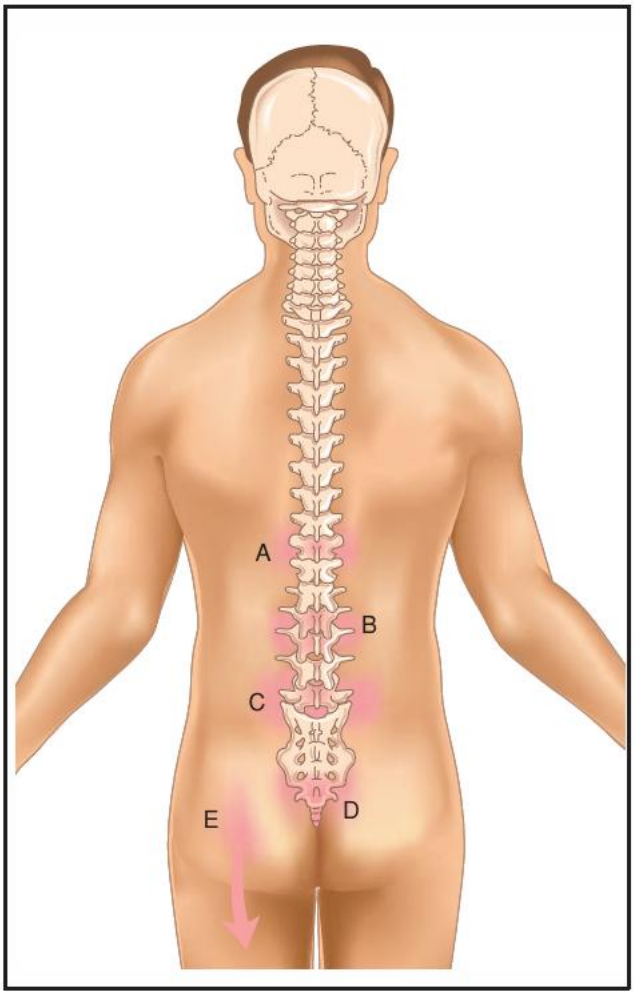

Caption: Sites of low back pain. Pain anywhere along the spine(A)can be caused by osteoarthritis. Pain along one or the other side of the spine maybe(B)a kidney infection. Trauma to back muscles, joints, or disks(C)causes low back pain. Damage to the coccyx (D) can occur during a fall. Sciatica (E) can cause pain to run down from the back and buttocks area down a leg. (Illustration by Electronic Illustrators Group.)

Disease: Esophageal cancer

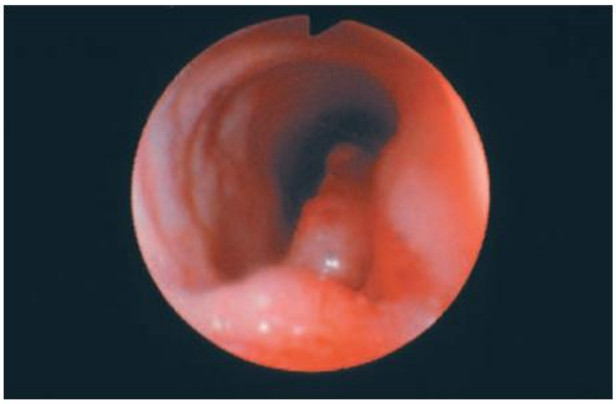

Caption: A close-up view of a cancerous esophageal tumor. (Custom Medical Stock Photo. Reproduced by permission.)

Disease: Mitral valve stenosis

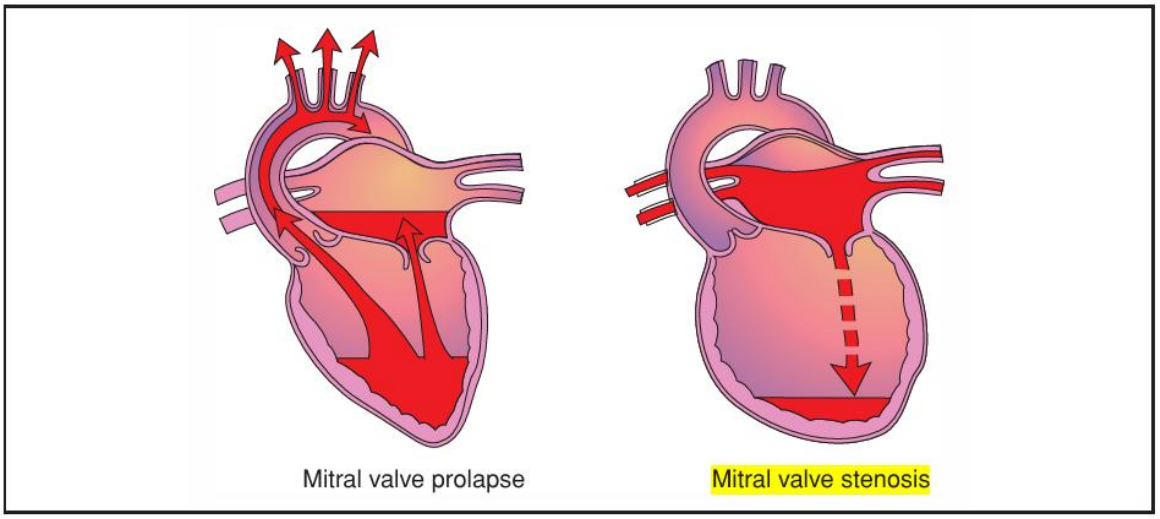

Caption: Mitral valve prolapse occurs when the mitral valve does not open and close properly. When this happens, the valve may balloon into the left atrium of the heart, causing the mitral valve to leak blood backward. Mitral valve stenosis refers to the narrowing of the mitral valve, in which the flow of blood from the atrium to the ventricle becomes restricted. (Illustration by Electronic Illustrators Group.)

Disease: Multiple sclerosis

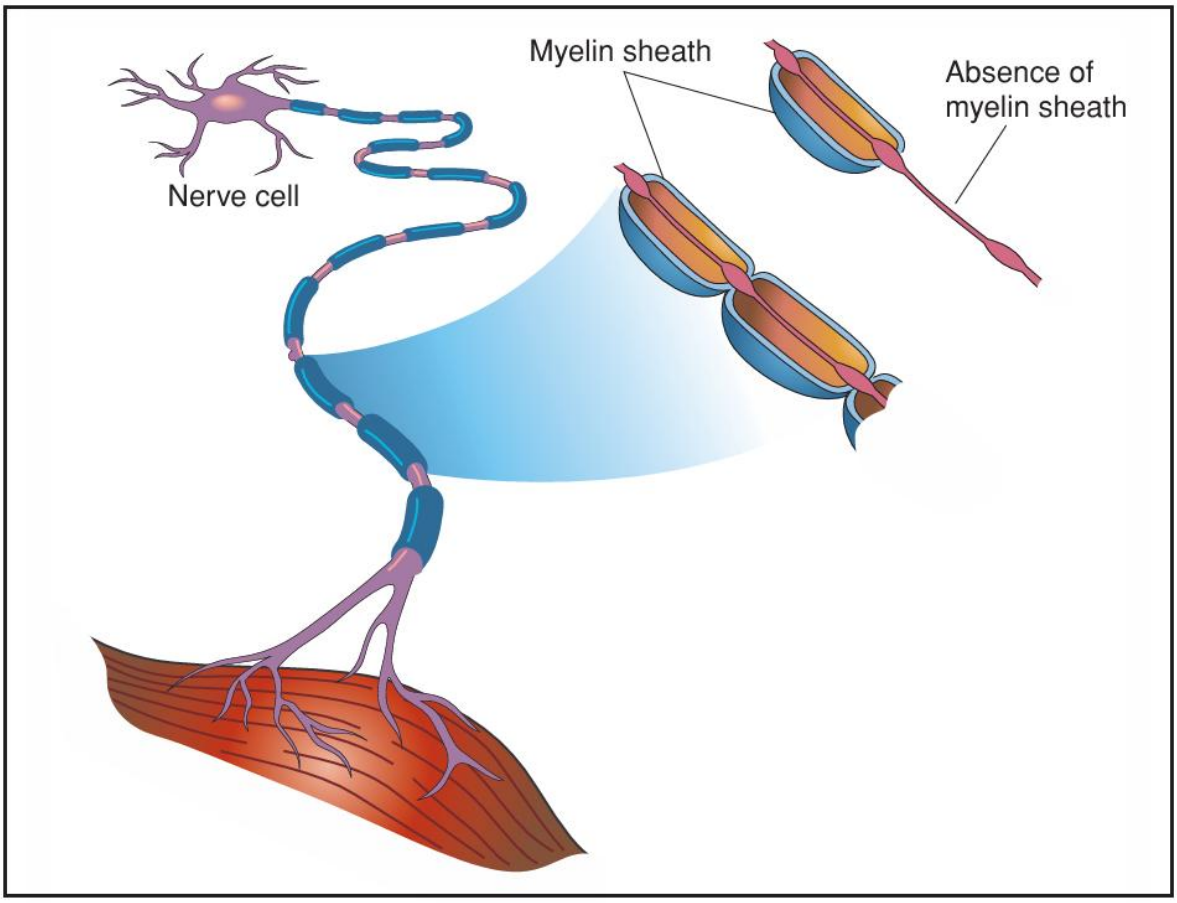

Caption: Multiple sclerosis (MS) is an autoimmune disease in which immune cells attack and destroy the myelin sheath which stimulates neurons in the brain and spinal cord. When myelin is destroyed, nerve messages are sent more slowly and less efficiently. Scar tissue then forms over the affected areas, disrupting nerve communication. MS symptoms occur when the brain and spinal cord nerves cease to communicate properly with other parts of the body. (Illustration by Electronic Illustrators Group.)

Disease: Influenza

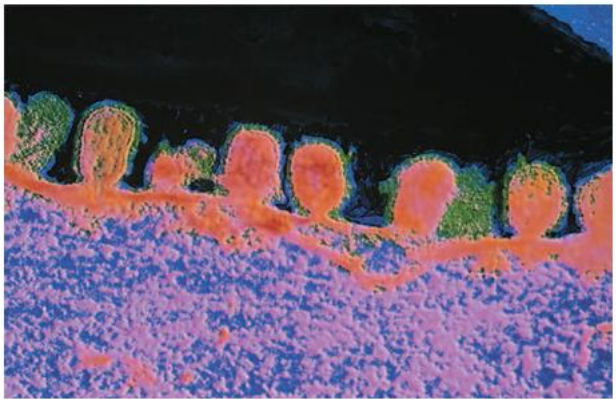

Caption: A transmission electron microscopy (TEM) image of influenza viruses budding from the surface of an infected cell. (Photo Researchers, Inc. Reproduced by permission.)

Disease: Tricuspid valve insufficiency

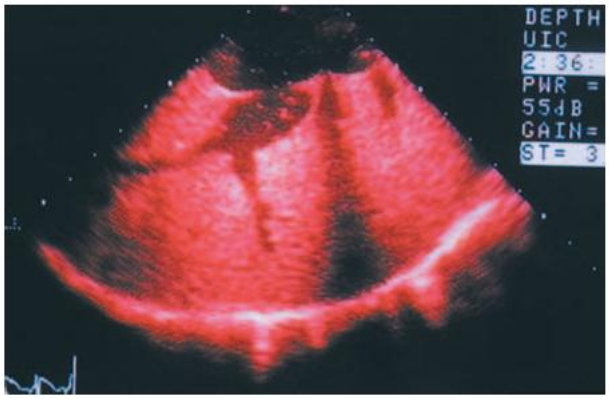

Caption: This echocardiogram of the heart shows tricuspid valve insufficiency. (Custom Medical Stock Photo. Reproduced by permission.)

Disease: Pernicious anemia

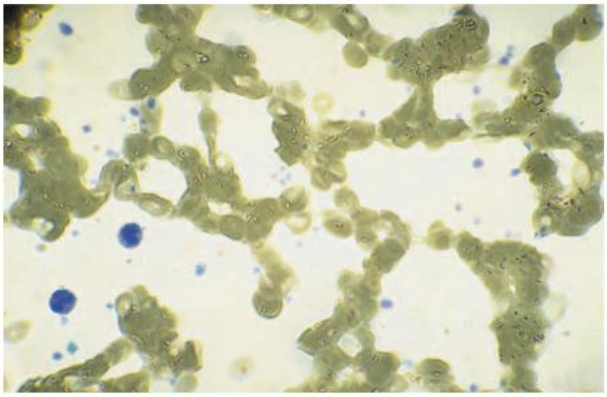

Caption: A smear of red blood cells indicating folic acid (vitamin B12) deficiency. (Custom Medical Stock Photo. Reproduced by permission.)

Disease: Malignant melanoma

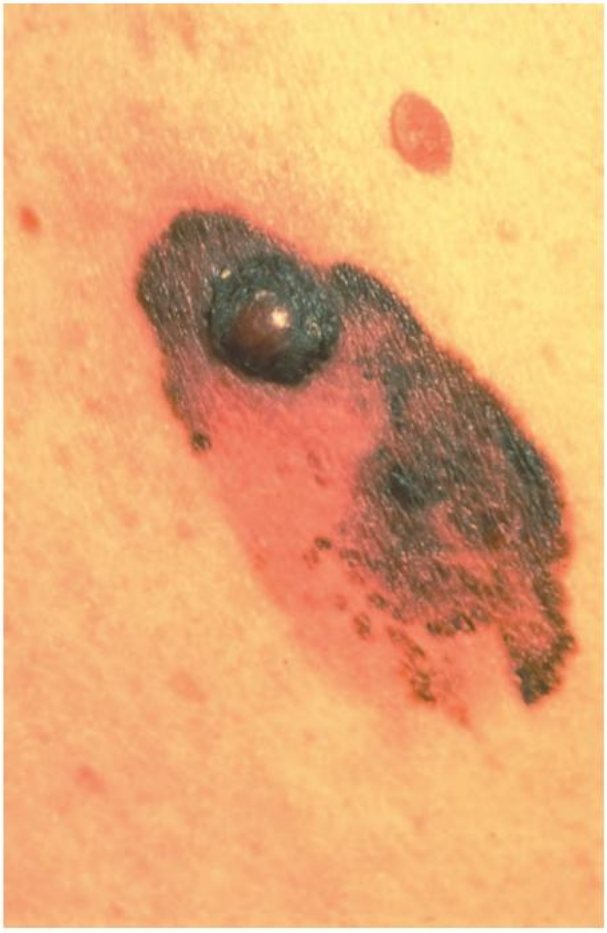

Caption: A close-up image of a malignant melanoma on a patient's back. (Custom Medical Stock Photo. Reproduced by permission.)

Disease: Breast cancer

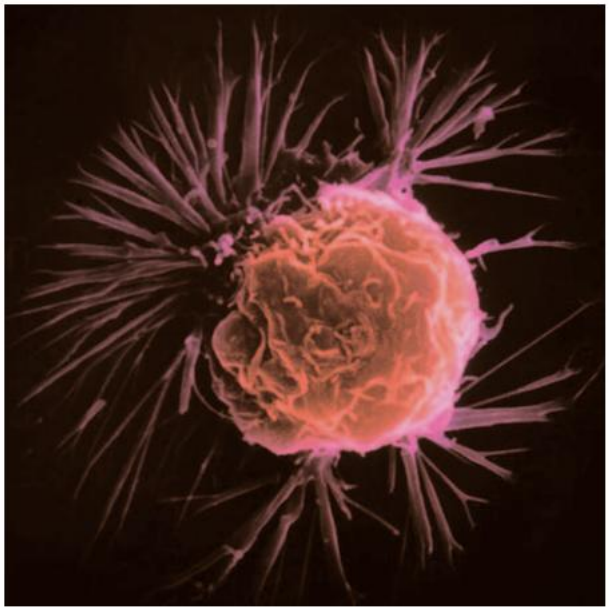

Caption: A breast cancer cell. (Phototake NYC. Reproduced by permission.)

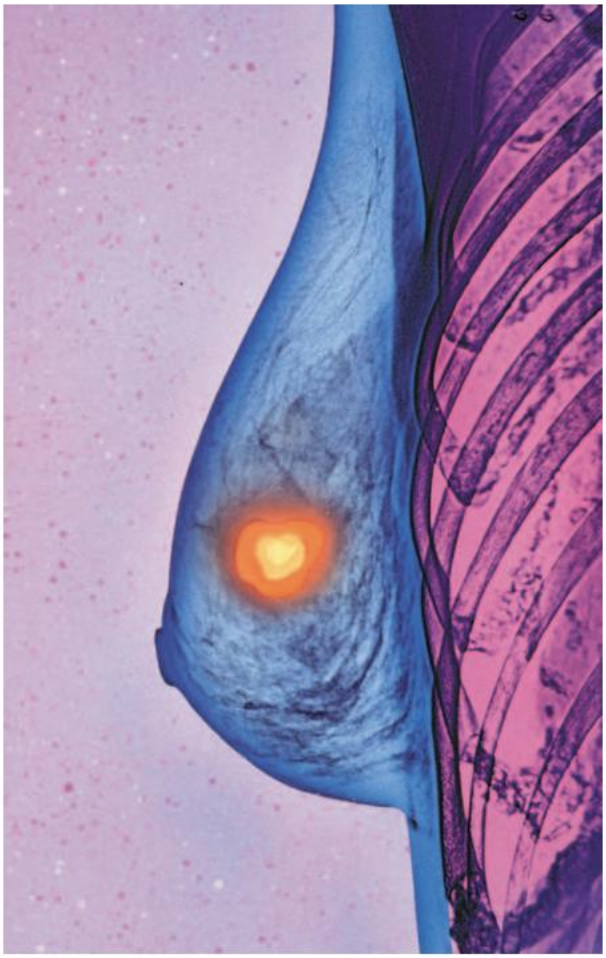

Caption: Mammogram indicating a tumor in the center of the breast. (Chris Bjornberg, Photo Researchers. Reproduced by permission.)

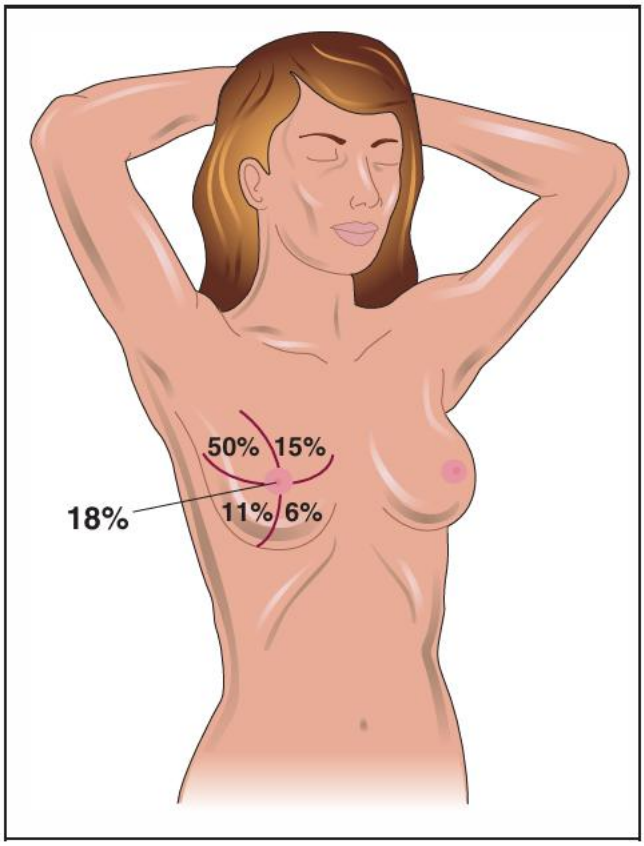

Caption: This illustration shows the frequency of breast cancer developing in the four quadrants of the breast and the nipple. (Illustration by Electronic Illustrators Group.)

Disease: Colon cancer

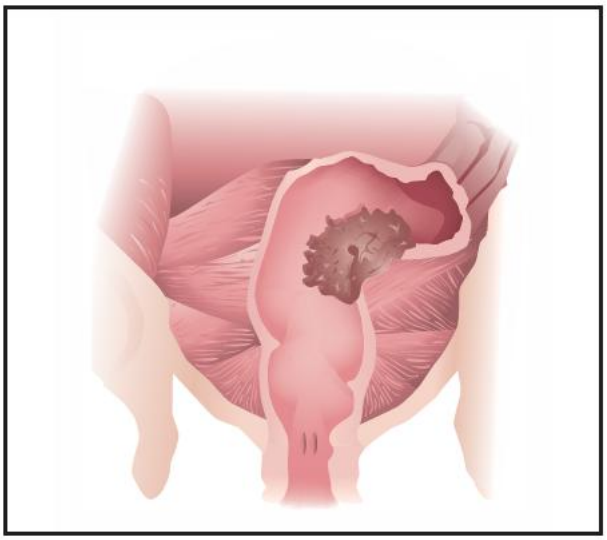

Caption: A colon with a cancerous growth. (Illustration by Argosy Inc.)

Disease: Polio

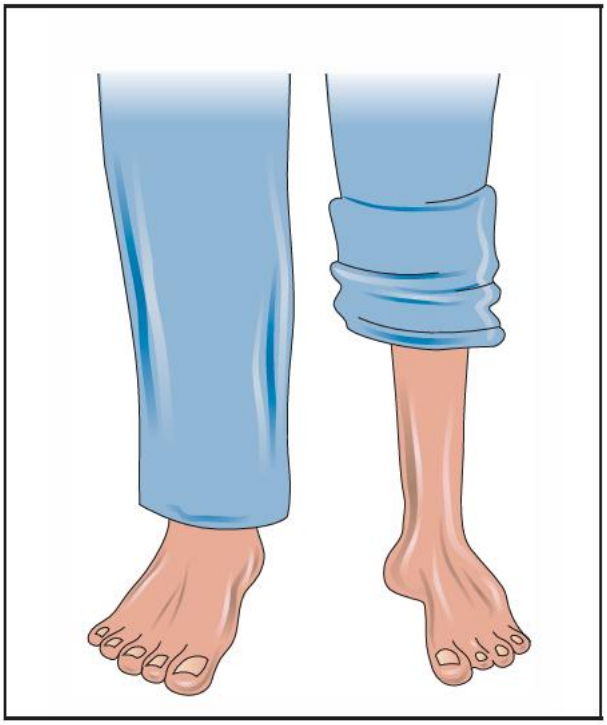

Caption: In its most severe form, polio causes paralysis of the muscles of the legs, arms, and respiratory system. All muscle tone is lost in the affected limb, and the muscle becomes flaccid and begins to atrophy, as shown in the illustration above. (Illustration by Electronic Illustrators Group.)

Disease: Pulmonary embolism

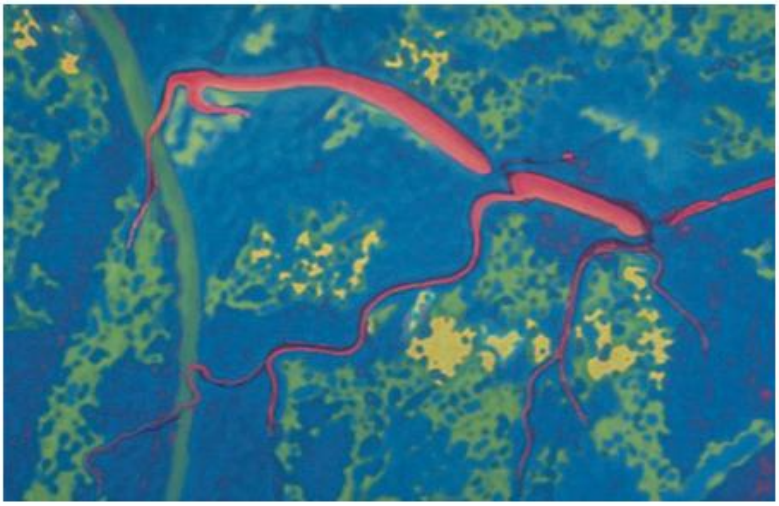

Caption: An angiography of a pulmonary embolism. (Custom Medical Stock Photo. Reproduced by permission.)

Disease: Coronary artery bypass graft surgery

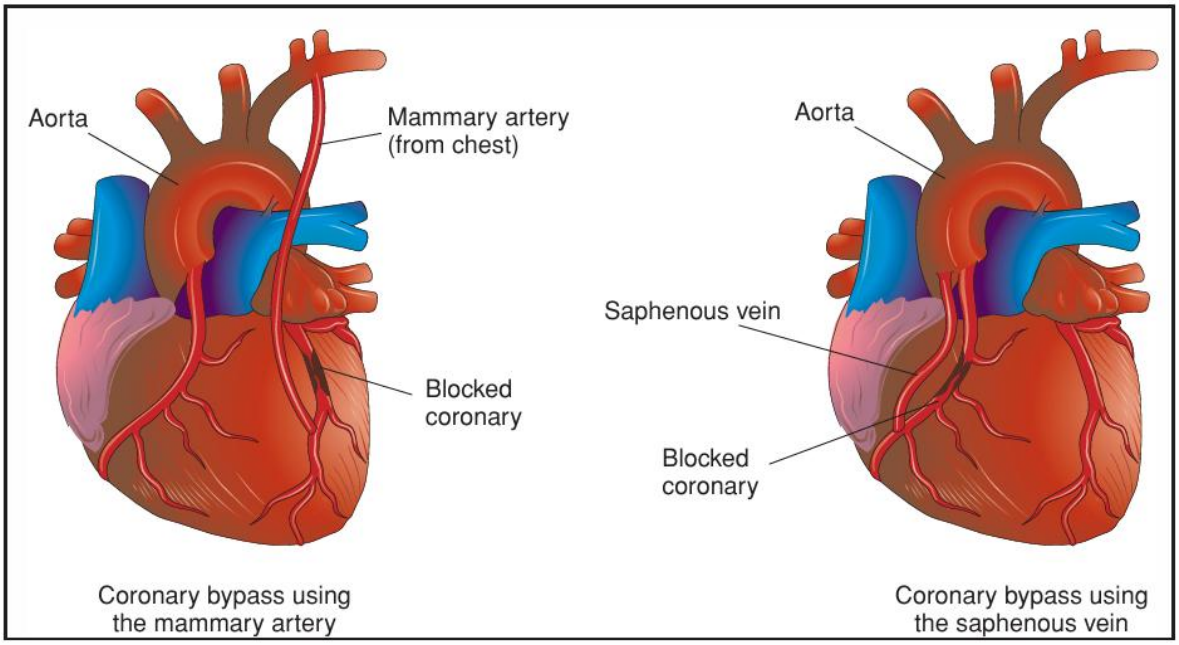

Caption: Coronary artery bypass graft surgery builds a detour around one or more blocked coronary arteries with a graft from a healthy vein or artery. The graft goes around the clogged artery (or arteries) to create new pathways for oxygen-rich blood to flow to the heart. (Illustration by Electronic Illustrators Group.)

Disease: Pacemakers

Caption: Pacemakers like these are usually implanted under the skin below the collarbone. The pacemaker is connected to the heart by a wire inserted into a major vein in the neck and guided down into the heart. (Photograph by Eamonn McNulty, Photo Researchers, Inc. Reproduced by permission.)

Disease: Psoriasis

Caption: Psoriasis, a chronic skin disorder, may appear on any area of the body, including the elbow, as shown above. (Photo Researchers, Inc. Reproduced by permission.)

Disease: Rashes

Caption: An unidentified rash on young boy's back. (Custom Medical Stock Photo. Reproduced by permission.)

Disease: Crohn's disease

Caption: A barium x-ray showing the colon of a patient with Crohn's disease where the large and small intestines join (bottom left). (Custom Medical Stock Photo. Reproduced by permission.)

Disease: Schizophrenia

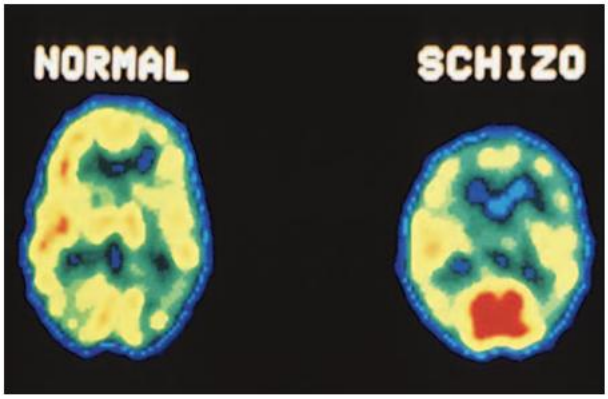

Caption: (Photo Researchers Inc. Reproduced by permission.)

Disease: Scoliosis

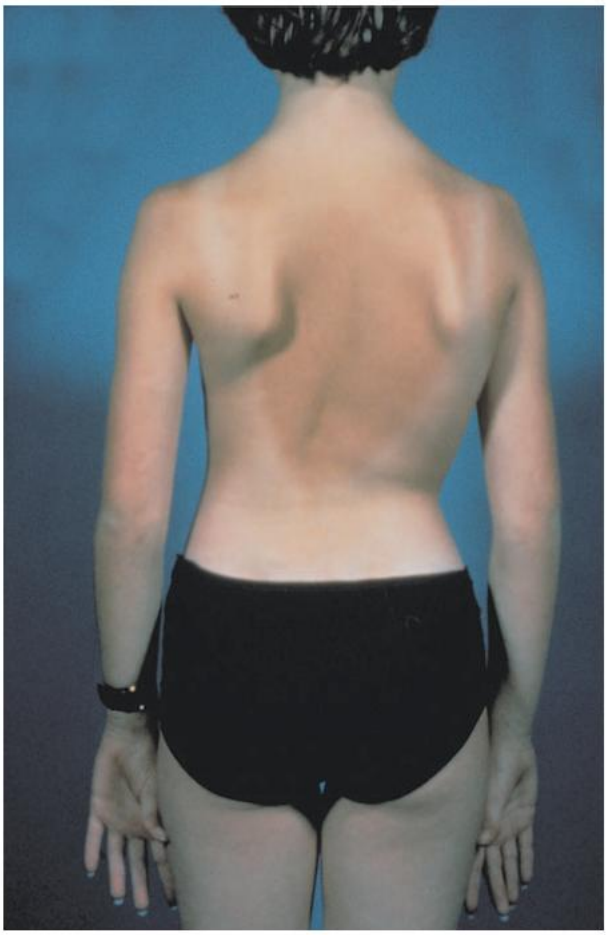

Caption: This woman suffers from scoliosis, or curvature of the spine. (Custom Medical Stock Photo. Reproduced by permission.)

Disease: Staphylococcal infections

Caption: A close-up of a woman's finger and nail cuticle infected with Staphyloccus aureus. (Custom Medical Stock Photo. Reproduced by permission.)

Disease: Staphylococcal infections

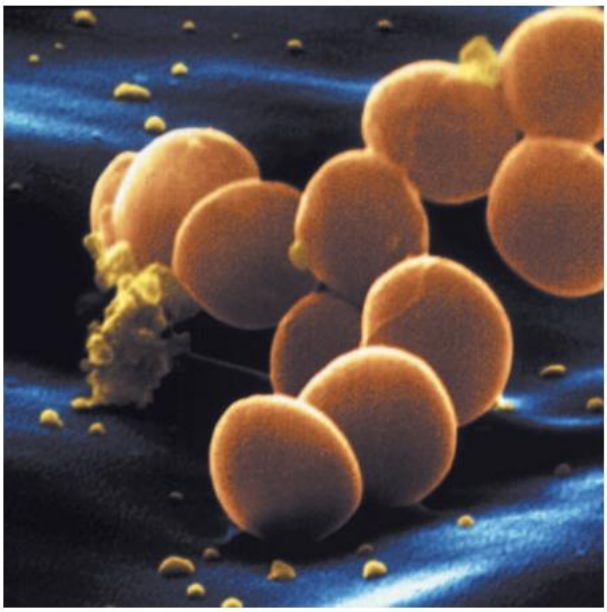

Caption: A micrographic image of Staphylococcus aureus. (Photograph by Oliver Meckes, Photo Researchers, Inc. Reproduced by permission.)

Disease: Tension headache

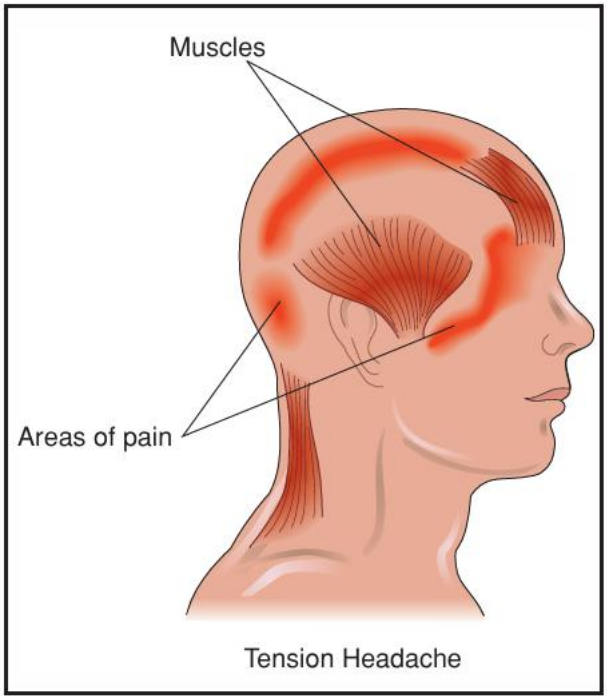

Caption: Tension headache is the most common type of headache caused by severe muscle contractions triggered by stress or exertion. Tension headaches usually occur in the front of the head, although they may also appear at the top or the back of the skull, as shown in the illustration above. (Illustration by Electronic Illustrators Group.)

Disease: Ulcerative colitis

Caption: A specimen of a colon indicating ulcerative colitis. (Photo Researchers, Inc. Reproduced by permission.)

Disease: Cataracts

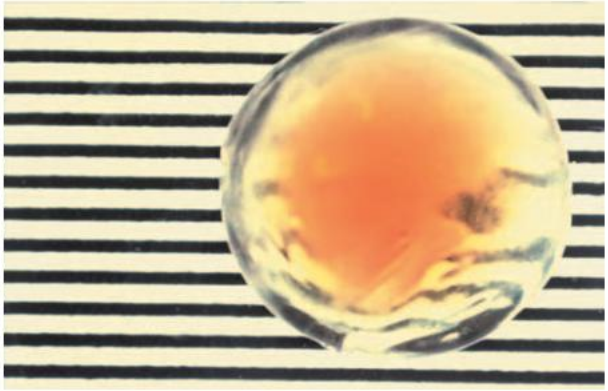

Caption: A dense cataract on lens of eye. (Photograph by Margaret Cubberly, Phototake NYC. Reproduced by permission.)

Disease: Kyphosis

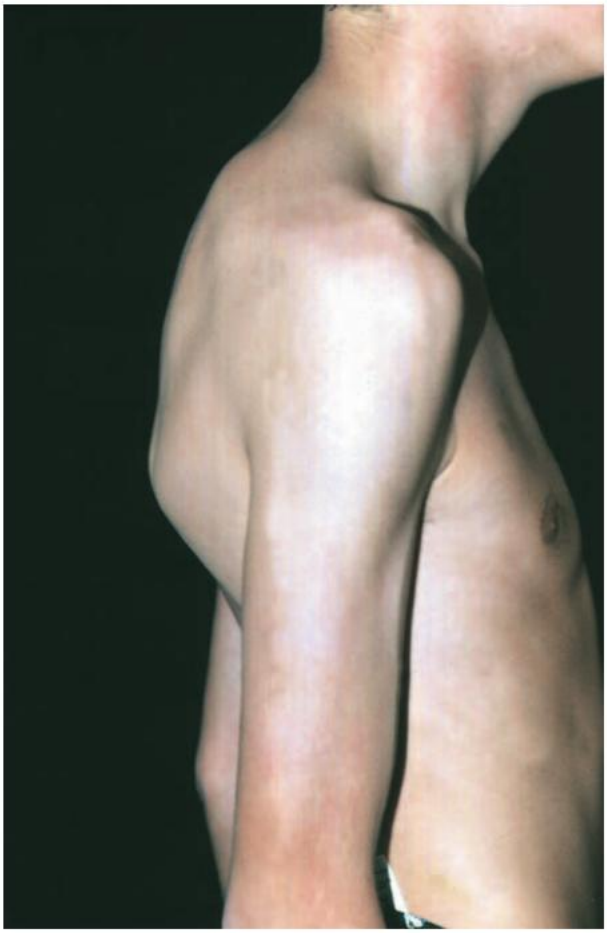

Caption: This patient's spine shows excessive backward curvature at the level of the upper chest. (Custom Medical Stock Photo. Reproduced by permission.)

Disease: Sinusitis

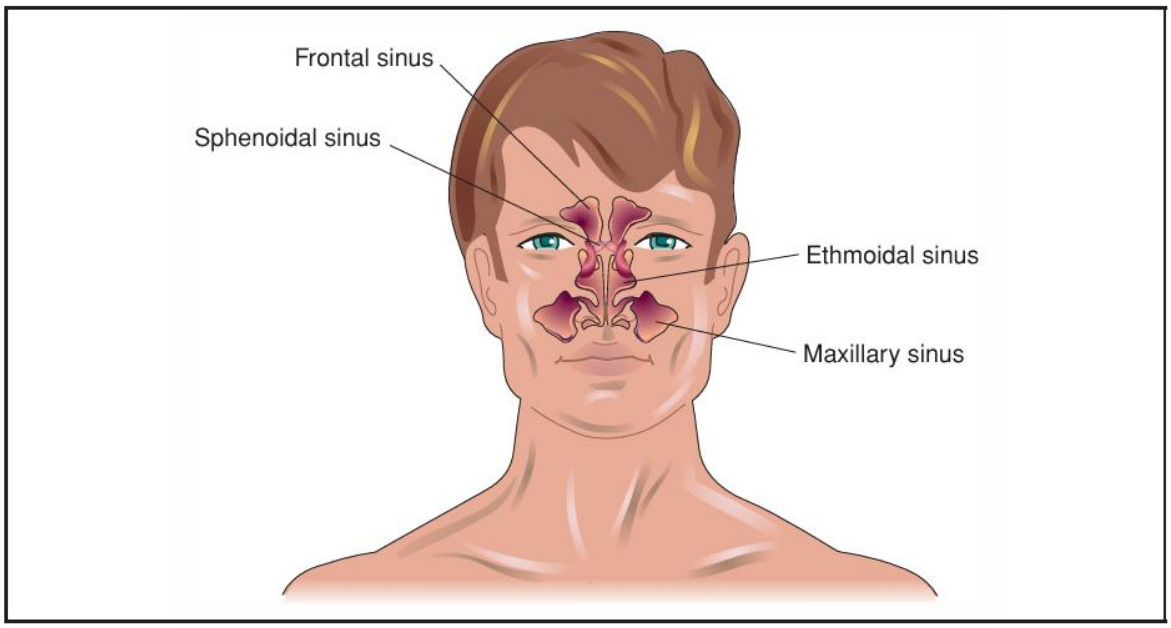

Caption: Sinusitis is the inflammation of the sinuses caused by a bacterial infection. Sometimes diagnosis may be problematic because the symptoms often mimic those of the common cold. Sinusitis is usually treated with antibiotics. (Illustration by Electronic Illustrators Group.)

Disease: Urinary incontinence

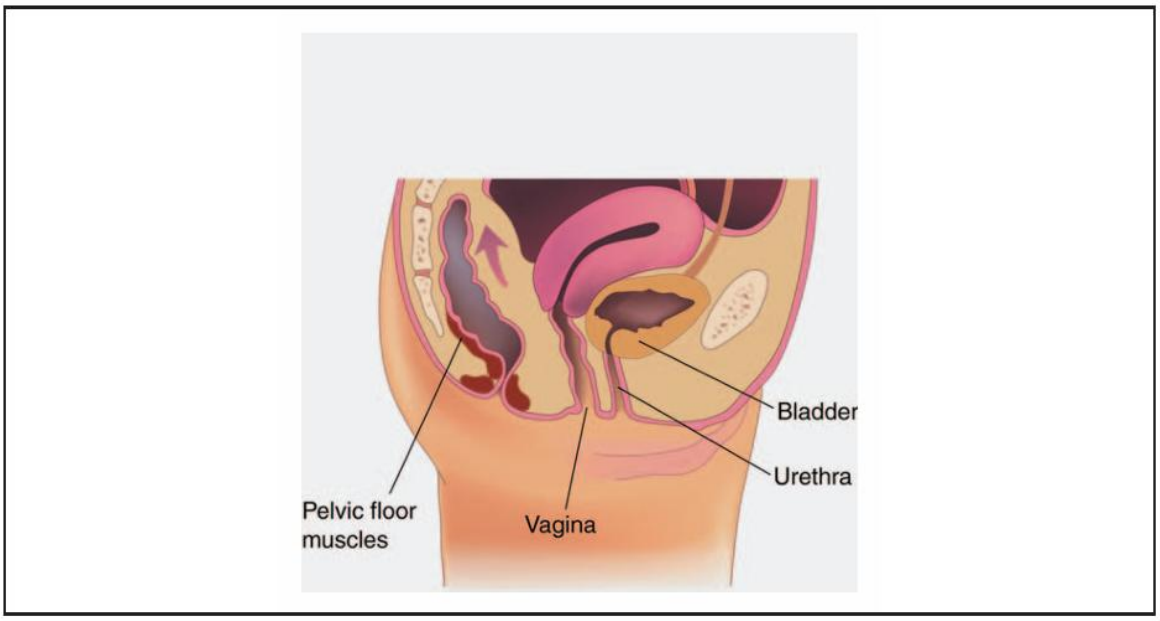

Caption: Strengthening the pelvic floor muscles by performing Kegel exercises helps to alleviate stress incontinence in women. Contract the pelvic floor muscles as if stopping an imaginary flow of urine. Hold for 10 seconds and repeat. (Illustration by Electronic Illustrators Group.)

Disease: Ventricular tachycardia

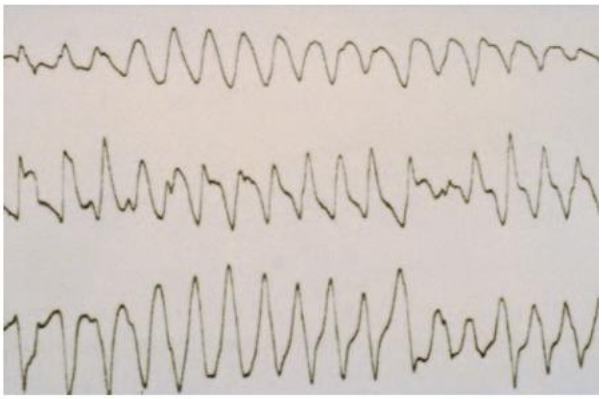

Caption: An electrocardiographic image indicating a rapid heartbeat. (Custom Medical Stock Photo. Reproduced by permission.)