DIABETIC RETINOPATHY SCREENING REPORT

Generated: April 27, 2026 01:12 AM | **Created by:** Dr. Macky

PATIENT INFORMATION

Full Name	Prince Dela Vega Mendez	Date of Birth	1999-12-31
Age	—	Sex	Male
Patient ID	EYS-2026-00014	Contact	42434343
Height	170.0 cm	Weight	109.0 kg
BMI	37.72 (Obese)	Eye(s) Screened	Right Eye, Left Eye
Screening Date	2026-04-26 07:31:21		

DIABETIC HISTORY & DIABETES MANAGEMENT

Diabetes Type	Type 1 + Type 2
Diagnosis Date	12/10/2019
Duration	78.0 year(s)
HbA1c	—
Treatment Regimen	Insulin + Oral medications
Previous DR Stage	Moderate NPDR
Previous DR Treatment	No

VITAL SIGNS

Blood Pressure	—	Fasting Blood Sugar	—
Visual Acuity (Left)	—	Visual Acuity (Right)	—
Random Blood Sugar	—		

REPORTED SYMPTOMS

None reported

OTHER SYMPTOM DETAILS

None recorded

AI CLASSIFICATION RESULT

Classification	**No DR**
Confidence	—

DOCTOR DECISION

Doctor Classification	**No DR**
Decision Mode	**Accepted**
Doctor Findings	—
Final Diagnosis	**No DR**
Final Diagnosis Scale	**Based on ICDR Severity Scale**

DOCTOR COMMENTS

No doctor comments provided

IMAGE RESULTS

Right Eye

AI Results: **No DR**

Confidence: —

FUNDUS

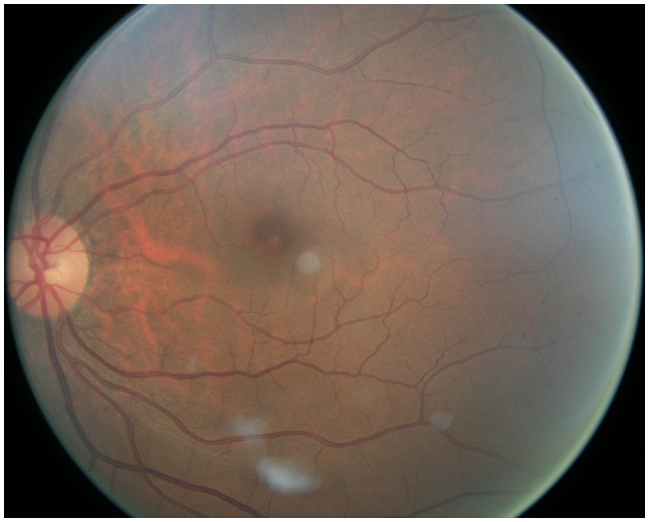

HEATMAP

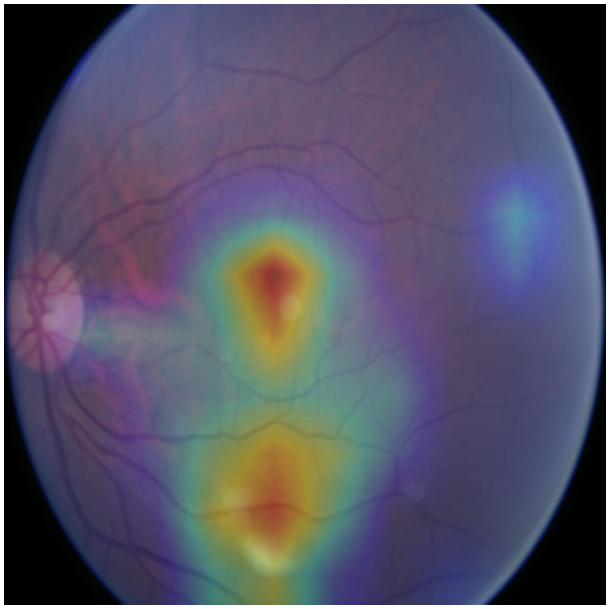

Left Eye

AI Results: **No DR**

Confidence: —

FUNDUS

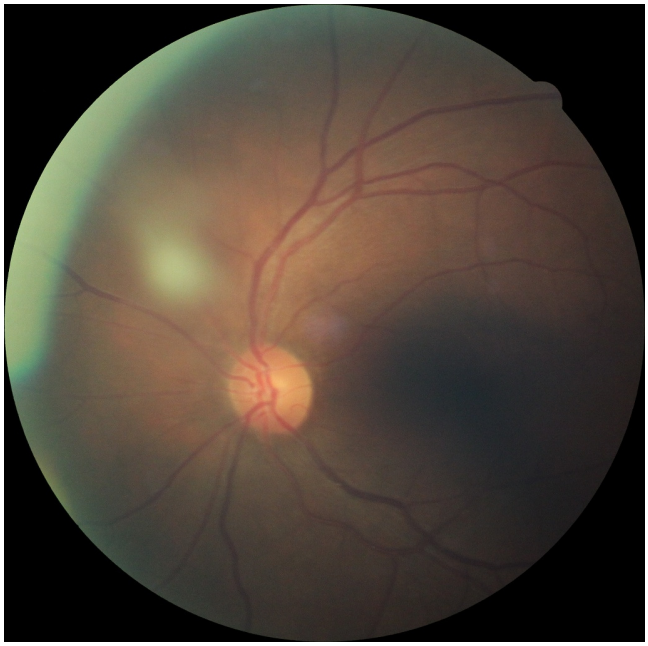

HEATMAP

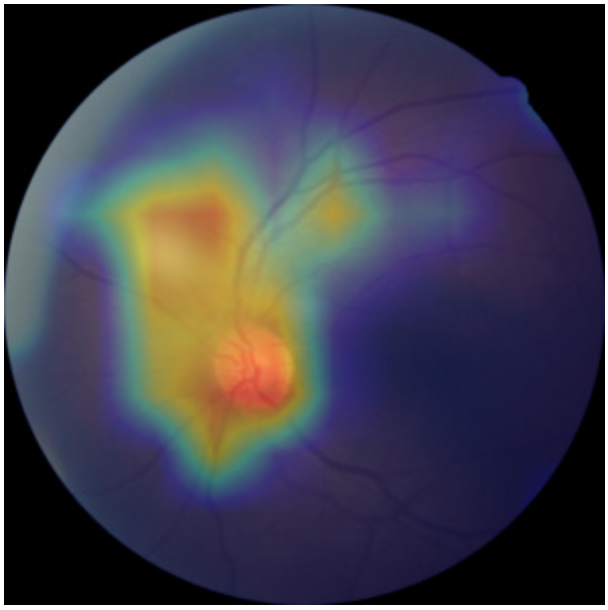

CLINICAL ANALYSIS

CLINICAL RECOMMENDATION

→ Annual screening recommended.

No signs of diabetic retinopathy were detected in this fundus image. Continue standard diabetes management, maintain optimal glycaemic and blood pressure control, and schedule routine annual retinal screening.

CLINICAL NOTES

None recorded

Created by: Dr. Macky

Finalized by: Dr. Macky

Generated: April 27, 2026 01:12 AM

This report is AI-assisted and does not replace the judgment of a licensed eye care professional. All findings must be reviewed and confirmed by a qualified healthcare professional before any clinical action is taken.