# Tutorial BAEP

## Indications

Intraoperative monitoring of auditory function with BAEPs is useful in several surgeries. Removal of acoustic neuromas as well as a number of posterior fossa procedures requires monitoring as hearing loss is a potential complication.
Intraoperative monitoring allows for real-time warning and subsequent correction (if possible) of auditory pathway impairment acquired during surgery. BAEPs can also be used to monitor for hearing restoration, albeit much less frequently.
Lastly, BAEPs are useful in assessing and monitoring the brainstem function intraoperatively. Specifically, changes in wave V during tumor resection or procedures involving the posterior
circulation can signify alter brainstem function [17].

## Notes

BAEPs are useful in sleep or awake states and in infancy through adulthood [1- Mazzali]. Sedation is not problematic and may be preferred in some cases to restrict tension or movement from affecting results. One necessary consideration, however, is that hypothermia may result in BAEP changes similar to those observed in pathological hearing impairment [28]. Anesthesia, drilling, and cerebellar retraction may also affect the recording accuracy, elaborated below. For measurement in children less than 3 years old, special considerations are necessary [29].
Intraoperative monitoring of BAEPs is currently classified by the American Society of Neurophysiological Monitoring as a Guideline, Type C, Class III recommendation for assessing brainstem function in procedures involving the brainstem, assessing brainstem function in procedures involving risk of injury to the posterior circulation, and assessing function of CN VIII in surgeries involving the cerebellopontine angle [17].
Loss of wave V and prolonged latency of ≥1 ms coupled with a wave V amplitude decrease of >50% have been identified as the most predictive of postoperative hearing loss [7].

## Limitations

The effectiveness of monitoring BAEPs is limited by certain factors. Monitoring of BAEPs is unable to completely eliminate hearing loss as an adverse outcome. Certain surgical manipulations, such as injury to a perforator, may result in immediate and irreversible loss of BAEPs. This limits the usefulness of monitoring as damage can occur without the opportunity for correction. Hearing loss may also occur without loss of BAEPs through unknown mechanisms.

# Anatomy/Physiology

Each wave generated in the BAEP corresponds to synapses in various locations along the auditory pathway. The knowledge of auditory pathway anatomy is critical for understanding the generated potentials, and their significance in lesion localization when abnormal findings are present.

The auditory pathway begins in the modiolus of the cochlea. Dendritic processes of the auditory nerve travel from the cochlea through the spiral ganglia to the internal auditory canal. In the temporal bone, the acoustic and vestibular portions merge to form the auditory nerve.

The auditory nerve exits the skull, terminating in either the posterior ventral cochlear nucleus or anterior ventral cochlear nucleus situated on the lateral surface of the inferior cerebellar peduncle in rostral medulla. The auditory pathway fibers synapsing at the posterior ventral cochlear nucleus also connect to the dorsal cochlear nucleus. Once fibers reach the dorsal cochlear nucleus, there are a number of available pathways, but most fibers cross to the contralateral brainstem via the trapezoid body.

Both the medial and lateral superior olivary nuclei in caudal pons receive some fibers, while others travel through the lateral lemniscus to the inferior colliculus. Of note, the superior olivary nucleus on each side receives input from bilateral cochlear nuclei, more so from contralateral cochlear nuclei, and acoustic information is bilaterally represented from this point onwards in the auditory pathway.

The ascending pathway includes synapses at the inferior colliculus, the medial geniculate body of the thalamus, and finally, the primary auditory cortex [17].

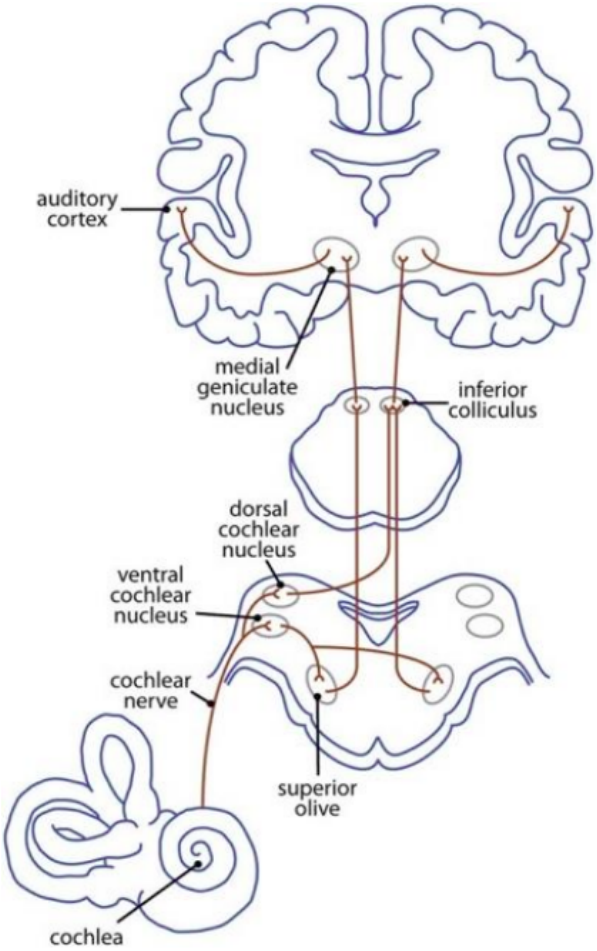

# Anomaly keywords (json file)

1. key : latency increase wave V: Slowly increasing latency of wave complex IV/V is related to a gradually evolving dysfunction at the lateral pons, frequently due to surgical distraction with a consequent reduction of blood flow in that area.
2. key : wave V absence: Conduction block and/or complete activation failure of the lateralized pontine nuclei.
3. key : wave II and V absence: This is most typical of a complete conduction block with the absence of all waves following Wave II: only the ipsilateral cochlear nucleus remains active.
4. key : delayed wave I (or I – II): A delayed activation latency of the first wave and eventual reduction in amplitude signifies high peripheral resistance to acoustic pressure or a pre-existing reduction of ipsilateral auditory function.
5. key : monolateral absence of responses: Absence of activation of the auditory pathway at the peripheral, ipsilateral level.
6. key : bilateral absence of responses: Absence of bilateral activation of the auditory pathway: check the integrity of the stimulation system.

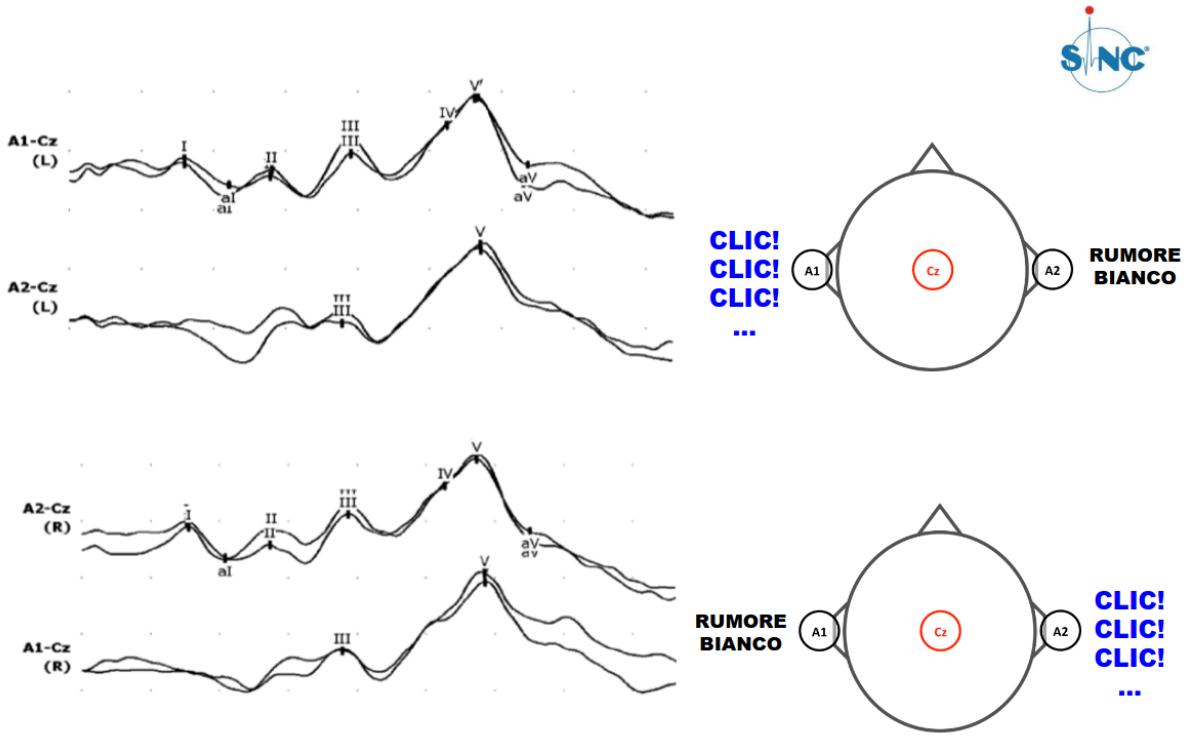

# Bibliography

(1) American Clinical Neurophysiology Society. Guideline 9C: guidelines on short-latency auditory evoked potentials. J Clin Neurophysiol. 2006;23:157.
(7) Park SK, Joo BE, Lee S, Lee JA, Hwang JH, Kong DS, et al. The critical warning sign of realtime brainstem auditory evoked potentials during microvascular decompression for hemifacial spasm. Clin Neurophysiol. 2018;129:1097.
(17) Martin WH, Stecker MM. ASNM position statement: intraoperative monitoring of auditory evoked potentials. J Clin Monit Comput. 2008;22:75.
(28) Markand ON, Lee BI, Warren C, Stoelting RK, King RD, Brown JW, et al. Effects of hypothermia on brainstem auditory evoked potentials in humans. Ann Neurol. 1987;22:507.
(29) Stapells DR. Auditory brainstem response assessment of infants and children. Semin Hear. 1989;10:229.