D-Wave

Direct Wave from spinal cord

The Spinal D-Wave (Direct Wave) is a motor evoked potential (MEP) recorded directly from the spinal cord surface[1]. It corresponds to the **compound action potential** resulting from the **direct** and **asynaptic** activation of the axons of the rapid-conduction corticospinal tract (CST)[2].

Generation and Distinction from I-Waves

The D-Wave is evoked via **Transcranial Electrical Stimulation (TES)** by applying a **single electrical pulse** to the motor cortex[3]. This high-intensity current impulse is capable of bypassing the cell body (soma) of the cortical motor neuron and directly activating the axon at the initial segment or the Node of Ranvier, generating an action potential that propagates orthodromically along the pyramidal tract[4].
In an awake subject, TES generates a series of **descending volleys**: the initial D-Wave is followed by a series of **I-Waves** (Indirect Waves)[5]. I-Waves are generated **trans-synaptically** through the activation of chains of vertically oriented excitatory interneurons in the motor cortex, which, in turn, activate the soma of the cortical motor neuron[6].

Critical Impact of Anesthesia

General anesthesia, particularly inhalational agents and many intravenous agents, exerts a potent suppressive effect on synaptic transmission at the cortical level[7]. This anesthetic effect effectively blocks the generation of I-Waves, which depend on multiple cortical synapses[8].
Conversely, the **D-Wave**, being the result of **direct** and **asynaptic** axonal activation, is not significantly influenced by common anesthetic protocols[9]. This pharmacological resistance makes it ideal for intraoperative monitoring.
While other potentials, such as Somatosensory Evoked Potentials (SSEPs) [10]or muscle motor evoked potentials (m-MEPs) [11], are notably sensitive to variations in anesthetic depth, the D-Wave provides a **stable baseline**[12].
This stability ensures that a change in the potential (e.g., a decrease in amplitude) can be attributed with high confidence to a surgical event (e.g., compression or mechanical damage to the spinal cord) rather than a pharmacological variation[13].

Axonal Integrity and Motor Function

The D-Wave does not measure **motor function** as a whole, but rather the **axonal integrity** of the corticospinal tract[14].

By not involving cortical synapses (I-Waves) or spinal synapses, the D-Wave answers a very specific and critical question for the surgeon: *"Are the CST axons physically and electrically continuous between the motor cortex and the recording point caudal to the lesion?"*[15].
This specificity constitutes its unique prognostic value[16].

Morphological Characteristics

The D-Wave is recorded in the epidural space via electrodes positioned by the surgeon, sometimes referred to as spinal catheters, though they are electrodes that conduct a signal to the neurophysiological amplification system[17].

Morphology and Latency

The D-Wave typically presents a triphasic morphology18, of which the onset latency and amplitude are measured.
The latency is a measure of conduction time 19 and is strictly dependent on the distance between the stimulation site (cortex) and the recording site (spinal electrode).

- **Cervical Recording:** Peak latency is typically between 3 and 6 ms[20].
- **Thoracic Recording:** Peak latency increases to approximately 6-9 ms[21].

These values are consistent with a conduction velocity in the fastest axons of the corticospinal tract (CST) of approximately 50 m/s[22].

Amplitude and Anatomical Correlation

The **amplitude** is a measure of signal power [23]and is clinically more significant, though more variable: the amplitude of the D-Wave is directly correlated to the **number of activated CST axons**[24]. This parameter shows a clear dependence on the recording level:

- **Cervical Recording:** Amplitude can reach 60 μV or more[25].
  Thoracic Recording: Amplitude is notably lower, often in the order of 10 μV[26].

This drastic reduction in amplitude between the cervical and thoracic levels is correlated with neuroaxonal anatomy27.
The corticospinal tract yields fibers (axons) at every segmental level to innervate motor neurons (e.g., for the upper limbs at the cervical level)28.
A high cervical recording captures the aggregate potential of nearly the entire tract, whereas a thoracic recording captures only the potential remaining after the fibers for the upper limbs have left the CST29.
This anatomical reduction in amplitude is also the foundation of the most significant limitation of D-Wave monitoring: the impossibility of recording it below the **T12/L1 level**[30]. At this level, the number of remaining corticospinal fibers (directed to the sacral segments) is insufficient to generate a potential distinguishable from background noise[31].

The Effect of Pathology: Desynchronization

The presence of spinal lesions, particularly **Intramedullary Spinal Cord Tumors (IMSCT)**, profoundly alters the D-Wave profile. In these patients, a decrease in amplitude and an increase in D-Wave latency are often observed[32]. This phenomenon is the result of potential desynchronization[33].

In a healthy spinal cord, a single stimulus generates a synchronous wavefront traveling at a uniform speed along the corticospinal tract fibers34.

A tumor compresses axons non-uniformly, causing partial demyelination and varying degrees of axonal damage (partial conduction block)35.

Consequently, healthy fibers conduct rapidly, while damaged ones conduct slowly, causing the originally synchronous wavefront to arrive at the recording electrode "smeared" over time[36].

This **temporal dispersion** drastically reduces the peak amplitude (since currents no longer summate temporally or in phase) and can render the baseline D-Wave low-amplitude and widened or, in severe cases, completely absent caudal to the lesion.37.

Intraoperative Stimulation and Acquisition Protocols

Stimulation Technique

Stimulation is performed via **TES** [38], using the **single-pulse** technique to isolate the D-Wave[39]. This contrasts with the **train-of-stimuli** technique required to evoke m-MEPs[40]. Stimulation parameters are optimized for axonal activation, with a stimulus duration typically of 500 μs[41]. Intensity is increased to a supramaximal level to recruit the greatest possible number of CST axons and maximize signal amplitude[42].

Recording Technique

Recording occurs via flexible electrodes, typically catheters, inserted into the epidural space [43], though they can equally be positioned in the subdural or intrathecal space [44]; epidural placement is the most common[45].
Placement is of fundamental importance:

- **Caudal Electrode:** The active recording electrode is positioned **caudally** to the surgical level[46]. This is essential for monitoring signal passage through the spinal cord segment at risk.
- **Rostral Electrode:** As emphasized by the American Society of Neurophysiological Monitoring (ASNM), placing a control electrode **rostrally** (above) the lesion is of "invaluable value"[47].

If the D-Wave disappears only on the caudal electrode but remains stable on the rostral one, this confirms that the signal is generated correctly but is blocked at the surgical site (a true emergency)48.
If the D-Wave disappears on both electrodes, this indicates a technical problem (e.g., stimulator, displaced stimulation electrodes) or a systemic/pharmacological issue, preventing a false surgical alarm49.

Acquisition and Real-Time Feedback

A distinctive feature of the D-Wave is its **rapid acquisition**[50]. Unlike potentials requiring extensive **averaging** (averaging hundreds of responses), the D-Wave has a sufficiently large amplitude [51]to be clearly visible without averaging, or at most with an average of 2-4 responses[52].
This allows for **almost instantaneous feedback** (updates every 1-2 seconds)[53]. The surgeon can correlate specific surgical acts (e.g., a dissection maneuver) with an immediate neurophysiological result, enabling guided resection and functional mapping of spinal tracts[54].
However, the electrode's position in the surgical field makes it susceptible to artifacts from manipulation (e.g., irrigation or application of instrumentation)[55]. Furthermore, in cases of

previous surgeries, scar tissue may complicate optimal electrode placement[56].

Clinical Applications

Intramedullary Spinal Cord Tumor Surgery (IMSCT)

The primary and undisputed application of the D-Wave is in **IMSCT surgery**[57]. Consensus from scientific societies such as the International Society of Intraoperative Neurophysiology (ISIN) considers D-Wave monitoring "mandatory" in this surgical context[58].
The rationale lies in the injury mechanism: in an extramedullary tumor (compressing the cord from the outside), the main risk is often ischemia, which is well detected by m-MEPs [59]; in an intramedullary tumor (e.g., ependymoma, astrocytoma), the surgeon must dissect **inside** the spinal parenchyma[60]. The main risk here is not (only) ischemia, but the **direct mechanical transection** of CST axons.
The D-Wave, as a direct measure of axonal integrity, is the only tool capable of reliably protecting against this type of irreversible damage61.
Its use is proven to improve long-term functional outcomes in these patients62.

Other Applications and "Compromised" Patients

Although mandatory for IMSCT, the D-Wave is also useful in selected cases of intradural extramedullary tumors, surgery for syringomyelia, and other myelopathies[63].
A critical clinical application is in **"compromised" patients**, such as those with severe chronic myelopathy presenting with significant motor deficits[64]. In these patients, m-MEPs (which depend on the excitability of the spinal alpha motor neuron pool [65]) may be absent or poorly defined even at baseline.
In this scenario, the D-Wave, being a direct and more robust axonal potential, can often still be recorded[66]. It thus becomes the **only motor monitoring tool available** to guide the surgery[67].

The Prognostic Value of the D-Wave

The most significant contribution of the D-Wave in IOM lies in its **prognostic value**[68].

The Strongest Predictor of Long-Term Outcome

Numerous studies and reviews agree that the D-Wave is the strongest and most accurate predictor of corticospinal tract integrity and long-term motor function69.
In this regard, it is distinctly different from m-MEPs. m-MEPs are excellent predictors of motor function immediately after surgery70.
The D-Wave, conversely, predicts long-term functional outcome, i.e., the patient's recovery potential in the following months71.

Surgical Implications

This distinction leads to a clinical "paradox" that is key to understanding the utility of the D-Wave: the presence of a stable and persistent caudal D-Wave is predictive of a good long-term motor outcome, even if m-MEPs are lost during surgery and the patient wakes up with a significant motor deficit[72].
This initially counterintuitive scenario reflects the different pathways monitored. The loss of m-MEPs may be caused by a **functional** and **transient** dysfunction (e.g., local ischemia, edema, metabolic "spinal shock") that silences the excitability of spinal alpha motor neurons[73]. However, if the D-Wave remains stable, it **proves** that the structural integrity of the CST axons is intact[74].
The post-operative motor deficit (predicted by m-MEPs) will therefore be transient, and the patient has a high potential for recovery (predicted by the D-Wave)[75].
This awareness has redefined the surgical objective. Before the D-Wave, a loss of m-MEPs would have meant the immediate cessation of the procedure76.
Now, the preservation of the D-Wave authorizes the surgeon to continue and complete the tumor resection, despite the loss of m-MEPs77. Essentially, the D-Wave allows the surgeon to accept a transient post-operative deficit in exchange for a more complete and potentially curative oncological resection, drastically improving overall outcomes78.

D-Wave versus Muscle Motor Evoked Potentials (m-MEPs)

The D-Wave and m-MEPs are not complementary techniques; multimodal monitoring including both (along with SSEPs for dorsal columns) represents the standard[79].
The technical necessity of a train of stimuli for m-MEPs 80compared to a single pulse for the D-Wave 81 is the manifestation of their different physiology.
A single pulse is not sufficient to depolarize a spinal alpha motor neuron in a patient under general anesthesia82.
A train of pulses is necessary to achieve temporal summation of excitatory post-synaptic potentials (EPSP) that brings the spinal motor neuron to threshold83.

This proves that the m-MEP is a measure of spinal synaptic excitability84.
The D-Wave, evoked by a single pulse, is a pure measure of axonal conduction85.
The following table summarizes the critical differences for intraoperative decision-making.

Table 1: Neurophysiological and Clinical Comparison between D-Wave and m-MEP Monitoring [86]

Feature	Spinal D-Wave	m-MEPs (Muscular)	Sources
Generation	Direct, Asynaptic	Indirect, Polysynaptic	[87]
Monitored Pathway	Only fast-conducting CST axons	Entire motor pathway (cortex, CST, alpha motor neuron, nerve, muscle)	[88]
Stimulation	Single Pulse TES	Train of Stimuli TES	[89]
Recording Site	Spinal epidural (cable)	Peripheral muscles (EMG)	[90]
Anesthesia Sens.	Very low / Robust	Very high (requires TIVA)	[91]
Averaging Need	No (or 2-4 traces)	Yes (but rapid)	[92]
Feedback	Real-time (1-2 sec)	Real-time (few sec)	[93]
Prognostic Value	**Long-Term** Outcome (strongest predictor)	**Immediate** Post-Op Outcome	[94]
Laterality	No (aggregated signal)	Yes (specific for muscle/side)	[95]
Warning Criterion	Amplitude Reduction >50% (IMSCT)	Disappearance / Amp. Red. >50% / Threshold Increase	[96]

Advantages and Limitations of the D-Wave

Despite its notable advantages, the D-Wave presents specific limitations that must be understood for safe use[97].

Advantages (Summary)

- **Superior Prognostic Value:** It is the most reliable predictor of long-term motor outcome[98].
- **Anesthetic Robustness:** Almost insensitive to anesthetic agents, providing a stable baseline[99].
- **Real-Time Feedback:** Rapid acquisition without the need for averaging allows for immediate surgical guidance[100].

Specificity: Specifically isolates the function of fast-conducting CST axons[101]. Limitations and Disadvantages

- **Anatomical Limit (T12):** It is not recordable below the T12/L1 level due to the paucity of CST fibers[102]. This makes it unusable for conus medullaris or cauda equina surgery.
- **Pediatric Limit:** The D-Wave is not usable in small children (generally under 4 years)[103]. This limit is a direct consequence of developmental neurobiology: the CST requires **fast, myelinated fibers**[104]. CST myelination is incomplete in the first years of life, preventing the synchronous and fast conduction necessary to generate a recordable wave.
- **Absence of Laterality:** This is a critical limitation. The epidurally recorded D-Wave is an **aggregated** (midline) field potential[105]. It cannot distinguish between damage to the right or left CST[106]. This is the main reason why the D-Wave must never be used alone.
- **m-MEPs**, recorded from specific muscles (e.g., right vs. left Tibialis Anterior), are essential to provide the missing laterality information[107].
- **Pathological Limits:** In the presence of very large tumors or severe chronic lesions causing extreme desynchronization, the baseline D-Wave may be of very low amplitude or completely absent, rendering monitoring impossible[108].

Guidelines (ISIN, ASNM)

The combined interpretation of D-Wave and m-MEPs is codified in decision-making algorithms and warning criteria established by international scientific societies[109].

Warning Criteria

- **D-Wave:** For intramedullary tumor surgery, the primary warning criterion is an **amplitude reduction >50%** compared to the baseline value, not explained by technical factors[110]. This 50% cutoff is not arbitrary; it is an empirically derived prognostic turning point[111]. Since amplitude is correlated with the number of axons [112], clinical studies have identified a loss >50% as the point beyond which the probability of a **permanent** and severe motor deficit becomes unacceptably high[113].
- **m-MEPs:** Disappearance (absence) is always a major criterion[114]. Minor criteria include marked amplitude reduction (e.g., >50%) or an increase in stimulation threshold[115].

Intraoperative Decision-Making Algorithm

The interaction between these two signals defines the clinical decision-making algorithm, which formally codifies the "prognostic paradox"[116]. Guidelines [117] instruct the team to hierarchically trust the D-Wave as the final indicator of CST integrity.

Scenario 1: "Yellow" Alarm (m-MEPs Absent + D-Wave Stable)

- **Signals:** m-MEPs attenuated or absent; D-Wave stable (reduction <50%)[118].

- **Interpretation:** Transient functional dysfunction (spinal shock, mild ischemia)[119]. Structural integrity of the CST is preserved.
- **Action:** Surgical pause, irrigation with warm solution, correction of vital parameters (e.g., increase blood pressure)[120]. The surgeon **can proceed** with resection, even if m-MEPs do not recover, trusting the stable D-Wave[121].

Scenario 2: "Red" Alarm (m-MEPs Absent + D-Wave Unstable)

- **Signals:** m-MEPs absent; D-Wave unstable (reduction >50%)[122].
- **Interpretation:** Severe and permanent structural damage to the CST[123].
- **Action: Immediate stop** of the procedure[124]. Pause to allow recovery. If the D-Wave does not recover, abandoning the procedure must be seriously considered to avoid permanent paraplegia[125].

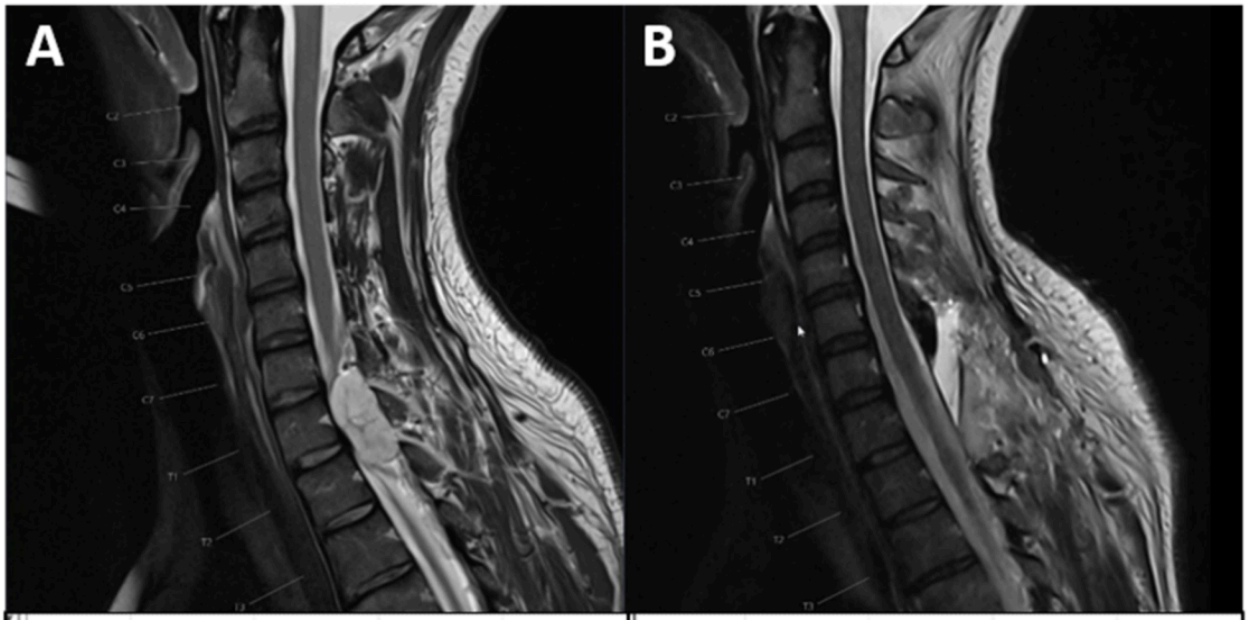

The figure illustrates pre-operative and post-operative MRI with complete removal of the lesion. [126]

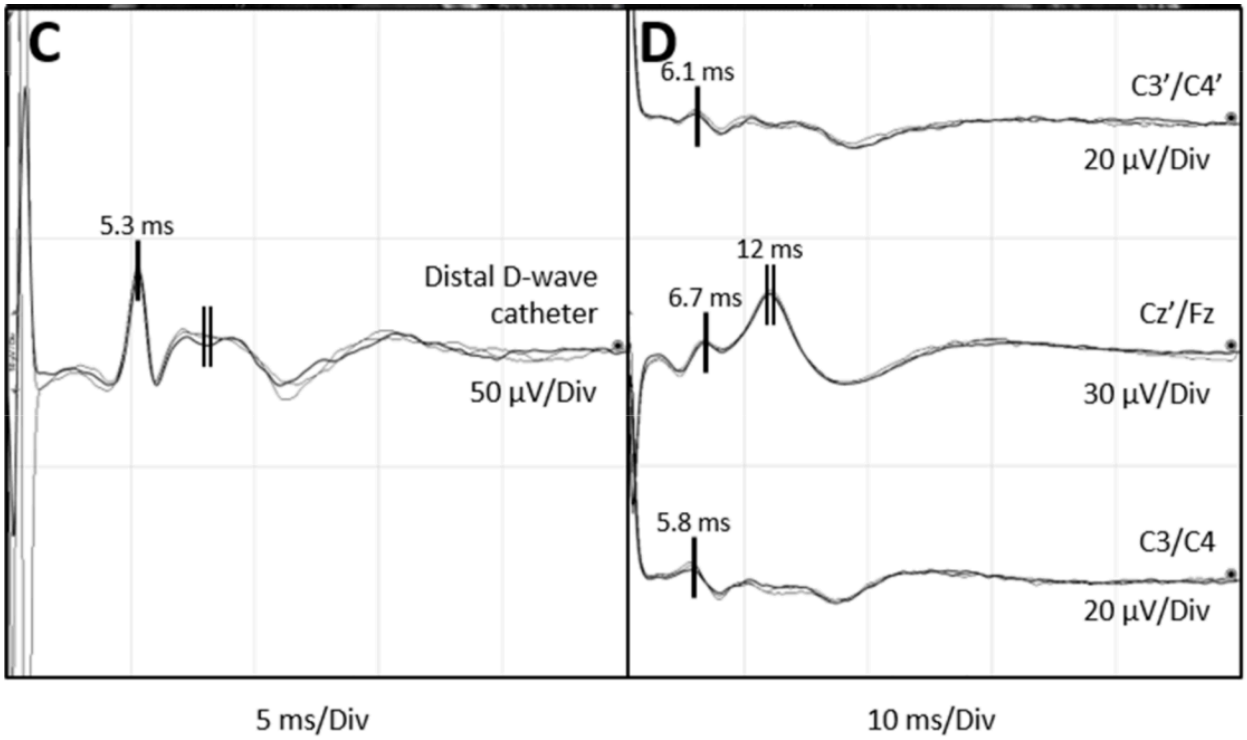

In the figure: intraoperative D-wave recording distal to the tumour site at the level of Th2–Th5 during tumor removal. The D-wave is characterized by a short-latency triphasic wave: peak

latency = 5.3 ms, amplitude = 24.7 μV. Note the later artefact of lower amplitude and longer duration caused by paraspinal muscles (double line marker). It should not be mistaken as a D-wave. In the left panel, the anti-D-wave recording illustrating a short latency potential with a peak latency ranging from 5.8 ms to 6.7 ms, depending on the recording channel (vertical line marker), followed by a higher amplitude and longer duration potential with a peak latency of 12 ms observed in the channel Cz'/Fz (double vertical line marker). This later potential corresponds to the somatosensory evoked response. Recordings were obtained at C3'/C4', Cz'/Fz and C3/C4 of the 10/20 International System. In C3/C4, corresponding to the montage over the motor cortex, the anti-D-wave (representing the antidromic activity of the CST) reaches its highest amplitude (1.8 μV). The highest amplitude of the somatosensory response is recorded in the sagittal montage Cz'/Fz (midline, frontoparietal). 127

The Anti D-Wave

Since 1986, many authors have applied electrical stimulation of the spinal cord to record signals on the scalp; these are called spinal cord evoked potentials (ScEPs)[128]. Two distinct categories of evoked potentials have been identified: an early potential and a late potential[129].

Interestingly, most researchers have focused their investigations on the potential with the longer latency, corresponding to the evoked electrical activity originating from the dorsal columns[130]. However, an intriguing hypothesis was that the early component might be linked to the CST[131].
The result was an early potential identified as the "anti D-wave", presumed to be non-synaptic in nature, as evidenced by its resistance to stimulation at very high rates132.
This wave, characterized by a triphasic pattern, exhibits a marginally longer latency compared to the D-wave within the same patient (0.8 ± 0.48 ms)133.
This discrepancy is likely attributable to a deeper activation of the CST when the D-wave is elicited via TES from the scalp134.
Furthermore, the observed latency shift between the D-wave and the anti D-wave aligns with the hypothesis suggesting that the anti D-wave is generated by the CST135.
The features of the anti D-wave exhibit a close correlation with those of the D-wave, particularly concerning its distribution, response to filtering, stimulus rate, and absence in paraplegic patients136.
However, further studies are necessary to evaluate the usefulness of the anti D-wave as a monitoring method137.

Synthesis

The **Spinal D-Wave** represents a cornerstone in the evolution of intraoperative neurophysiological monitoring[138]. Its unique combination of anesthetic robustness, asynaptic generation, and superior prognostic value for long-term motor outcome [139]has made it an essential and mandatory tool for intramedullary tumor surgery[140]. By allowing surgeons to

distinguish between transient functional damage and permanent structural injury, the D-Wave has significantly improved both patient safety and oncological results, enabling more aggressive and safer resections[141].

The future of spinal monitoring lies in the **multimodal approach**: the D-Wave provides assessment of axonal integrity, m-MEPs provide sensitivity to laterality and ischemia, and SSEPs monitor dorsal column integrity[142]. The refinement of CST mapping techniques [143]and the development of new paradigms, such as the emerging concept of "anti D-wave"[144], will continue to enhance the ability to protect the spinal cord during complex surgical procedures.

Bibliografia

1. Basic methodological principles of multimodal intraoperative ... - NIH, ' 'https://pmc.ncbi.nlm.nih.gov/articles/PMC2072896/
2. A Concise Guide to D-Wave Monitoring during Intramedullary Spinal ..., ' 'https://www.mdpi.com/1648-9144/60/8/1242
3. Monitoraggio Neurofisiologico Intraoperatorio in Neurochirurgia, ' 'https://www.sinc-italia.it/pdf/DOCUMENTO_INTERSOCIETARIO_IOM_2016.pdf
4. Intraoperative motor evoked potential monitoring â€“ A position statement by the American Society of Neurophysiological Mon, ' 'https://asnm.org/wp-content/uploads/2023/05/Intraoperative_Motor_Evoked_.pdf
5. Intraoperative neurophysiological monitoring of the spinal cord ..., ' 'https://pubmed.ncbi.nlm.nih.gov/18053764/
6. A Concise Guide to D-Wave Monitoring during Intramedullary Spinal Cord Tumour Surgery - PMC - PubMed Central, ' 'https://pmc.ncbi.nlm.nih.gov/articles/PMC11356140/
7. (PDF) A Concise Guide to D-Wave Monitoring during Intramedullary Spinal Cord Tumour Surgery - ResearchGate, ' 'https://www.researchgate.net/publication/382710907_A_Concise_Guide_to_D-Wave_Monitoring_during_Intramedullary_Spinal_Cord_Tumour_Surgery
8. Intraoperative neurophysiological monitoring in spinal surgery - Baishideng Publishing Group, ' 'https://www.wjgnet.com/2307-8960/full/v3/i9/765.htm
9. Relevance of intraoperative D wave in spine and spinal cord ... - NIH, ' 'https://pmc.ncbi.nlm.nih.gov/articles/PMC3631052/
10. D waves during spinal cord tumor surgery - ASNM, ' 'https://asnm.org/d-waves-during-spinal-cord-tumor-surgery/
11. Current opinions and recommendations on multimodal intraoperative monitoring during spine surgeries - PMC - NIH, ' 'https://pmc.ncbi.nlm.nih.gov/articles/PMC2072891/
12. Direct Wave Intraoperative Neuromonitoring for Spinal Tumor Resection: A Focused Review - PMC - PubMed Central, ' 'https://pmc.ncbi.nlm.nih.gov/articles/PMC9547300/
13. 11 TELENEUROFISIOLOGIA INTRAOPERATORIA DELL'ADULTO E DEL BAMBINO 11.1 Principi generali di IOM in telemedicina, ' 'https://publ.iss.it/ITA/Items/GetPDF?uuid=0f186c0d-5830-4b52-a0a1-19b76da16224