Electrocorticography

Platinum electrocorticography (ECoG) electrode arrays were configured as linear strips or grids, and embedded in silastic with 1cm spacing (4mm diameter with 2.3mm exposed). They were placed

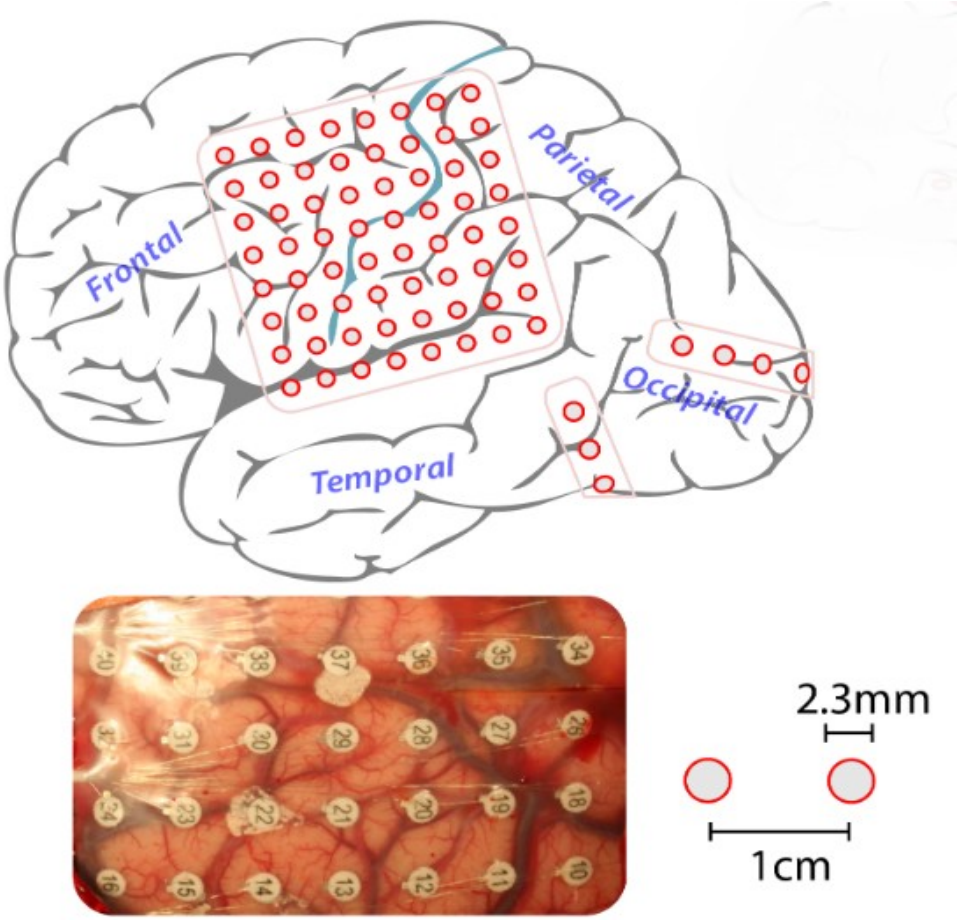

along the subdural space via open craniotomies.
We performed a comparison of the LOC method with intra-operative figures to show correspondence. A photograph taken before placement of a subdural grid array is used to identify brain sulcal landmarks.

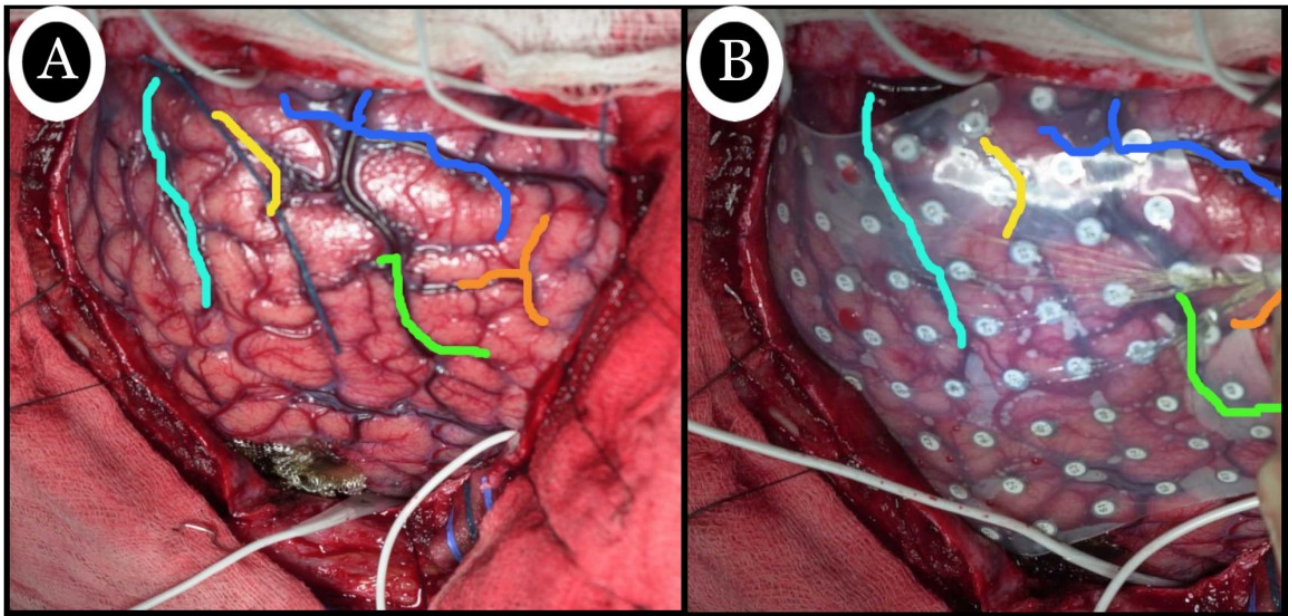

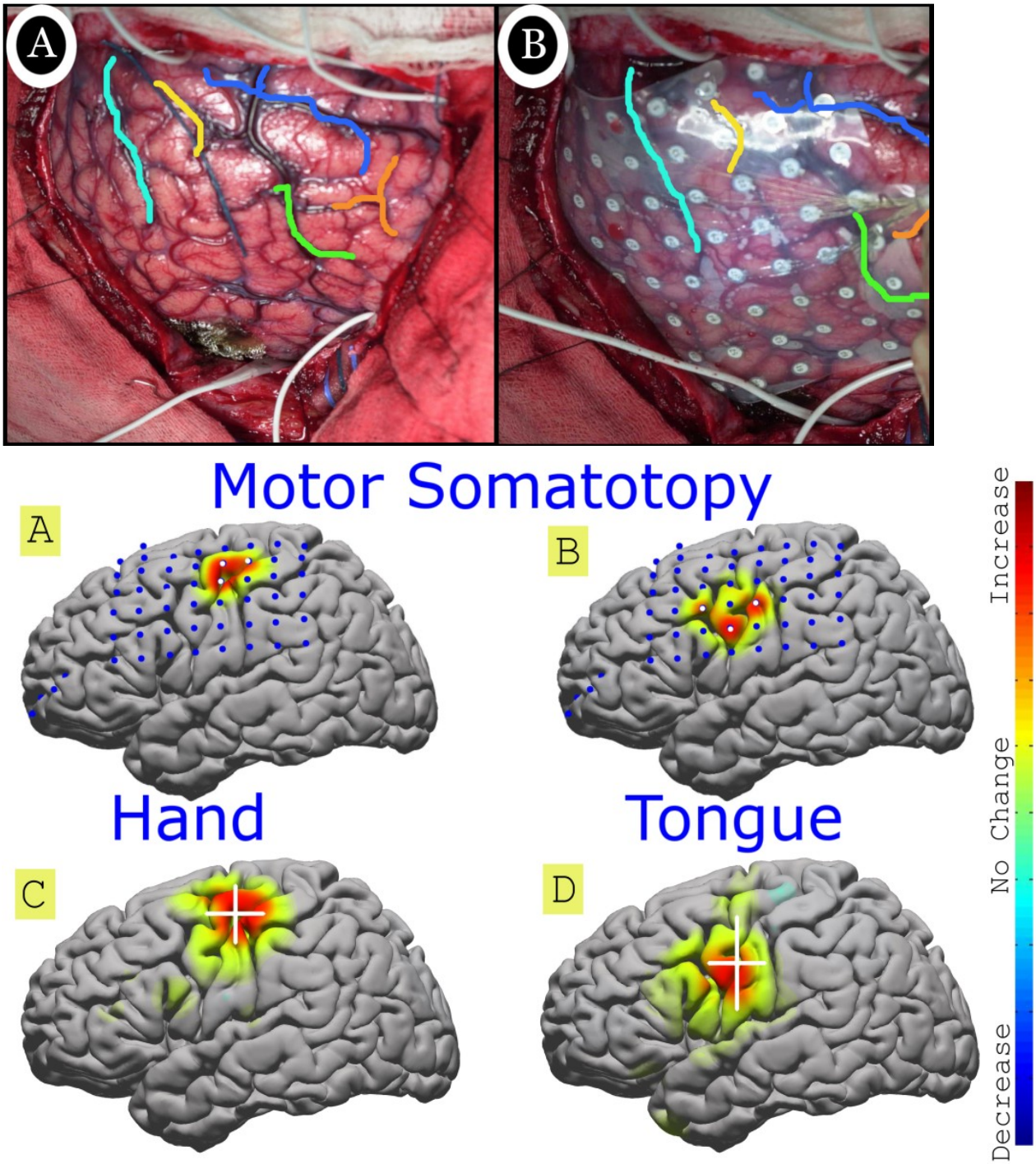

In the figure, the reconstruction of the cortical distribution of field intensity relative to the somatotopic localization of the motor activity of the hand and the tongue is observed.

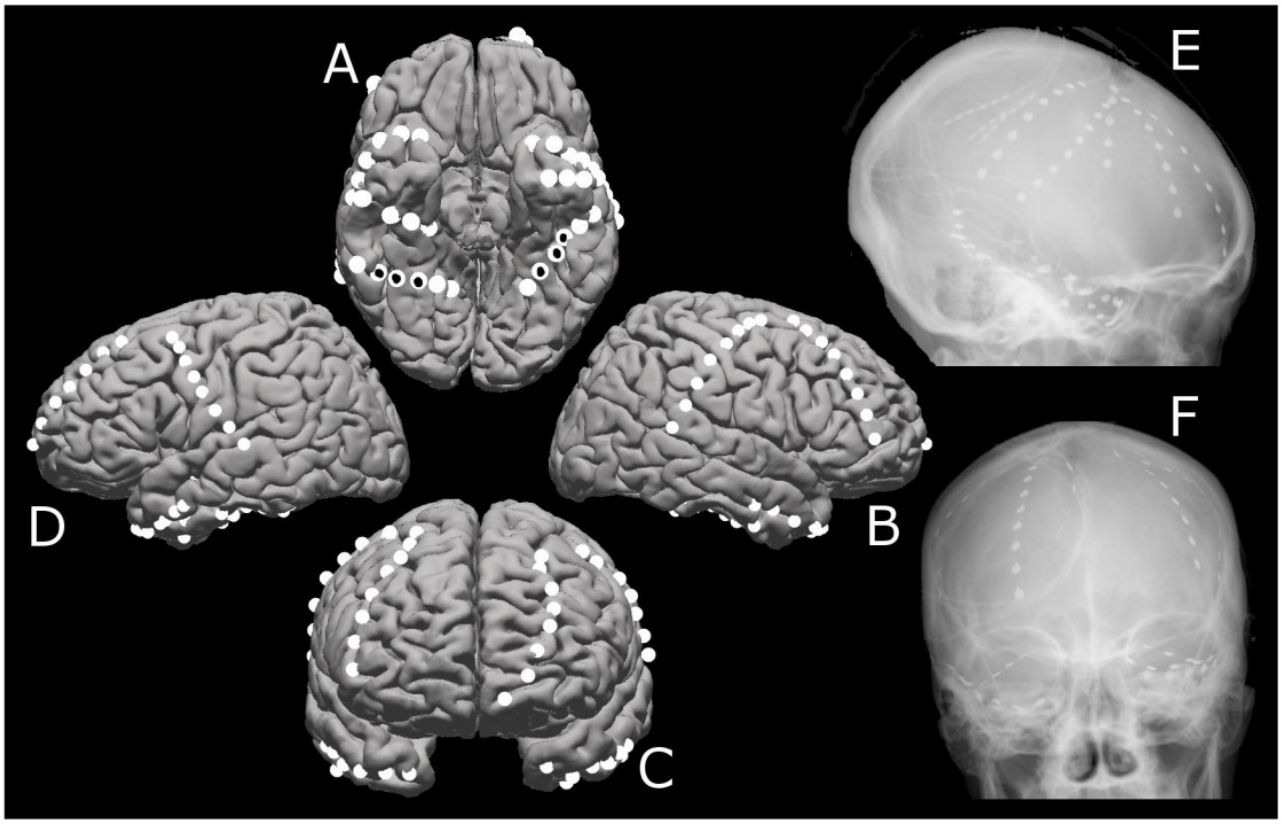

Arrangement of linear electrode strings on various cortical areas of interest.
Once the subdural electrodes have been placed via craniotomy, the patient proceeds to the preoperative testing phases.
These consist of evaluating the spontaneous corticographic electrical activity, which in itself can be highly informative regarding the interictal epileptogenic activity in active epileptic foci.
Various tests are performed to activate motor and sensory functions (movements of the hand, foot, and tongue), which allow for sub-centimeter mapping of the competent location at the cortical level.
Regarding language, 'production' and 'comprehension' tests are performed through the presentation of various simplified neuropsychological assessments, which may nonetheless involve both a verbal and a motor response from the patient.
Tutte queste informazioni sono utilizzate dal team chirurgico per pianificare l’intervento.