# MEP

Parametri di stimolazione e registrazione per MEP intraoperatorio

**▶ TABLE 35–2. STIMULATION AND RECORDING PARAMETERS**

| | | TcMEP | | dcMEP |
|---|---|---|---|---|
| Stimulation Parameters | Stimulating electrode | Corkscrew, needle transcranial | | Subdural grid/probe |
| | Stimulation type | Constant voltage (or current) | | Constant voltage (or current) |
| | Pulse phase | Monophasic | | Mono or biphasic |
| | Stimulation rate | 250–500 Hz | | 250–500 Hz |
| | Pulse width | 50–500 µs | | 500 µs |
| | Intensity | 100–800 V | | <100 V (up to 20 mA) |
| | Number of pulses | 5–7 | 1 | 3–6 |
| | Intertrain interval/freq | 10–35 ms[a] | n/a | 0.5–2 Hz |
| Recording Parameters | Recording site | Muscle (CMAP[b]) | Spinal cord (D wave) | Muscle (CMAP[b]) |
| | Low-frequency filter | 30 Hz | 1.5 Hz | 100 Hz |
| | High-frequency filter | 3000 Hz | 1700 Hz | 500 Hz |
| | Average | One | Few | Few |
| | Time base (epoch) | 50–100 ms | 20 ms | 50–100 ms |

Commonly used stimulation parameters for transcranial and direct current motor evoked potentials.
[a]Intertrain interval for TcMEP is occasionally used as a spatial facilitation technique to improve myogenic signals.
[b]CMAP: Compound muscle action potential.

**▶ TABLE 35–1. MUSCLES COMMONLY USED IN INTRAOPERATIVE NEUROMONITORING**

| Muscle | Nerve | Roots | | | | | | | | | | | | | |
|---|---|---|---|---|---|---|---|---|---|---|---|---|---|---|---|
| | | C3 | C4 | C5 | C6 | C7 | C8 | T1 | T6–12 | L2 | L3 | L4 | L5 | S1 | S2–S4 |
| Trapezius | CN XI | ■ | ■ | | | | | | | | | | | | |
| Deltoid | Axillary | | | ■ | ▒ | | | | | | | | | | |
| Biceps brachii | Musculocutaneous | | | ■ | ■ | | | | | | | | | | |
| Triceps | Radial | | | | ■ | ■ | | | | | | | | | |
| Abductor pollicis brevis | Median | | | | | | ▒ | ■ | | | | | | | |
| Abductor digiti minimi | Ulnar | | | | | | ■ | ▒ | | | | | | | |
| Adductor pollicis | Ulnar | | | | | | ■ | ▒ | | | | | | | |
| First dorsal interosseus | Ulnar | | | | | | ■ | ▒ | | | | | | | |
| External oblique | | | | | | | | | ■ | | | | | | |
| Rectus abdominis | | | | | | | | | ■ | | | | | | |
| Iliacus | Lumbar plexus | | | | | | | | | ■ | ■ | ▒ | | | |
| Vastus lateralis/medialis | Femoral | | | | | | | | | ▒ | ■ | ■ | | | |
| Rectus femoris | Femoral | | | | | | | | | ▒ | ■ | ■ | | | |
| Semitendinosus/ membranosus | Sciatic | | | | | | | | | | | ▒ | ■ | ▒ | |
| Tibialis anterior | Peroneal | | | | | | | | | | | ■ | ■ | | |
| Extensor halluces | Peroneal | | | | | | | | | | | | ■ | ▒ | |
| Extensor digitorum brevis | Peroneal | | | | | | | | | | | | ■ | ▒ | |
| Gastrocnemius lateral | Tibial | | | | | | | | | | | | ▒ | ■ | |
| Gastrocnemius medial | Tibial | | | | | | | | | | | | | ■ | ▒ |
| Abductor halluces | Tibial | | | | | | | | | | | | | ■ | ■ |
| External anal sphincter | Pudendal | | | | | | | | | | | | | | ■ |
| External urethral sphincter | Pudendal | | | | | | | | | | | | | | ■ |

*Note:* Muscle groups are selected based on the area at risk during surgery. Typically, at least one muscle group is selected above the area at risk to serve as a control. Control muscle groups generally help provide information about adequacy of stimulation, anesthetic or systemic effects.

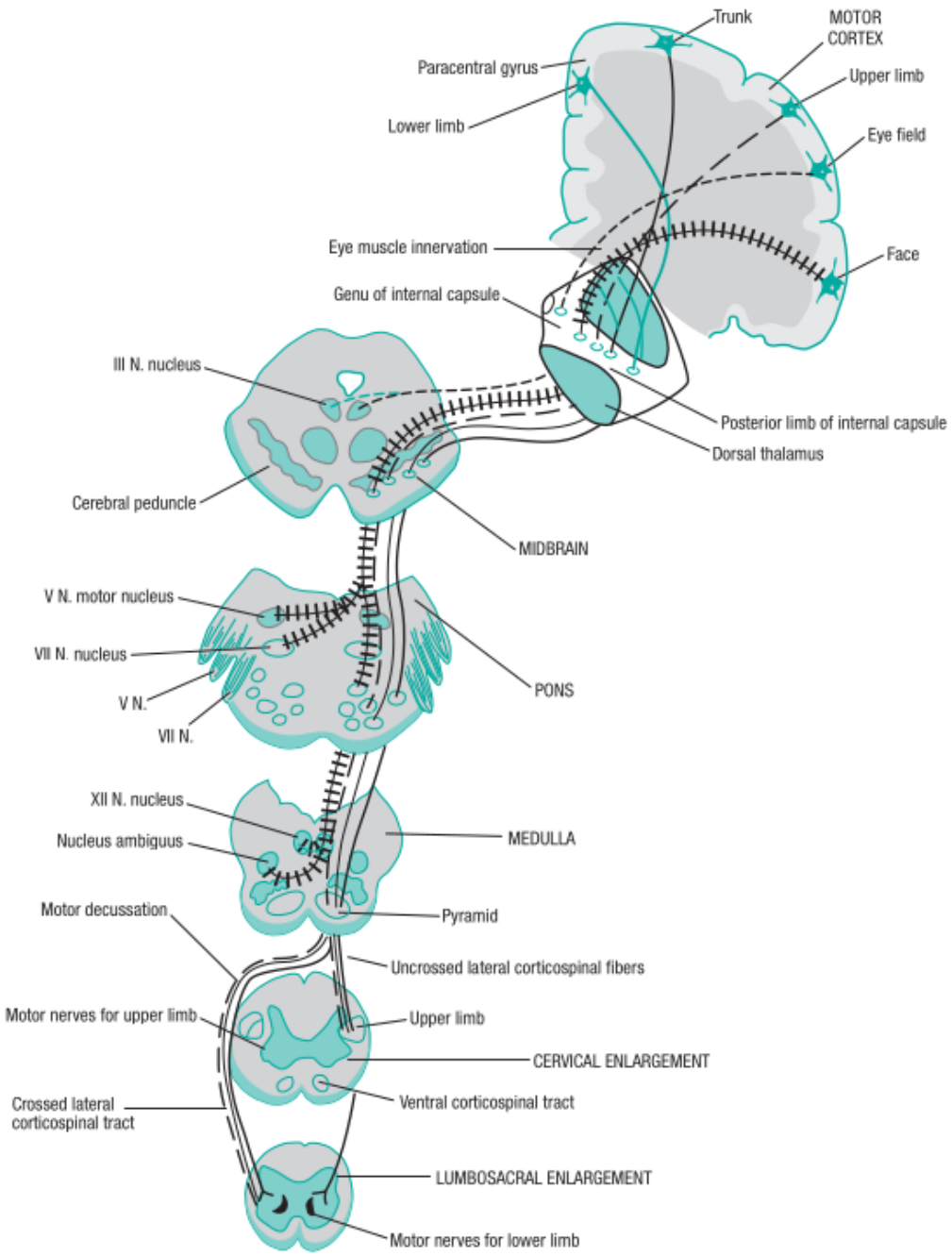


**Figure 35–1.** Depiction of the anatomical course of the corticospinal and corticobulbar tracts. (Reproduced with permission from Ropper A, Brown R, *Adams and Victor's Principles of Neurology*, 9th Edition. Available at http://www.accessmedicine.com. Copyright © McGraw-Hill Education. All rights reserved.)

Via cortico spinale e cortico bulbare.