MEDICAL RECORD — CONSULTATION SHEET

REQUEST

TO:	FROM: (Requesting physician or agency)	DATE OF REQUEST
PULMONARY	HOURI, GOLO	11/3/97

REASON FOR REQUEST (Complaints and findings)

64 y/o Recent CT chest shd RLL subpleural irregular nodule 2° to scarring or malignancy please advise as to further evaluation. (He has had prior CTs from an outside hospital which I will attempt to obtain)

PROVISIONAL DIAGNOSIS

RLL nodule

DOCTOR'S SIGNATURE	APPROVED	PLACE OF CONSULTATION	
[signature]		☐ BEDSIDE ☐ ON CALL	☐ ROUTINE ☐ TODAY ☐ 72 HOURS ☐ EMERGENCY

CONSULTATION REPORT

(Continued on reverse side)

SIGNATURE AND TITLE			DATE
IDENTIFICATION NO	**ORGANIZATION**	**REGISTER NO**	**WARD NO**

PATIENT'S IDENTIFICATION (For typed or written entries give Name—last, first, middle; grade; rank; race; hospital or medical facility)

DANKOJR, PAUL

169-26-7266

CONSULTATION SHEET
STANDARD FORM 513 (Rev. 9-77)
Prescribed by GSA/ICMR
FIRMR (41 CFR) 201-45.505
513-106

96741564

Source: https://www.industrydocuments.ucsf.edu/docs/gqgg0072

PULMONARY [redacted] is performed only by prior appro[redacted]

MEDICAL RECORD | **CONSULTATION SHEET** 12/26/11

REQUEST

TO: PULMONARY LABORATORY

FROM: [redacted]

DATE OF REQUEST

REASON FOR REQUEST: PULMONARY FUNCTION STUDY REQUEST

PATIENT INFORMATION

1. Chest X-ray: NEG ( ) INFILTRATE ( )
2. Using supplemental oxygen ( ) Yes ( ) No
3. If Pre-op, indicate date _____
4. PULMONARY DIAGNOSIS:
5. History of occupational exposure:

Hb: (If diffusing Capacity desired)

TESTS REQUESTED

- (✓) SPIROMETRY (FV LOOP, FVC, FEV_1, FEV_1/FVC RATIO)
- ( ) LUNG VOLUMES (RESTRICTION SUSPECTED
- (✓) DIFFUSING CAPACITY
- ( ) BRONCHODILATOR
- ( ) ARTERIAL BLOOD GASES
- ( ) HOME O_2 EVALUATION
- ( ) O_2 STUDY PATIENT
- ( ) MVV (For study patients only)

DOCTOR'S SIGNATURE (PRINT NAME)	APPROVED	PLACE OF CONSULTATION	ROUTINE / TODAY
		BEDSIDE / ON CALL	72 HOURS / EMERGENCY

CONSULTATION REPORT

PATIENT EVALUATION (PERFORMED BY PFT STAFF)

Smoking History: Currently smoking (✓) Cigarette <1/2 pack-years. Cigar/Pipe _____
Non-Smoker ( )
Quit ____ years ago, _____ months ago, _____ weeks ago

Cough: History of cough: Months/Years < 2 C None _____ Sputum color [illegible]
Test: Loose (✓) Dry ( ) None ( )

Dyspnea:
( ) 0 - None
( ) 1 - One flight or walking fast
(✓) 2 - Walking on level ground
( ) 3 - Sitting in chair
( ) 4 - Sometimes

Breathing Medications: N Time of last dose _____ Hr/ago

Maximum Pressures: Inspiration _____ Expiration _____

Patient effort and cooperation:

(Continued on reverse side)

SIGNATURE AND TITLE | DATE

IDENTIFICATION NO | ORGANIZATION | REGISTER NO | WARD NO

PATIENT'S IDENTIFICATION

OP-264 (646)

CONSULTATION SHEET
STANDARD FORM 513 Rev. 8

DANKO, T 1969

169-26

9674156 5

PULMONARY FUNCTION LABORATORY
V.A. PITTSBURGH HEALTHCARE SYSTEM
UNIVERSITY DRIVE DIVISION

Name:DANKO, PAUL JR.
Age: 64 Years
Sex/Race: Male / Caucasian
Height: 67 in 170 cm
Weight: 176 lbs 80 kg

ID#:169-25-7266
Room:PLM Date:09-DEC-97
Temp/Pres: 23 C / 733 mmHg
Physician:ATWOOD
Tested by:LARRY ALEXANDER

		PRED	PRE-RX BEST	PRE-RX %PRED	POST-RX BEST	POST-RX %PRED	%CHG
SPIROMETRY (BTPS)							
FVC	Liters	4.07	2.51 #	62*			
FEV1	Liters	2.86	1.93	68*			
FEV1/FVC	%	71	77				
FEF25-75%	L/Sec	2.78	1.83	66			
PEF50%	L/Sec	3.76	2.62	70			
PEF	L/Sec	3.76	7.00	90			
Vol Extrap	Liters		0.13				

---

* = OUTSIDE 95% CONFIDENCE INTERVAL # = OUTSIDE NORMAL RANGE
CALIBRATION: PRED: 7.04 ACTUAL: 6.96 L PK INDEX: 3.7
FEV-0L10-0E IPS-0H10-07 N-1004-4

COMMENTS:

PT. EXECUTION THROUGHOUT TESTING VERY GOOD. UNABLE TO OBTAIN
RELIABLE DLCO

96741566

Source: https://www.industrydocuments.ucsf.edu/docs/gqgg0072

PULMONARY FUNCTION LABORATORY
V.A. PITTSBURGH HEALTHCARE SYSTEM
UNIVERSITY DRIVE DIVISION

Name:DANKO, PAUL JR. ID#:169-26-7066
Age: 64 Years Room:PLM Date:09-DEC-97
Sex/Race: Male / Caucasian Temp/Pres: 23 C / 733 mm Hg
Height: 67 in 170 cm Physician:ATWOOD
Weight: 176 lbs 80 kg Tester by:CARRY ALEXANDER

		PRED	TRL1	TRL2	TRL3	BEST %PRED	%CHG
SPIROMETRY	(BTPS)	PRE-BY					
FVC	Liters	4.07	3.21	3.41	3.42	3.51	3%
FEV1	Liters	2.86	1.45	1.57	1.85	1.93	32%
FEV1/FVC	%	71	66	77	76	77	
FEF25-75%	L/Sec	2.78	0.66	1.83	1.50	1.82	-34%
FEF50%	L/Sec	3.76	1.39	2.60	2.99	2.60	-31%
PEF	L/Sec	7.76	1.99	3.19	7.00	7.00	-10%
Vol Extrap	Liters		0.36	0.13	0.06	0.13	

* = OUTSIDE 95% CONFIDENCE INTERVAL # = OUTSIDE NORMAL LIMITS
INTERPRETATION: PRED: 3.94 ACTUAL: PRE 3.93 POST 3.71
ATS-0L10-08 IPS-0H10-07 [illegible] 1.4

[illegible]

[illegible] EXECUTION THROUGHOUT TEST TIME WERE ACCEPTABLE. [illegible] 3.71 USED.
VARIABLE DLCO

96741567

Source: https://www.industrydocuments.ucsf.edu/docs/gqgg0072

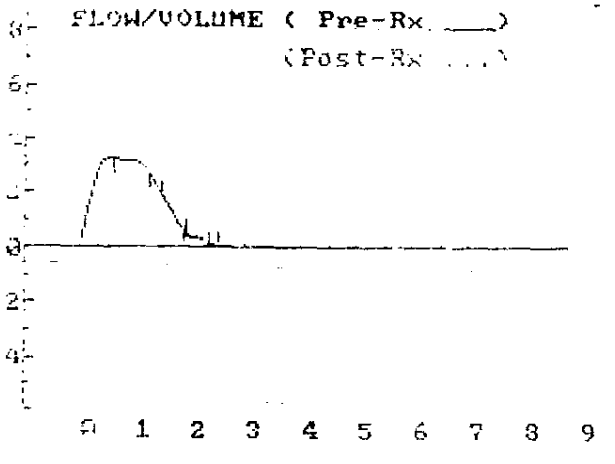
PULMONARY FUNCTION LABORATORY
V.A. PITTSBURGH HEALTHCARE SYSTEM
UNIVERSITY DRIVE DIVISION

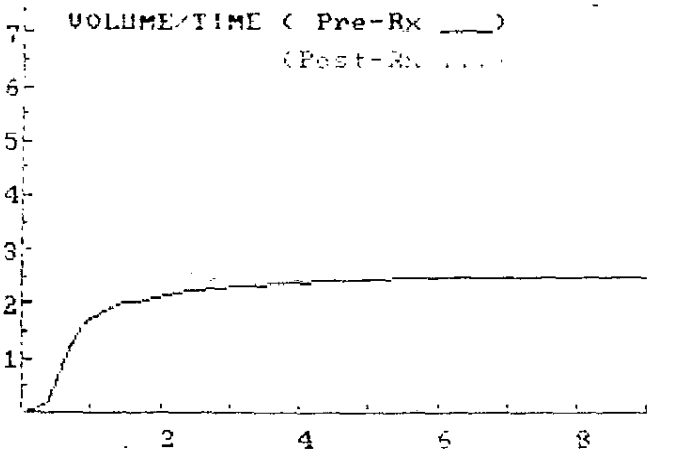
Name: DAVID, PAUL JR.
Age: 64 Years
Sex/Race: Male / Caucasian
Height: 67 in 170 cm
Weight: 176 lbs 80 kg

ID#: 169-36-7216
Room: PLM Date: 09-DEC-97
Temp/Press: 23 C / 777 mmHg
Physician: ATWOOD
Tested by: BARRY ALEXANDER

		PRED	PRE-RX BEST	PRE-RX %PRED	POST-RX BEST	POST-RX %PRED	%CHG
SPIROMETRY (ATS)							
FVC	Liters	4.07	2.51 #	62*			
FEV1	Liters	3.36	1.93	58*			
FEV1/FVC	%	71	77				
FEF25-75%	L/Sec	2.78	1.93	69			
PEF	L/Sec	7.74	2.47	32			
FEF	L/Sec	7.76	7.00	90			
FEV1 % Exap	Liters		0.13				

= OUTSIDE 95% CONFIDENCE INTERVAL * = OUTSIDE NORMAL RANGE
(Pre-Rx 12-DEC-97 IPS-0810-07 FL=1.00)

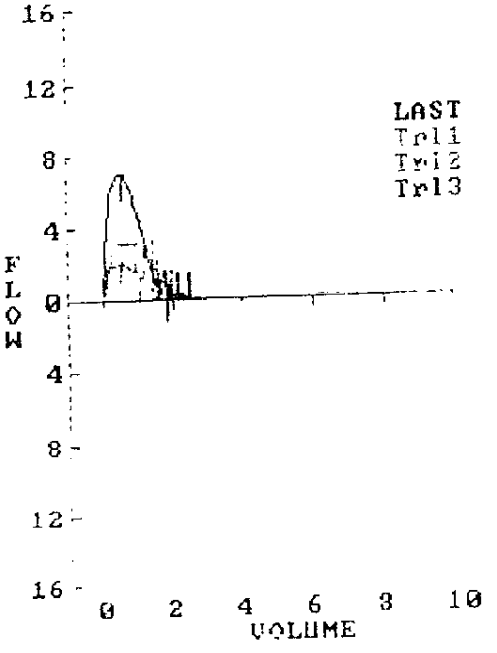




9674568

Source: https://www.industrydocuments.ucsf.edu/docs/gqgg0072

Name: DANKO, PAUL JR.
ID #: 159-26-7256



96741569

Source: https://www.industrydocuments.ucsf.edu/docs/gqgg0072

MEDICAL RECORD	PROGRESS NOTES

DATE 10/27/97 Ent

F.V. (R) Neck Mass – Resolved
Pub L.N. – (R) FNAB (–)

Mass is gone –
was "2 ½"

Still Sw) to (R)

Had CT "Lateral" done

Last CT 7/11 (a) (–)

On Tegaret – still sore throat
Ba Sw – (1) Achalasia ? dysphagia
(2) Esophageal dysfx
(3) Hiatal hernia
(4) Cervical Esophageal Web

IDL – 4/

DC – 4/

Neck – Ill defined

(R) Neck Fullness – smaller than
when measured palpated –
post FNAB

Tf – Plan No ED
GERD

GERD

Discuss swallowing Tx

Plan Pt Pillows / Propacid

EKG

(Continue on reverse side)

PATIENT'S IDENTIFICATION (For typed or written entries give Name—last, first, middle, grade, rank, rate, hospital or medical facility)

REGISTER NO. | WARD NO.

Wanko, Ruth
169-26-7266

PROGRESS NOTES
STANDARD FORM 509 (Rev. 11-77)
Prescribed by GSA/ICMR
FIRMR(41CFR)201.45.505
509-111

967415 70

Source: https://www.industrydocuments.ucsf.edu/docs/gqgg0072

MEDICAL RECORD	CONSULTATION SHEET

REQUEST

TO: ENT

FROM: [illegible]

DATE OF REQUEST: 3/5/97

REASON FOR REQUEST (Complaint and Findings)

63 yo F very hoarse for 3 months, progressive ... now SOB

h/o GERD, IV drug ...

PROVISIONAL DIAGNOSIS

SCHEDULE AFTER 5/1/97

DOCTOR'S SIGNATURE	APPROVED	PLACE OF CONSULTATION	ROUTINE / URGENT
COX		BEDSIDE / ON CALL	24 HOURS / EMERGENCY

CONSULTATION REPORT

Please See Progress Note

7/7/97

(Continued on reverse side)

SIGNATURE AND TITLE

DATE

IDENTIFICATION NO	ORGANIZATION	REGISTER NO	WARD NO
		169 20 7460	

PATIENT'S IDENTIFICATION (Typed or written entry: give Name - last, first, middle; grade; rank; unit; hospital or medical facility)

DANKO, JX

CONSULTATION SHEET
STANDARD FORM 513 (Rev. 6-77)
Prescribed by GSA
FPMR (41 CFR) 101-11.6

969415 71

Source: https://www.industrydocuments.ucsf.edu/docs/gqgg0072

MEDICAL RECORD | PROGRESS NOTES

DATE 7/4/97

Ext - New PT / Consult
- Patient seen late (count 3/97)
at 4:15 w/o +
Hoarseness / dysphagia onset. oddly, mostly right sore throat - left. Hx of head & neck
T&C - Yrs ago
- Stopped 10 yrs
- Etoh
- All : codeine
- Fx hx - schizophrenia, paranoia
Prisons - ?.

AD - WNL
AS - WNL
Nose - WNL - Septal deviation to right.
Cavity not see Vocal cords
Rt. post neck - (+) Node ?
Lt. ligament.
F. no needle.

No CT/R on Cxpt

A/P. Hoarseness / dysphagia ?

FNA Rt. post neck Adenopathy
Videostrobe - N/
Nasopharyngeal - N/
1) Barium swallow
2) CXR
3) CT Neck
4) BUN / Lytes / Cbc / T&T

STAT CXR Tod - NS

(Continue on reverse side)

PATIENT'S IDENTIFICATION (For typed or written entries give: Name—last, first, middle, grade, rank, rate, hospital or medical facility)

DANKO JR, PAUL
169-26-7266

REGISTER NO. | WARD (s)

PROGRESS NOTES
STANDARD FORM 509 (Rev. 11-77)
Prescribed by GSA/IDMR
FIRMR(41 CFR)201-45.505
5/a 111

9674 1572

Source: https://www.industrydocuments.ucsf.edu/docs/gqgg0072

DEPARTMENT OF LABORATORY MEDICINE
SURGICAL PATHOLOGY REPORT

Specimen No. S92-1768

Name DANKO, PAUL Age 58Y Sex M MR No. 488804

Pt. Loc. 37304 Ord. Loc. OR12 Received 02/18/92 Reported 02/19/92

Att. Phy. FRAZIER, JOHN E., M.D. Ord. Phy. MAGOVERN, GEORGE JR., M.D.

Specimen: Right coronary artery plaque

Clinical Diagnosis:

MAC DES:

The specimen, right coronary artery plaque, consists of a 3.8 cm, elongated, calcified piece of tan-yellow tissue, sectioned. The specimen is totally submitted in one cassette.

DG/vap

DIAGNOSIS:

RIGHT CORONARY ENDARTERECTOMY:
CALCIFIED ATHEROSCLEROTIC PLAQUE

Robert R. Dawson, M.D.
Resident

Peter R. Olson, M.D.
Surgical Pathologist

cb

~~DANKO Exhibit No. 13-A~~ ~~NOTE: 13-A-1~~

96741573

Source: https://www.industrydocuments.ucsf.edu/docs/gqgg0072

[redacted]

REG:03/24/92
DOD:07/1993

FINAL RADIOLOGY REPORT

[redacted]

ABDOMEN 2.01

REPORTS TO:HAHN/BALK
XRAY FILE#:37968
EXAM DATE:03/24/92

&
RADIOLOGIST: SINGH,HERAMB
STENOGRAPHER: COLLAR,JEANNETTE

CT SCAN OF THE ABDOMEN WITH CONTRAST AND LIVER WITH AND WITHOUT CONTRAST:
CT OF THE ABDOMEN AND LIVER WAS OBTAINED OF THE DOME OF THE DIAPHRAGM TO THE PUBIC SYMPHYSIS. THE STUDY DEMONSTRATES IN THE LIVER THERE IS NO EVIDENCE OF ANY DILATED INTRA OR EXTRAHEPATIC DUCTS THE GALL BLADDER APPEARS TO BE NORMAL. THE PANCREAS IS ALSO OF NORMAL DENSITY. THE SPLEEN IS NORMAL. BOTH KIDNEYS ARE NORMAL IN NEPHROGRAM. THERE IS NO EVIDENCE OF ANY CYST OR MASS. THE BOWELS ARE WELL OPACIFIED WITH ORAL CONTRAST AND THERE IS NO EVIDENCE OF ANY MASS SEEN.

IMPRESSION

NORMAL CT SCAN OF THE ABDOMEN AND LIVER WITH AND WITHOUT CONTRAST.

LAST PAGE

1992

967411574

[redacted]

05195340324

FINAL RADIOLOGY REPORT

Attach to EMR No. 13-B

DIAGNOSIS (CONT'D):

3. Coronary artery disease:
   a. Significant disease of the proximal left anterior descending with a critical stenosis of the mid left anterior descending.
   b. Significant disease of the proximal left circumflex with a critical stenosis of the mid left circumflex.
   c. Functional occlusion of the distal right coronary artery.

COMPLICATIONS: None.

PLAN: Coronary artery bypass graft surgery, hopefully with grafts to the left anterior descending, mid and posterior marginals, and posterior descending artery.

ATTENDING: Michael J. Pecora, M.D.

FELLOW:

Michael J. Pecora MD

Michael J. Pecora, M.D.

MJP/mkm

96741575

DAF EXHIBIT 13

Source: https://www.industrydocuments.ucsf.edu/docs/gqgg0072

ALLEGHENY GENERAL HOSPITAL CARDIAC LABORATORY
CARDIAC CATHETERIZATION REPORT

PATIENT: DANKO, PAUL
DATE OF STUDY: 2/14/92

ID#: 48 88 80
DOB: 7/27/33

FILM NO: JH 374

TYPE OF STUDY: SELECTIVE CORONARY ARTERIOGRAPHY AND LEFT VENTRICULOGRAPHY

PERFORMED BY: Michael J. Pecora, M.D.

MAR 17 199

ANESTHESIA: Valium, Xylocaine.

CATHETERS: #8 French multipurpose.

CONTRAST: Omnipaque.

INDICATIONS: Unstable angina, overwhelmingly positive exercise echocardiogram.

RESULTS: Left ventricle: Ventriculography demonstrates essentially normal overall left ventricular function, perhaps with mild inferior hypokinesis. The left ventriculogram was performed a hand injection, due to the patient's markedly positive exercise treadmill and critical triple vessel disease. There is no mitral regurgitation. The left ventricular end-diastolic pressure pre ventriculography was 24. The left ventricular end-diastolic pressure post nitroglycerin dropped to 14.

Right coronary artery: There is a 40% diameter stenosis of the proximal right coronary artery, a 40% stenosis of the mid right coronary artery, and a 99% diameter stenosis of the distal right coronary artery prior to the posterior descending artery. The distal right coronary lesion is a very long, complex stenosis. The posterior descending artery is a large bypassable vessel.

Left main: Normal.

Left anterior descending: There is a 60% diameter stenosis of the proximal left anterior descending with a 95% diameter stenosis of the mid left anterior descending. The distal left anterior descending is a large bypassable vessel.

Left circumflex: There is a 70% diameter stenosis of the proximal left circumflex with a 90% stenosis of the mid left circumflex prior to a large posterior marginal. The mid and posterior marginals are large bypassable vessels.

DIAGNOSIS:
1. Elevated left ventricular end-diastolic pressure.
2. Essentially normal overall left ventricular systolic function.

967415 76

Danko Exhibit No 13 D

Source: https://www.industrydocuments.ucsf.edu/docs/gqgg0072

ALLEGHENY GENERAL HOSPITAL
RECORD OF OPERATIC

PATIENT: Danko, Paul MEDICAL RECORD #: 488804

DATE: 02-18-92

SURGEON: George J. Magovern, Jr., M.D.
ASSISTANT: Robert R. Lazzara, M.D.
John Belhumeur, PA-C
ANESTHESIA: General endotracheal.
ANESTHESIOLOGIST:

PREOPERATIVE DIAGNOSIS: Coronary artery disease.

POSTOPERATIVE DIAGNOSIS: Same.

OPERATIVE PROCEDURE: Coronary bypass grafting LIMA to AD, SVG to circumflex marginal, SVG to RCA with endarterectomy of RCA.

CROSS CLAMP TIME: 17 minutes.
TOTAL BYPASS TIME: 111 minutes.
COMPLICATIONS: None.

OPERATIVE NOTE: The patient was brought to the Operating Room and identified, following which a Swan-Ganz catheter and femoral arterial lines were placed. The patient underwent general endotracheal anesthesia and was prepped and draped in the usual sterile fashion, following which a standard midline sternotomy incision was made and taken down through the subcutaneous tissues. The sternum was marked in the midline and transected. At the same time, a saphenous vein was harvested from the lower extremity in the usual fashion. After opening the sternum, bleeding was controlled, and the IMA tract was inserted . The IMA was taken down from the left internal thoracic bed. Upon taking down the IMA, it was felt to have a good pulse and be of adequate size. Attention was then turned back to the anterior mediastinum, where the pericardium split from the anomalent vein and the diaphragm marsupialized in the usual manner. To concentric pursestrings were placed in the ascending aorta. A single concentric pursestring was placed to the right atrial appendage. The patient was systemically heparinized. The arterial cannula followed by the venous cannula were placed. At this time, the IMA was prepared for distal anastomosis. The patient was the placed on cardiopulmonary bypass. The aorta was crossed clamped and cold blood cardioplegia was infusion antegrade through a 14 gauge angiographic catheter, approximately 1,000cc. was given. At this time, attention was turned to the right coronary artery. The proximal portion was dissected free from surrounding epicardial tissue. The vessel was heavily calcified. At this time it was decided to perform an endarterectomy. The vessel was opened for approximately 4cm and endarterectomized without any difficulty. An end to side anastomosis was then performed with the previously harvested, reversed, and beveled saphenous vein graft utilizing 7-0 Prolene. The vein was marked for length and transected. Approximately100cc. of cold blood cardioplegia was given down this vein. Two repair stitches were made, one on each side. A this time, attention was turned to the obtuse marginal branch #1. The circumflex coronary artery was dissected free from surrounding epicardial fat. An arteriotomy was made, and the vessel was free of disease. End to side anastomosis was then performed with running 7-0 Prolene without difficulty. The vein was marked for length and transected. At this time, attention was turned toward the left anterior descending portion. The left anterior descending artery in its mid portion was dissected free from surrounding epicardial fat, just distal to the crossing vein.

DANKO EXB NO. 13 E

96741577

Source: https://www.industrydocuments.ucsf.edu/docs/gqgg0072

The vessel was [illegible]. it easily took a 1½mm probe, distally as well as proximally. An end to side anastomosis was then performed to the left internal mammary artery utilizing running 8-0 Prolene. A single repair stitch was performed on the left lateral side. At this time the aortic cross clamp was removed. The partial occlusion clamp was placed. Two 4mm punches were made and proximal anastomoses performed with running 6-0 Prolene. The partial occlusion clamp was removed, and the vein were aspirated of air. Please note that prior to cross clamping the aorta, pulmonary vent was placed to the main pulmonary artery. At this time it was removed, and the hole oversewn with running 4-0 Prolene. Atrioventricular pacing wires were placed in the standard fashion. A left pleural chest tube was placed. The patient was then slowly weaned from cardiopulmonary bypass without difficulty. Following a good cardiac index and mean pressure range of 70, venous cannula was removed and the arterial cannula was used for transfusion of pumped blood. Protamine was begun. Following institution of Protamine, the arterial cannula was removed. The site was oversewn with 4-0 Prolene. Inspection of all distal anastomoses and cannulation sites were noted to be hemostatically stable. Inspection of the left internal mammary artery bed revealed it to be stable. This area was also copiously irrigated with bacitracin saline. The chest was flushed with warm normal saline and continuing antibiotic solution. Two #32 French mediastinal chest tubes were placed. These were secured to the skin in the standard fashion. The chest was then closed utilizing interrupted #5 stainless steel wires, 0 Tycron, 0 Dexon, running 2-0 Dexon, and running 3-0 Dexon. The lower extremity had been previous closed utilizing running 2-0 and 3-0 Dexon.

George J. Magovern, Jr., M.D.

By: Robert R. Lazzara, M.D.
DICT: 02-18-92
TRAN: 02-19-92
RPL/per

96741578

Source: https://www.industrydocuments.ucsf.edu/docs/gqgg0072