BUILDING AN EX VIVO ATLAS OF THE EARLIEST BRAIN REGIONS AFFECTED BY ALZHEIMER'S DISEASE PATHOLOGY

Sadhana Ravikumar[1], Laura E.M. Wisse[12], Ranjit Ittyerah[1], Sydney Lim[1], Madigan Lavery[1], Long Xie[1], John L. Robinson[2], Theresa Schuck[3], Murray Grossman[2], Edward B. Lee[3], M. Dylan Tisdall[1], Karthik Prabhakaran[2], John A. Detre[2], Sandhitsu R. Das[1], Gabor Mizsei[1], Emilio Artacho-Pérula[4], Maria Mercedes Iñiguez de Onzono Martin[4], María del Mar Arroyo Jiménez[4], Monica Muñoz[4], Francisco Javier Molina Romero[4], Maria del Pilar Marcos Rabal[4], David J. Irwin[3], John Q. Trojanowski[3], David A. Wolk[2], Ricardo Insausti[4], Paul A. Yushkevich[1]

Depts. of [1]Radiology,[2]Neurology and [3]Pathology, University of Pennsylvania, Philadelphia, USA
[4]Human Neuroanatomy Laboratory, University of Castilla La Mancha, Albacete, Spain

ABSTRACT

Earliest neuropathological changes in Alzheimer's Disease (AD) emerge in the medial temporal lobe (MTL). In order for MRI biomarkers to detect changes linked specifically to AD pathology (as opposed to aging or other pathological factors) macroscopic patterns of structural change in the MTL must be linked to the underlying neuropathology. To provide such a linkage, we are conducting an autopsy imaging study combining *ex vivo* MRI and serial histopathology. Information from multiple subjects can be studied by creating a "population average" atlas of the MTL. We present a groupwise registration approach for constructing the atlas that is able to successfully capture the complex structure of the MTL, and anatomical variability across subjects. This atlas allows us to generate maps of cortical thickness measurements and identify regions in the MTL where structural changes correlate most strongly with AD progression. We show that using this atlas, we are able to find a significant correlation between atrophy and AD pathology in the MTL sub-regions associated with the earliest stages of AD pathology as described by Braak and Braak [1].

1. INTRODUCTION

Alzheimer's Disease (AD) pathology is characterized by phosphorylated-tau neurofibrillary tangles (NFTs) and β-amyloid plaques [1, 2]. Accumulation of these pathologies begins a decade or more before cognitive symptoms are observed. Of the two pathologies, the accumulation of NFTs in particular is thought to have a strong correlation with neuronal loss and cognitive decline [3]. Braak and Braak have described the characteristic pattern of spread of NFTs through the brain as AD progresses [1]. The earliest stages of NFT pathology emerge in a specific area of the medial temporal lobe (MTL), known as the *transentorhinal region*, located at the boundary of Brodmann Area 35 (BA35) and entorhinal cortex (ERC). The NFTs then spread through the subiculum (SUB) and CA1 subfield of the hippocampus, before spreading further out through other parts of the brain [1].

Using *in vivo* MRI, granular measurements of volumetric changes in the MTL caused by neurodegenration can be obtained [4]. These measurements have been shown to be sensitive to changes during the early stages of AD [4]. However, they are limited by the fact that other brain pathologies such as TDP43, vascular disease, and even "normal" aging, also affect MTL morphometry. Improved specificity of MRI-based MTL measures to NFT pathology would result in biomarkers that are more sensitive to longitudinal change in the presence of preclincal AD, and reduce the cost and duration of clinical trials evaluating treatment effectiveness in AD.

Several studies have looked at the association between *in vivo* MRI measurements and pathological [3] or more recently, tau PET [5] measures of NFT burden. Tau PET enables *in vivo* quantification of tau burden, but lacks the spatial resolution to obtain measurements within specific MTL sub-regions affected during the early stages of AD. **In this work, we use high resolution *ex vivo* imaging with pathologically derived ratings of NFT and non-NFT pathology to better understand the localized effects of AD on MTL structure**. Such an analysis can be used to define "hotspots" in the MTL where changes detected on *in vivo* imaging are expected to correlate most strongly with AD progression. As a first step, we apply computational anatomy techniques [6] to generate an *ex vivo* atlas that captures the "average" anatomy of the MTL. This is a challenging task due to the large degree of anatomical variability (i.e. different cortical folding and branching patterns) that the MTL exhibits. Conventional deformable image registration techniques fail to accurately align detailed anatomical features when registering high resolution *ex vivo* scans. We present an advanced, multi-step registration pipeline to construct an *ex vivo* atlas of the MTL. The

This work is supported by NIH grants R01 EB017255, R01 AG056014, P30 AG010124, R01 AG054519, AG017586, a UCLM travel grant to R.I. and a UCLM research grant to Human Neuroanatomy Laboratory

developed atlas is used to study the localized effects of NFT pathology on MTL structure in terms of cortical thickness.

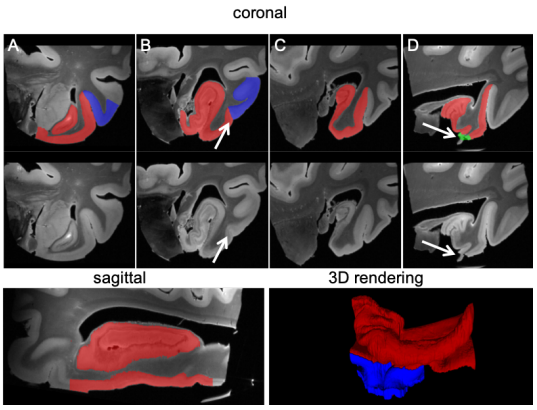

Fig. 1: Example multilabel segmentation of the medial temporal lobe (MTL) in an *ex vivo* MRI scan. Separate labels were used to label the lateral portion of the collateral sulcus (blue), as well as minor regions of the image with MRI artifacts, cut or missing tissues, and other irregularities (green).

2. MATERIALS AND METHODS

Intact *ex vivo* brain bank specimens of the MTL were obtained from 24 donors (15 males), aged 44−93 from the Human Neuroanatomy Laboratory (UCLM) and Center for Neurodegenerative Disease Research (UPenn).[1] The specimens contain varying degrees of pathology, spanning the spectrum of AD and common co-morbid non-AD pathologies (TDP43, cerebrovascular disease, Lewy body disease). Following 4+ weeks of fixation, the MTL blocks were scanned overnight on 9.4T MRI using a T2-weighted, multi-slice spin echo sequence (TE = 9330ms, TR = 23ms), with a resolution of 0.2 x 0.2 x 0.2 mm^3. The scans were then non-uniform bias field corrected [7] and normalized to a common intensity range. Due to gradient distortions in the 9.4T scanner, as part of the post-processing, all of the scans had to be warped to correct for differences between the scanner coordinate frame and physical coordinate frame. Linear scaling factors for this transformation were derived using a 3D printed phantom [8].

For 21 of the specimens, an expert pathologist provided semi-quantitative ratings of the severity of tau pathology in the MTL. In an effort to preserve the scanned MTL specimens for serial histology, these ratings were done by sampling the contralateral hemisphere. Ratings were provided for three sub-regions, namely ERC, DG (Dentate Gyrus) and CA (Cornu Ammonis), on a scale of 0-3, where 0 means no/rare pathology and 3 means severe pathology (advanced AD) [2]. For our study, we used the average rating across all the three regions as a measure of general NFT severity in a specimen. The average NFT rating across the 21 specimens was 1.45 ± 0.90.

[1] Human brain specimens were obtained in accordance with the University of Pennsylvania Institutional Review Board guidelines. Pre-consent during life and/or next-of-kin consent at death was given for all cases.

2.1. MTL segmentation

The initial steps of the atlas building process use segmentations of the MTL to guide groupwise registration. Given the large number of slices per dataset, full manual segmentation of the MTL would have been highly laborious. Therefore, segmentations were obtained using a semi-automated interpolation tool in ITK-SNAP software [9]. In each of the 24 specimens, the MTL was labelled manually approximately every 15 slices to initialize the algorithm. Given the labelled slices, the interpolation method uses binary weighted averaging and a random forest classifier to compute the intermediate segmentations [10]. This algorithm was applied iteratively, allowing the interpolated result to be reviewed and manually edited at each step to refine the segmentation. An example MTL segmentation obtained using this approach is shown in Fig 1. In several specimens the collateral sulcus (CS) of the MTL is tightly folded, making it difficult to distinguish the medial and lateral banks of the sulcal fold. Therefore, to better capture the large variability in the anatomy of the CS, a different label was used to manually segment the lateral portion of the sulcus (blue label in Fig. 1B). Additionally, the use of *ex vivo* MRI introduces unique challenges in the dataset such as artifacts due to air bubbles trapped in brain folds, and possible tearing of the tissue. While segmentations of these affected regions can still be used to guide the registration process, incorporating intensity information from these regions would introduce errors in any intensity-based registration steps. To address this issue, a separate label was used to segment regions of the MTL which should be excluded from intensity-based registration, as well as the eventual morphometry analysis (green label in Fig 1D).

2.2. MRI atlas construction

Construction of the atlas involves multiple image registration steps, as described in [8]. All of the registrations were performed using an implementation of the log domain diffeomorphic demons (Log-Demons) algorithm included in the "Greedy" package [11]. For the first stage, a graph-based approach is used to identify a registration sequence that minimizes the amount of shape deformation that is required to achieve a common image space across all the specimens [12]. We constructed a complete undirected graph where each specimen corresponds to a node and each pair of specimens corresponds to an undirected edge. To obtain edge weights, we performed affine and highly regularized, deformable registration between the medial and lateral portions of the MTL segmentations for each pair of specimens. The residual difference between the co-registered segmentations, computed using the generalized Dice similarity coefficient across the red and blue MTL labels provides a measure of the anatomical

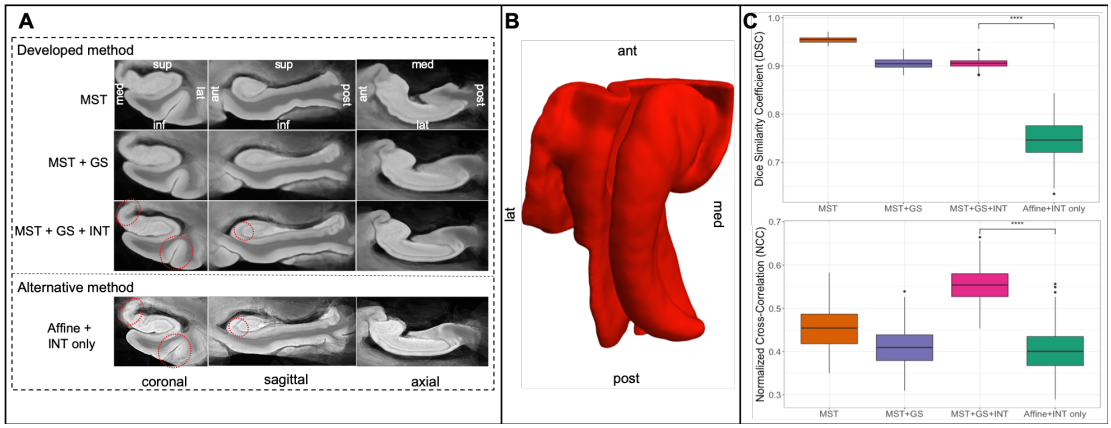

Fig. 2: A) Qualitative comparison of the MRI atlases generated by each stage of the atlas pipeline: minimum spanning tree (MST), geodesic shooting (MST + GS) and intensity-based groupwise registration (MST + GS + INT). The bottom row shows the atlas obtained using an alternate approach: affine alignment of the segmentations, followed by intensity-based groupwise registration (Affine + INT only). The dashed red circles highlight areas where the developed atlas (MST + GS + INT) shows a visible improvement compared to the "Affine + INT only" template. B) 3D rendering of the final template segmentation c) Quantitative metrics of the registration quality after each stage of the atlas pipeline, and the alternate "Affine + INT only" approach. Asterisks indicate statistically significant differences (****: $P < 0.0001$, paired t-test)

similarity between two specimens. A smaller edge weight indicates a greater degree of similarity. After constructing the graph, we applied Prim's Minimum Spanning Tree (MST) algorithm to the graph [13]. A root node of the MST is then identified as the node that has the smallest distance along the tree to every other node. The shortest path between each specimen and the root corresponds to a sequence of registrations involving the smallest amount of deformation at each step. After identifying the MST root, a second set of deformable registrations were performed between each specimen and the root following this unique sequence of composed, diffeomorphic transformations defined by the MST. These registrations used a smaller smoothing parameter, which resulted in less "diffusion-like" regularization.

The MST stage yields a set of affine and deformable transformations between each specimen and a common root specimen which closely matches up the boundaries of the MTL. The average shape of the MTL following this stage is biased by the anatomy of the root specimen. Therefore, the next stage of the pipeline performs shape correction using Geodesic Shooting (GS). This was implemented following the theoretical framework described in [14]. GS allows diffeomorphic transformations between the atlas shape and subject shape to be represented compactly using the initial momentum vector field. Diffeomorphic mappings were performed on point landmarks instead of the image, allowing for simpler and more efficient matching. To obtain these point landmarks, we generated surface meshes for the red and blue MTL labels in the root specimen's segmentation, and then extracted a single set of landmarks by roughly uniformly sampling each mesh equally. The root landmarks were then warped into the space of each specimen using the composed transformations from the MST stage. After obtaining landmarks, the shape averaging algorithm iteratively corrects the shape average by alternating between registering each specimen to the shape average using a combination of rigid alignment and geodesic shooting, and updating the shape average by applying geodesic shooting in the direction of the average initial momenta. This process was repeated for several iterations until the shape average stabilized.

For the final stage, intensity-based deformable registration (INT) was performed following the groupwise unbiased framework proposed in [6] to generate a population template. Unlike the previous stages which relied predominantly on the segmentations for shape information, this stage incorporates the MR images to resolve residual misalignment between specimens. The green label in the segmentations (Fig. 1D) was used to mask out regions with artifacts from the registration computation. The registration process iteratively alternates between intensity-based Log-Demons registration with the normalized cross-correlation (NCC) metric between each specimen and the groupwise template, and updating the template by averaging the transformed images. These steps were repeated until the template stabilized.

2.3. Regional thickness measurements

The output of the atlas pipeline described in section 2.2 is an average template image, average template segmentation, and a set of transformations, T_j which map the template into the native space of each of the specimens, j. To obtain thickness measurements, we first extracted a surface mesh of the MTL from the template segmentation. The surface mesh was smoothed using the Taubin smoothing algorithm to remove sharp voxel edges [15]. Using the transformations T_j, the surface mesh was then warped into the native space of each of

the 21 specimens for which we had pathology data. Regional thickness is measured by extracting the Voronoi skeleton [16] of each surface mesh, and computing twice the distance between each vertex on the mesh and the closest point on the skeleton. For each specimen, the computed thicknesses were brought back into the common template space, resulting in a set of 21 measurements at each vertex. Due to the artifacts described in section 2.1, at certain vertices in some specimens thickness measurements had to be excluded from the mesh. This resulted in a variable number of observations at each vertex, and was accounted for in the statistical analysis.

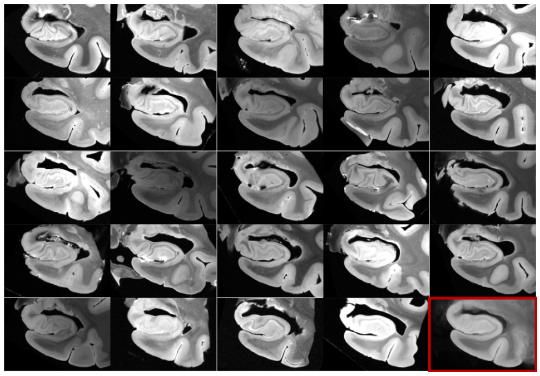

Fig. 3: MRI scans of each of the 24 specimens after registration into the final MRI atlas space. The more similar the warped images, the better the atlas quality. The corresponding atlas image is displayed in the bottom-right corner.

2.4. Statistical analysis

To test the localized correlation between NFTs and cortical thickness, we fit a general linear model at each vertex with thickness as the dependent variable, pathology score as an independent variable, and age as a covariate. To account for multiple statistical comparisons, cluster-level familywise error rate correction is used (empirical threshold: uncorrected $p = 0.01$) [17]. Permutation testing with 1000 iterations was performed to assign a corrected p-value to each cluster.

3. RESULTS AND DISCUSSION

The constructed atlas achieves excellent groupwise alignment and captures the anatomical variability of the MTL. Fig. 2 shows the final MRI atlas constructed from the 24 specimens as a synthetic average MR image following each stage of the atlas pipeline, and a 3D rendering of the average atlas segmentation (Fig 2B). In Fig 2A, we see that the geodesic shooting step (MST+GS) causes a clear change in the shape of the MTL towards a more average shape compared to MST only. The final stage of incorporating intensity information (MST+GS+INT) results in sharper intensity features. Traditionally, *in vivo* morphometry studies rely on groupwise intensity-based deformable registration (INT only). However, this conventional approach does not work as well as the developed multi-step pipeline (Fig 2A). The dashed red circles highlight regions where the MST+GS+INT template achieves a markedly better result than the INT only template. Quantitative metrics of atlas quality following each of the three stages are reported in Fig. 2C. After each stage, we computed the average Dice similarity coefficient (DSC) for the entire MTL segmentation across all pairs of specimens registered to a given atlas [18], and the average NCC between each pair of specimens registered to the atlas, integrated over the volume of the MTL segmentation. While we would expect MS+GS+INT to result in a higher DSC metric compared to "Affine + INT only" due to the direct use of segmentations in the first two stages, we see that our method also achieves a significantly better NCC metric.

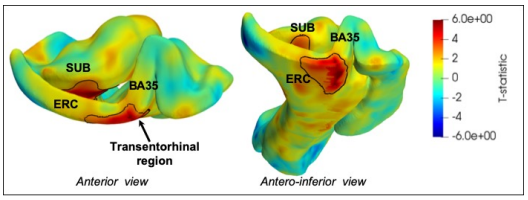

Fig. 4: T-statistic map of the correlation between cortical thickness and the severity of NFT pathology in a subject. The clusters outlined in black indicate regions where a significant correlation was observed (corrected $p < 0.05$). These clusters correspond with the regions associated with the earliest Braak stages [1]

Fig. 3 shows the quality of the registrations between individual specimens and the final MRI atlas. In some specimens, the CS was particularly challenging to register due to significant variability in the structure of sulcal folds. Overall the warped specimens look similar to each other following registration, although some mis-registrations remain.

Fig. 4 shows the results of the correlation analysis between NFTs and cortical thickness. We observe a significant correlation (corrected $p < 0.05$) between the severity of NFTs and atrophy in the transentorhinal region and subiculum. These regions, indicated by the outlined clusters, are consistent with the earliest neuropathological stages of NFT progression as described by Braak and Braak [1].

4. CONCLUSION

We present a computational *ex vivo* atlas of the human MTL. This atlas was constructed using highly customized, computational anatomy techniques, from a unique 3D dataset of postmortem MTL specimens. Using this atlas, we were able to examine the localized effects of AD-specific pathology on MTL cortical thickness. A limitation of our current analysis is the use of semi-quantitative pathology ratings. In future work, this atlas will be leveraged to study variability in the distribution of NFT pathology in 3D, by mapping quantitative serial pathology images into *ex vivo* MRI space.

5. REFERENCES

[1] H. Braak, and E. Braak, "Neuropathological stageing of Alzheimer-related changes," *Acta Neuropathologica*, vol. 82, no. 4, pp. 239–259, 1991.

[2] B. T. Hyman, C. H. Phelps, T. G. Beach, E. H. Bigio, N. J. Cairns, M. C. Carrillo, D. W. Dickson, C. Duyckaerts, M. P. Frosch, E. Masliah, S. S. Mirra, P. T. Nelson, J. A. Schneider, D. R. Thal, B. Thies, J. Q. Trojanowski, H. V. Vinters, and T. J. Montine, "National Institute on Aging-Alzheimer's Association guidelines for the neuropathologic assessment of Alzheimer's disease," *Alzheimer's and Dementia*, vol. 8, no. 1, pp. 1–13, jan 2012.

[3] M. Bobinski, J. Wegiel, M. Tarnawski, M. Bobinski, B. Reisberg, M. J. De Leon, D. C. Miller, and H. M. Wisniewski, "Relationships between regional and neuronal loss and neurofibrillary changes in the hippocampal formation and duration and severity of Alzheimer disease," *Journal of Neuropathology and Experimental Neurology*, vol. 56, no. 4, pp. 414–420, apr 1997.

[4] P. A. Yushkevich, J. B. Pluta, H. Wang, L. Xie, S. L. Ding, E. C. Gertje, L. Mancuso, D. Kliot, S. R. Das, and D. A. Wolk, "Automated volumetry and regional thickness analysis of hippocampal subfields and medial temporal cortical structures in mild cognitive impairment," *Human Brain Mapping*, vol. 36, no. 1, pp. 258–287, jan 2015.

[5] S. R. Das, L. Xie, L. E. Wisse, N. Vergnet, R. Ittyerah, S. Cui, P. A. Yushkevich, and D. A. Wolk, "In vivo measures of tau burden are associated with atrophy in early Braak stage medial temporal lobe regions in amyloid-negative individuals," *Alzheimer's & Dementia*, pp. 1–10, 2019.

[6] S. Joshi, B. Davis, M. Jomier, and G. Gerig, "Unbiased diffeomorphic atlas construction for computational anatomy," *NeuroImage*, vol. 23, no. SUPPL. 1, 2004.

[7] N. J. Tustison, B. B. Avants, P. A. Cook, Y. Zheng, A. Egan, P. A. Yushkevich, and J. C. Gee, "N4ITK: Improved N3 bias correction," *IEEE Transactions on Medical Imaging*, vol. 29, no. 6, pp. 1310–1320, jun 2010.

[8] D. H. Adler, L. E. Wisse, R. Ittyerah, J. B. Pluta, S. L. Ding, L. Xie, J. Wang, S. Kadivar, J. L. Robinson, T. Schuck, J. Q. Trojanowski, M. Grossman, J. A. Detre, M. A. Elliott, J. B. Toledo, W. Liu, S. Pickup, M. I. Miller, S. R. Das, D. A. Wolk, and P. A. Yushkevich, "Characterizing the human hippocampus in aging and Alzheimer's disease using a computational atlas derived from ex vivo MRI and histology," *Proceedings of the National Academy of Sciences of the United States of America*, vol. 115, no. 16, pp. 4252–4257, 2018.

[9] P. A. Yushkevich, J. Piven, H. C. Hazlett, R. G. Smith, S. Ho, J. C. Gee, and G. Gerig, "User-guided 3D active contour segmentation of anatomical structures: Significantly improved efficiency and reliability," *NeuroImage*, vol. 31, no. 3, pp. 1116–1128, jul 2006.

[10] S. Ravikumar, L. Wisse, Y. Gao, G. Gerig, and P. Yushkevich, "Facilitating Manual Segmentation of 3D Datasets Using Contour And Intensity Guided Interpolation," in *2019 IEEE 16th International Symposium on Biomedical Imaging (ISBI 2019)*, 2019, pp. 714–718.

[11] T. Vercauteren, X. Pennec, A. Perchant, and N. Ayache, "Symmetric log-domain diffeomorphic registration: A demons-based approach," *Lecture Notes in Computer Science (including subseries Lecture Notes in Artificial Intelligence and Lecture Notes in Bioinformatics)*, vol. 5241 LNCS, no. PART 1, pp. 754–761, 2008.

[12] L. Xie, J. B. Pluta, S. R. Das, L. E. Wisse, H. Wang, L. Mancuso, D. Kliot, B. B. Avants, S.-L. Ding, J. V. Manjón, et al., "Multi-template analysis of human perirhinal cortex in brain mri: Explicitly accounting for anatomical variability," *NeuroImage*, vol. 144, pp. 183–202, 2017.

[13] R. C. Prim, "Shortest Connection Networks And Some Generalizations," *Bell System Technical Journal*, vol. 36, no. 6, pp. 1389–1401, nov 1957.

[14] M. Vaillant, M. I. Miller, L. Younes, and A. Trouvé, "Statistics on diffeomorphisms via tangent space representations," *NeuroImage*, vol. 23, no. SUPPL. 1, pp. S161–S169, jan 2004.

[15] P. Cignoni, M. Callieri, M. Corsini, M. Dellepiane, F. Ganovelli, and G. Ranzuglia, "MeshLab: an Open-Source Mesh Processing Tool," in *Eurographics Italian Chapter Conference*, V. Scarano, R. D. Chiara, and U. Erra, Eds. 2008, The Eurographics Association.

[16] R. L. Ogniewicz, and O. Kübler, "Hierarchic Voronoi skeletons," *Pattern Recognition*, vol. 28, no. 3, pp. 343–359, mar 1995.

[17] T. Nichols, and S. Hayasaka, "Controlling the familywise error rate in functional neuroimaging: A comparative review," *Statistical Methods in Medical Research*, vol. 12, no. 5, pp. 419–446, oct 2003.

[18] W. R. Crum, O. Camara, and D. L. Hill, "Generalized overlap measures for evaluation and validation in medical image analysis," *IEEE Transactions on Medical Imaging*, vol. 25, no. 11, pp. 1451–1461, nov 2006.