Journal of Computer Assisted Tomography
26(2):216–222
© 2002 Lippincott Williams & Wilkins, Inc., Philadelphia

Pictorial Essay

Contrast-Enhanced MRI of the Liver With Mangafodipir Trisodium: Imaging Technique and Results

Dushyant V. Sahani, Martin E. O'Malley, Sandeep Bhat, Peter F. Hahn, and Sanjay Saini

Abstract: Magnetic resonance (MR) contrast agents are now routinely used for detecting and characterizing focal liver lesions. Liver specific, hepatobiliary, MRI contrast agent mangafodipir trisodium (Mn-DPDP) is taken up by the functioning hepatocytes and excreted by the biliary system. Contrast uptake leads to persistent elevation of T1-weighted signal of normal liver parenchyma within 10 minutes of injection. Most tumors of non-hepatocellular origin typically are hypointense relative to enhanced liver parenchyma on T1 weighted images and are more conspicuous than on unenhanced images. Whereas, tumors of hepatocellular origin such as focal nodular hyperplasia (FNH), adenoma, and well-differentiated hepatocellular carcinomas (HCC) have been shown to accumulate Mn-DPDP, providing characterization information to discriminate hepatocellular from non-hepatocellular tumors. The purpose of this pictorial essay is to illustrate the appearance of various liver tumors on mangafodipir enhanced liver MR imaging. **Index Terms:** Liver tumor—Contrast agent—Mangafodipir trisodium—Magnetic resonance imaging.

LIPPINCOTT
WILLIAMS & WILKINS

From the Division of Abdominal Imaging and Intervention, Department of Radiology, Massachusetts General Hospital, Boston, MA (D. V. Sahani, P. F. Hahn, and S. Saini), and Clinical Research, Nycomed Amersham, Wayne, PA (S. Bhat), U.S.A.; and Department of Medical Imaging, Toronto General Hospital, Toronto, Ontario, Canada (M. E. O'Malley). Address correspondence and reprint requests to Dr. S. Saini at Division of Abdominal Imaging and Intervention, Department of Radiology, Massachusetts General Hospital, Ellison 234-E, 55 Fruit St., Boston, MA 02114, U.S.A. E-mail: saini.sanjay@mgh.harvard.edu

Unauthorized use prohibited

INTRODUCTION

MR contrast agents are now routinely used for detecting and characterizing focal liver lesions (1). Recently, the liver-specific hepatobiliary MR contrast agent mangafodipir trisodium (Teslascan; Nycomed, Wayne, PA, U.S.A.) was approved for liver imaging. Mangafodipir is also known as Mn-DPDP, which stands for its manga-

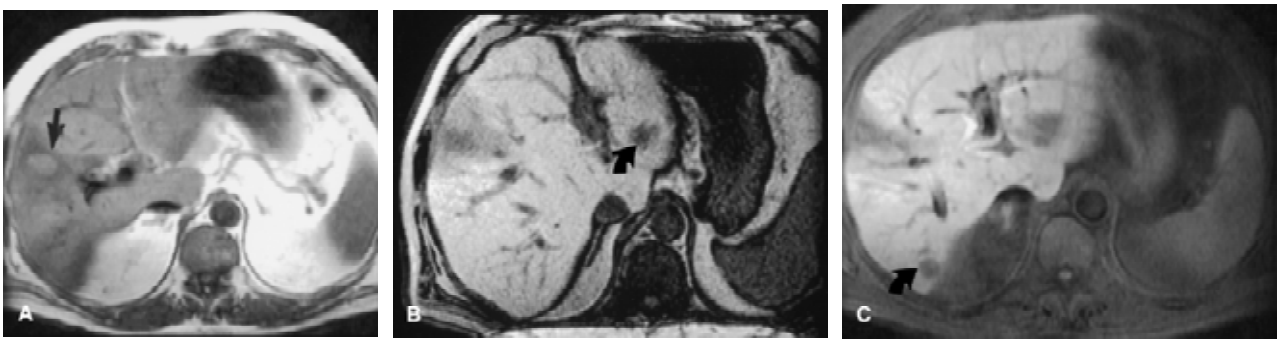

FIG. 1. A 71-year-old man with liver metastases from colon cancer. **A:** Precontrast gradient echo T1-weighted (TR 150/TE 2.1) image shows subtle signal abnormality in segment 8. **B:** Mangafodipir-enhanced T1-weighted gradient echo (TR 150/TE 2.1) image without fat saturation improves the conspicuity of the segment 8 liver lesion. Additional lesion is detected in segment 3 (arrow). **C:** Fat-saturated T1-weighted spin echo (TR 300/TE 11) image shows better tumor-to-liver contrast than the gradient echo image.

nese dipyridoxal diphosphate, a manganese chelate that is taken up by the functioning hepatocytes by exploiting the vitamin B6 pathway; >50% of the contrast agent is excreted by the biliary system. Mangafodipir is also taken up by renal and pancreatic tissue (2). Uptake leads to persistent elevation of T1-weighted signal of normal liver parenchyma. Liver enhancement is maximal within 10 min of injection and persists for several hours, developing a useful imaging window between 10 min and 24 h. Tumors of nonhepatocyte origin such as colorectal cancer metastases typically are hypointense relative to Mn-DPDP-enhanced liver parenchyma on T1-weighted images and are more conspicuous than on unenhanced images (2,3). Mn-DPDP has been shown to improve detection of liver metastases when compared with noncontrast images (3,7).

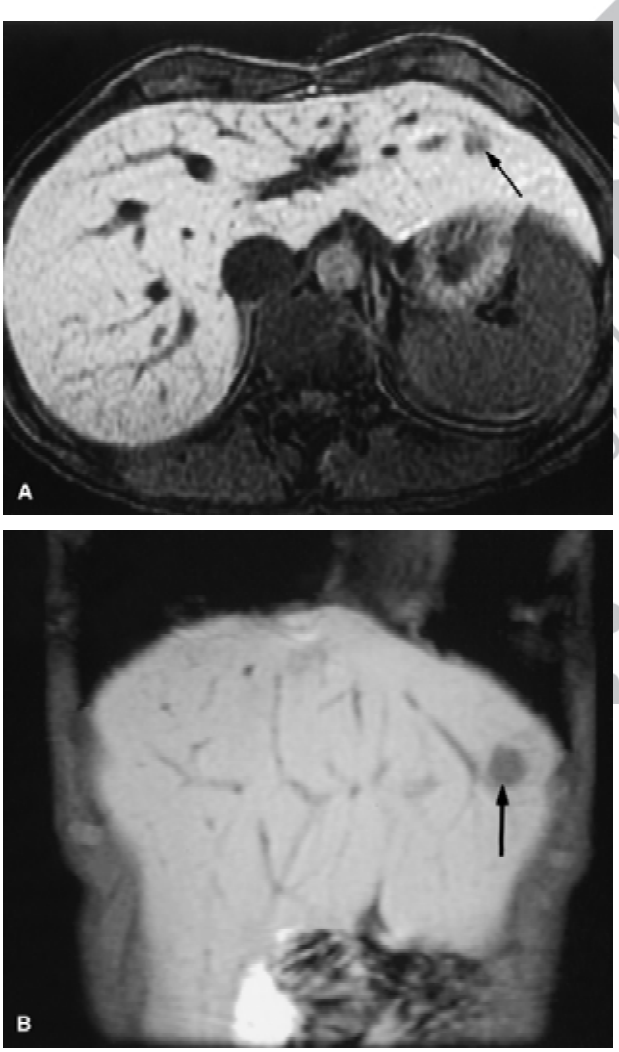

FIG. 2. Colon cancer metastases in a 38-year-old woman who was scheduled for liver resection. **A:** Mangafodipir-enhanced T1-weighted (TR 150/TE 2.1) axial image demonstrates focal metastasis in the lateral segment (segment 2/3) of the liver (arrow). **B:** Postmangafodipir coronal image allows localization of the lesion in segment 2 (arrow).

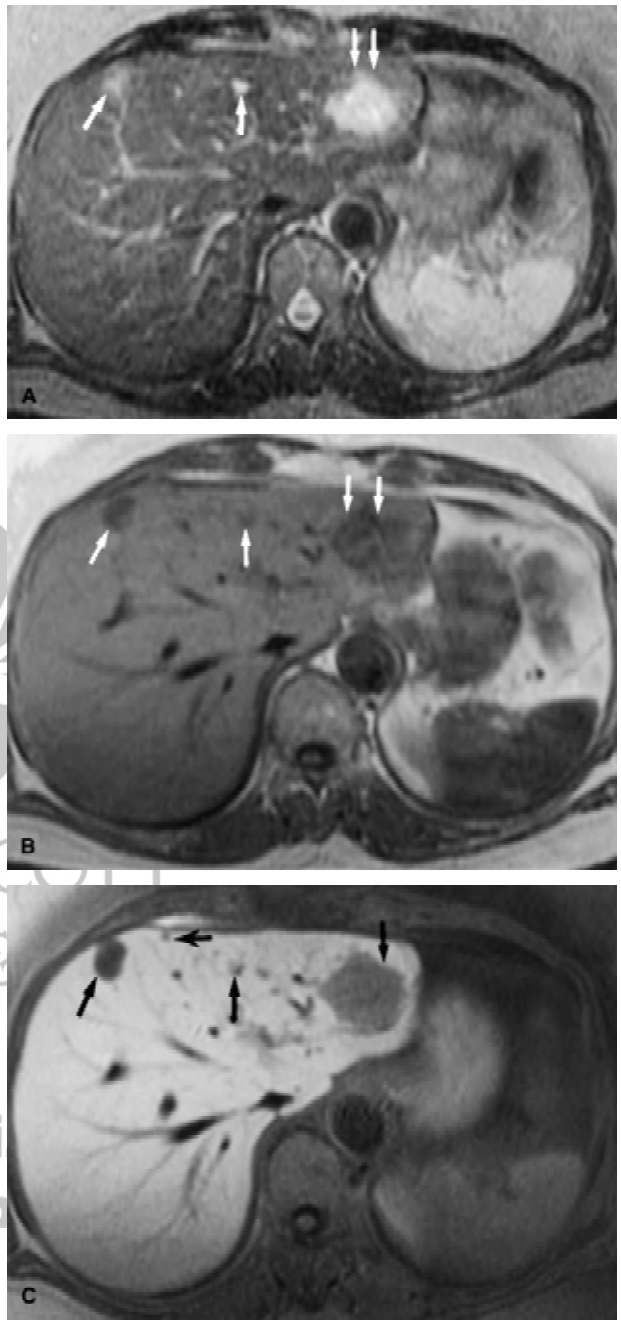

FIG. 3. Colon cancer metastases in a 51-year-old man. **A and B:** Precontrast T1-weighted gradient echo (TR 150/TE 2.1) image (A) and fast spin echo T2-weighted (B) image show three ill-defined focal lesions in the liver (arrows). **C:** Mangafodipir-enhanced T1 image improves the delineation of the focal lesions and detects additional lesion in the periphery of segment 4 (arrow).

Tumors of hepatocellular origin such as focal nodular hyperplasia (FNH), adenoma, and well differentiated hepatocellular carcinomas (HCCs) have been shown to accumulate Mn-DPDP, providing characterization information to discriminate hepatocellular from nonhepatocellular tumors (4,10).

A vasomotor effect of the manganese, which is sensed as facial flushing or warmth during injection, is frequent, but there are no more serious side effects. The purpose of this pictorial essay is to illustrate the appearance of various liver tumors on mangafodipir-enhanced liver MRI.

IMAGING TECHNIQUE

Mangafodipir is administered intravenously at a dose of 5 μmol/kg over approximately 1–2 min. Peak liver enhancement occurs between 10 and 30 min; there is an approximate 200% increase in liver signal-to-noise ratio on T1-weighted images (Fig. 1A and B), and the T2-weighted images are unaffected (4). Since short scan times are not mandatory, for optimal results, high-resolution T1-weighted images with fat saturation may be used for postcontrast imaging (Fig. 1C) (6). Delayed imaging between 4 and 24 h after injection can add specificity for hepatocellular lesions (3).

NONHEPATOCELLULAR LESIONS

Typically, metastases appear as nonenhancing hypointense lesions. The lesions are much more conspicuous after mangafodipir than on unenhanced images (see Figs. 1 and 3), and more liver lesions are seen after the administration of mangafodipir than on unenhanced MR images. In a Phase II and III clinical trial of mangafodipir, postcontrast T1-weighted spin echo images detected significantly more lesions than precontrast T1- and T2-weighted images (7). Thus, in patients with colon cancer and potentially resectable liver metastases, mangafodipir may play a role in preoperative detection and localization of liver lesions. The latter is possible because the high liver vessel contrast readily permits delineation of hepatic segmental anatomy (Fig. 2A). Oblique axial and coronal images (Figs. 2B and 4) can help in differentiating small vessels seen in cross-section from small centrally located metastases. Tumor margins are better delineated on the postcontrast images, allowing the differentiation from surrounding edema (Fig. 3). Both conventional gadolinium chelate and Mn-DPDP have been shown to improve detection of liver metastases (1,7,9) when used independently and compared with unenhanced liver images. To our knowledge, there has not been any study to make a direct comparison of the sensitivity and specificity of Mn-DPDP with gadopentetate dimeglumine (Gd-DTPA) for liver lesion detection.

FIG. 5. Solitary liver metastasis in a 44-year-old man with adenocarcinoma of the rectum. **A:** Premangafodipir T1-weighted gradient echo (TR 150/TE 2.1) image shows a hypointense mass in segments 6/7. **B:** T1-weighted gradient echo image obtained 4 h after mangafodipir injection demonstrates a hyperintense ring around the liver metastasis due to the delay in washout of contrast material from the compressed liver parenchyma (arrow).

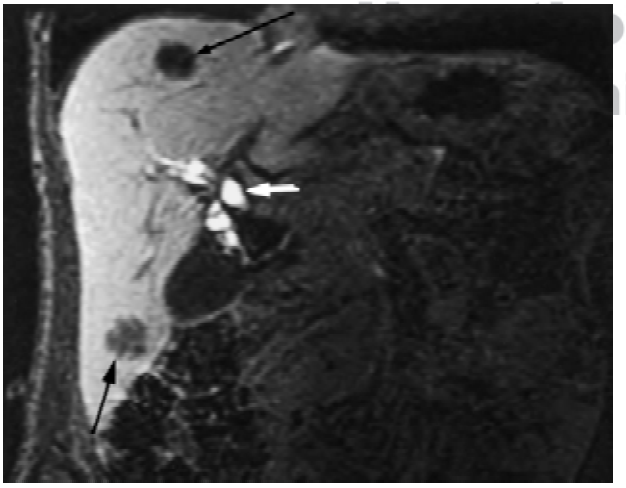

FIG. 4. Middle-aged women with liver metastasis from colon cancer. Coronal postcontrast T1-weighted image demonstrates excretion of T1 bright contrast in the bile ducts (thick arrow) and gallbladder. Note two metastases in the right lobe of liver (thin arrows).

On delayed (>4 h) images, metastases often show peripheral enhancement, which has been attributed to poor washout of the contrast agent from compressed normal hepatic tissue (Fig. 5) (3). This feature is not usually seen in benign lesions such as cysts or hemangiomas (Fig. 6A and B).

Focal fatty infiltration or fatty sparing of the liver is usually characterized at MR with out-of-phase gradient-

LIPPINCOTT WILLIAMS & WILKINS Unauthorized Use Prohibited

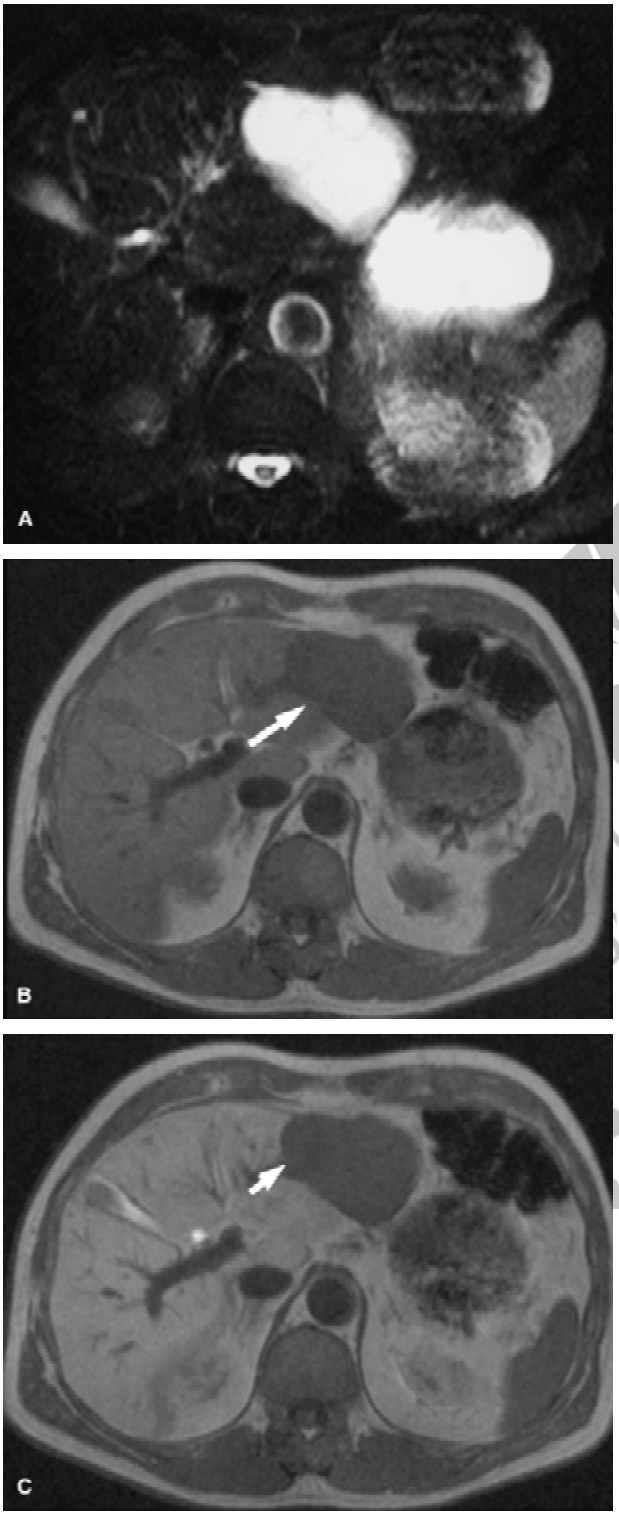

FIG. 6. Left lobe liver hemangioma in a 67-year-old man with a recently diagnosed right left renal mass. Fast spin echo T2-weighted image (**A**) demonstrates a bright lesion in the left lobe of liver, which maintains its T1 dark characteristics on the pre (**B**) and post (**C**) mangafodipir-enhanced gradient echo (TR 150/TE 2.1) images. Note the enhancement of the background liver parenchyma.

recalled echo (GRE) images. On mangafodipir-enhanced images, the absence of metastases in the region of abnormal signal intensity can be demonstrated by uptake of the contrast agent (Fig. 7B).

HEPATOCELLULAR LESIONS

FNH and adenoma are the two most common benign hepatocellular liver tumors. Both tumors take up mangafodipir and display increased or similar signal enhancement characteristics compared with adjacent normal liver (Fig. 8) (3,8,10). Both FNH and adenoma show higher uptake than the surrounding normal liver parenchyma, probably owing to high arterial blood supply, larger number of hepatocytes per unit volume, and possible different cellular activity. On delayed images, there is persistent enhancement of the FNH due to insufficient biliary drainage (Fig. 8C). The scar of FNH, although rich in biliary radicals, does not enhance on the initial or delayed images. There is insufficient experience in the literature to suggest any difference in the enhancement characteristics of a hepatocellular adenoma and FNH (10). The Phase III clinical trial data of Teslascan reflect the same findings.

HEPATOCELLULAR LESIONS IN CIRRHOTIC LIVER

In patients with cirrhosis, liver enhancement may be lower than enhancement seen in the noncirrhotic liver (5). This is probably due to hepatocyte dysfunction and fibrotic changes. The contrast agent excretion is also delayed in comparison with the normal liver owing to impaired biliary excretion. Dysplastic nodules often enhance to become more conspicuous on contrast-enhanced images (Fig. 9). HCCs may take up mangafodipir according to the degree of tumor differentiation. HCC enhancement may be uniform (Figs. 10 and 11), heterogeneous (Fig. 12), capsular sparing, or internal band-like, depending on the degree of cellular differentiation (2,5). Thus, well differentiated HCC enhances and may be less conspicuous after the administration of mangafodipir (Fig. 9A). Delayed images are useful since HCCs may retain mangafodipir to a greater degree than the normal liver (Fig. 9B). This can be attributed to the absence of a functional biliary system within the tumor or obstruction of intratumoral bile ducts. Therefore, mangafodipir alone has a limited role in differentiating benign from malignant hepatocellular tumors.

CLINICAL APPROACH

The primary indication of mangafodipir-enhanced liver imaging is for detection and localization of hepatic metastasis. We administer the contrast agent after acquiring precontrast T1-weighted images; T2-weighted im-

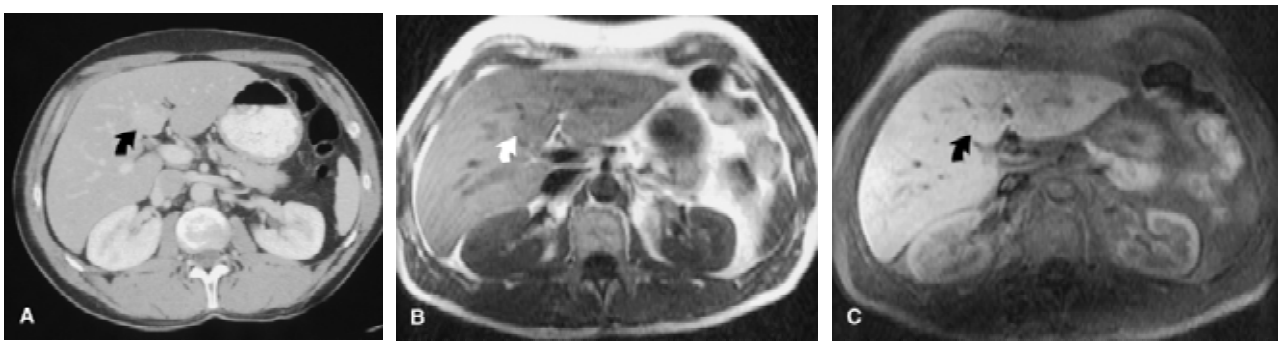

FIG. 7. Focal fatty sparing of the liver in a 44-year-old woman with breast carcinoma. **A:** Focal area of increased attenuation in segment 4 (curved black arrow) is noted on the contrast-enhanced CT of the liver. **B:** Premangafodipir T1-weighted spin echo (TR 300/TE 11) image shows an ill-defined focal area of relatively low signal in segment 4 (curved white arrow). **C:** Uniform contrast agent uptake (curved black arrow) on the post-mangafodipir-enhanced T1 image excludes liver metastasis.

ages are acquired while the contrast agent is being taken up by the liver. Finally, postcontrast T1-weighted images are obtained. This produces a very time-efficient imaging protocol. Dual contrast MRI utilizing sequential administration of Gd-DTPA and Mn-DPDP in a single imaging protocol was recently suggested by Martin et al. (11) for detection and characterization of focal hepatic lesions. They typically administered gadolinium first and then Mn-DPDP was administered; 60 min after gadolinium injection, patients were again imaged with MRI. This approach increases the total time spent by the patient in the MR scanner and affects patient through-put. Gadolinium administration prior to Mn-DPDP also interferes with characterization of the focal hepatic masses with

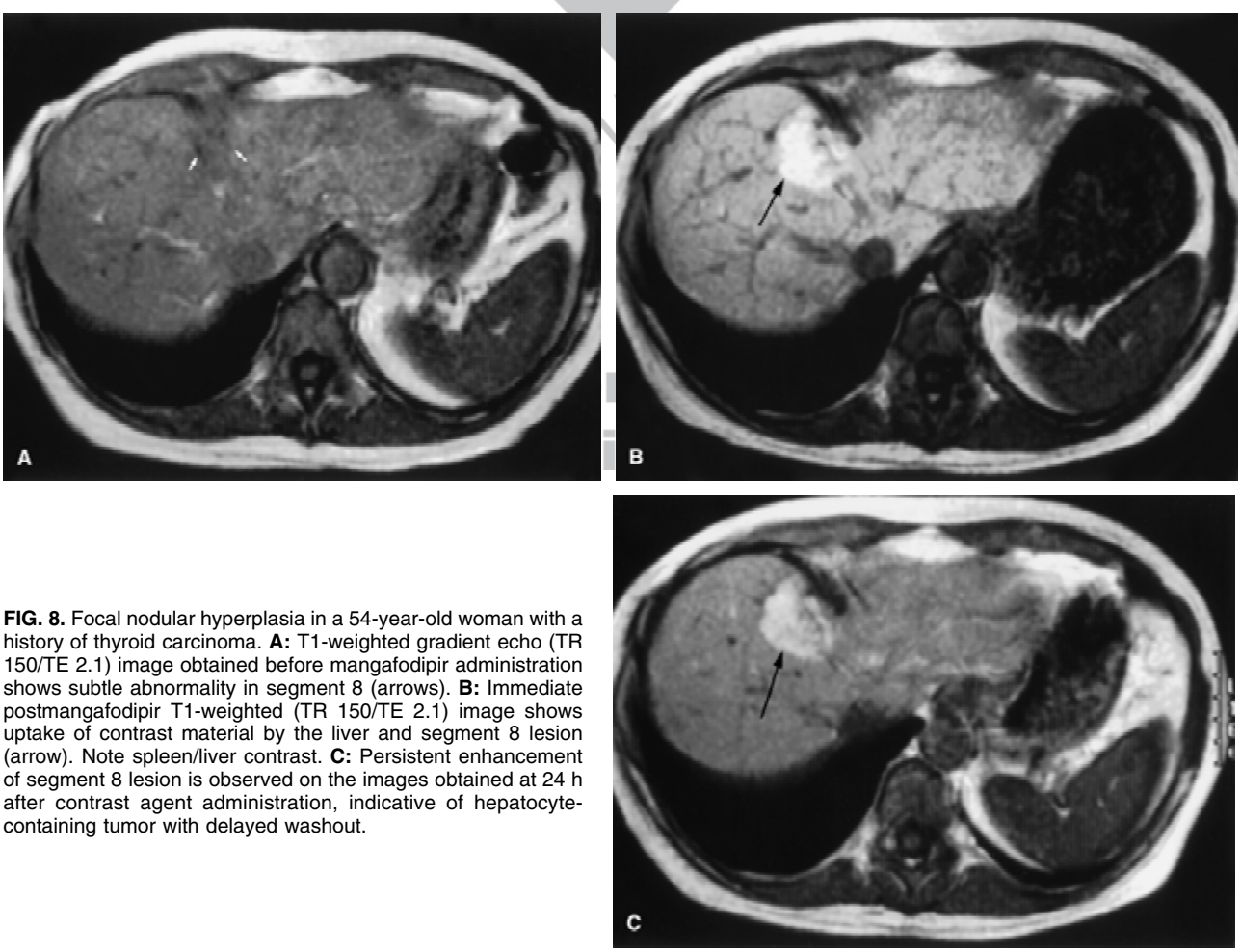

FIG. 8. Focal nodular hyperplasia in a 54-year-old woman with a history of thyroid carcinoma. **A:** T1-weighted gradient echo (TR 150/TE 2.1) image obtained before mangafodipir administration shows subtle abnormality in segment 8 (arrows). **B:** Immediate postmangafodipir T1-weighted (TR 150/TE 2.1) image shows uptake of contrast material by the liver and segment 8 lesion (arrow). Note spleen/liver contrast. **C:** Persistent enhancement of segment 8 lesion is observed on the images obtained at 24 h after contrast agent administration, indicative of hepatocyte-containing tumor with delayed washout.

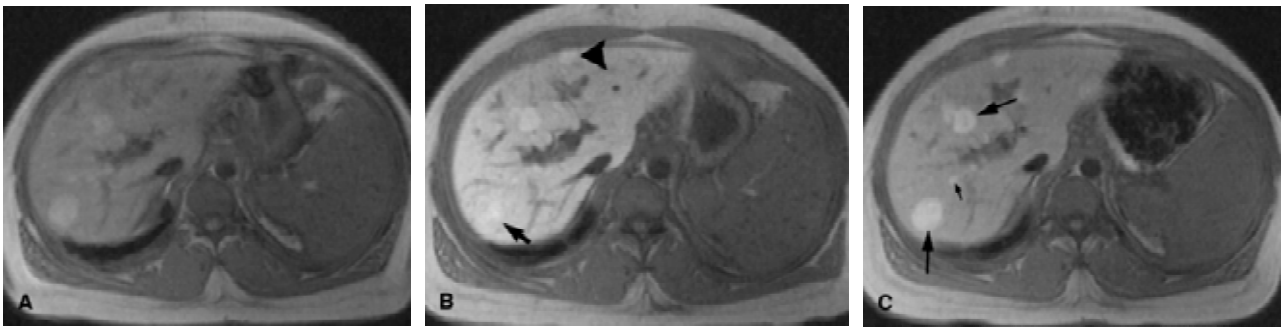

FIG. 9. Dysplastic nodules in a 25-year-old cirrhotic man. **A:** Pre-Mn-DPDP T1-weighted gradient echo (TR 150/TE 2.1) image shows multiple well defined hyperintense nodules in the liver in the background of cirrhosis. **B:** Immediate post-Mn-DPDP T1-weighted gradient echo (TR 150/TE 2.1) image increases the signal intensity within the liver and the lesions. There is reduced conspicuity of the nodule seen in segment 7 (arrow), and an additional nodule is seen in segment 2. **C:** On 24 h post-Mn-DPDP T1-weighted gradient echo (TR 150/TE 2.1) image, the nodules remain enhanced (large arrows), making them more conspicuous, as more nodules are seen now (small arrow).

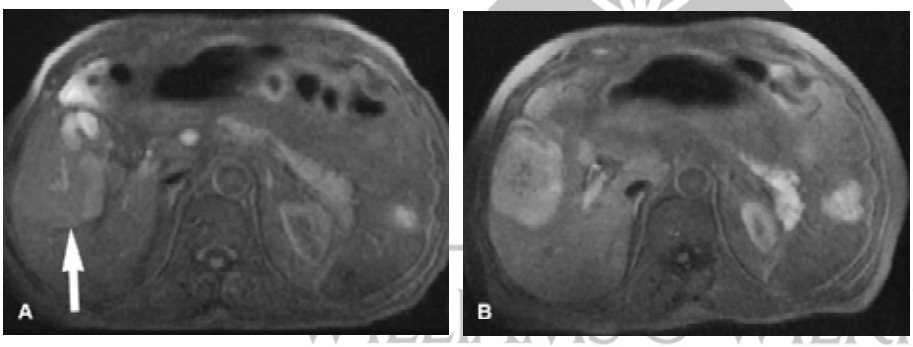

FIG. 10. Well differentiated hepatocellular carcinoma in a 79-year-old cirrhotic man. **A:** A vague area of increased signal intensity is noted in segment 8/5 (arrow) on the precontrast T1-weighted gradient echo (TR 150/TE 2.1) image. **B:** T1-weighted gradient echo (TR 150/TE 2.1) image obtained 4 h after mangafodipir administration shows pronounced enhancement of the tumor and poor enhancement of the cirrhotic liver.

WILEY-VCH WILEY-VCH
Unauthorized Use
Prohibited

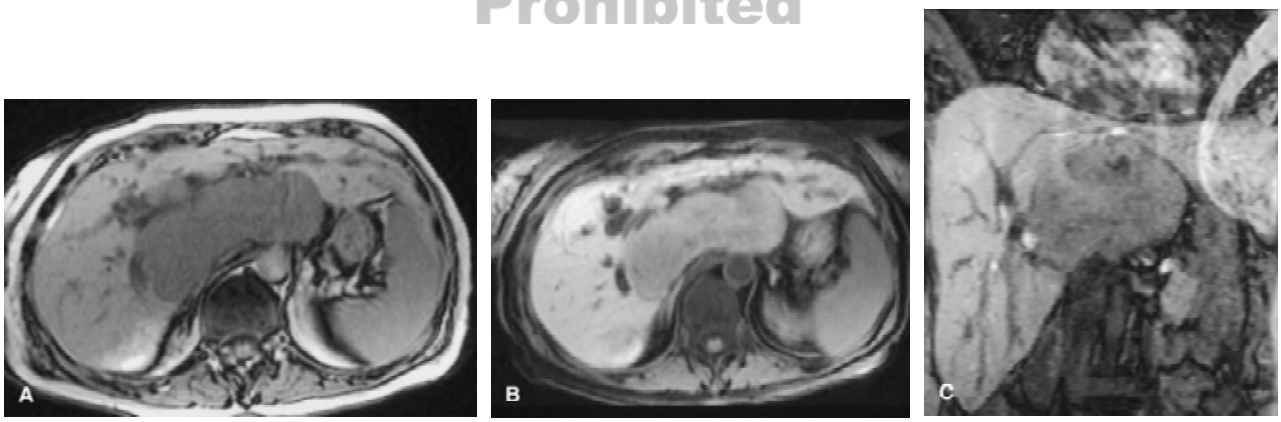

FIG. 11. Moderately differentiated hepatocellular carcinoma in a 57-year-old woman. **A:** Precontrast axial T1-weighted gradient echo (TR 150/TE 2.1) image demonstrates a large exophytic neoplasm centered in segment 1 and 4. **B:** Homogeneous contrast agent uptake is seen within the tumor and liver parenchyma on immediate post-Mn-DPDP axial T1-weighted gradient echo (TR 150/TE 2.1) image. **C:** Post-Mn-DPDP coronal T1-weighted gradient echo (TR 150/TE 2.1) image shows the exophytic component of the tumor.

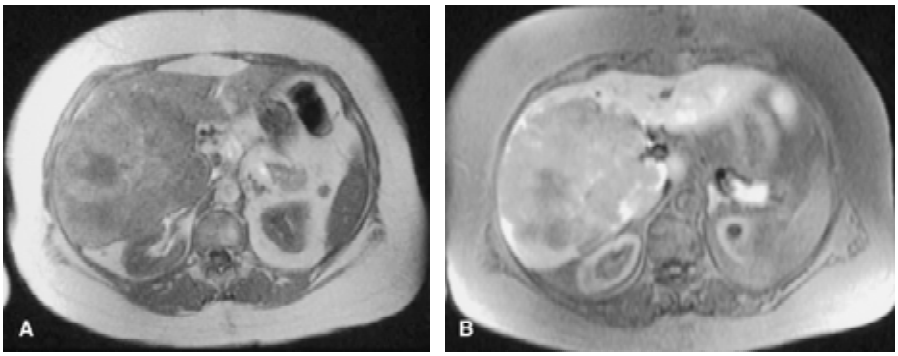

FIG. 12. Poorly differentiated hepatocellular carcinoma in a 62-year-old man. **A:** Pre-Mn-DPDP T1-weighted gradient echo (TR 150/TE 2.1) image shows a lobulated hypointense mass in the liver. **B:** Post-Mn-DPDP T1-weighted gradient echo (TR 150/TE 2.1) image shows a heterogenous contrast uptake within the tumor. Increase in the tumor-to-liver contrast is present due to high contrast agent uptake in the liver.

Mn-DPDP as some of the lesions may retain Gd-DTPA for a longer time. We recommend administration of Mn-DPDP first, followed by Gd-DTPA. This is a more time-efficient protocol; moreover, in our experience, the administration of Mn-DPDP first did not interfere with lesion characterization with Gd-DTPA.

Delayed images (>4 h) are useful in characterizing tumors as hepatocellular in origin but probably cannot differentiate between benign and malignant hepatocellular tumors. Therefore, we do not recommended delayed imaging as a routine practice. In patients with cirrhosis, we do not use mangafodipir but instead perform dynamic imaging with extracellular gadolinium chelate.

REFERENCES

1. Beers BV, Gallez B, Pringot J. Contrast-enhanced MR imaging of the liver. *Radiology* 1997;203:297–306.
2. Rofsky NM, Weinreb JC, Bernardino ME, et al. Hepatocellular tumors: characterization with Mn-DPDP-enhanced MR imaging. *Radiology* 1993;188:53–9.
3. Hamm B, Vogl TJ, Branding G, et al. Focal liver lesions: MR imaging with Mn-DPDP—initial clinical results in 40 patients. *Radiology* 1992;182:167–74.
4. Liou J, Lee JK, Borrello JA, et al. Differentiation of hepatomas from nonhepatomatous masses: use of MnDPDP-enhanced MR images. *Magn Res Imag* 1994;12:71–9.
5. Murakami T, Baron RL, Peterson MS, et al. Hepatocellular carcinoma: MR imaging with mangafodipir trisodium (Mn-DPDP). *Radiology* 1996;200:69–77.
6. Slater GJ, Saini S, Mayo-Smith WW, et al. Mn-DPDP enhanced MR imaging of the liver: analysis of pulse sequence performance. *Clin Radiol* 1996;51:484–6.
7. Rummeny EJ, Ehrenheim C, Gehl HB, et al. Manganese-DPDP as a hepatobiliary contrast agent in the MR imaging of liver tumors: results of clinical phase II trials in Germany including 141 patients. *Invest Radiol* 1992;27:879–86.
8. Vogl TJ, Hamm B, Schnell B, et al. Mn-DPDP enhancement pattern of hepatocellular lesions on MR images. *J Magn Res Imag* 1993;3:51–8.
9. Earls JP, Bluemke DA. New MR imaging contrast agents. *MRI Clin North Am* 1999;7:225–73.
10. Coffin CM, Diche T, Mahfouz A, et al. Benign and malignant hepatocellular tumors: evaluation of tumoral enhancement after mangafodipir trisodium injection on MR imaging. *Eur Radiol* 1999;9:444–9.
11. Martin D, Semelka R, Chung J, et al. Sequential use of gadolinium chelate and mangafodipir trisodium for the assessment of focal liver lesions: initial observations. *Magn Res Imag* 2000;18:955–63.

LIPPINCOTT WILLIAMS & WILKINS
Unauthorized Use Prohibited