Multimodality Diagnosis of Liver Tumors:

Feature Analysis with CT, Liver-specific and Contrast-enhanced MR, and a Computer Model[1]

Steven E. Seltzer, MD, David J. Getty, PhD, Ronald M. Pickett, PhD, John A. Swets, PhD, Gregory Sica, MD
Jeffrey Brown, MD, Sanjay Saini, MD, Robert F. Mattrey, MD, Ben Harmon, MD, Isaac R. Francis, MD
Judith Chezmar, MD, Mitchell O. Schnall, MD, PhD, Evan S. Siegelman, MD, Rocco Ballerini, PhD, Sandeep Bhat, BSE

Rationale and Objectives. The purpose of this study was to measure and to clarify the diagnostic contributions of image-based features in differentiating benign from malignant and hepatocyte-containing from non–hepatocyte-containing liver lesions.

Materials and Methods. Six experienced abdominal radiologists each read images from 146 cases (including a contrast material–enhanced computed tomographic [CT] scan and contrast-enhanced and unenhanced magnetic resonance [MR] images) following a checklist-questionnaire requiring them to rate quantitatively each of as many as 131 image features and then reported on each of the two differentiations. The diagnostic value of each feature was assessed, and linear discriminant analysis was used to develop statistical prediction rules (SPRs) for merging feature data into computerized "second opinions." For the two differentiations, accuracy (area under the receiver operating characteristic curve [A_z]) was then determined for the radiologists' readings by themselves and for each of three SPRs.

Results. Thirty-seven candidate features had diagnostic value for each of the two differentiations (a slightly different feature set for each). Radiologists' performance at both differentiations was excellent ($A_z = 0.929$ [benign vs malignant] and 0.926 [hepatocyte-containing vs non–hepatocyte-containing]). Performance of the SPR that operated on the features from all modalities together was better than that of radiologists ($A_z = 0.936$ [benign vs malignant] and 0.951 [hepatocyte-containing vs non–hepatocyte-containing]), but this difference was of marginal statistical significance ($P = .11$). Contrast-enhanced MR imaging and contrast-enhanced CT each made significant adjunctive contributions to accuracy compared with unenhanced MR imaging alone.

Conclusion. Many CT- and MR imaging–based features have diagnostic value in differentiating benign from malignant and hepatocyte-containing from non–hepatocyte-containing liver lesions. Radiologists could also benefit from the fully informed SPR's "second opinions."

Key Words. Liver, tumors; computer–aided diagnosis.

© AUR, 2002

It generally is agreed that the substantial progress made during the past decade in the area of image-based detection of liver lesions has not been matched by commensurate progress in the area of differential diagnosis (1,2). This dichotomy may exist because the recent availability of a wide array of powerful liver-imaging tools (ie, breath-hold magnetic resonance [MR] imaging, tissue-specific MR contrast agents [3–6], and helical computed tomography [CT]) may facilitate lesion detection but make classification a highly complex task. For instance, radiologists often need to extract and integrate findings from several imaging studies to develop a differential diagnosis. Such an approach can yield high levels of accu-

Acad Radiol 2002; 9:256–269

[1] From the Department of Radiology, Brigham and Women's Hospital, Harvard Medical School, 75 Francis St, Boston, MA 02115 (S.E.S., D.J.G., R.M.P., J.A.S., G.S.); BBN Technologies, Cambridge, Mass (D.J.G., R.M.P., J.A.S.); Mallinckrodt Institute of Radiology, Washington University School of Medicine, St Louis, Mo (J.B.); Department of Radiology, Massachusetts General Hospital, Harvard Medical School, Boston (S.S.); Department of Radiology, University of California, San Diego (R.F.M.); Department of Radiology, Methodist Hospital, Indianapolis, Ind (B.H.); Department of Radiology, University of Michigan, Ann Arbor (I.R.F.); Department of Radiology, Emory University School of Medicine, Atlanta, Ga (J.C.); Department of Radiology, University of Pennsylvania, Philadelphia (M.O.S., E.S.S.); and Nycomed-Amersham, Princeton, NJ (R.B., S.B.).
Received May 29, 2001; revision requested August 2; revision received October 26; accepted October 29. Supported in part by a grant from Nycomed-Amersham. **Address correspondence to** S.E.S.

© AUR, 2002

racy, but those yields typically are achieved only by specialists or when working with a limited domain of highly selected cases. A more detailed and systematic, feature-based approach to diagnostic classification could represent an important advance in our field by allowing high levels of accuracy to generalize even to nonexpert radiologists. This technique involves the use of (*a*) a checklist–questionnaire covering all the key features to be considered with each modality that the radiologist follows and fills out for each case and (*b*) a computer aid that takes those feature data and merges them in a statistically optimal way to create a "second opinion" for the radiologist to consider when making his or her final diagnosis. This approach has been successfully applied in several other complex, image-based diagnostic settings (7–12). We sought to demonstrate the value of such a feature-based approach in this study.

The purpose of this study was to measure and to clarify the diagnostic contributions of image-based features in differentiating benign from malignant and hepatocyte-containing from non–hepatocyte-containing liver lesions. To accomplish this, we used features derived from three modalities (unenhanced MR imaging, contrast material-enhanced CT, and contrast-enhanced MR imaging) both individually and combined. Of particular interest was the contribution of features derived from the use of tissue-specific MR contrast media, because this was the new addition to the diagnostic regimen. The aim of this work was *not* to perform a classic technology-assessment study. Neither the design nor the data collected were appropriate to tease out the relative accuracies of CT versus MR imaging or of unenhanced versus contrast-enhanced MR imaging. Moreover, some features were harvested across modalities, so a pure comparison of one imaging tool with another was not possible.

The first of three specific goals was to identify an exhaustive list of image-based features that expert radiologists believed had diagnostic value. The second was to determine by means of univariate analyses which of these features did, in fact, have diagnostic power. The third was to determine by means of multivariate analyses the diagnostic power of the features in combination. Statistical prediction rules (SPRs) were developed that could take the feature-rating data reported by radiologists on the questionnaire for each case and merge these ratings of multiple features optimally into a computerized "second opinion." Three different SPRs were developed for each of the two differentiations: (*a*) for unenhanced MR imaging alone, (*b*) for unenhanced plus contrast-enhanced MR imaging, and (*c*) for all three modalities combined. Of primary interest was how well the performance of SPRs using information from all three modalities together compared with the performance of radiologists also working with all three modalities together; this would provide a basis for estimating the contribution to accuracy by the computer aid.

MATERIALS AND METHODS

Study Design

The overall design of the study is shown in Figure 1. We began with a comprehensive survey to identify all features having potential relevance to establishing the diagnosis of liver lesion with use of each modality. We then developed the checklist-questionnaire that the radiologists would follow and fill out for each case in the reading study. For each case in the reading study, the six radiologists who participated were given all the modalities to consider together and were required to fill out the checklist-questionnaire and to produce the two lesion differentiations of interest. ROC analyses were then conducted to derive an accuracy index for each reader regarding each of the differentiations.

The feature data obtained on the checklist–questionnaires were then subjected to two types of statistical processing. First, univariate analysis was used to determine which features carried statistically significant diagnostic power. Second, multivariate analysis involving features, taken in combination, was used to train and to test the various SPRs that would produce the same two differentiations of interest on each case. Accuracy indices for each SPR, computed separately for each reader's feature data, were also then derived by means of ROC analysis. Finally, we conducted statistical analyses on the accuracy indices to test for various differences of interest: between the radiologists and the SPR working with all the modalities together, and between SPRs working with different combinations of the modalities.

Case Material

The 146 cases used in this study were taken from a previously completed, multicenter, phase III clinical trial of mangafodipir trisodium (Teslascan; Nycomed-Amersham, Princeton, NJ), a hepatocyte-specific MR imaging contrast agent. The retrospective use of this case material was believed to be advantageous for the current study because (*a*) patients had been enrolled according to well-specified eligibility criteria, (*b*) imaging followed standard protocols,

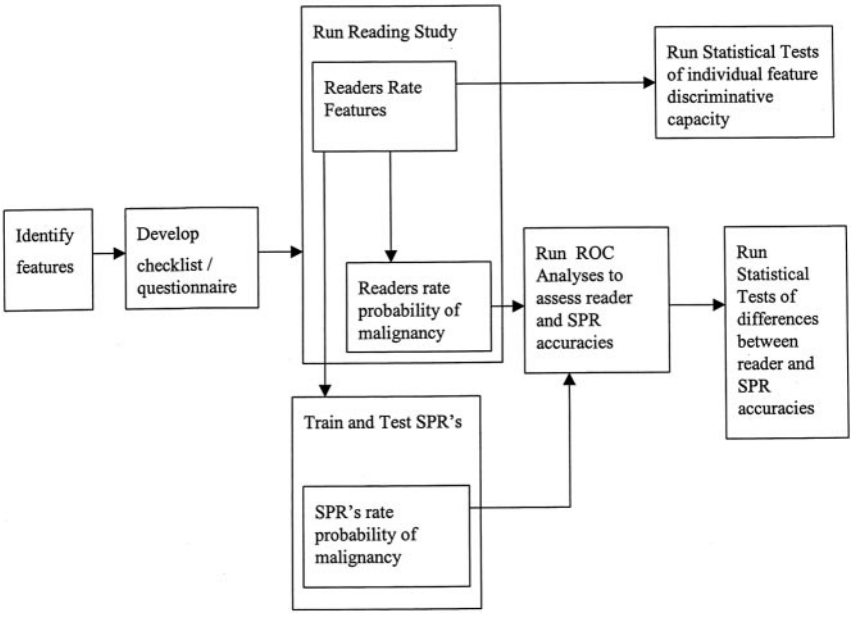

Figure 1. Study design schematic. *ROC* = receiver operating characteristic.

and (*c*) a high level of proof for the final diagnoses (either histopathologic proof [$n = 89$] or a final clinical diagnosis established on the basis of all available imaging evidence and clinical follow-up [$n = 57$]) was available. All cases were enrolled in the current study with the provision that each met minimum standards of image quality as judged by one of the investigators (M.O.S.).

The details of the patient population and of patient inclusion and exclusion from the clinical trial are reported elsewhere (13). Briefly, all patients were adults who had been referred for imaging of known or suspected focal liver lesions. In all, the patient population included 146 cases, involving 92 malignant and 54 benign lesions. Of these 146 lesions (average diameter, 4.2 cm; range, 0.8–15.0 cm), 56 contained hepatocytes, and 90 did not (Table 1). The specific types of lesions included cysts ($n = 22$), hemangiomas ($n = 17$), regenerative nodules ($n = 4$), focal nodular hyperplasia ($n = 7$), hepatocellular carcinomas ($n = 40$), cholangiocarcinomas ($n = 4$), metastases ($n = 45$), and other miscellaneous lesions ($n = 7$).

All patients underwent an initial conventional or helical, contrast-enhanced (intravenous administration; iodine, ≥45 g) CT examination that acquired at least eight scans per minute at a section thickness of 10 mm or less and a display matrix of 512 × 512 pixels. This contrast–enhanced CT study was followed by unenhanced MR imaging that included T1-weighted, breath-hold, fast gradient–recalled echo sequences (repetition time msec/echo time msec, 100–160/2–6; flip angle, 60°–90°) and T2-weighted, fast-spin echo pulse sequences (>2,500/80–110). The patient then received an intravenous injection of mangafodipir trisodium (5 μmol/kg), and contrast-enhanced MR images were obtained at 15 minutes with the same parameters as those for the unenhanced sequences. In the original clinical trial, some patients underwent MR imaging at 4 and 24 hours after injection; however, because these "delayed images" were obtained inconsistently, they were not included in the present study. All MR imaging studies were performed with a field of view fit to the patient and displayed on a matrix of 192 × 256 pixels.

Table 1
Characteristics of Lesions in Study ($n = 146$)

	Malignant	Benign	Total
Hepatocyte	41	15	56
Nonhepatocyte	51	39	90
Total	92	54	146

All images were stored in electronic format at full resolution and were viewed on workstations by the readers. Readers were blinded to the patients' identities and final diagnoses. The location of the suspicious lesion on the image was noted by one of the investigators (M.O.S.) to ensure that all readers were evaluating the same abnor-

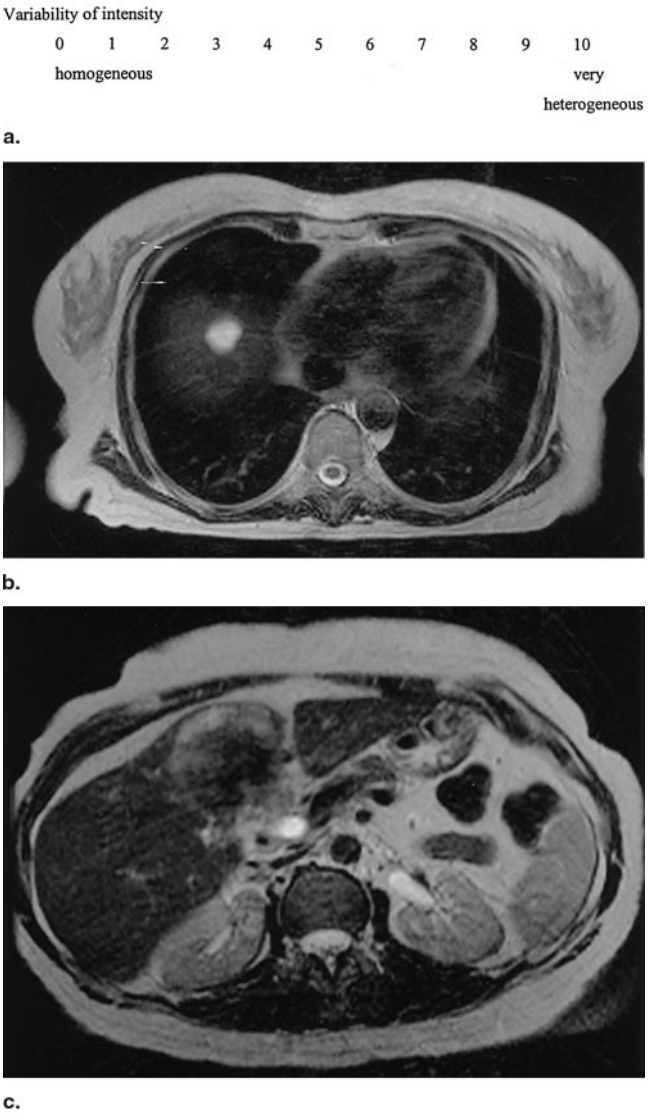

Figure 2. Lesion variability on T2-weighted, unenhanced MR images as a differentiator of benign from malignant masses. **(a)** Excerpt from the feature checklist demonstrates the rating scale for the interior substance of the lesion. Readers were instructed to circle one number on the scale. **(b)** T2–weighted MR image shows low variability. A 2-cm cyst is present in the dome of the liver. This lesion is extremely homogeneous, an appearance that is highly correlated with a benign histopathologic findings. **(c)** T2–weighted image shows high variability. A 6-cm metastasis is present in the medial segment of the left lobe of the liver. The lesion is extremely heterogeneous, an appearance that is highly correlated with malignancy.

mality. Thus, the study was structured not as a search task but, rather, as a lesion-classification task.

Readers

Six board-certified academic radiologists with subspecialty interest and experience in liver imaging (J.B., S.S., R.F.M., B.H., I.R.F., and J.C.) served as the expert readers for this study. These experts had also participated as local principal investigators in the phase III clinical trial of mangafodipir trisodium and were familiar with the physiology and pharmacology of this drug. Although each reader had previously seen as many as 15 of the cases in an unblinded fashion as part of the clinical trial, we felt confident that they would not remember specific cases. More than 18 months had elapsed since the trial, and the cases in the current study were presented as part of a large set and without identifying information (ie, no patient name or hospital of origin). In previous studies (7,11), such measures have been sufficient to avoid the introduction of memory effects or bias in a reader's feature ratings.

Feature Checklist-Questionnaire

Our first goal was to identify an exhaustive list of image-based features that the expert readers believed were useful in establishing a diagnosis and to organize these features into a checklist that permitted quantitative assessments of each. The feature checklist-questionnaire was developed in a series of steps. First, a structured interview was conducted with each of the six experts; the goal was to have each expert describe every contrast–enhanced CT, as well as unenhanced and contrast–enhanced MR imaging–based, feature that they thought could contribute diagnostic information. We next created a quantitative rating scale for each of the suggested features and compiled them into a provisional feature checklist-questionnaire. This list was then reviewed and refined at a consensus conference with the experts into a final version for use in the reading study. This final version contained 131 candidate features. To make this list more manageable, it was subdivided into categories, including "global" features (eg, liver size and shape) that were derived from inspection of the images across all modalities and "specific" features that related to the appearance of the lesion on a specific modality or pulse sequence.

Reading Procedure

Each expert rated all discernible features on images obtained with all available modalities in each of the 146 cases. Figures 2a and 3a provide examples of the type of rating scales used in this procedure. For some cases, the lesion itself (or some aspect of the lesion on which features were to be rated) was not discernible in images obtained with one or another modality, for one or another reader, and so those features were not rated. The result was a database containing much less than the 114,756

potential features (6 readers × 146 cases × 131 features). Those data, in various partitions, were used as input for training the SPRs (described later).

After completion of the feature ratings for each case, each expert reader rendered the two required differentiations based on his or her analysis of the lesion's appearance on the contrast-enhanced CT scans and on the unenhanced and contrast-enhanced MR images. On a 100-point probability scale, the reader's judgment was, first, whether the lesion was benign or malignant and, second, whether the lesion contained or did not contain hepatocytes. These differentiations were then subjected to ROC analyses to obtain a measure of accuracy for each of the differentiations (described later).

Assessing the Diagnostic Value of Individual Features: Univariate Analysis

To assess the diagnostic value of each individual feature, we conducted a univariate analysis of variance on each feature using a mixed model in which readers and cases were treated as random factors and in which pathologic characteristics or tissue type was treated as a fixed factor. The mean values associated with benign and malignant or hepatocyte-containing and non–hepatocyte-containing lesions were determined for each feature, along with the significance level in each test. Features that achieved significance levels of .05 or better were included in the final tally.

Training the Statistical Prediction Rules: Multivariate Analysis

To assess the diagnostic value of the features taken in an optimal combination, we used the pooled feature ratings of the experts to train the SPRs. This approach has been previously described (11). Briefly, stepwise multivariate linear discriminant analysis was used in which candidate features were added incrementally to the rule. At each step, the most powerful remaining feature was added, taking feature intercorrelations into account. This process continued until additional features failed to make a statistically significant contribution. The product was a prediction rule that made use of multiple features simultaneously and that assigned a weight to each feature to combine them optimally. The output of the SPR is an estimated probability of the nature of the lesion; these probabilities are used to construct ROC curves. For the current study, two sets of SPRs were trained: one for the benign versus malignant differentiation, and one for the hepatocyte-containing versus non–hepatocyte-containing

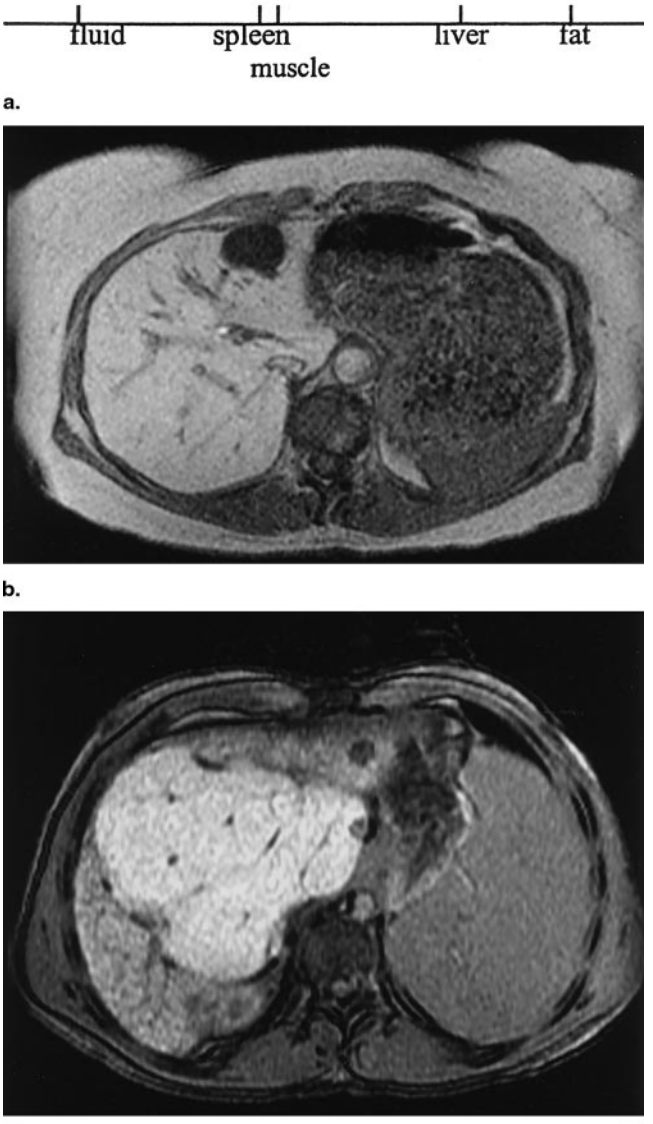

Figure 3. Lesion intensity on T1-weighted, contrast–enhanced MR images as a differentiator of non–hepatocyte-containing from hepatocyte-containing masses. **(a)** Excerpt from the feature checklist demonstrates the rating scale for lesion intensity. Readers were instructed to make a tick mark at the appropriate point on the line. Intermediate anchor points indicating the intensity of various normal tissues were provided to assist the reader. The actual metric used was the percentage of the physical distance between fluid and fat to the reader's mark. **(b)** T1–weighted, contrast–enhanced MR image shows low intensity. A 3-cm hemangioma is present in the lateral segment of the left lobe of the liver. The intensity of this lesion is similar to that of fluid or muscle, an appearance that is highly correlated with non–hepatocyte-containing masses. **(c)** T1–weighted, contrast–enhanced MR image shows high intensity. A 6 × 8-cm adenoma is present in the intersegmental portion of the liver. The intensity of the lesion is similar to that of normal liver or fat, an appearance that is highly correlated with hepatocyte-containing masses.

differentiation. When training the SPR involving a particular set of modalities, all the features for that set were candidates for inclusion in that SPR.

Evaluation of Diagnostic Accuracy

For both the benign versus malignant and the hepatocyte-containing versus non–hepatocyte-containing differentiations, the accuracy of two approaches to diagnosis could be measured: the radiologists' feature-aided diagnoses, and the SPR diagnoses. Because the SPRs were trained and tested on the same group of cases, those results required correction for an optimistic bias; therefore, a jackknifing statistical procedure was applied. We used the "leave-one-out" method, in which an SPR applied to any given case was developed on the basis of the data for all other cases (ie, with the data for the tested case omitted).

The adjunctive contribution of each imaging modality to the accuracy of the SPR was assessed by training a rule on unenhanced MR imaging features alone, then training that rule on both unenhanced and contrast-enhanced MR imaging features, then adding CT features, with its accuracy being reassessed at each step. For a particular combination of modalities, all features of those modalities were candidates for inclusion in the rule during the stepwise analysis.

Accuracy rates for the radiologist and SPR readings were analyzed by constructing separate ROC curves for each reader's differentiations. The area under the ROC curve was used as the summary measure of performance. We compared the accuracy of the expert radiologists and the SPRs by means of two-tailed, paired *t* tests.

RESULTS

We present the results first with respect to the ability of each of the individual features to discriminate between benign and malignant and between hepatocyte-containing and non–hepatocyte-containing lesions. We then review the diagnostic accuracy achieved by the expert radiologists and also by the corresponding SPRs for each of the two differentiations.

Informativeness of Individual Features

Our analysis provides evidence of the capacity of many individual features to differentiate between benign and malignant and between hepatocyte-containing and non–hepatocyte-containing lesions.

Benign versus malignant differentiations.—Table 2 lists the 37 individual image-based features that we found to discriminate between benign and malignant lesions with a significance level of .05 or better. The features are grouped according to the modality with which they were depicted. For each feature, Table 2 lists its short description, the anchor points on the scale used to rate it, the feature's mean value in benign and malignant cases, and the *P* value of the associated analysis of variance. So, for example, feature 14 is the degree of clarity or definition of the lesion border on unenhanced, T1-weighted MR images.

Using a numeric rating scale ranging from 0 (ie, a well-defined lesion border) to 10 (ie, a poorly defined border), the readers indicated that benign lesions had a statistically significantly better-defined border than malignant lesions (mean ratings, 2.6 vs 4.4; $P < .0005$).

Among the most powerful of these features was the degree of variability of the lesion interior on T2-weighted MR images (feature 31 in Table 2). As seen in Figure 2, lesions that appeared on these images to be homogeneous internally tended to be benign (Fig 2b), whereas heterogeneous lesions tended to be malignant (Fig 2c). In addition, malignant lesions tended to be conspicuous, with poor border definition, heterogeneous internal intensity, and marked contrast enhancement on both MR images and CT scans. Also, any lesion with more than one visible layer or boundary, or any lesion associated with circumferential vascular enhancement, was highly likely to be malignant (Table 2).

Hepatocyte-containing versus non–hepatocyte-containing differentiations.—Table 3 lists the 37 individual features that statistically significantly discriminate between hepatocyte-containing and non–hepatocyte-containing lesions at $P \leq .05$. Twenty-four of these 37 features also were statistically significant discriminators of benign versus malignant lesions. Again, Table 3 groups features on the basis of modality and lists the description, rating scale mean values for hepatocyte-containing and non–hepatocyte-containing lesions, and statistical significance.

A powerful feature for distinguishing between hepatocyte-containing and non–hepatocyte-containing lesions was intensity of the lesion interior on contrast-enhanced, T1-weighted MR images (feature 23 in Table 3). As seen in Figure 3, lesions that showed no contrast enhancement tended not to contain hepatocytes (Fig 3a), whereas those that showed bright contrast enhancement tended to contain hepatocytes (Fig 3b). In addition, hepatocyte-containing lesions were found in livers manifesting diffuse liver

Table 2
Image-based Features that Discriminate Benign from Malignant Lesions

Feature	Modality*	Description	Anchor Points on Scale	Mean Value		*P*
				Benign	Malignant	
1	All	Confidence regarding presence of bulging in liver contour	0 (definitely no bulging) to 10 (definitely some bulging)	2.0	3.4	.006
2	All	Confidence regarding presence of clot or tumor in portal or hepatic vein	0 (definitely no clot or tumor present) to 10 (definitely clot or tumor present)	0.4	1.2	.001
3	All	Confidence regarding presence of regional bile duct dilation	0 (definitely no regional dilation) to 10 (definitely some regional dilation)	0.2	1.0	.003
4	All	Degree of diffuse liver disease	0 (no disease) to 10 (severe disease)	1.5	2.7	.019
5	All	Number of interfaces visible (1, 2, or 3)	1–3	1.2	1.6	.000
6	CT+	Attenuation level of interior of lesion (Hounsfield units)	−80 (fat) to 1,000 (bone)	45.1	82.0	.046
7	CT+	Variability of attenuation of lesion interior	0 (homogeneous) to 10 (very hetergeneous)	2.8	4.9	.000
8	CT+	Definition of lesion border	0 (very well defined) to 10 (poorly defined)	3.4	4.9	.015
9	CT+	Percentage of area of lesion interior enhanced	0%–100%	37.4	58.4	.000
10	CT+	Shape of lesion	0 (circular) to 5 (lobular) to 10 (irregular)	2.8	4.1	.003
11	CT+	Size of lesion	Pixels (*n*)	31.4	55.5	.000
12	CT+	Second interface visible?	0 (No), 1 (Yes)	0.07	0.27	.000
13	CT+	Third interface visible?	0 (No), 1 (Yes)	0.00	0.03	.025
14	MRT1	Definition of lesion border	0 (very well defined) to 10 (poorly defined)	2.6	4.4	.000
15	MRT1	Intensity of lesion interior (arbitrary scale)	0 (fluid) to 100 (fat)	34.9	53.3	.000
16	MRT1	Variability of intensity of lesion interior	0 (homogeneous) to 10 (very hetergeneous)	1.5	3.9	.000
17	MRT1	Shape of lesion	0 (circular) to 5 (lobular) to 10 (irregular)	2.9	4.1	.002
18	MRT1	Size of lesion	Pixels (*n*)	33.1	56.6	.000
19	MRT1	Visibility of lesion	0 (not visible) to 10 (clearly visible)	8.1	7.4	.032
20	MRT1	Second interface visible?	0 (No), 1 (Yes)	0.05	0.22	.000
21	MRT1	Third interface visible?	0 (No), 1 (Yes)	0.00	0.04	.022
22	MRT1 or MRT1+	Confidence that the lesion-liver boundary interface is seen as a black line on these images	0 (definitely not seen as a black line) to 10 (definitely seen as a black line)	1.3	2.7	.007

(*continues*)

*CT+ = contrast-enhanced CT, MRT1 = T1-weighted, unenhanced MR imaging, MRT1+ = T1-weighted, contrast-enhanced MR imaging, MRT2 = T2-weighted, unenhanced MR imaging.

Table 2 (*continued*)
Image-based Features that Discriminate Benign from Malignant Lesions (continued)

Feature	Modality*	Description	Anchor Points on Scale	Mean Value		P
				Benign	Malignant	
23	MRT1+	Intensity of lesion interior (arbitrary scale)	0 (fluid) to 100 (fat)	37.4	55.4	.000
24	MRT1+	Variability of intensity of lesion interior	0 (homogeneous) to 10 (very hetergeneous)	1.5	3.0	.000
25	MRT1+	Shape of lesion	0 (circular) to 5 (lobular) to 10 (irregular)	2.9	4.3	.000
26	MRT1+	Size of lesion	Pixels (*n*)	33.7	56.1	.001
27	MRT1+	Second interface visible?	0 (No), 1 (Yes)	0.10	0.34	.000
28	MRT1+	Third interface visible?	0 (No), 1 (Yes)	0.00	0.05	.014
29	MRT2	Definition of lesion border	0 (very well defined) to 10 (poorly defined)	2.1	4.9	.000
30	MRT2	Intensity of lesion interior (arbitrary scale)	0 (muscle) to 100 (fluid)	81.2	58.8	.000
31	MRT2	Variability of intensity of lesion interior	0 (homogeneous) to 10 (very hetergeneous)	1.5	5.0	.000
32	MRT2	Shape of lesion	0 (circular) to 5 (lobular) to 10 (irregular)	2.9	4.4	.000
33	MRT2	Size of lesion	Pixels (*n*)	33.8	58.0	.001
34	MRT2	Visibility of lesion	0 (not visible) to 10 (clearly visible)	8.6	7.1	.001
35	MRT2	First interface visible?	0 (No), 1 (Yes)	0.93	0.86	.045
36	MRT2	Second interface visible?	0 (No), 1 (Yes)	0.04	0.30	.000
37	MRT2	Third interface visible?	0 (No), 1 (Yes)	0.00	0.05	.002

*CT+ = contrast-enhanced CT, MRT1 = T1-weighted, unenhanced MR imaging, MRT1+ = T1-weighted, contrast-enhanced MR imaging, MRT2 = T2-weighted, unenhanced MR imaging.

disease and tended to be larger, to be irregular in shape, and to manifest strong and variable contrast enhancement on MR images. Also, any lesion that demonstrated a black line at its boundary with the liver on T1-weighted MR images or that was associated with bile duct dilatation was highly likely to contain hepatocytes.

Accuracy of the Diagnoses of Each Type

Radiologists.—As indicated in Table 4 and in Figures 4 and 5, radiologists were able to classify liver lesions correctly with high levels of accuracy. A_z values exceeded 0.90 for both the benign versus malignant and the hepatocyte-containing versus non–hepatocyte-containing differentiations, reaching 0.929 ± 0.034 (mean ± standard deviation) and 0.926 ± 0.040, respectively. (Individual reader results for the benign vs malignant differentiation were 0.872, 0.960, 0.910, 0.935, 0.936, and 0.965; individual reader results for the hepatocyte-containing vs non–hepatocyte-containing differentiation were 0.944, 0.953, 0.929, 0.928, 0.953, and 0.848.) This high absolute level of performance indicates that, using the feature checklist, the experts were able to integrate effectively image-based information across CT scans, unenhanced MR images, and contrast-enhanced MR images.

In practical terms, one can translate this level of performance into a family of specificity and sensitivity values for the combined CT and MR imaging readings. For example, if one were to fix the specificity rate at 90% (ie, implying a "false–positive" or overall rate of 10%), then the radiologists could achieve sensitivities (ie, true-positive rates) of 79% for benign versus malignant differentiation and 80% for hepatocyte-containing versus non–hepatocyte-containing differentiation.

Statistical prediction rules.—As seen in Table 2 and in Figures 4 and 5, the SPRs also performed at a high level of accuracy. At their best, the SPRs outperformed the expert radiologists' own readings, with A_z values reaching 0.936 (0.007 better than the radiologists, $P = .69$) and

Table 3
Image-based Features that Discriminate Hepatocyte-containing from Non–Hepatocyte-containing Lesions

Feature	Modality*	Description	Scale	Mean Value		P
				Nonhepatic	Hepatic	
1	All	Confidence regarding presence of bulging in liver contour	0 (definitely no bulging) to 10 (definitely some bulging)	1.7	4.8	.000
2	All	Confidence regarding presence of clot or tumor in portal or hepatic vein	0 (definitely no clot or tumor present) to 10 (definitely clot or tumor present)	0.4	1.6	.000
3	All	Confidence regarding presence of retraction in liver contour	0 (definitely no retraction) to 10 (definitely some retraction)	0.5	1.7	.000
4	All	Degree of diffuse liver disease	0 (no disease) to 10 (severe disease)	0.8	4.6	.000
5	All	Number of other similar lesions (0, 1, 2, 3, or more)	0–4	1.1	0.8	.035
6	All	Which visible interface is the boundary between the lesion and the liver?	1 (outer), 2 (inner), or 3 (innermost)	1.11	1.02	.000
7	CT+	Lesion visible?	0 (No), 1 (Yes)	0.96	0.88	.008
8	CT+	Degree of visibility	0 (not visible) to 10 (clearly visible)	8.3	6.9	.000
9	CT+	Attenuation level of interior of lesion (Hounsfield units)	−80 (fat) to 1,000 (bone)	49.3	102.0	.002
10	CT+	Variability of attenuation of lesion interior	0 (homogeneous) to 10 (very hetergeneous)	3.7	4.8	.033
11	CT+	Definition of lesion border	0 (very well defined) to 10 (poorly defined)	3.7	5.4	.000
12	CT+	Degree of maximum enhancement of lesion interior	0 (no enhancement) to 10 (very high enhancement)	2.8	4.6	.000
13	CT+	Percentage of area of lesion interior enhanced	0%–100%	40.1	69.3	.000
14	CT+	Size of lesion	Pixels (*n*)	40.1	57.9	.011
15	MRT1	Definition of lesion border	0 (very well defined) to 10 (poorly defined)	3.0	5.1	.000
16	MRT1	Intensity of lesion interior (arbitrary scale)	0 (fluid) to 100 (fat)	39.0	59.5	.000
17	MRT1	Variability of intensity of lesion interior	0 (homogeneous) to 10 (very hetergeneous)	2.0	4.8	.000
18	MRT1	Size of lesion	Pixels (*n*)	40.0	61.2	.000
19	MRT1	Visibility of lesion	0 (not visible) to 10 (clearly visible)	8.2	6.6	.000
20	MRT1 or MRT1+	Confidence that the lesion-liver boundary interface is seen as a black line on these images	0 (definitely not seen as a black line) to 10 (definitely seen as a black line)	0.9	4.4	.000

(*continues*)

*CT+ = contrast-enhanced CT, MRT1 = T1-weighted, unenhanced MR imaging, MRT1+ = T1-weighted, contrast-enhanced MR imaging, MRT2 = T2-weighted, unenhanced MR imaging.

Table 3 (*continued*)
Image-based Features that Discriminate Hepatocyte-containing from Non–Hepatocyte-containing Lesions (continued)

Feature	Modality*	Description	Scale	Mean Value		P
				Nonhepatic	Hepatic	
21	MRT1+	Lesion visible?	0 (No), 1 (Yes)	1.00	0.98	.006
22	MRT1+	Definition of lesion border	0 (very well defined) to 10 (poorly defined)	1.6	3.5	.000
23	MRT1+	Intensity of lesion interior (arbitrary scale)	0 (fluid) to 100 (fat)	36.0	69.4	.000
24	MRT1+	Variability of intensity of lesion interior	0 (homogeneous) to 10 (very hetergeneous)	1.5	4.1	.000
25	MRT1+	Degree of maximum enhancement of lesion interior	0 (no enhancement) to 10 (very high enhancement)	0.4	3.7	.000
26	MRT1+	Percentage of area of lesion interior enhanced	0%–100%	15.8	60.0	.000
27	MRT1+	Size of lesion	Pixels (*n*)	40.0	60.4	.002
28	MRT1+	Visibility of lesion	0 (not visible) to 10 (clearly visible)	9.1	7.4	.000
29	MRT1+	Second interface visible?	0 (No), 1 (Yes)	0.21	0.31	.046
30	MRT2	Lesion visible?	0 (No), 1 (Yes)	0.97	0.85	.001
31	MRT2	Definition of lesion border	0 (very well defined) to 10 (poorly defined)	3.0	5.5	.000
32	MRT2	Intensity of lesion interior (arbitrary scale)	0 (muscle) to 100 (fluid)	74.9	53.7	.000
33	MRT2	Variability of intensity of lesion interior	0 (homogeneous) to 10 (very hetergeneous)	2.9	5.0	.000
34	MRT2	Shape of lesion	0 (circular) to 5 (lobular) to 10 (irregular)	3.4	4.6	.018
35	MRT2	Size of lesion	Pixels (*n*)	39.3	65.9	.000
36	MRT2	Visibility of lesion	0 (not visible) to 10 (clearly visible)	8.4	6.4	.000
37	MRT2	First interface visible?	0 (No), 1 (Yes)	0.92	0.83	.014

*CT+ = contrast-enhanced CT, MRT1 = T1-weighted, unenhanced MR imaging, MRT1+ = T1-weighted, contrast-enhanced MR imaging, MRT2 = T2-weighted, unenhanced MR imaging.

0.951 (0.025 better than the radiologists, $P = .11$) for benign versus malignant and hepatocyte-containing versus non–hepatocyte-containing, respectively. Again, if one were to fix the specificity rate at 90%, then use of the SPRs would improve the sensitivities to 82% and 86% for the two decisions, respectively.

For both the benign versus malignant and the hepatocyte-containing versus non–hepatocyte-containing decisions, the SPR results are orderly, with A_z values rising incrementally, in general, as features from each new modality are added. Specifically, even though the SPR trained on unenhanced MR images and global features performed well, the addition of features from the contrast-enhanced MR imaging study increased its performance (A_z) by 0.019 ($P = .007$) and 0.026 ($P = .066$) for the two differentiations. Adding contrast–enhanced CT scan–based features produced yet another 0.017 improvement ($P = .015$) in A_z for the benign versus malignant differentiation but no further improvement of the hepatocyte-containing versus non–hepatocyte-containing differentiation.

Thus, particularly for the benign versus malignant differentiation, adding image data from several modalities can be useful. At a fixed specificity of 90%, the sensitivity of reading MR images alone (plus global features) was 65%, and this sensitivity increased to 74% with the addition of contrast-enhanced MR images and to 82% with the addition of contrast-enhanced CT data. Effectively, this means that 17 additional patients per 100 studied would have a malignant liver lesion diagnosed correctly if data from unenhanced MR imaging, contrast-enhanced MR imaging, and CT were combined compared the situation with MR imaging alone.

It would be misleading to consider the magnitude of these accuracy increments as being a pure measure of the

adjunctive contributions by each modality. Because the incorporated "global" features derived from all modalities into all its calculations, even that for unenhanced MR imaging, then the adjunctive value of contrast-enhanced MR or CT were "discounted." The increments in accuracy that were observed represent the minimum additional contribution that these other modalities could have made.

DISCUSSION

We believe that this study fulfilled its major objective, namely, to measure the contributions of image-based features to the problem of liver-lesion classification, and that we demonstrated clearly the validity and effectiveness of the feature-based technique. In this process, we produced lists of specific imaging features contributing to each of the differentiations from each of the modalities. These should be useful for training radiologists to conduct these complex diagnoses more on a par with the experts, and they may well facilitate better communication not just for diagnosis but also for pursuing a better understanding of the disease process.

The value of the checklist-questionnaire derives, we think, from two main effects: improving the radiologists' reliability in addressing each relevant feature, and improving how they do it. This approach recognizes that whereas experienced readers can bring enormous intelligence and analytic capability to the task, they are substantially limited in their abilities to keep track of the numerous features to be considered and to produce from those considerations a set of clear, specific, and memorable impressions. The checklist-questionnaire should be helpful in both regards, because it leads the reader to reliably consider every one of the informative features in an explicit and well-focused way.

The value of the computerized system in assisting the radiologist with merging the image-feature data is also evident. Use of such an expert system has been validated in other contexts, including the classification of breast tumors (9) and the staging of prostate cancer (11,12). This approach recognizes that readers are limited when it comes to efficiently merging a number of features into a summary conclusion, particularly when the number of features to be merged is as large as it was here, whereas computers can do so efficiently. Therefore, in this study, we looked for a gain in accuracy when an SPR rather than a radiologist merges the features, and the study design provided a reasonably good test of that expectation. The SPRs for the two differentiations that were trained and tested on the feature data from all the modalities together might reasonably be expected to do better than the readers in this same situation (who need to merge all the information in their own minds). Performance of the SPRs might also be expected to reflect the best of both worlds—highly effective gathering of the feature data by the radiologists, and highly effective merging of those data by the SPRs—and the results do suggest this to be the case. The differences were not statistically significant, but the SPRs did show a larger A_z score for both differentiations.

How the checklist-questionnaire and the computer aid for merging the feature data worked together so effectively to mediate such a high degree of accuracy also deserves some discussion. Just adding the contrast-enhanced MR imaging modality would be expected to increase accuracy, because it also adds independent information that, if combined effectively with the other two modalities, should help. The combined information ought to be particularly advantageous, because the three modalities generate information based on three different tissue characteristics: x-ray attenuation coefficient (for CT), proton relax-

Table 4
Performance of Radiologists and SPRs

Diagnosis	Benign vs Malignant	Hepatocyte-containing vs Non–Hepatocyte-containing
Readers (feature-aided)	0.929 ± 0.034	0.926 ± 0.040
SPR		
Global and MR imaging*	0.900 ± 0.037	0.929 ± 0.019
Global, MR imaging, and contrast material†	0.919 ± 0.031‡	0.955 ± 0.012‡
Global, MR imaging, contrast material, and CT§	0.936 ± 0.027‡	0.951 ± 0.010‡

Note.—All values are mean A_z ± standard deviation.

*Derived from general features from all modalities (global) plus specific features derived from MR imaging without contrast material.

†Derived from general features from all modalities (global) plus specific features derived from MR imaging without contrast material, but adding features derived from contrast-enhanced MR imaging.

‡$P < .10$ compared with global and MR imaging (two-tailed, paired t test).

§Derived from general features from all modalities (global) plus specific features derived from MR imaging without contrast material plus features derived from contrast-enhanced MR imaging, but adding features derived from CT.

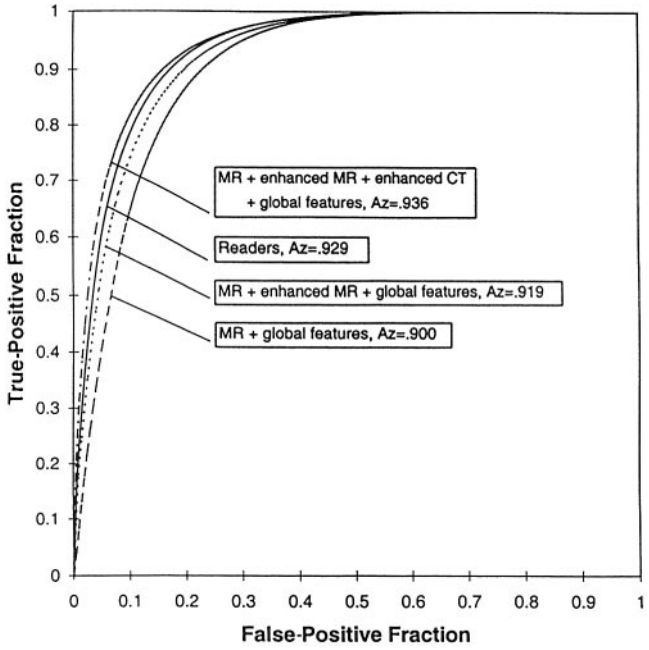

Figure 4. ROC curves for the malignant versus benign differentiation. *Az* = area under the ROC curve.

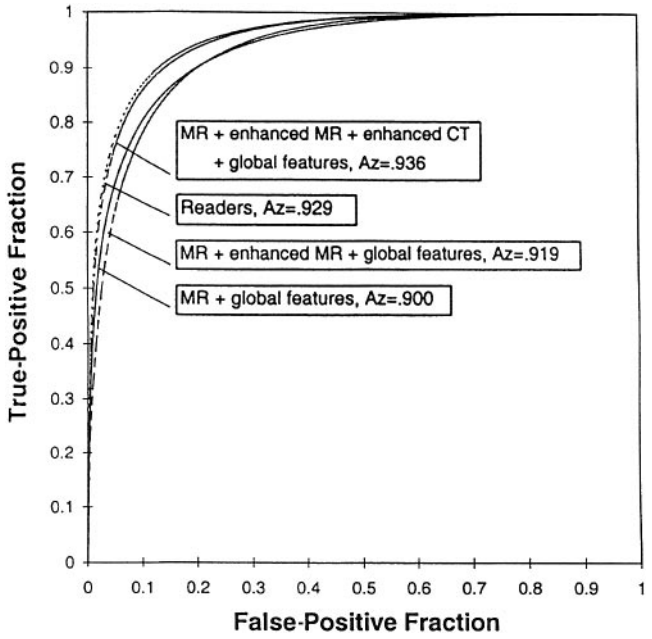

Figure 5. ROC curves for the hepatic versus nonhepatic differentiation.

ation times (for MR imaging), and information on specific membrane receptors (for contrast-enhanced MR imaging). The particular advantage of the two parts of the feature-based technique (ie, the checklist and the SPR) when used in combination is that they enable merging of the information across the three modalities at the "feature level." When using multiple modalities, radiologists conventionally will attempt to merge the findings at the "diagnosis level"; that is, they will determine a working or a differential diagnosis for a candidate lesion on the basis of one modality and seek to establish a confirmatory diagnosis on the basis of a second. Such an approach can founder, however, if the findings from the two modalities are perceived to be incongruent or contradictory. On the other hand, the combination of information at the feature level permits the rationalization of diagnostic judgments across modalities and the generation of a single conclusion by the radiologist or, in this study, by the computer advisor.

The checklist-questionnaire, when used in combination with computer merging, has also contributed substantially to an understanding of how each of the modalities, particularly contrast-enhanced MR imaging, contributes to the differentiations. Because experience with hepatocyte-specific contrast media is limited, even our expert radiologists disagreed somewhat before the study began about which image-based features were most relevant. The diversity of their opinion was reflected in the enormous list of potential candidate features that they generated for the master list. The application of a statistically rigorous analysis of the value of these features permitted us to extract the most contributory ones and to allow this more limited set to be used efficiently. The full identification and effective use of those key features might not have occurred had we followed the conventional approach of merging information at the diagnosis level. The primary benefit one might seek to reap from identifying these features would be to improve diagnostic accuracy, but another important potential benefit would be to improve one's understanding of the disease process (eg, to relate specific image features to tissue correlates).

The previous discussions make evident that the computer aid has an important potential role in establishing a diagnosis, but an important caveat must be stated. The SPR works on a reduced set of features that deliver the greatest diagnostic power when used in combination. Because some features are highly correlated with one another, the rule typically uses only the best feature in a class, and it actually may discard individually powerful features that do not add incremental value. Therefore, experienced diagnosticians may note that the reduced set of features used by the SPRs may not contain one or

more features that they find to be both useful and reliable. Their deletion certainly does not imply that such features are irrelevant. Indeed, such features may be critically informative in specific cases.

Our study design also had some limitations. First, we could not accurately determine the separate contributions of each modality to the high level of classification accuracy achieved when using them together, nor could we draw any conclusions regarding the relative values of CT or MR imaging for this task. This limitation derives fundamentally from this work not being designed as a technology-assessment study. That is, cases were not evaluated prospectively, several valuable new techniques (eg, hepatic arterial phase CT) were not included, and readers had information available from all modalities when making their diagnostic and feature-rating judgements. Such a formal technology-assessment study for the classification of liver tumors would be interesting and worthwhile but is beyond the scope of this work.

A second important limitation was that our observation of both radiologists and SPRs achieving high accuracy ratings when using features from all modalities is tempered by the absence of an appropriate control condition or study against which our overall result can be compared. We have looked for comparable classification accuracies in other published studies on liver-lesion diagnosis, but virtually all such potential literature-based control studies involve the element of lesion detection in addition to classification, making the relevant comparisons invalid. The unaided readings of our cases in the original clinical trial of mangafodipir trisodium come as close as we can get to an adequate control study, but that comparison is also compromised. The cases were, in fact, the same in both studies. The clinical trial used an expanded and more diverse set of readers, however, and no single reader in that study read the entire case set. Also, the readers' tasks and reading environments were different. The way in which accuracy was scored in the two studies was different, as well.

A third limitation is that the SPRs were trained and tested with the same case sets. Jackknifing is a well-established procedure to reduce substantially the amount of optimistic bias that can be introduced by this economic use of cases. Therefore we believe, though we cannot be certain, that the magnitude of any remaining bias in the present study is small. Despite our desire to have an entire case set reserved just for testing the SPR, such a large number of additional cases was not available.

Finally, we would have preferred that our case set contained even more imaging "modalities" (eg, arterial phase, contrast-enhanced CT; gadolinium-enhanced MR imaging; in-phase/out-of-phase MR imaging; calculated T2-weighted relaxation times; ultrasound; and nuclear medicine studies). We were limited, however, to the modalities used in the mangafodipir trisodium clinical trial. We are optimistic that features derived from any additional modalities will further enhance the power of the feature-based approach to lesion diagnosis and that our current results may actually be conservative.

The results of this study show that multimodality liver imaging makes positive contributions to both of the differentiations examined with each modality through each of several different features. We have also established the important adjunctive contribution of the contrast agent for increasing the accuracy of both differentiations. Clarification regarding which particular features are diagnostically informative in each modality should be helpful even to experienced radiologists when dealing with the complexity of multiple modalities, and it should surely be of help to them in training novices. Indeed, the results suggest that the accuracy of diagnosis, even by experienced radiologists, can be improved by taking into account the "second opinions" of the fully informed SPR developed here.

Our findings reinforce the notion that sophisticated use of the diagnostic tools in our current arsenal can improve our approach to patients with liver lesions. We also believe that this general approach will be effective in many other multimodality, image-based diagnostic contexts.

ACKNOWLEDGMENTS

The authors thank Eileen Concannon, Betty Emanuel, Stephanie Papcun, Shari Houtman, and Katie Dittami for their help with manuscript preparation.

REFERENCES

1. Hamm B, Thoeni RF, Gould RG, et al. Focal liver lesions: characterization with nonenhanced and dynamic contrast material-enhanced MR imaging. Radiology 1994; 190:417–423.
2. Ito K, Mitchell DG, Outwater EK, Szklaruk J, Sadek AG. Hepatic lesions: discrimination of nonsolid, benign lesions from solid malignant lesions. Radiology 1997; 204:729–737.
3. Rummeny E, Ehrenheim C, Gehl HB, et al. Manganese-DPDP as a hepatobiliary contrast agent in the magnetic resonance imaging of liver tumors. Invest Radiol 1991; 26(suppl):S142–S145.
4. Rofsky NM, Weinreb JC, Bernardino ME, Young SE, Lee JKT, Noz ME. Hepatocellular tumors: characterization with Mn-DPDP-enhanced MR imaging. Radiology 1993; 188:53–59.

5. Hamm B, Vogl TJ, Branding G, et al. Focal liver lesions: MR imaging with MnDPDP—initial clinical results in 40 patients. Radiology 1992; 182:167–174.
6. Ros PR, Freeny PC, Harms SE, et al. Hepatic MR imaging with ferumoxides: a multicenter clinical trial of the safety and efficacy in the detection of focal hepatic lesions. Radiology 1995; 196:481–488.
7. Getty DJ, Pickett RM, D'Orsi CJ, Swets JA. Enhanced interpretation of diagnostic images. Invest Radiol 1988; 23:240–252.
8. Swets JA, Getty DJ, Pickett RM, D'Orsi CJ, Seltzer SE, McNeil BJ. Enhancing and evaluating diagnostic accuracy. Med Decis Making 1991; 11:9–18.
9. Seltzer SE, McNeil BJ, D'Orsi CJ, Getty DJ, Pickett RM, Swets JA. Combining evidence from multiple imaging modalities: a feature-analysis method. Comput Med Imaging Graph 1992; 16:373–380.
10. D'Orsi CJ, Getty DJ, Swets JA, Pickett RM, Seltzer SE, McNeil BJ. Reading and decision aids for improved accuracy and standardization of mammographic diagnosis. Radiology 1992; 185:619–622.
11. Seltzer SE, Getty DJ, Tempany CMC, et al. Combined radiologist-computer system for staging prostate cancer by magnetic resonance imaging. Radiology 1997; 202:219–226.
12. Getty DJ, Seltzer SE, Tempany CMC, Pickett RM, Swets JA, McNeil BJ. Improved staging of prostate cancer: the relative contributions of age, PSA, biopsy Gleason score and aided MR. Radiology 1997; 204: 471–479.
13. Federle MP, Chezmar JL, Rubin DL, et al. Safety and efficiency of mangafodipir trisodium (MnDPDP) injection for hepatic MRI in adults: results of the U.S. multicenter phase III clinical trials (safety). J Magn Reson Imaging 2000; 12:186–197.