The Arts in Psychotherapy 71 (2020) 101690

Contents lists available at ScienceDirect

The Arts in Psychotherapy

journal homepage: www.elsevier.com/locate/artspsycho

Research Article

Drawing on the brain: An ALE meta-analysis of functional brain activation during drawing

Frances J. Griffith[a,*], Verner P. Bingman[b]

[a] Department of Psychology, Bowling Green State University, United States
[b] Department of Psychology and J.P. Scott Center for Neuroscience, Mind & Behavior, Bowling Green State University, United States

ARTICLE INFO

Keywords:
Activation likelihood estimation (ALE)
Functional brain activation
Functional magnetic resonance imaging (fMRI)
Neuroimaging
Expressive therapies continuum (ETC)

ABSTRACT

Art therapy researchers and practitioners are increasingly interested in the brain mechanisms underlying art therapy, an investigation area associated with almost no neuroimaging research. Lusebrink (2010) hypothesized that expression at different levels of the Expressive Therapies Continuum (ETC) would be supported by different patterns of functional brain activation. In the current study, we tested Lusebrink's (2010) hypotheses through an activation likelihood estimation (ALE) meta-analysis of past neuroimaging research as participants engaged in different drawing tasks. Results supported our predictions that *cognitive drawing*, operationalized by internally-cued drawing stimuli or objective drawing content, would be associated with activation of the prefrontal and cingulate cortices. However, results failed to support our predictions that *perceptual drawing*, operationalized by externally-cued drawing stimuli and nonobjective drawing content, would be associated with activation of the ventral visual pathway in the temporal lobe. Perceptual drawing was associated with cerebellum, frontal, and parietal lobe activation (including the motor and somatosensory cortices). The dorsal visual pathway, largely in the parietal lobe, was engaged during cognitive and perceptual drawing. Our findings on patterns of brain activation can inform broader neuroscientific conceptualizations of the ETC framework and future directions for art therapy research and practice.

Introduction

Art therapists increasingly theorize about the neural mechanisms behind art therapy processes (Bednash, 2016). Despite observed changes in behavior in art therapy participants, changes at the neurocognitive level underlying outward therapeutic change remain understudied. There is little research using neuroimaging to study functional brain activation, connectivity, or structural change during and after art therapy (Belkofer, Van Hecke, & Konopka, 2014). Directed drawing, by contrast, is one art making process that is commonly studied by neuroimaging in the context of neurocognitive assessment or as a control condition for handwriting in studies of writing-specific brain regions (Beeson et al., 2003; DeMarco, Wilson, Rising, Rapcsak, & Beeson, 2017; Yang et al., 2019). In the current study, we used past neuroimaging research to conduct activation likelihood estimation (ALE) meta-analyses of functional brain activation during drawing. This enabled us to test hypotheses that specific neural regions are associated with artistic expression at different levels of the Expressive Therapies Continuum (ETC).

Neuroscience and drawing

The neural control of various drawing tasks has been well-researched, including the use of drawing in clinical applications. Neuroscientists have studied the ways in which drawing tasks can enhance neuroplasticity to correct for neural deficits (Cacciamani & Likova, 2017; Farias, Davis, & Harrington, 2006; Likova, 2012). Cacciamani and Likova (2017) found that training participants with congenital and acquired blindness in a memory-guided drawing task enhanced reorganization of the primary visual cortex (V1) using tactile memory representations. This was demonstrated by increased perirhinal cortex-to-V1 Granger causality. Farias et al. (2006) compared writing and drawing tasks for people with aphasia and found that drawing enhanced accurate object naming responses more than writing the names of those objects.

Objective vs. nonobjective drawing

Neuroimaging research has made the distinction between objective and nonobjective content in drawing tasks, finding differences in functional brain activation depending, for example, on whether the

* Corresponding author at: Bowling Green State University, Bowling Green, OH, 43403, United States.
E-mail address: fgriffi@bgsu.edu (F.J. Griffith).

https://doi.org/10.1016/j.aip.2020.101690
Received 3 April 2020; Received in revised form 25 July 2020; Accepted 2 August 2020
Available online 06 August 2020
0197-4556/ © 2020 Elsevier Ltd. All rights reserved.

participant was drawing faces from observation or copying geometric figures (Miall, Nam, & Tchalenko, 2014; Solso, 2001). Miall et al. (2014) found heightened activation bilaterally in the frontal, temporal, and occipital lobes, including the fusiform face area, when participants drew faces compared to abstract figures. Contrasting drawing familiar objects from memory to drawing abstracts from memory, Harrington, Farias, and Davis (2009) also found significantly more activation in the frontal, temporal, and parietal lobes, mostly in the left hemisphere.

Internally-cued vs. externally-cued drawing

Neuroimaging studies have also investigated differential patterns of brain activation based on the origin of the stimuli to be drawn. Drawing can be externally-cued by stimuli (such as drawing from observation, copying, or tracing) or internally-cued (such as generating original imagery or drawing from memory; Gowen & Miall, 2007; Ogawa & Inui, 2009). Gowen and Miall (2007) found that externally-cued tracing produced significantly more activation in the occipital lobe than internally-cued drawing of shapes. Similarly, Ogawa and Inui (2009) found more bilateral activation in the occipital lobe for externally-cued, visually guided drawing than internally-cued drawing from memory. Internally-cued drawing resulted in significantly more activation in the frontal and parietal lobes.

Art therapists and clinical neuroscience

There is a wealth of theoretical work by art therapists identifying potential neural mechanisms relevant to art therapy processes. (Hass-Cohen and Findlay, 2015) defined the Art Therapy Relational Neuroscience (ATR-N) approach with neuroscientific principles at work during art therapy: Creative embodiment; Relational resonating; Expressive communicating; Adaptive responding; Transformative integrating; and Empathizing and compassion (*CREATE*). Hass-Cohen and Findlay (2015) described how art experiences may enhance emotional regulation by modulating neurocognitive processes. They hypothesized that interconnections among the limbic, somatosensory, and cerebellar motor systems are engaged during the continuous voluntary movement and sensory stimulation with tactile art materials like clay. Hass-Cohen and Findlay also asserted that planning more complex artworks may enhance cognitive processes by demanding attention, concentration, and decision-making using the frontal lobe. Most recently, Hass-Cohen and Findlay (2019) integrated ATR-N approaches with memory reconsolidation (MR) interventions in a drawing protocol for people who had experienced trauma.

Like neuroscientists studying congenital blindness and aphasia (Cacciamani & Likova, 2017; Farias et al., 2006), art therapists have theorized about the ability of art-based interventions to promote neural plasticity and reorganization. Kane (2013) discussed how art making may promote neuroplasticity through its provision of novel experiences. New art media and processes require the artist to learn new procedures and solve new problems, forming neural connections that can be rehearsed through continued art making (Kane). Similarly, Stewart (2004) asserted the importance of art making as part of treating patients with dementia, because art can capitalize on neurocognitive processes localized in less affected areas of the brain, especially regions that support nonverbal as opposed to verbal communication and self-expression.

Despite the neuroscience-theoretical work by art therapists, there is little research using neuroimaging before, during, or after art therapy. We conducted an informal review of *The Arts in Psychotherapy* and *Art Therapy* using the search terms: "fMRI" [functional magnetic resonance imaging], "fNIRS" [functional near-infrared spectroscopy], "EEG" [electroencephalograph], and "MoBI" [mobile brain/body imaging], and found only four studies using these scanning techniques. Belkofer and Konopka (2008) found significantly increased alpha and beta wave activity after painting and drawing. Similarly, Belkofer et al. (2014) found changes in alpha wave activity after drawing in both artists and non-artists. These results suggest that art-making may increase states of relaxation associated with higher alpha wave activity. Kruk, Aravich, Deaver, and deBeus (2014) found increased gamma wave activity in the right parietal lobe during both drawing and clay-sculpting conditions. The clay-sculpting condition was also associated with decreased gamma activity in the right medial frontal lobe and increased theta activity, which is associated with more meditative states. Kaimal et al. (2017) used fNIRS and found medial prefrontal cortex activation during coloring, doodling, and free drawing. Kaimal et al. discussed the potential perception of rewards during art-making. In an fMRI study of service members, Walker, Stamper, Nathan, and Riedy (2018) found correlations between graphic elements of service members' artwork and several neuropsychiatric measures: thalamic connectivity, brain scars, and PTSD indicators.

The expressive therapies continuum

The Expressive Therapies Continuum (ETC) in art therapy can further contextualize neuroscience research in a way that is relevant for art therapists (Lusebrink, 1990, 2010). Introduced by Kagin and Lusebrink (1978), the ETC gives a framework for artistic engagement with different art media through three hierarchical levels ascending from the kinesthetic/sensory level, to the perceptual/affective level, to the cognitive/symbolic level. A fourth, creative level transcends and integrates the other levels during the artistic process (Kagin & Lusebrink). The ETC as a conceptual framework enables art therapists to discern which art media may be beneficial in therapy and whether a client is able to progress through levels or not (potentially indicative of pathology; Lusebrink, 1990). According to Lusebrink (1990), engagement at the kinesthetic/sensory level is marked by either vigorous movement (kinesthetic) or tactile exploration of textures (sensory). Art making at the perceptual/affective level involves an emphasis on line, shape, and form in artwork (perceptual) or increased emotional expression and varied colors in artwork (affective). The cognitive/symbolic level of the ETC is associated with artwork composition, concept formation, and verbal integration (cognitive) or personal symbol formation and autobiographical memory (symbolic).

Lusebrink (2010) hypothesized that the levels of the ETC correspond to distinct neural processes and structures, which are engaged when an artist is operating at the corresponding level with art media. She suggested that engagement with art materials at the kinesthetic or sensory first level is likely to be associated with the primary motor cortex (kinesthetic) or the primary somatosensory cortex (sensory). Art making at the perceptual or affective second level was hypothesized to be associated with the ventral visual pathway (the "what" pathway) in the temporal lobe (perceptual) or the amygdala and other limbic structures (affective). Finally, according to Lusebrink, engagement with media at the cognitive or symbolic third level may be associated with the prefrontal and anterior cingulate cortices (cognitive) or the orbitofrontal and posterior cingulate cortices (symbolic).

Current analysis

In the reported meta-analyses, we examined previously published, functional brain activation data acquired while participants were engaged in different drawing tasks with the purpose of informing art therapy research and practice. We conducted ALE meta-analyses to test predictions that drawing tasks approximating different ETC components would result in different patterns of brain activation.

Operating definitions

The ETC as a theoretical model of both engagement with art media and neurocognitive processes may help regionally localize artistic processes in the brain (Lusebrink, 2010). In past research on the neural organization of drawing, procedures have been subdivided based on the drawing content (objective or nonobjective) and the origin of the drawing stimulus (internally-cued or externally-cued). Almost all these

experimental drawing tasks can be conceptualized as occurring primarily at the cognitive or perceptual level of the ETC. However, it is important to note that drawing is just one artistic process and these tasks are only one way of many to demonstrate levels of the ETC.

For the purposes of this study, *cognitive drawing* was operationalized in two different ways based on art therapy literature and trends in neuroimaging research. First, we approximated cognitive drawings as having objective content representing a person, place, or thing, because these drawings involve aspects of the cognitive ETC level according to Lusebrink (1990, 2010): planning, step-by-step procedures, and verbal concept associations. Regarding stimuli, internally-cued drawings were similarly chosen to approximate cognitive drawings, because generating original imagery or imagery from memory also require compositional planning and associated verbal concepts. Hinz (2009) gave examples of cognitive drawing tasks, such as lifelines, genograms, or cognitive maps, as interventions that help art therapy participants structure and reflect on past experiences, learn new skills, enhance cognitive ability, or process traumatic events in a more reflective, integrated narrative. It is noteworthy that these tasks may involve symbolic and affective components in an art therapy setting, but the highly controlled tasks of the reviewed neuroscience research (such as looking at a drawing of a house and then drawing it from memory) would involve little to no emotional content for participants.

We also operationalized *perceptual drawing* in two different ways by both content and stimuli. We first approximated perceptual drawings as those not intended to represent objects, places, or people. Drawing nonobjective content was chosen due to Lusebrink's (1990, 2010) assertion that expression at the perceptual level of the ETC emphasizes line, shape, and form. Hinz (2009) discussed nonrobjective drawing as an example of a perceptual art therapy intervention with couples or families. Externally-cued drawings were also chosen to approximate perceptual drawing due to their basis in visual perception as the drawings' inspiration. Hinz also described externally-cued still life drawings as an example of a perceptual drawing intervention that could be grounding and reality-orienting.

Based on Lusebrink's (2010) conjectures about neural activation during artistic expression at the cognitive and perceptual levels of the ETC, we predicted that:

1 *Objective drawings (one example of cognitive drawing*) will be associated with increased functional activation in the prefrontal and cingulate cortices, whereas *nonobjective drawings (one example of perceptual drawing*) will be associated with increased activation of the ventral visual pathway regions of the temporal lobe.
2 *Internally-cued drawings (one example of cognitive drawing)* will be associated with increased activation in the prefrontal and cingulate cortices, whereas *externally-cued drawings (one example of perceptual drawing)* will be associated with increased activation of the ventral visual pathway regions of the temporal lobe.

Methods

Study selection

Our inclusion criteria for studies were: 1. Participants engaged in some form of drawing (mark-making on a surface, mark-making movements without a surface, or trained imaginal mark-making if not letters) and 2. Participants underwent fMRI scans *during* the drawing tasks with published activation coordinates. Control conditions for most of the studies required subjects to scribble or tap with their hands. At times, the drawing task was itself the control condition in comparison to handwriting. A Web of Science search was conducted using the following criteria: Topic = fMRI + drawing; Language = English; Document Types = Article. The search was followed by an initial title reading and cut, an abstract review and cut, and a full-text review and cut based on methods and published results.

For the articles selected for the review, we converted all activation foci to the Montreal Neurological Institute (MNI) coordinates system. Then, we categorized experimental sets of foci based on predetermined binary drawing task categories: objective drawing content (e.g. faces, familiar objects, etc.) or nonobjective drawing content (e.g. lines, geometric figures, etc.); internally-cued drawing stimuli (e.g. generating original imagery, drawing from memory) or externally-cued drawing stimuli (e.g. observational drawing, copying, tracing).

ALE meta-analysis

We used ALE meta-analysis through the *GingerALE* software in the BrainMap suite (Laird et al., 2009; http://brainmap.org/ale). ALE uses the three-dimensional coordinates of activation (or foci) from fMRI studies to find areas of convergence among brain regions of activation across multiple studies of a process or task (Laird et al.). Due to the spatial uncertainty of activation coordinates obtained using fMRI, ALE meta-analysis first models reported foci as the center of spatial probability distributions (Eickhoff et al., 2009). An ALE map is created to identify convergence of activation foci between fMRI experiments (Eickhoff et al., 2009). The creation of null distributions for each experiment's ALE statistic allows for the assignment of a *p*-value for each observed ALE (Eickhoff, Bzdok, Laird, Kurth, & Fox, 2012).

We used cluster-level inferencing with family-wise error (FWE) correction through *GingerALE* as a conservative cluster-forming method to reduce the chance of false positives (Eickhoff et al., 2012). During cluster-level inferencing, random datasets are generated with the same number of foci as experimental datasets in a predetermined number of permutations (Eickhoff et al., 2012). In the reported meta-analyses, we used 1,000 permutations for single dataset meta-analyses. We set the cluster-level inferencing threshold at .05, which corresponds to the level at which only 5 % of the results of simulated studies exceed that value, and the uncorrected *p*-value was set at .001. Single ALE meta-analysis, including cluster-level inferencing with FWE correction, was performed on both groups of each of the two binary comparison categories of drawing tasks (objective and nonobjective drawing experiments; internally-cued and externally-cued drawing experiments). Due to the relatively low number of studies found, we were unable to combine groups by both content type and stimulus type (e.g. internally-cued objective drawings) for meta-analysis as the power would have been prohibitively low.

To contrast these single dataset meta-analyses, we also performed contrast analyses based on the drawing task categories (objective vs. nonobjective drawings; internally-cued vs. externally-cued drawings). Contrast analyses can find statistically different clusters of increased activation between the ALE images of two different meta-analyses. Each ALE image is subtracted from the other to find areas of increased activation that differ between the comparison treatments. *GingerALE* uses a form of permutation test in contrast analyses, in this case to correct for differences in study size, to determine whether the subtracted ALE image reflects a true difference between the data sets' areas of increased activation. For contrast analyses, we used 10,000 permutations and a higher *p*-value of .05 due to the low power of the current contrast analyses with fifteen or fewer studies in each single dataset.

Results

The Web of Science search query initially yielded 748 articles with the topics of "fMRI" and "drawing" in English. Based on an initial reading of titles, 675 articles were cut, leaving 73 articles. Using our inclusion criteria, an abstract review resulted in the further exclusion of 36 articles, leaving 37. A full text reading, including experimental methods and results, led to the last cut of 19 articles, leaving a final sample of 18 articles (N = 25 experimental analyses) relevant to the present review of functional brain activation (see Table 1).

Table 1
Studies of Functional Brain Activation included in ALE Meta-analyses.

Author (Year)	Tasks	*N*	Relevant experimental analyses
Ellamil et al. (2012)	O, I-C	15	"Generate > Evaluate"
Ferber et al. (2007)	O, I-C	12	"Draw > Copy-R"
Garbarini et al. (2014)	NO, I-C	12	"Real > Imagery"
Gowen and Miall (2007)	NO, I-C, E-C	10	"Eye-hand trace > Baseline," "Eye-hand draw > Baseline"
Harrington et al. (2007)	O, I-C	11	"Draw"
Harrington et al. (2009)	O, NO, I-C	8	"Non-objects," "Familiar-objects"
Ino et al. (2003)	O, I-C	18	"Clock drawing task"
Karimpoor et al. (2017)	NO, I-C	22	"TMT-A," "TMT-B"
Makuuchi et al. (2003)	O, E-C	17	"Drawing"
Miall et al. (2014)	O, E-C	13	"Drawing faces > Drawing abstracts"
Ogawa et al. (2009)	NO, I-C, E-C	26	"Visually-guided > Memory-guided drawing" "Memory-guided > Visually-guided drawing"
Potgeiser et al. (2015)	NO, I-C	16	"Left-hand drawing > Left-hand tapping" "Right-hand drawing > Right-hand tapping"
Saggar et al. (2015)	O, I-C	30	"Word-drawing > Zigzag-drawing"
Schaer et al. (2012)	O, E-C	20	"Naturalistic drawing > Viewing of the face" "Sketchy drawing > Viewing of the face"
Talwar et al. (2019)	O, I-C	33	"CDT Performance > Fixation"
Van Impe et al. (2011)	NO, E-C	40	"Drawing"
Yang et al. (2019)	NO, I-C	33	"Drawing circles > Writing characters"
Yuan and Brown (2014)	NO, I-C, E-C	15	"Mark-making," "Copying"

"O" represents the inclusion of drawing tasks with objective content. "NO" represents the inclusion of drawing tasks with nonobjective content. "I-C" represents the inclusion of drawing tasks based on internally-cued stimuli. "E-C" represents the inclusion of drawing tasks based on externally-cued stimuli.

ALE meta-analysis

Among these 25 drawing analyses, 15 included internally-cued drawing tasks (four memory-based drawing tasks and 11 generative drawing tasks) and 10 were externally-cued drawing tasks (eight observational, copying, or tracing tasks and two connect-the-dot tasks). Also, out of the 25 analyses, 11 included objective drawing tasks and 14 nonobjective drawing tasks. The results of the ALE meta-analyses on these 25 experimental analyses are described below.

Objective vs. Nonobjective Content

We predicted that drawings with objective content, as one example of *cognitive drawing*, would be associated with increased functional activation in the prefrontal and cingulate cortices. Conversely, we expected drawing with nonobjective content, as one example of *perceptual drawing*, to be associated with increased functional activation of the ventral visual pathway regions of the temporal lobe.

Single meta-analysis: cognitive drawing with objective content

The results of 11 experimental analyses of objective drawing tasks (drawings of familiar objects and people) were entered as a single dataset into an ALE meta-analysis, including 255 foci and 197 participants. Cluster-level inferencing resulted in five significant clusters of activation above the threshold (see Fig. 1 and Supplemental table). Our findings supported our predictions about objective content, because enhanced activation clusters occurred as predicted in the right frontal-cingulate region (associated with self-control and problem solving; see Fig. 1, cluster 1) and the left frontal lobe (clusters 2 and 5), including in the left prefrontal cortex (associated with attention and decision-making; cluster 5). There was also significant activation bilaterally in the parietal lobe (containing the dorsal visual pathway associated with tracking visual movement, spatial orientation, and motor coordination; clusters 3 and 4). Activated gyri included the middle, medial, and inferior frontal; precentral; precuneus; inferior and superior parietal; supramarginal; cingulate; and sub-gyral regions.

Single meta-analysis: perceptual drawing with nonobjective content

The results of the 14 analyses of nonobjective drawing tasks were also entered as a single dataset into an ALE meta-analysis, including 230 foci and 271 participants. Cluster-level inferencing resulted in nine significant clusters of activation above the threshold (see Fig. 2 and supplemental table). Our predictions about nonobjective content were not supported by these findings. Enhanced activation clusters occurred bilaterally in the frontal lobe (Fig. 2, clusters 3, 5, 7, 8 and 9), the left frontal-parietal region (cluster 1), bilaterally in the parietal lobe,

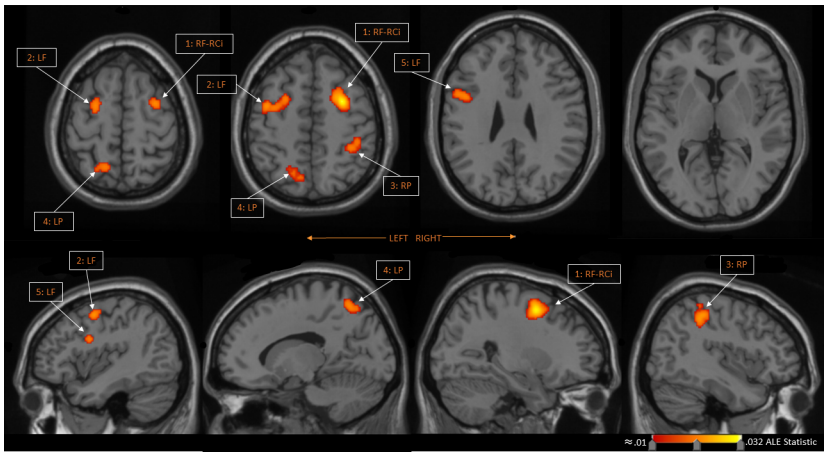

Fig. 1. Objective meta-analysis clusters of activation. Cluster 1 in the right frontal-cingulate region (RF-RCi): middle frontal, precentral, medial frontal, and cingulate gyri; Cluster 2 in the left frontal lobe (LF): middle frontal and precentral gyri; Cluster 3 in the right parietal lobe (RP): inferior parietal lobule and supramarginal gyrus; Cluster 4 in the left parietal lobe (LP): precuneus and superior parietal lobule; Cluster 5 in the left frontal lobe (LF): inferior frontal and precentral gyri. Figure was produced using Mango software (Lancaster & Martinez, http://ric.uthscsa.edu/mango/). Any color indicates significant increased activation above 0.

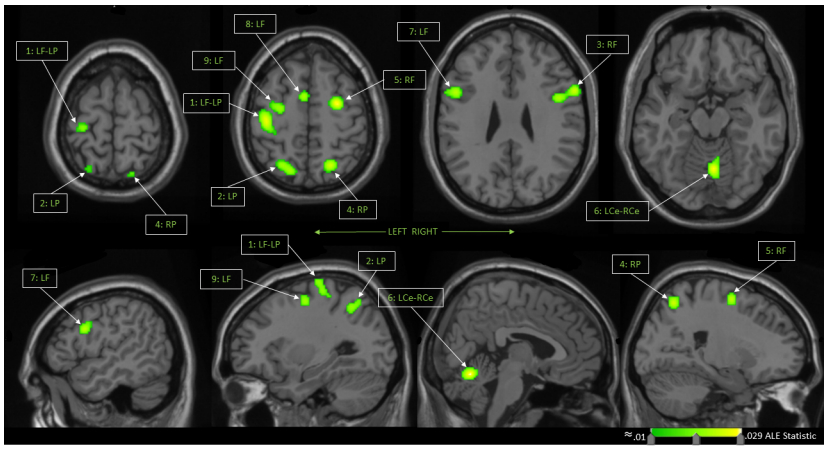

Fig. 2. Nonobjective meta-analysis clusters of activation. Cluster 1 in the left frontal-parietal region (LF-LP): postcentral and precentral gyri and inferior parietal lobule; Cluster 2 in the left parietal lobe (LP): precuneus and superior parietal lobule; Cluster 3 in the right frontal lobe (RF): inferior frontal lobule and precentral and middle frontal gyri; Cluster 4 in the right parietal lobe (RP): precuneus and superior parietal lobule; Cluster 5 in the right frontal lobe (RF): middle frontal and precentral gyri; Cluster 6 in the left and right cerebellum (LCe-RCe): anterior and posterior lobes; Cluster 7 in the left frontal lobe (LF): precentral and inferior frontal gyri; Cluster 8 in the left frontal lobe (LF): precentral and middle frontal gyri; Cluster 9 in the left frontal lobe (LF): medial frontal gyrus. Figure was produced using Mango software (Lancaster & Martinez, http://ric.uthscsa.edu/mango/). Any color indicates significant activation above 0.

containing the dorsal visual pathway and the primary motor and somatosensory cortices (associated with movement and haptic sensory perception and exploration; clusters 2 and 4), and bilaterally in the cerebellum (associated with coordinated movement and eye movements; cluster 6), but not as predicted in the temporal lobe (containing the ventral visual pathway). Activated gyri included the middle, medial, and inferior frontal; precentral; postcentral; precuneus; inferior and superior parietal; sub-gyral; as well as the declive; culmen; and declive of vermis regions of the cerebellum.

Contrast analysis: objective vs. nonobjective content

There were three significant objective clusters remaining after the ALE image from the nonobjective drawing meta-analysis was subtracted (see Fig. 3 and supplemental table). Enhanced activation clusters unique to the objective content dataset occurred in the right frontal-cingulate region (Fig. 3, orange cluster 1), the left frontal lobe (orange cluster 2), and the left parietal lobe (orange cluster 3). This contrast analysis supported our prediction about objective content, especially the significant activation of the cingulate cortex for objective content in contrast to nonobjective. Activated gyri included the middle and medial frontal, precentral, precuneus, superior parietal, cingulate, and sub-gyral regions.

There were four significant nonobjective clusters remaining after the ALE image from the objective meta-analysis was subtracted (see Fig. 3 and supplemental table). This contrast analysis did not support our predictions about nonobjective content. Enhanced activation clusters unique to the nonobjective dataset occurred in the right frontal lobe (Fig. 3, green cluster 4), the left frontal-parietal region (green cluster 3), the left parietal lobe (green cluster 2), and bilaterally in the cerebellum (green cluster 1), but not as predicted in the temporal lobe, containing the ventral visual pathway. Activated gyri included the middle frontal, precentral, postcentral, inferior parietal, as well as the declive, culmen, and declive of vermis regions of the cerebellum.

2 Internally-cued vs. Externally-cued Stimuli

We predicted that drawings with internally-cued stimuli, as one example of *cognitive drawing*, would be associated with increased functional activation in the prefrontal and cingulate cortices. By contrast, we predicted drawing with externally-cued stimuli, as one example of *perceptual drawing*, would be associated with increased functional activation of the ventral visual pathway regions of the temporal lobe.

Single meta-analysis: cognitive drawing with internally-cued stimuli

The results of the 15 analyses using internally-cued stimuli for drawing were entered as a single dataset into an ALE meta-analysis, including 227 foci and 263 participants. Cluster-level inferencing resulted in nine significant clusters of activation above the threshold (see Fig. 4 and supplemental table). Our findings supported our predictions about internally-cued stimuli, because enhanced activation clusters occurred bilaterally in the prefrontal cortex (Fig. 4, clusters 3 and 6), in the right frontal-cingulate region (cluster 2), bilaterally in the parietal lobe, containing the dorsal visual pathway (clusters 5 and 7), and in the left temporal-occipital region, containing the ventral visual pathway (associated with object and color perception; cluster 8). Activated gyri included the middle and inferior frontal, precentral, fusiform, middle and inferior temporal, middle occipital, precuneus, inferior and superior parietal, supramarginal, cingulate, and sub-gyral regions.

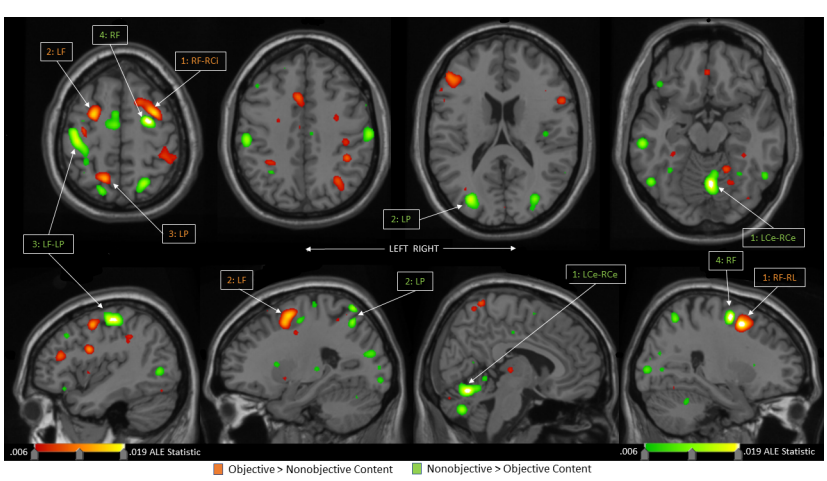

Fig. 3. Objective and nonobjective contrast analyses. Objective clusters with nonobjective clusters subtracted include Cluster 1 in the right frontal-cingulate region (RF-RCi): middle frontal, precentral, medial frontal, and cingulate gyri; Cluster 2 in the left frontal lobe (LF): middle frontal and precentral gyri; Cluster 3 in the left parietal lobe (LP): precuneus and superior parietal lobule. Nonobjective clusters with objective clusters subtracted include Cluster 1 in the right cerebellum and left cerebellum (RCe-LCe): posterior and anterior lobes; Cluster 2 in the left parietal lobe (LP): postcentral gyrus and inferior parietal lobule; Cluster 3 in the left frontal-parietal region (LF-LP): postcentral and precentral gyri; Cluster 4 in the right frontal lobe (RF): middle frontal and precentral gyri. Figure was produced using Mango software (Lancaster & Martinez, http://ric.uthscsa.edu/mango/). Any color indicates significant activation above 0.

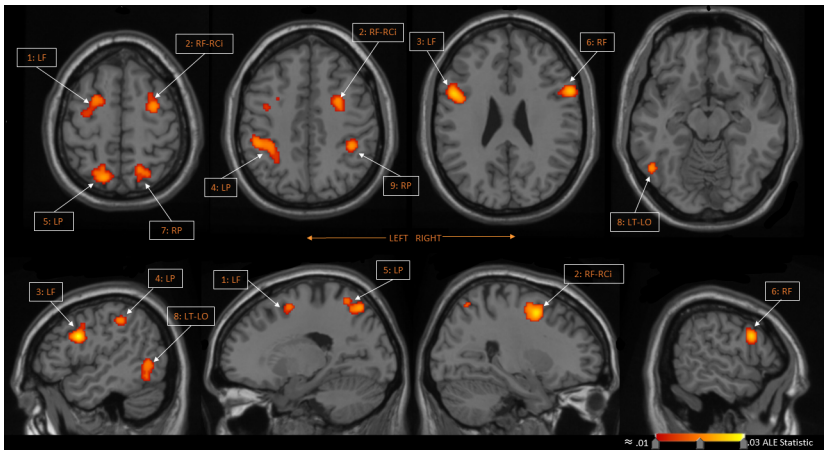

Fig. 4. Internally-cued meta-analysis clusters of activation. Cluster 1 in the left frontal lobe (LF): middle frontal and precentral gyri; Cluster 2 in the right frontal-cingulate region (RF-RCi): middle frontal, precentral, and cingulate gyri; Cluster 3 in the left frontal lobe (LF): inferior frontal and precentral gyri; Cluster 4 in the left parietal lobe (LP): inferior parietal lobule and supramarginal gyrus; Cluster 5 in the left parietal lobe (LP): precuneus and superior parietal lobule; Cluster 6 in the right frontal lobe (RF): inferior frontal and precentral gyri; Cluster 7 in the right parietal lobe (RP): precuneus and superior parietal lobule; Cluster 8 in the left temporal-occipital region (LT-LO): fusiform, middle temporal, inferior temporal, and middle occipital gyri; Cluster 9 in the right parietal lobe (RP): inferior parietal lobule. Figure was produced using Mango software (Lancaster & Martinez, http://ric.uthscsa.edu/mango/). Any color indicates significant increased activation above 0.

Single meta-analysis: perceptual drawing with externally-cued stimuli

The results of the 10 analyses of externally-cued drawing tasks were also entered as a single dataset into an ALE meta-analysis, including 258 foci and 205 participants. Cluster-level inferencing resulted in five significant clusters of enhanced activation above the threshold (see Fig. 5 and supplemental table). Our prediction about externally-cued drawing was not supported by these findings. Enhanced activation clusters occurred in the right frontal lobe (Fig. 5, cluster 3), the left frontal-parietal region (cluster 1), bilaterally in the parietal lobe, containing the dorsal visual pathway and the primary motor and somatosensory cortices (clusters 2 and 4), and bilaterally in the cerebellum (cluster 5), but not as predicted in the temporal lobe, containing the ventral visual pathway. Activated gyri included the middle frontal, precentral, postcentral, precuneus, inferior and superior parietal, subgyral, as well as the declive, culmen, and declive of vermis regions of the cerebellum.

Contrast analysis: internally-cued vs. externally-cued stimuli

There were five significant internally-cued clusters remaining after the ALE image from the externally-cued drawing meta-analysis was subtracted (see Fig. 6 and supplemental table). This contrast analysis partially supported our prediction for internally-cued stimuli. Enhanced activation clusters unique to the internally-cued dataset occurred bilaterally in the frontal lobe (Fig. 2, orange clusters 2, 4, and 5), including bilaterally in the dorsolateral prefrontal cortex (associated with planning, organization, and memory; orange clusters 2 and 5), but no remaining significant activation of the cingulate cortex was found. There was also activation unique to internally-cued drawing in the left temporal-occipital region, containing the ventral visual pathway (orange cluster 1), and left parietal lobe, containing the dorsal visual pathway (orange cluster 3). Activated gyri included the inferior and middle frontal, precentral, fusiform, inferior temporal, middle occipital, inferior parietal, and sub-gyral regions.

There were three significant externally-cued clusters after the ALE image from the internally-cued drawing meta-analysis was subtracted (see Fig. 2 and supplemental table). This contrast analysis did not support our prediction about externally-cued stimuli. Enhanced activation clusters unique to the externally-cued dataset occurred in the left frontal-parietal region (Fig. 2, green cluster 1), in the right parietal lobe, containing the dorsal visual pathway (green cluster 3), and bilaterally in the cerebellum (green cluster 2), but not as predicted in the temporal lobe, containing the ventral visual pathway. Activated gyri included the middle frontal, precentral, postcentral, superior parietal, as well as the declive regions of the cerebellum.

Discussion

ALE meta-analyses were conducted to explore functional brain activation, as measured using fMRI during drawing tasks approximating different components of the ETC. Overall, results supported our predictions that *cognitive drawing*, operationalized by internally-cued and objective drawing, would be associated with activation of the prefrontal and cingulate cortices. However, our predictions that *perceptual drawing*, operationalized by externally-cued and nonobjective drawing, would be associated with activation of the higher-order areas of the ventral visual pathway in the temporal lobe were not supported.

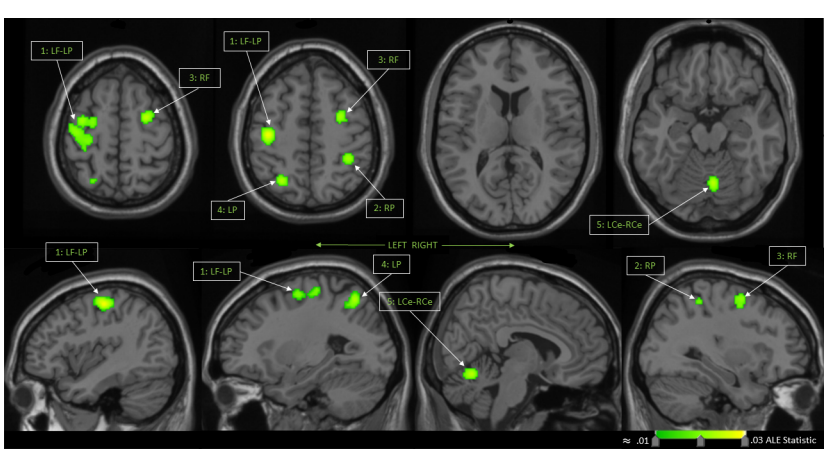

Fig. 5. Externally-cued meta-analysis clusters of activation. Cluster 1 in the left frontal-parietal region (LF-LP): precentral, postcentral, and middle frontal gyri; Cluster 2 in the right parietal lobe (RP): inferior parietal lobule, superior parietal lobule, and precuneus; Cluster 3 in the right frontal lobe (RF): middle frontal and precentral gyri; Cluster 4 in the left parietal lobe (LP): superior parietal lobule and precuneus; Cluster 5 in the left and right cerebellum (LCe-RCe): anterior and posterior lobes. Figure was produced using Mango software (Lancaster & Martinez, http://ric.uthscsa.edu/mango/). Any color indicates significant activation above 0.

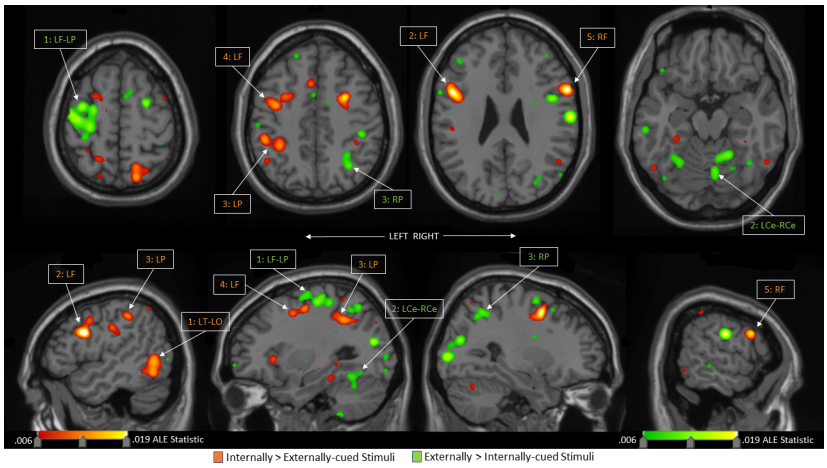

Fig. 6. Internally and externally-cued contrast analyses. Internally-cued clusters with externally-cued clusters subtracted include Cluster 1 in the left temporal-occipital region (LT-LO): fusiform, inferior temporal, and middle occipital gyri; Cluster 2 in the left frontal lobe (LF): inferior frontal and precentral gyri; Cluster 3 in the left parietal lobe (LP): inferior parietal lobule; Cluster 4 in the left frontal lobe (LF): middle frontal gyrus; Cluster 5 in the right frontal lobe (RF): inferior frontal and precentral gyri. Externally-cued clusters with internally-cued clusters subtracted include Cluster 1 in the left frontal-parietal region (LF-LP): precentral, postcentral, and middle frontal gyri; Cluster 2 in the left cerebellum and right cerebellum (LCe-RCe): posterior lobe; Cluster 3 in the right parietal lobe (RP): superior parietal lobule. Figure was produced using Mango software (Lancaster & Martinez, http://ric.uthscsa.edu/mango/). Any color indicates significant increased activation above 0.

Implications for art therapy theory

Our findings have implications for the ETC and the understanding of brain structures and pathways underlying artistic expression at different levels. Although our approximations of cognitive drawing were associated with heightened activation of the prefrontal and cingulate cortices, consistent with Lusebrink's (2010) hypotheses, other brain regions also displayed higher activation during these tasks even after contrast analyses. The data identify a broadly distributed brain network and associated cognitive processes that contribute to cognitive drawing as opposed to single regions. The dorsal visual pathway consistently displayed significant increased activation for both objective and internally-cued drawings. Although the dorsal visual pathway, the "where" or "how" pathway, is associated with the detection of movement in the visual field, it is also associated with hand/eye coordination and spatial orientation with respect to visual stimuli like art materials (Hass-Cohen & Loya, 2008). Internally-cued drawings also resulted in heightened activation of the ventral visual pathway, the "what" pathway, involved with object and color perception (Hass-Cohen & Loya, 2008), perhaps due to the necessity of drawing objects and shapes from memory or pre-existing internal representations.

Perceptual drawings also showed a broader swath of activation than expected, implying large networks and multiple support processes. Although our meta-analyses on perceptual drawing (nonobjective or externally-cued) did not show our predicted activation of the ventral visual pathway, previous single experiments have shown significant temporal-occipital activation for externally-cued drawing (Gowen & Miall, 2007; Ogawa & Inui, 2009). Therefore, it is still possible and perhaps likely that this pathway is important for perceptual drawing in parallel with the dorsal visual pathway. However, what was clear from our meta-analyses was that perceptual drawings resulted in significantly higher activation in the frontal (at times prefrontal) and parietal lobes as well as the cerebellum even after contrast analyses. This means that even these highly controlled perceptual drawing tasks (such as connecting dots or tracing a geometric shape) activated areas hypothesized by Lusebrink (2010) to be associated both with the highest level of the ETC (frontal lobe, prefrontal cortex) and with the lowest level of the ETC (primary motor and somatosensory cortices).

What do these broad brain activation patterns imply for ETC theory as informed by neuroscience? Lusebrink and Hinz (2019) recently discussed the potential importance of three large scale brain networks (LSBN) to both cognitive and symbolic artistic expression: the central executive network, the default mode network, and the salience network. Based on our findings, we would argue that broadly distributed brain networks are important both for the higher and lower levels of the ETC, including the perceptual component. Using fMRI and dynamic causal modelling to examine functional connectivity and coupling in the brain, Dijkstra, Zeidman, Ondobaka, van Gerven, and Friston (2017) studied directionality of neural processes during perception of imagery (externally-cued) vs. imagination of imagery (internally-cued). Internal imagination of imagery was associated with more *top-down processing*, i.e. outgoing signals from the inferior frontal gyrus projecting to early visual areas. Perception of external imagery, by contrast, was associated with more *bottom-up processing*, i.e. projections from the early visual areas to the inferior frontal gyrus.

Based on our findings and those of Dijkstra et al. (2017), we hypothesize that artistic expression at different ETC levels is associated with differences in regional brain origin and directionality of processing, as well as activation of large brain networks. Cognitive, and potentially symbolic, art-making may be more associated with top-down or feedback processing characterized by greater reflective distance as described by Lusebrink (1990). Reflective distance refers to time spent thinking about or planning an artwork as opposed to spontaneous execution, and greater distance is encouraged by more resistive art materials lower in fluidity (Lusebrink). By contrast, perceptual, and potentially kinesthetic and sensory, art-making may be more associated with bottom-up or feedforward processing characterized by less reflective distance from artwork and more fluid, malleable art materials.

Implications for art therapy research and practice

A better understanding of neural processes during artistic expression leads to more questions for art therapy researchers and new ideas for practitioners. More research comparing neuroimaging before and after art therapy is crucial to the field. As suggested by King and Kaimal (2019), brain scanning technologies that allow for more mobility, such as MoBI, fNIRS, and EEG, could examine therapeutic mechanisms in art therapy related to media, expression, and therapeutic relationships. Future studies could involve neuroimaging during art-based tasks more closely approximating components of the ETC as they may occur in art therapy. Research would be best informed if undertaken in collaboration between neuroscientists and art therapists. Also, an experiment directly comparing activation during combinations of the drawing task categories as factors (internally-cued vs. externally-cued and objective vs. nonobjective) may shed some light on potential interactions between stimuli type and content type on regional brain functional activation. More research of functional connectivity during different art tasks that modulate reflective distance by media (drawing vs. clay-sculpting) and by art directive (planning a composition vs. scribble chasing) could further illuminate differences in the relationship of bottom-up versus top-down processing.

Although our meta-analyses of neuroimaging studies subdivided by task are only approximations of levels of expression used in art therapy, our findings go beyond research and basic science to practice

applications. For example, it is helpful for art therapists to be informed which art directives are likely to activate desired areas of the brain. More perceptual art-making may help clients engage in more bottom-up brain processing and the associated network of brain regions. Our findings indicate that perceptual drawings of nonobjective content or externally-cued stimuli, compared to other drawing tasks, are likely to disproportionately activate parietal lobe regions of the dorsal visual pathway, the primary motor and somatosensory cortices, and the cerebellum. Connection through the senses, including sight, to one's surroundings can be a grounding experience enhancing reality orientation and mindfulness skills, especially for some clients experiencing dissociation or psychosis (Hinz, 2009). Hass-Cohen and Loya (2008) also discussed the value of engaging bottom-up visual processing through the dorsal visual pathway for clients stuck in therapy, because orienting oneself spatially and through movement with new art materials or processes can be exciting and promote the creation of new neural connections.

Our findings also have implications for art therapists hoping to increase their client's reflective distance from an art product and engage the cognitive level of expression. Our results indicate that drawings of objective content or with internally-cued stimuli may engage more top-down or feedback processing. Directives that require clients to incorporating planning, organization, and verbal integration (e.g., illustrated narratives, cognitive maps, or comic strips) may enhance those clients' skills associated with the prefrontal cortex: attention, decision-making, problem-solving skills, or memory.

Due to the potential for increased restorative plasticity through art making, the current meta-analyses are also pertinent to art therapy participants with neural deficits. In general, greater understanding of the network of brain regions associated with different art-based tasks is useful in treating clients with brain damage resulting from traumatic brain injury (TBI) or dementia. Art therapists and their clients can capitalize on unaffected areas of the brain using targeted art directives activating these areas in the hope of creating new functional pathways. Through repetition, participants may gradually become more able to complete art-based tasks formerly relying on affected brain areas by exploiting the plasticity that promotes neuronal reorganization. This process has been evident in people with aphasia increasingly able to remember the names of objects through drawing (Farias et al., 2006). Plasticity nurtured through art-making could extend beyond the more cognitive drawing tasks described by Farias et al. (2006) and Cacciamani and Likova (2017) to include more perceptual or sensory art tasks incorporating rich and novel stimuli.

Limitations

The findings of the meta-analyses must be considered in the context of their limitations. Due to the relatively small sample of studies, the current meta-analyses would have benefitted from more power, especially in the contrast analyses. Also, aggregated numbers of participants across experiments included in the meta-analyses do not necessarily equate to the number of unique participants, because multiple analyses were taken from the same articles. Furthermore, the common categories of drawing tasks in past neuroscientific research (objective vs. non-objective; internally-cued vs. externally-cued) are only an approximation of the cognitive and perceptual components of the ETC with only one art medium.

Conclusion

Due to the lack of previous research using neuroimaging in the context of art therapy, this ALE meta-analysis capitalized on the commonality of drawing tasks in neuroimaging research to test whether specific brain regions were associated with expression at different levels of the ETC. There were increased prefrontal and cingulate cortex activations for more cognitive drawings. By contrast, increased activation of the ventral visual pathway was not significantly associated with more perceptual drawings. In general, each type of drawing resulted in broader activation across the brain than expected, even after contrast analyses. For example, the ventral and dorsal visual pathways were implicated in internally-cued cognitive drawings. Also, perceptual drawings were associated with activation in the frontal and parietal lobes and the cerebellum. Considered in the context of the recent literature, these broad activations across the brain imply that larger brain networks, and potentially feedforward and feedback processing across the brain, are important to these art tasks as opposed to control by a small number of localized brain regions.

The findings of the present meta-analyses, although only an approximation of artistic expression in art therapy, have implications for clinical practice. Increased understanding of brain processes and networks likely to be activated during perceptual or cognitive art tasks will enable art therapists to better understand why specific interventions are successful. When art therapists are more aware of underlying brain processes during art making with different stimuli or different content, they are also better equipped to select effective art media and directives, potentially promoting the restorative potential of neural plasticity for their clients.

Declaration of Competing Interest

This paper was written while VPB was funded by National Science Foundation grant IOS-1457304.

Appendix A. Supplementary data

Supplementary material related to this article can be found, in the online version, at doi:https://doi.org/10.1016/j.aip.2020.101690.

References

Bednash, C. J. (2016). *Art therapy and neuroscience: A model for wellness*(Published masters thesis). Los Angeles, CA: Loyola Marymount University. http://digitalcommons.lmu.edu/etd/297.

Beeson, P., Rapcsak, S., Plante, E., Chargualaf, J., Chung, A., Johnson, S., et al. (2003). The neural substrates of writing: A functional magnetic resonance imaging study. *Aphasiology, 17*(6–7), 647–665.

Belkofer, C. M., & Konopka, L. M. (2008). Conducting art therapy research using quantitative EEG measures. *Art Therapy, 25*(2), 56–63.

Belkofer, C. M., Van Hecke, A. V., & Konopka, L. M. (2014). Effects of drawing on alpha activity: A quantitative EEG study with implications for art therapy. *Art Therapy, 31*(2), 61–68.

Cacciamani, L., & Likova, L. T. (2017). Memory-guided drawing training increases Granger causal influences from the perirhinal cortex to V1 in the blind. *Neurobiology of Learning and Memory, 141*, 101–107.

DeMarco, A. T., Wilson, S. M., Rising, K., Rapcsak, S. Z., & Beeson, P. M. (2017). Neural substrates of sublexical processing for spelling. *Brain and Language, 164*, 118–128.

Dijkstra, N., Zeidman, P., Ondobaka, S., van Gerven, M. A., & Friston, K. (2017). Distinct top-down and bottom-up brain connectivity during visual perception and imagery. *Scientific Reports, 7*(1), 1–9.

Eickhoff, S. B., Laird, A. R., Grefkes, C., Wang, L. E., Zilles, K., & Fox, P. T. (2009). Coordinate-based activation likelihood estimation meta-analysis of neuroimaging data: A random-effects approach based on empirical estimates of spatial uncertainty. *Human Brain Mapping, 30*, 2907–2926.

Eickhoff, S. B., Bzdok, D., Laird, A. R., Kurth, F., & Fox, P. T. (2012). Activation likelihood estimation revisited. *Neuroimage, 59*, 2349–2361.

Ellamil, M., Dobson, C., Beeman, M., & Christoff, K. (2012). Evaluative and generative modes of thought during the creative process. *Neuroimage, 59*(2), 1783–1794.

Farias, D., Davis, C., & Harrington, G. (2006). Drawing: Its contribution to naming in aphasia. *Brain and Language, 97*(1), 53–63.

Ferber, S., Mraz, R., Baker, N., & Graham, S. J. (2007). Shared and differential neural substrates of copying versus drawing: A functional magnetic resonance imaging study. *Neuroreport, 18*(11), 1089–1093.

Garbarini, F., D'Agata, F., Piedimonte, A., Sacco, K., Rabuffetti, M., Tam, F., et al. (2014). Drawing lines while imagining circles: Neural basis of the bimanual coupling effect during motor execution and motor imagery. *Neuroimage, 88*, 100–112.

Gowen, E., & Miall, R. C. (2007). Differentiation between external and internal cuing: An fMRI study comparing tracing with drawing. *Neuroimage, 36*(2), 396–410.

Harrington, G. S., Farias, D., Davis, C. H., & Buonocore, M. H. (2007). Comparison of the neural basis for imagined writing and drawing. *Human Brain Mapping, 28*(5), 450–459.

Harrington, G. S., Farias, D., & Davis, C. H. (2009). The neural basis for simulated

drawing and the semantic implications. *Cortex, 45*(3), 386–393.
Hass-Cohen, N., & Findlay, J. C. (2015). *Art therapy and neuroscience of relationships, creativity and resiliency: Skills and practices.* New York & London: W.W. Norton & Company.
Hass-Cohen, N., & Loya, N. (2008). Visual system in action. In N. Hass-Cohen, & R. Carr (Eds.). *Art therapy and clinical neuroscience* (pp. 92–110). Jessica Kingsley Publishers.
Hinz, L. D. (2009). *Expressive therapies continuum: A framework for using art in therapy*. New York & London: Routledge.
Ino, T., Asada, T., Ito, J., Kimura, T., & Fukuyama, H. (2003). Parieto-frontal networks for clock drawing revealed with fMRI. *Neuroscience Research, 45*(1), 71–77.
Kagin, S. L., & Lusebrink, V. B. (1978). The expressive therapies continuum. *Art Psychotherapy, 5*(4), 171–180. https://doi.org/10.1016/0090-9092(78)90031-5.
Kaimal, G., Ayaz, H., Herres, J., Dieterich-Hartwell, R., Makwana, B., Kaiser, D. H., et al. (2017). Functional near-infrared spectroscopy assessment of reward perception based on visual self-expression: Coloring, doodling, and free drawing. *The Arts in Psychotherapy, 55*, 85–92.
Kane, K. C. (2013). *Art therapy and neuroplasticity: How creativity can heal trauma* (Published masters thesis). Minnetonka, MN: Adler Graduate School. https://alfredadler.edu/library/masters/2013/kristin-c-kane.
Karimpoor, M., Churchill, N. W., Tam, F., Fischer, C. E., Schweizer, T. A., & Graham, S. J. (2017). Tablet-based functional MRI of the trail making test: Effect of tablet interaction mode. *Frontiers in Human Neuroscience, 11*, 496.
King, J. L., & Kaimal, G. (2019). Approaches to research in art therapy using imaging technologies. *Frontiers in Human Neuroscience, 13*, 159.
Kruk, K. A., Aravich, P. F., Deaver, S. P., & deBeus, R. (2014). Comparison of brain activity during drawing and clay sculpting: A preliminary qEEG study. *Art Therapy, 31*(2), 52–60.
Laird, A. R., Eickhoff, S. B., Kurth, F., Fox, P. M., Uecker, A. M., Turner, J. A., et al. (2009). ALE meta-analysis workflows via the Brainmap database: Progress towards a probabilistic functional brain atlas. *Frontiers in Neuroinformatics, 3*, 23.
Likova, L. T. (2012). Drawing enhances cross-modal memory plasticity in the human brain: A case study in a totally blind adult. *Frontiers in Human Neuroscience, 6*, 44.
Lusebrink, V. B. (1990). *Imagery and visual expression in therapy*. New York, NY: Plenum Press67–114.
Lusebrink, V. B. (2010). Assessment and therapeutic application of the expressive therapies continuum: Implications for brain structures and functions. *Art Therapy, 27*(4), 168–177.
Lusebrink, V. B., & Hinz, L. D. (2019). Cognitive and symbolic aspects of art therapy and similarities with large scale brain networks. *Art Therapy,* 1–11.
Makuuchi, M., Kaminaga, T., & Sugishita, M. (2003). Both parietal lobes are involved in drawing: A functional MRI study and implications for constructional apraxia. *Cognitive Brain Research, 16*(3), 338–347.
Miall, R. C., Nam, S. H., & Tchalenko, J. (2014). The influence of stimulus format on drawing—A functional imaging study of decision making in portrait drawing. *NeuroImage, 102,* 608–619.
Ogawa, K., & Inui, T. (2009). The role of the posterior parietal cortex in drawing by copying. *Neuropsychologia, 47*(4), 1013–1022.
Potgeiser, A. R., van der Hoorn, A., & de Jong, B. M. (2015). Cerebral activations related to writing and drawing with each hand. *PloS One, 10*(5), Article e0126723.
Saggar, M., Quintin, E. M., Kienitz, E., Bott, N. T., Sun, Z., Hong, W. C., et al. (2015). Pictionary-based fMRI paradigm to study the neural correlates of spontaneous improvisation and figural creativity. *Scientific Reports, 5*, 10894.
Schaer, K., Jahn, G., & Lotze, M. (2012). fMRI-activation during drawing a naturalistic or sketchy portrait. *Behavioural Brain Research, 233*(1), 209–216.
Solso, R. L. (2001). Brain activities in a skilled versus a novice artist: An fMRI study. *Leonardo, 34*(1), 31–34.
Stewart, E. G. (2004). Art therapy and neuroscience blend: Working with patients who have dementia. *Art Therapy: Journal of the American Art Therapy Association, 21*(3), 148–155. https://doi.org/10.1080/07421656.2004.10129499.
Talwar, N., Churchill, N. W., Hird, M. A., Pshonyak, I., Tam, F., Fischer, C. E., et al. (2019). The neural correlates of the clock-drawing test in healthy aging. *Frontiers in Human Neuroscience, 13*, 25.
Van Impe, A., Coxon, J. P., Goble, D. J., Wenderoth, N., & Swinnen, S. P. (2011). Age-related changes in brain activation underlying single-and dual-task performance: visuomanual drawing and mental arithmetic. *Neuropsychologia, 49*(9), 2400–2409.
Walker, M. S., Stamper, A. M., Nathan, D. E., & Riedy, G. (2018). Art therapy and underlying fMRI brain patterns in military TBI: A case series. *International Journal of Art Therapy, 23*(4), 180–187.
Yang, Y., Zuo, Z., Tam, F., Graham, S. J., Tao, R., Wang, N., et al. (2019). Brain activation and functional connectivity during Chinese writing: An fMRI study. *Journal of Neurolinguistics, 51*, 199–211.
Yuan, Y., & Brown, S. (2014). The neural basis of mark making: A functional MRI study of drawing. *PloS One, 9*(10), Article e108628.