Radiological Evaluation of CNS Tumors

Dr Subhash Thakur
JR, Radiation Oncology, PGIMER

Brief History

- Arthur schiller (1874-1957) is considered as Father of neuro - radiology
- studied skull x-rays systemically
- Walter Dandy 1918 described diagnostic ventriculography and pneumoencephalography

Dr. Arthur Schüller, in American Journal of Neuroradiology AJNR 1997 18: 1297-1302

Objectives of Brain tumour imaging

- **Diagnosis**
  - Tumour vs. non tumour lesion
- **Treatment Plan**
  - Delineation of tumour extent
  - Tumour vs. peri tumoural oedema
- **Post treatment and Follow up**
  - Residual tumour vs. treatment necrosis

Available Modalities

- X ray
- Computed Tomography (CT)
- Magnetic Resonance Imaging (MRI)
- Nuclear Imaging.

Skull X-rays

- Of historical interest since the onset of CT in 1974
- Only useful in demonstrating
  - Calcification
  - Erosion or hyperostosis
- For conventional RT planning

Bony landmarks for conventional Planning

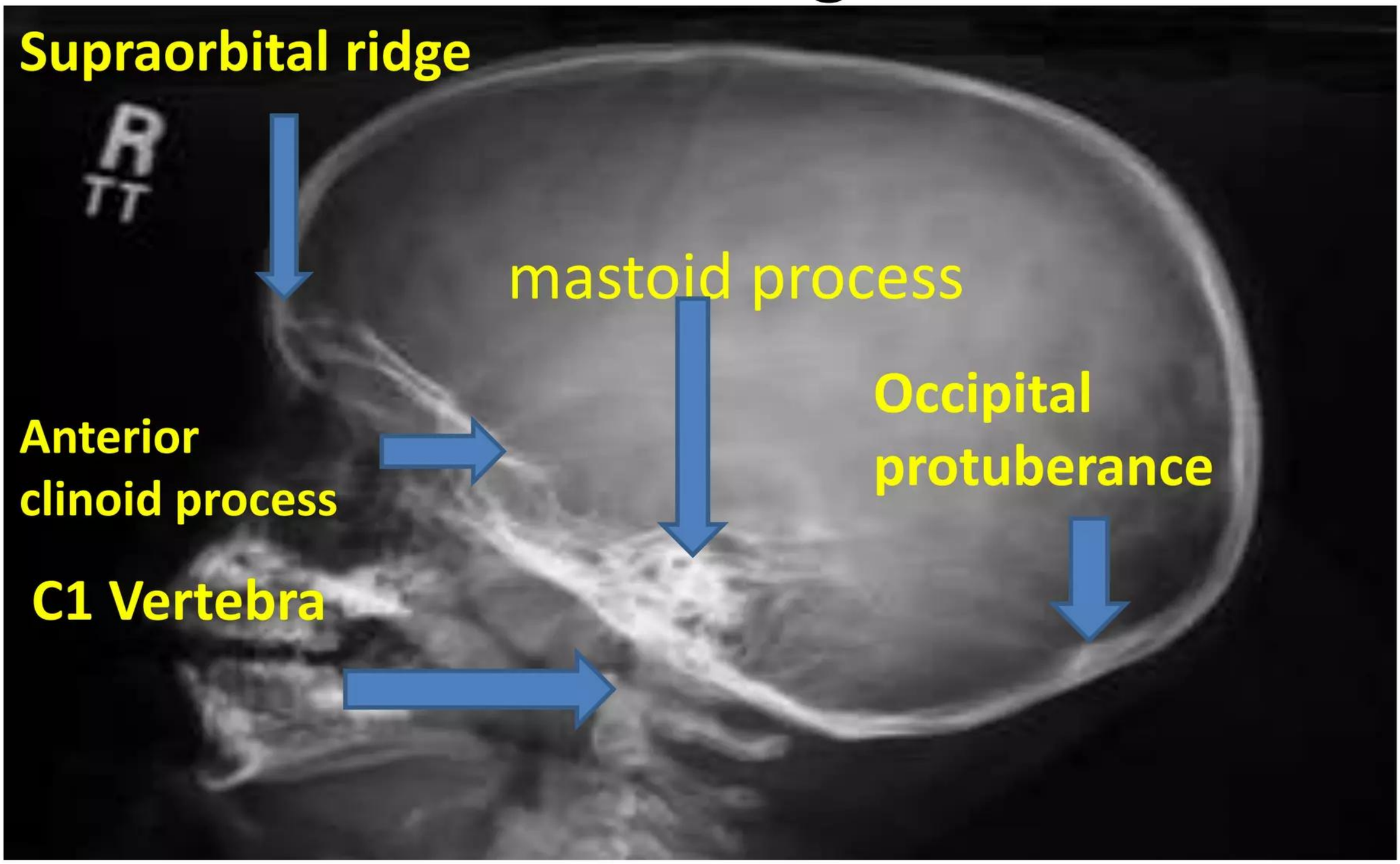

CLINICAL SIGNIFICANCE IN RT

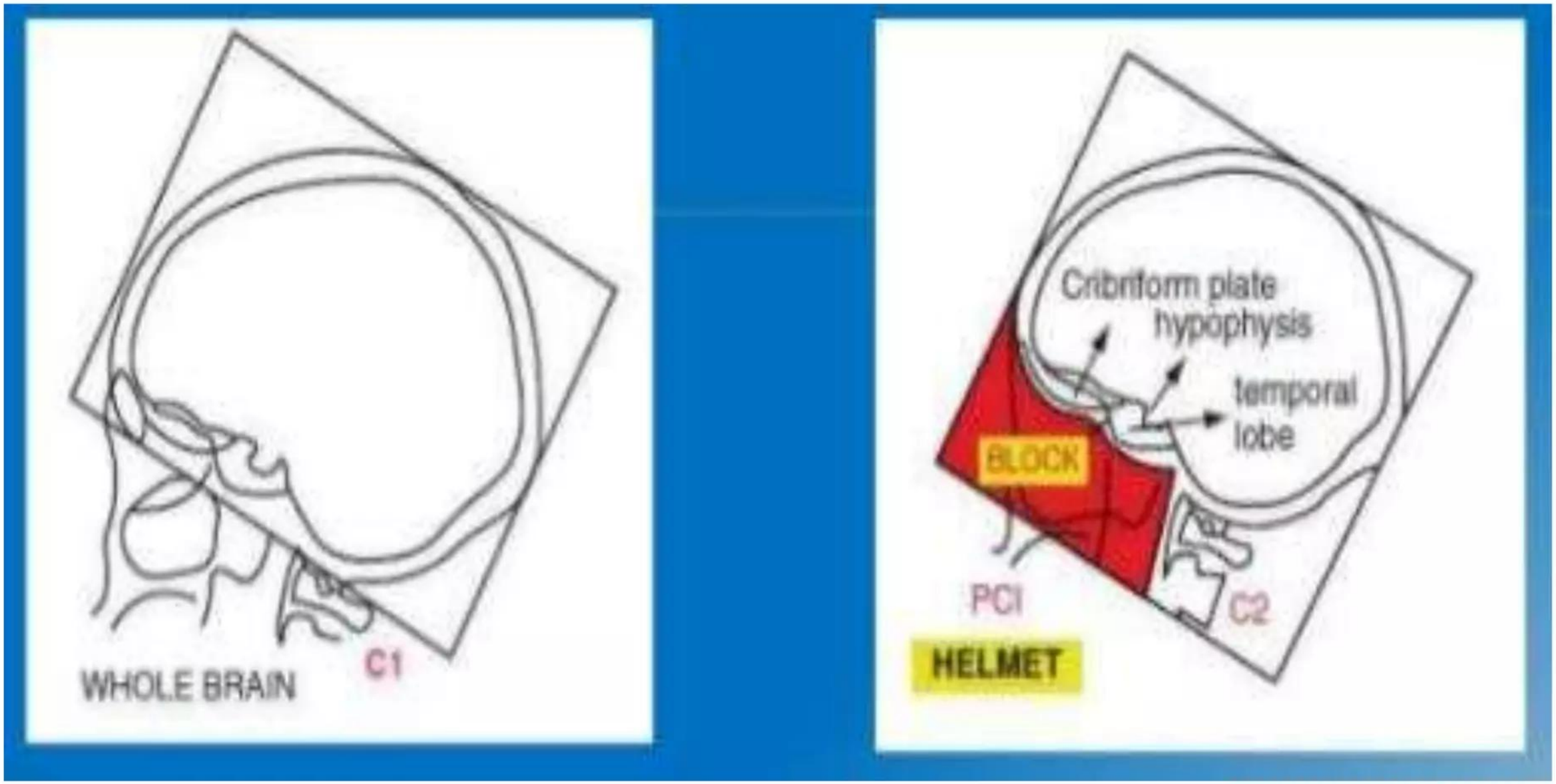

PITUTARY & POSTERIOR FOSSA BOOST

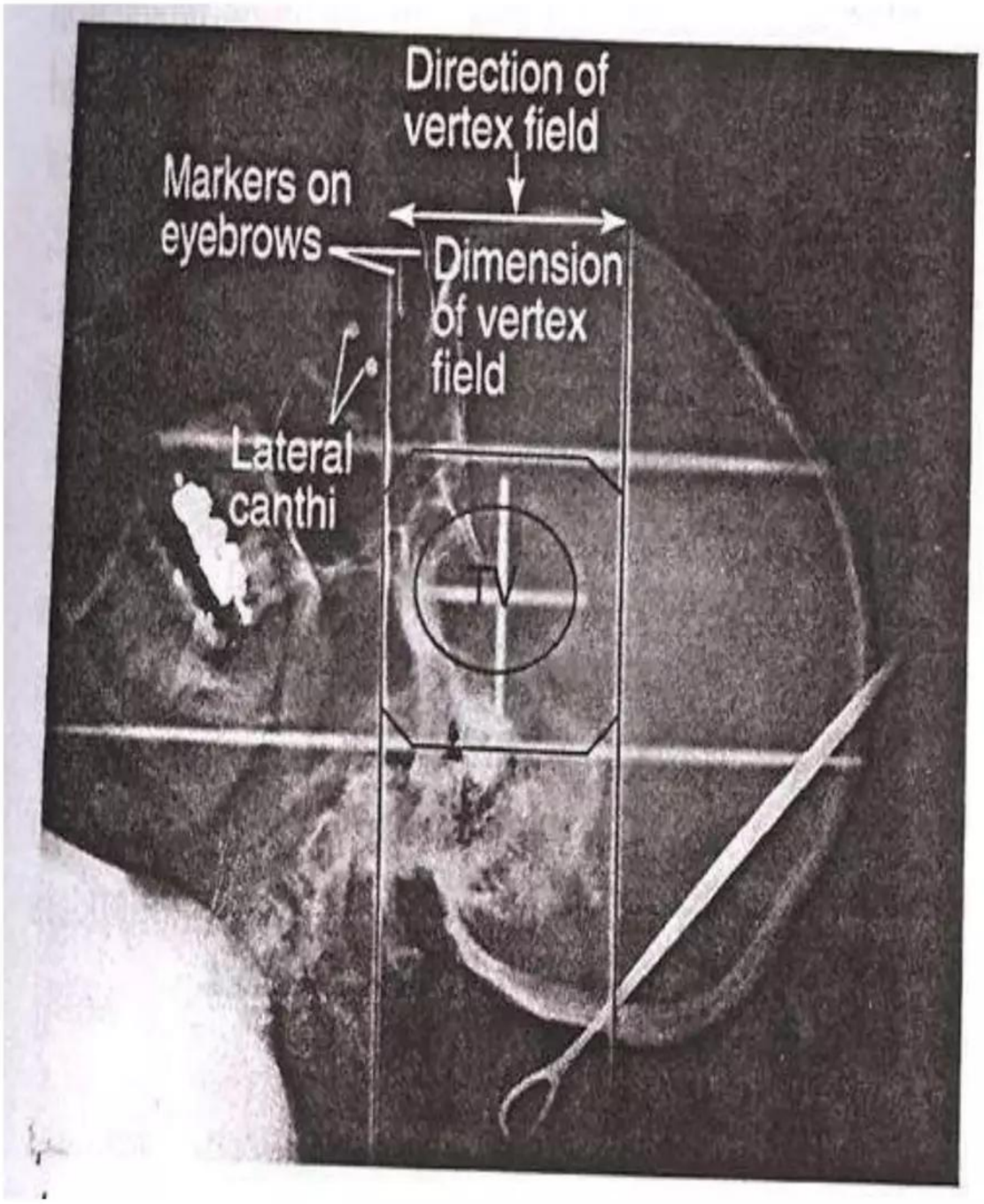

Impact of the orientation of the line joining the foramen magnum to the skull on the definition of the posterior fossa boundary. Drayer et al IJROBP 1998.

CT scan

- **Though MRI is the modality of choice, CT is more sensitive for**
  - Acute haemorrhage
  - Calcification and
  - Bony involvement
- **What CT can miss**
  - Small tumours <0.5cm
  - Tumors adjacent to bone like pituitary adenoma, clival tumours and vestibular schwannomas
  - Brain stem tumours and
  - Low grade astrocytomas
- MAIN MODALITY FOR RT PLANNING

RT PLANNING CT

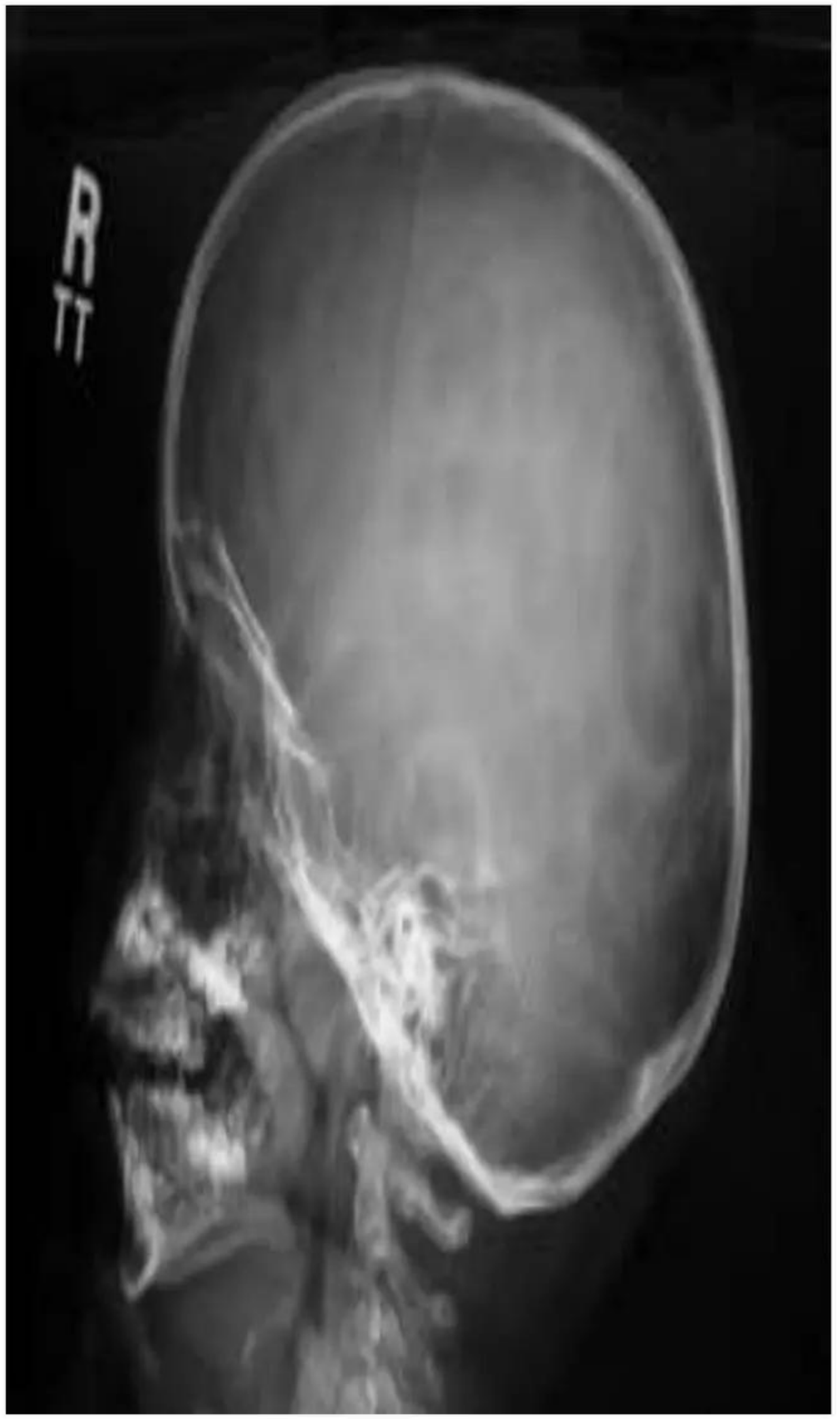

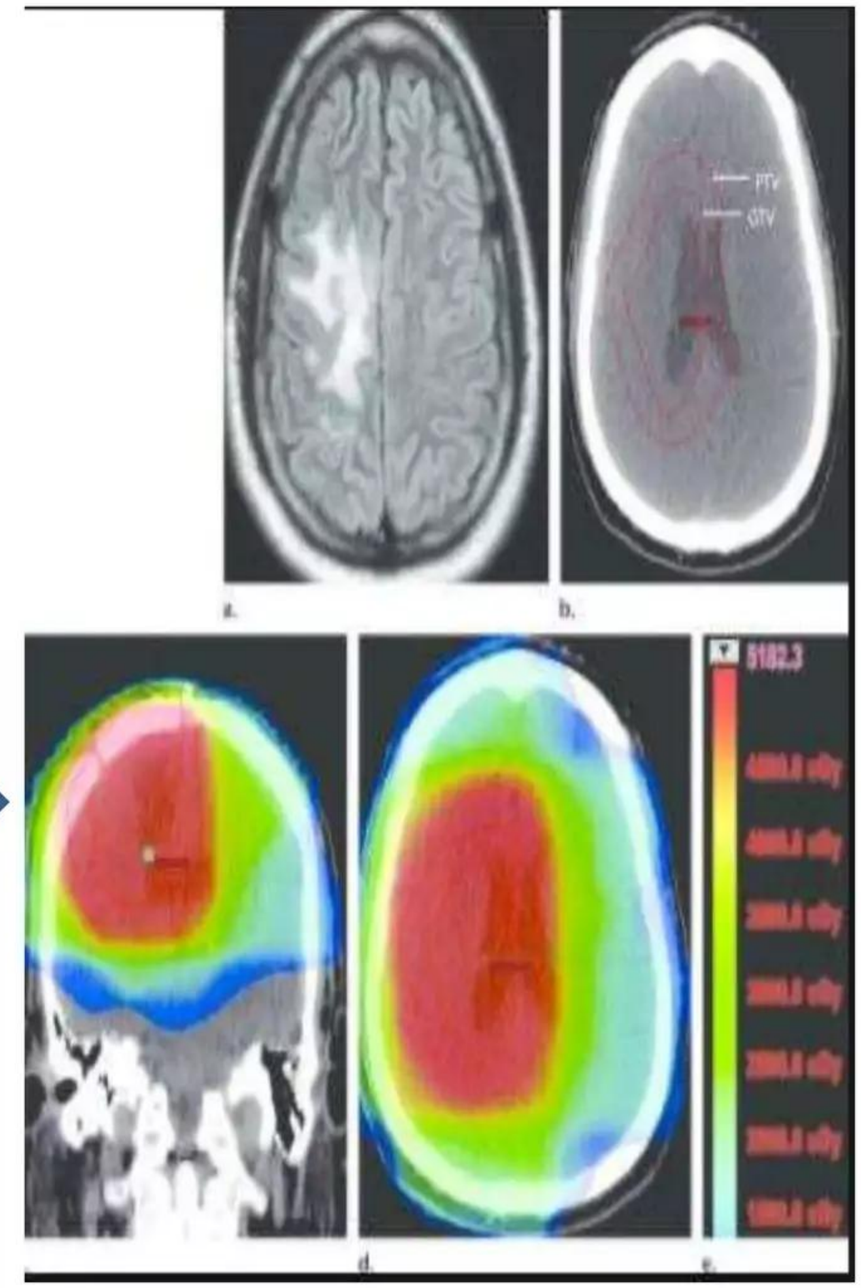

- PGI protocol for planning CT in brain tumors
  - Contrast is injected, CT is taken immediately and after 7 minutes.
  - Principle : Immediate CT shows contrast enhancement in the vessels
  - Delayed CT delineates tumor better due to leakage of contrast through breached BBB.

MRI

- Felix bloch and Edward Purcell (1946) first described Magnetic resonance phenomenon
  - Awarded the nobel prize
- **Principle of functioning :**
  - MRI exploits increased water content of many neoplasm. This water content shows up as increased signal on T2 weighted images and decreased signal on T1 images

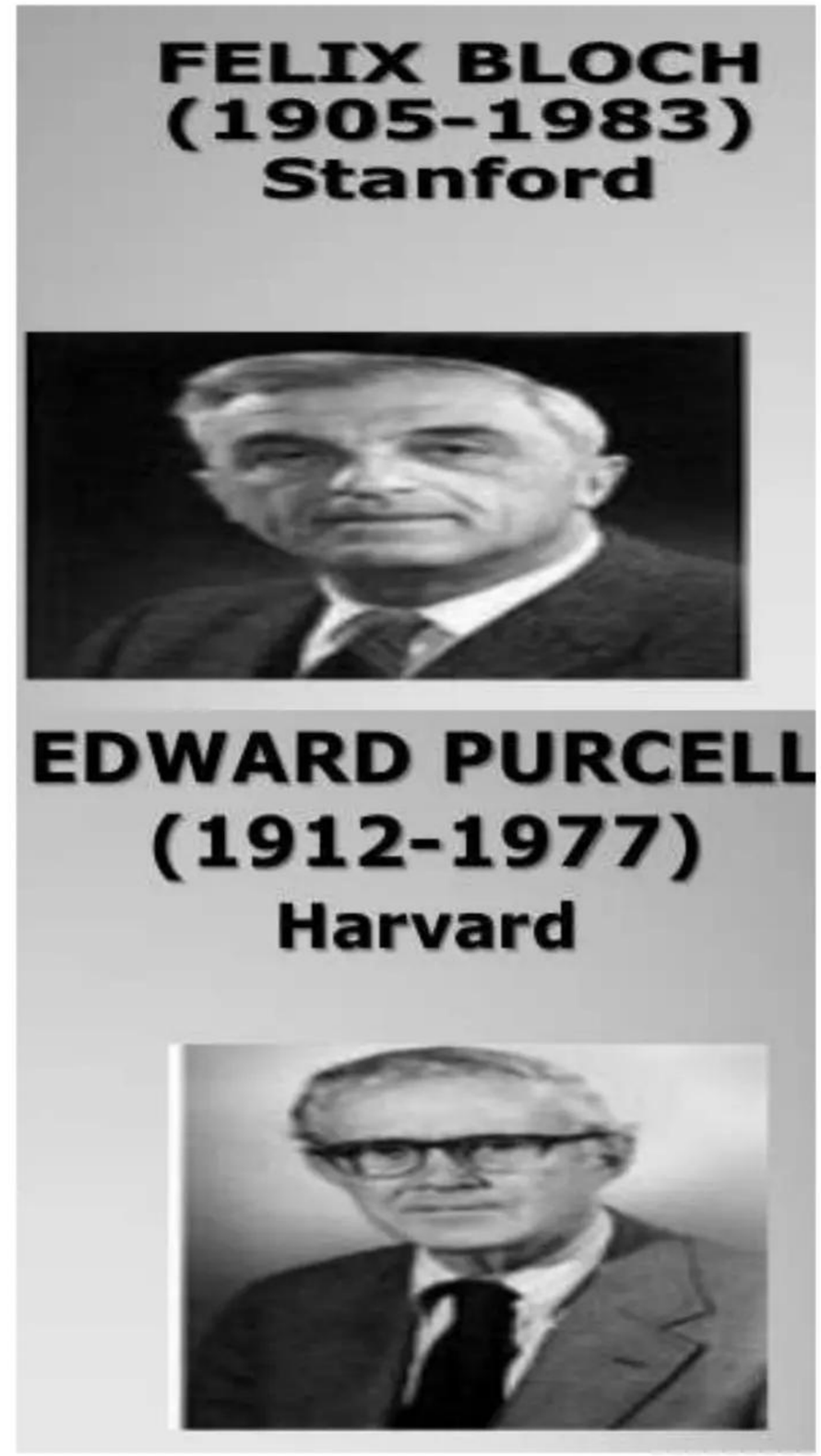

- **Advantages of MRI**
  - Higher sensitivity in the demonstration of oedema so better for earlier detection of tumours
  - Brain stem structures are better identified
  - Better characterization of brain tumours
- **Limitations of MRI**
  - Infiltrative small gliomas without significant mass effect may go undetected
  - Infiltrating tumors can extend several cms beyond the enhancing region

MRI Sequences

- **T1**

  Recognition

  - fat is bright
  - Water is dark
  - New blood is bright

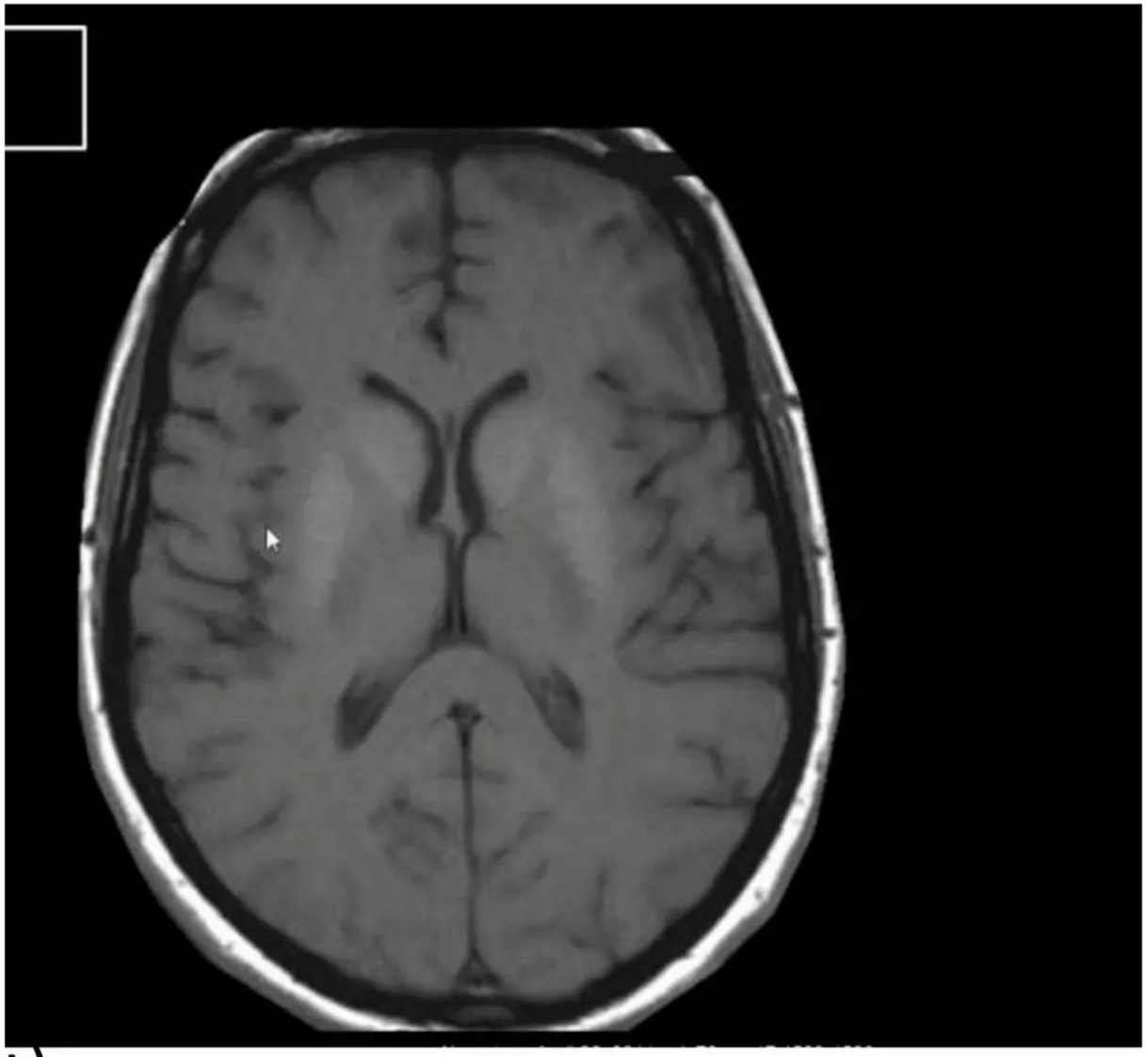

- **Useful for**
  - Anatomic details
  - Vascular changes (with contrast)
  - Dispruption of BBB (with contrast)

- **T2**

  Recognition
  - fat is dark
  - Water is bright
  - Flow is dark
- **Useful for**
  - Anatomic details (CSF spaces)
  - Most lesion
- But cannot distinguish lesion from csf where edema/lesion is close to CSF spaces

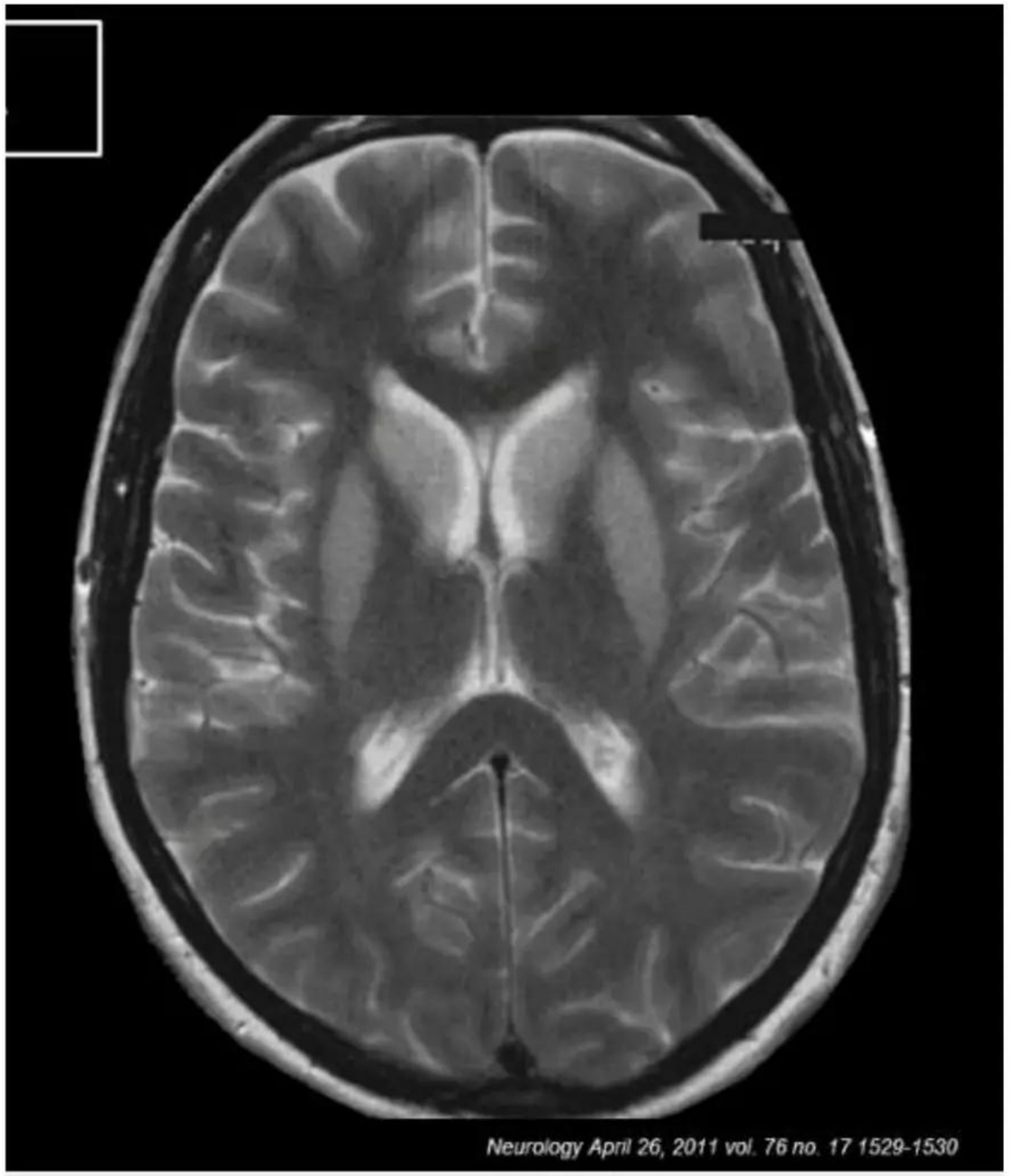

T1 Vs T2

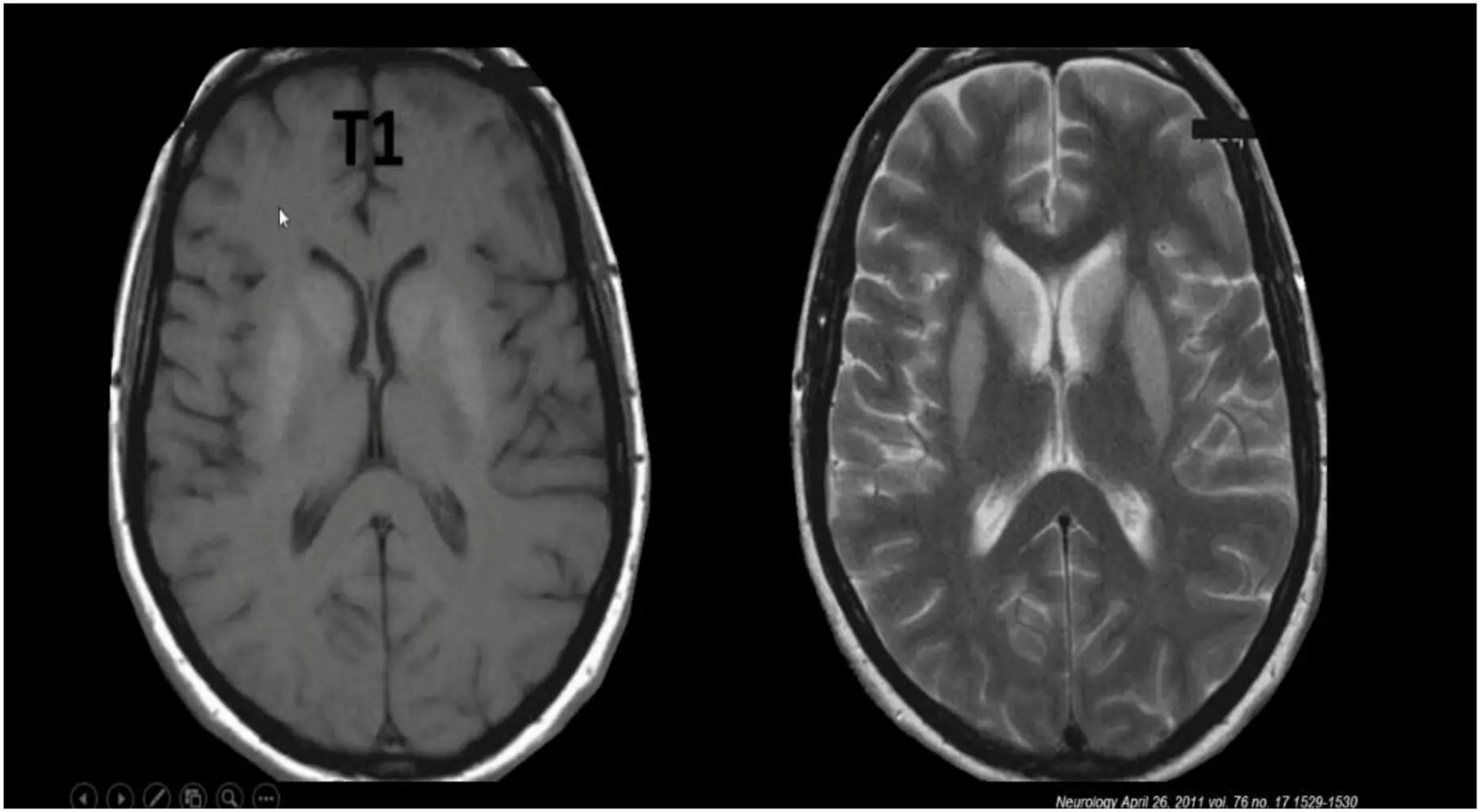

FLAIR
Fluid attenuation Inversion recovery

Recognition

- T2 + free flowing water (CSF) is dark
- Non free flowing water is bright

- **Useful for**
  - Same as T2
  - Can delineate lesion near ventricles
  - Edema
  - Can improve Grey-White diffrentiation

T2 Vs FLAIR

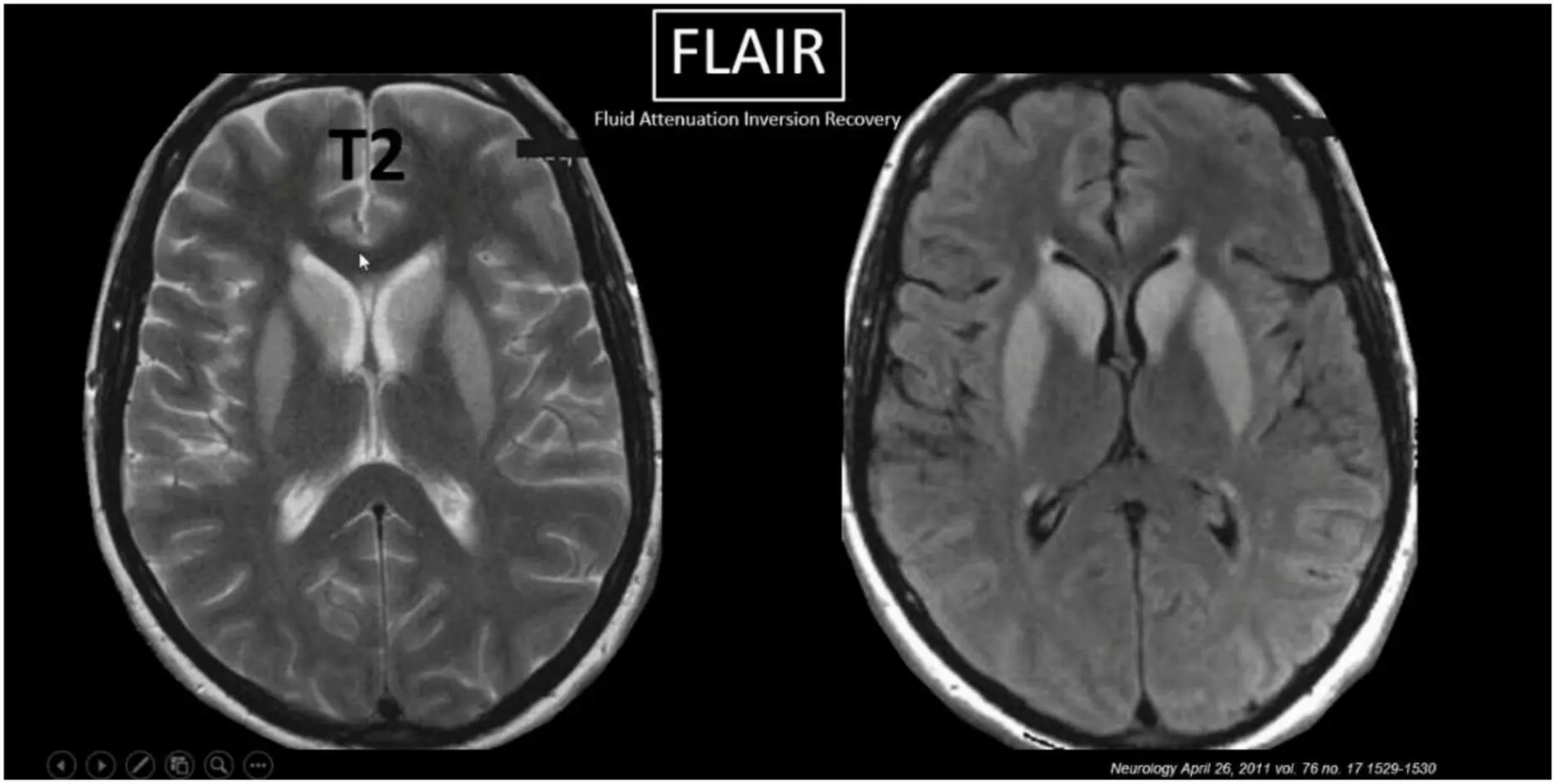
FLAIR
Fluid Attenuation Inversion Recovery
T2
Neurology April 26, 2011 vol. 76 no. 17 1529-1530

T2 vs FLAIR
Delineation of lesion from ventricle

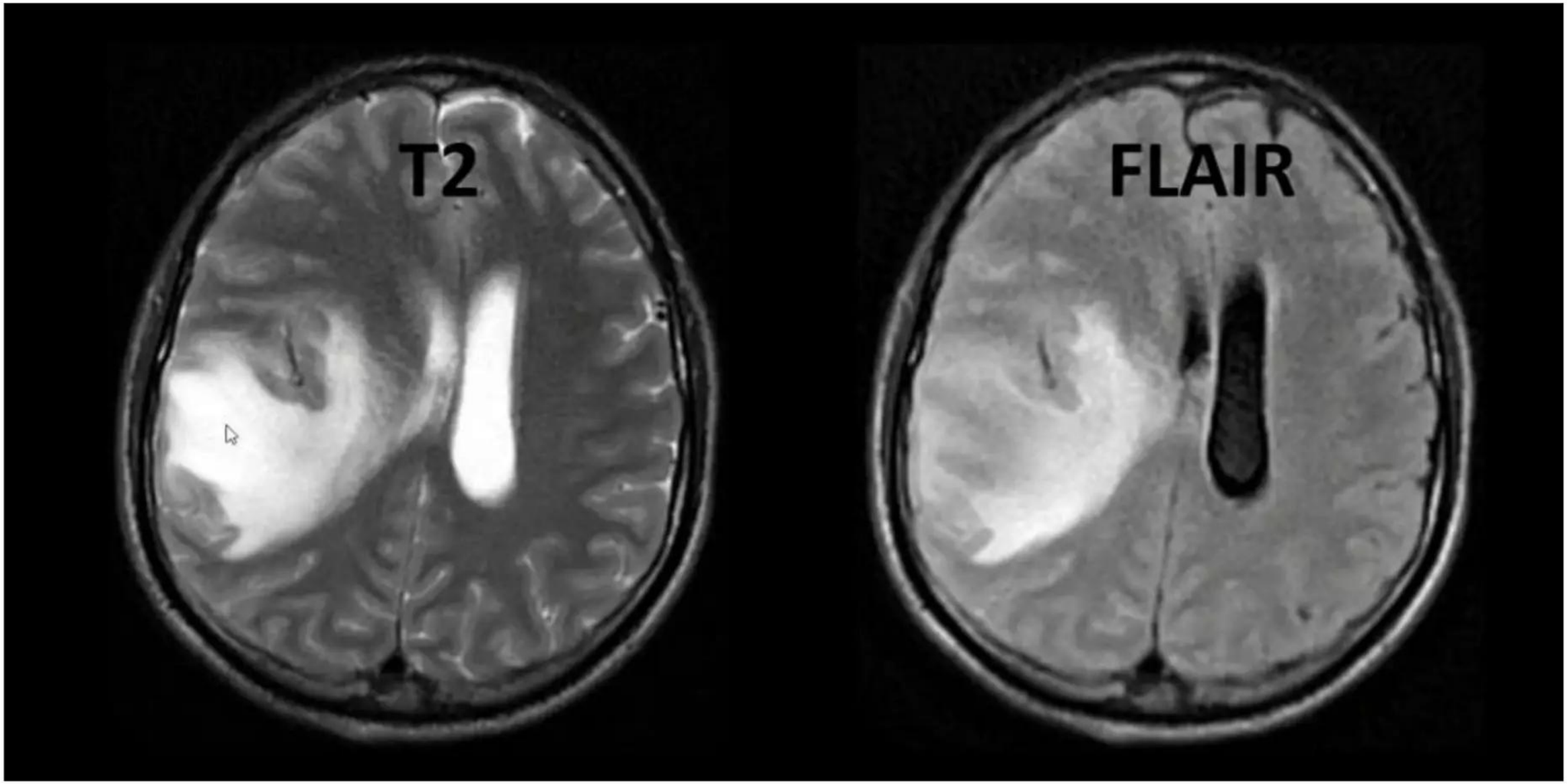

BASIC MRI seq - RADIOTHERAPY

- CT MRI fusion is done in Radiotherapy of brain tumors for better delineation of the target
- In PGI, T1C is fused with Planning CT images

Advanced MRI techniques

- Diffusion weighted image
- Perfusion weighted imaging
- Gradient Echo (GRE)
- Magnetic resonance spectroscopy

DWI
Diffusion Weighted Imaging

- Measures brownian movement of water molecules
- Water molecules in extracellular space
- Ischemia : cell swellings : cytotoxic edema
- **Recognition**
  - Fluid restriction is bright (cytotoxic edema)
- **Useful for**
  - Ishchemia
  - abscess

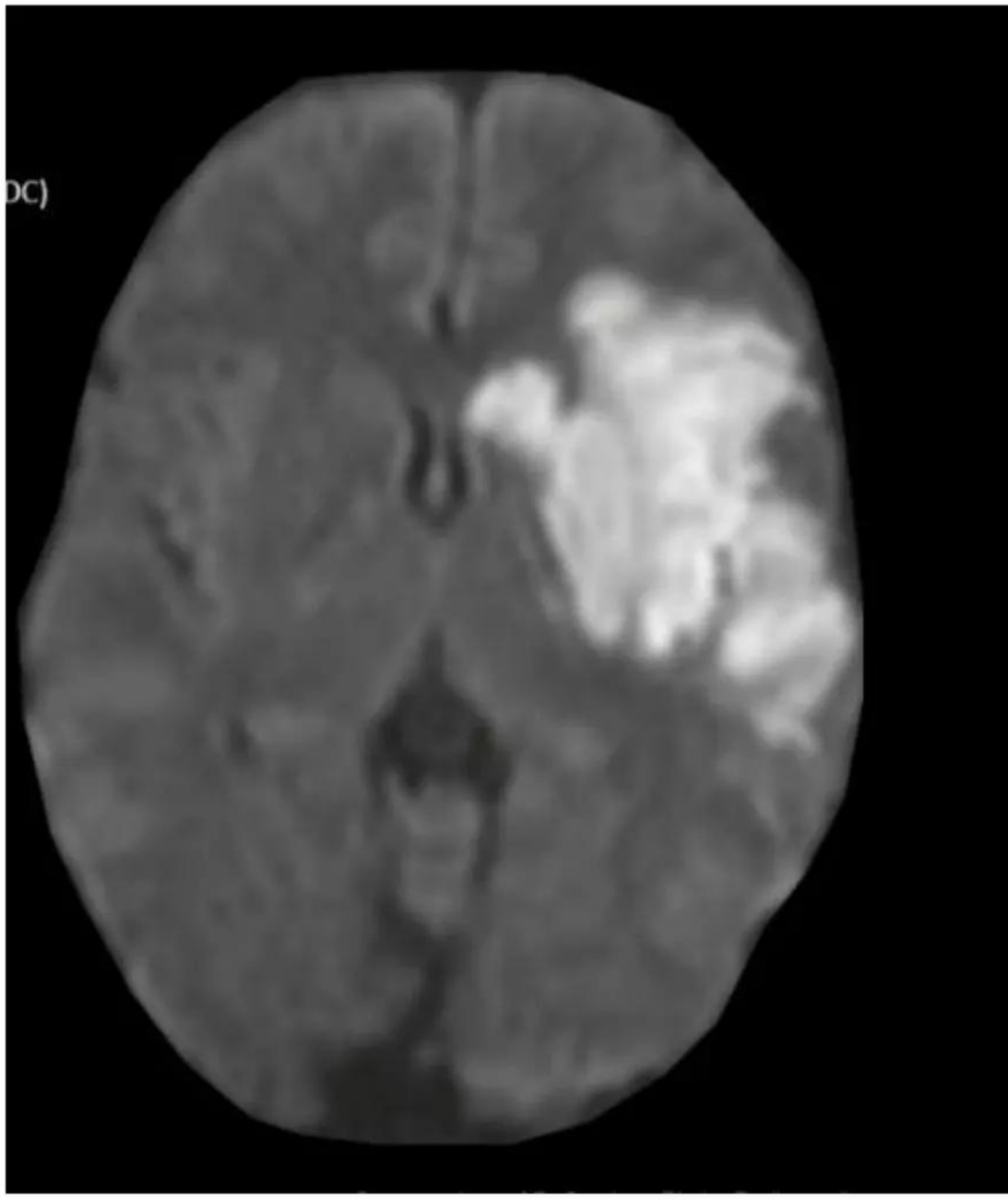

Diffusion weighted imaging

- Most tumours don't show significant restriction of diffusion
- High signal on DWI is seen with abscess, epidermoid cysts and acute infarction

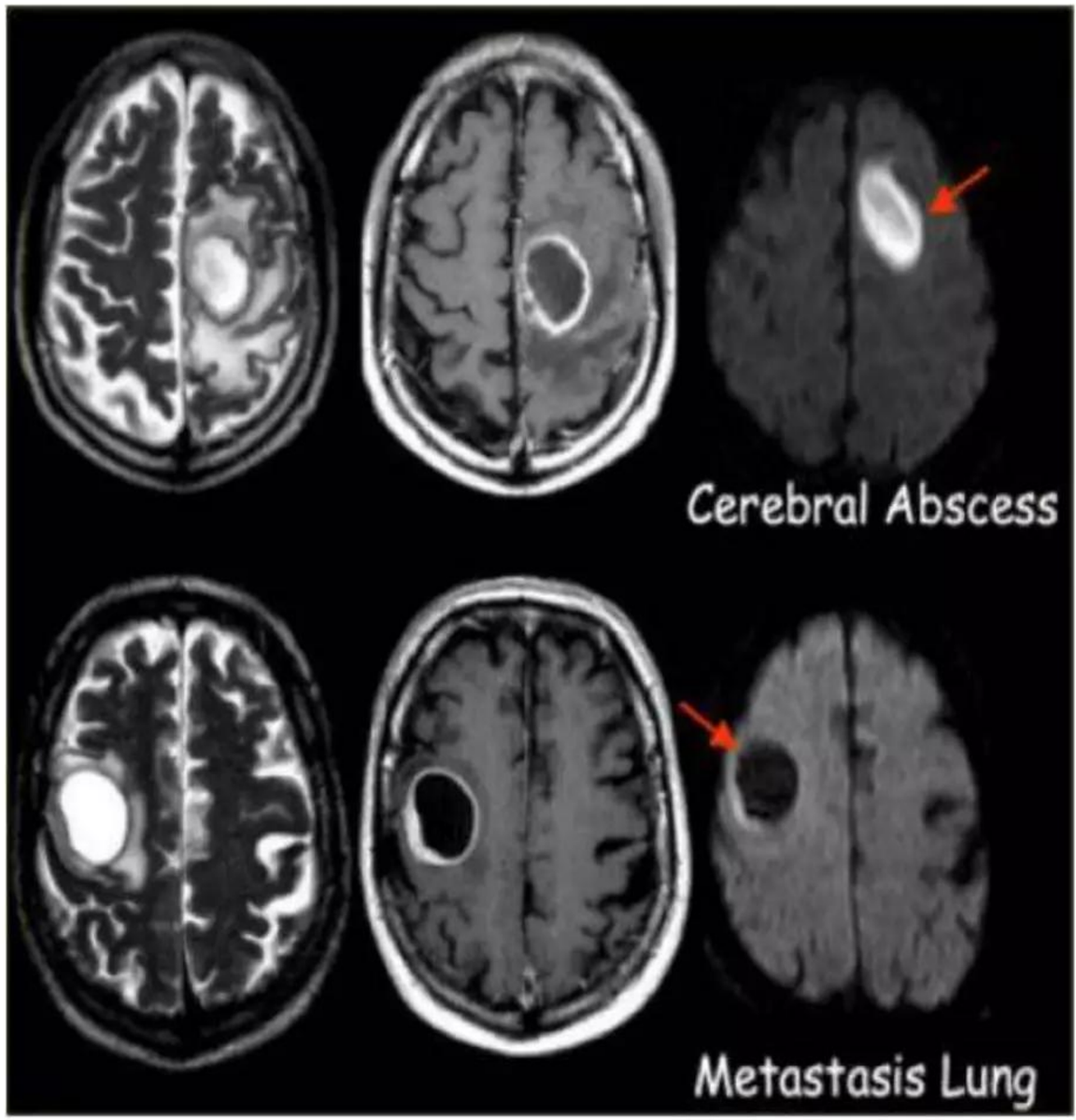

Perfusion weighted imaging

- Based on the premise that contrast material remains within the intravascular compartment
- Signal intensity depends on vascularity not on breakdown of BBB
- Better correlation with malignancy than CE

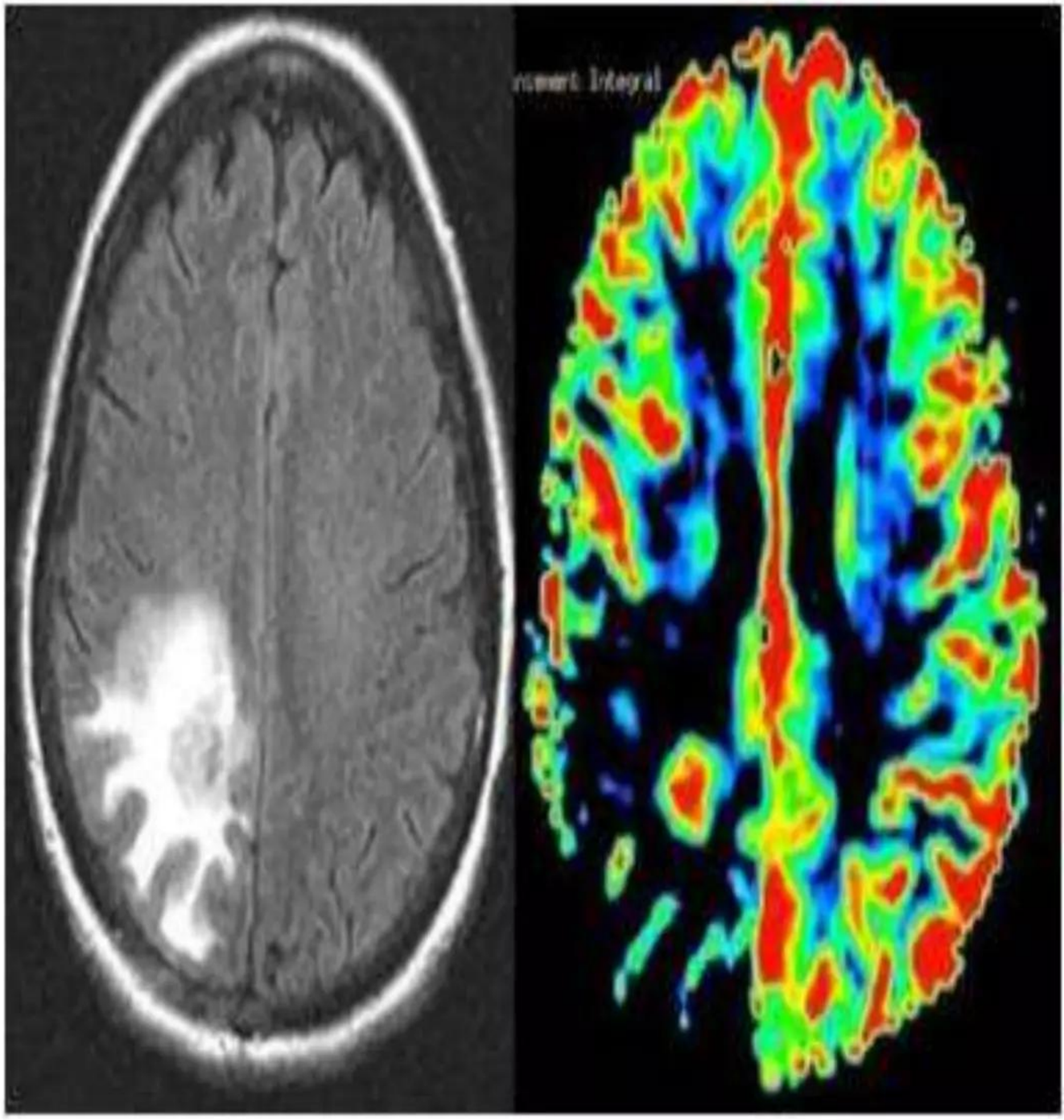

GRE
Gradient Echo

- **Recognition**
  - Paramagnetic substance are dark
    - Blood
    - Calcium
    - Other metals : wilson disease
  - **Useful for**
    - Early haemorrhage
    - Old haemorrhage (secondary to hemosiderin deposition)
    - Detecting hemorrhage in tumor

Magnetic Resonance Spectroscopy

- MRS allows analysis of specific metabolites within brain tissue
- Most commonly used echo times : 144 msec and 279 msec
- At these time spectrum is dominated by 5 different metabolite peaks
  - Choline : cell membrane turnover
  - Creatine : energy synthesis
  - NAA : exclusive to neuronal cells
  - Lactate : anaerobic metabolism
  - Lipid : cellular and myelin breakdown products

- The common way to analyze clinical spectra is to look at metabolite rations, namely NAA/Cr, NAA/Cho and Cho/Cr.
- Primary brain tumors show very specific pattern in elevation of choline and loss of NAA peaks

Metabolite Ratios

	Normal	Abnormal
NAA/Cr	2.0	<1.6
NAA/Cho	1.6	<1.2
Cho/Cr	1.2	>1.5

- The MRS spectrum of major metabolites in a normal brain

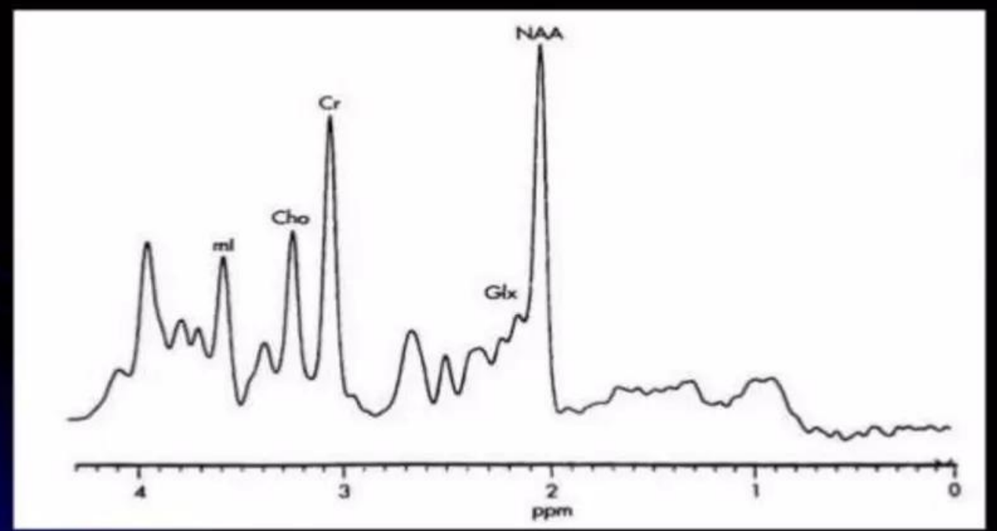

- **Usefulness for brain tumors**
  - To determine the degree of malignancy
  - As malignancy increases, NAA and Creatine decreases and choline, lactate and lipids increase
  - NAA decreases as tumor growth displaces or destroys neurons

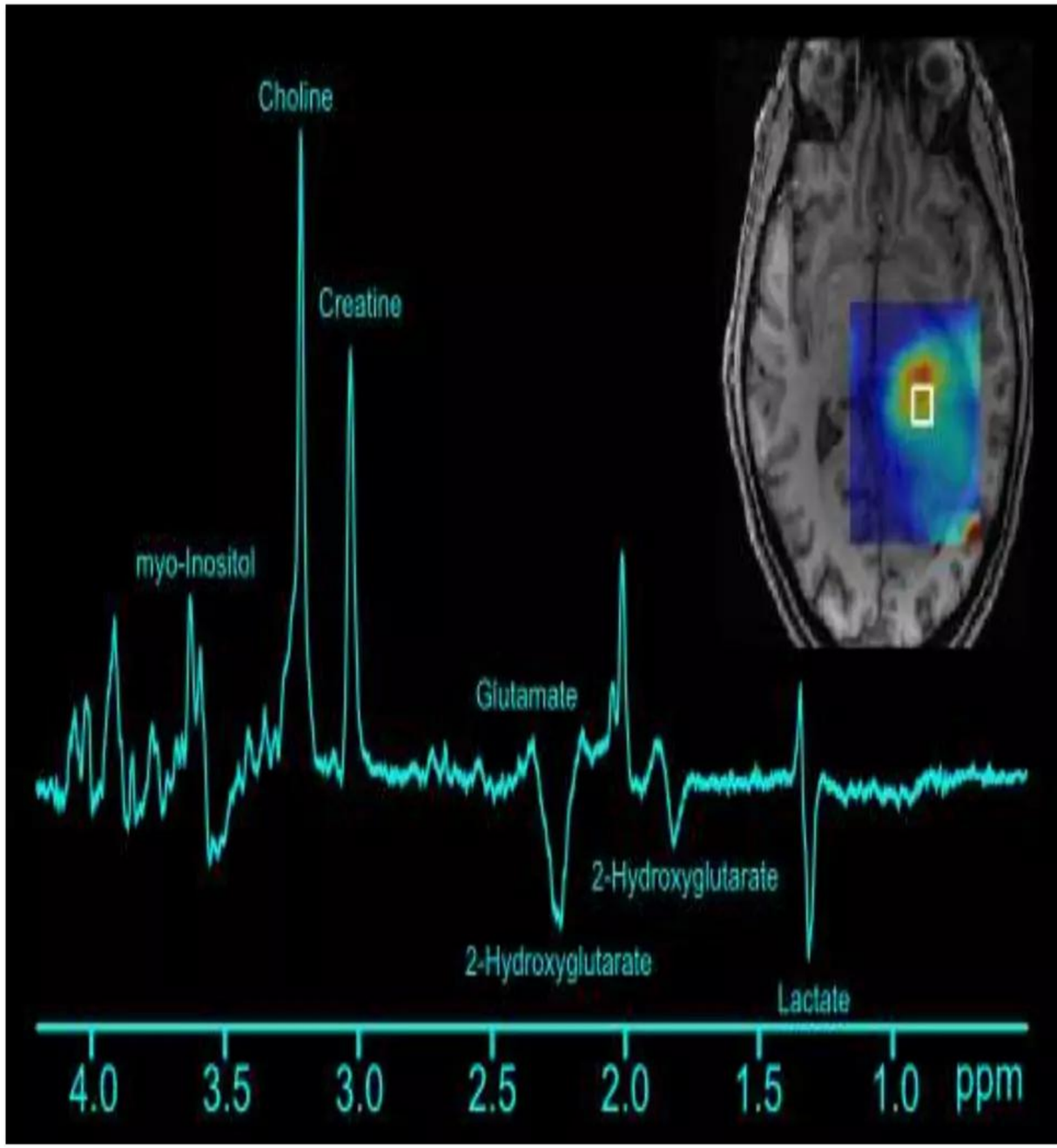

PET In Brain tumor imaging

- Metabolic imaging tool
- Produces visual impression of detailed biochemical changes caused by brain tumors and metabolic activities

- **Principle of Functioning**
  - PET provide concentrations of tracer amounts of positron emitting isotopes, introduced into body
  - Radioisotopes decay to produce positrons, These positrons combine with adjacent electrons to produce two gamma rays that travel in opposite direction.
  - Detection of these gamma rays allows calculation of their exact point of origin.

Most commonly used Isotope : FDG

- FDG detect metabolic differences between normal brain, low grade and high grade gliomas.
- FDG competes with glucose for hexokinase. FDG-6-P is trapped in cells in proportion to glucose metabolic rate, PET can detect its accumulation.

Amino acid PET tracers

- It visualizes radiolabelled aminoacids utilized for protein synthesis which are accelerated in tumor
- Shows higher tumor to normal tissue contrast.
- Most common tracer : 11-C-methionine

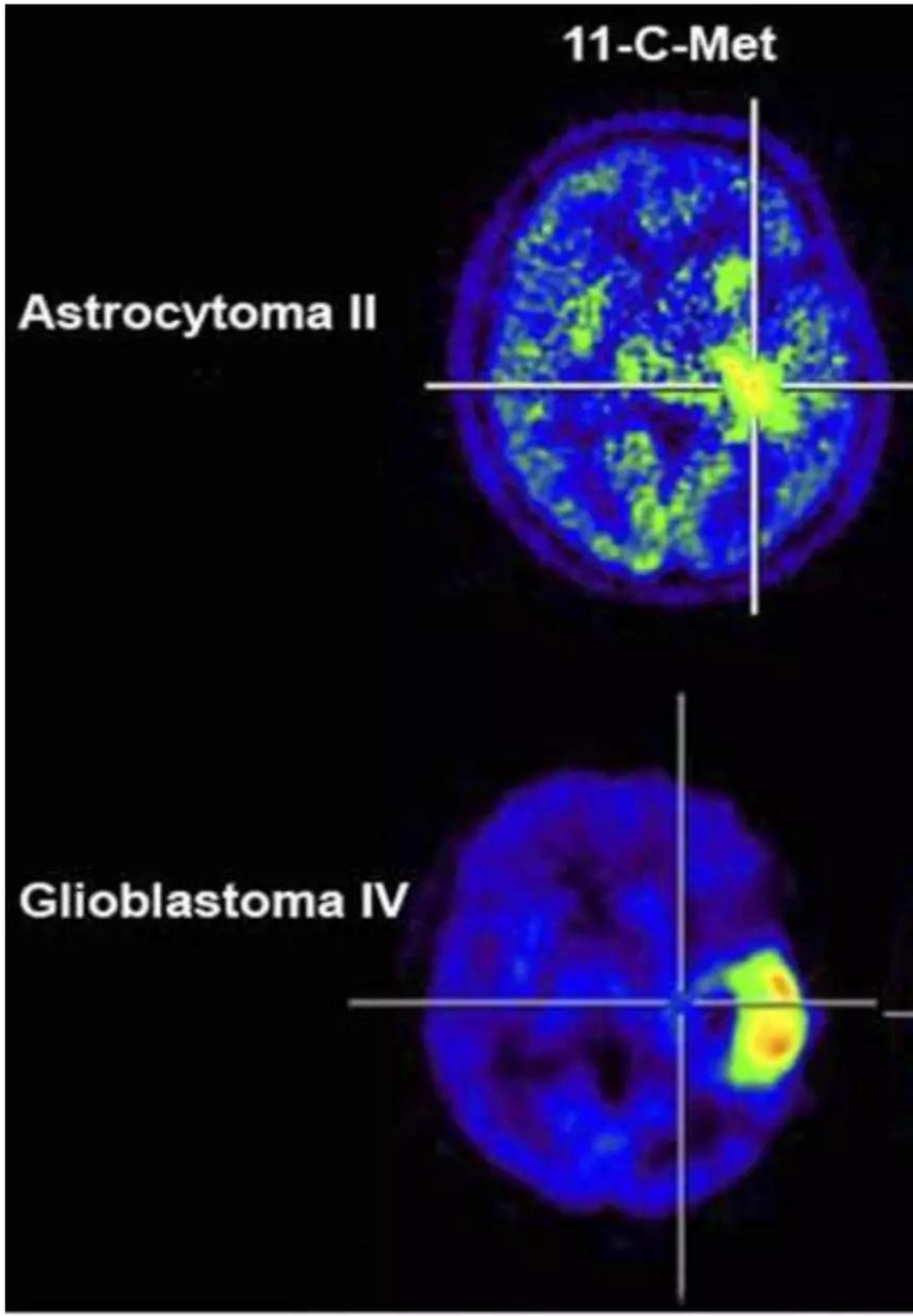

Uses

- Able to distinguish between benign and malignant lesion
- Better for differentiating between recurrent brain tumor and Rx related changes like radiation necrosis or post surgical changes
- Aggressive tumor responds with bright signal whereas radiation necrosis does not.

Single Photon Emission Computed Tomography (SPECT)

- Gamma Rays emitted during radionucleide decay are detected by gamma camera.
- **Advantages**
  - Localization of defects is more precise
  - Extend and size of defects is better defined
  - Images free of background

APPROACH TO AN IMAGE

What am I looking at?

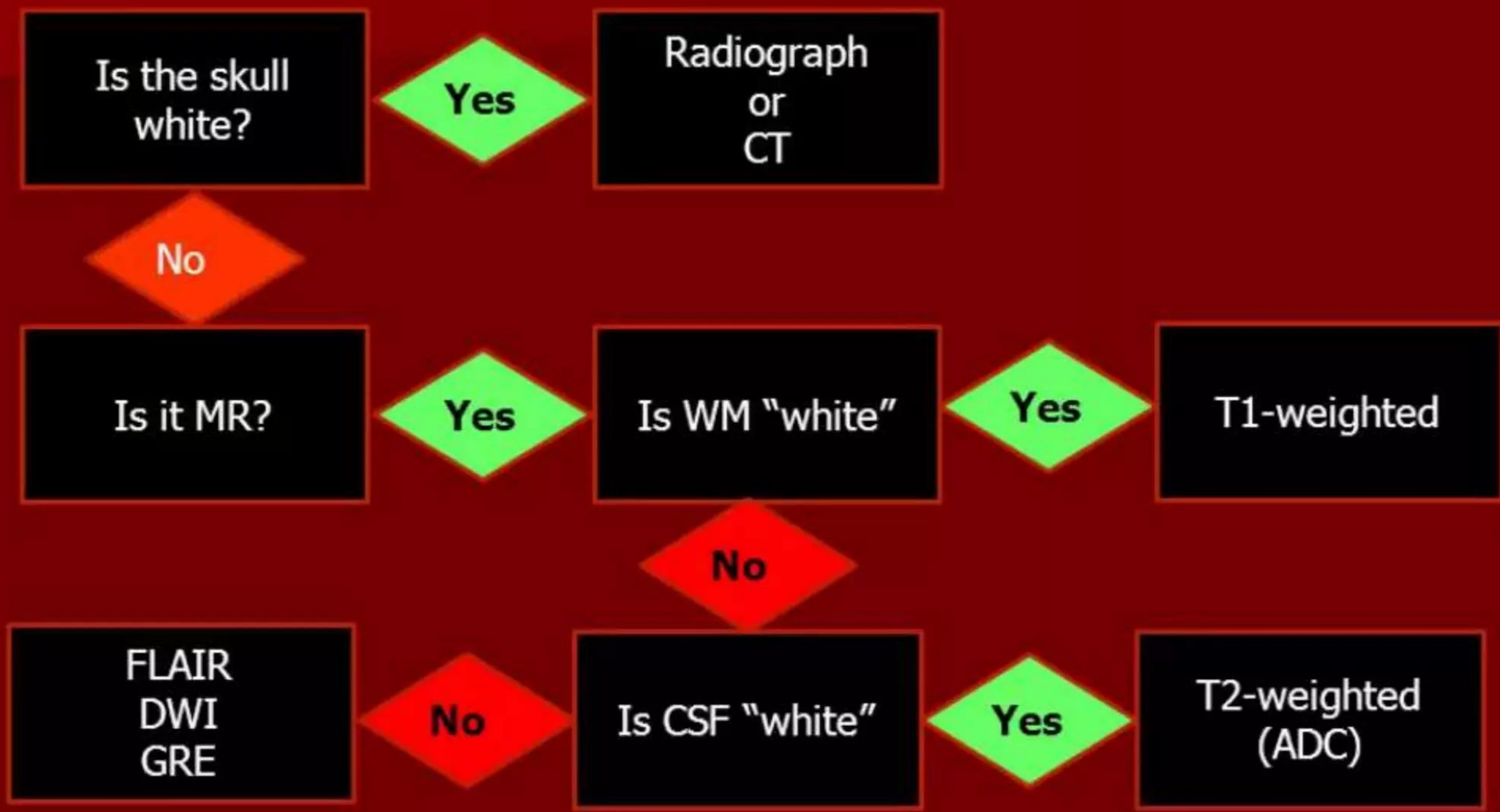

Approach – clues to diagnosis

- Age
- Location
- Local tumour spread
- Solitary or multifocal
- Specific imaging characteristics

Age distribution

- 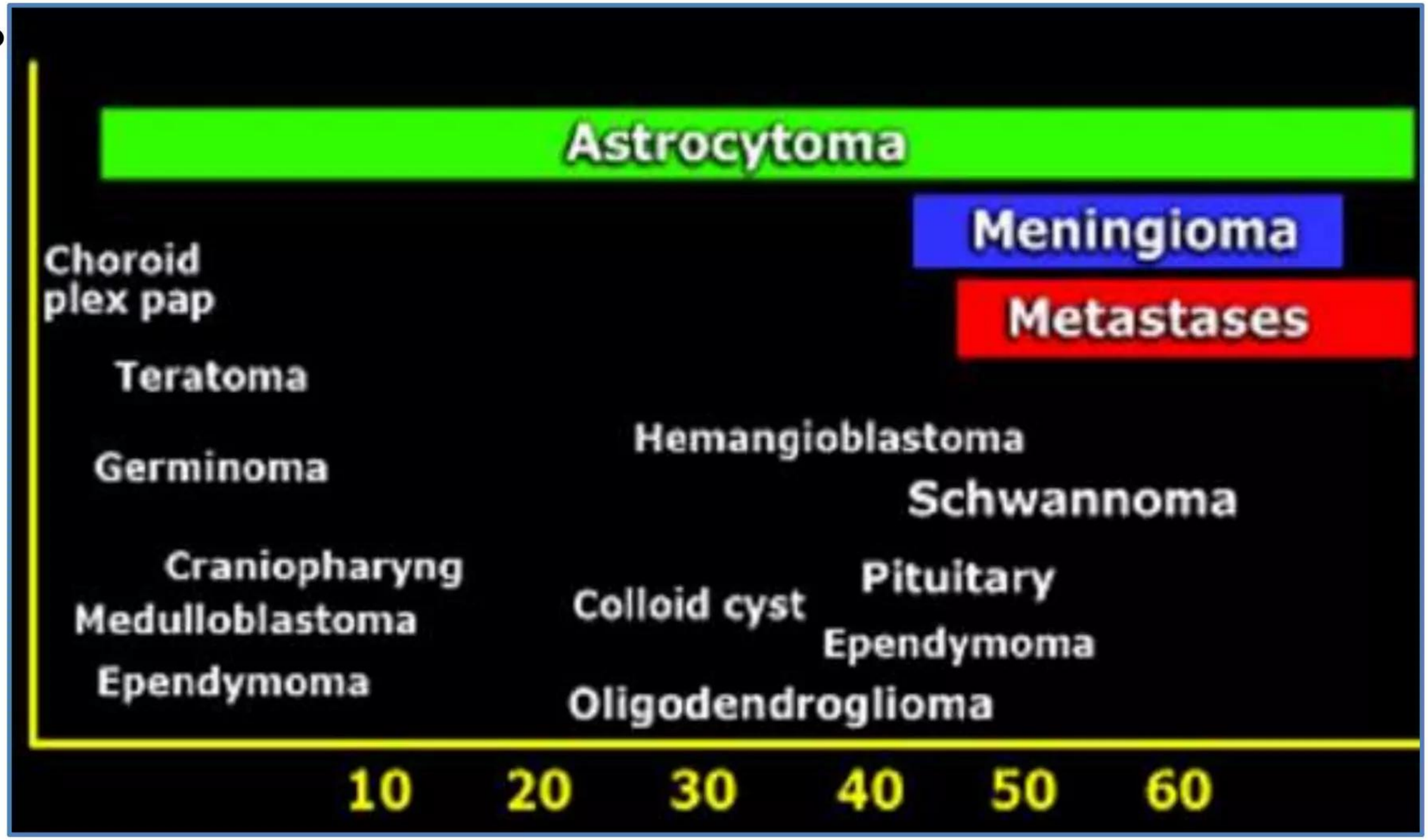

Location : CNS tumors can be classified into:

- Brain tumors
- Spinal tumors

Brain Tumors

- **Primary**
  - Intra-axial tumors
    - Supratentorial
    - infratentorial
  - Extra-axial tumors
    - Meningioma
    - schwannoma
- **Metastases**
  - Lung 50%
  - Breast 15%
  - Melanoma 10%
- **Supratentorial**
  - Adult
    - Metastases
    - Gliomas
  - Pediatric
    - Astrocytoma
    - Pleomorphich Xanthoastrocytoma
    - ganglioglioma
- **infratentorial**
  - Adult
    - Metastases
    - hemangioblastoma
  - Pediatric
    - Juvenile pilocytic astrocytoma
    - Medulloblastoma
    - Ependymoma
    - Brain stem Gliomas

- Specific anatomic Sites
  - Sella/suprasellar
  - Pineal region
  - Intraventricular

Intra-axial Vs Extra-axial tumours

- Signs of Extra-axial tumours
  1. CSF cleft
  2. Displaced subarachnoid vessels
  3. Cortex between brain and lesion
  4. Broad dural base
  5. Bony reaction

  – >80% EATs are either meningioma or schwannoma

Signs of extra axial tumor
1. CSF cleft

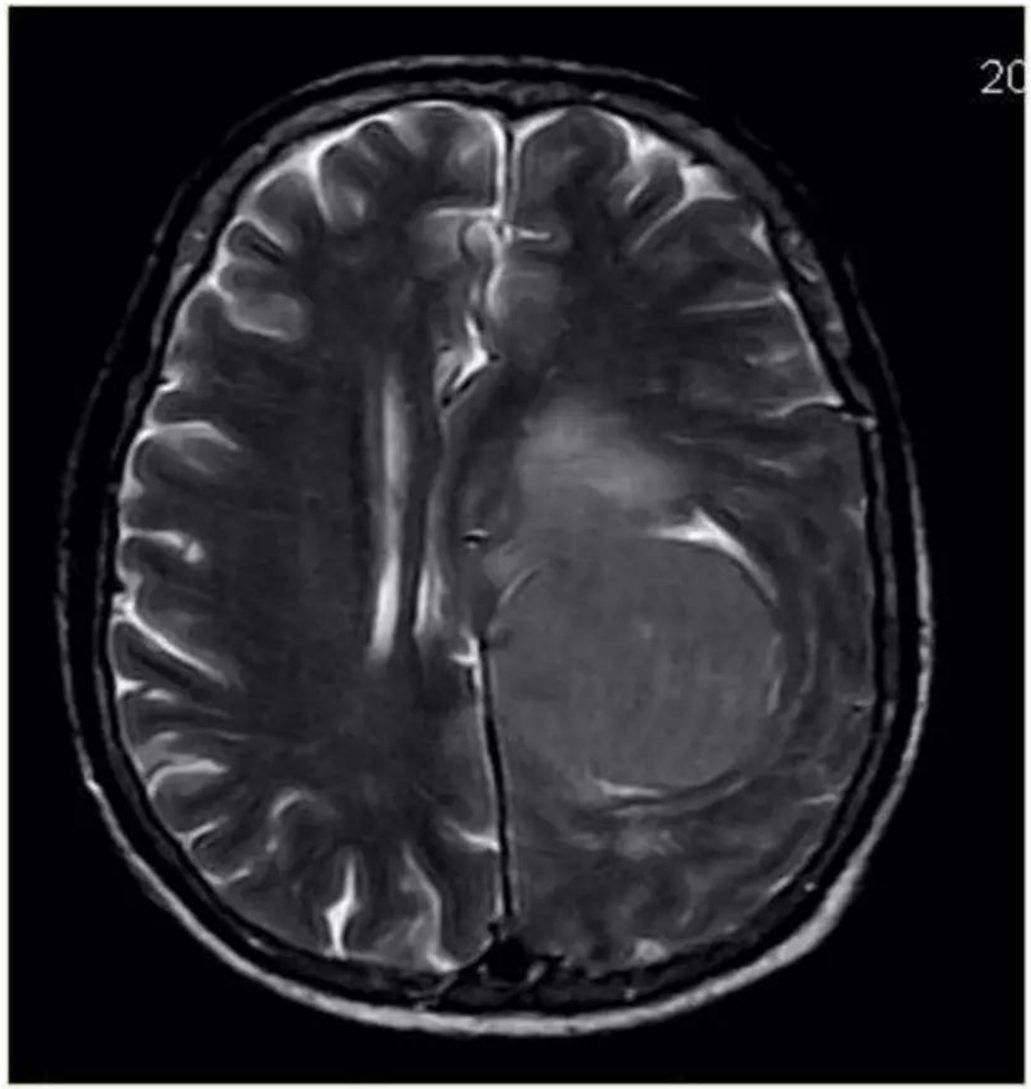

Vs

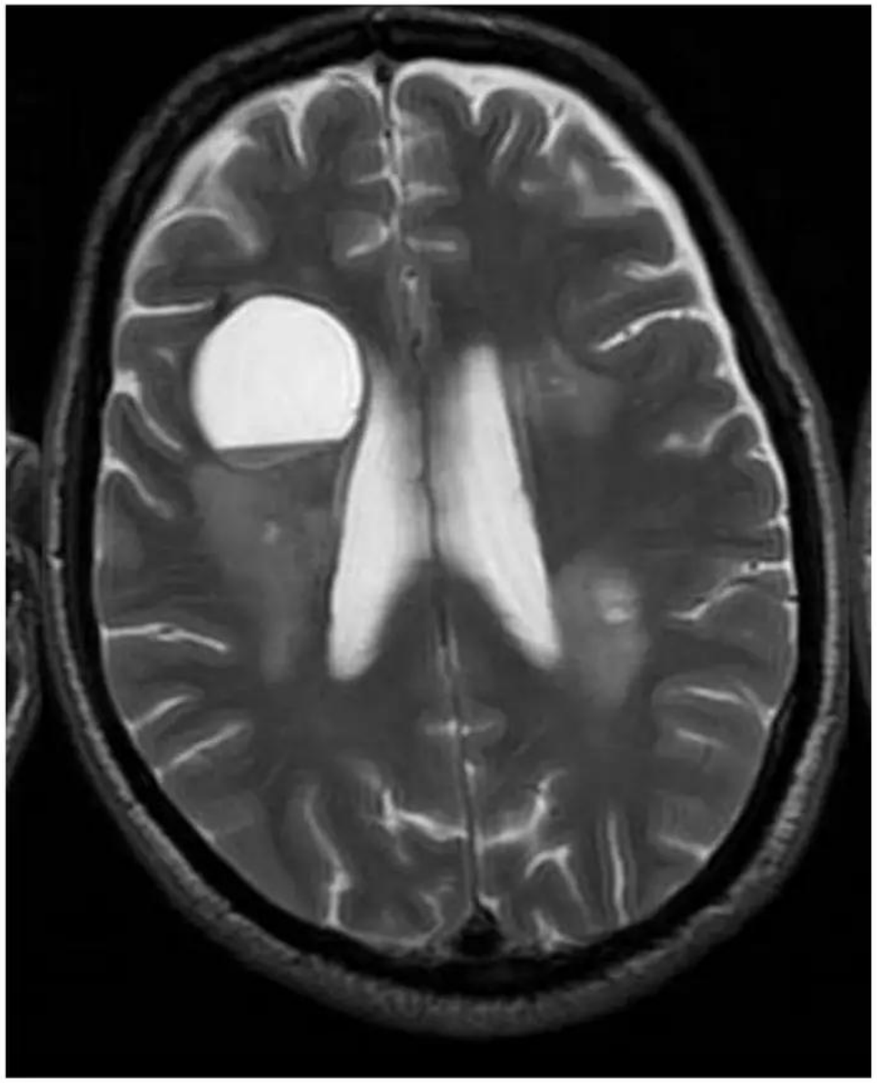

2.Vessels between lesion and brain

3. Definitive cortex between lesion and brain

Vs

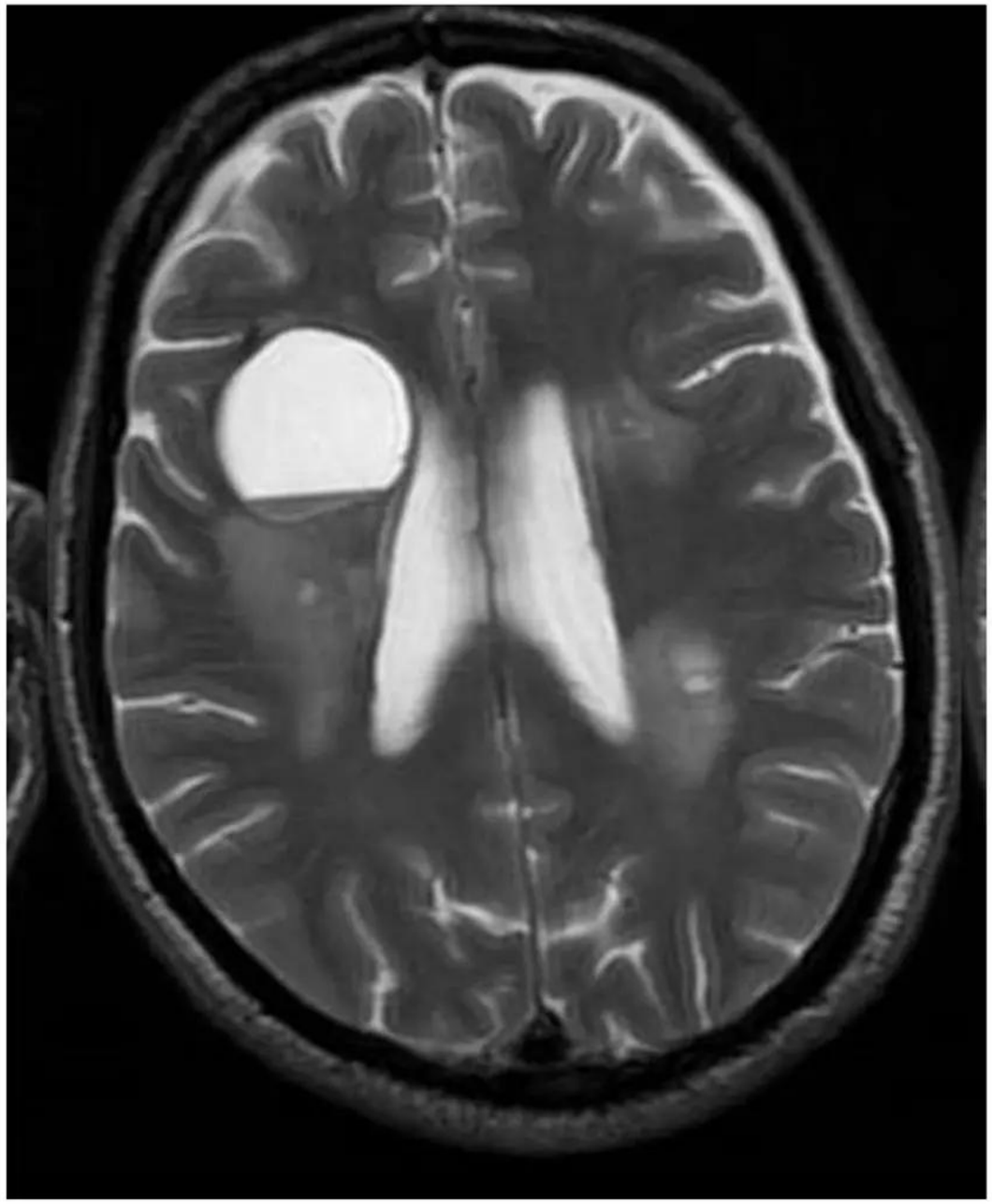

4.Broad based towards dura

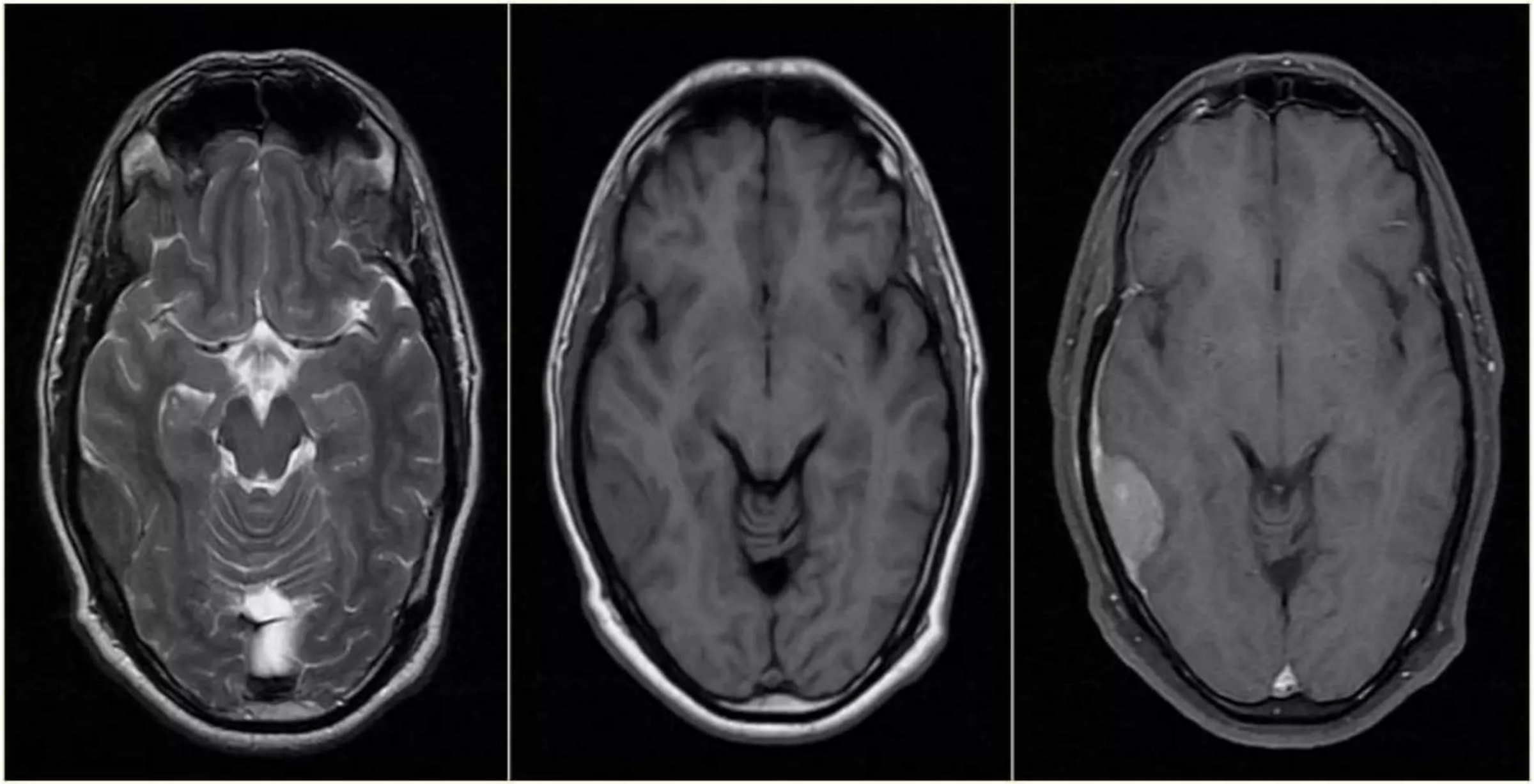

5. Adjacent bony changes

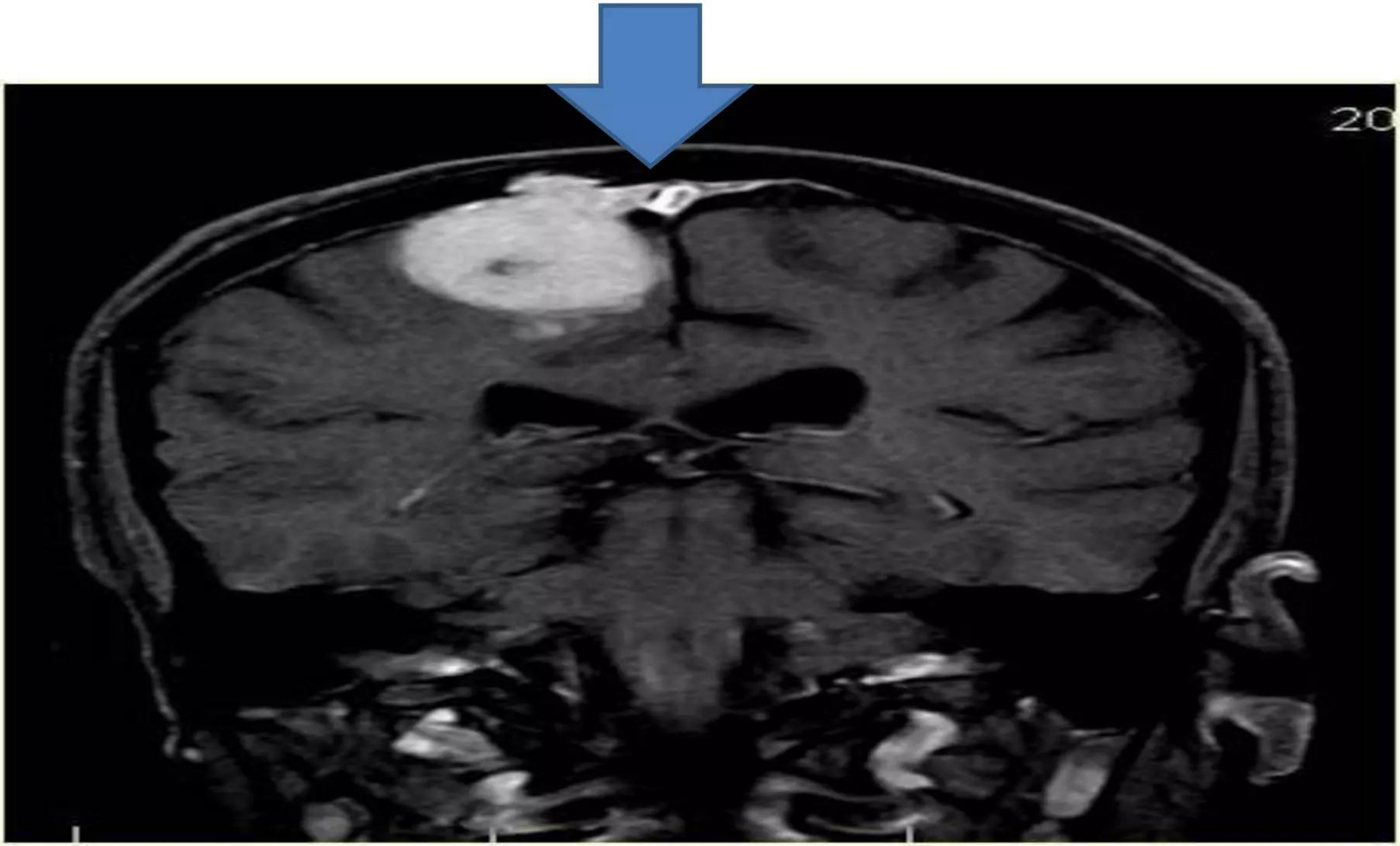

Enhancement of meninges

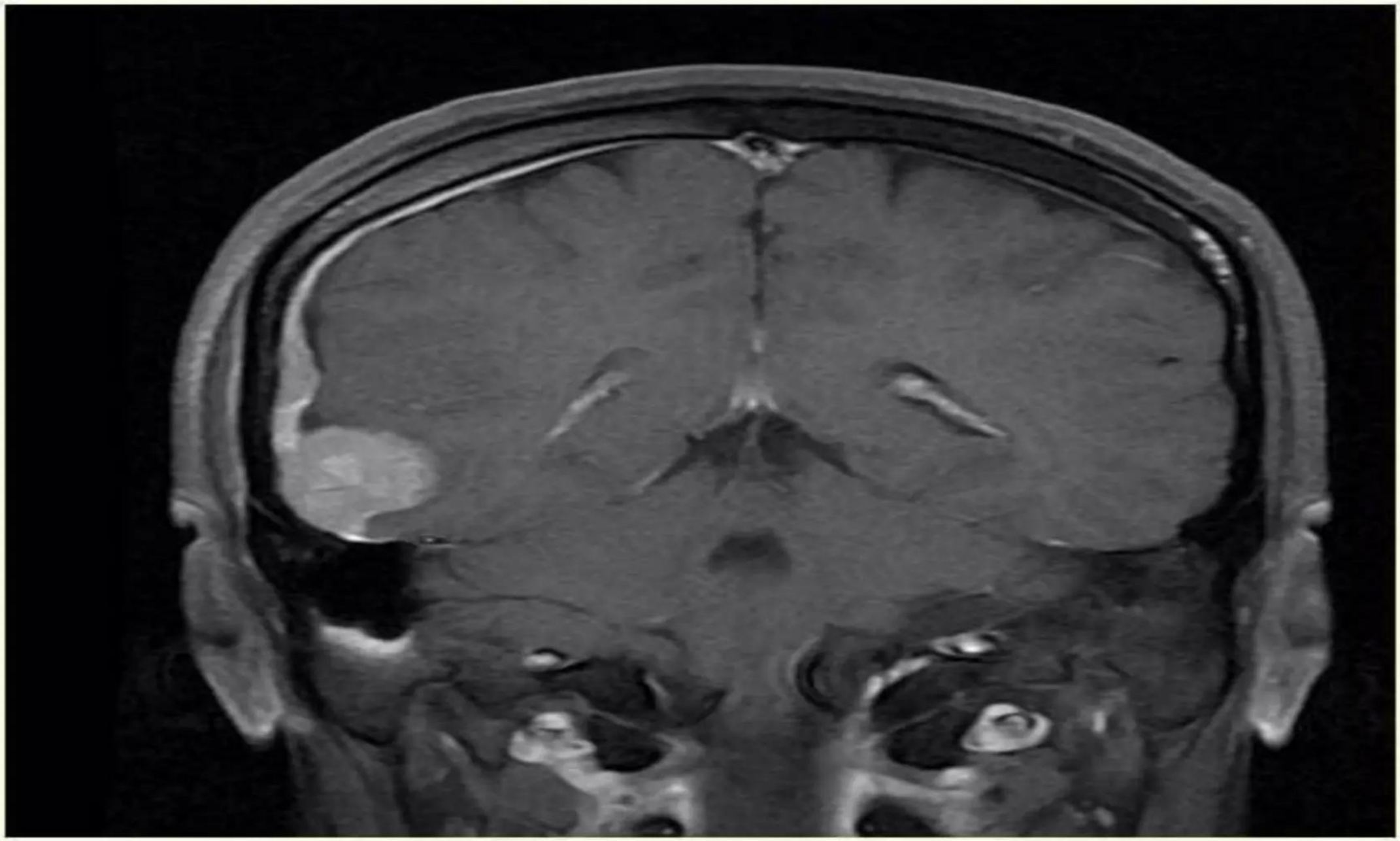

Local tumor Spread
Midline crossing

- GBM frequently crosses the midline by infiltrating through the white matter tracts of corpus callosum
- Radiation necrosis mimics GBM and sometimes crosses the midline
- Meningioma can spread along the meninges to the contralateral side
- Lymphoma is usually located near the midline

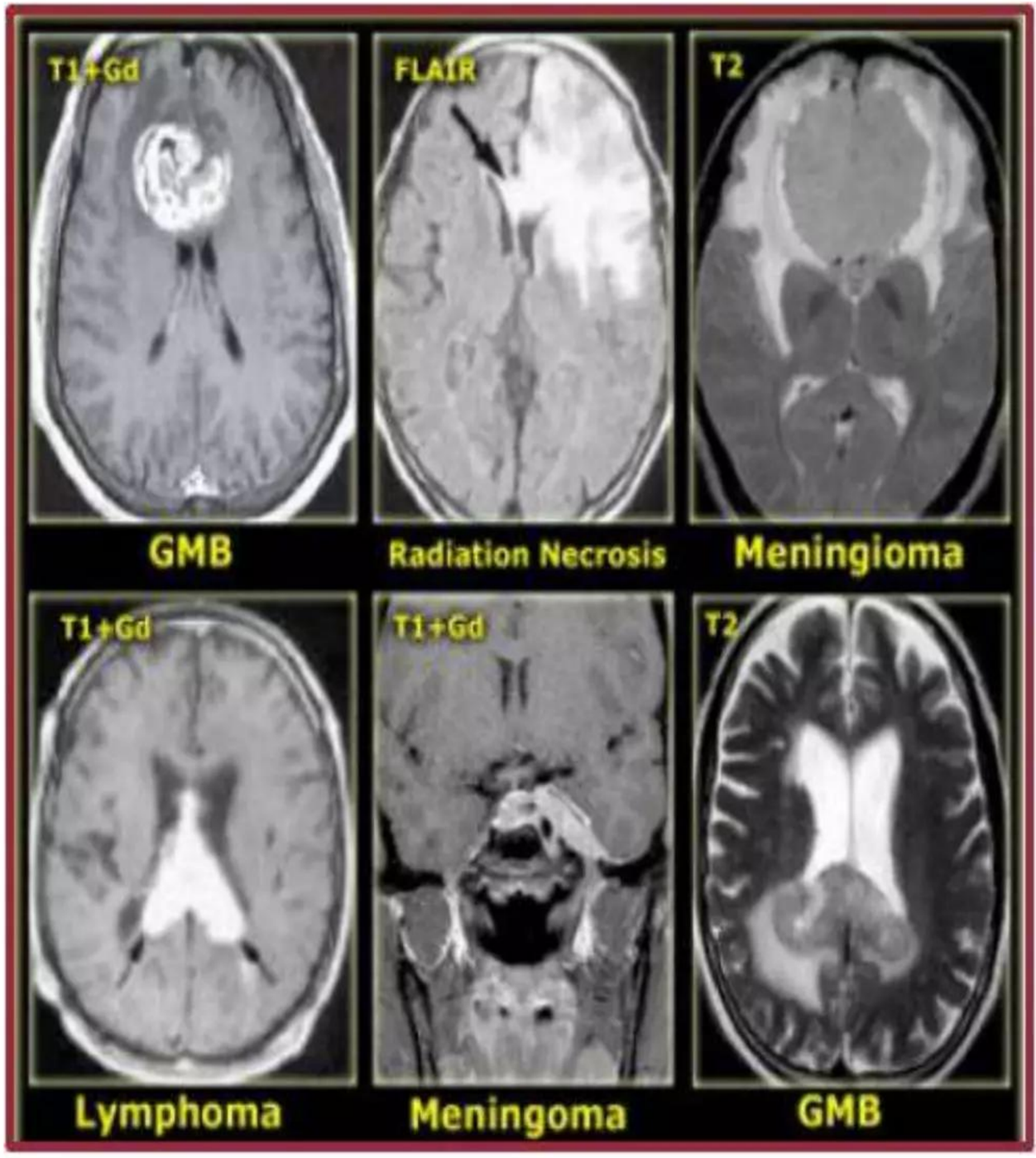

Effect on adjacent structures

- **Primary brain tumours** :
  - Less mass effect for their size than expected d/t their infiltrative growth
- **Metastasis and Extra-axial tumours**
  - like meningiomas and schwannomas have more mass effect d/t their expansive growth

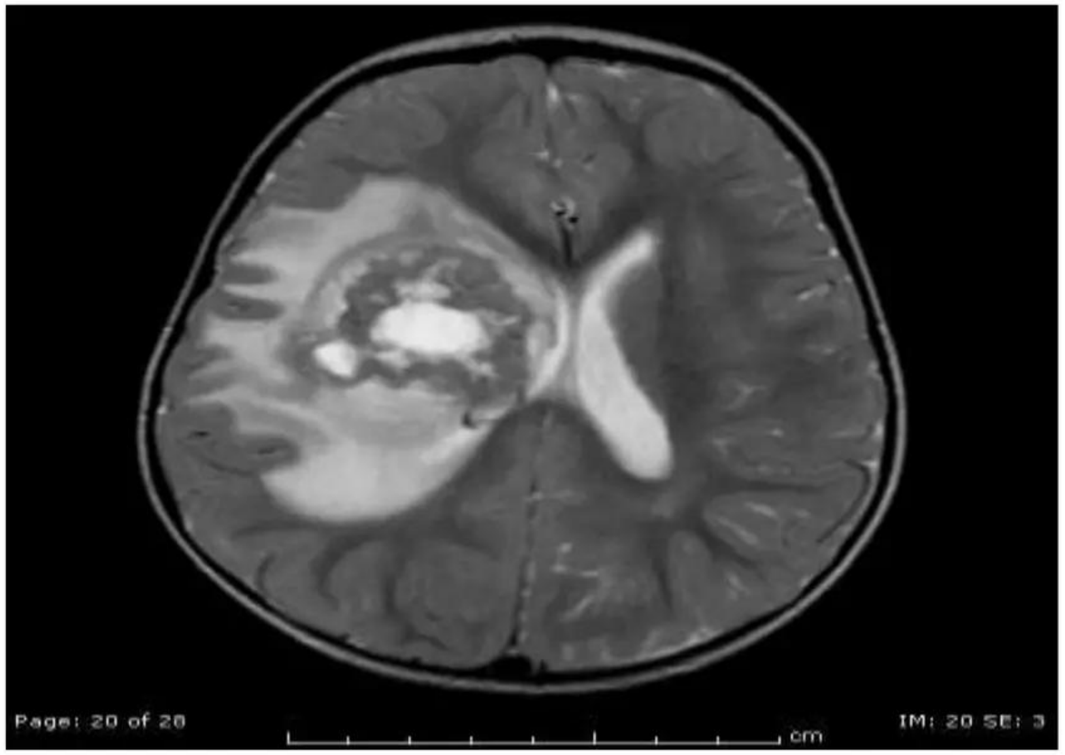

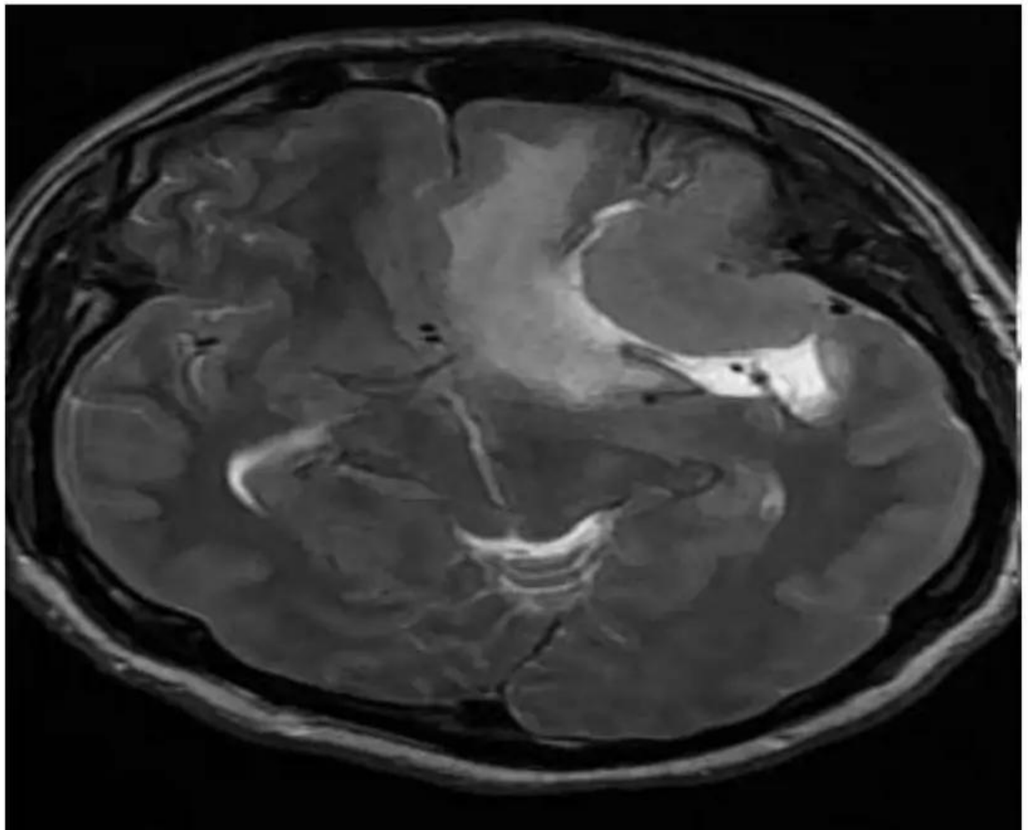

Solitary Vs Multifocal Lesions

- Metastasis and CNS lymphoma : Multiple lesions
- Seeding metastsis : Medulloblastoma and ependymomas
- Multiple brain tumours may occur in
  - NF I : optic gliomas, astrocytomas, Schwannoma
  - NF II : meningiomas, ependymomas ,B/L Schwannoma
  - Tuberous sclerosis : ependymomas, intraventricular giant cell astrocytomas
  - Von Hippel Lindau : Hemangioblastomas

Contrast enhancement

- Extra axial tumours, pituitary, pineal and choroid plexus tumours, enhance because they are outside BBB
- CE does not visualize full extent of infiltrative tumours eg. Gliomas
- In gliomas, enhancement indicates higher degree of malignancy
- Ganglioglioma and pilocytic astrocytomas are exceptions, low grade tumours that enhance vividly

Contrast enhancement Patterns

- **No enhancement**
  - Low grade astrocytomas
  - Cystic non tumoral lesions
- **Homogenous enhancement**
  - Germinoma
  - Pituitary adenomas
  - Pilocytic astrocytomas
  - Hemangioblastoma
  - Ganglioglioma
  - Meningioma and
  - schwannoma

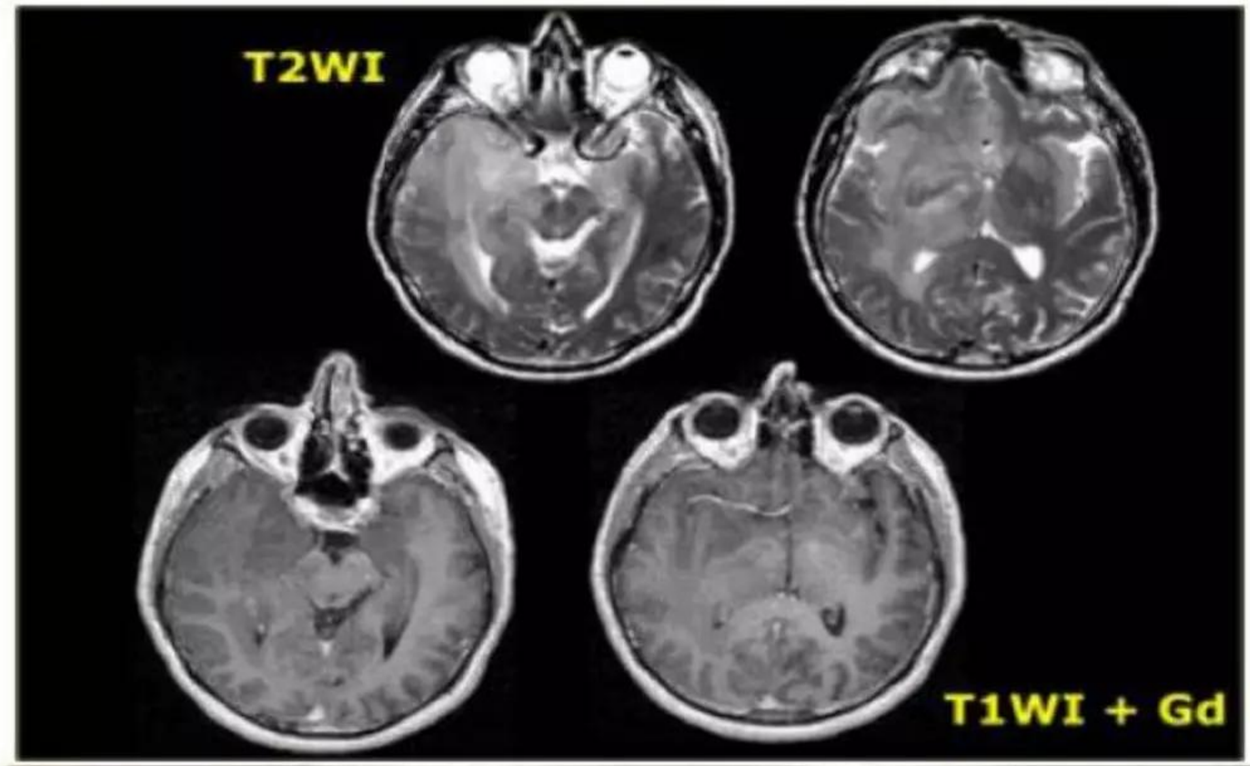

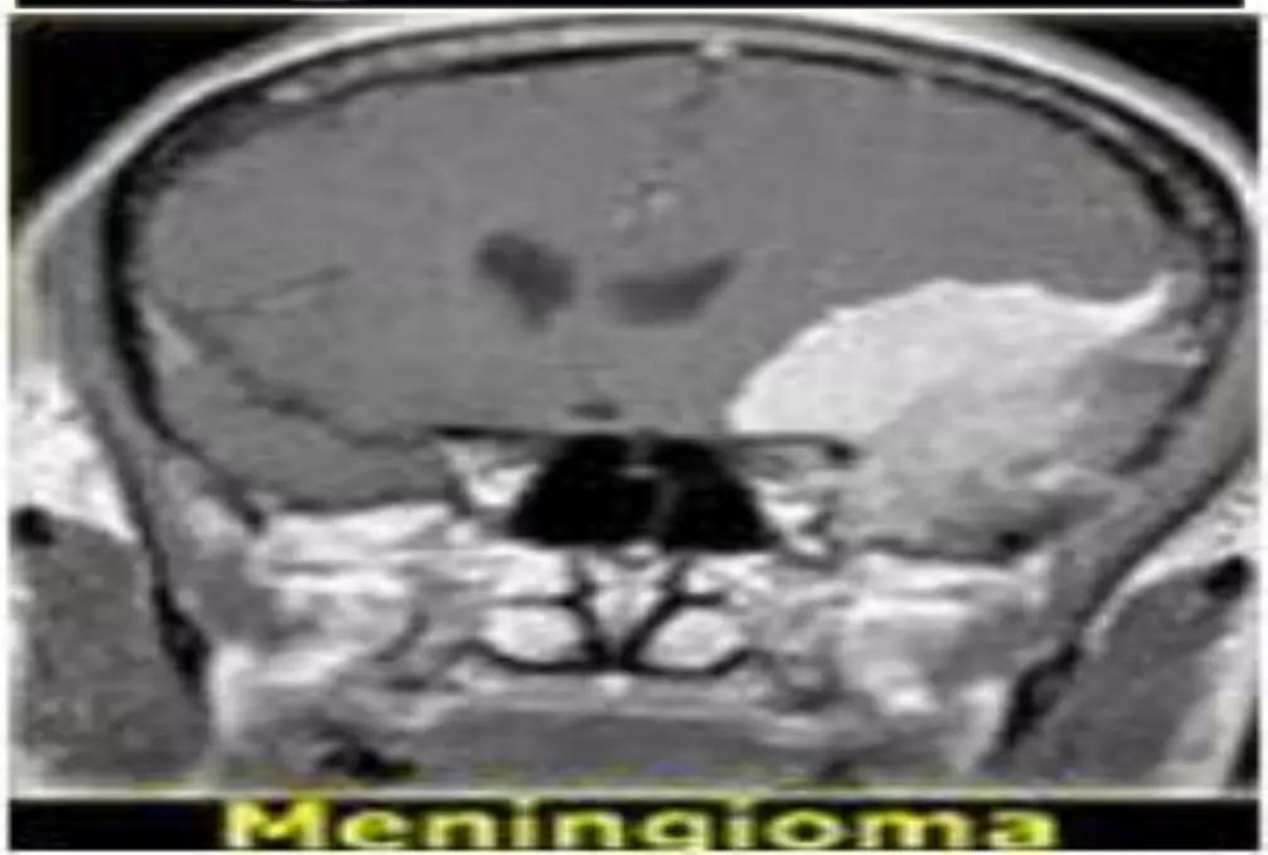

- **Patchy enhancement**
  - Radiation necrosis
- **Ring enhancement**
  - High grade gliomas
  - Metastasis and
  - abscess

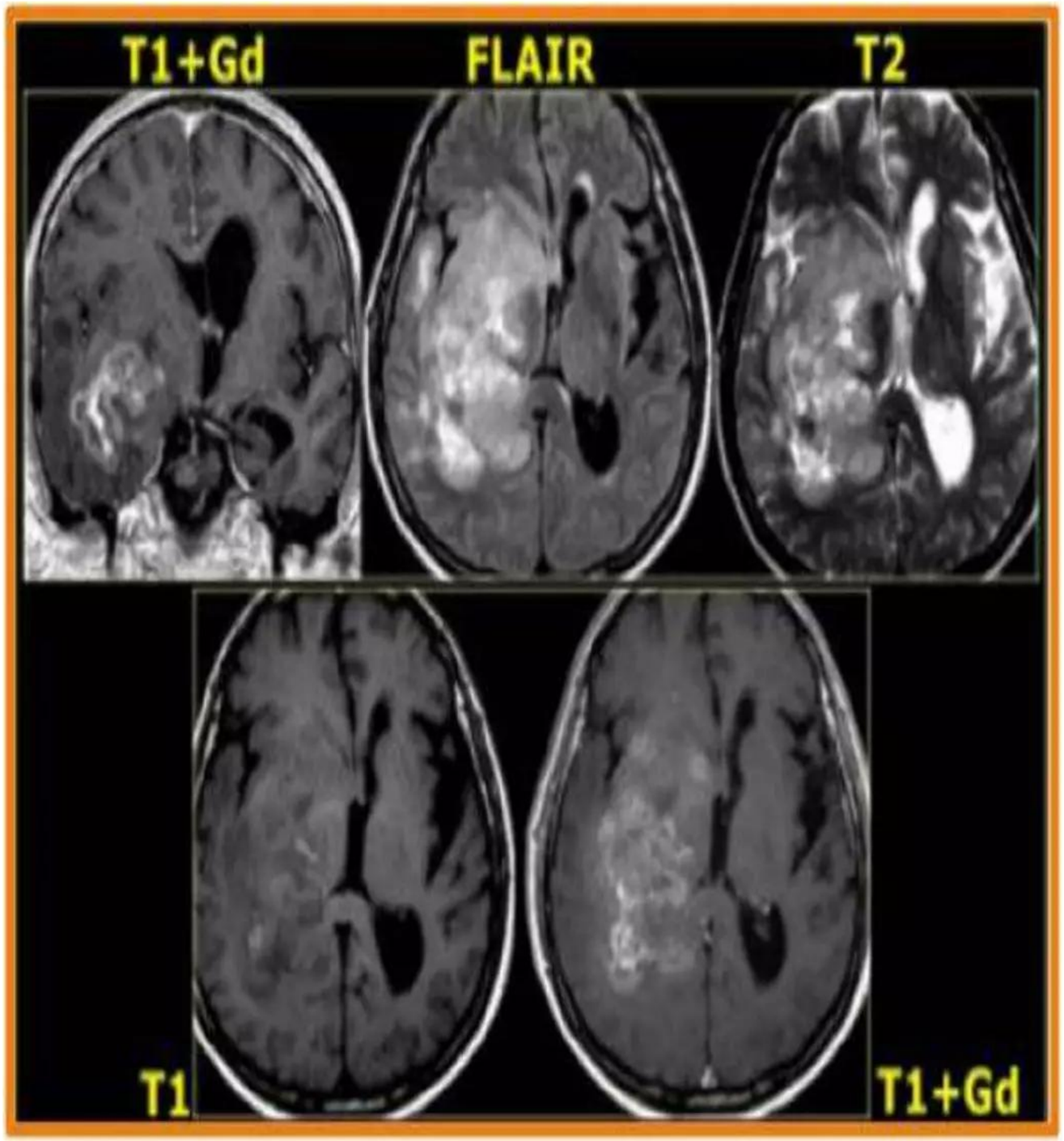

Individual description of important tumors

Meningioma

- **non contrast CT**
  - 60% Hyperdense to normal brain
  - 20-30% have some calcification
- **Post contrast CT**
  - 72% brightly and homogenously enhance
  - Malignant or cystic variants demonstrate more heterogeneity
- **Hyperostosis 5%**
  - Typical for meningioma that abut the base of skull

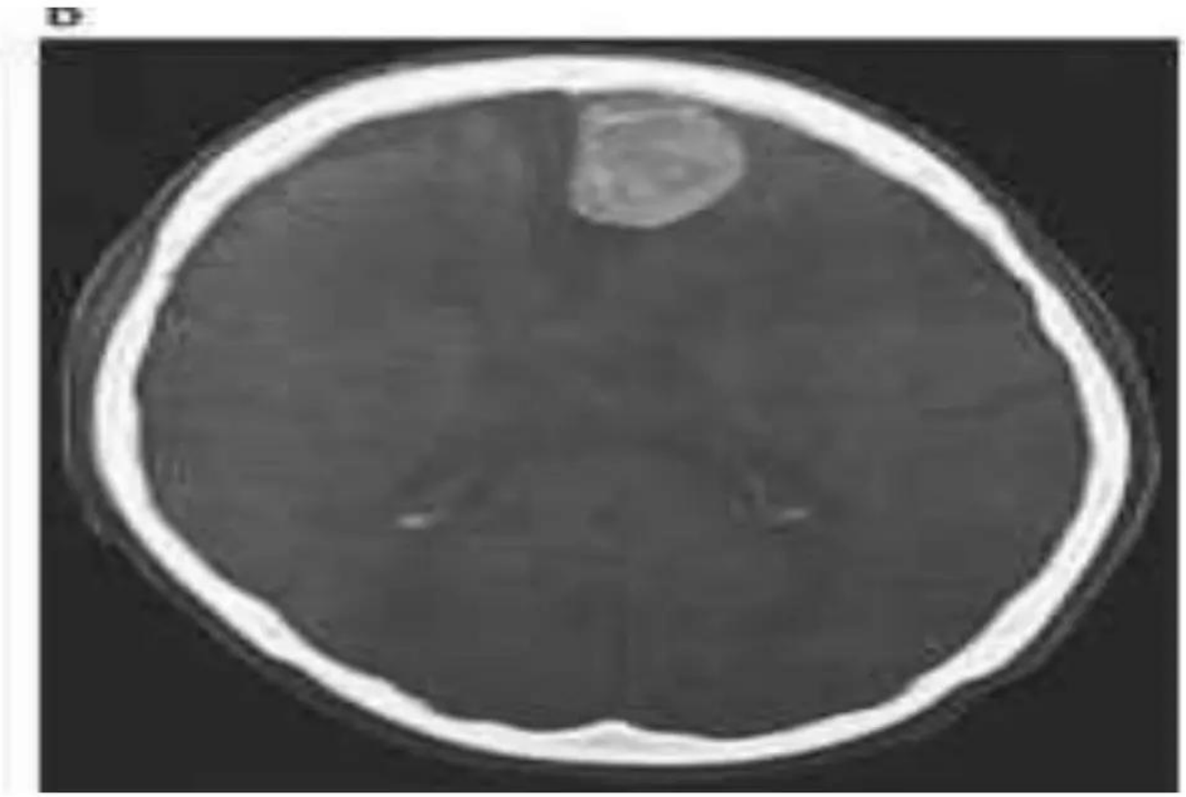

Helpful signs of meningioma on MRI

- CSF vascular cleft sign
- Dural tail sign : 60 to 70%
- Sunburst or spokewheel appearance of vessels
- Arterial narrowing
  - Typically in meningioma which encase arteries

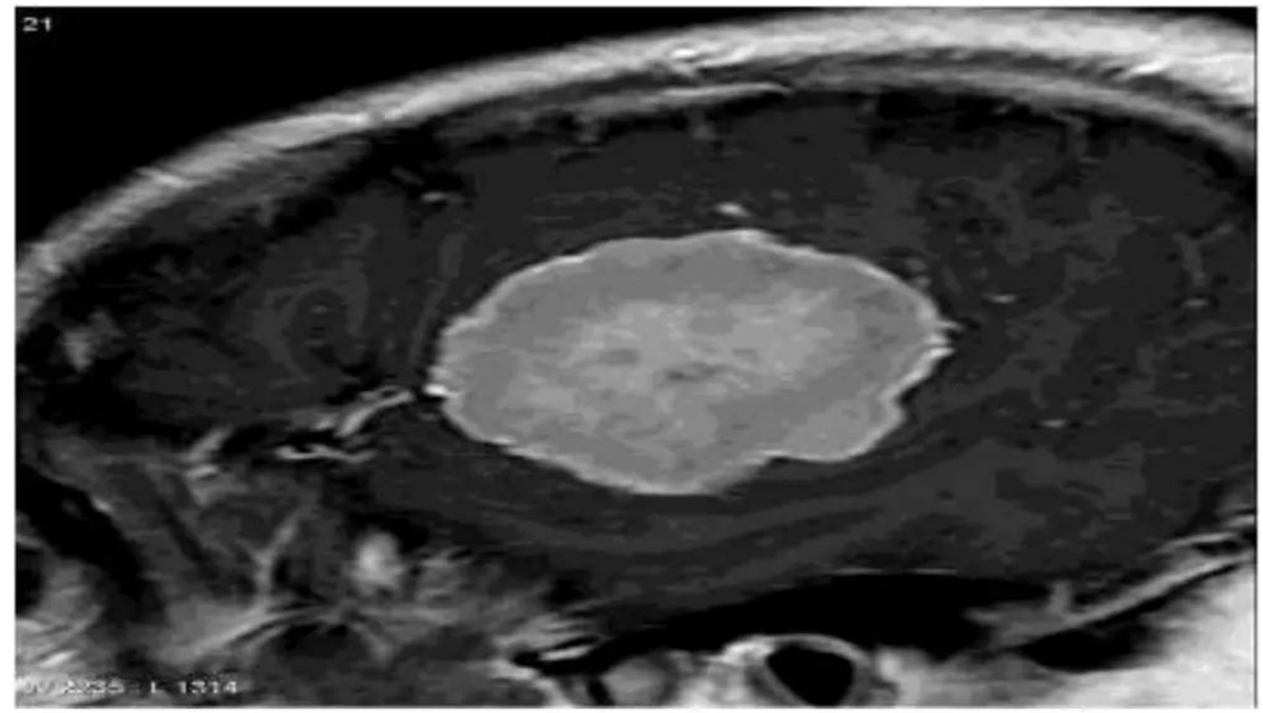

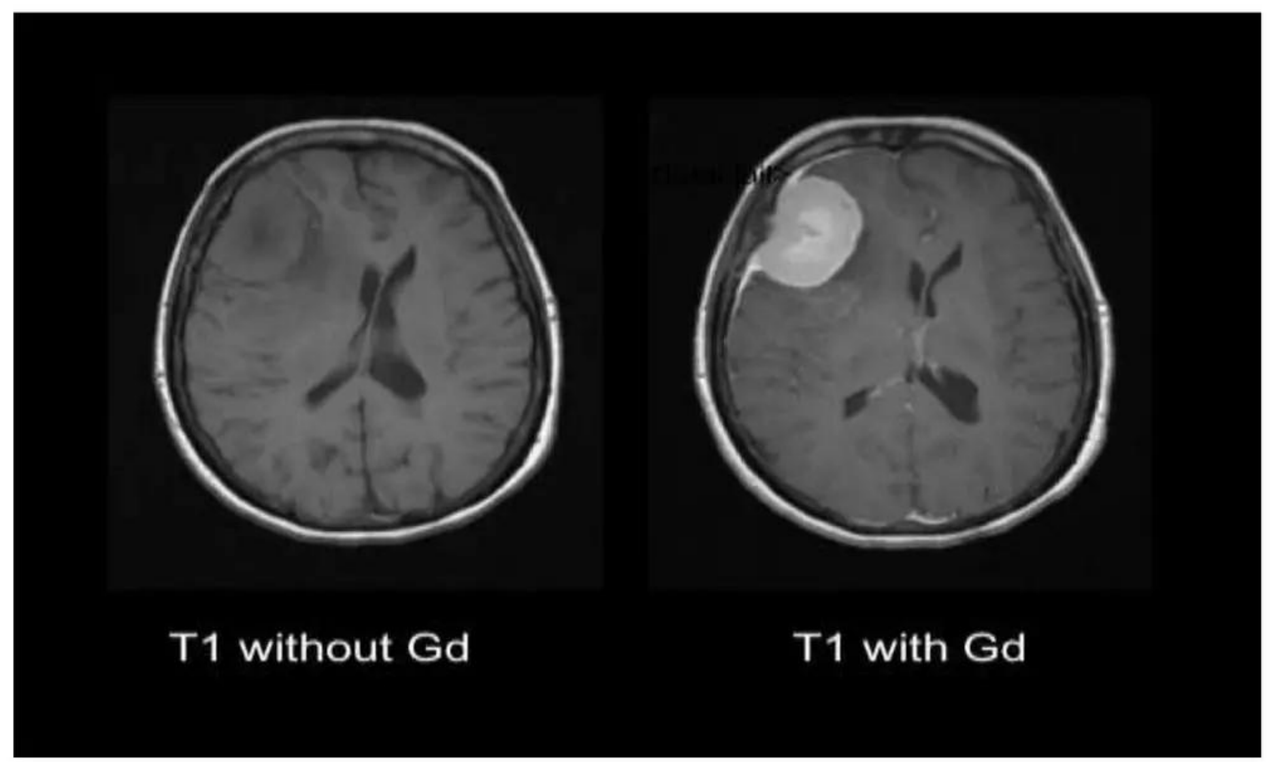

Falcine meningioma

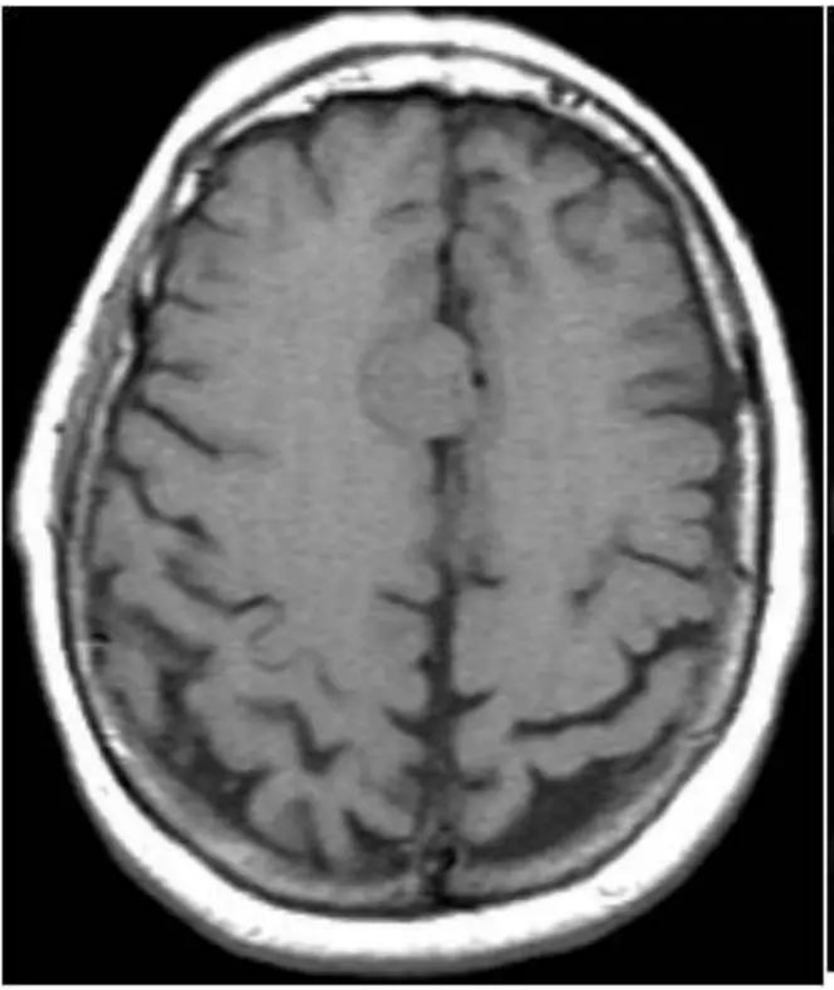

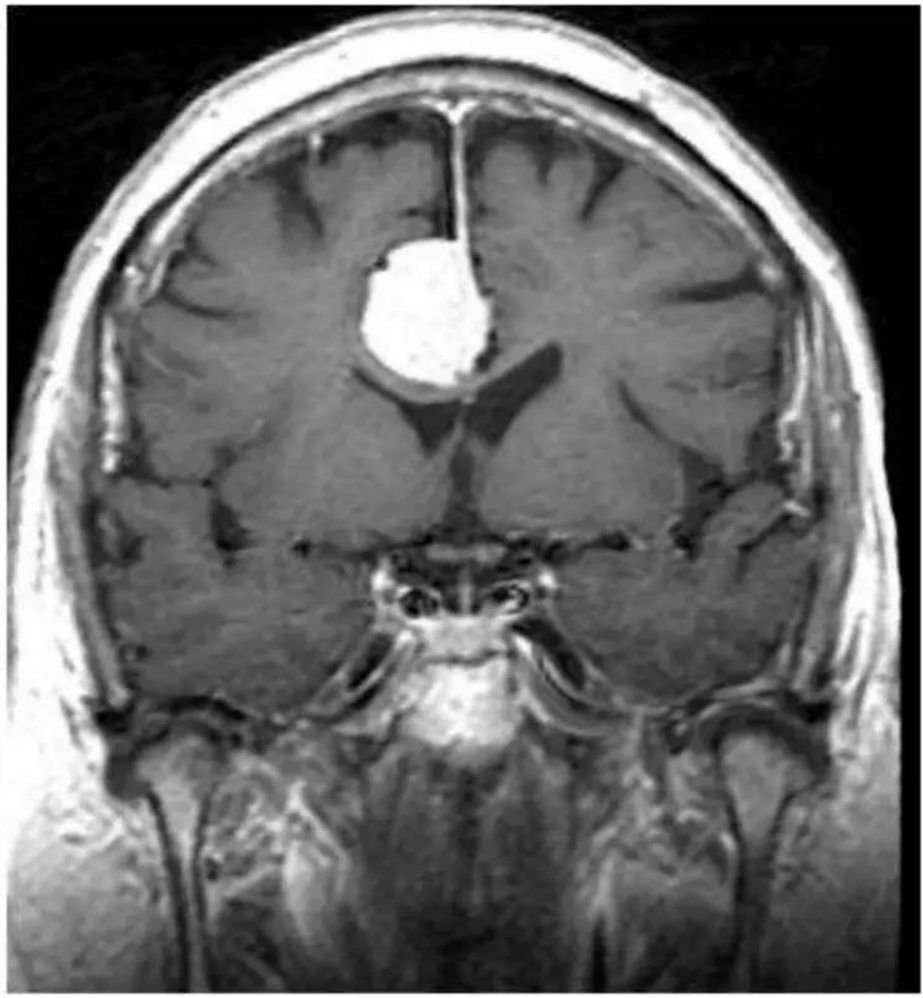

Astrocytomas
Diffuse low grade astrocytomas

- Epidemiology
  - 15% of astrocytomas

  -Young adults
- Location
  - Cerebral hemisphere
    - Supratentorial 2/3
    - Infratentorial 1/3
- Best diagnostic Clue : focal or diffuse non enhancingg white matter mass

CT images of Astrocytomas Low grade

- Well circumscribed, non enhancing hypodense or isodense lesion

MRI

- **T1W :**
  - Homogenous hypointense mass
  - May expand white matter and adjacent cortex
  - Appears circumscribed but infiltrates adjacent brain
- **T1C**
  - Usually no enhancement
  - Enhancement suggest progression to higher grade

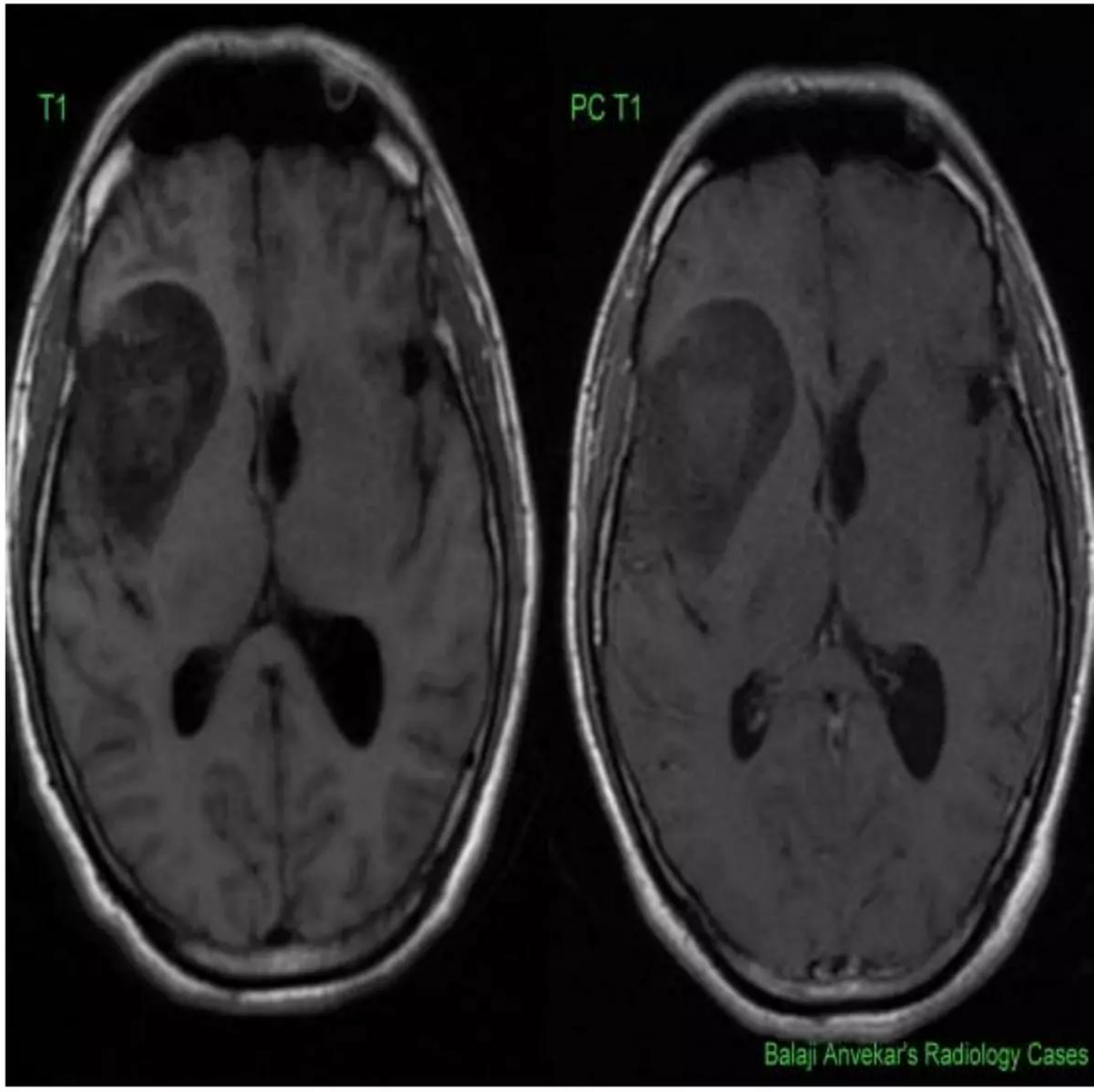

- **T2 W**
  - Well circumscribed area of increased signal intensity
- **FLAIR image**
  - Increased signal intensity
- **Perfusion MRI**
  - Decreased relative cerebral blood volume

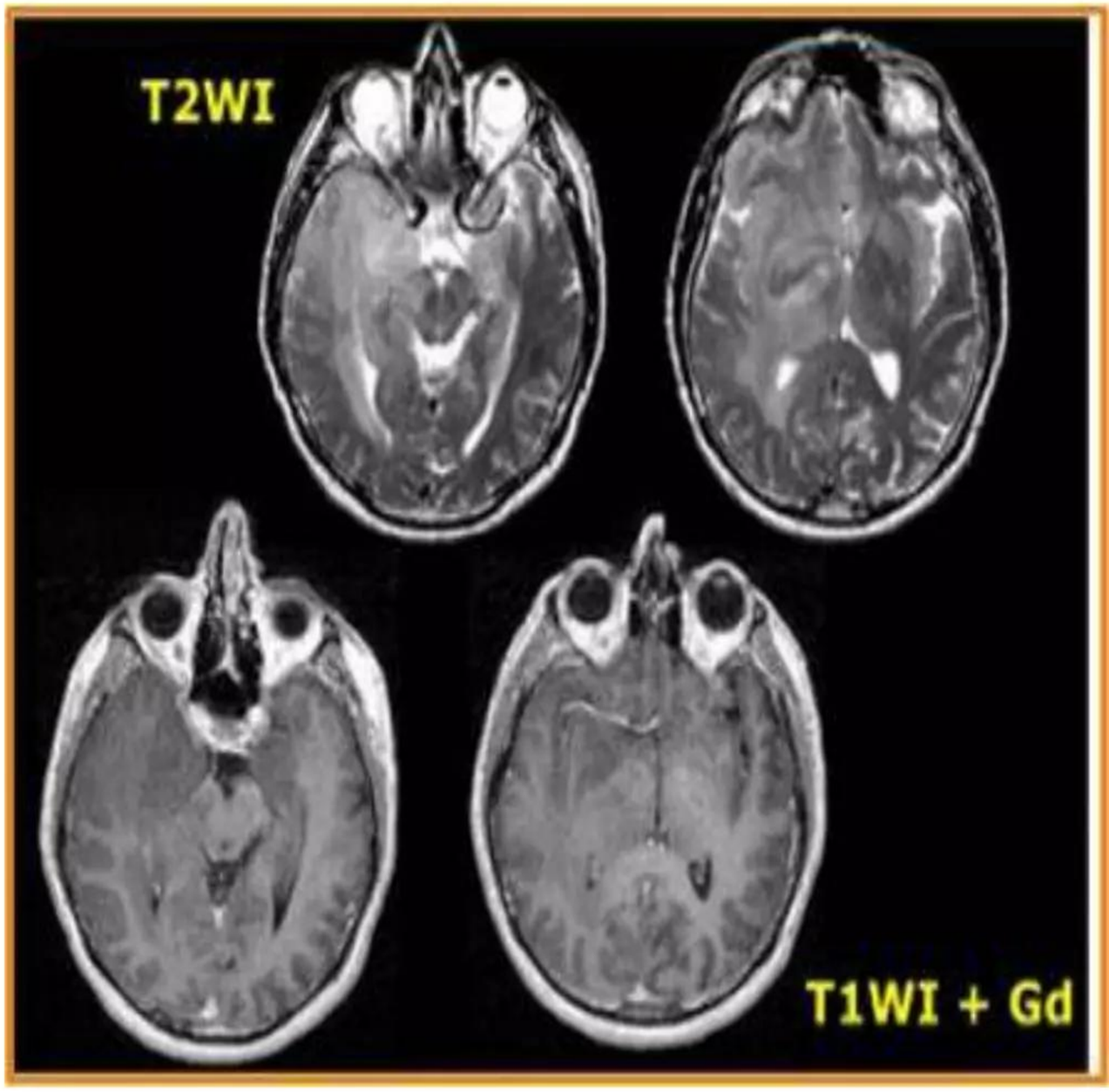

High grade Astrocytoma
Glioblastoma

- Most common of all intracranial neoplasm
- Location :
  - Supratentorial : most common frontal, temporal and parietal lobes
- Presentation :
  - headaches, mental changes and seizure
- Age
  - Peak : 45 to 70 yrs of age

Imaging

- CT
  - Irregular thick margings : iso to slightly hyperattenuating (high cellularity)
  - Irregular hypodense centre representing necrosis
  - Marked mass effect
  - Surrounding vasogenic oedema
  - Hemorrhage occasionally seen
  - Calcification is uncommon
  - **Intense irregular heterogenous enhancement of the margins is almost always present**

MRI

- **T1**
  - Hypo to isointense mass within white matter
  - Central heterogenous signal (necrosis, intratumoral haemorrhage)
- **T1 C (Gd)**
  - Enhancement is variable but is almost always present
  - Typically peripheral and irregular with nodular components
  - Usually surrounds necrosis
- **T2/FLAIR**
  - hypertense

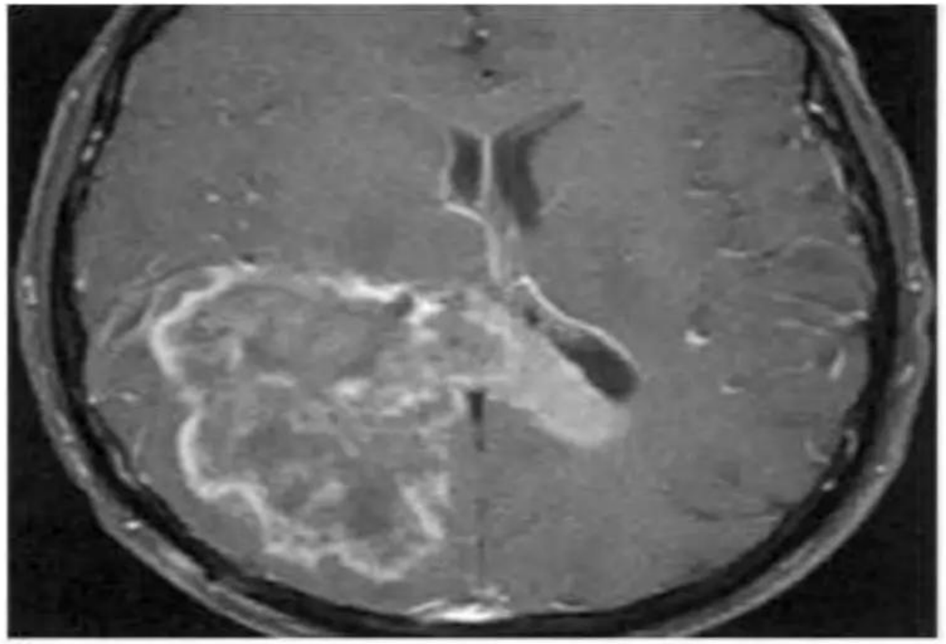

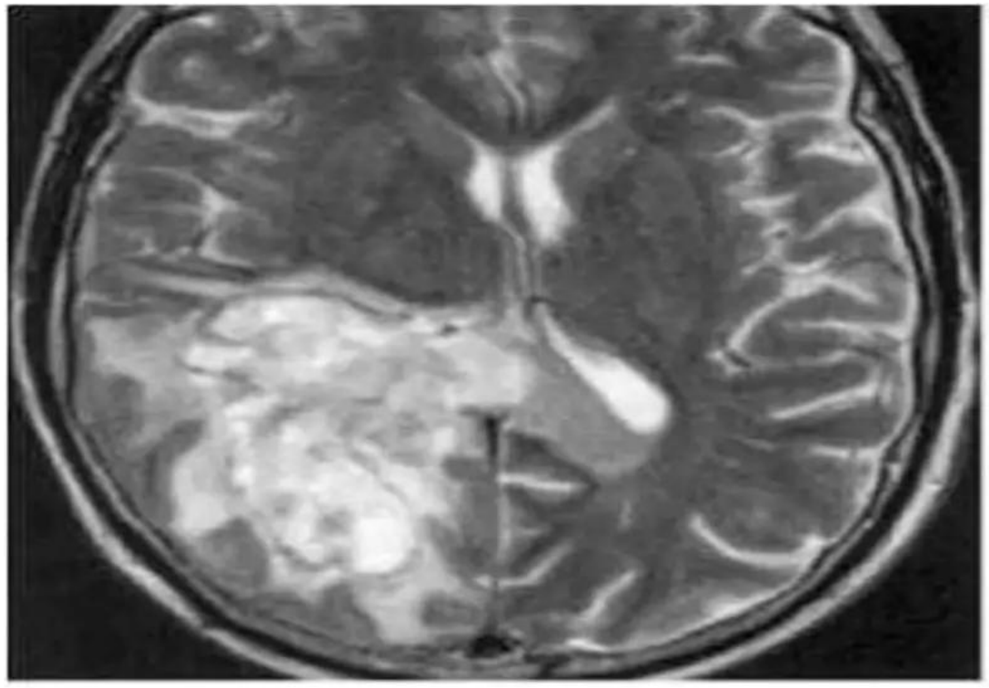

GBM crossing mideline and showing typical butterfly pattern

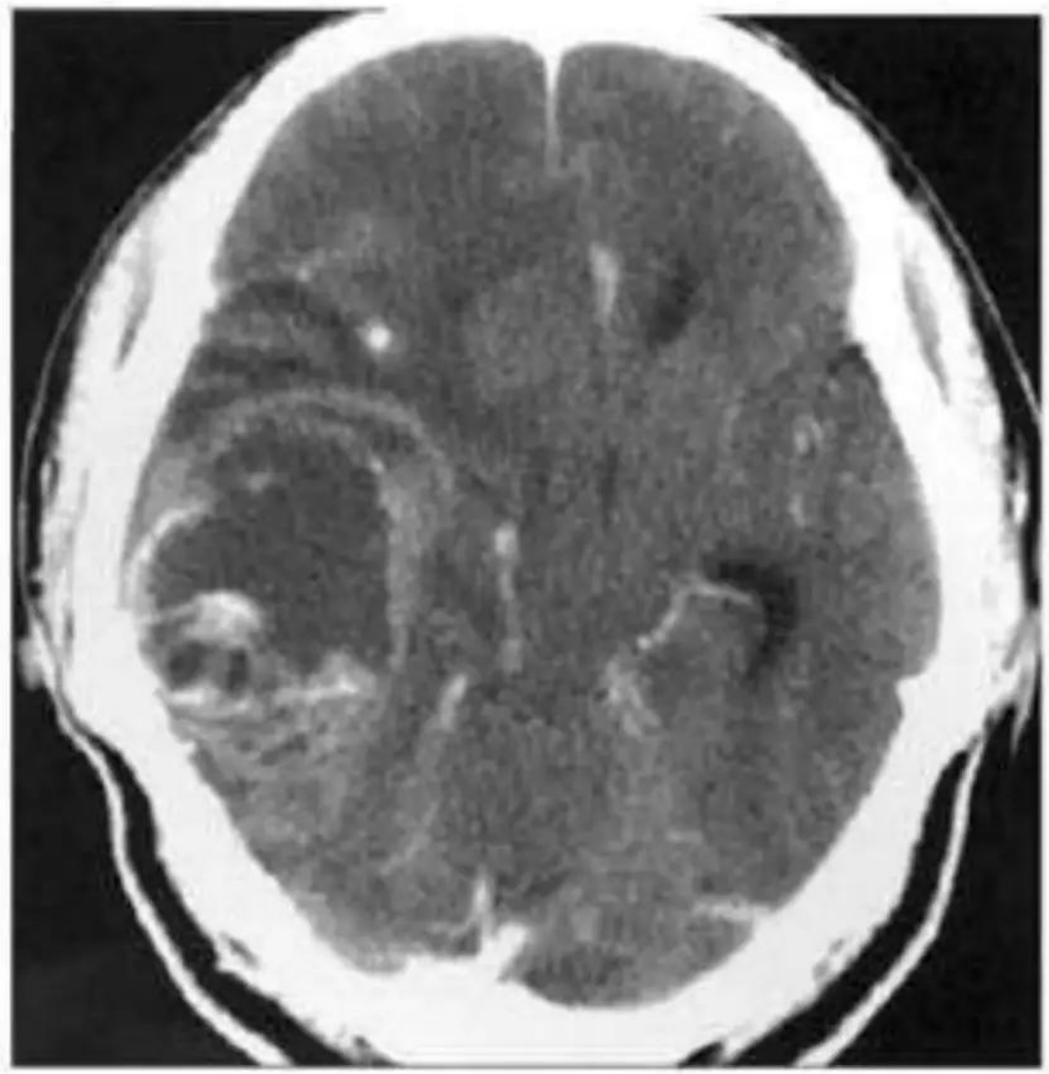

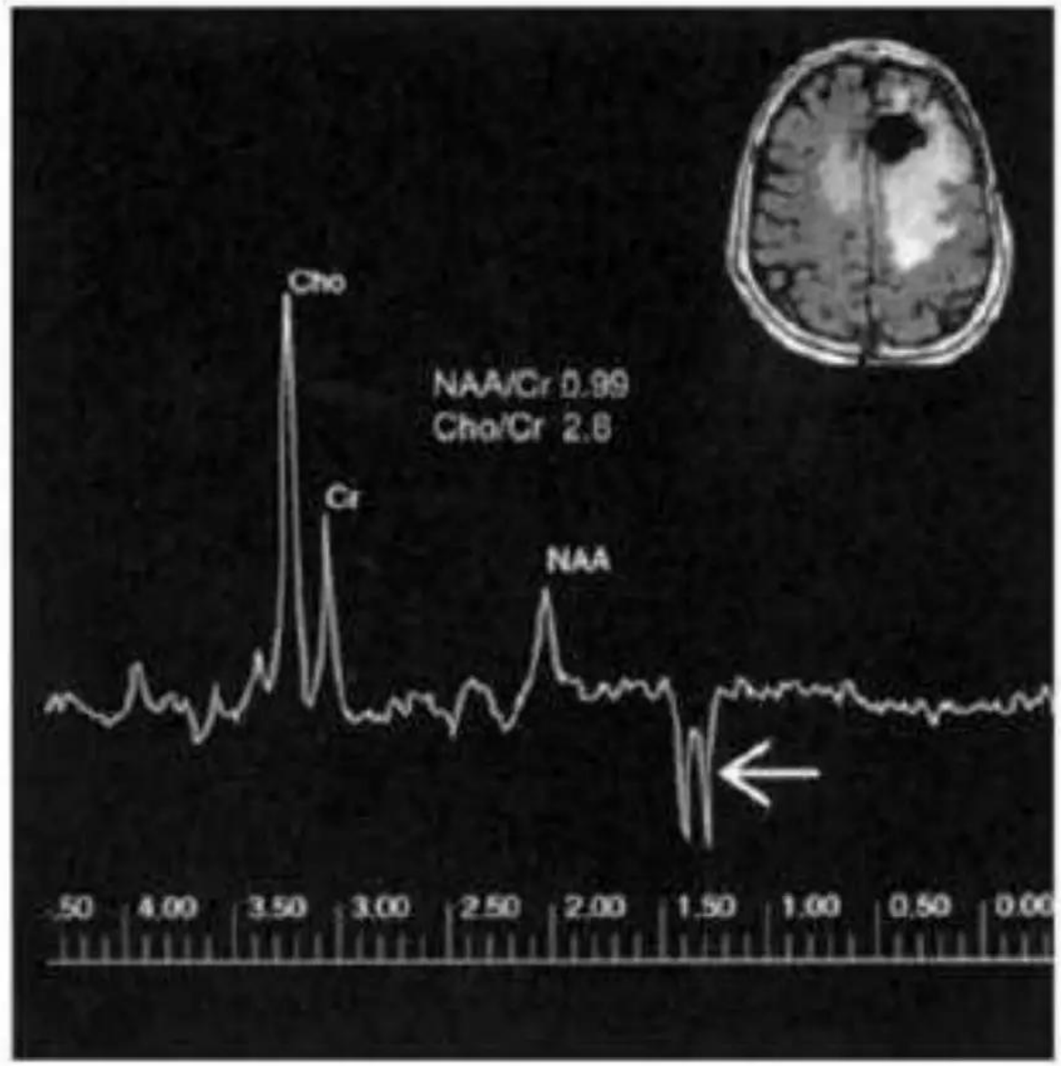
Cho
NAA/Cr 0.99
Cho/Cr 2.8
Cr
NAA
4.00
3.50
3.00
2.50
2.00
1.50
1.00
0.50
0.00

Implications of MRI sequences on contouring HGG

NCBI Resources How To

PMC US National Library of Medicine National Institutes of Health

PMC Advanced Journal list

Journal List > Onco Targets Ther > v.9; 2016 > PMC4892826

Dovepress OncoTargets and Therapy

Dove Medical Press | This Article | Suscribe | Submit a Manuscript | Search | Follow

Onco Targets Ther. 2016; 9: 3197–3204.
Published online 2016 May 27. doi: 10.2147/OTT.S104241

PMCID: PMC4892826

Delineation of radiation therapy target volumes for patients with postoperative glioblastoma: a review

Fen Zhao,[1,2,*] Minghuan Li,[1,2,*] Li Kong,[1,2] Guoli Zhang,[1,2] and Jinming Yu[1,2]

Author information ► Copyright and License information ►

treatment planning tends to include the contrast-enhancing tumor on CT/T1-weighted MRI plus a 2 cm margin, or the FLAIR/T2-weighted abnormality on the postoperative MRI scan plus a 1 cm margin.

Oligodendroglioma

- **CT**
  - Well circumscribed, hypodense lesions with **heavy calcification**
  - Cystic degeneration is common but hemorrhage and oedema are uncommon

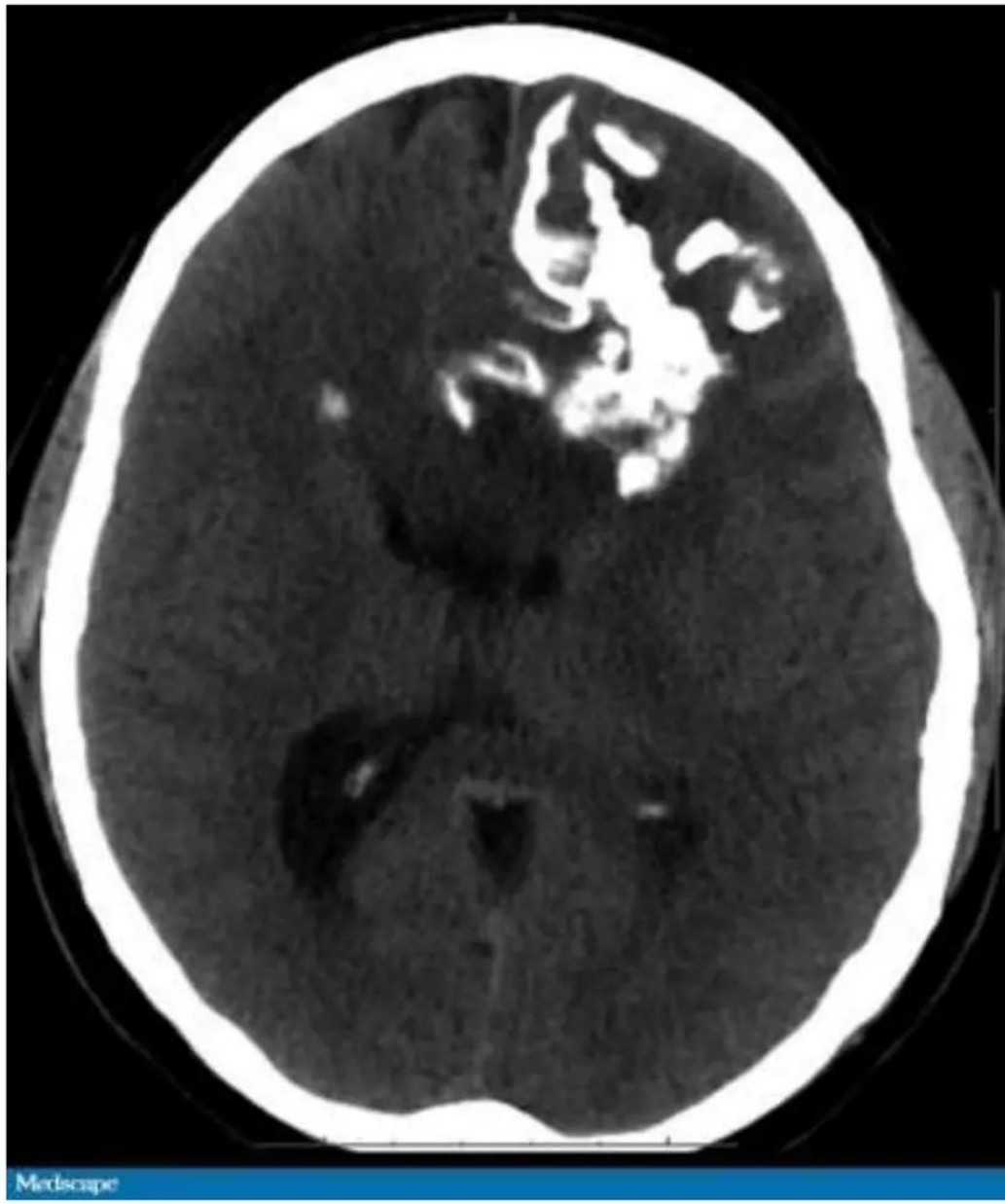

- **MRI**
  - Hypotense or isotense on T1 W images
  - Hypertense on T2W images with variable enhancement
- **T1 C+ (Gd):**
  - contrast enhancement is common but it is not a reliable indicator of tumour grade

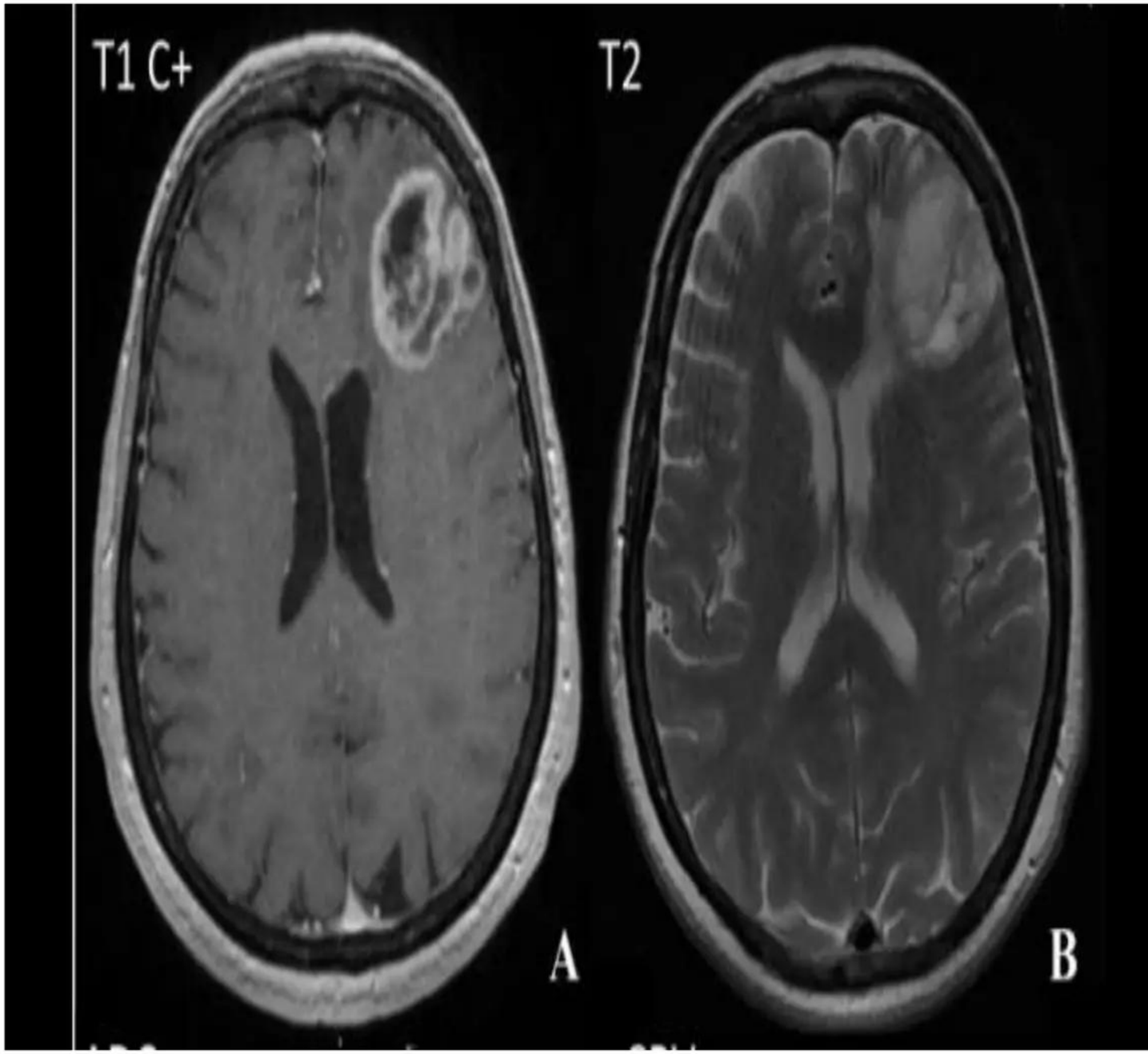

Pleomorphic xanthoastrocytoma

- Benign supratentorial astrocytoma
- Found exclusively in young adults
- Presentation
  - Epilepsy long standing, temporal lobe involvement : partial complex seizures
  - Others : headache and focal neurologic deficits
- Age
  - Children/young adults
  - 2/3 <18 yrs
- Location :
  - Peripherally located, usually involves cortex and meninges
  - 98% supratentorial, temporal lobe is most common

imaging

- Best diagnostic clue : supratentorial cortical mass with adjacent enhancing dural “tail”
- **CT findings**
  - Cystic/solid mass: hypodense with mixed density nodule
  - Solid mass : variable, hypodense, hyperdense or mixed, minimal or no oedema

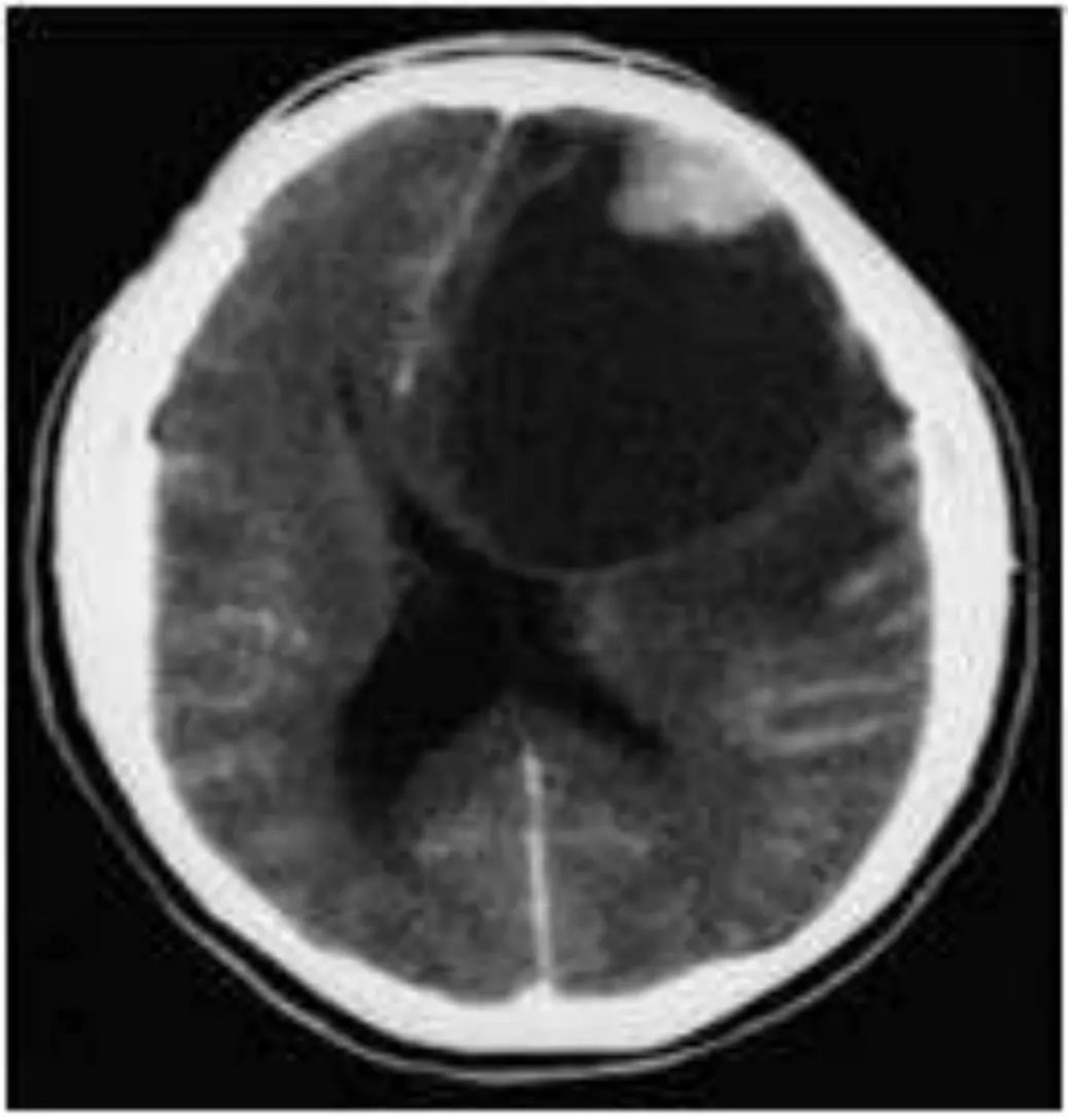

MRI findings

- **T1W :**
  - Mass is hypointense or isointense to grey matter
- **T2W :**
  - Hyperintense or mixed signal intensity mass

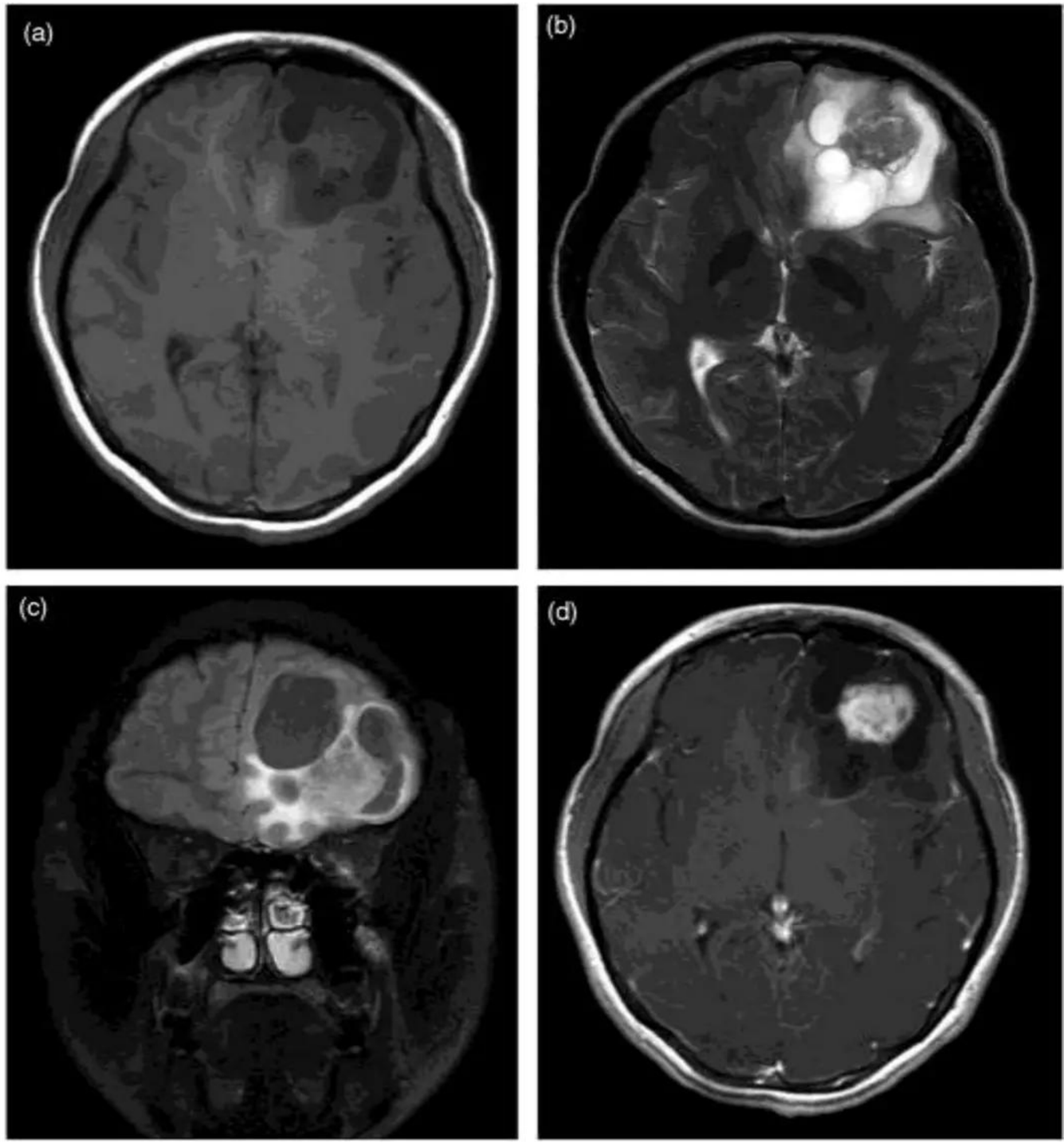

Ganglioglioma

- Well diffrentiated slowly growing neuroepithelial tumour composed of neoplastic ganglion cells and neoplastic glial cells
- Most common cause of temporal lobe epilepsy
- Presentation
  - Chronic temporal lobe epilepsy
  - Partial complex seizure
- Age
  - 80% of patients < 30 yrs
- Location

  Most common – superficial hemisphere temporal lobe

Imaging

- **Best diagnostic clue** :
  - partially cystic, enhancing cortically based mass in child/yound adult with TLE
- **CT findings**
  - 40% hypodense, 30% mixed hypodense, isodense 15% isodense or hyperdense
  - Ca++ common, 35-50%
  - Approximately 50% enhance

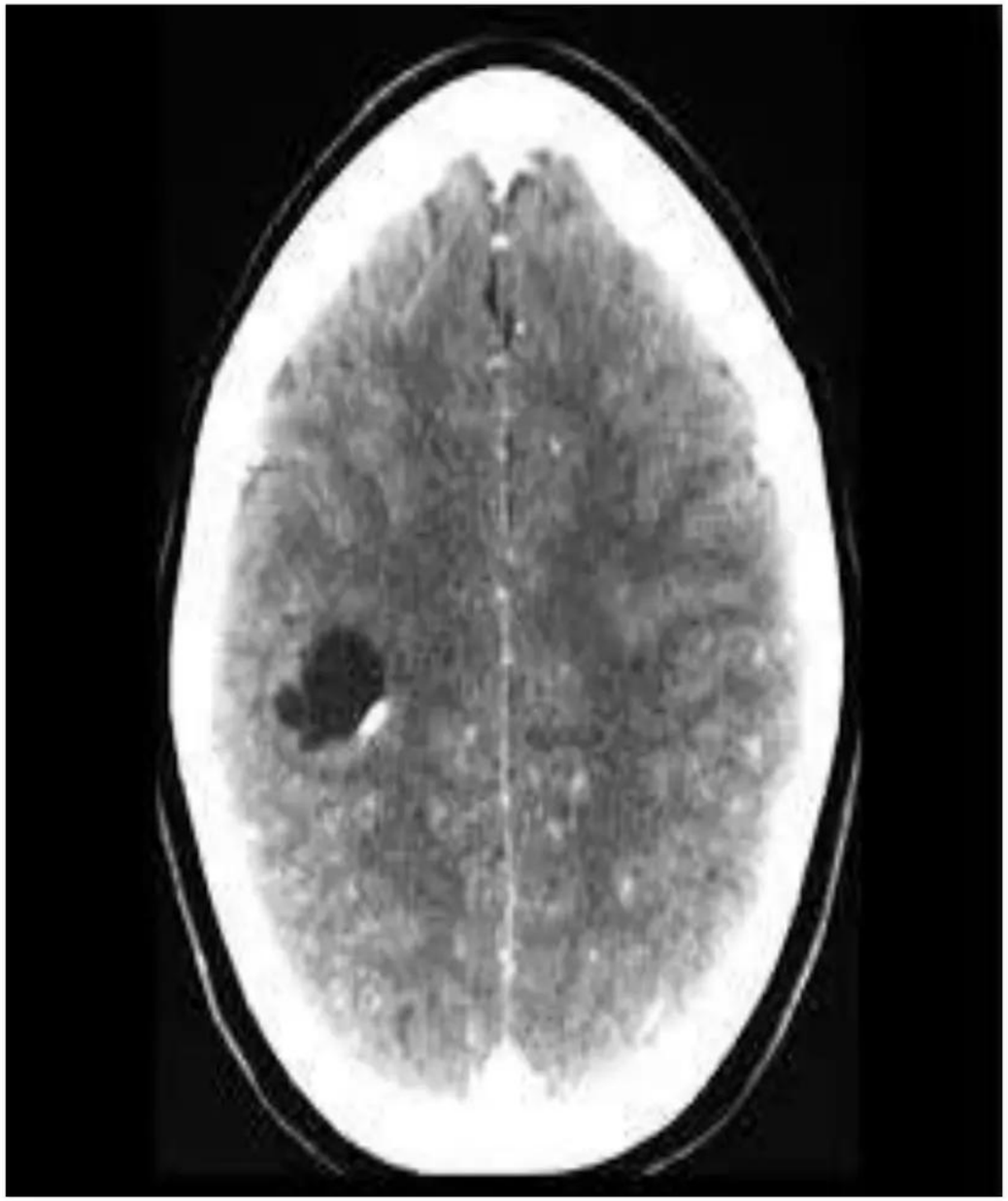

MRI findings

- **T1W**
  - Hypo to isointense to gray matter
- **T2W**
  - Hyperintense, heterogenous
- **T1C :**
  - Variable enhancement, usually moderate

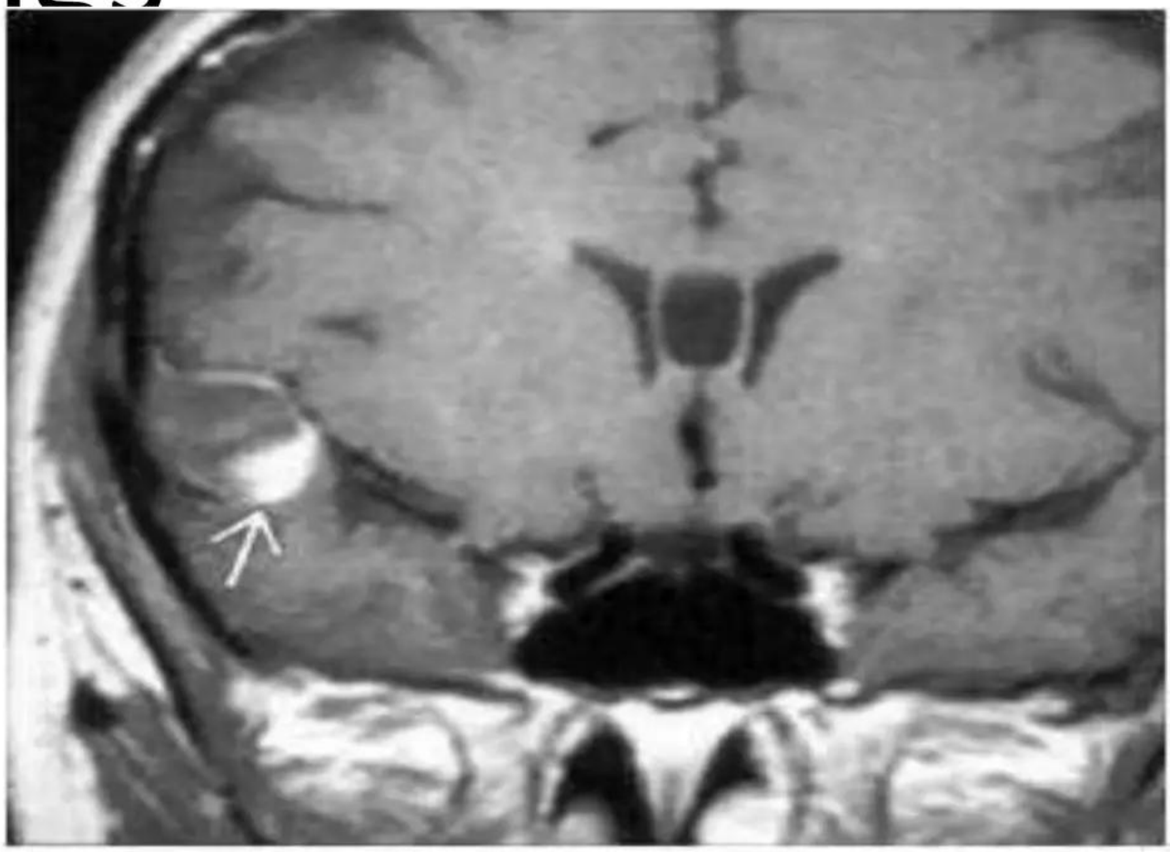

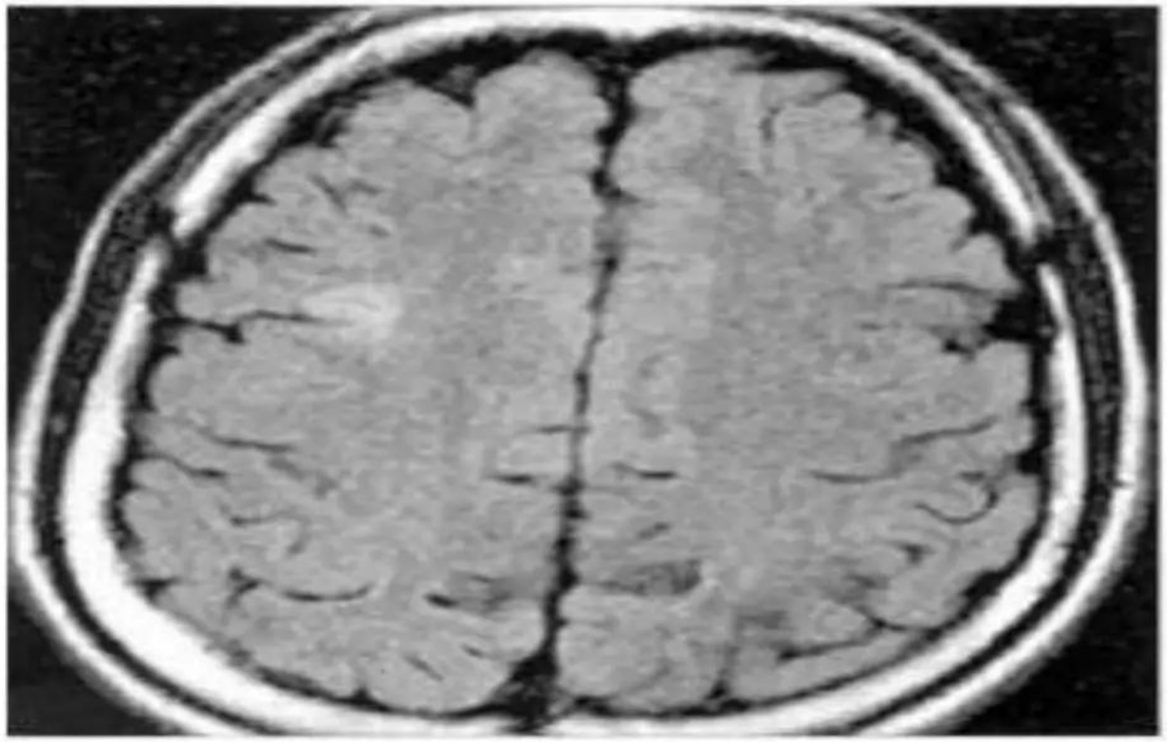

Cortical based tumours
Dysembryoplastic neuroepithelial tumour

- Best diagnostic clue
  - Well demarcated, wedge shaped “bubbly” intracortical mass in young patient with long standing partial seizures
- Location
  - Temporal lobe (amygdala/hypocampus) most common site
- Size
  - Variable

CT findings

- **NCCT**
  - Wedge shaped low density area
    - cortical/subcortical lesion
  - Extends towards ventricle
  - Calcification in 20 to 40%
- **CECT**
  - Non enhancing
  - Faint nodular or patchy enhancement in 20%

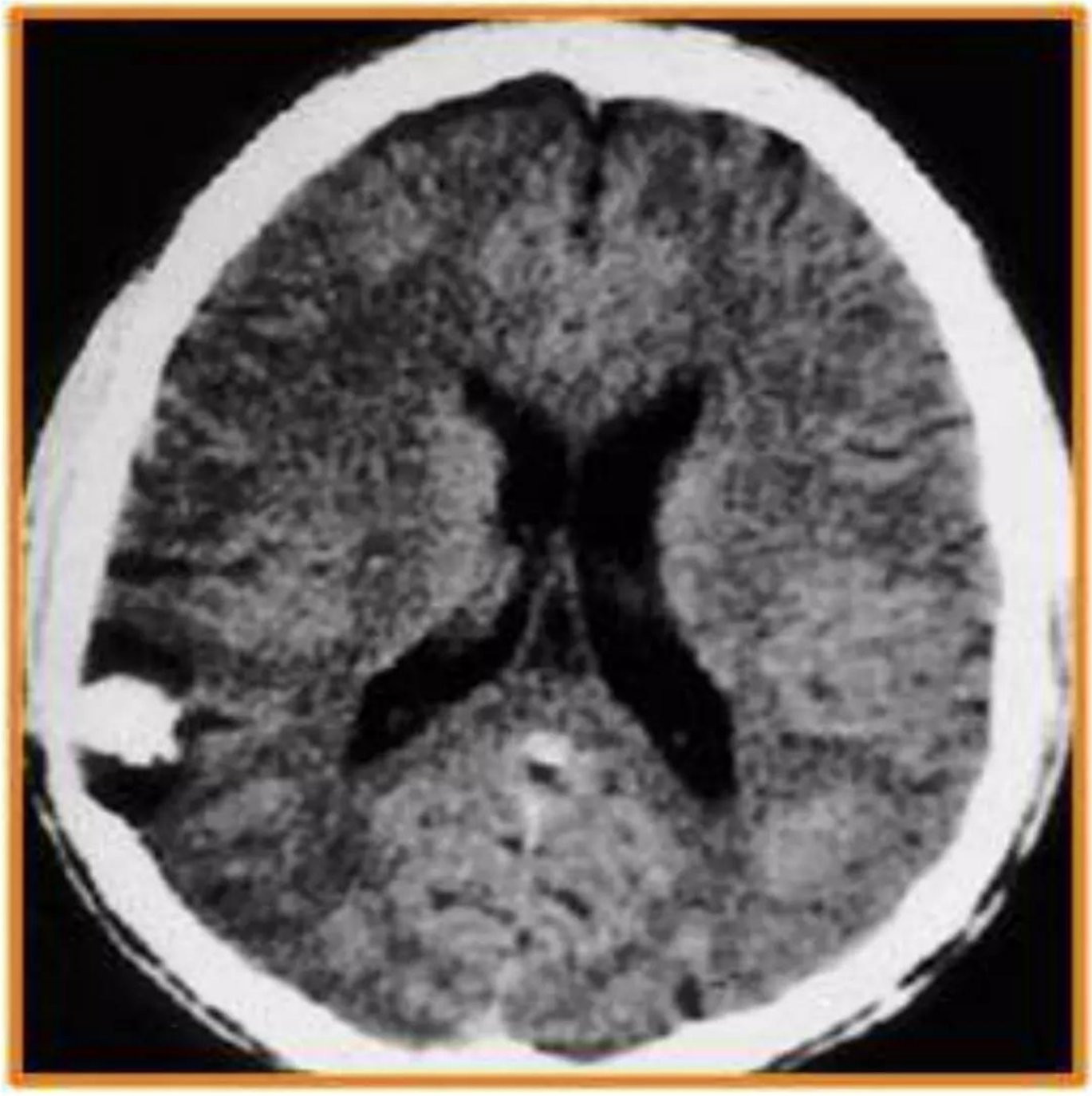

MRI findings

- **T1W**
  - Pseudocystic, multinodular “bubbly” mass
  - Hypointense on T1
- **T2W**
  - Very hyperintense on T2
  - Multinodular or septated appearance

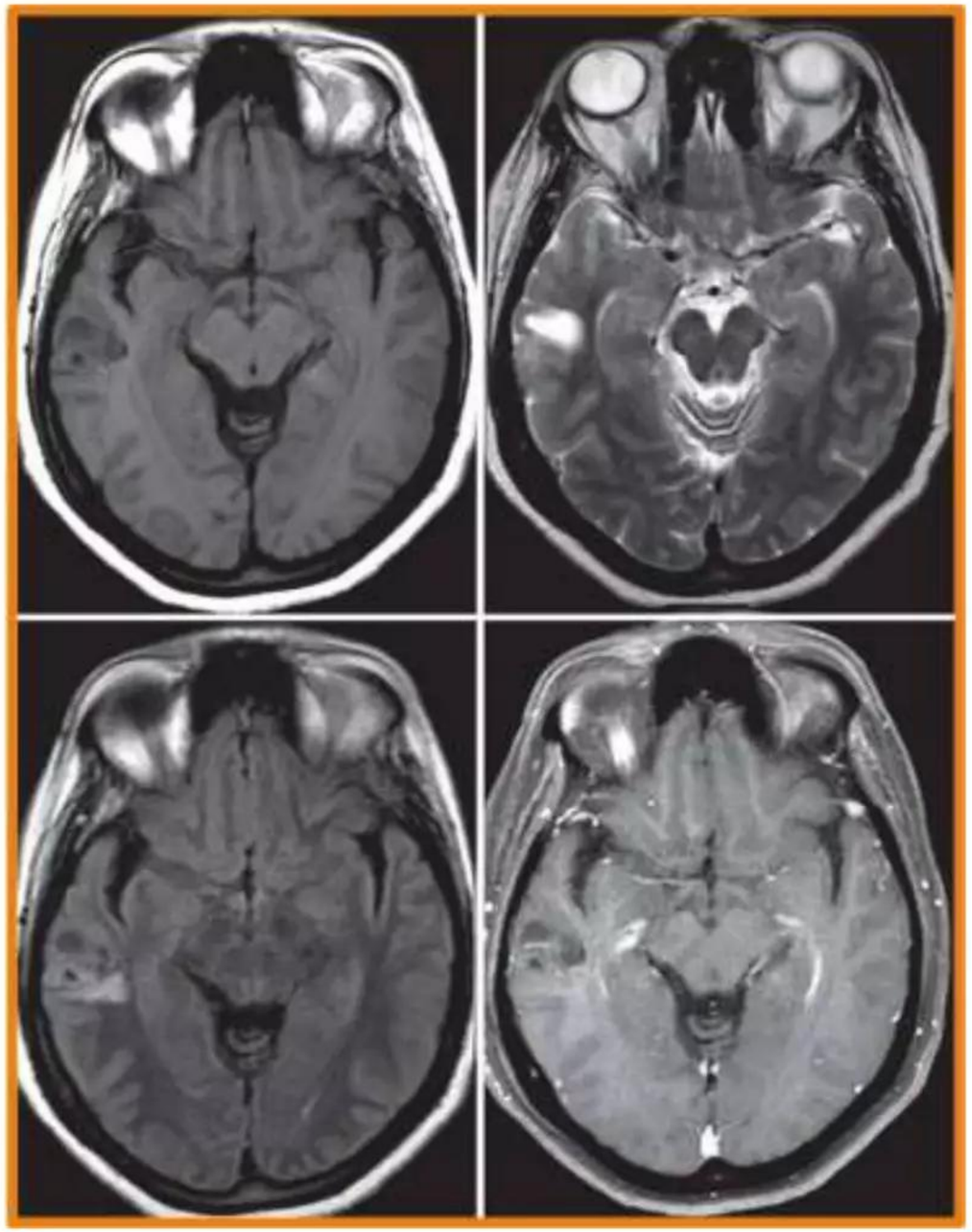

Hypothalamic Glioma

- General characteristic
  - Solid, cystic or combination
  - Globular/exophytic suprasellar mass
- **CT**
  - Low density to isodense
  - Intense enhancement with contrast

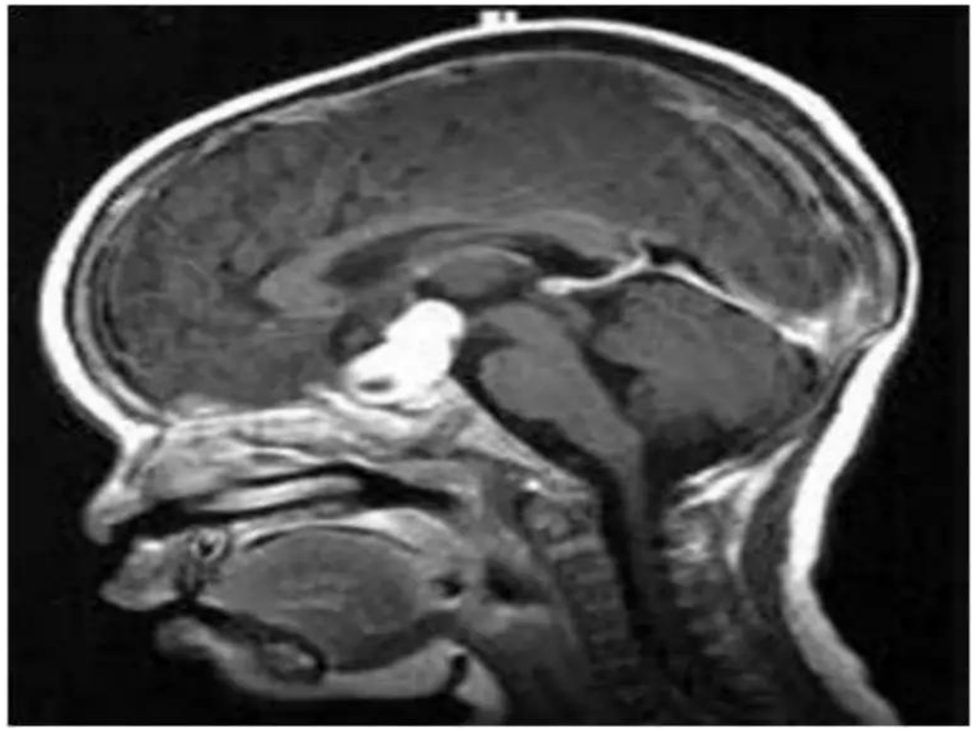

MRI findings

- **T1 W :**
  - Low intensity with marked gadolinium enhancement
- **T2 W**
  - Hypeintense mass
  - Grow posterosuperiorly with invagination of the 3rd ventricle

Tumours of Specific Anatomic Sites

- **Sella/Suprasellar**
  - Optic/hypothalamic glioma
  - Craniopharyngioma
  - Pituitary tumors
- **Pineal region**
  - Pinealoblastoma
  - Germinoma
- **Intraventricular**
  - Ependymoma
  - Choroid plexus papillma

Craniopharyngiomas

- X-ray lateral view in pt with craniopharyngioma showing suprasellar calcification

CT finding :

- Best diagnostic clue
  - partially calcified, partially solid cystic suprasellar mass in a child

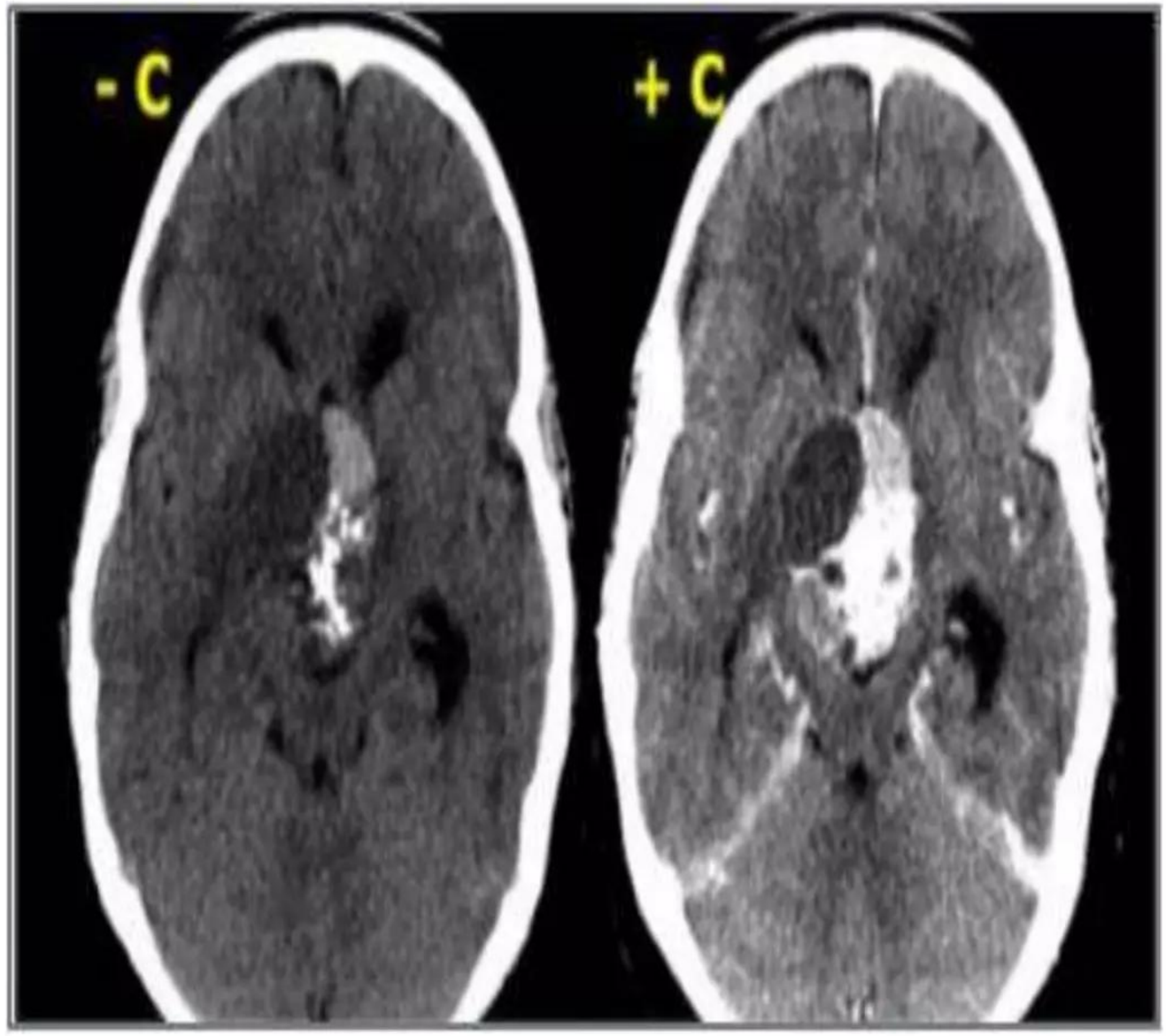

- MRI finding : high signal intensity suprasellar mass on pre contrast T1W
- Axial MRI T1 image showing cystic craniopharyngioma

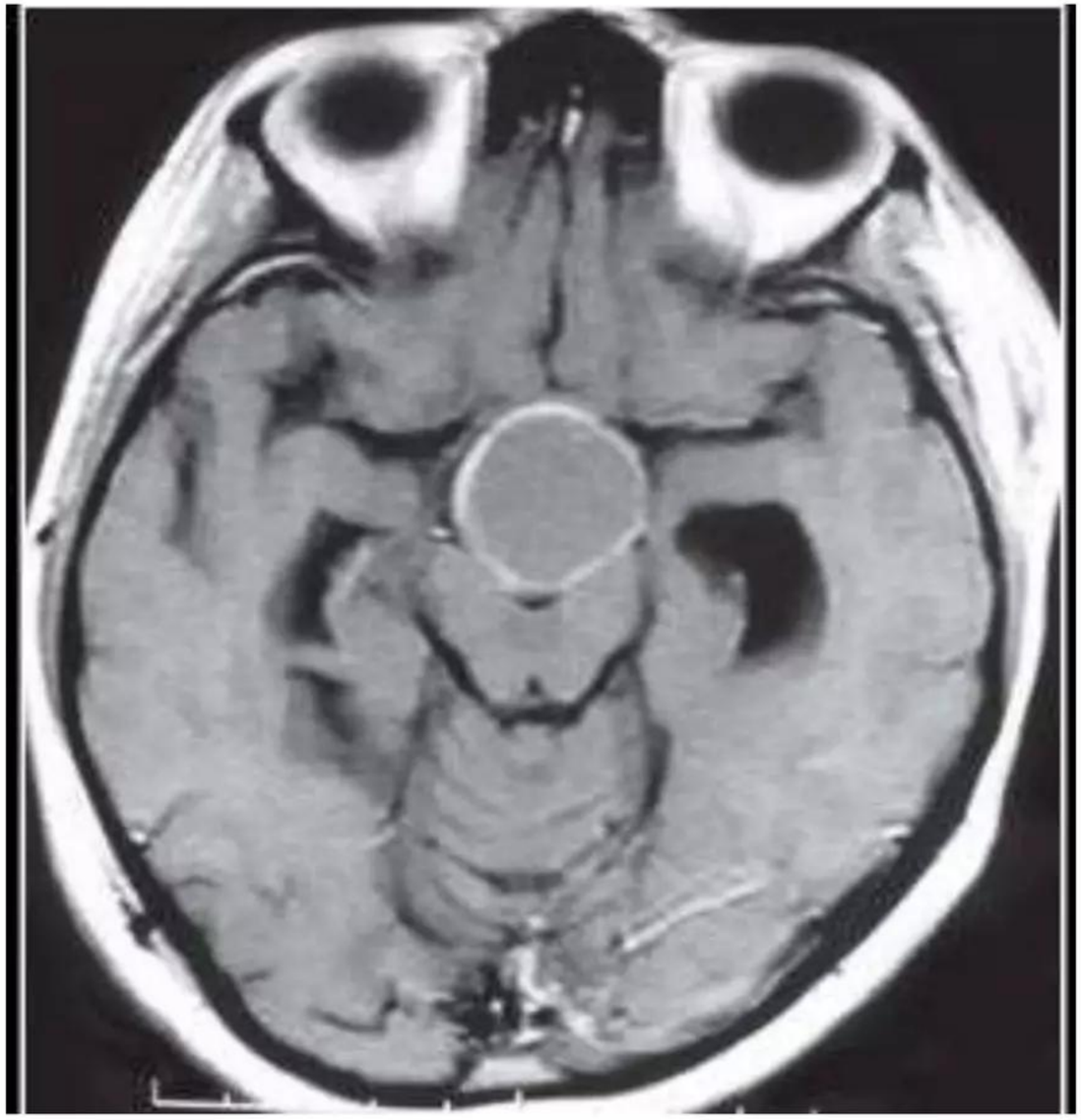

Pituitary Adenomas

- Imaging
  - Mass arising from pituitary gland and usually extending superiorly: indentation at the diaphragm sellae can give a snowman or **figure 8** configuration
- Plain x ray
  - Enlarged sella turcica

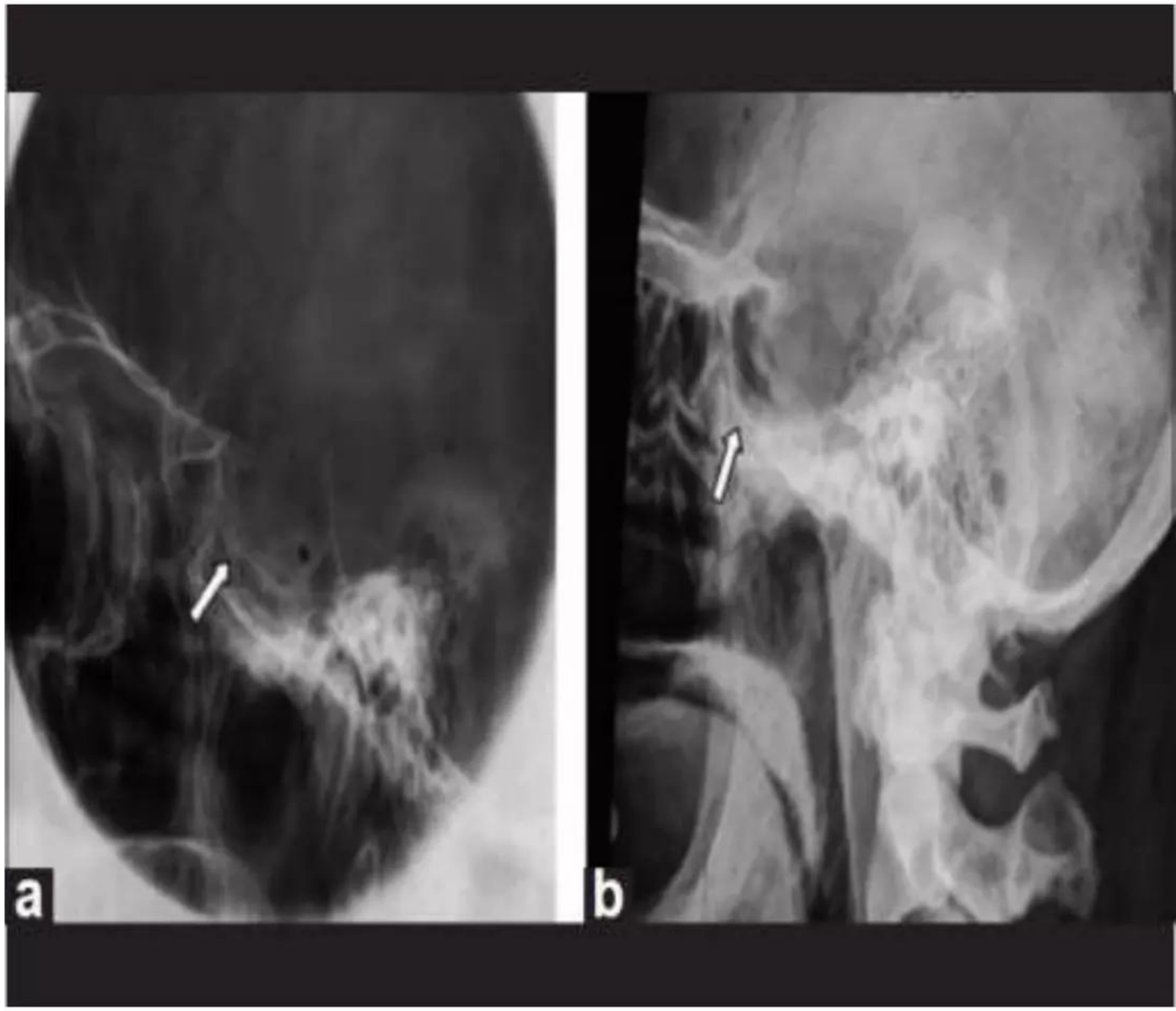

a.Pituitary adenoma showing double flooring of the sella

CT findings

- Contrast attenuation depends on hemorrhagic, cystic and necrotic components
- Solid adenomas without h'ge attenuation similar to brain and demonstrates moderate contrast enhancement

MRI findings

- Preferred imaging modality
- Delineate the mass and clearly visualize the optic chaism, anterior cerebral vessels and cavernous sinuses
- **T1W**
  - Typically isotense to gray matter
- **T1 C**
  - Solid components demonstrates moderate to bright enhancement

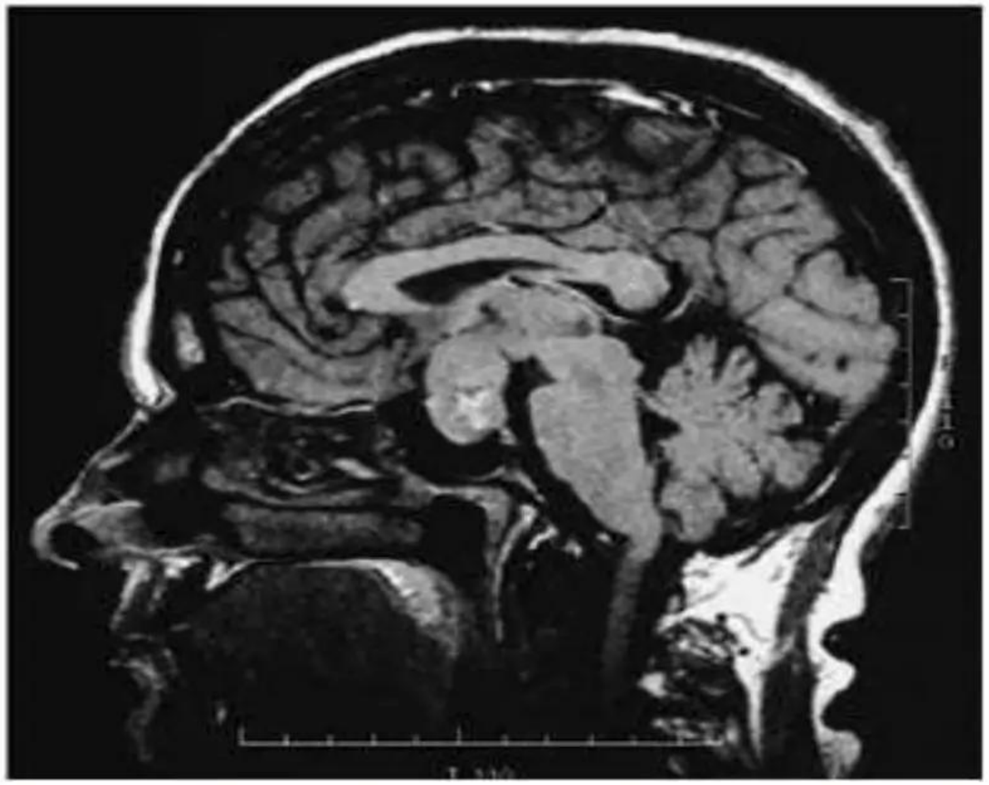

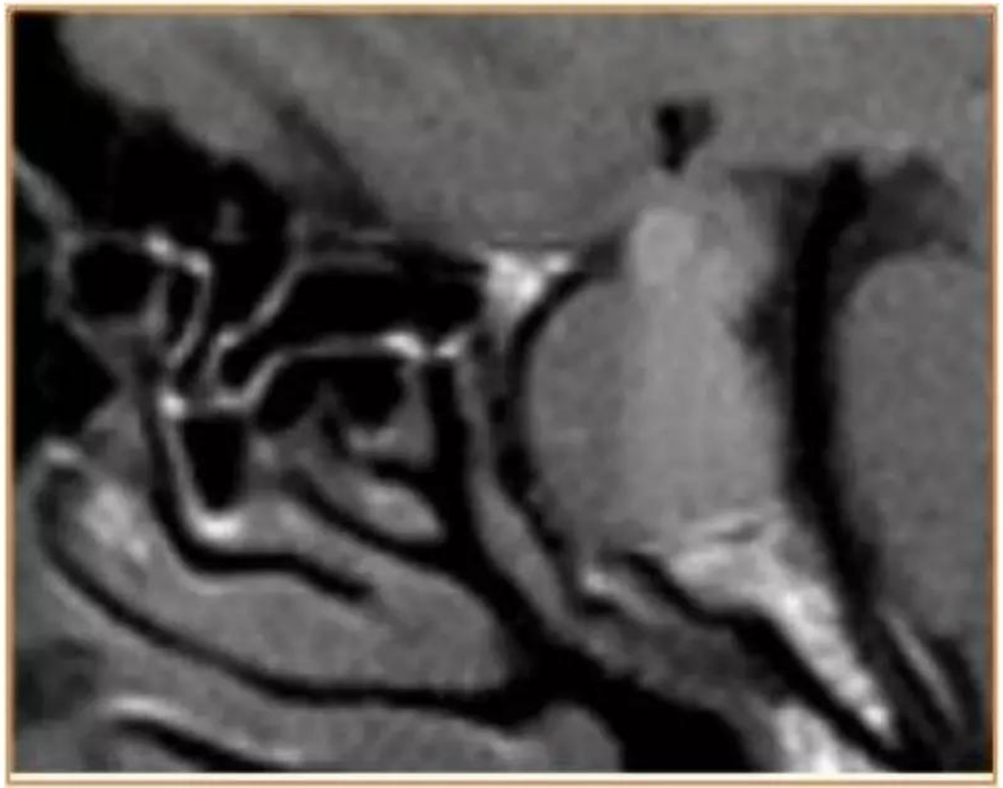

- T2
  - Typically isointense to gray matter
  - Larger lesions are often heterogenous d/t cystic changes/necrosis/h'ge

Pineal Region Tumors

- Classification of pineal tumours
- Tumors of Pineal parenchymal cells (25%)
  - Pineoblastomas
  - Pineocytomas
- Germ Cell tumours
  - Germinomas (75%)
  - Embroyonal carcinoma
- Glial cell Origin tumours
  - Astrocytomas
  - glioblastomas

An approach to Pineal Region

- Normal appearance
  - Pineal gland is a small (7mm) structure located at the posterior most aspect of third ventricle
  - No calcification before the age of 5 yrs
  - Any calcification >1cm or any calcification before 4 years of age is considered pathological

Germinoma

- Germ cell tulors
- Cause Parinaud's syndrome : fixed upward gaze
- Presentation
  - Obstructive hydrocephalus d/t aqueductal stenosis

Imaging

- CT
  - Isodense or hyperdense
  - Enhances with contrast
- MRI
  - Isointense to hypointense on T1WI
  - Enhances with gadolinium
  - Hyperintense on T2 images

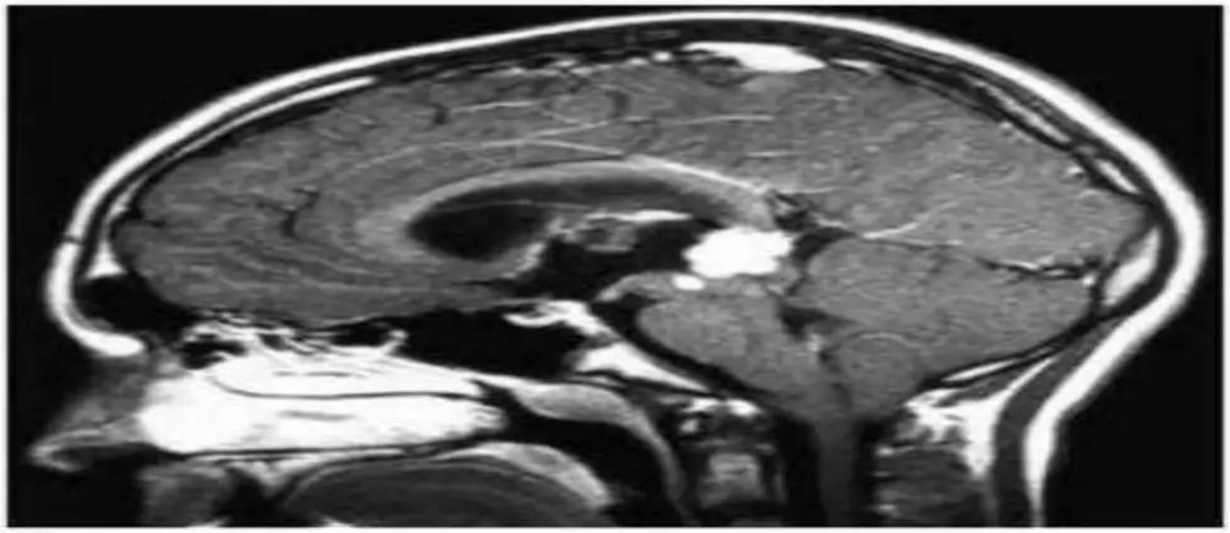

A

B

Intraventricular tumours

- Ependymoma
- Subependymoma
- Choroid plexus papilloma

Ependymoma

- **Best diagnostic clue** : heterogenous signal, soft tumour, squeezes out through 4th ventricle foramina into cisterns
- **CT findings**
  - Infratentorial
    - 4th ventricle tumour extends into CPA/cisterna magna, calcification is common
  - Supratentorial :
    - Large heterogenous periventricular mass
    - Calcification common
    - Variable heterogenous enhancement

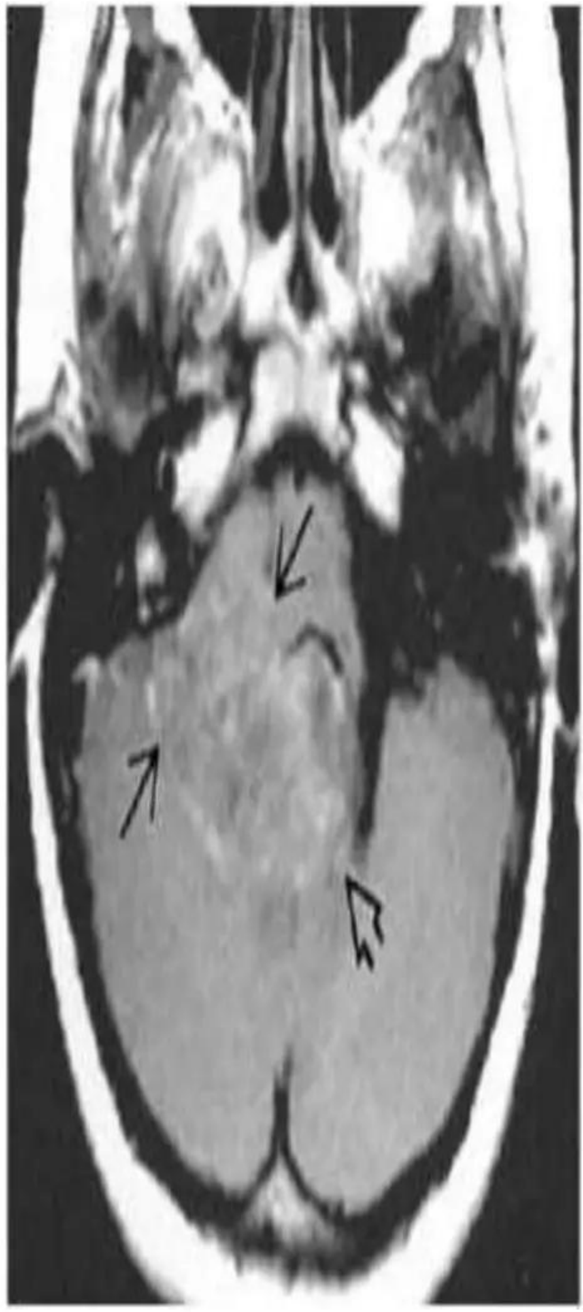

MRI

- **T1**
  - solid portions of ependymoma typically are isointense to hypointense relative to white matter
- **T1 C+ (Gd)**
  - enhancement present but heterogeneous
  - enhancement with gadolinium is useful in differentiating tumour from adjacent vasogenic oedema and normal brain parenchyma

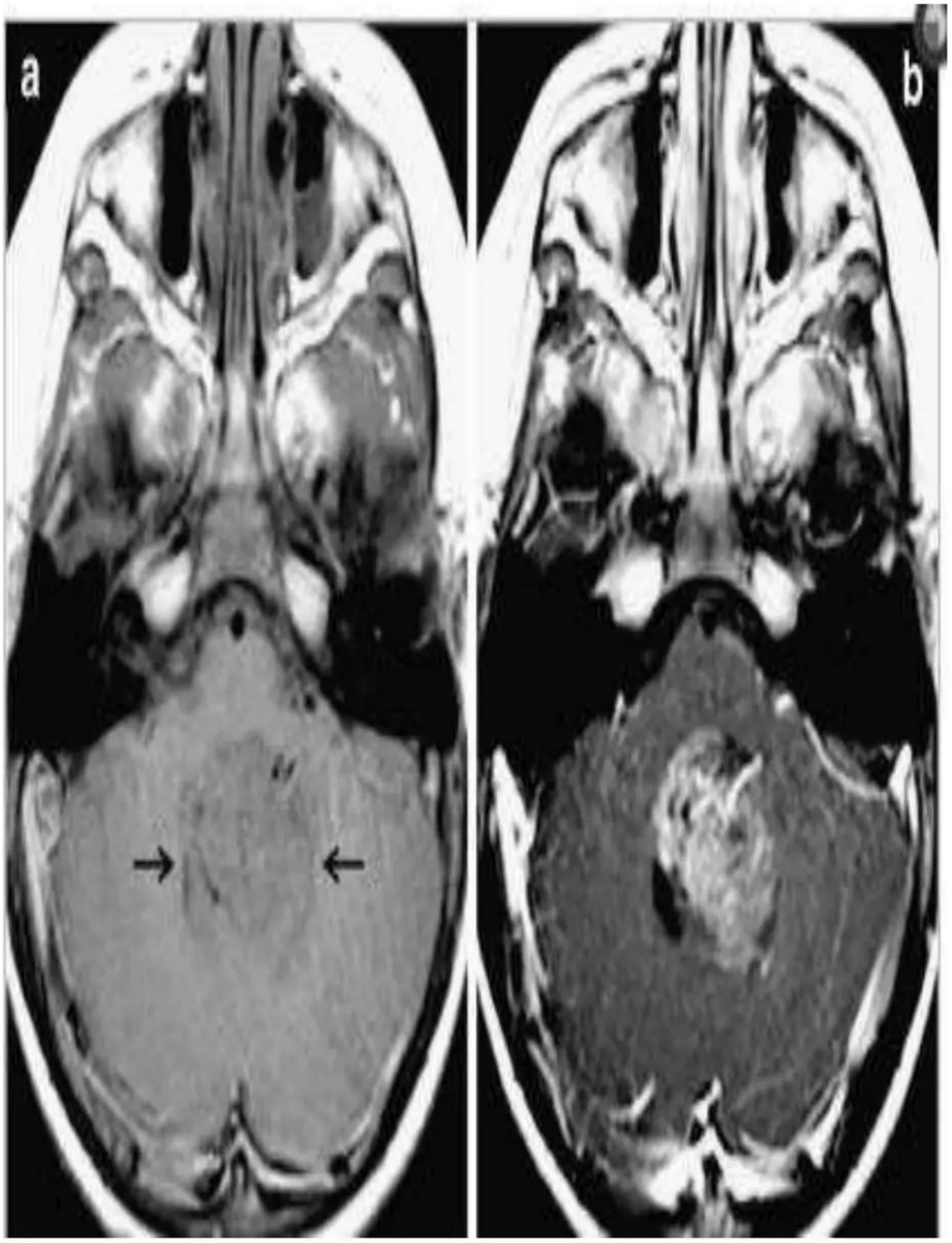

- **T2**
  - hyperintense to white matter
  - more reliable in differentiating tumour margins than non-contrast T1-weighted images (but less reliable than contrast enhanced T1)

Choroid plexus papillomas

- Best diagnostic clue : child with strongly enhancing lobulated intraventricular mass
- Imaging
  - Increased cranial to facial ratio
  - Sutural diastasis d/t hydrocephalus
- CT findings
  - Intraventricular bosselated mass
  - Intense, homogenous enhancement
  - Heterogenous enhancement suggests Choroid plexus carcinoma

MRI findings

- T1W :
  - Well delineated, lobulated mass
  - Iso to hypointense
- T2W :
  - Iso to hyperintense
- T1C :
  - Homogenous enhancement

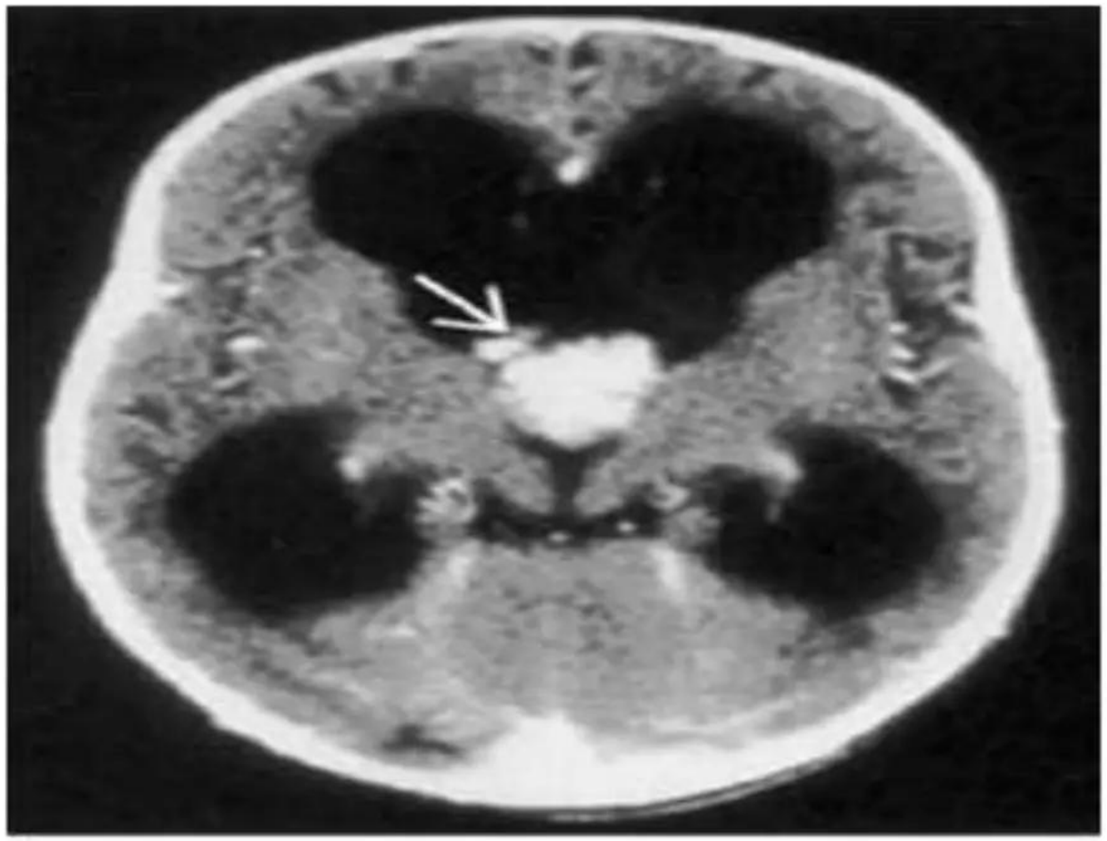

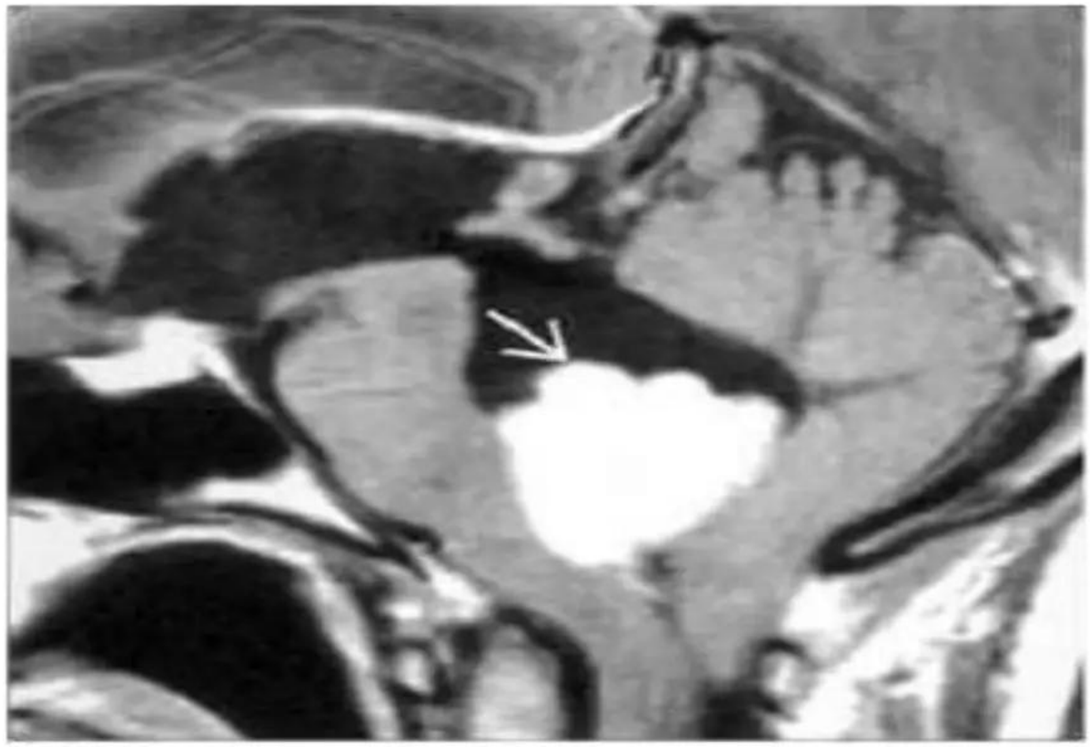

Intra Axial -Posterior Fossa Tumors

- medulloblastoma
- Pilocytic astrocytoma
- Hemangioblastoma
- Brain stem Glioma

Medulloblastoma

- **CT**
  - Mass arising from the vermis
  - Usually hyperdense 90%
  - Cyst formation/necrosis is common 50%
  - Enhancement is present in over 90% cases

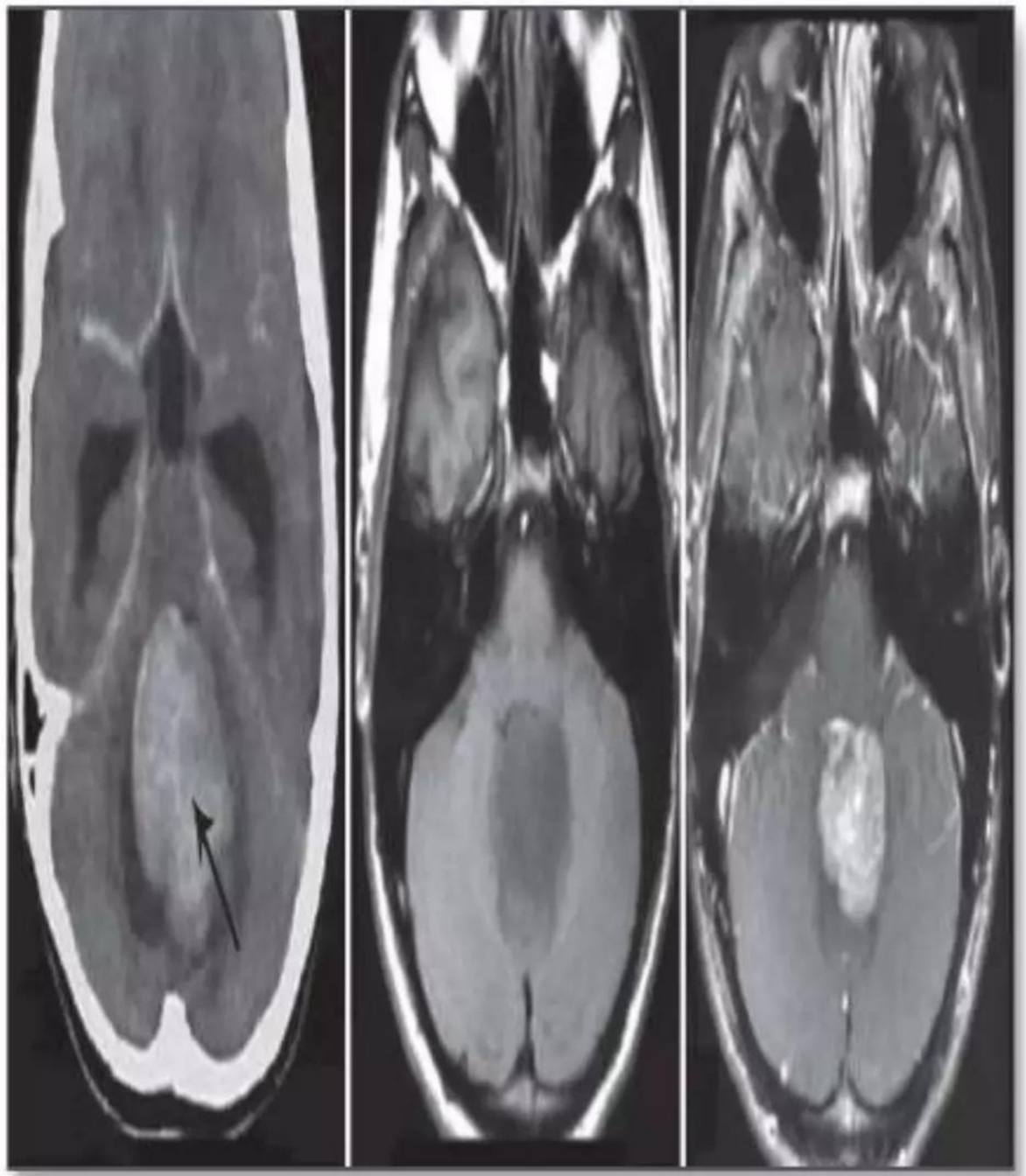

MRI findings

- **T1 :**
  - Hypointense to GM
- **T1C**
  - Overall 90% enhance, often heterogenously
- **T2/FLAIR**
  - Iso to hyperintense to GM
  - Heterogenous due to calcification, necrosis and cyst formation

Fig 5. Sagittal T1 weighted MRI after contrast injection showing a midline cerebellar mass with posterior compression of the brain stem.

EXPEDITED PUBLICATION
BRAIN

MRI Surrogates for Molecular Subgroups of Medulloblastoma

S. Perreault, V. Ramaswamy, A.S. Achrol, K. Chao, T.T. Liu, D. Shih, M. Remke, S. Schubert, E. Bouffet, P.G. Fisher, S. Partap, H. Vogel, M.D. Taylor, Y.J. Cho, and K.W. Yeom

ABSTRACT

BACKGROUND AND PURPOSE: Recently identified molecular subgroups of medulloblastoma have shown potential for improved risk stratification. We hypothesized that distinct MR imaging features can predict these subgroups.

MATERIALS AND METHODS: All patients with a diagnosis of medulloblastoma at one institution, with both pretherapy MR imaging and surgical tissue, served as the discovery cohort ($n = 47$). MR imaging features were assessed by 3 blinded neuroradiologists. NanoString-based assay of tumor tissues was conducted to classify the tumors into the 4 established molecular subgroups (wingless, sonic hedgehog, group 3, and group 4). A second pediatric medulloblastoma cohort ($n = 52$) from an independent institution was used for validation of the MR imaging features predictive of the molecular subtypes.

RESULTS: Logistic regression analysis within the discovery cohort revealed tumor location ($P < .001$) and enhancement pattern ($P = .001$) to be significant predictors of medulloblastoma subgroups. Stereospecific computational analyses confirmed that group 3 and 4 tumors predominated within the midline fourth ventricle (100%, $P = .007$), wingless tumors were localized to the cerebellar peduncle/cerebellopontine angle cistern with a positive predictive value of 100% (95% CI, 30%–100%), and sonic hedgehog tumors arose in the cerebellar hemispheres with a positive predictive value of 100% (95% CI, 59%–100%). Midline group 4 tumors presented with minimal/no enhancement with a positive predictive value of 91% (95% CI, 59%–98%). When we used the MR imaging feature–based regression model, 66% of medulloblastomas were correctly predicted in the discovery cohort, and 65%, in the validation cohort.

CONCLUSIONS: Tumor location and enhancement pattern were predictive of molecular subgroups of pediatric medulloblastoma and may potentially serve as a surrogate for genomic testing.

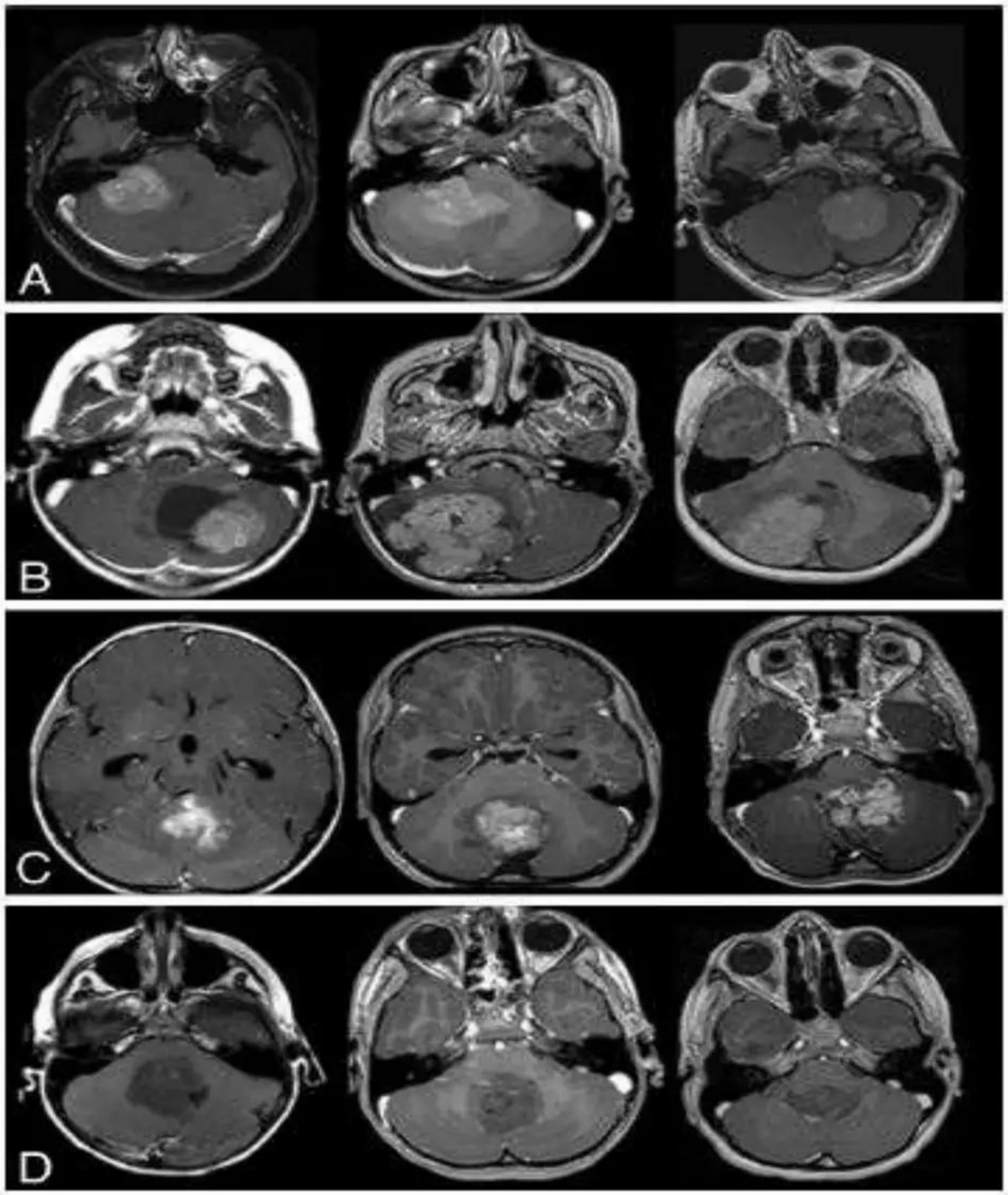

FIG 2. Characteristic MR imaging features according to medulloblastoma molecular subgroups. *A*, In the top row, characteristic location of WNT tumors in the CP/CPA region is shown. *B*, In the second row, SHH tumors are predominantly located in the cerebellar hemispheres. *C*, In the third row, group 3 tumors are located in the midline/fourth ventricle and show enhancement and ill-defined features against the adjacent brain parenchyma. *D*, In the fourth row, group 4 tumors are also located in the midline fourth ventricle but tend to show minimal or no enhancement.

Table 2: Percentage correct with the model when applied to the discovery cohort and validation cohort

Medulloblastoma Subgroups	Percentage Correct in Discovery Cohort	Percentage Correct in Validation Cohort
Total	66%	65%
WNT	75%	50%
SHH	54%	73%
Group 3	92%	83%
Group 4	59%	58%

Pilocytic Astrocytoma

- Best diagnostic clue : cystic cerebellar mass with enhancing mural nodule
- CT findings :
  - Discrete cystic/solid mass
  - Little or no surrounding oedema
  - Often cause obstructive hydrocephalus

MRI findings

- T1W :
  - Solid portions iso/hypointense to GM
  - Cyst : iso to slightyly hyperintense to CSF
- T2W :
  - Solid portions hyperintense to GM
  - Cyst : hyperintense to CSF
- T1C :
  - Intense but heterogenous enhancement of solid portion

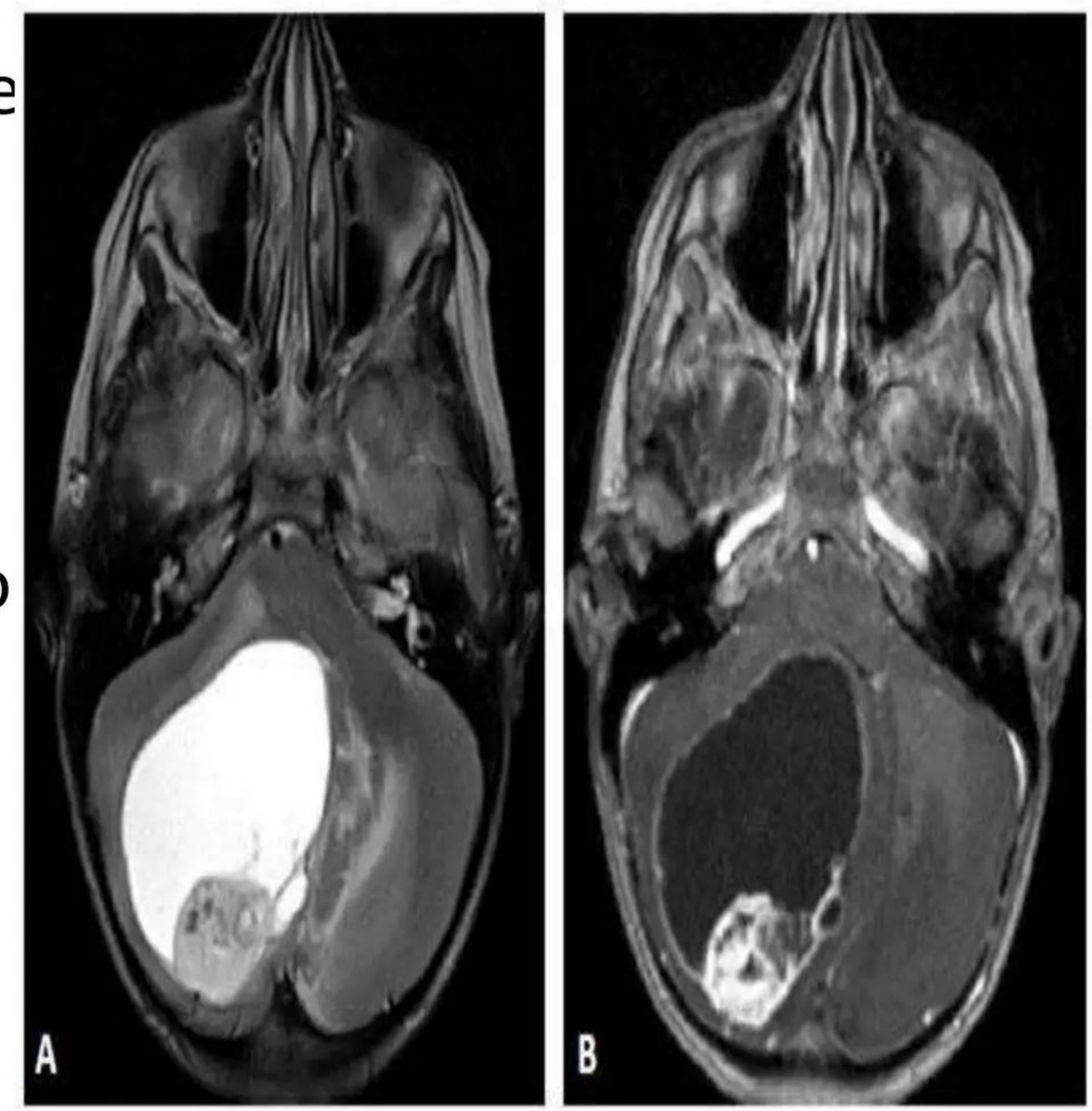

Hemangioblastoma

- CT
  - Isodense to brain on non contrast scans with fluid density surrounding cyst
  - Bright enhancement of the nodule with contrast
  - Cyst walls don’t usually enhance

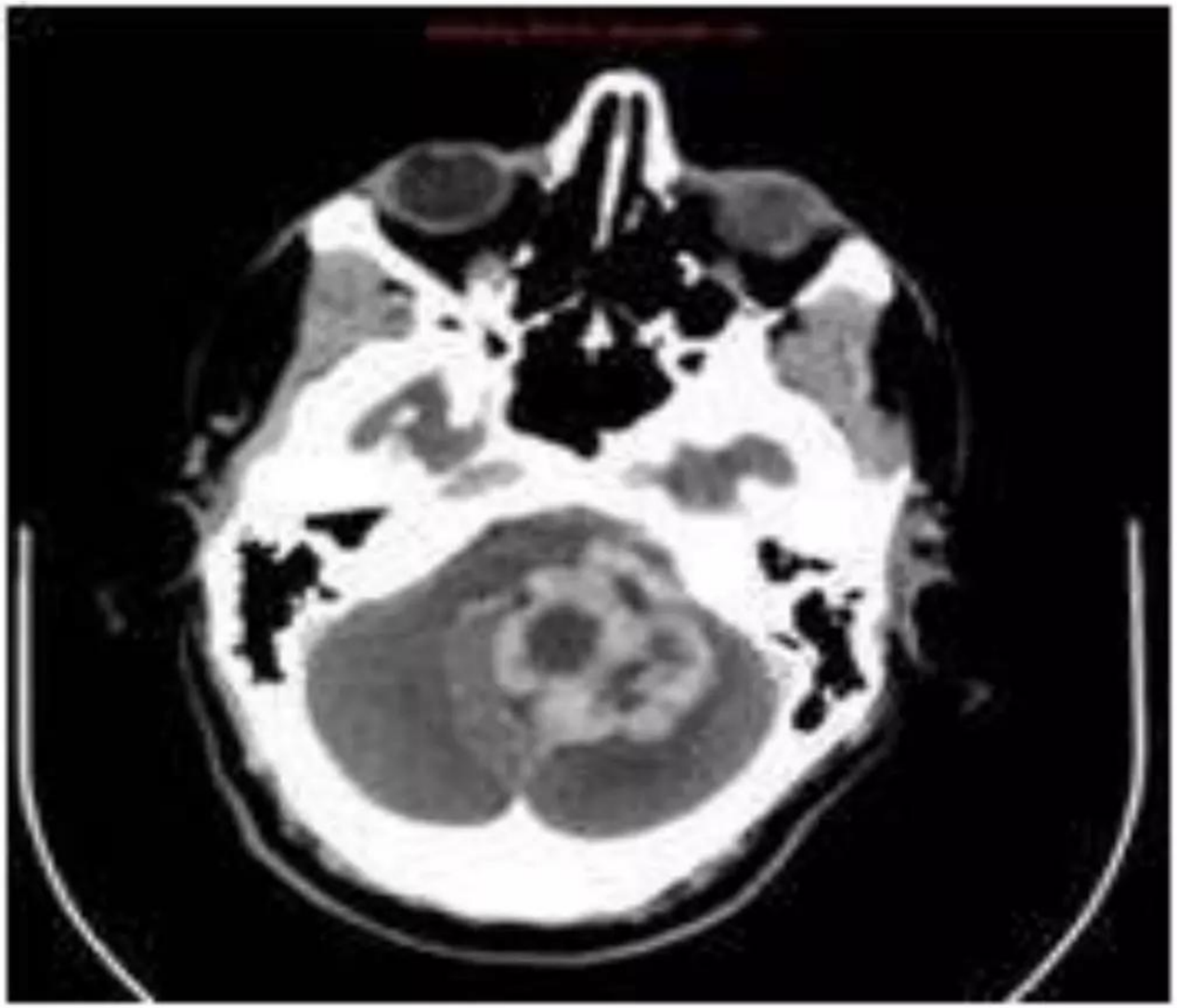

MRI

- T1
  - Hypointense to isointense mural nodule
- T1C :
  - Mural nodule vividly enhances but cyst wall doesnot
- T2 :
  - Hypeintense mural nodule
  - Fluid filled cyst
- Angiography
  - Enlarged feeding arteries and often dilated draining veins with a dense tumour blush centrally

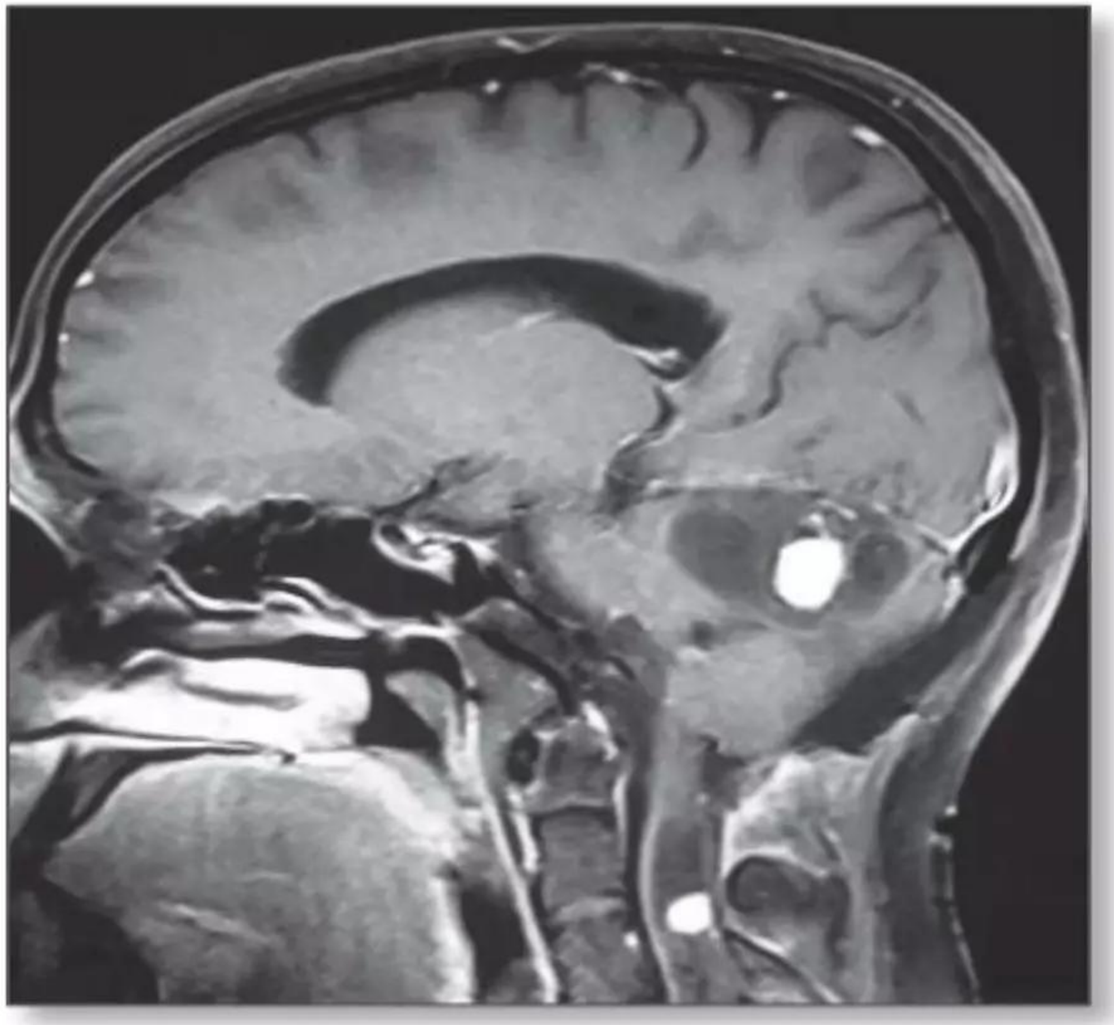

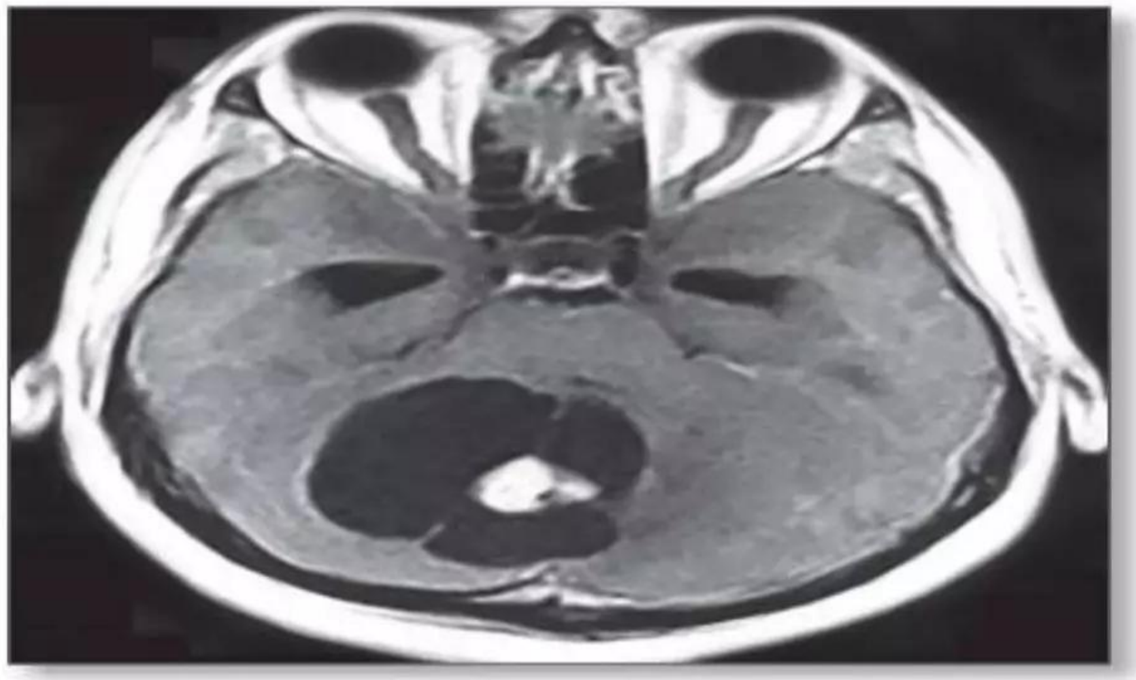

Brain stem Gliomas

- MRI is the method of choice to image these tumours
- Appears isointense or hypointense on T1 images, hyperintense on T2 and enhance uniformly and brightly with IV contrast

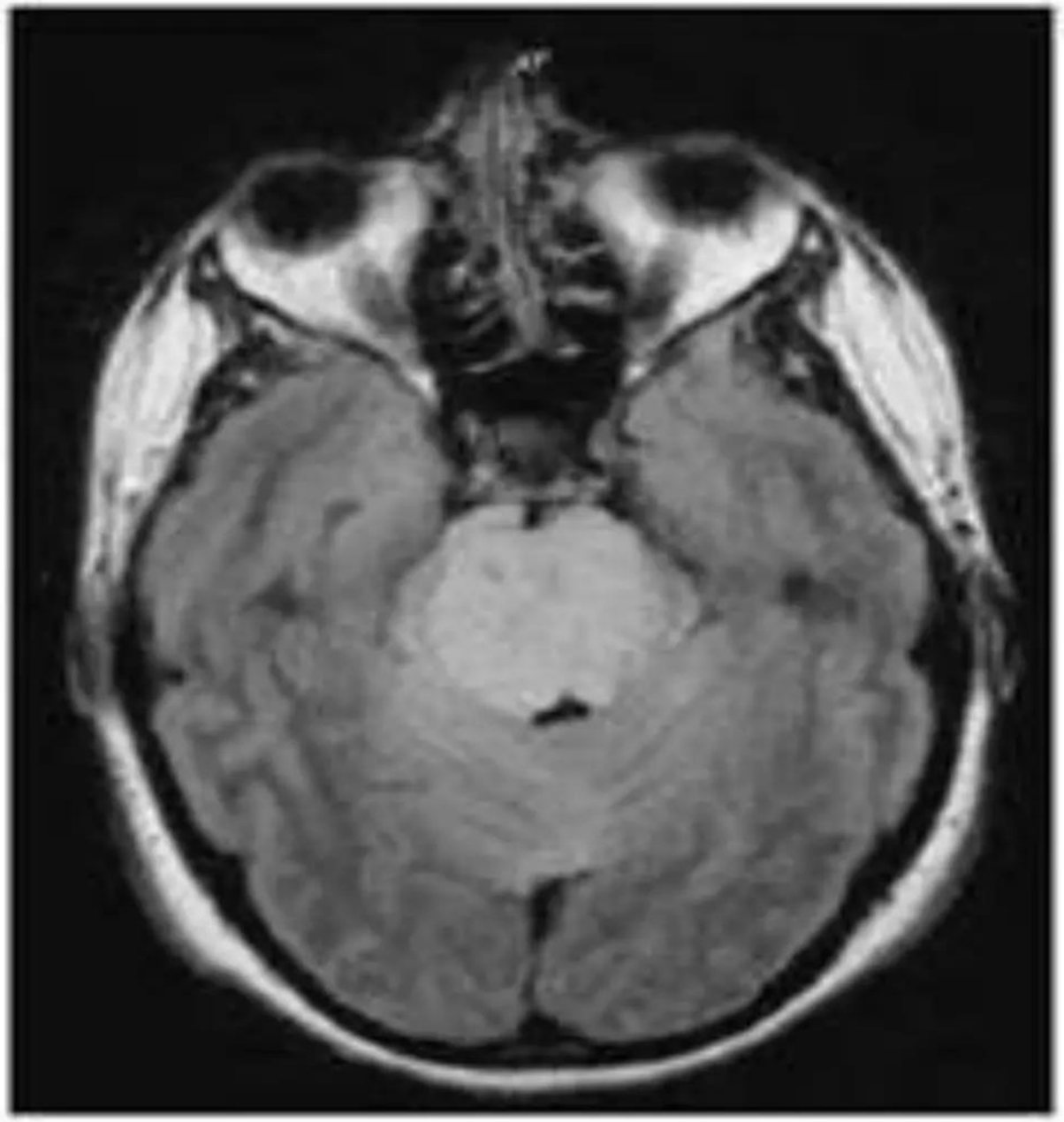

Brain Stem Gliomas

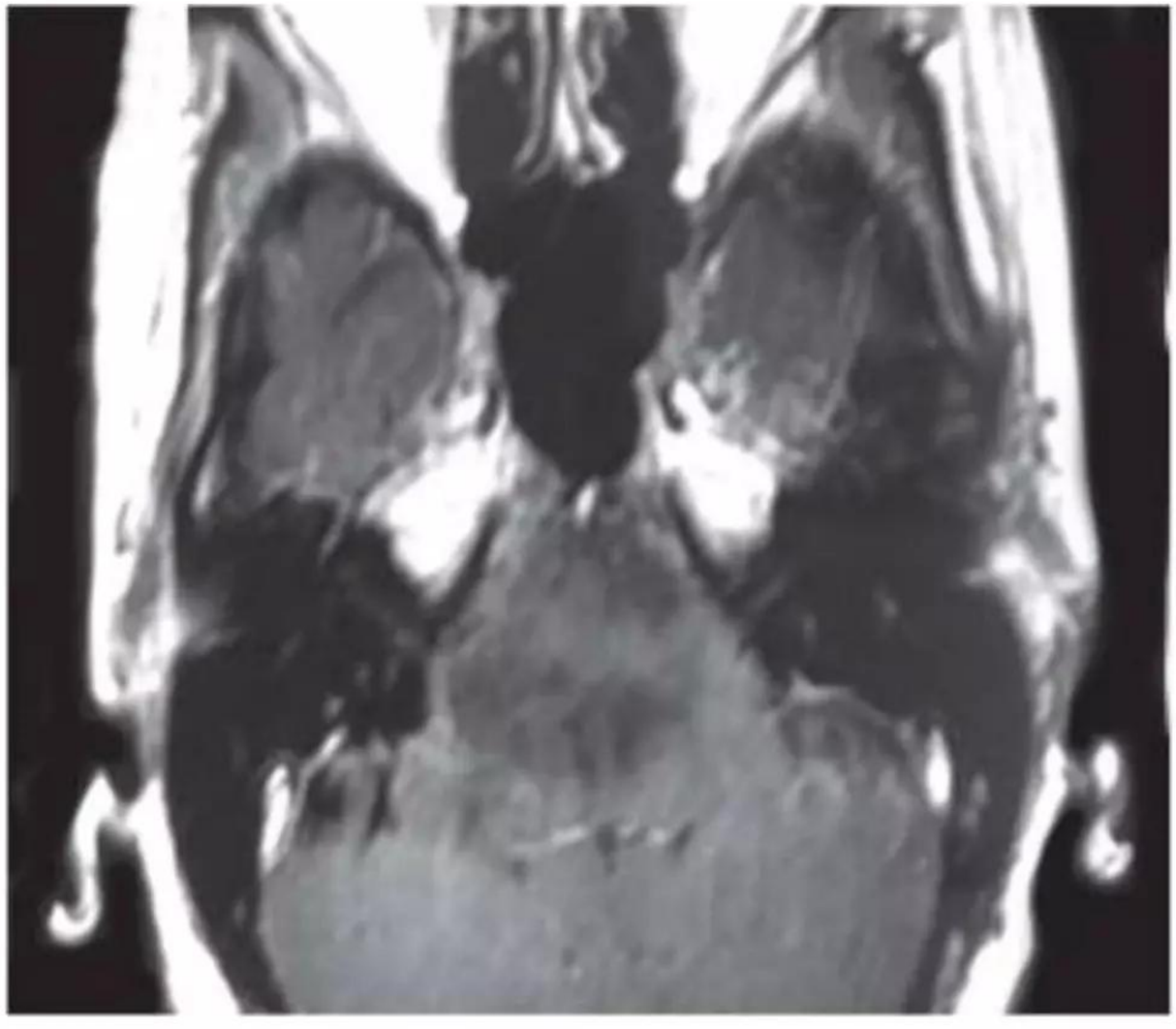

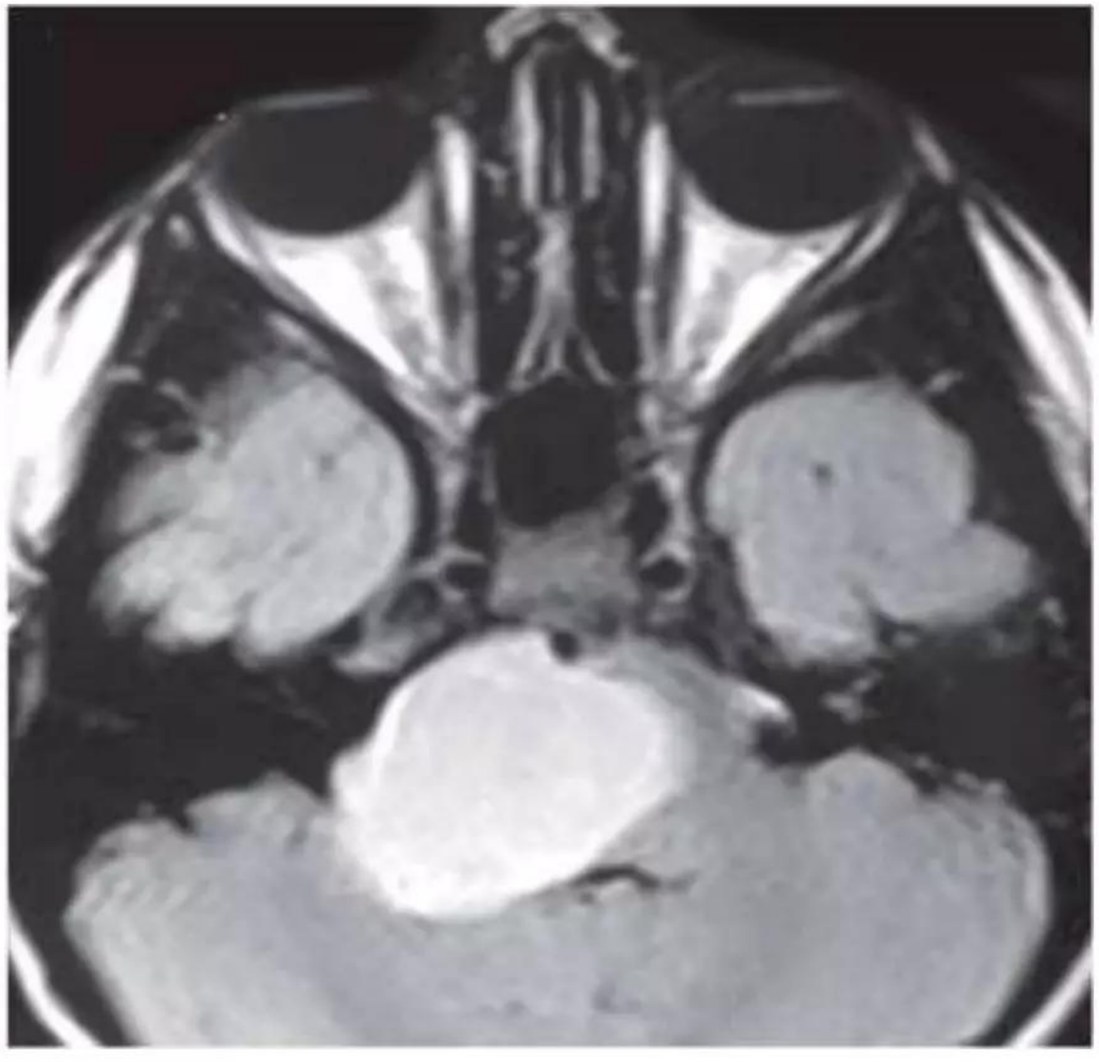

Spinal Tumors

- Spinal tumors are important due to
  - Potentially devastating clinical effects
  - Challenging radiographic appearance
- The differential diagnosis for spinal tumors is established on the basis of
  - Location
  - Clinical presentation : patient’s age

Classification of lesions

- Subdivided according to their point of Origin :
  - Intramedullary
  - Extramedullary
    - Intradural
  - Extradural

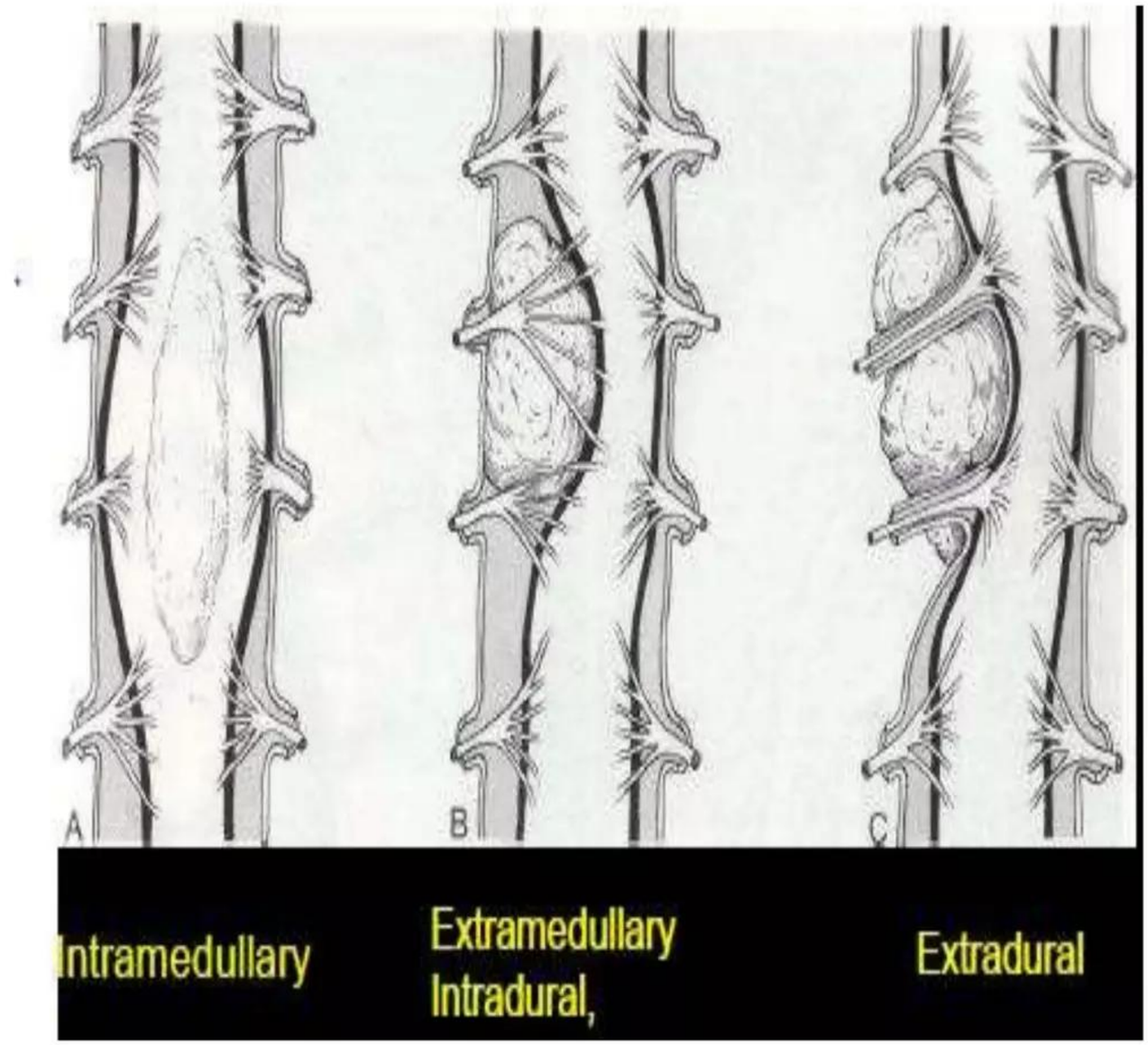

Intramedullary tumors

- Intramedullary tumors are rare, 4 -10 % of all CNS tumors
- It includes
  - Gliomas : ependymomas, astrocytomas and gangliogliomas
  - Non glial tumors : hemangioblastoma, lymphoma and metastasis

Ependymomas : Imaging

- MRI :
  - Iso to hypointense on T1W1 and hyperintense on T2W1
  - Produce symmetric spinal cord expansion
  - Clear tumor margins,
  - uniform enhancement and central location

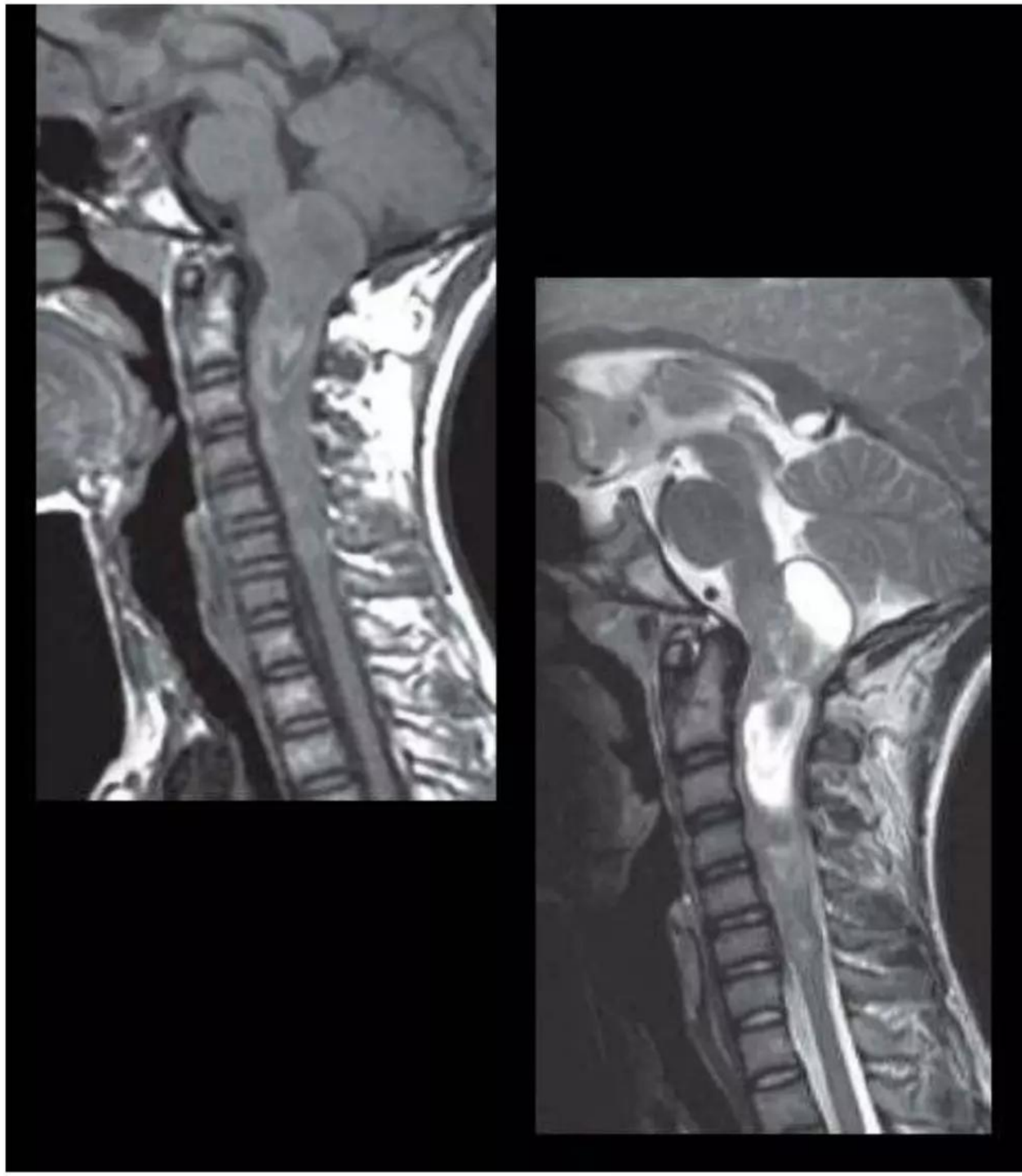

Astrocytomas

- Are located eccentrically within the spinal cord
- Spinal cord astrocytomas infiltrate the cord and are difficult to resect completely and have worse prognosis.
- Most common location : cervicomedullary junction and cervico-thoracic cord
- On MRI, Pilocytic astrocytomas are characterized by enlargement of the spinal cord within a widened spinal canal

Imaging

- Frequently involve a large portion of the cord, spanning multiple vertebral levels in length.
- Areas of necrotic-cystic degeneration
- Solid components are iso to hypointense on T1W1 and hyperintense on T2W1
- Pattern of enhancement : focal, nodular, or diffuse and doesnot define tumor margins

Gangliogliomas

- 2nd m.c intramedullary tumor in pediatric age group
- Location : cervical > thoracic region
- Low malignant potential, slow growth and significant propensity for local recurrence
- Extensive presentation, occupying an average length of 8 vertebral segments, compared to ependymomas and astrocytomas which average 4 vertebral segments in length

Imaging

- Calcification is the single most feature of gangliomas
- Solid portions : mixed iso-hypointensity on T1WI and heterogenous iso-hyperintensity on T2WI
- Eccentrically located within the spinal cord

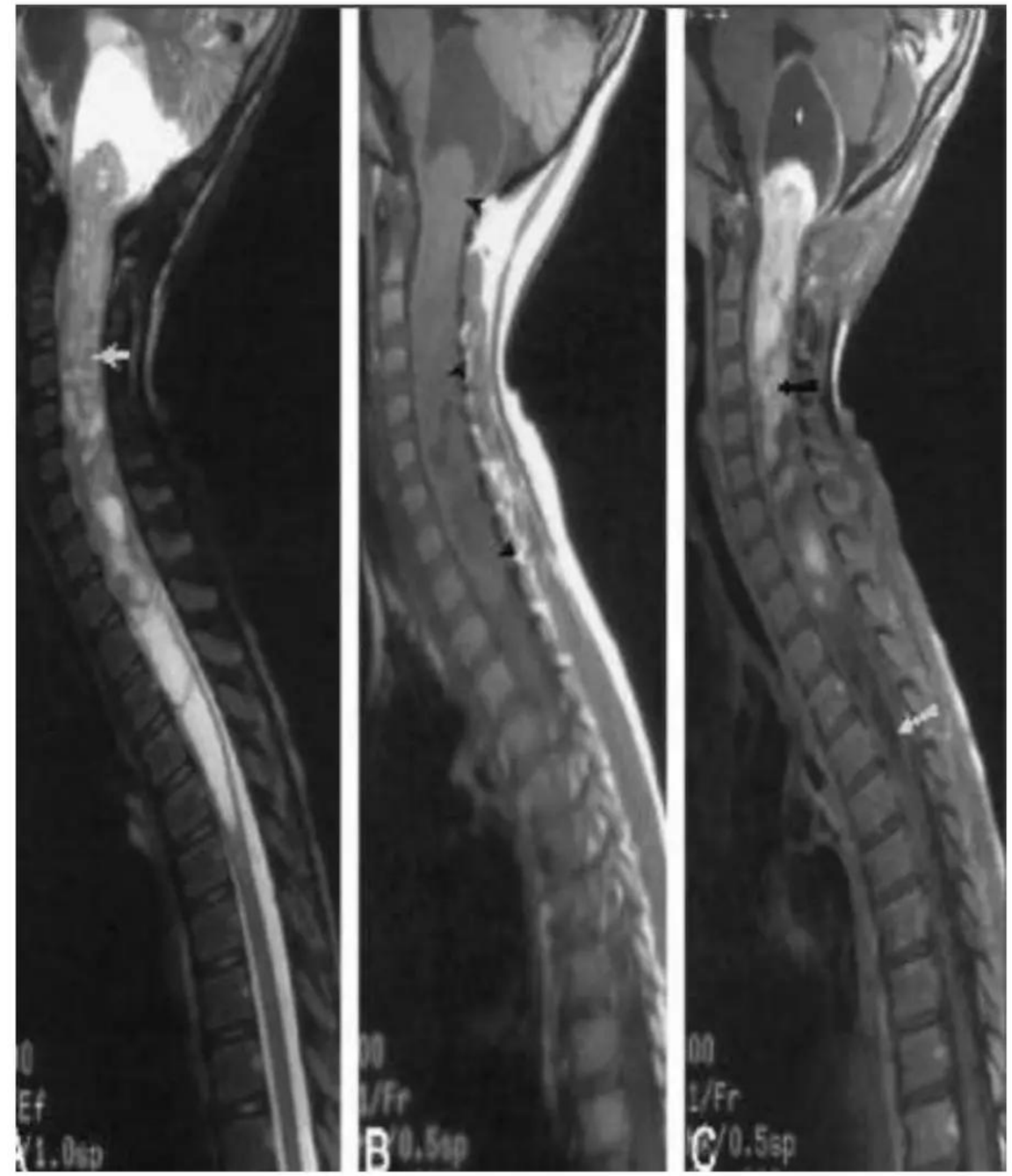

Intra medullary : Non Glial Tumors Hemangioblastoma

- Nonglial, highly vascular neoplasm of unknown cell origin
- Thoracic spine > cervical spine
- A/w VHL disease

Imaging

- MRI feature of spinal hemangioblastoma depend upon the size of the tumor
  - Small (<10mm) :
    - Isointense on T1W
    - Hyperintense on T2W
    - Homogenous enhancement

– Large (>10mm) :
  - Hypo or mixed on T1W
  - Heterogenous on T2W
  - Heterogenous enhancement

Intradural – extramedullary tumors

- Since the arachnoid is essentially continous with the dura in the spine, intradural lesions are located in the subarachnoid space
- It includes :
  - Meningiomas
  - Nerve sheath tumors
  - Lymphoma/leukemia

Meningiomas

- Strong female predominance, 5 to 6th decade of life
- Multiple spinal meningiomas seen in patients with NF-2
- Thoracic > craniocervical > lumbar region
- Most thoracic and lumbar are based on posterior dura, craniocervical may be anterior or posterior in location.

Imaging

- T1 and T2 signal that is isointense with the spinal cord and intense homogenous enhancement
- A dural tail may be seen
- CT may show intra tumoral calcification and this aid in distinguishing between meningiomas and nerve sheath tumors, which don’t show calcifications.

Nerve sheath tumors

- Schwannomas and neurofibromas
- Schwannomas are most common while neurofibromas occur in a/w NF-1

Imaging

- Both may be slightly T2 hypointense secondary to fibrous tissue proliferation
- Both show homogenous or inhomogenous enhancement but schwannomas may have typical ring in which central portion of the mass remains relatively hypointense after contrast

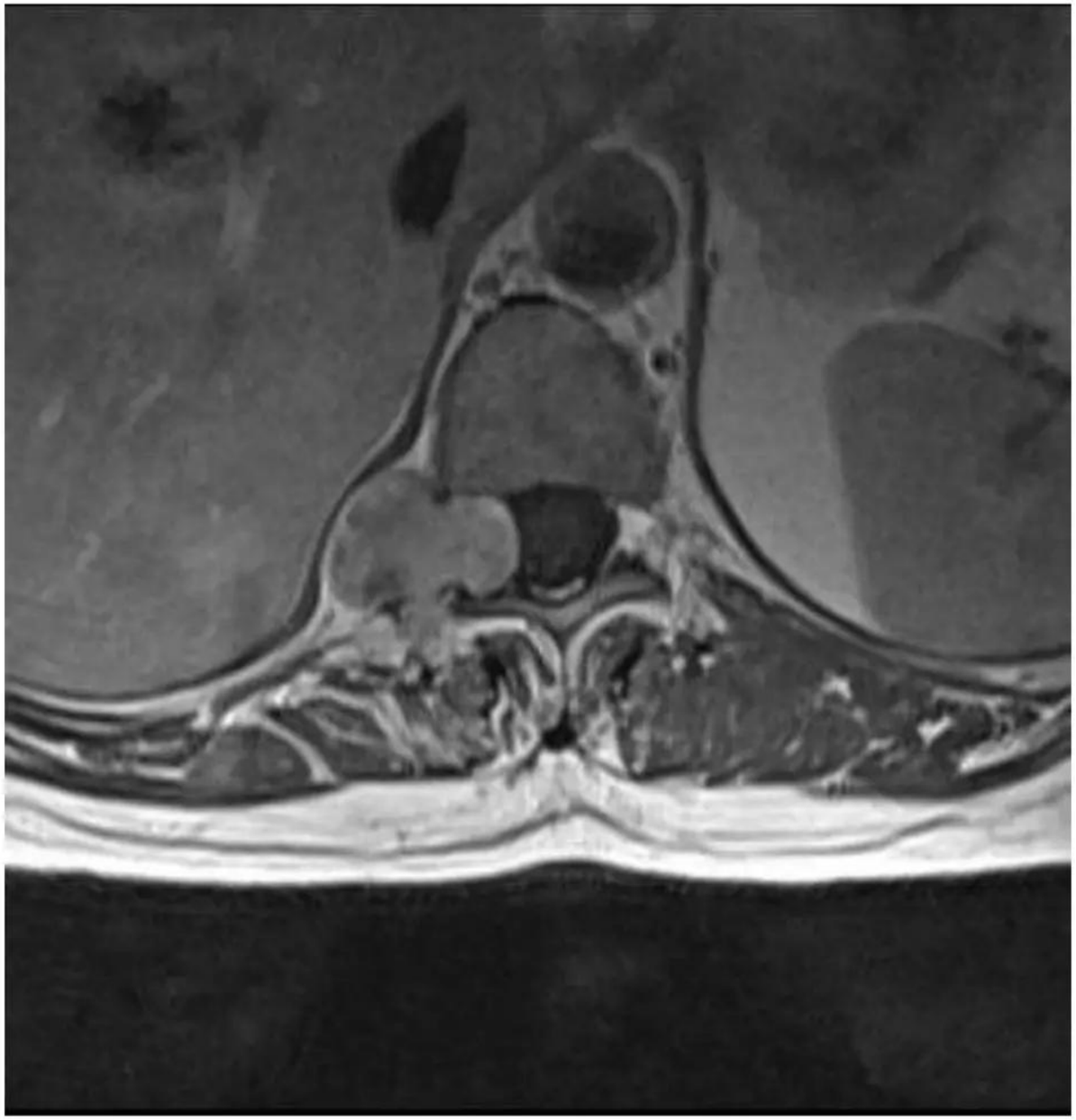

Extradural Tumors

- Metastases
  - Thoracic > lumbar > cervical spine
- T1 hypointense and T2 hyperintense lesions that replace normal marrow
- Most metastases enhance

Multiple myeloma

- On plain film or Ct, they appear as focal lytic lesions
- Hypointense on T1WI and enhancement on Gd-enhanced images

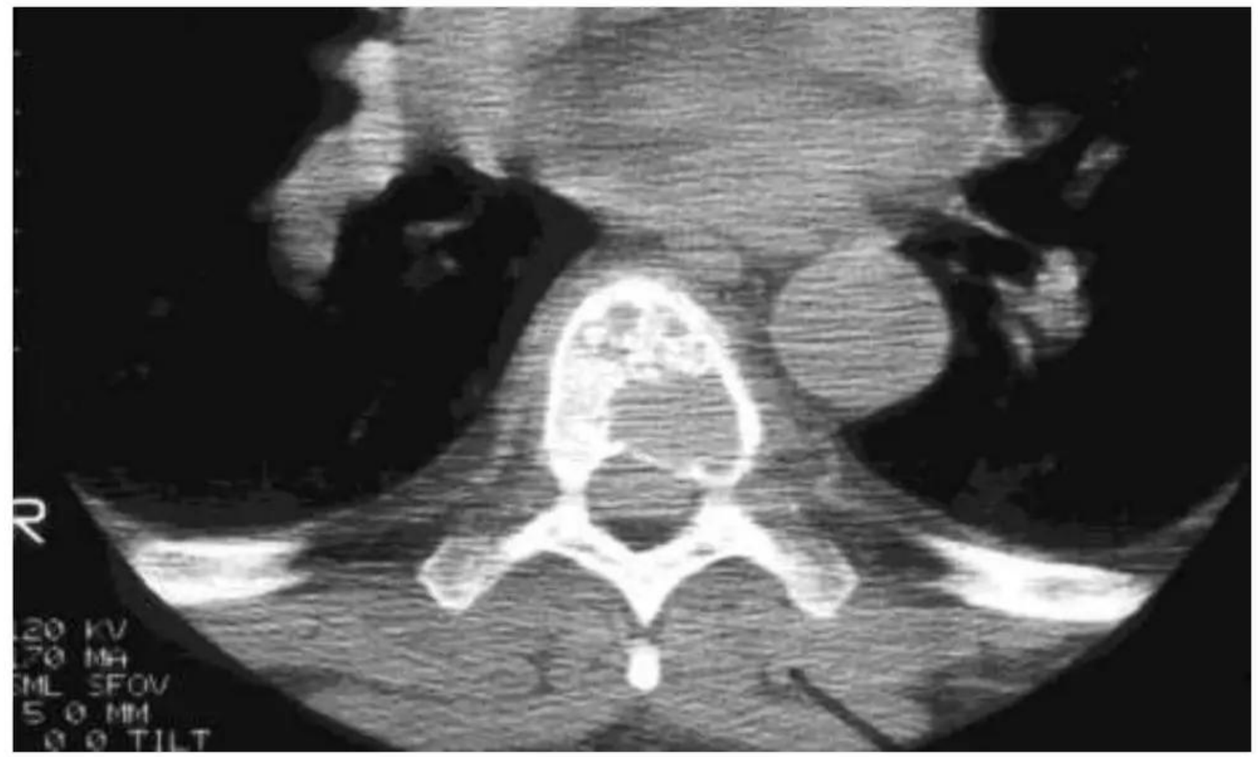

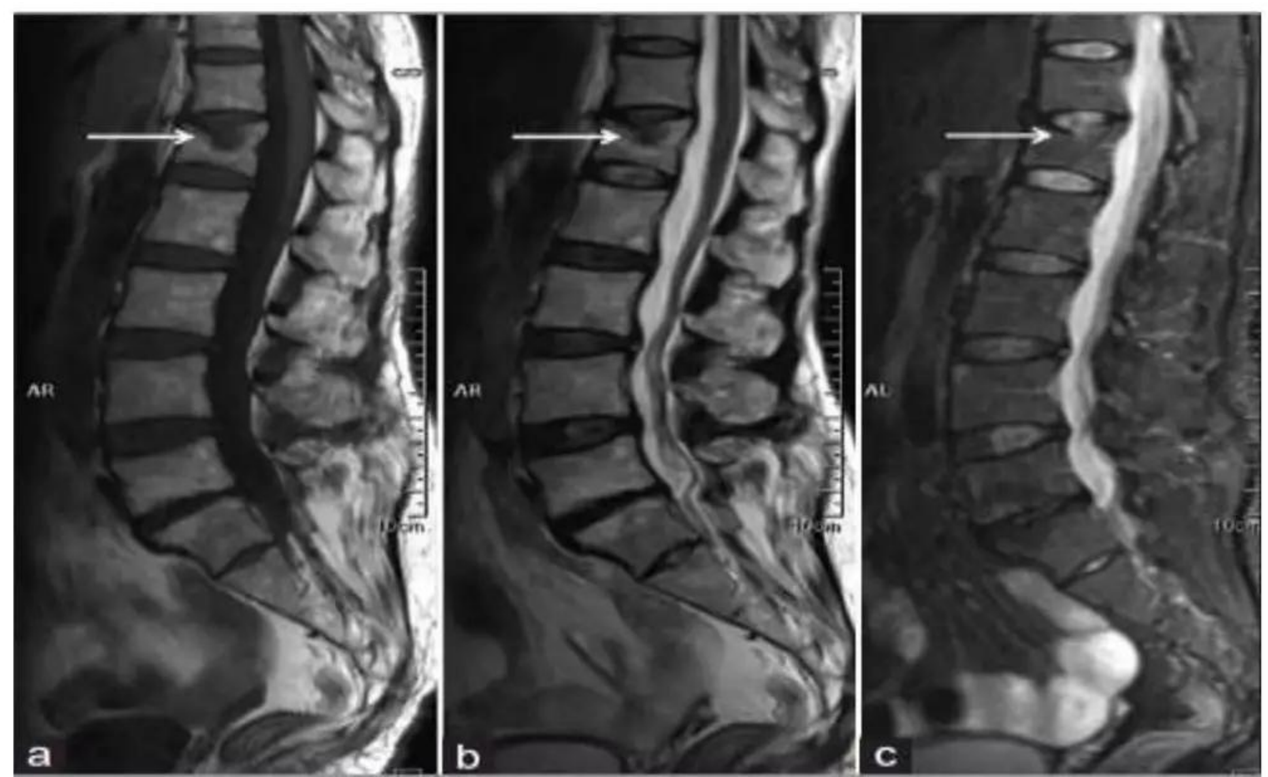

On F/u post treatment
Radiation Necrosis Vs Residual/Recurrent lesion

- The features of Radiation necrosis on conventional MRI
  - New enhancing lesion
  - Satellite lesion
  - Mass effect and
  - Crossing the midline through corpus callosum
- But these features are non specific and do resemble with high grade glioma recurrence
- MR spectroscopy and PET scans are more specific for diffrentiating them

- On MRS
  - Elevated choline for recurrent tumour vs Low NAA, creatine and choline for radiation changes
  - Radiation necrosis : elevated lipids and lactate
- PET scan
  - Aggressive tumour responds with bright signal vs no changes with radiation necrosis.

Conclusions

- Age and clinical features should be considered while looking at radiographic image
- MRI is the imaging modality of choice for CNS tumors
- Generally tumors are hypointense to isointense on T1WI and hyperintense on T2WI
- FLAIR images are useful to delineate lesion near CSF images
- MRS and PET Scans are more specific for diffrentiating between radiation necrosis and residual/recurrent tumors.

Thank you