ADNI Alzheimer's Disease Neuroimaging Initiative

UC Berkeley Amyloid PET Processing Methods

Susan Landau, Ji Yeon Lee, Jacinda Taggett, and William Jagust
Helen Wills Neuroscience Institute, UC Berkeley and Lawrence Berkeley National Laboratory

Summary

This methods document describes the UC Berkeley analysis of all ADNI amyloid PET data using [18F] florbetaben (FBB), [18F] florbetapir (referred to as AV45 in image filenames), and [18F] NAV4694 (NAV).

The **primary quantitative amyloid PET measurement is tracer uptake in a cortical summary SUVR which captures overall amyloid burden in the brain and can be used to determine amyloid +/- status using previously validated thresholds**. This dataset contains the continuous cortical summary SUVR and Centiloid (CL) values derived using methods described in detail in Landau et al. Alz & Dem 2024 [16] that reflect amyloid PET uptake across the cortical summary region and other individual regions, dichotomous variables that reflect amyloid +/- status, and volumetric measurements for each PET ROI.

Please note that the UC Berkeley amyloid PET dataset contains data from multiple amyloid PET tracers. CL values can be compared directly to one another in analyses involving multiple tracers, but SUVRs from multiple tracers are not directly comparable.

Our native space PET analysis pipeline uses the structural MRI scan that is closest in time to each amyloid PET scan. The MRI is segmented and parcellated with Freesurfer v7.1.0 to define a **cortical summary region that is made up of frontal, anterior/posterior cingulate, lateral parietal, lateral temporal regions** (see complete list in Appendix 1).

We have also defined **five candidate reference regions: cerebellar grey matter, whole cerebellum, brainstem, eroded subcortical white matter, and a composite reference region** (made up of whole cerebellum, brainstem, and eroded subcortical WM).

To generate the SUVRs in this dataset, we coregistered each amyloid PET scan to the corresponding segmented/parcellated MRI, intensity normalized the PET scan by the whole cerebellum, and calculated the mean uptake (SUVR) within each Freesurfer Desikan-Killiany region (left, right and volume-weighted bilateral), the cortical summary region, and the five reference regions.

Are the numerical amyloid data already intensity normalized?

Yes. The SUVR and CL values reflect data that has been intensity normalized by the whole cerebellum. This can be observed by the whole cerebellum column having an intensity of "1.0" across all scans. **However, since the reference regions are themselves intensity normalized by the whole cerebellum, it is possible to re-intensity normalize regional or summary SUVRs once by dividing by one of the other reference regions in our dataset.**

This re-normalization divides out the initial whole cerebellum normalization. For example, to calculate summary SUVRs normalized by the composite reference region you must divide the SUMMARY_SUVR values by COMPOSITE_REF_SUVR values.

NOTE: The cortical summary CLs cannot be directly transformed to a different intensity normalization. For cross-sectional analyses, we recommend using the summary SUVR (SUMMARY_SUVR) normalized by the whole cerebellum reference region. For longitudinal analyses, we recommend using the summary SUVR normalized by the composite reference region (SUMMARY_SUVR / COMPOSITE_REF_SUVR). See "Amyloid Positivity Status" section for the provided binarized SUVR variables and derivation of the positivity thresholds.

Methods

Acquisition of amyloid PET and MRI from LONI

We download amyloid PET images from LONI in the most fully pre-processed format (Step4, frames realigned and averaged, linear transformation to straighten out the head, standardized voxel size and smoothed to 6). LONI image description search terms for each tracer are listed in Table 1. Note that as of 09/01/22, the "Step 4" pre-processed amyloid and tau PET data is smoothed to 6mm FWHM uniform resolution. Most PET data acquired prior to this date was also retroactively smoothed to 6mm to enable quantitative harmonization of all historical amyloid and tau PET data. However, a small amount of PET data prior to this date could not be smoothed to 6mm because of older, low spatial resolution scanners (that are no longer used at existing ADNI sites). We developed transformation equations to "convert" 8mm-based SUVRs to be compatible with the 6mm resolution dataset (see [16] for more information, as well as the 02/21/2025 UC Berkeley methods document about smoothing posted on LONI). Therefore, the UC Berkeley amyloid and tau PET datasets contain fully harmonized quantitative PET data from images acquired throughout different phases of ADNI.

Table 1: LONI image search terms for fully pre-processed amyloid and corresponding original structural MRIs

Image Resolution	Tracer	LONI Image Description Search Term	Image Type
8mm	Florbetapir	AV45 Coreg, Avg, Std Img and Vox Siz, Uniform Resolution	"Fully Pre-processed ("stage 4)"
	Florbetaben	FBB Coreg, Avg, Std Img and Vox Siz, Uniform Resolution	
6mm	Florbetapir	AV45 Coreg, Avg, Std Img and Vox Siz, Uniform 6mm Res	
	Florbetaben	FBB Coreg, Avg, Std Img and Vox Siz, Uniform 6mm Res	
	NAV4694	NAV4694 Coreg, Avg, Std Img and Vox Siz, Uniform 6mm Res	
-	MRI	ADNI 1 *N3*; ADNI GO/2 *N3*	"Pre-processed"

		ADNI3/4 *MP*RAGE, *IR-FSPGR* (excluding *_ND: non-distortion corrected MRI)	"Original"

FreeSurfer-defined cortical summary and reference regions

The pipeline uses a native-space structural MRI scan that is closest in time to each amyloid PET scan. The MRI is first segmented and parcellated with Freesurfer (FS) v7.1.0, and then coregistered to the amyloid PET image with SPM. The cortical summary region ("SUMMARY_SUVR") is made up of frontal, anterior/posterior cingulate, lateral parietal, lateral temporal regions) [3, 4] defined by the Desikan-Killiany atlas, shown in Figure 1 and listed in Appendix 1 adapted from FreeSurfer naming convention.

There are five candidate FreeSurfer-defined reference regions: cerebellar grey matter, whole cerebellum, brainstem, eroded subcortical white matter, and a composite reference region. We recommend intensity normalization using whole cerebellum for cross-sectional analyses and composite reference region for longitudinal analyses with florbetapir and florbetaben (Figure 2).

The composite reference region is a non-weighted average of whole cerebellum, brainstem/pons, and subcortical WM regions proposed by Koeppe [5]. We eroded the subcortical white matter region away from ventricles and cortical grey matter to reduce spillover from signal in these regions into white matter. To do this, we smoothed a binarized a FreeSurfer-defined bilateral white matter region mask ("Cerebral White Matter" in FS naming convention) to the same resolution as the PET data, and then thresholded it at 0.70, resulting in an eroded subcortical WM region made up of voxels containing at least 70% white matter.

Recent work in our laboratory and others [10, 11] has shown that reference regions containing subcortical eroded WM result in longitudinal florbetapir measurements that appeared to be less noisy and more accurate [12]. Therefore, normalization by **eroded WM or composite reference region (made up of whole cerebellum, brainstem, and eroded subcortical white matter) is an option for use in longitudinal amyloid PET analyses.**

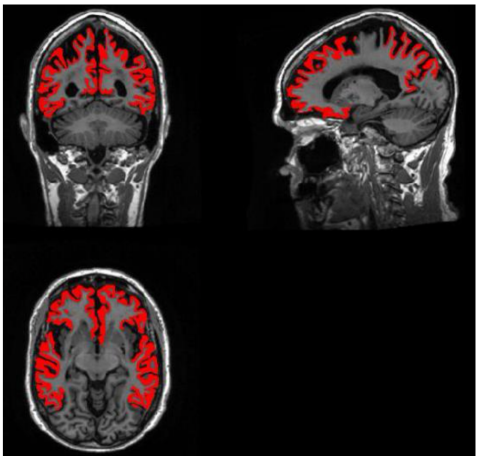

Figure 1. All cortical regions used to create the composite summary region ("SUMMARY_SUVR") are shown in red on an example subject's MRI. Freesurfer-defined regions making up this composite region are listed in Appendix 1.

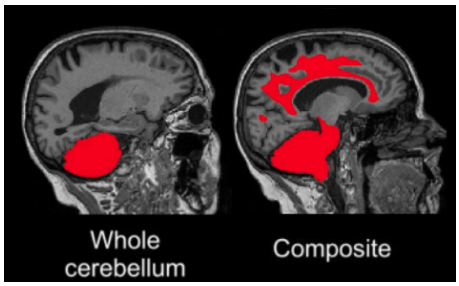

Figure 2. Reference regions recommended for cross-sectional (whole cerebellum) and longitudinal (composite reference) analyses. The WM is eroded away from cortex to avoid partial volume effects. The composite reference region is an average of the whole cerebellum, brainstem and eroded WM regions. See [12].

Summary regions and recommended reference regions are summarized in Table 2.

Table 2

	Target region	**Recommended Reference regions**	
	Cortical summary region	**Whole cerebellum (cross-sectional)**	**Composite Ref (longitudinal)**
Native space FS ROIs	Frontal, temporal, parietal, cingulate regions (see Figure 1 and complete list in Appendix1)	Cerebellar GM + WM (see Figure 2)	Whole cerebellum, brainstem, eroded WM (see Figure 2)

Centiloids

The "CENTILOIDS" column contains a standardized quantitative amyloid measure called Centiloids (CLs), intended to facilitate comparison across different amyloid PET tracers. The Centiloid scale is tied to a 0 anchor, based on typical young controls, and a 100 anchor, based on typical AD patients, but some values will lie outside of the 0-100 bounds. SUVRs normalized to whole cerebellum (SUMMARY_SUVR variable) as described by Landau et al. [16] are converted to CLs using tracer-specific conversion equations shown in Table 3 [13]. See Klunk et al. [14] for more information on the CL scale. **The equations below were developed for the cortical summary region and are not validated for use in other ROIs.**

Table 3. Centiloids conversion equations for cortical summary SUVRs normalized by whole cerebellum

Centiloids Conversion Equations for the Cortical Summary Region Normalized by Whole Cerebellum		
AV45	**FBB**	**NAV**
CL=188.22×SUMMARY_SUVR−189.16	CL=157.15×SUMMARY_SUVR−151.87	CL=109.45×SUMMARY_SUVR – 106.78

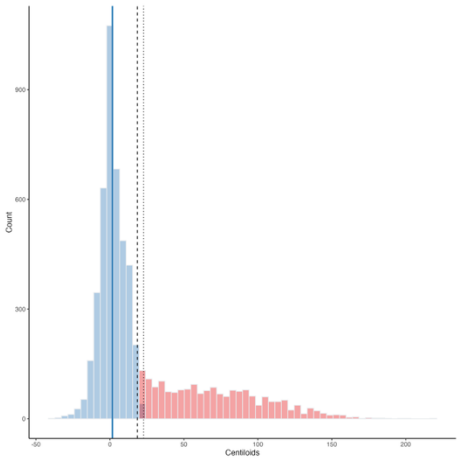

Tracer-generic (Centiloid) threshold

For analyses where it is useful to have a fixed threshold across all tracers, we recommend 18 CL. This threshold was derived from performing a Gaussian Mixture Model with 6,212 amyloid scans across four tracers (FBB, AV45, NAV, PiB) from six cohorts in our local repository (table below).

Figure 3. Validation of FBB cross-sectional threshold with Gaussian Mixture Model derivation method. *GMM (normalmixEM function from mixtools using R) was used to identify upper (blue) and lower (pink) distributions of N=6,212 baseline cortical summary CLs with whole cerebellum normalization. 2SDs above the mean of the lower distribution was a CL of 18 (mean=1.12, SD=7.98). The mean of lower distribution is shown with a solid blue line, mean + 2SDs is shown with a long dashed blue line, and mean+2.5SDs is shown with a small dashed blue line.*

Cohort	Total	FBP	FBB	NAV	PiB
N	6212	1430	4018	160	604
AB+ (%)	2157 (35%)	720 (50%)	1048 (26%)	93 (58%)	296 (49%)
Age	70.2 (7.7)	73.5 (7.7)	68.5 (7.3)	73.3 (7.3)	72.9 (6.9)
APOE4+ (%)	1969 (32%)	553 (39%)	1144 (28%)	29 (42%)	172 (28%)
CL	21 +/- 39	38 +/- 48	17 +/- 31	65 +/- 61	33 +/- 47
DX (% CN)	4156 (67%)	589 (41%)	2874 (73%)	63 (39%)	445 (74%)

Tracer-specific amyloid positivity

SUVR cutoffs for establishing amyloid positivity or negativity are specific to both the radiotracer and the image processing methods used [6, 7]. Please see Landau et al. Alzheimer's & Dementia (2025) for detailed tracer-specific threshold information [16].

Selection of an appropriate cutoff depends on the goals of the study or analysis. We have provided amyloid positivity categorizations by the whole cerebellum reference cutoff (for cross-sectional analyses) and the composite reference cutoff (for longitudinal analyses). For the Amyloid 6mm dataset (combined of multiple tracers), the tracer-dependent binarized SUVR

variables are "AMYLOID_STATUS" (whole cerebellum reference) and "AMYLOID_STATUS_COMPOSITE_REF" (composite reference).

The SUVRs were binarized based on the positivity thresholds listed and described in Table 4. **The thresholds apply to the cortical summary SUVRs normalized by the whole cerebellum reference region or composite reference region ONLY and are NOT applicable to the individual subregions.**

Table 4. Amyloid Positivity Threshold by Tracer and Reference Region and their derivation method

Tracer	**AV45**		**FBB**		**NAV**	
Reference Region	Derivation Method	Threshold	Derivation Method	Threshold	Derivation Method	Threshold
Whole Cerebellum	Upper 95% CI above mean of Young Controls	**1.11 SUVR**	Mean+2SD of Young Controls	**1.08 SUVR**	Mean+2SD of GMM "Low" Amyloid Group	**1.14 SUVR**
Composite Reference	Linear transformation from whole cerebellum-normalized threshold	**0.78 SUVR**	Linear transformation from whole cerebellum-normalized threshold	**0.74 SUVR**	**–**	**–**

For longitudinal analyses, we converted whole cerebellum-normalized thresholds to composite reference-normalized SUVR units for AV45 (0.78) and FBB (0.74) only based on linear regression of composite reference-normalized SUVRs against whole cerebellum-normalized SUVRs (Figure 4).

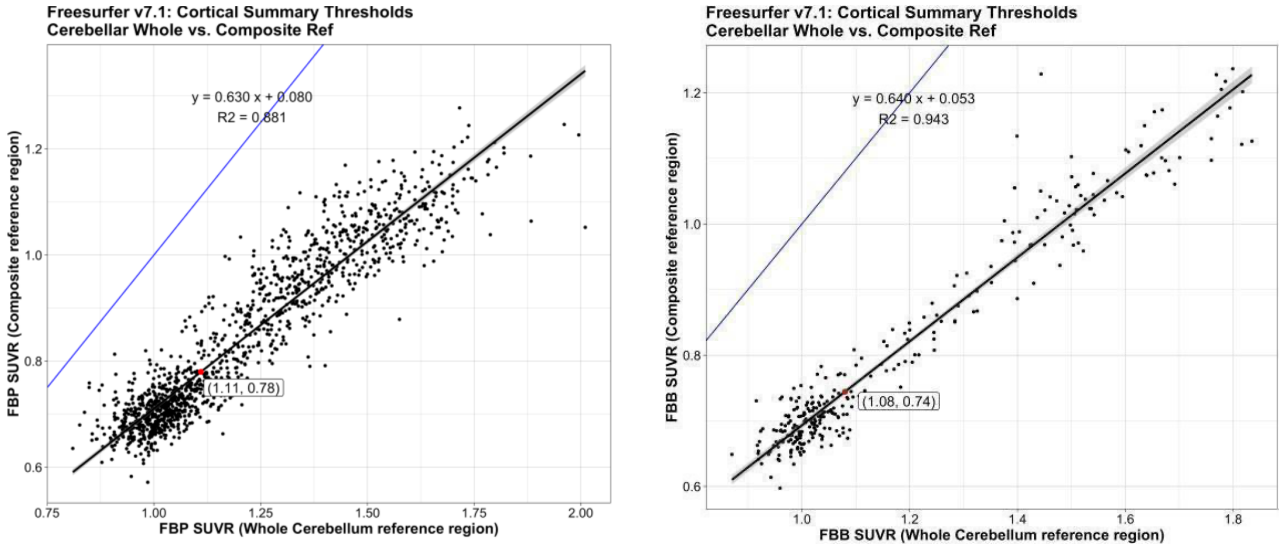

Figure 4. Linear regressions of AV45 (left) and FBB (right) composite reference-normalized SUVRs against whole cerebellum-normalized SUVRs. *Transforming the AV45 whole cerebellum-normalized threshold of 1.11 into composite reference-normalized units results in a threshold of 0.78 (left). Transforming the FBB whole cerebellum-normalized threshold of 1.08 into composite reference-normalized units results in a threshold of 0.74 (right).*

Pipeline Quality Control Flag

Included in the 6mm dataset is a column (qc_flag) for our technicians to flag errors in the pipeline where the data (SUVR or volume) are unavailable or may not be reliable based on visual inspection of the FreeSurfer segmentation and MR/PET registration [see 16 for more info]. Our QC emphasizes accuracy of primary regions of interest (cortical summary and whole cerebellum), so usable images may receive a full pass (qc_flag=2) or partial pass (qc_flag=1) depending on our assessment of the usability of the primary ROIs relative to the other brain regions.

qc_flag	Result	Description
2	Pass	Primary ROIs meet the processing requirement and the Freesurfer parcellation follows the T1 cortical ribbon throughout the whole brain.
1	Partial pass	Primary ROIs meet the processing requirement; other ROIs may be incorrect.
0	Fail	A processing related error has a significant effect on the segmentation of the primary ROIs.
-1	Not assessed	The image has not been QC'd.

-2	Cannot be processed	The image cannot be processed or has failed to complete the pipeline despite troubleshooting efforts.

Version Information

This document supersedes our AV45/FBP Methods and FBB Methods documents dated June 29 2023. It applies to the Amyloid 6mm dataset published April 30 2025.

Listed below are the changes that from the previous version:

1. **Integration of [18F] NAV4694 (NAV) scans**

Additional information:

1. **Merging of tracer**: Multiple tracers (AV45/FBP, FBB and NAV) are combined in a single dataset, distinguishable by the "TRACER" column. **Use CL values, not SUVRs to directly compare data from different tracers.**

2. Amyloid positivity variables ("AMYLOID_STATUS" and "AMYLOID_STATUS_COMPOSITE_REF") use different tracer-dependent thresholds.

3. The "**qc_flag**" column. Please refer to "Pipeline Quality Control Flag" section.

Dataset Information

This methods document applies to the following datasets available from the ADNI repository:

TBLNAME	Dataset Name	Date Submitted
UCBERKELEY_AMY_6MM	UC Berkeley - Amyloid PET 6mm Res Analysis	30 April 2025*

*New data will be uploaded to the 6mm dataset (UCBERKELEY_AMY_6MM) periodically. Users can refer to its "update_stamp" column to check when the dataset is last updated. The "PROCESSDATE" column represents the date when the quantification pipeline was run. If a PET image has been re-processed (e.g., when a new MRI becomes available), its numerical data will be updated along with new PROCESSDATE and update_stamp.

Data dictionaries can be found at Download Study Data > Study Info > Data Dictionary [ADNI1,GO,2,3]. Use TBLNAME column to filter the corresponding data dictionaries from the long spreadsheet.

References

1. Landau, S.M., et al., Comparing positron emission tomography imaging and cerebrospinal fluid measurements of beta-amyloid. Ann Neurol, 2013. 74(6): p. 826-36.
2. Landau, S.M., et al., Amyloid deposition, hypometabolism, and longitudinal cognitive decline. Ann Neurol, 2012. doi:10.1002/ana.23650.

3. Mormino, E.C., et al., Episodic memory loss is related to hippocampal-mediated beta-amyloid deposition in elderly subjects. Brain, 2009. 132(Pt 5): p. 1310-23.
4. Jagust, W.J., et al., Relationships between biomarkers in aging and dementia. Neurology, 2009. 73(15): p. 1193-9.
5. Koeppe, R.A., Data analysis for amyloid PET imaging: Longitudinal studies, in Human Amyloid Imaging. 2013: Miami, FL.
6. Landau, S.M., et al., Amyloid-beta imaging with Pittsburgh compound B and florbetapir: comparing radiotracers and quantification methods. J Nucl Med, 2013. 54(1): p. 70-7.
7. Landau, S.M., et al., Amyloid PET imaging in Alzheimer's disease: a comparison of three radiotracers. Eur J Nucl Med Mol Imaging, 2014.
8. Joshi, A.D., et al., Performance characteristics of amyloid PET with florbetapir F 18 in patients with alzheimer's disease and cognitively normal subjects. J Nucl Med, 2012. 53(3): p. 378-84.
9. Clark, C.M., et al., Use of florbetapir-PET for imaging beta-amyloid pathology. JAMA, 2011. 305(3): p. 275-83.
10. Brendel, M., et al., Improved longitudinal [(18)F]-AV45 amyloid PET by white matter reference and VOI-based partial volume effect correction. Neuroimage, 2015. 108: p. 450-9.
11. Chen, K., et al., Improved power for characterizing longitudinal amyloid-beta PET changes and evaluating amyloid-modifying treatments with a cerebral white matter reference region. J Nucl Med, 2015. 56(4): p. 560-6.
12. Landau, S.M., et al., Measurement of longitudinal beta-amyloid change with 18F-florbetapir PET and standardized uptake value ratios. J Nucl Med, 2015. 56(4): p. 567-74.
13. Royse S.K., et al. Validation of amyloid PET positivity thresholds in centiloids: a multisite PET study approach. Alzheimers Res Ther., 2021;13(1):99. doi:10.1186/s13195-021-00836-1
14. Klunk W.E., et al. The Centiloid Project: standardizing quantitative amyloid plaque estimation by PET. Alzheimers Dement., 2015;11(1):1-15.e154. doi:10.1016/j.jalz.2014.07.003
15. Ellis K.A., et al., The Australian Imaging, Biomarkers and Lifestyle (AIBL) study of aging: methodology and baseline characteristics of 1112 individuals recruited for a longitudinal study of Alzheimer's disease. Int Psychogeriatr., 2009 Aug;21(4):672-87. doi: 10.1017/S1041610209009405.
16. Landau, S.M., et al., Positron emission tomography harmonization in the Alzheimer's Disease Neuroimaging Initiative: A scalable and rigorous approach to multisite amyloid and tau quantification. Alzheimer's & Dementia, 2024. doi: 10.1002/alz.14378.

About the Authors

This document was prepared by Ji Yeon Lee, Jacinda Taggett, JiaQie Lee, Susan Landau, Theresa Harrison, William Jagust, Helen Wills Neuroscience Institute. For more information, please contact slandau@berkeley.edu.

Notice: This document is presented by the author(s) as a service to ADNI data users. However, users should be aware that no formal review process has vetted this document and that ADNI cannot guarantee the accuracy or utility of this document.

Appendix 1 - Cortical Summary ROIs

We include both volumes and SUVRs for right/left (shown) and bilateral versions of the following FreeSurfer regions.

Frontal regions:
ctx-lh-caudalmiddlefrontal
ctx-lh-lateralorbitofrontal
ctx-lh-medialorbitofrontal
ctx-lh-parsopercularis
ctx-lh-parsorbitalis
ctx-lh-parstriangularis
ctx-lh-rostralmiddlefrontal
ctx-lh-superiorfrontal
ctx-lh-frontalpole
ctx-rh-caudalmiddlefrontal
ctx-rh-lateralorbitofrontal
ctx-rh-medialorbitofrontal
ctx-rh-parsopercularis
ctx-rh-parsorbitalis
ctx-rh-parstriangularis
ctx-rh-rostralmiddlefrontal
ctx-rh-superiorfrontal
ctx-rh-frontalpole

Anterior/posterior cingulate regions:
ctx-lh-caudalanteriorcingulate
ctx-lh-isthmuscingulate
ctx-lh-posteriorcingulate
ctx-lh-rostralanteriorcingulate
ctx-rh-caudalanteriorcingulate
ctx-rh-isthmuscingulate
ctx-rh-posteriorcingulate
ctx-rh-rostralanteriorcingulate

Lateral parietal regions:
ctx-lh-inferiorparietal
ctx-lh-precuneus
ctx-lh-superiorparietal
ctx-lh-supramarginal
ctx-rh-inferiorparietal
ctx-rh-precuneus
ctx-rh-superiorparietal
ctx-rh-supramarginal

Lateral temporal regions:
ctx-lh-inferiortemporal
ctx-lh-middletemporal
ctx-lh-superiortemporal
ctx-rh-inferiortemporal
ctx-rh-middletemporal
ctx-rh-superiortemporal