Original Article
Int Neurourol J 2025;29(Suppl 2):S90-94
https://doi.org/10.5213/inj.2550292.146
pISSN 2093-4777 · eISSN 2093-6931

INTERNATIONAL NEUROUROLOGY JOURNAL
INJ
OPEN ACCESS

Data-Efficient Deep Learning Framework for Urolithiasis Detection Using Transfer and Self-Supervised Learning

Jae-Seoung Kim[1], Sung-Jong Eun[2]

[1]Core Research & Development Center, Korea University Ansan Hospital, Ansan, Korea
[2]National IT Industry Promotion Agency, Jincheon, Korea

Purpose: Recent studies on urolithiasis detection using deep learning have demonstrated promising accuracy; however, most rely on large-scale labeled imaging datasets. In clinical practice, only limited and partially labeled computed tomography (CT) scans are typically available, restricting the generalizability of conventional supervised models. This study aimed to propose a data-efficient framework for accurate stone detection from a small CT dataset by integrating self-supervised learning (SSL) and transfer learning (TL).

Methods: A total of 100 abdominal CT scans were analyzed and labeled as stone present or normal by expert radiologists. To learn generalizable feature representations from limited data, a SimCLR-based SSL framework with a ResNet50 backbone was employed. During the SSL stage, the model learned from augmented image pairs without labels to maximize similarity between positive pairs and minimize similarity between negatives. The pretrained encoder was subsequently fine-tuned using labeled data in the TL stage, with the lower layers frozen and higher blocks optimized using a linear classifier. Model training was performed with 5-fold cross-validation, and performance was evaluated using accuracy, precision, recall, F1-score, and area under the receiver operating characteristic curve (AUC).

Results: The proposed SSL+TL model achieved the best performance (AUC, 0.95; F1-score, 0.91), significantly outperforming both the random initialization and TL-only models. These findings indicate that SSL pretraining effectively learns robust and transferable representations even with limited data.

Conclusions: The proposed framework demonstrates the feasibility of artificial intelligence-based urolithiasis detection in small-data clinical environments. Combining SSL and TL alleviates data scarcity and provides a foundation for developing generalizable and resource-efficient diagnostic models for urological imaging.

Keywords: Urolithiasis; Computed tomography; Deep learning; Transfer learning

- **Grant/Fund Support:** This study received no specific grant from any funding agency in the public, commercial, or not-for-profit sectors.
- **Conflict of Interest:** No potential conflict of interest relevant to this article was reported.

INTRODUCTION

Urolithiasis is among the most common urological conditions, affecting approximately 10% of adults worldwide and often recurring throughout life [1, 2]. Timely and accurate detection is essential because stones can cause severe pain, urinary tract infection, or renal impairment. Abdominal computed tomography (CT) is considered the gold standard imaging modality for stone detection, although its diagnostic performance can vary depending on image quality and radiologist expertise [3].

Recent advances in artificial intelligence (AI) and deep learning have enabled automated detection and classification of uro-

Corresponding author: Sung-Jong Eun https://orcid.org/0000-0003-3063-0452
National IT Industry Promotion Agency, 10 Jeongtong-ro, Deoksan-eup, Jincheon 27872, Korea
Email: sjeun@nipa.kr
Submitted: September 11, 2025 / **Accepted after revision:** November 6, 2025

This is an Open Access article distributed under the terms of the Creative Commons Attribution Non-Commercial License (https://creativecommons.org/licenses/by-nc/4.0/) which permits unrestricted non-commercial use, distribution, and reproduction in any medium, provided the original work is properly cited.

Copyright © 2025 Korean Continence Society

logical diseases, including urolithiasis [4-6]. Convolutional neural networks combined with transfer learning (TL) have achieved high accuracy when trained on large-scale labeled datasets. However, such models typically require thousands of annotated images, which are rarely available in real-world clinical practice due to the high cost and labor-intensive nature of data labeling [7].

To overcome these limitations, self-supervised learning (SSL) has emerged as a powerful alternative. SSL enables representation learning from unlabeled data by defining proxy tasks such as contrastive learning [8]. SimCLR, a representative SSL method, learns visual features by maximizing similarity between augmented views of the same image and minimizing similarity between different images [9]. When combined with transfer learning, SSL can markedly improve generalization performance in small-data scenarios [10].

The objective of this study was to develop and evaluate a data-efficient deep learning framework integrating SSL and TL for urolithiasis detection using limited CT scans. We hypothesized that SSL pretraining could extract meaningful feature representations that enhance model robustness even under data-constrained conditions.

MATERIALS AND METHODS

Dataset and Labeling

This study utilized 20 abdominal CT scans for urolithiasis detection. All images were anonymized before analysis and reconstructed into 3-dimensional volumes. Each case was labeled by an experienced urologist as either stone present (positive) or normal. Training was performed on axial slices containing relevant urinary structures. Representative CT slices from the dataset are shown Fig. 1.

Preprocessing and Image Augmentation

CT images were resampled to 512×512 pixels, and intensity

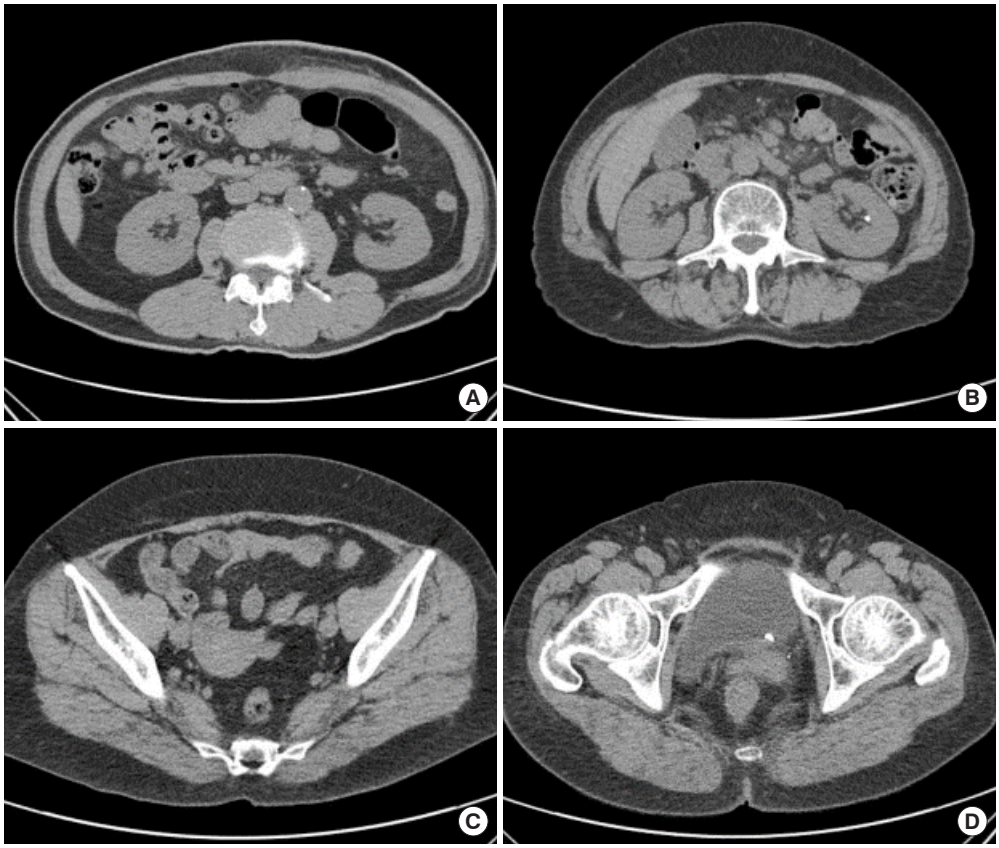

Fig. 1. Representative computed tomography slices of the urolithiasis dataset. (A) Normal kidney without any renal stones. (B) Kidney with renal stones. (C) Normal ureter without stones. (D) Ureter with ureteral stones.

values were clipped to a window of -200 to 1,000 HU. Standard z-score normalization was applied. To improve generalization, data augmentation techniques including random rotation (±10°), horizontal flipping, and brightness adjustment were employed.

Self-Supervised Pretraining

A SimCLR-based contrastive learning approach [10] was used for SSL pretraining. Using a ResNet50 encoder, augmented image pairs were generated from unlabeled CT slices. The model learned to maximize similarity for positive pairs and minimize it for negative pairs using the following loss function:

$$L_{i,j} = -log\frac{\exp\left(sim(z_i, z_j)/\gamma\right)}{\sum_{k=1}^{2N} 1_{[k\neq i]}\exp\left(sim(z_i, z_k)/\gamma\right)} \quad (1)$$

where sim(zi,zj) denotes cosine similarity between embeddings and τ is a temperature parameter. The overall SSL and transfer learning pipeline is illustrated in Fig. 2.

Transfer Learning and Fine-Tuning

After SSL pretraining, transfer learning was applied using labeled CT data. Lower convolutional layers were frozen, while upper layers and the linear classifier were fine-tuned with a learning rate of 1×10^{-4}using the Adam optimizer. Training was conducted with 5-fold cross-validation, ensuring patient-level separation between training and validation datasets.

Evaluation Metrics

Performance metrics included accuracy, precision, recall, F1-score, and AUC. All values were reported as mean ± standard deviation. Statistical significance was assessed using the paired t-test with a threshold of $P<0.05$.

RESULTS

A comparison of model performance across the three learning strategies is summarized in Table 1. The proposed SSL+TL model achieved superior performance, with an AUC of 0.95 ± 0.02 and an F1-score of 0.91 ± 0.03, significantly higher than both the random initialization model (AUC, 0.72 ± 0.04) and the TL-only model (AUC, 0.85 ± 0.03) ($P<0.05$). The receiver operating characteristic curves comparing the 3 learning strategies are shown in Fig. 3. These findings confirm that SSL pretraining enhances feature generalization even under limited

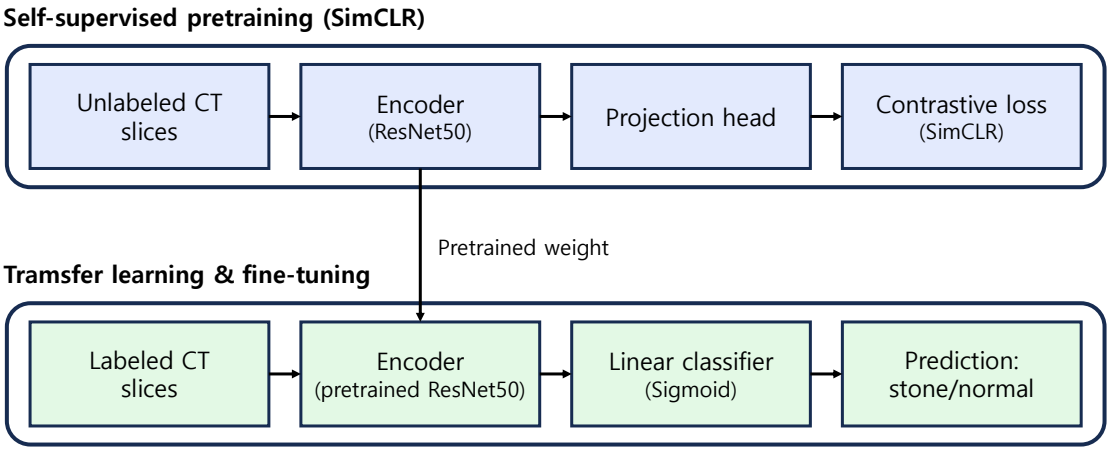

Fig. 2. Proposed self-supervised + transfer learning framework. CT, computed tomography.

Table 1. Comparison of model performance across learning strategies

Model	Accuracy	Precision	Recall	F1-score	AUC
Random initialization	0.74 ± 0.05	0.70 ± 0.04	0.68 ± 0.06	0.68 ± 0.06	0.72 ± 0.04
Transfer learning	0.86 ± 0.03	0.84 ± 0.03	0.87 ± 0.04	0.81 ± 0.04	0.85 ± 0.03
SSL+TL (proposed)	0.93 ± 0.02	0.90 ± 0.03	0.92 ± 0.02	0.91 ± 0.03	0.95 ± 0.02

AUC, area under the receiver operating characteristic curve; SSL, self-supervised learning; TL, transfer learning.

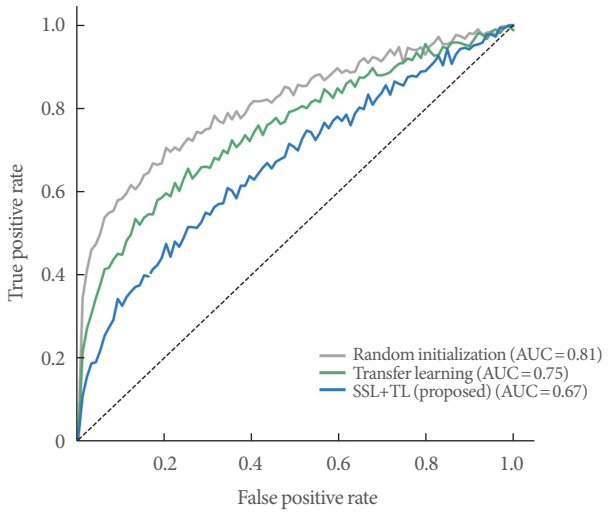

Fig. 3. Receiver operating characteristic (ROC) curves comparing random initialization, transfer learning, and SSL + TL models. AUC, area under the ROC curve; SSL, self-supervised learning; TL, transfer learning.

data conditions.

Training stability analysis indicated that the SSL+TL model converged within 30 epochs, exhibiting a steadily decreasing loss, whereas the TL-only model showed greater variance and trends toward overfitting. Cross-validation demonstrated consistent performance across folds (AUC, 0.93–0.97).

Feature representation analysis using t-distributed stochastic neighbor embedding revealed clear separation between normal and stone clusters in the SSL+TL model, whereas the random initialization and TL-only models showed substantial overlap (Fig. 4).

Misclassification analysis showed that most errors occurred in cases with very small stones (< 2 mm) or in high-density regions such as bowel gas and vascular calcifications, where similar intensity patterns led to confusion.

DISCUSSION

This study demonstrated that combining self-supervised and transfer learning enables robust urolithiasis detection from a small CT dataset. Unlike conventional supervised models that require large labeled datasets, the proposed SSL+TL framework effectively leveraged unlabeled data to pretrain meaningful feature representations.

The SSL+TL model achieved an AUC of 0.95 and an F1-score of 0.91, outperforming both baseline approaches. The

Fig. 4. Feature representation visualization (t-SNE). The SSL + TL model exhibits the clearest separation between normal (blue) and stone (red) samples. t-SNE, t-distributed stochastic neighbor embedding; SSL, self-supervised learning; TL, transfer learning.

pretraining phase allowed the model to learn morphological and contextual features of stones, facilitating efficient fine-tuning with limited labeled data. Consistent cross-validation results and faster convergence further indicate enhanced model stability and reduced overfitting.

From a clinical standpoint, this framework demonstrates that AI models can be feasibly developed even in data-limited environments such as small hospitals. SSL provides a data-efficient foundation for future extensions to tasks such as stone size and location analysis or other urological imaging applications.

Study limitations include the small dataset size, single-center design, and binary classification restricted to stone presence. Future research should incorporate multi-institutional datasets, evaluate advanced SSL variants (e.g., BYOL, MoCo), and validate the framework within real-world clinical workflows.

In conclusion, the proposed SSL+TL-based framework offers a practical and data-efficient solution for AI model development under data scarcity, presenting a promising direction for medical image analysis in urology.

AUTHOR CONTRIBUTION STATEMENT

· Conceptualization: *JSK,SJE*
· Data curation: *JSK*
· Formal analysis: *JSK*
· Methodology: *JSK, SJE*
· Project administration: *SJE*
· Visualization: *JSK*
· Writing - original draft: *JSK*
· Writing - review & editing: *JSK, SJE*

ORCID

Jae-Seoung Kim 0009-0006-9682-6131
Sung-Jong Eun 0000-0003-3063-0452

REFERENCES

1. Türk C, Petřík A, Sarica K, Seitz C, Skolarikos A, Straub M, et al. EAU guidelines on diagnosis and conservative management of urolithiasis. Eur Urol 2016;69:468-74.
2. Scales CD Jr, Smith AC, Hanley JM, Saigal CS; Urologic Diseases in America Project. Prevalence of kidney stones in the United States. Eur Urol 2012;62:160-5.
3. Rule AD, Lieske JC, Li X, Melton LJ 3rd, Krambeck AE, Bergstralh EJ. The ROKS nomogram for predicting a second symptomatic stone episode. J Am Soc Nephrol 2014;25:2878-86.
4. Kim JS, Lee DY, Seo BK, Park CH, Lee JH, Kang DH, et al. Deep learning for urolithiasis detection on computed tomography. Int Neurourol J 2023;27(Suppl 1):S21-6.
5. Tian X, Zhang X, Pan Y, Wang Y, Liu C, Li W, et al. Automatic detection of urinary stones using deep convolutional neural networks on unenhanced CT images. Eur Radiol 2022;32:5620-9.
6. Zhang G, Wu J, Liu X, Chen Z, Luo Q, Li Y, et al. Artificial intelligence-assisted CT detection and classification of urinary tract stones: a multicenter study. Front Med (Lausanne) 2023;10:1115634.
7. Tajbakhsh N, Jeyaseelan L, Li Q, Chiang JN, Wu Z, Ding X. Embracing imperfect datasets: a review of deep learning solutions for medical image segmentation. Med Image Anal 2020;63:101693.
8. Azizi S, Mustafa B, Ryan F, Beaver Z, Freyberg J, Deaton J, et al. Big self-supervised models advance medical image classification. Proc IEEE/CVF Int Conf Comput Vis 2021;2021:3478-88.
9. Chen T, Kornblith S, Norouzi M, Hinton G. A simple framework for contrastive learning of visual representations. Proc Mach Learn Res 2020;119:1597-607.
10. Chaitanya K, Erdil E, Karani N, Konukoglu E. Contrastive learning of global and local features for medical image segmentation with limited annotations. Adv Neural Inf Process Syst 2020;33:12546-58.