Abdominal Radiology (2024) 49:1987–1995
https://doi.org/10.1007/s00261-024-04223-w

KIDNEYS, URETERS, BLADDER, RETROPERITONEUM

Detection of urinary tract stones on submillisievert abdominopelvic CT imaging with deep-learning image reconstruction algorithm (DLIR)

Sarah Prod'homme[1] · Roger Bouzerar[2] · Thomas Forzini[3] · Aurélien Delabie[1] · Cédric Renard[1]

Received: 11 November 2023 / Revised: 23 January 2024 / Accepted: 24 January 2024 / Published online: 12 March 2024
© The Author(s), under exclusive licence to Springer Science+Business Media, LLC, part of Springer Nature 2024

Abstract

Purpose Urolithiasis is a chronic condition that leads to repeated CT scans throughout the patient's life. The goal was to assess the diagnostic performance and image quality of submillisievert abdominopelvic computed tomography (CT) using deep learning-based image reconstruction (DLIR) in urolithiasis.

Methods 57 patients with suspected urolithiasis underwent both non-contrast low-dose (LD) and ULD abdominopelvic CT. Raw image data of ULD CT were reconstructed using hybrid iterative reconstruction (ASIR-V 70%) and high-strength-level DLIR (DLIR-H). The performance of ULD CT for the detection of urinary stones was assessed by two readers and compared with LD CT with ASIR-V 70% as a reference standard. Image quality was assessed subjectively and objectively.

Results 266 stones were detected in 38 patients. Mean effective dose was 0.59 mSv for ULD CT and 1.96 mSv for LD CT. For diagnostic performance, sensitivity and specificity were 89% and 94%, respectively, for ULDCT with DLIR-H. There was an almost perfect intra-observer concordance on ULD CT with DLIR-H versus LDCT with ASIR-V 70% (ICC = 0.90 and 0.90 for the two readers). Image noise was significantly lower and signal-to-noise ratio significantly higher with DLIR-H compared to ASIR-V 70%. Subjective image quality was also significantly better with ULDCT with DLIR-H.

Conclusion ULD CT with Deep Learning Image Reconstruction maintains a good diagnostic performance in urolithiasis, with better image quality than hybrid iterative reconstruction and a significant radiation dose reduction.

✉ Cédric Renard
renard.cedric@chu-amiens.fr

Sarah Prod'homme
Prod'homme.Sarah@chu-amiens.fr

Roger Bouzerar
Bouzerar.Roger@chu-amiens.fr

Thomas Forzini
Forzini.Thomas@chu-amiens.fr

Aurélien Delabie
Delabie.Aurelien@chu-amiens.fr

1 Department of Radiology, Amiens University Hospital, 1 Rond-Point du Professeur Christian Cabrol, 80054 Amiens Cedex 01, France

2 Biophysics and Image Processing Unit, Amiens University Hospital, Amiens, France

3 Department of Urology and Transplantation, Amiens University Hospital, Amiens, France

Graphical abstract

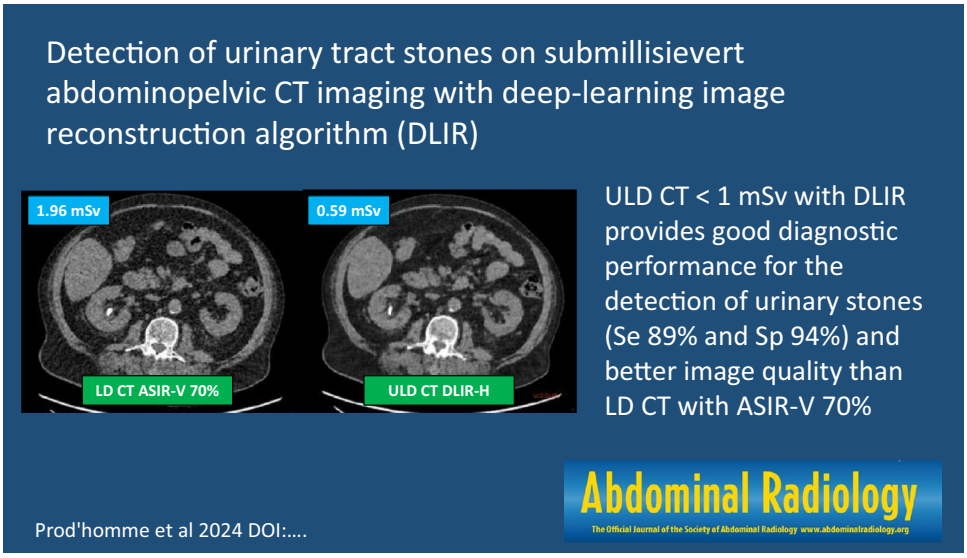

Keywords Urolithiasis · Deep learning · Image enhancement · Computed tomography · Radiation dose

Introduction

Urolithiasisis is a common health problem in Europe and the United States, due to its prevalence and repeated radiologic examinations. The most common expression of urolithiasis is renal colic [1]. Abdominopelvic computed tomography (CT) has become the reference standard as this technique provides excellent sensitivity (96%) and specificity (98%) for the diagnosis of urolithiasis [2]. It also allows the detection of possible complications such as hydronephrosis or obstructive pyelonephritis [3, 4].

Repeated CT may increase cumulative radiation exposure [5–7] and many efforts have been made to reduce this radiation exposure [8]. Urolithiasis is a chronic condition that leads to repeated CT scans throughout the patient's life. Some authors have shown that the radiation dose can be reduced below 3 mSv without affecting the diagnostic performance for the detection of urinary stones [9]. Low dose (LD) abdominopelvic CT (< 3 mSv) has become the reference standard for diagnosing urinary stones. However, decreasing the radiation dose leads to a significant increase in image noise, resulting in an alteration of image quality, which may hinder accurate interpretation. Iterative reconstructions (IR), developed to reduce image noise, allow dose reduction while maintaining diagnostic confidence but altering image texture. Several modes of IR algorithms have emerged including statistical IR, model-based IR or hybrid IR. Although model-based IR methods are very efficient, their deployment in routine clinical practice is not so straight forward because of the huge processing power required. Due to its fast processing time, Hybrid-IR algorithms such as ASIR-V are a good compromise between IR algorithm performance and daily practice constraints [10]. Nevertheless, IR algorithms are only efficient for the detection of urinary stones larger than 3 mm at ultra-low dose [11–14].

Recently, artificial intelligence techniques have been deployed to further improve image reconstruction algorithms. CT providers have designed deep learning networks to outperform existing model-based IR algorithms through robust supervised training. GE Healthcare's Deep Learning Image Reconstruction method (DLIR, TrueFidelity™) is based on a deep neural network trained on high quality Filtered Back-Projection (FBP) images from subjects or phantoms. This algorithm produces high quality images from LD CT sinograms with three selectable noise reduction levels (High -H, Medium -M, Low -L) [15, 16].

The aim of this study was to assess the diagnostic performance and image quality of unenhanced ultra-low dose (ULD) abdominopelvic CT using deep learning-based image reconstruction (DLIR) in urolithiasis compared to standard ASIR-V reconstruction.

Table 1 Baseline characteristics of the population

Patients ($n=57$)	
Male (n %)	35 (61.40%)
Female (n %)	22 (38.60%)
Age (y.o.)	53.8 ± 14.7 (20–84)
Weight (kg)	81.8 ± 20.9 (50–149)
Height (m)	1.70 ± 0.08 (1.48–1.86)
BMI (kg/m^2)	28.2 ± 7.2 (15.9–54.7)
< 20	4 (7.0%)
20–25	18 (31.6%)
25–30	17 (29.8%)
30–35	11 (19.3%)
35–40	1 (1.75%)
> 40	6 (10.5%)

Table 2 CT image acquisition parameters

	LDCT	ULDCT
Peak tube voltage (kVp)	100	100
Tube current (mA)	50–200	10–60
Noise index	30	50
Rotation time (s)	0.6	0.6
Collimation (mm)	40	40
Pitch	1.375	1.375
Reconstruction algorithm	ASIR-V 70%	ASIR V-70% and DLIR-H

LDCT low dose CT, *ULDCT* ultra-low dose CT

Materials and methods

Study population

This prospective, single-center, cross-sectional study was approved by the Committee for the Protection of Individuals *CPP EST I* (Dijon, France) on June 13, 2020 (ID-RCB: 2020-A01436-33).

Written informed consent was obtained from all patients. Fifty-seven patients referred for an abdominopelvic CT to confirm urolithiasis or for follow-up were included in the study: 35 men, 40 women, mean age = 53.8 ± 14.7 years, age range = 20–84 y.o. Full baseline patient demographics are summarized in Table 1.

Volume CT dose index (CTDIvol) and dose-length product (DLP) were recorded. Effective radiation dose (mSv) was calculated using a conversion factor of $k = 0.015$.

CT acquisition

All CT scans were performed using a 256-slice scanner (Revolution CT, GE Healthcare, Milwaukee, Wis). Patients who consented to participate in the study underwent both non-enhanced LD and ULD dose acquisitions in a supine position. The routine LDCT was performed at 100 kVp (kilovolt peak) with tube current adjusted according to the patient's weight (50–200 mA and a noise index of 30). ULD CT was performed immediately after, typically with an interval of less than 1 min (100 kVp, tube current 10–60 mA, and a noise index of 50). The scan range for both examinations extended from just above the dome of the diaphragm to just below the ischial tuberosities. Scanning parameters for LD and ULD CT acquisitions are summarized in Table 2. LD and ULD sinograms were both reconstructed using ASIR-V 70% algorithm and ULD with high-strength-level DLIR (DLIR-H) algorithm. All images were reconstructed with use of standard kernel and 0.625 mm slice thickness.

CT image analysis

All images were analyzed on a commercially available workstation (AWServer 3.2, GE Healthcare, Milwaukee, Wis) in native slice thickness (0.625 mm), with soft tissue windowing (Width 400 HU, Level 40 HU) for stone detection and bone windowing (Width 2000 HU, Level 500 HU) for stone measurement. The three reconstructed series (Standard LD CT in ASIR-V 70% as reference and ULD ASIR-V 70% and DLIR-H) were anonymized and randomized independently for each patient.

Quantitative and subjective analysis

Quantitative analysis of the three reconstructed series (LD ASIR-V 70%, ULD ASIR-V 70%, and ULD DLIR-H) was quantitatively assessed by a single reader with 5 years of experience in the interpretation of abdominal CT. Three identical regions of interest (ROI) of equal area (1 cm^2) were drawn at the same location on the 3 reconstructed series. These ROIs were placed on an axial image, in the parenchyma of the upper pole of the right kidney, in the spleen and in the bladder (Fig. 1). The 3 ROIs were copied and pasted on each reconstruction (LD CT ASIR-V 70%, ULD CT ASIR-V 70%, and DLIR-H). Minimum, maximum, mean attenuation, and standard deviation in Hounsfield units (HU) were recorded. The signal to noise ratio was then calculated using the mean attenuation and the standard deviation in each anatomical region.

Subjective image analysis was performed by two observers, with 6 and 5 years of experience in abdominal CT imaging, on both ULD CT reconstructions (DLIR-H and ASIR-V 70%). Diagnostic image quality was assessed using a visual scale ranging from 0 to 3: 0: not interpretable, 1: difficult with partial study of the urinary tract, 2: correct with almost

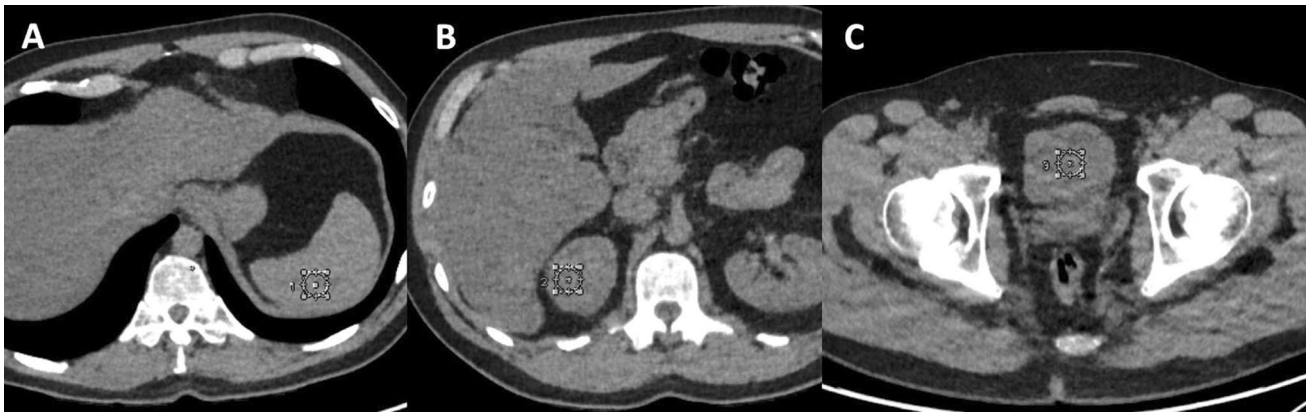

Fig. 1 Example of ROI drawings in the spleen (**A**), the kidney (**B**), and the bladder (**C**)

complete study of the urinary tract, 3: easy with perfect study of the urinary tract.

Detection of urinary stones

Urinary stones were interpreted on a per-lesion basis. The urinary tract has been divided into nine anatomical regions: the pyelocaliceal system, lumbar ureter, iliac ureter, pelvic ureter, bilaterally, and bladder. LD CT with ASIR-V 70% was defined as the reference and reviewed by a radiologist with 15 years of experience in urinary imaging. ULD CT with ASIR-V 70% and DLIR-H were reviewed by the two previous observers. Images were analyzed in two sessions, separated by one month. For each region the presence, number and size of urinary stones were recorded. The maximal size of each stone was measured in axial and coronal planes using the same window (W 2000, L 500). An example of axial slices for the three reconstruction algorithms is depicted in Fig. 2.

Sensitivity, specificity, negative predictive value and positive predictive value were calculated according to the presence or absence of stone per patient, location and size.

Statistical analysis

Statistical analysis was performed using R software (R Core Team, http://www.R-project.org). Descriptive statistics were expressed as absolute value, percentage or mean ± SD and range. A non-parametric Wilcoxon test was performed to compare the numeric variables. In order to assess the detection performance of observers against the reference, the intraclass correlation coefficient (ICC) was used. ICC values were interpreted as follows: poor reliability (< 0.20); fair (0.20–0.39); moderate (0.40–0.59); substantial (0.60–0.79); almost perfect (0.80–1). The p-value threshold for statistical significance was 5%.

Results

Radiation dose

The mean DLP was 39.7 ± 9.8 mGy.cm and 130.9 ± 32.2 mGy.cm for ULD CT and LD CT, respectively. This corresponds to an estimated mean effective dose of 0.59 and 1.96 mSv, respectively (Table 3).

Detection

From the reference series (LD CT ASIR-V 70%), 266 stones including 255 pyelocaliceal stones, 10 ureteric stones, and 1 bladder stone were detected. The distribution of stones in the population was as follows: 0 stone: $n = 19$ (33.3%), 1–2 stones: $n = 17$ (29.8%), 3–4 stones: $n = 11$ (19.3%), 5 à 8 stones: $n = 3$ (5.3%), > 20 stones: $n = 7$ (12.3%).

For the detection performance of ULD CT, regardless of stone size and location, DLIR sensitivities were 89 and 84% for observer 1 and 2, respectively, whereas ASIR-V sensitivities were 78 and 84%, respectively (Table 4). For the detection of all urinary stones using DLIR reconstruction, an almost perfect intra-observer agreement (ICC = 0.90) was observed for both observers. This trend was similar using ASIR-V (ICC = 0.91 and 0.95 for observer 1 and 2, respectively).

For kidney stones, sensitivity was higher with DLIR than ASIR-V for the first observer (86 and 72%, respectively) whereas similar performance was observed for the second observer (75%). For ureteral stones, the gap between DLIR and ASIR-V methods is more obvious for both the first (77% and 33%, respectively) and second observer (71 and 55%, respectively).

Using DLIR algorithm, the detection of stones larger than 3 mm was more accurate (ICC = 0.89 for the two observers) than the detection of smaller stones (ICC = 0.67 and 0.84 for observer 1 and 2, respectively).

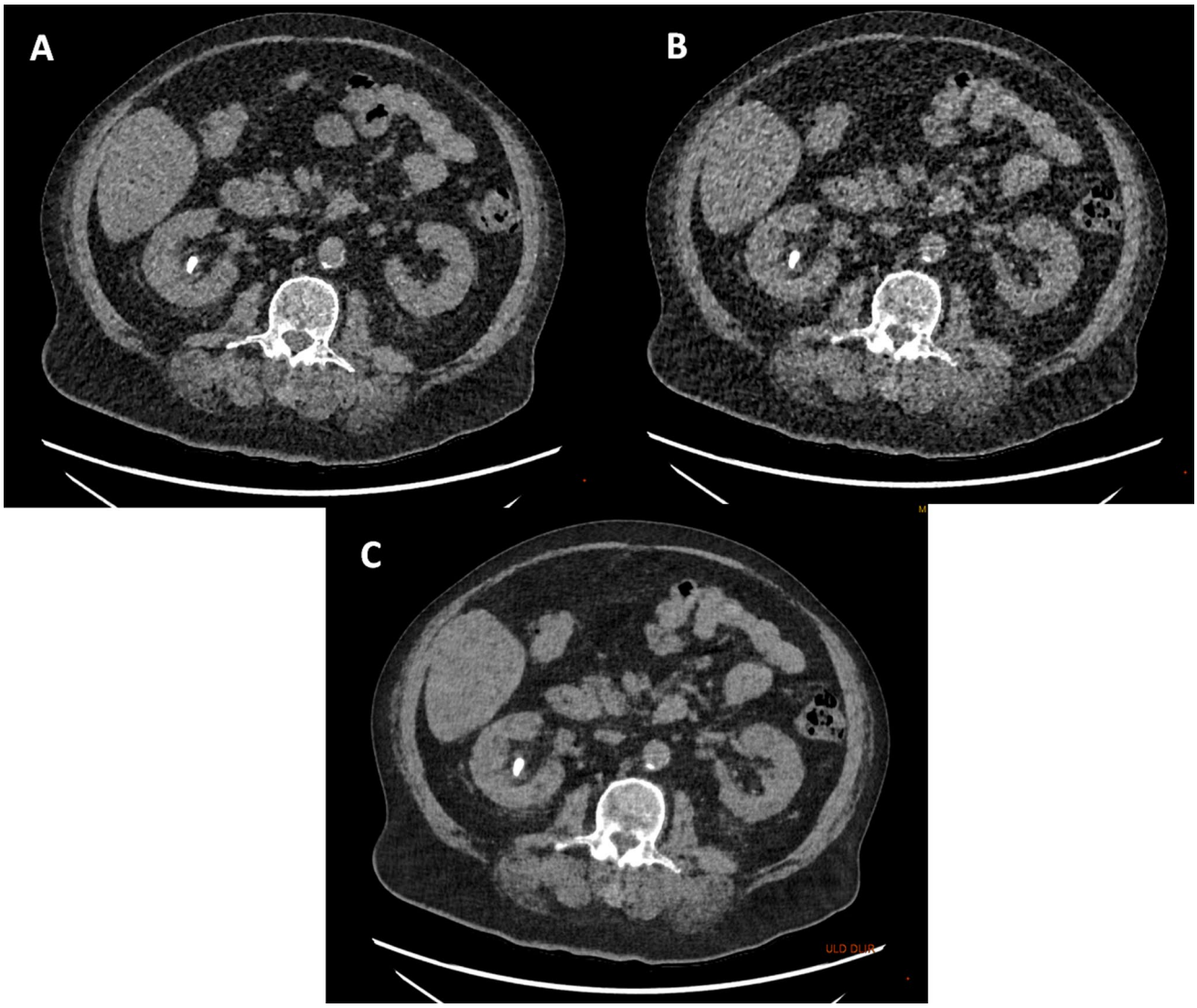

Fig. 2 81-Year-old man monitored for a 12-mm stone in the right kidney. Axial 0.625 mm slice thickness images: LD ASIR-V 70% (**A**), ULD ASIR-V 70% (**B**), and ULD DLIR-H (**C**) reconstructions

Table 3 Radiation dose measurements at low dose and ultra-low dose

Radiation doses	LD	ULD
CTDIvol (mGy)	2.65 ± 0.58 (1.2–3.52)	0.80 ± 0.16 (0.48–1.1)
DLP (mGy.cm)	130.9 ± 32.3 (64.0–192)	39.7 ± 9.8 (20.8–64.9)
Effective dose (mSv)	1.96 ± 0.48 (0.96–2.88)	0.59 ± 0.14 (0.31–0.97)

CTDIvol volumetric CT dose index, *DLP* dose-length product

Table 4 Diagnostic performance of ULDCT with DLIR-H and ASIR-V 70%

	DLIR-H		ASIR-V 70%	
	Obs. 1	Obs. 2	Obs. 1	Obs. 2
Sensitivity %	89.5	84.2	78.9	84.2
Specificity %	94.7	100	100	100
PPV %	97.1	100	100	100
NPV %	81.8	76.0	70.7	76.0

Quantitative and subjective analysis

Quantitative assessment of image quality showed that noise was significantly lower at ULD with DLIR reconstruction compared to LD and ULD with ASIR-V reconstruction (Table 5). When compared to ULD with ASIR-V reconstruction, we observed a 44% noise reduction in the spleen when using ULD with DLIR-H reconstruction (33.9 HU

Table 5 Attenuation, noise and signal to noise ratio for each reconstruction algorithm at 3 anatomical levels

	Spleen	Kidney	Bladder
LD ASIR-V 70%			
Attenuation (HU)	54.5	37.9	18.0
SD (HU)	25.4	25.1	29.4
SNR	2.20	1.50	0.62
ULD ASIR-V 70%			
Attenuation (HU)	54.1	34.6	19.7
SD (HU)	33.9	34.6	39.1
SNR	1.64	1.04	0.50
ULD DLIR-H			
Attenuation (HU)	54.2	35.9	21.3
SD (HU)	19.1	21.2	23.7
SNR	2.93	1.78	0.91

vs 19.1 HU, $p < 10^{-4}$). Similar significant decreases were observed in the kidney (39%, $p < 10^{-4}$) and in the bladder (40%, $p < 10^{-4}$). Noise was also significantly lower in ULD with DLIR-H reconstruction compared to LD with ASIR-V reconstruction (Fig. 3).

SNR was significantly improved with ULD with DLIR-H reconstruction compared to LD and ULD with ASIR-V reconstruction for all anatomical regions explored (Fig. 4).

Both readers rated image quality as significantly higher with DLIR-H reconstruction (1.68 and 1.57, respectively) compared to ASIR-V 70% reconstruction (1.36 and 1.33, respectively) on ULD CT images.

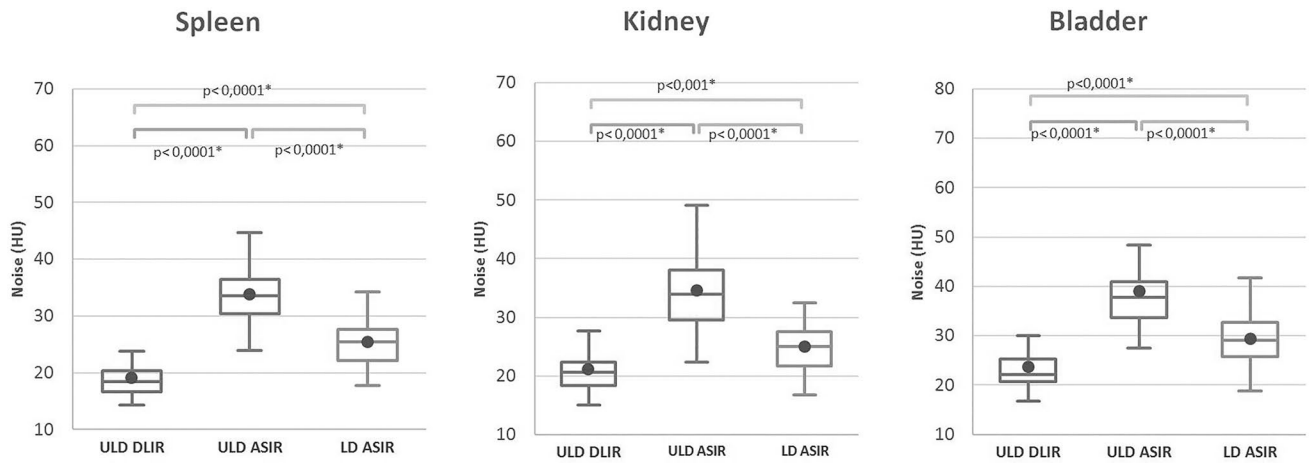

Fig. 3 Noise measurements in the spleen, the kidney, and the bladder for the three reconstruction techniques (ULD DLIR-H, ULD ASIR-V 70%, and LD ASIR-V 70%)

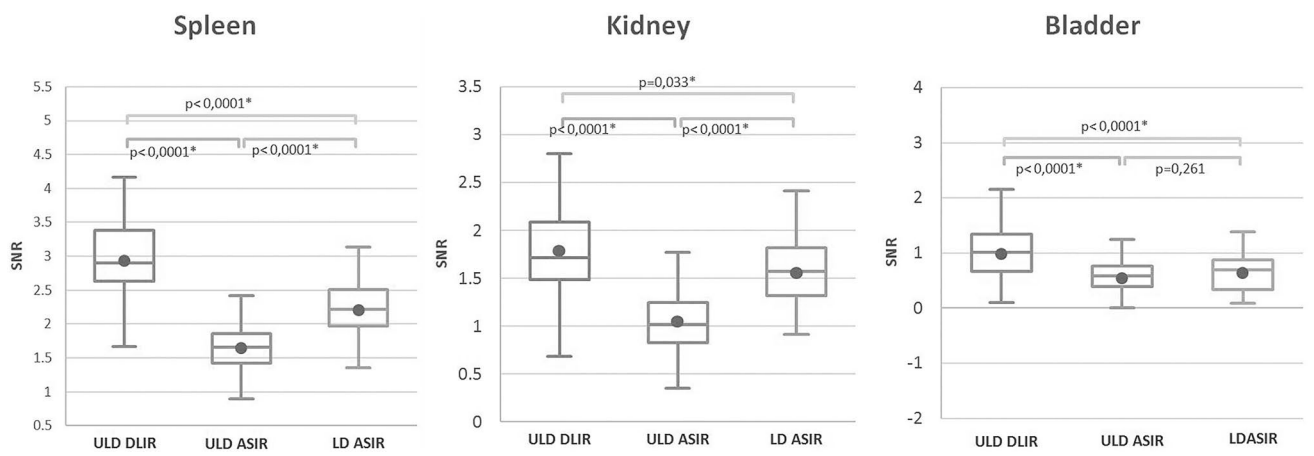

Fig. 4 Signal to Noise Ratio (SNR) in the spleen, the kidney, and the bladder for the three reconstruction techniques (ULD DLIR-H, ULD ASIR-V 70%, and LD ASIR-V 70%)

Discussion

In this study, we aimed to investigate the diagnostic performance and image quality of unenhanced abdominopelvic submillisievert ULD CT with deep learning-based image reconstruction in patients referred to confirm or follow-up urolithiasis. Low-dose abdominopelvic computed tomography (< 3 mSv) has become the reference standard for detecting urolithiasis and detecting alternative diagnoses in the evaluation of acute flank pain [17–19]. ULD CT acquisitions allow a substantial reduction in radiation dose, which is essential because many patients with urinary stones are young and often have recurrent kidney or ureteral calculi requiring repeated diagnostic examinations. In our study, the mean effective doses of ULD and LD CT were 0.59 and 1.96 mSv, respectively. Although both CT acquisitions covered the entire abdominopelvic region, all patients received an effective dose of less than 1 mSv at ULD CT. Despite the significant dose reduction achieved with ULD CT, the diagnostic performance of the DLIR algorithm was excellent (sensitivity 84–89% and specificity 94–100%, on a per-stone basis). In a meta-analysis of the diagnostic performance of LD and ULD CT for the detection of urinary calculi, Rodger et al. [20] observed mean effective doses ranging from 0.48 to 1.9 mSv for ULD CT and from 2.1 to 4.5 mSv for LD CT with CT acquisitions covering only the urinary system in most studies. The sensitivity ranged from 72 to 99% and the specificity ranged from 86 to 100% for the detection of urinary stones at ULD CT, on a per-patient basis, and from 90 to 98% and 88 to 100%, respectively, at LD CT. However, ULD and LD CT may not be as effective at detecting stones < 3 mm in size or in patients with a BMI > 30 kg/m^2 [21]. The performance of iterative reconstruction algorithms has improved in recent years, from statistical-based to model-based iterative algorithms. Shim et al. [22] evaluated the diagnostic performance and image quality of submillisievert CT using a model-based iterative reconstruction algorithm (ADMIRE, Siemens Healthcare, Forchheim, Germany) with spectral filtration for the detection of urolithiasis. The mean effective dose delivered by ULD CT was 0.3 mSv, with all examinations < 0.5 mSv. The overall sensitivity was 74.9%, with excellent agreement between observers. For urinary stones larger than 3 mm, the sensitivity reached 95.1%. The authors demonstrated better detection performance in the ureters than in the kidneys (sensitivity of 91.7% and 70.5%, respectively). In our study, detection was better in the kidneys than in the ureters, but very few stones were observed in the latter anatomical area.

Although very effective at reducing image noise, iterative reconstructions have been criticized for altering CT images by giving them a "plastic" texture [23]. DLIR reconstruction provides more natural textures to images, probably because deep learning-based algorithms are generated by training an artificial neural network with high-dose images as input [15, 24–26]. In the present study, objective image quality analysis showed the superiority of the DLIR reconstruction at ULD CT over the ASIR-V 70% algorithm at both LD and ULD CT. Regardless of anatomical structures, there was a significant decrease in noise (~ 40%) and increase in SNR (~ 80%) with DLIR-H reconstructions compared to ASIR-V 70% reconstructions on ULD CT images. These results are consistent with the findings of phantom studies, which showed that noise was significantly lower with deep learning-based reconstructions than with FBP, hybrid iterative and MBIR reconstructions, particularly at low radiation dose [24, 27]. In a previous study investigating LD CT with DLIR in urolithiasis, Delabie et al. demonstrated that both signal-to-noise and contrast-to-noise ratios were significantly higher with DLIR than with FBP and hybrid iterative reconstructions [28].

Deep learning-based image reconstructions have also been developed by other CT manufacturers and evaluated in abdominal CT imaging. Zhang et al. [29] recently investigated urinary stone detection on LD CT images using another deep learning-based image reconstruction algorithm (Advanced Intelligent Clear-IQ Engine (AiCE), Canon Medical Systems). They found that the detectability of urinary stones was excellent and slightly better than in our study using ULD CT both with hybrid iterative reconstruction (95.9%) and deep learning-based reconstruction (96.6%) compared to LD CT with hybrid iterative reconstruction. Nevertheless, in that study, the mean effective dose was much higher than in our study, for both LD CT (5.49 ± 1.00 vs 1.96 ± 0.48 mSv) and ULD CT (1.28 ± 0.34 vs 0.59 ± 0.14 mSv) CT acquisitions. Previously, Singh et al. [30] compared image quality with the use of the same algorithm on submillisievert chest and abdominal CT with FBP, iterative (AIDR 3D, Canon Medical Systems) and model-based iterative (FIRST, Canon Medical Systems) reconstructions for various clinical indications. Deep learning-based image reconstruction had lower image noise and a higher signal-to-noise ratio compared to all other image reconstruction methods. Moreover, DLR images received superior subjective ratings across all observers compared to iterative reconstructions. In our study, both subjective and objective ratings were better with Deep learning-based image reconstruction than with iterative reconstruction.

Our study is subject to several limitations, mainly related to the small size of the population. According to the design of the present study, a larger population was targeted, but some eligible patients did not wish to undergo a second CT acquisition, even though the additional

radiation dose was low. However, our sample size was similar to that of studies investigating ULD CT with deep learning-based image reconstruction in urolithiasis [29]. We also did not consider the influence of BMI, which can affect urinary stone detection performance. Finally, we used LD CT as a reference standard, without using clinical or follow-up data to assess urolithiasis. However, LD-CT is generally accepted as the gold standard for the assessment of urinary stones.

In conclusion, the use of deep learning-based image reconstruction (DLIR) maintains good diagnostic performance at ultra-low dose CT scans while significantly reducing radiation exposure. In addition, compared with hybrid iterative reconstructions, DLIR improves objective and subjective image quality for both low and ultra-low dose acquisitions.

Funding This research did not receive any specific grant from funding agencies in the public, commercial, or not-for-profit sectors.

Declarations

Conflict of interest The authors declare that they have no known competing financial interests or personal relationships that could have appeared to influence the work reported in this paper.

Ethical approval The study was approved by the Committee for the Protection of Individuals *CPP EST I* (Dijon, France) on June 13, 2020 (ID-RCB: 2020-A01436-33).

Informed consent Written informed consent was obtained from all patients.

References

1. Carpentier X, Traxer O, Lechevallier E, Saussine C (2008) [Physiopathology of acute renal colic]. Progres En Urol J Assoc Francaise Urol Soc Francaise Urol 18:844–848. https://doi.org/10.1016/j.purol.2008.09.023
2. Wright PJ, English PJ, Hungin APS, Marsden SNE (2002) Managing acute renal colic across the primary-secondary care interface: a pathway of care based on evidence and consensus. BMJ 325:1408–1412. https://doi.org/10.1136/bmj.325.7377.1408
3. Fielding JR, Fox LA, Heller H et al (1997) Spiral CT in the evaluation of flank pain: overall accuracy and feature analysis. J Comput Assist Tomogr 21:635–638. https://doi.org/10.1097/00004728-199707000-00022
4. Smith RC, Verga M, Dalrymple N, McCarthy S, Rosenfield AT (1996) Acute ureteral obstruction: value of secondary signs of helical unenhanced CT. AJR Am J Roentgenol 167:1109–1113. https://doi.org/10.2214/ajr.167.5.8911160
5. Hall EJ, Brenner DJ (2012) Cancer risks from diagnostic radiology: the impact of new epidemiological data. Br J Radiol 85:e1316-1317. https://doi.org/10.1259/bjr/13739950
6. Brenner DJ, Hall EJ (2012) Cancer risks from CT scans: now we have data, what next? Radiology 265:330–331. https://doi.org/10.1148/radiol.12121248
7. Brenner DJ, Hall EJ (2007) Computed tomography--an increasing source of radiation exposure. N Engl J Med 357:2277–2284. https://doi.org/10.1056/NEJMra072149
8. Khawaja RDA, Singh S, Blake M et al (2015) Ultra-low dose abdominal MDCT: using a knowledge-based Iterative Model Reconstruction technique for substantial dose reduction in a prospective clinical study. Eur J Radiol 84:2–10. https://doi.org/10.1016/j.ejrad.2014.09.022
9. Niemann T, Kollmann T, Bongartz G (2008) Diagnostic performance of low-dose CT for the detection of urolithiasis: a meta-analysis. AJR Am J Roentgenol 191:396–401. https://doi.org/10.2214/AJR.07.3414
10. De Marco P, Origgi D (2018) New adaptive statistical iterative reconstruction ASiR-V: assessment of noise performance in comparison to ASiR. J Appl Clin Med Phys 19:275–286. https://doi.org/10.1002/acm2.12253
11. Glazer DI, Maturen KE, Cohan RH et al (2014) Assessment of 1 mSv urinary tract stone CT with model-based iterative reconstruction. AJR Am J Roentgenol 203:1230–1235. https://doi.org/10.2214/AJR.13.12271
12. Hur J, Park SB, Lee JB et al (2015) CT for evaluation of urolithiasis: image quality of ultralow-dose (Sub mSv) CT with knowledge-based iterative reconstruction and diagnostic performance of low-dose CT with statistical iterative reconstruction. Abdom Imaging 40:2432–2440. https://doi.org/10.1007/s00261-015-0411-2
13. Park SB, Kim YS, Lee JB, Park HJ (2015) Knowledge-based iterative model reconstruction (IMR) algorithm in ultralow-dose CT for evaluation of urolithiasis: evaluation of radiation dose reduction, image quality, and diagnostic performance. Abdom Imaging 40:3137–3146. https://doi.org/10.1007/s00261-015-0504-y
14. Pooler BD, Lubner MG, Kim DH et al (2014) Prospective trial of the detection of urolithiasis on ultralow dose (sub mSv) noncontrast computerized tomography: direct comparison against routine low dose reference standard. J Urol 192:1433–1439. https://doi.org/10.1016/j.juro.2014.05.089
15. Hsieh J, Liu E, Nett B, Tang J, Thibault J-B, Sahney S (2019) A new era of image reconstruction: TrueFidelity™. Technical white paper on deep learning image reconstruction. https://www.gehealthcare.com/-/jssmedia/040dd213fa89463287155151fdb01922.pdf. Accessed 21 Jan 2024
16. Greffier J, Hamard A, Pereira F et al (2020) Image quality and dose reduction opportunity of deep learning image reconstruction algorithm for CT: a phantom study. Eur Radiol 30:3951–3959. https://doi.org/10.1007/s00330-020-06724-w
17. Hamm M, Knopfle E, Wartenberg S, Wawroschek F, Weckermann D, Harzmann R (2002) Low dose unenhanced helical computerized tomography for the evaluation of acute flank pain. J Urol 167:1687–1691. https://doi.org/10.1016/S0022-5347(05)65178-6
18. Türk C, Petřík A, Sarica K et al (2016) EAU guidelines on diagnosis and conservative management of urolithiasis. Eur Urol 69:468–474. https://doi.org/10.1016/j.eururo.2015.07.040
19. Expert Panel on Urological Imaging, Gupta RT, Kalisz K, et al (2023) ACR appropriateness criteria® acute onset flank pain-suspicion of stone disease (urolithiasis). J Am Coll Radiol JACR 20:S315–S328. https://doi.org/10.1016/j.jacr.2023.08.020
20. Rodger F, Roditi G, Aboumarzouk OM (2018) Diagnostic accuracy of low and ultra-low dose CT for identification of urinary tract stones: a systematic review. Urol Int 100:375–385. https://doi.org/10.1159/000488062
21. Rob S, Bryant T, Wilson I, Somani BK (2017) Ultra-low-dose, low-dose, and standard-dose CT of the kidney, ureters, and bladder: is there a difference? Results from a systematic review of the literature. Clin Radiol 72:11–15. https://doi.org/10.1016/j.crad.2016.10.005

22. Shim YS, Park SH, Choi SJ et al (2020) Comparison of submillisievert CT with standard-dose CT for urolithiasis. Acta Radiol Stockh Swed 1987 61:1105–1115. https://doi.org/10.1177/0284185119890088
23. McCollough CH, Yu L, Kofler JM et al (2015) Degradation of CT low-contrast spatial resolution due to the use of iterative reconstruction and reduced dose levels. Radiology 276:499–506. https://doi.org/10.1148/radiol.15142047
24. Higaki T, Nakamura Y, Zhou J et al (2020) Deep learning reconstruction at CT: phantom study of the image characteristics. Acad Radiol 27:82–87. https://doi.org/10.1016/j.acra.2019.09.008
25. Park C, Choo KS, Jung Y, Jeong HS, Hwang J-Y, Yun MS (2021) CT iterative vs deep learning reconstruction: comparison of noise and sharpness. Eur Radiol 31:3156–3164. https://doi.org/10.1007/s00330-020-07358-8
26. Akagi M, Nakamura Y, Higaki T et al (2019) Deep learning reconstruction improves image quality of abdominal ultra-high-resolution CT. Eur Radiol 29:6163–6171. https://doi.org/10.1007/s00330-019-06170-3
27. Solomon J, Lyu P, Marin D, Samei E (2020) Noise and spatial resolution properties of a commercially available deep learning-based CT reconstruction algorithm. Med Phys 47:3961–3971. https://doi.org/10.1002/mp.14319
28. Delabie A, Bouzerar R, Pichois R, Desdoit X, Vial J, Renard C (2022) Diagnostic performance and image quality of deep learning image reconstruction (DLIR) on unenhanced low-dose abdominal CT for urolithiasis. Acta Radiol Stockh Swed 1987 63:1283–1292. https://doi.org/10.1177/02841851211035896
29. Zhang G, Zhang X, Xu L et al (2022) Value of deep learning reconstruction at ultra-low-dose CT for evaluation of urolithiasis. Eur Radiol 32:5954–5963. https://doi.org/10.1007/s00330-022-08739-x
30. Singh R, Digumarthy SR, Muse VV et al (2020) Image quality and lesion detection on deep learning reconstruction and iterative reconstruction of submillisievert chest and abdominal CT. AJR Am J Roentgenol 214:566–573. https://doi.org/10.2214/AJR.19.21809

Publisher's Note Springer Nature remains neutral with regard to jurisdictional claims in published maps and institutional affiliations.

Springer Nature or its licensor (e.g. a society or other partner) holds exclusive rights to this article under a publishing agreement with the author(s) or other rightsholder(s); author self-archiving of the accepted manuscript version of this article is solely governed by the terms of such publishing agreement and applicable law.