Abdominal Radiology (2026) 51:424–445
https://doi.org/10.1007/s00261-025-05031-6

REVIEW

Artificial intelligence (AI) and CT in abdominal imaging: image reconstruction and beyond

Nisanard Pisuchpen[1,2] · Shravya Srinivas Rao[1] · Yoshifumi Noda[1,3] · Sasiprang Kongboonvijit[1,2] · Abbas Rezaei[1] · Avinash Kambadakone[1]

Received: 10 February 2025 / Revised: 19 May 2025 / Accepted: 21 May 2025 / Published online: 16 June 2025
© The Author(s), under exclusive licence to Springer Science+Business Media, LLC, part of Springer Nature 2025

Abstract

Computed tomography (CT) is a cornerstone of abdominal imaging, playing a vital role in accurate diagnosis, appropriate treatment planning, and disease monitoring. The evolution of artificial intelligence (AI) in imaging has introduced deep learning-based reconstruction (DLR) techniques that enhance image quality, reduce radiation dose, and improve workflow efficiency. Traditional image reconstruction methods, including filtered back projection (FBP) and iterative reconstruction (IR), have limitations such as high noise levels and artificial image texture. DLR overcomes these challenges by leveraging convolutional neural networks to generate high-fidelity images while preserving anatomical details. Recent advances in vendor-specific and vendor-agnostic DLR algorithms, such as TrueFidelity, AiCE, and Precise Image, have demonstrated significant improvements in contrast-to-noise ratio, lesion detection, and diagnostic confidence across various abdominal organs, including the liver, pancreas, and kidneys. Furthermore, AI extends beyond image reconstruction to applications such as low contrast lesion detection, quantitative imaging, and workflow optimization, augmenting radiologists' efficiency and diagnostic accuracy. However, challenges remain in clinical validation, standardization, and widespread adoption. This review explores the principles, advancements, and future directions of AI-driven CT image reconstruction and its expanding role in abdominal imaging.

✉ Avinash Kambadakone
akambadakone@mgh.harvard.edu

Nisanard Pisuchpen
nisanard.p@chula.ac.th

Shravya Srinivas Rao
ssrinivasrao@mgh.harvard.edu

Yoshifumi Noda
ynoda@mgh.harvard.edu

Sasiprang Kongboonvijit
sasiprangk@gmail.com

Abbas Rezaei
arezaei1@mgh.harvard.edu

[1] Abdominal Radiology Division, Department of Radiology, Massachusetts General Hospital, Harvard Medical School, White 270, 55 Fruit Street, Boston 02114, MA, United States

[2] Department of Radiology, Faculty of Medicine, King Chulalongkorn Memorial Hospital, Thai Red Cross Society, Chulalongkorn University, 1873, Rama 4 Road, 10330 Bangkok, Thailand

[3] Department of Radiology, Gifu University, 1-1, Yanagido, 501-1194 Gifu, Japan

Abbreviations

AI	Artificial intelligence
AiCE	Advanced Intelligent Clear-IQ Engine
ASiR-V	Adaptive statistical iterative reconstruction-V
BMI	Body mass index
CAD	Computer-aided diagnosis
CNN	Convolutional neural network
CNR	Contrast-to-noise ratio
CT	Computed tomography
DECT	Dual energy CT
DLLD	Deep learning-based lesion detection algorithm
DLIR	Deep learning-based image reconstruction
DLR	Deep learning-based reconstruction
FBP	Filtered back projection
FCN	Fully convolutional network
FDA	Food and Drug Administration
IR	Iterative reconstruction
MBIR	Model-based iterative reconstruction
PIQE	Precise IQ Engine
SR-DLR	Super-Resolution DLR
SNR	Signal-to-noise ratio

Introduction

Computed tomography (CT), one of the most novel medical breakthroughs, is an important diagnostic tool that plays a critical role in day-to-day clinical practice, impacting patient management with a wide range of clinical applications. Its role in abdominal imaging is particularly significant given the gamut of organs and pathologies within the abdomen. While it plays an important role in management, generation of CT images after scanning involves a multi-step process. CT workflow in a busy imaging practice ranges from patient preparation, scanning and acquisition, image reconstruction, post-processing, image interpretation and reporting. These processes are interdependent, requiring manual and automated steps with involvement of CT technologists, managers, nursing staff, radiologists, and physicists. The multi-step process also provide opportunities for innovation to enhance efficiency, reduce waiting time, improve image quality, and reduce radiation exposure.

The introduction of artificial intelligence (AI) in imaging in the past decade has gradually gained popularity due to its potential to enhance workflow efficiency, improve image quality, and reduce workload. AI is a broad term and refers to developing computer systems capable of doing activities that typically necessitate human intelligence. Machine learning is a subset of AI where computers are trained to perform tasks by learning patterns from data without direct programming. Deep learning is a form of machine learning that uses algorithms based on multilayer neural networks to transform input data into valuable output, from which the algorithm can learn the features throughout the training process. Among the various deep learning approaches, convolutional neural networks (CNNs) are most often used for imaging-based data due to their ability to process spatial information effectively [1–3]. This narrative review describes the current applications of AI in abdominal CT, particularly focusing on deep learning-based image reconstruction algorithms [1, 2]. As with all narrative reviews, potential selection biases should be acknowledged, including a tendency to preference studies published in high-impact journals or those with greater visibility in literature.

Deep learning-based CT image reconstruction

Basics of CT image reconstruction

Advanced image processing and reconstruction techniques transform raw projection data obtained after CT scanning and data acquisition into diagnostically useful images [4]. Three main types of reconstruction methods employed currently in practice include analytical reconstruction, iterative reconstruction (IR), and deep learning-based reconstruction (DLR). Analytical reconstruction methods include filtered back projection (FBP), Feldkamp algorithm (FDK) and Katsevich algorithm. Among them, FBP has conventionally been the most commonly used reconstruction technique and involves the use of a convolutional filter in projection space to obtain the final image. Here, projection data (sinograms) are filtered by a high-pass convolutional filter and subsequently backward-projected into the image domain. However, high radiation dose and increased noise at low dose techniques are the two main disadvantages of FBP. FBP has been a widely used reconstruction technique for decades before the initial IR technique was clinically available in 2009 [5].

Iterative reconstruction techniques allow for substantial radiation dose reduction by reducing noise during CT image processing, thereby improving image quality [6, 7]. In IR, following the CT acquisition process, a first image estimate is generated. An X-ray beam is simulated via forward projection to obtain simulated projection data. The first image estimate is updated based on simulated projection by the underlying algorithm. This process is repeated until the final image is generated. One key component of IR is an image space regularization (or an iterative image filter), which reduces noise while preserving resolution. Nevertheless, this regularization step can also create artificial noise textures as a tradeoff. IR allows for the reduction of image noise, lower radiation dose, improved spatial resolution and artifact reduction. However, significant reduction of image noise led the images to appear too plasticky or pixelated [8].

Deep learning-based reconstruction methods

Deep learning-based reconstruction is a novel image reconstruction method introduced to further improve image quality, reduce image noise and diminish negative image texture (Fig. 1) [3]. A core component of DLR model development is the setting and tuning network structure, number of layers, and activation function. However, it is equally important and sometimes more crucial to carefully design the right training pairs, i.e., the input and ground truth images. The choice of training data is critical to ensure that the model generalizes well across a wide range of clinical protocols, with varying dose levels, patient sizes, and scanner settings. Training data curation is key to the generalizability and robustness of DLR. This network undergoes training, validation, and testing phases, typically using low-dose CT data as input and matched to routine or higher-dose CT data as the ground truth image [9]. Two main categories of DLR methods include indirect and direct DLR algorithms (Fig. 2), differentiating by their use of FBP or IR [9]. Direct

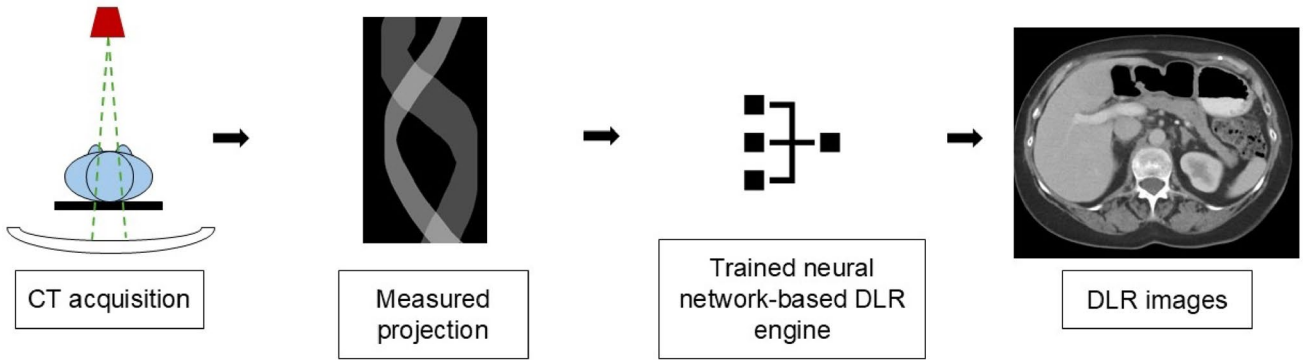

Fig. 1 Deep learning image reconstruction (DLR) method. Following the CT acquisition process, a first image estimate is generated. Final DLR CT images are obtained after processing through a trained neural network-based DLR engine

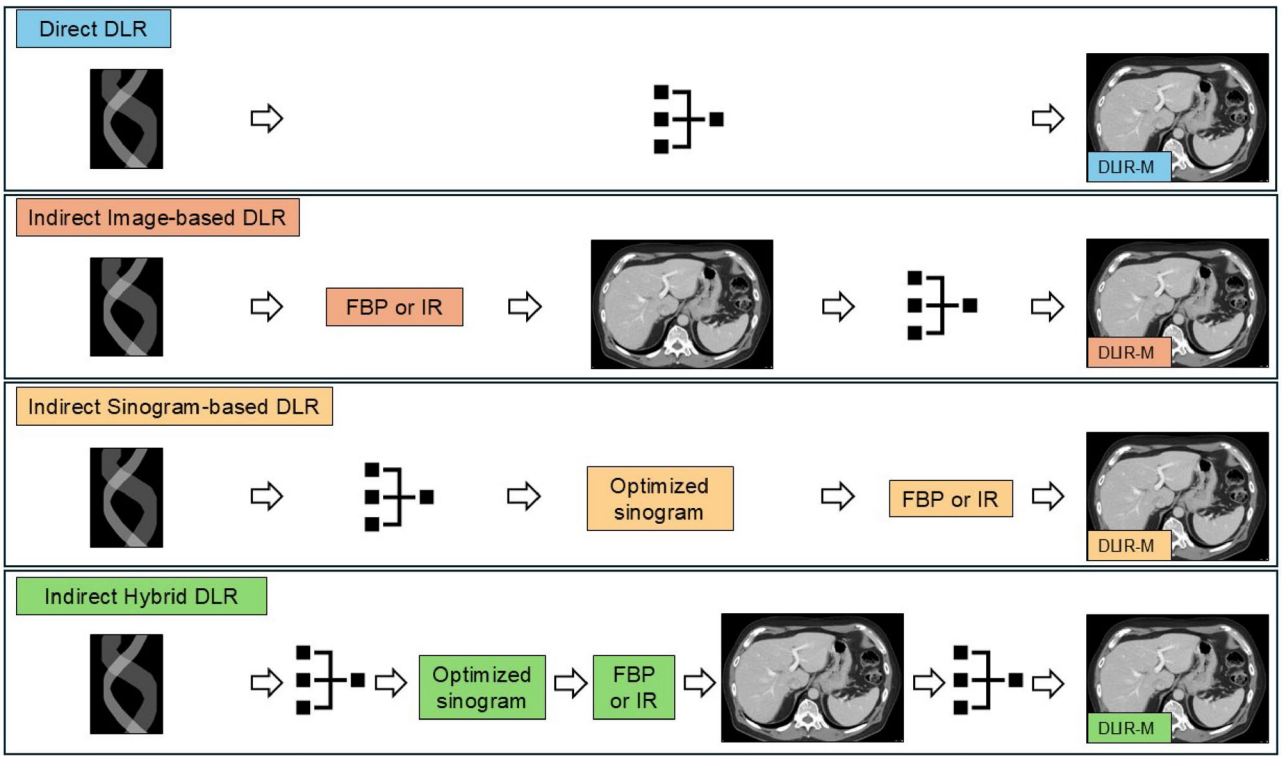

Fig. 2 Schematic diagrams demonstrate types of deep learning-based reconstruction (DLR) methods. Direct DLR algorithms convert the sinogram directly into an image, bypassing the need for filtered back projection (FBP) or iterative reconstruction (IR). Indirect DLR algorithms incorporate either FBP or IR. For indirect image-based DLR, an image was initially reconstructed using FBP or IR and then optimized by the network. In indirect sinogram-based DLR the network optimizes the sinogram before reconstruction with FBP or IR. Indirect hybrid DLR integrates both sinogram and image optimization. Adapted from Koetzier LR, Mastrodicasa D, Szczykutowicz TP, et al. (2023) Deep Learning Image Reconstruction for CT: Technical Principles and Clinical Prospects. Radiology 306:e221257

DLR algorithms convert the sinogram directly into an image, bypassing the need for FBP or IR. These algorithms may diminish artifacts typically generated by FBP or IR, but their effectiveness depends on training the model with ground truth images free from such artifacts. An example of direct DLR is FBPConvnet [10]. Indirect DLR algorithms incorporate either FBP or IR. They are categorized into three types (sinogram-based, image-based and hybrid algorithms) based on when the deep learning network is applied during the CT reconstruction process. In sinogram-based algorithms, the network optimizes the sinogram before reconstruction with FBP or IR. For image-based algorithms, an image was initially reconstructed using FBP or IR, and then optimized by the network. The hybrid algorithm integrates both sinogram and image optimization. In general, the deep learning networks used in indirect algorithms are CNN-based.

Clinically available deep-learning reconstruction algorithms

The U.S. Food and Drug Administration (FDA) has currently approved three vendor-specific DLR algorithms. In 2019, GE Healthcare launched TrueFidelity, the first FDA-approved deep learning-based image reconstruction (DLIR) algorithm [9, 11]. The training process uses low-dose, high-noise CT datasets as input and high-dose, low-noise CT datasets reconstructed by FBP as the ground truth, obtained from both phantoms and patients. Subsequent to training, the network is employed on CT scanners for image reconstruction. Nevertheless, the details regarding the use of projection data in training and inference for TrueFidelity remain a bit unclear based on publicly accessible information [12]. This DLIR aims to effectively eliminate noise while preserving noise texture and anatomical and pathological details. In the same year, FDA also approved the Advanced Intelligent Clear-IQ Engine (AiCE) developed by Canon Medical Systems corporation. The AiCE is an indirect image-based DLR algorithm, using low-quality input data and high-quality data with high-tube current and reconstructed with true model-based iterative reconstruction (MBIR) as the gold standard [13]. The AiCE learns to reduce noise and artifacts while preserving edges and maintaining imaging details. This DLR also prioritizes workflow speed with fast reconstruction times. The latest vendor-specific direct DLR algorithm is Precise Image from Philips Healthcare, approved by the FDA in 2022 [9]. The training process for Precise Image includes generating low-dose simulated scan data from routine-dose scan data before reconstruction as input and matching routine-dose FBP images as ground truth. The data used in the training process were acquired from a diverse population with various scan parameters [14]. Additionally, the FDA has approved two vendor-agnostic deep learning-based denoising algorithms, ClariCT.AI (ClariPi) and PixelShine (AlgoMedica) [9]. Following ClariCT.AI, ClariPi introduced ClariACE, a deep learning-based iodine contrast-augmenting algorithm that selectively enhances the contrast of the iodine without increasing image noise [15]. In December 2024, GE Healthcare, unveiled two new DLIR methods for CT, True Enhance DL and TrueFidelity DL [16]. The former estimates monochromatic 50 keV images from single-energy X-ray to increase contrast and support confident diagnoses, while the latter offers impressive image quality performance and preferred image sharpness and noise texture without compromising dose performance [16]. Furthermore, Canon Medical introduced a Super-Resolution DLR (SR-DLR) algorithm for cardiac CT, called Precise IQ Engine (PIQE), which enhances cardiac image quality by significantly diminishing noise and offering greater potential for dose reduction [17].

Research studies and applications of DLR in abdominal CT

Several investigators have worked on exploring the clinical applications of DLR in abdominal CT in the past few years, including both single-energy CT and dual-energy CT (DECT) [18, 19]. Jensen et al. [20] initially investigated the performance of DLIR (TrueFidelity) in contrast-enhanced oncologic abdominal CT compared to hybrid model-based adaptive statistical iterative reconstruction-V (ASiR-V) at 30%. This study demonstrated that DLIR achieved a higher contrast-to-noise ratio (CNR) and lower image noise than ASiR-V, along with enhanced overall image quality. Additionally, DLIR increased diagnostic confidence and lesion conspicuity in multiple abdominal organs, including the liver, spleen, pancreas, kidneys, and adrenal glands. Similar results were reported by Akagi et al. using AiCE, developed by Canon Medical Systems Corporation [21]. However, there is currently no direct comparative study between AiCE and TrueFidelity in abdominal CT, which limits the ability to directly compare their noise texture or clinical imaging characteristics. Many studies have explored the utilization of DLR across various abdominal organs, as detailed below.

Liver

A majority of studies exploring the role of DLR in abdominal CT have focused on its applications in the liver. Parakh et al. examined the image quality and perception of abdominal CT using three strengths of DLIR [low (DLIR-L), medium (DLIR-M), and high (DLIR-H)] in comparison to the ASiR-V at 40% [22]. DLIR outperformed image quality scores compared to ASiR-V, with DLIR-H achieving the highest scores, followed by DLIR-M and DLIR-L, respectively. All DLIRs exhibited lower image noise and higher CNR compared to ASiR-V (Fig. 3). Additionally, DLIR-H had the highest objective scores. Several other studies have also highlighted the ability of DLR to improve image quality and reduce image noise, along with the benefits in lower-dose CT and promising radiation dose reduction [23–26]. Better or comparable lesion visibility has been reported with DLR compared to standard reconstruction algorithms [27–29]. However, one study revealed that a 65% reduced-dose DLIR protocol had inferior characterization accuracy for all liver lesions and lower detection for small liver metastasis (≤ 5 mm) compared to standard-dose FBP in patients with colorectal liver metastasis despite the improved image quality [30].

Wang et al. recently investigated the value of DLIR in relation to body mass index (BMI), categorizing patients into three groups: the 80-kVp group (BMI ≤23.9 kg/m^2), 100-kVp group (BMI 24–28.9 kg/m^2), and 120-kVp group

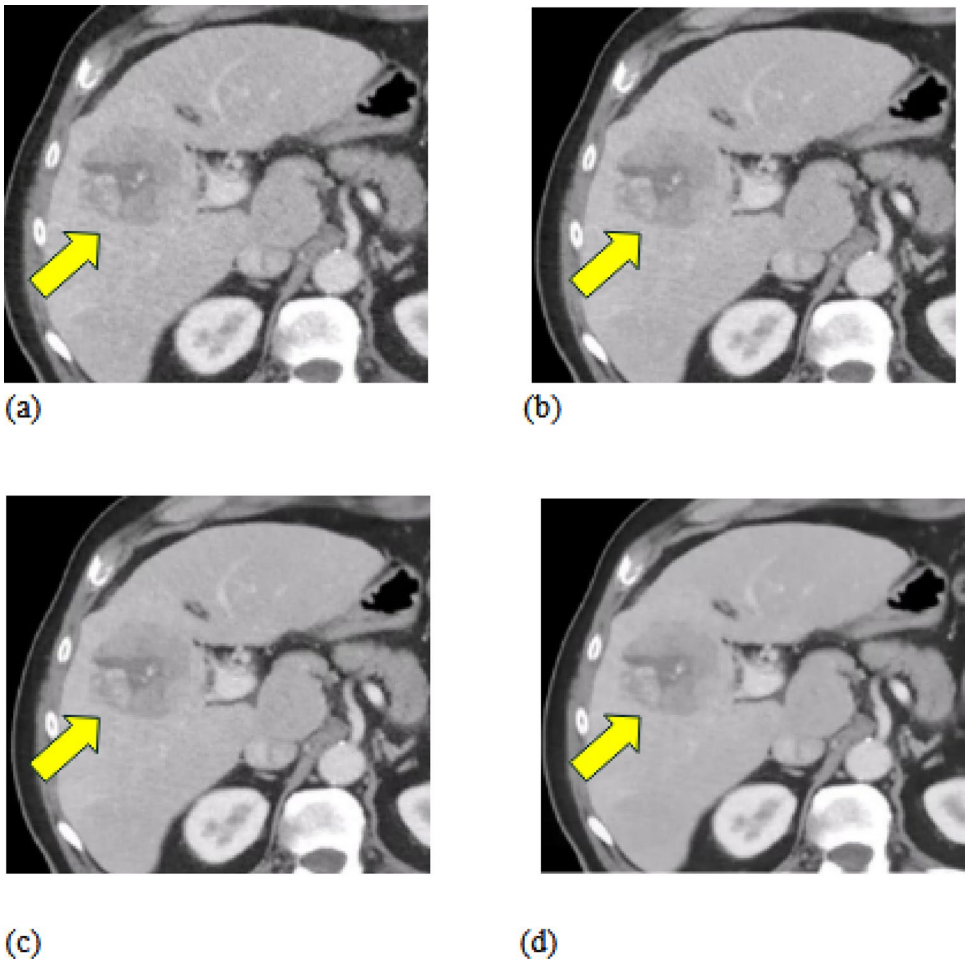

Fig. 3 Different types of image reconstructions depicting right hepatic lobe hepatocellular carcinoma in a 82-year-old male (arrows). Axial portal venous phase CT in (a) adaptive statistical iterative reconstruction-V 40% (ASiR-V 40), (b) deep learning-based image reconstruction low strength (DLIR-L), (c) medium strength (DLIR-M) and (d) high strength (DLIR-H) shows DLIR images have better image quality with lower noise

(BMI ≥29 kg/m^2) [31]. This study revealed that DLIR-M and DLIR-H provided superior image quality, lower image noise, and enhanced lesion visibility in both low- and high-contrast hepatic lesions compared to FBP and IR across all BMI groups. DLIR-M showed the greatest subjective overall image quality and lesion conspicuity scores, suggesting it as the optimal approach for abdominal CT scans across varying BMI categories. The benefits of DLIR are also evident in rapid kV switching DECT, demonstrating improved image quality, reduced image noise, higher CNR, and enhanced lesion visibility in multiparametric images, including virtual monoenergetic, iodine, and virtual unenhanced images [27, 32–35]. Comparable CT attenuation and iodine concentration values were observed between DLIR and ASiR-V, with reduced variability in iodine concentration values. The potential for enabling thinner slice thickness reconstruction in abdominal DECT through DLIR is also evident [35].

Park et al. demonstrated that low-dose liver CT utilizing a vendor-neutral image reconstruction technique (ClariCT.AI) exhibits non-inferior overall image quality and liver lesion detectability compared to standard-dose CT using MBIR [36]. Additionally, two studies explored the use of a commercially available, vendor-agnostic, deep learning-based iodine contrast-boosting algorithm (ClariACE) in liver CT images– one focused on hepatocellular carcinoma (HCC) and the other on hypovascular liver metastasis. Both studies demonstrated good image quality and diagnostic performance, even with reduced contrast and radiation doses [15, 37].

Pancreas

DLIR-H has shown the potential to improve diagnostic performance and reader confidence in assessing the resectability of pancreatic cancer, together with reducing interreader variability [38]. It has also demonstrated improved image quality and visibility of pancreatic ductal adenocarcinoma [39]. This improved image quality and lesion conspicuity is also reported in DECT and low-dose CT [40, 41]. In evaluating pancreatic cystic lesions, DLIR allows a radiation dose reduction of 64% while maintaining comparable diagnostic performance and lesion visibility [42]. Additional

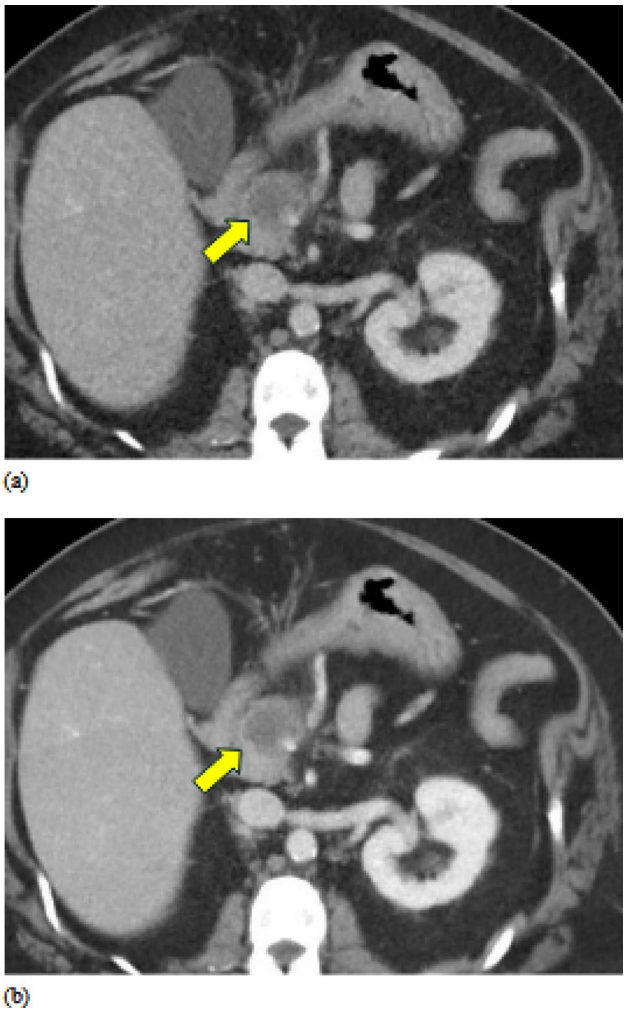

Fig. 4 Different types of image reconstructions depicting pancreatic head ductal adenocarcinoma in a 76-year-old female (arrows). Axial portal venous phase CT in (a) adaptive statistical iterative reconstruction-V 40% (ASiR-V 40), (b) deep learning-based image reconstruction medium strength (DLIR-M) shows DLIR image has better image quality with lower noise

benefits include enhanced image quality, increased CNR and reduced image noise (Fig. 4) [42, 43].

Kidneys

Beyond the liver and pancreas, DLR has shown concordant and promising results on the urinary tract stones evaluation. Studies have demonstrated enhanced image quality and maintaining high diagnostic performance, beneficial for both adult and pediatric populations (Fig. 5) [44–48]. Furthermore, implementing DLR facilitates radiation dose reduction without compromising diagnostic accuracy in urolithiasis with a potentially lower dose to submillisievert levels. One study investigating CT urography revealed similar

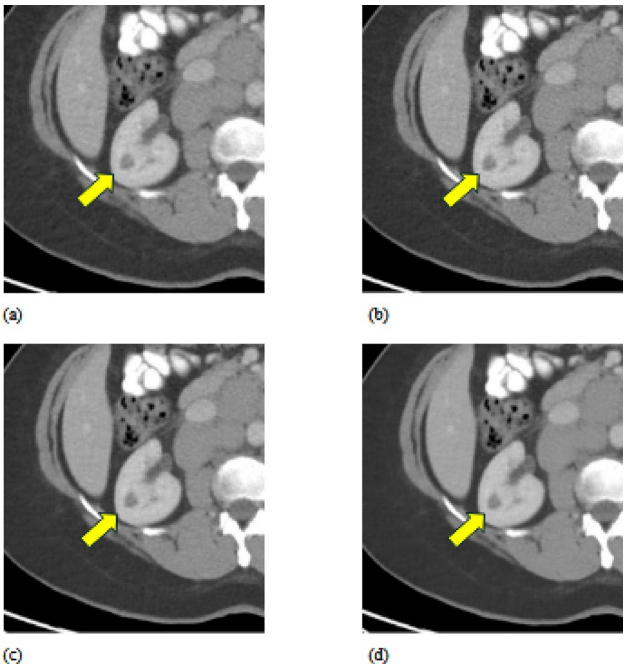

Fig. 5 Different types of image reconstructions depicting hypodense renal lesion in a 58-year-old male weighing 264 pounds (arrows). Axial portal venous phase CT in (a) adaptive statistical iterative reconstruction-V 40% (ASiR-V 40), (b) deep learning-based image reconstruction low strength (DLIR-L), (c) medium strength (DLIR-M) and (d) high strength (DLIR-H) shows DLIR images have higher image quality with lower noise and increased conspicuity of low contrast renal lesion despite patient's large body habitus

results with good image quality in low-dose CT urography using DLIR with 71% radiation dose reduction [49].

Systematic review and meta-analysis

In 2022, van Stiphout et al. conducted a systematic review and meta-analysis assessing the impact of DLR on CT attenuation values and image quality in abdominal CT scans [50]. Among 16 included studies, six were suitable for meta-analysis. The results indicated that CT attenuation values in the liver, spleen and pancreas are comparable between DLR, FBP and IR. DLR improved image quality with higher CNR and signal-to-noise ratio (SNR) compared to FBP and IR. These findings suggest that DLR can be safely adopted in clinical practice, allowing for improved image quality without compromising quantitative CT attenuation values.

With the growing robust evidence on DLR in routine clinical practice, another recent systemic review and meta-analysis was published in 2023, comprising the two most clinically used DLR algorithms: TrueFidelity and AiCE [51]. A total of 44 articles, including 32 studies with TrueFidelity and 12 studies with AiCE, were included. This meta-analysis demonstrated that DLR significantly improved image quality with decreased image noise and increased CNR on

both single- and dual-energy CT scans. The study revealed a radiation dose reduction of 35.1–78.5%. For low-contrast liver lesion detection, a CTDIvol of 6.8 to 12.2 mGy was sufficient for lesions larger than 5 mm, whereas a CTDIvol of 13.6–34.9 mGy was required for detecting smaller lesions and improved characterization in normal weight to obese patients. In summary, DLR has demonstrated significant potential to improve image quality by lower image noise and enhancing CNR. These advancements facilitate radiation dose reduction, improve lesion detection, enable thinner slice reconstruction and have a potential application across varying BMIs. It is worth noting that current clinical studies are predominantly established on TrueFidelity and AiCE, while only a few studies on Precise Image. However, the results of these studies align with similar trends [52, 53]. Another concern in this systemic review is related to the heterogeneity of the included studies, along with other factors such as variations in radiation dose, slice thickness, patient demographics and contrast utilization.

The details and key results from example recent studies across various abdominal organs are summarized and provided in Table 1. The studies listed in Table 1 were selected based on their publication in high-impact, peer-reviewed journals, representation of various clinical applications across different organs, sufficient sample sizes to ensure generalizability, a preference for prospective over retrospective study designs, and an emphasis on recent publications.

AI beyond image reconstruction in abdominal imaging

Imaging interpretation and diagnosis

Lesion detection and characterization are primary, time-consuming tasks for radiologists in clinical practice. Computer-aided diagnosis (CAD) systems have been introduced to assist abnormality detection, improve accuracy and reduce the time required for imaging interpretation [54]. However, earlier CAD systems were limited by high false-positive rates and labor requirements that need to be reassessed by radiologists. Recent efforts have integrated AI into image analysis through deep learning, particularly using CNNs. These CNNs, specifically tailored for radiology, are the fundamental of lesion detection and classification. These models learn to identify patterns, textures, and abnormalities indicative of lesions [55]. A preliminary study in 2018 used a CNN-based deep learning model to differentiate liver masses in multiphasic contrast-enhanced abdominal CT into five categories: classic HCCs, malignant tumors other than classic and early HCCs, indeterminate masses or mass-like lesions, rare benign liver masses other than hemangiomas and cysts, and hemangiomas and cysts. This model simplifies the workload for radiologists by requiring them to focus only on the tumors, capture the images and input them into the CNN without the need to trace complex-shaped tumor boundaries for regions of interest. This CNN model on triphasic CT images could differentiate malignant lesions from indeterminate and benign masses with an area under the receiver operating curve of 0.92, achieving an overall accuracy of 0.84 in classifying all liver lesions [56].

Liver metastasis is one of the most common hepatic lesions encountered in routine practice. Determining the number and size of liver metastasis is crucial for preoperative planning and prognosis, particularly in colorectal liver metastasis. Vorontsov et al. assessed the performance of a fully convolutional network (FCN) for detecting and segmenting liver lesions on abdominal CT scans in patients with colorectal liver metastases and showed promising results with high sensitivity for lesions larger than 10 mm [57]. Although very low sensitivity in lesions smaller than 10 mm was noted using automated segmentation. Nevertheless, user corrections of automated segmentation addressed these limitations and proved faster than manual segmentation. A subsequent study on colorectal liver metastasis revealed concordant results, with good sensitivity on lesions larger than 10 mm [58]. However, it noted that the false positive rates of deep learning-based lesion detection algorithm (DLLD) exceeded those of radiologists, suggesting that DLLD is more suitable as an assistant tool rather than a standalone diagnostic solution.

Hepatocellular carcinoma is the most commonly encountered primary liver malignancy and needs to be differentiated from other hepatic lesions such as intrahepatic cholangiocarcinoma or other hypervascular tumors. Deep learning methods have been developed to improve the diagnostic accuracy of HCC, yielding high-performance levels comparable to experienced radiologists [59]. A recent meta-analysis on the diagnostic performance of deep learning techniques for HCC diagnosis, including 13 CT studies, reported a pooled sensitivity of 91% (95% CI: 88–94), a pooled specificity of 92% (95% CI: 89–94), and the AUC value was 0.97 (95% CI: 0.95–0.98) [60]. Nevertheless, publication bias and high heterogeneity among studies may lead to an overestimation of the diagnostic accuracy of these techniques.

Pancreatic cancer is often evaluated using CT scans, which play a crucial role in early detection. The NCCN guidelines recommend pancreatic protocol CT as an initial step in the workup of a patient with clinically suspected pancreatic cancer. Early detection of pancreatic cancer is crucial because early-stage pancreatic cancer has a good prognosis [61]. Chen et al. developed an end-to-end deep learning-based detection tool that achieved 91% accuracy in

Table 1 Example studies on deep learning image reconstruction for abdominal CT

Study	Organs	Number	Participants	Scanner	DLR name/Vendor	DLR strength	Purpose	Key results
Nakamura (2021) [24]	Liver	72 patients	Patients with liver screening, staging, or restaging	Aquilion Precision, Canon Medical Systems	AiCE, Canon	N/A	To compare image quality on low dose abdominal U-HRCT using DLR, hybrid-IR, or MBIR compared to standard-dose U-HRCT using hybrid-IR	Lower dose DLR images had better image quality and lower image noise compared to standard-dose hybrid-IR images. Neither hybrid-IR nor MBIR appeared to facilitate a radiation dose reduction on abdominal U-HRCT without adversely affecting the image quality. DLR enables a decrease in radiation dose while preserving image quality, potentially applying to abdominal U-HRCT scans
Tamura et al. (2021) [25]	Liver, abdominal aorta	91 patients	Not specified	Aquilion ONE PRISM, Canon Medical System	AiCE, Canon	Body mild	To compare the image quality of low-dose abdominal CT reconstructed using DLR, MBIR and FBP	DLR had superior image quality to MBIR and FBP. DLR was the only technique that showed lower image noise in obese patients compared to those with a normal BMI.

Table 1 (continued)

Study	Organs	Number	Participants	Scanner	DLR name/Vendor	DLR strength	Purpose	Key results
Jensen et al. (2022) [30]	Liver	51 patients with 161 lesions	Patients with colorectal liver metastasis	Revolution, GE Healthcare	TrueFidelity, GE	Medium	To compare liver metastases evaluation and image quality on contrast-enhanced abdominal CT using reduced-dose DLIR and standard-dose FBP	DLIR with 65% radiation dose reduction had superior image quality and CNR for liver metastasis compared to standard-dose FBP while preserving detection of liver lesion larger than 0.5 cm. Reduced-dose DLIR had inferior lesion characterization accuracy to standard-dose FBP. Reduced-dose DLIR showed lower detection of small lesions (≤ 0.5 cm) than standard-dose FBP.
Park et al. (2022) [36]	Liver	80 patients	Patients with malignant and pre-malignant liver lesions	SOMATOM Force, Siemens Healthcare	ClariCT.AI, Vendor-agnostic	N/A	To compare image quality and detectability of significant (malignant and pre-malignant) liver lesions of low-dose liver CT using DLD compared to standard-dose CT using MBIR	Low-dose liver CT using DLD with 67% dose reduction had non-inferior overall image quality and non-inferior detectability for liver lesions compared to standard-dose CT using MBIR. Low-dose CT using DLD had significantly less noise and higher CNR of liver lesions than standard-dose CT using MBIR.

Table 1 (continued)

Study	Organs	Number	Participants	Scanner	DLR name/Vendor	DLR strength	Purpose	Key results
Xu et al. (2023) [35]	Liver	30 patients	Suspicion of intraabdominal abscess/infection, post surgical evaluation	Revolution, GE Healthcare; TrueFidelity	TrueFidelity, GE	High	To compare image quality in 0.625 and 2.5 mm slice thickness 74 keV VMI on DECT using DLIR and ASiR-V	DLIR had lower image noise and higher CNR and SNR as well as improved image quality in 0.625 mm slice images, compared to ASiR-V. DLIR may enable the image reconstruction with thinner slice thickness in routine abdominal DECT.
Kang et al. (2023) [15]	Liver	68 patients with 57 lesions	High risk for HCC	IQon, Philips Healthcare	ClariACE, Vendor-agnostic	N/A	To compare image quality and lesion conspicuity of a DL-CB on DLD CT of simultaneous radiation and contrast doses reduction with standard dose protocol	DL-CB on DLD CT (19.8% lower radiation dose and 27% lower contrast dose) had significantly higher CNR than standard-dose CT. Detection rate of all liver lesions and HCCs was not significantly different between the two protocols.
Lee et al. (2023) [37]	Liver	128 patients	Hepatic metastasis surveillance	SOMATOM Force, Siemens Healthcare;	ClariACE, Vendor-agnostic	N/A	To compare image quality and diagnostic performance of low-contrast-dose liver CT including 50-keV VMI, linearly blended simulating 120-kVp images and post-processed 120-kVp images using DLICA	DLICA 120-kVp images had significantly higher CNR of liver lesions, superior lesion conspicuity and lower subjective noise compared with 50-keV VMI and 120-kVp images. DLICA 120-kVp had overall similar diagnostic performance for hypovascular liver metastasis compared with 50-keV VMI and 120-kVp images; however, DLICA 120-kVp showed superior lesion detectability for small metastases (< 20 mm) compared to 50-kev VMI.

Table 1 (continued)

Study	Organs	Number	Participants	Scanner	DLR name/Vendor	DLR strength	Purpose	Key results
Cao et al. (2024) [32]	Liver, aorta	100 patients	Cancer staging/re-staging, trauma	Revolution, GE Healthcare	TrueFidelity, GE	Low Medium High	To compare image quality on multiparametric DECT including 65 keV monoenergetic, iodine and virtual enhanced images, using DLIR and ASiR-V	DLIR had superior qualitative scores than ASiR-V images, with the exception of artifacts, where both reconstructions were comparable; additionally, DLIR-H showed the highest image quality scores. DLIR showed comparable attenuation values to ASiR-V while demonstrating superior CNR for the liver and portal vein and lower noise levels.
Lyu et al. (2024) [27]	Liver	80 patients	Patients with liver metastasis	Revolution Apex, GE Healthcare	TrueFidelity, GE	Medium High	To compare image quality and liver metastasis detection on reduced-dose DECT with DLIR and standard dose SECT with DLIR or IR	DLIR with 34% radiation dose reduction in DECT had a similar liver metastasis detection rate and perceptual image quality to full-dose SECT. The 40- and 50-keV VMIs with DLIR showed higher lesion conspicuity and similar or better perceptual image quality compared to SECT with IR. The 50-keV VMIs with DLIR had comparable lesion conspicuity and perceptual image quality to SECT with DLIR.

Table 1 (continued)

Study	Organs	Number	Participants	Scanner	DLR name/Vendor	DLR strength	Purpose	Key results
Wang et al. (2024) [31]	Liver	112 patients with 97 lesions	Not specified	Revolution, GE Healthcare	TrueFidelity, GE	Low Medium High	To compare image quality and lesion conspicuity on abdominal CT using DLIR, ASiR-V and FBP in patients with a wide range of BMIs	DLIR-M and DLIR-H had better image quality and lesion conspicuity than FBP and IR for all BMIs. DLIR-H showed the lowest image noise and highest CNR value, while DLIR-M had the best overall image quality and lesion conspicuity scores in low- and high-contrast hepatic lesions. For all BMIs, DLIR enhanced image quality and hepatic lesion conspicuity, with DLIR-M being the optimal choice for considering both factors.
Cao et al. (2024) [28]	Liver	50 patients + Phantom	Patients with low-contrast liver lesions	Revolution, GE Healthcare	TrueFidelity, GE	Low Medium High	To compare the low-contrast detectability of hypoattenuating liver lesions on CT images reconstructed using DLIR and ASiR-V	DLIR and ASiR-V at 40% strength had similar performance in detecting low-contrast liver lesions in both patient and phantom studies. DLIR-M and DLIR-H had greater lesion-to-background contrast-to-noise ratios than ASiR-V at 40% strength.

Table 1 (continued)

Study	Organs	Number	Participants	Scanner	DLR name/Vendor	DLR strength	Purpose	Key results
Lyu et al. (2021) [38]	Pancreas	47 patients	Pancreatic cancer	Revolution, GE Healthcare	TrueFidelity, GE	Low Medium High	To compare diagnostic performance and reader confidence in assessing the resectability of pancreatic cancer on CT using DLIR, ASiR-V and FBP	DLIR-H demonstrated higher the average area under the receiver operating characteristic curve for prediction of margin-negative resection and highest inter-reader agreement in resectability classification than other reconstruction algorithms. DLIR had superior confidence scores compared to FBP and ASiR-V at 60% strength, with a linear increase correlating to the increment of DLIR strength level.
Noda et al. (2022) [41]	Pancreas	30 patients	Pancreatic cancer	Revolution, GE Healthcare	TrueFidelity, GE	Medium High	To compare image quality and iodine concentration measurement in DECT with pancreatic protocol using DLIR and IR	DLIR-M showed the highest image quality and lesion conspicuity. DLIR significantly decreased background noise and increased CNR and SNR. DLIR could reduce the variability of iodine concentration.
Takai etl al (2023) [39]	Pancreas	56 patients	Pancreatic adenocarcinoma	Revolution, GE Healthcare	TrueFidelity, GE	Medium High	To compare image quality of visibility of pancreatic adenocarcinoma in 80-kVp pancreatic CT protocol using DLIR and IR	DLIR-H had higher image quality, lesion visibility and CNR as well as lower noise compared to DLIR-M and IR.

Table 1 (continued)

Study	Organs	Number	Participants	Scanner	DLR name/Vendor	DLR strength	Purpose	Key results
Koh et al. (2023) [42]	Pancreas	103 patients	Follow-up of incidentally detected pancreatic cystic lesions	Revolution Apex, GE Healthcare	TrueFidelity, GE	Medium High	To compare efficacy in surveillance of pancreatic cystic lesion on low-dose CT using DLIR and standard-dose CT using ASiR-V	Using the DLIR algorithm in low-dose CT revealed a dose reduction of 64% compared to standard-dose CT, while still maintaining comparable performance and lesion conspicuity. DLIR-H in low-dose CT demonstrated the highest overall image quality and CNR, as well as, the lowest image noise.
Kanzawa (2024) [43]	Pancreas	54 patients	Not specified	Aquilion ONE, Canon Medical Systems	AiCE, Canon	Body sharp	To compare image quality and detection performance of pancreatic cystic lesions on abdominal CT using DLR and FBP	DLR showed lower image noise and improved SNR and CNR as well as superior image quality scores. DLR had similar performance in lesion detection to FBP.
Cheng (2021) [49]	Kidney	52 patients	Mixed, urolithiasis, tumor, or hematuria	Revolution, GE Healthcare	TrueFidelity, GE	High	To compare image quality on low-dose CTU with DLIR and conventional CTU using ASiR-V	Low-dose CTU using DLIR with a 71% radiation dose reduction had good and comparable image quality to conventional CTU performed with ASiR-V.

Table 1 (continued)

Study	Organs	Number	Participants	Scanner	DLR name/Vendor	DLR strength	Purpose	Key results
Zhang et al. (2022) [47]	Kidney	60 patients with 148 urinary stones	Patients with suspected urolithiasis	Aquilion ONE Genesis, Canon Medical Systems	AiCE, Canon	Body sharp	To compare diagnostic accuracy and image quality in evaluating urinary tract stones on ULDCT with DLR and ULDCT with HIR, compared to LDCT with HIR as the reference standard	ULDCT-DLR had comparable urinary stone detection rates and stone size estimation to LDCT-HIR with superior image quality, lower image noise and significantly lower radiation dose. ULDCT-DLR, ULDCT-HIR and LDCT-HIR had similar stone detection rates and stone stize estimation in clinical significant stone ≥3 mm
Delabie et al. (2022) [44]	Kidney	75 patients with 192 urinary stones	Patients with urolithiasis	Revolution, GE Healthcare	TrueFidelity, GE	High	To compare urinary tract stones detection rate on low-dose non-enhanced abdominal CT using DLIR, IR and FBP	DLIR reconstruction had superior image quality, lower image noise and high CNR to ASiR-V and FBP as well as excellent urinary stone detection, particularly on stones larger than 3 mm.
Steuwe et al. (2022) [48]	Kidney	45 patients	Patients with urolithiasis	Somatom Definition Flash, Siemens Healthineers	PixelShine, Vendor-agnostic	N/A	To compare the size, attenuation and image quality of urinary stones in low-dose CT images using DLR technique and traditional reconstruction	DLR had significantly higher CNR and SNR by decreasing image noise. DLR demonstrated improved objective image quality while maintaining both correct stone size and CT attenuation values.

Table 1 (continued)

Study	Organs	Number	Participants	Scanner	DLR name/Vendor	DLR strength	Purpose	Key results
Prod'homme et al. (2024) [45]	Kidney	57 patients with 266 urinary stones	Patients with suspected urolithiasis	Revolution, GE Healthcare	TrueFidelity, GE	High	To compare diagnostic performance and image quality on submillisievert abdominal CT in evaluating urolithiasis using DLIR and ASiR-V	DLIR-H in ULDCT showed good diagnostic performance in urinary tract stone detection regardless of stone size and location with a sensitivity of 89% and specificity of 94%. DLIR-H had lower image noise, higher SNR and better image quality compared to ASiR-V at 70% strength in ULDCT.

Table 1 (continued)

Study	Organs	Number	Participants	Scanner	DLR name/Vendor	DLR strength	Purpose	Key results
Singh et al. (2020) [18]	Abdominal solid organs, peritoneum, lungs	59 patients	Mixed, abdominal pain, cancer diagnosis and staging, unexplained weight loss	Aquilion ONE, Canon Medical Systems	AiCE, Canon	N/A	To compare image quality and clinically significant lesion detection on submillisievert chest and abdominal CT using DLR and IR	DLR had superior image quality and significant lesion detection to IR and FBP images on submillisievert chest and abdominal CT.
Zhong et al. (2023) [19]	Liver, spleen, pancreas, kidney, aorta, portal vein, IVC, paraspinal muscle	47 patients with 84 lesions	Mixed, cancer staging or surveillance, abdominal lesion, or suspected lesions detected by unenhanced scans	Revolution Apex, GE Healthcare	TrueFidelity, GE	Low Medium High	To compare image quality, diagnostic acceptability, and lesion conspicuity on abdominal DECT using DLIR and ASiR-V	DLIR had lower image noise than ASiR-V at 50% strength while better preserving the average noise power spectrum frequency. DLIR-M and DLIR-H showed superior image quality for image contrast, noise, sharpness, and diagnostic acceptability than ASiR-V at 50% strength, while DLIR-H had better lesion conspicuity than ASiR-V at 50% strength and DLIR-M. DLIR-H could be safely recommended for clinical use in routine low-keV VMI reconstruction in abdominal DECT, offering superior lesion conspicuity and improved image quality compared to the standard ASiR-V.

AiCE = Advanced Intelligent Clear-IQ Engine, ASiR-V = Adaptive statistical iterative reconstruction-V, BMI = Body mass index, CNR = Contrast-to-noise ratio, CT = Computed Tomography, CTU = CT urography, DECT = Dual energy CT, DL-CB = Deep-learning-based contrast boosting algorithm, DLD = Double low-dose, DLICA = Deep learning-based iodine contrast -augmenting algorithm, DLIR = Deep learning-based image reconstruction, DLR = Deep learning-based reconstruction, DLIR-H = DLIR with high strength, DLIR-M = DLIR with medium strength, FBP = Filtered back projection, HCC = Hepatocellular carcinoma, HIR = hybrid iterative reconstruction, IR = Iterative reconstruction, LDCT = Low-dose CT, MBIR = Model-based iterative reconstruction, SECT = Single-energy CT, SNR = Signal-to-noise ratio, U-HRCT = Ultra-high-resolution CT, ULDCT = Ultra-low-dose CT, VMI = Virtual monoenergetic image

identifying pancreatic cancer on CT scans in a nationwide real-world test without manual image labeling or preprocessing [62]. Additionally, this tool demonstrated a reasonable sensitivity of about 75% for small tumors (< 2 cm). Another study explored a deep learning-based approach for detecting solid and cystic pancreatic neoplasm, showing good diagnostic performance for solid lesions of any size and cystic lesions measuring 1.0 cm or larger, with results comparable to those of radiologists [63]. Furthermore, the potential application of deep learning models for preoperative lymph

node staging in pancreatic ductal adenocarcinoma has also been reported [64].

Deep learning has also been applied to urinary stone detection using cascading CNNs, demonstrating good accuracy in identifying urinary tract stones on unenhanced abdominal CT scans. This method may assist in prioritization of scans in a busy clinical practice [65]. Deep learning algorithms employed on multiphasic contrast-enhanced CT have revealed comparable performance to radiologists for identification of small renal masses (< 3 cm) [66]. Efforts have also been made to use deep learning methods to help characterize solid-enhancing renal masses particularly to differentiate lipid poor angiomyolipoma from renal cell carcinoma and oncocytoma from clear cell carcinoma [67, 68]. Various applications of deep learning for lesion detection in abdominal CT have been reported, including the identification of splenic injuries, bowel obstructions and pneumoperitoneum [69–71].

Quantitative analysis and predictive modeling

Deep learning algorithms show a significant potential for quantitative CT imaging due to their ability to automatically segment anatomical structures such as liver, renal and adrenal volume as well as abdominal fat and muscles [72–74]. They are also effective in quantifying abnormal pathologies such as hepatic steatosis, aortic calcification, ascites and hemoperitoneum [75–78]. Lee et al. demonstrated the capability of a deep learning-based model to quantify the volume of liver Couinaud segments and the spleen on contrasted-enhanced CT. This model showed comparable performance to manual measurements in predicting histopathologic liver cirrhosis and advanced fibrosis. A multivariable model incorporating liver segmental volume ratios, liver volume proportions, splenic volume, and liver attenuation achieved an AUC of 0.94 in predicting cirrhosis in patients with hepatitis C [79]. Furthermore, a fully automated machine learning algorithm utilized on routine abdominal CT shows promise as an adjunctive tool for predicting cardiovascular events. Visceral fat area derived from a fully automated and age-, race- and sex-normalized analysis of abdominal CT effectively predicts subsequent myocardial infarction or stroke in both Black and White patients [80].

Workflow optimization

CT workflow dynamics include various steps prior to image acquisition and image analysis. Before scan acquisition, AI-based systems can be employed to analyze electronic medical records to identify potential contraindications, such as contrast allergies or elevated serum creatinine levels enabling alert systems as safety mechanism [81]. CT protocols are carefully designed to match the clinical question being addressed to enable accurate image acquisition. CT protocols specify critical scanning parameters such as the area to be scanned, slice thickness, and the use of contrast. Collaboration between radiologists and technologists is key to protocol selection and modification based on patient-specific needs. Machine learning can enhance automatic protocoling systems, improving both quality and efficiency [82]. Chung et al. assessed the impact of an automated CT protocol system on workflow efficiency and found that it significantly minimized radiologists' protocoling workload while also shortening the time between order entry, protocol assignment, and examination completion. Additionally, protocol errors and recalls were rare [83].

While deep learning methods play an important role in image reconstruction, AI can contribute to various processes prior to image acquisition. AI can assist in patient positioning and intravenous contrast optimization to ensure high quality imaging [84, 85]. Furthermore, minimizing radiation dose is a critical safety measure, achieved through several strategies, including the integration of AI to denoise low-dose CT images. Following scan acquisition, AI can aid in study prioritization by identifying acute findings and alerting clinicians to critical results, allowing timely intervention and management [86].

Challenges and future directions

The translation from use of AI in research studies into its utilization in real-world clinical practice faces several challenges [87]. Although DLR has demonstrated promising performance, concerns remain in vendor-specific comparisons and generalization of vendor specific models. As mentioned earlier, different vendors have different training algorithms and techniques, resulting in different image appearances, which may impact clinical comparability, especially when patients need to follow up. There is a requirement for improved vendor collaborations to minimize discrepancies in image data. Nevertheless, the individual algorithm remains under private ownership; thus, training set size, data sources, and pathologic anomalies must be standardized [9]. Specific strategies for addressing standardization, such as phantom testing across various platforms or utilizing benchmark datasets, should be implemented. Comparative studies across vendors, as well as in-depth evaluations of standardization issues and potential strategies to reconcile these discrepancies, would be valuable. In addition to vendor variability, statistical heterogeneity across studies presents another challenge that should be acknowledged when comparing results among multiple studies.

Beyond DLR, other AI applications, such as image diagnosis or detection, has additional challenges. Building a strong and reliable AI model requires large and various datasets from different populations to ensure generalization. However, much of the existing research has been conducted in single institutions, raising concerns about the broad application of these models to varied patient groups with different racial backgrounds and risk factors. The development of such a robust model is a time-consuming process and requires extensive resources.

Demonstrating clinical efficacy is another concern for both DLR and other AI applications. While DLR has shown many positive results regarding the enhancement of image quality, further prospective studies are required to validate its impact on diagnostic accuracy, such as improved sensitivity and specificity in lesion detection. Moreover, addressing common clinical challenges, such as detecting small and subtle lesions, differentiating between tumors sharing similar imaging characteristics, or reducing time-consuming tasks, will promote the AI-based devices to become practical adjunctive tools for radiologists.

Accessibility of AI tools also impacts its universal utilization. Currently, these tools are mainly confined to large or leading medical centers. However, AI has the potential to address the disparities in healthcare by applying clinically validated AI tools showing performance comparable to experienced radiologists in remote areas that lack specialized radiologists. So, developing user-friendly and commercially available AI tools would significantly enhance their utility in real-world settings.

Despite several challenges, AI has immense potential to enhance the utility of CT in clinical practice. Future research should prioritize several important areas, including multicenter prospective studies, which are needed to validate the performance and generalizability of DLR across different vendors and imaging platforms. Additionally, cost-effectiveness analyses should be performed to assess outcomes such as decreased radiologist workload, shortened reading time, lower contrast media dose, or reduced treatment cost resulting from improved diagnostic accuracy. Furthermore, the development of standardized protocols for integrating AI tools into clinical workflows, as well as the exploration of their longitudinal impact, will be crucial. These efforts are all aimed at validating and supporting the implementation of AI in routine clinical practice.

Conclusion

Artificial intelligence in radiology, particularly for abdominal CT, is a promising tool with potential applications across multiple steps in CT workflow, from patient preparation and scan acquisition to treatment planning. While extensive research demonstrates the benefits of deep learning-based tools in enhancing image quality, further validation is required to confirm their ability to improve diagnostic accuracy in clinical practice. Integrating these tools in abdominal imaging can enhance efficiency and improve patient care in awareness of their limitations.

Author contributions N.P. and A.K. developed the idea for the article. N.P., S.S.R., Y.N., and A.K. wrote the main manuscript text. N.P., S.S.R., and A.K. prepared figures and wrote captions. N.P., S.S.R., Y.N., S.K., A.R., and A.K. contributed to critical revision of the manuscript and figures.

Data availability No datasets were generated or analysed during the current study.

Declarations

Competing interests The authors declare no competing interests.

References

1. Chartrand G, Cheng PM, Vorontsov E, et al. (2017) Deep Learning: A Primer for Radiologists. Radiographics 37:2113–2131. https://doi.org/10.1148/rg.2017170077
2. Cheng PM, Montagnon E, Yamashita R, et al. (2021) Deep Learning: An Update for Radiologists. Radiographics 41:1427–1445. https://doi.org/10.1148/rg.2021200210
3. Szczykutowicz TP, Toia GV, Dhanantwari A, Nett B (2022) A Review of Deep Learning CT Reconstruction: Concepts, Limitations, and Promise in Clinical Practice. Current Radiology Reports 10:101–115. https://doi.org/10.1007/s40134-022-00399-5
4. Stiller W (2018) Basics of iterative reconstruction methods in computed tomography: A vendor-independent overview. Eur J Radiol 109:147–154. https://doi.org/10.1016/j.ejrad.2018.10.025
5. Willemink MJ, Noel PB (2019) The evolution of image reconstruction for CT-from filtered back projection to artificial intelligence. Eur Radiol 29:2185–2195. https://doi.org/10.1007/s00330-018-5810-7
6. Nakaura T, Nakamura S, Maruyama N, et al. (2012) Low contrast agent and radiation dose protocol for hepatic dynamic CT of thin adults at 256-detector row CT: effect of low tube voltage and hybrid iterative reconstruction algorithm on image quality. Radiology 264:445–454. https://doi.org/10.1148/radiol.12111082
7. Singh S, Kalra MK, Hsieh J, et al. (2010) Abdominal CT: comparison of adaptive statistical iterative and filtered back projection reconstruction techniques. Radiology 257:373–383. https://doi.org/10.1148/radiol.10092212
8. Padole A, Ali Khawaja RD, Kalra MK, Singh S (2015) CT radiation dose and iterative reconstruction techniques. AJR Am J Roentgenol 204:W384-392. https://doi.org/10.2214/AJR.14.13241
9. Koetzier LR, Mastrodicasa D, Szczykutowicz TP, et al. (2023) Deep Learning Image Reconstruction for CT: Technical Principles and Clinical Prospects. Radiology 306:e221257. https://doi.org/10.1148/radiol.221257
10. Kyong Hwan J, McCann MT, Froustey E, Unser M (2017) Deep Convolutional Neural Network for Inverse Problems in Imaging.

IEEE Trans Image Process 26:4509–4522. https://doi.org/10.1109/TIP.2017.2713099
11. Jiang Hsieh EL, Brian Nett, Jie Tang, Jean-Baptiste Thibault, Sonia Sahney. A new era of image reconstruction: TrueFidelity™– Technical white paper on deep learning image reconstruction2019. Available from: https://www.gehealthcare.com/-/jssmedia/040dd213fa89463287155151fdb01922.pdf?srsltid=AfmBOop4p8IQSoeB_XdIE2QjU22dBtjHkLIHQjgibQQ-hP3GJs3esylx.
12. Mileto A, Yu L, Revels JW, et al. (2024) State-of-the-Art Deep Learning CT Reconstruction Algorithms in Abdominal Imaging. Radiographics 44:e240095. https://doi.org/10.1148/rg.240095
13. AiCE Deep Learning Reconstruction: Bringing the power of Ultra-High Resolution CT to routine imaging. [Internet]. Canon Medical Systems. 2019 [cited 15 November 2024]. Available from: https://global.medical.canon/publication/ct/2019WP_AiCE_Deep_Learning.
14. AI for significantly lower dose and improved image quality Precise Image:white paper. [Internet]. Philips. 2021 [cited 15 November 2024]. Available from: https://www.philips.com/c-dam/b2bhc/master/resource-catalog/landing/precise-suite/incisive_precise_image.pdf
15. Kang HJ, Lee JM, Ahn C, et al. (2023) Low dose of contrast agent and low radiation liver computed tomography with deep-learning-based contrast boosting model in participants at high-risk for hepatocellular carcinoma: prospective, randomized, double-blind study. Eur Radiol 33:3660–3670. https://doi.org/10.1007/s00330-023-09520-4
16. Imai Y SR, Inoue J, Langoju R, Agrawal U, Das B. True Enhance DL– Technical White Paper on Deep Learning Image Reconstruction.2024. Available from: https://landing1.gehealthcare.com/rs/005-SHS-767/images/TrueEnhance_DL_whitepaper_230724.pdf.
17. Greffier J, Pastor M, Si-Mohamed S, et al. (2024) Comparison of two deep-learning image reconstruction algorithms on cardiac CT images: A phantom study. Diagn Interv Imaging 105:110–117. https://doi.org/10.1016/j.diii.2023.10.004
18. Singh R, Digumarthy SR, Muse VV, et al. (2020) Image Quality and Lesion Detection on Deep Learning Reconstruction and Iterative Reconstruction of Submillisievert Chest and Abdominal CT. AJR Am J Roentgenol 214:566–573. https://doi.org/10.2214/AJR.19.21809
19. Zhong J, Wang L, Shen H, et al. (2023) Improving lesion conspicuity in abdominal dual-energy CT with deep learning image reconstruction: a prospective study with five readers. Eur Radiol 33:5331–5343. https://doi.org/10.1007/s00330-023-09556-6
20. Jensen CT, Liu X, Tamm EP, et al. (2020) Image Quality Assessment of Abdominal CT by Use of New Deep Learning Image Reconstruction: Initial Experience. AJR Am J Roentgenol 215:50–57. https://doi.org/10.2214/AJR.19.22332
21. Akagi M, Nakamura Y, Higaki T, et al. (2019) Deep learning reconstruction improves image quality of abdominal ultra-high-resolution CT. Eur Radiol 29:6163–6171. https://doi.org/10.1007/s00330-019-06170-3
22. Parakh A, Cao J, Pierce TT, Blake MA, Savage CA, Kambadakone AR (2021) Sinogram-based deep learning image reconstruction technique in abdominal CT: image quality considerations. Eur Radiol 31:8342–8353. https://doi.org/10.1007/s00330-021-07952-4
23. Cao L, Liu X, Li J, et al. (2021) A study of using a deep learning image reconstruction to improve the image quality of extremely low-dose contrast-enhanced abdominal CT for patients with hepatic lesions. Br J Radiol 94:20201086. https://doi.org/10.1259/bjr.20201086
24. Nakamura Y, Narita K, Higaki T, Akagi M, Honda Y, Awai K (2021) Diagnostic value of deep learning reconstruction for radiation dose reduction at abdominal ultra-high-resolution CT. Eur Radiol 31:4700–4709. https://doi.org/10.1007/s00330-020-07566-2
25. Tamura A, Mukaida E, Ota Y, Kamata M, Abe S, Yoshioka K (2021) Superior objective and subjective image quality of deep learning reconstruction for low-dose abdominal CT imaging in comparison with model-based iterative reconstruction and filtered back projection. Br J Radiol 94:20201357. https://doi.org/10.1259/bjr.20201357
26. Ichikawa Y, Kanii Y, Yamazaki A, et al. (2021) Deep learning image reconstruction for improvement of image quality of abdominal computed tomography: comparison with hybrid iterative reconstruction. Jpn J Radiol 39:598–604. https://doi.org/10.1007/s11604-021-01089-6
27. Lyu P, Li Z, Chen Y, et al. (2024) Deep learning reconstruction CT for liver metastases: low-dose dual-energy vs standard-dose single-energy. Eur Radiol 34:28–38. https://doi.org/10.1007/s00330-023-10033-3
28. Cao J, Mroueh N, Mercaldo N, et al. (2024) Detectability of Hypoattenuating Liver Lesions with Deep Learning CT Reconstruction: A Phantom and Patient Study. Radiology 313:e232749. https://doi.org/10.1148/radiol.232749
29. Nakamura Y, Higaki T, Tatsugami F, et al. (2019) Deep Learning-based CT Image Reconstruction: Initial Evaluation Targeting Hypovascular Hepatic Metastases. Radiol Artif Intell 1:e180011. https://doi.org/10.1148/ryai.2019180011
30. Jensen CT, Gupta S, Saleh MM, et al. (2022) Reduced-Dose Deep Learning Reconstruction for Abdominal CT of Liver Metastases. Radiology 303:90–98. https://doi.org/10.1148/radiol.211838
31. Wang H, Yue S, Liu N, et al. (2024) Deep learning reconstruction vs standard reconstruction for abdominal CT: the influence of BMI. Eur Radiol 34:1614–1623. https://doi.org/10.1007/s00330-023-10179-0
32. Cao J, Mroueh N, Lennartz S, et al. (2024) Multi-reader multiparametric DECT study evaluating different strengths of iterative and deep learning-based image reconstruction techniques. Eur Radiol https://doi.org/10.1007/s00330-024-10974-3
33. Fukutomi A, Sofue K, Ueshima E, et al. (2023) Deep learning image reconstruction to improve accuracy of iodine quantification and image quality in dual-energy CT of the abdomen: a phantom and clinical study. Eur Radiol 33:1388–1399. https://doi.org/10.1007/s00330-022-09127-1
34. Sato M, Ichikawa Y, Domae K, et al. (2022) Deep learning image reconstruction for improving image quality of contrast-enhanced dual-energy CT in abdomen. Eur Radiol 32:5499–5507. https://doi.org/10.1007/s00330-022-08647-0
35. Xu JJ, Lonn L, Budtz-Jorgensen E, Jawad S, Ulriksen PS, Hansen KL (2023) Evaluation of thin-slice abdominal DECT using deep-learning image reconstruction in 74 keV virtual monoenergetic images: an image quality comparison. Abdom Radiol (NY) 48:1536–1544. https://doi.org/10.1007/s00261-023-03845-w
36. Park S, Yoon JH, Joo I, et al. (2022) Image quality in liver CT: low-dose deep learning vs standard-dose model-based iterative reconstructions. Eur Radiol 32:2865–2874. https://doi.org/10.1007/s00330-021-08380-0
37. Lee T, Yoon JH, Park JY, et al. (2023) Deep learning-based iodine contrast-augmenting algorithm for low-contrast-dose liver CT to assess hypovascular hepatic metastasis. Abdom Radiol (NY) 48:3430–3440. https://doi.org/10.1007/s00261-023-04039-0
38. Lyu P, Neely B, Solomon J, et al. (2021) Effect of deep learning image reconstruction in the prediction of resectability of pancreatic cancer: Diagnostic performance and reader confidence. Eur J Radiol 141:109825. https://doi.org/10.1016/j.ejrad.2021.109825
39. Takai Y, Noda Y, Asano M, et al. (2023) Deep-learning image reconstruction for 80-kVp pancreatic CT protocol: Comparison of image quality and pancreatic ductal adenocarcinoma visibility

with hybrid-iterative reconstruction. Eur J Radiol 165:110960. https://doi.org/10.1016/j.ejrad.2023.110960
40. Noda Y, Iritani Y, Kawai N, et al. (2021) Deep learning image reconstruction for pancreatic low-dose computed tomography: comparison with hybrid iterative reconstruction. Abdom Radiol (NY) 46:4238–4244. https://doi.org/10.1007/s00261-021-03111-x
41. Noda Y, Kawai N, Nagata S, et al. (2022) Deep learning image reconstruction algorithm for pancreatic protocol dual-energy computed tomography: image quality and quantification of iodine concentration. Eur Radiol 32:384–394. https://doi.org/10.1007/s00330-021-08121-3
42. Koh S, Lee NK, Kim S, Hong SB, Kim DU, Han SY (2023) The efficacy of low-dose CT with deep learning image reconstruction in the surveillance of incidentally detected pancreatic cystic lesions. Abdom Radiol (NY) 48:2585–2595. https://doi.org/10.1007/s00261-023-03958-2
43. Kanzawa J, Yasaka K, Ohizumi Y, Morita Y, Kurokawa M, Abe O (2024) Effect of deep learning reconstruction on the assessment of pancreatic cystic lesions using computed tomography. Radiol Phys Technol https://doi.org/10.1007/s12194-024-00834-6
44. Delabie A, Bouzerar R, Pichois R, Desdoit X, Vial J, Renard C (2022) Diagnostic performance and image quality of deep learning image reconstruction (DLIR) on unenhanced low-dose abdominal CT for urolithiasis. Acta Radiol 63:1283–1292. https://doi.org/10.1177/02841851211035896
45. Prod'homme S, Bouzerar R, Forzini T, Delabie A, Renard C (2024) Detection of urinary tract stones on submillisievert abdominopelvic CT imaging with deep-learning image reconstruction algorithm (DLIR). Abdom Radiol (NY) 49:1987–1995. https://doi.org/10.1007/s00261-024-04223-w
46. Thapaliya S, Brady SL, Somasundaram E, et al. (2022) Detection of urinary tract calculi on CT images reconstructed with deep learning algorithms. Abdom Radiol (NY) 47:265–271. https://doi.org/10.1007/s00261-021-03274-7
47. Zhang G, Zhang X, Xu L, et al. (2022) Value of deep learning reconstruction at ultra-low-dose CT for evaluation of urolithiasis. Eur Radiol 32:5954–5963. https://doi.org/10.1007/s00330-022-08739-x
48. Steuwe A, Valentin B, Bethge OT, et al. (2022) Influence of a Deep Learning Noise Reduction on the CT Values, Image Noise and Characterization of Kidney and Ureter Stones. Diagnostics (Basel) 12https://doi.org/10.3390/diagnostics12071627
49. Cheng Y, Han Y, Li J, et al. (2021) Low-dose CT urography using deep learning image reconstruction: a prospective study for comparison with conventional CT urography. Br J Radiol 94:20201291. https://doi.org/10.1259/bjr.20201291
50. van Stiphout JA, Driessen J, Koetzier LR, et al. (2022) The effect of deep learning reconstruction on abdominal CT densitometry and image quality: a systematic review and meta-analysis. Eur Radiol 32:2921–2929. https://doi.org/10.1007/s00330-021-08438-z
51. Shehata MA, Saad AM, Kamel S, et al. (2023) Deep-learning CT reconstruction in clinical scans of the abdomen: a systematic review and meta-analysis. Abdom Radiol (NY) 48:2724–2756. https://doi.org/10.1007/s00261-023-03966-2
52. Barca P, Domenichelli S, Golfieri R, et al. (2023) "Image quality evaluation of the Precise image CT deep learning reconstruction algorithm compared to Filtered Back-projection and iDose(4): a phantom study at different dose levels". Phys Med 106:102517. https://doi.org/10.1016/j.ejmp.2022.102517
53. Greffier J, Durand Q, Serrand C, et al. (2023) First Results of a New Deep Learning Reconstruction Algorithm on Image Quality and Liver Metastasis Conspicuity for Abdominal Low-Dose CT. Diagnostics (Basel) 13https://doi.org/10.3390/diagnostics13061182
54. Santos MK, Ferreira Junior JR, Wada DT, Tenorio APM, Barbosa MHN, Marques PMA (2019) Artificial intelligence, machine learning, computer-aided diagnosis, and radiomics: advances in imaging towards to precision medicine. Radiol Bras 52:387–396. https://doi.org/10.1590/0100-3984.2019.0049
55. Yamashita R, Nishio M, Do RKG, Togashi K (2018) Convolutional neural networks: an overview and application in radiology. Insights Imaging 9:611–629. https://doi.org/10.1007/s13244-018-0639-9
56. Yasaka K, Akai H, Abe O, Kiryu S (2018) Deep Learning with Convolutional Neural Network for Differentiation of Liver Masses at Dynamic Contrast-enhanced CT: A Preliminary Study. Radiology 286:887–896. https://doi.org/10.1148/radiol.2017170706
57. Vorontsov E, Cerny M, Regnier P, et al. (2019) Deep Learning for Automated Segmentation of Liver Lesions at CT in Patients with Colorectal Cancer Liver Metastases. Radiol Artif Intell 1:180014. https://doi.org/10.1148/ryai.2019180014
58. Kim K, Kim S, Han K, Bae H, Shin J, Lim JS (2021) Diagnostic Performance of Deep Learning-Based Lesion Detection Algorithm in CT for Detecting Hepatic Metastasis from Colorectal Cancer. Korean J Radiol 22:912–921. https://doi.org/10.3348/kjr.2020.0447
59. Wang M, Fu F, Zheng B, et al. (2021) Development of an AI system for accurately diagnose hepatocellular carcinoma from computed tomography imaging data. Br J Cancer 125:1111–1121. https://doi.org/10.1038/s41416-021-01511-w
60. Wei Q, Tan N, Xiong S, Luo W, Xia H, Luo B (2023) Deep Learning Methods in Medical Image-Based Hepatocellular Carcinoma Diagnosis: A Systematic Review and Meta-Analysis. Cancers (Basel) 15https://doi.org/10.3390/cancers15235701
61. Egawa S, Toma H, Ohigashi H, et al. (2012) Japan Pancreatic Cancer Registry; 30th year anniversary: Japan Pancreas Society. Pancreas 41:985–992. https://doi.org/10.1097/MPA.0b013e318258055c
62. Chen PT, Wu T, Wang P, et al. (2023) Pancreatic Cancer Detection on CT Scans with Deep Learning: A Nationwide Population-based Study. Radiology 306:172–182. https://doi.org/10.1148/radiol.220152
63. Park HJ, Shin K, You MW, et al. (2023) Deep Learning-based Detection of Solid and Cystic Pancreatic Neoplasms at Contrast-enhanced CT. Radiology 306:140–149. https://doi.org/10.1148/radiol.220171
64. Castellana R, Fanni SC, Roncella C, Romei C, Natrella M, Neri E (2024) Radiomics and deep learning models for CT pre-operative lymph node staging in pancreatic ductal adenocarcinoma: A systematic review and meta-analysis. Eur J Radiol 176:111510. https://doi.org/10.1016/j.ejrad.2024.111510
65. Parakh A, Lee H, Lee JH, Eisner BH, Sahani DV, Do S (2019) Urinary Stone Detection on CT Images Using Deep Convolutional Neural Networks: Evaluation of Model Performance and Generalization. Radiol Artif Intell 1:e180066. https://doi.org/10.1148/ryai.2019180066
66. Dai C, Xiong Y, Zhu P, et al. (2024) Deep Learning Assessment of Small Renal Masses at Contrast-enhanced Multiphase CT. Radiology 311:e232178. https://doi.org/10.1148/radiol.232178
67. Coy H, Hsieh K, Wu W, et al. (2019) Deep learning and radiomics: the utility of Google TensorFlow Inception in classifying clear cell renal cell carcinoma and oncocytoma on multiphasic CT. Abdom Radiol (NY) 44:2009–2020. https://doi.org/10.1007/s00261-019-01929-0
68. Feng Z, Rong P, Cao P, et al. (2018) Machine learning-based quantitative texture analysis of CT images of small renal masses: Differentiation of angiomyolipoma without visible fat from renal cell carcinoma. Eur Radiol 28:1625–1633. https://doi.org/10.1007/s00330-017-5118-z

69. Chiu IM, Huang TY, Ouyang D, et al. (2024) PACT-3D, a deep learning algorithm for pneumoperitoneum detection in abdominal CT scans. Nat Commun 15:9660. https://doi.org/10.1038/s41467-024-54043-1
70. Hamghalam M, Moreland R, Gomez D, et al. (2024) Machine Learning Detection and Characterization of Splenic Injuries on Abdominal Computed Tomography. Can Assoc Radiol J 75:534–541. https://doi.org/10.1177/08465371231221052
71. Vanderbecq Q, Gelard M, Pesquet JC, et al. (2024) Deep learning for automatic bowel-obstruction identification on abdominal CT. Eur Radiol 34:5842–5853. https://doi.org/10.1007/s00330-024-10657-z
72. Park HJ, Shin Y, Park J, et al. (2020) Development and Validation of a Deep Learning System for Segmentation of Abdominal Muscle and Fat on Computed Tomography. Korean J Radiol 21:88–100. https://doi.org/10.3348/kjr.2019.0470
73. Weston AD, Korfiatis P, Kline TL, et al. (2019) Automated Abdominal Segmentation of CT Scans for Body Composition Analysis Using Deep Learning. Radiology 290:669–679. https://doi.org/10.1148/radiol.2018181432
74. Kim TM, Choi SJ, Ko JY, et al. (2023) Fully automatic volume measurement of the adrenal gland on CT using deep learning to classify adrenal hyperplasia. Eur Radiol 33:4292–4302. https://doi.org/10.1007/s00330-022-09347-5
75. Graffy PM, Sandfort V, Summers RM, Pickhardt PJ (2019) Automated Liver Fat Quantification at Nonenhanced Abdominal CT for Population-based Steatosis Assessment. Radiology 293:334–342. https://doi.org/10.1148/radiol.2019190512
76. Graffy PM, Liu J, O'Connor S, Summers RM, Pickhardt PJ (2019) Automated segmentation and quantification of aortic calcification at abdominal CT: application of a deep learning-based algorithm to a longitudinal screening cohort. Abdom Radiol (NY) 44:2921–2928. https://doi.org/10.1007/s00261-019-02014-2
77. Hou B, Lee S, Lee JM, et al. (2024) Deep Learning Segmentation of Ascites on Abdominal CT Scans for Automatic Volume Quantification. Radiol Artif Intell 6:e230601. https://doi.org/10.1148/ryai.230601
78. Dreizin D, Zhou Y, Fu S, et al. (2020) A Multiscale Deep Learning Method for Quantitative Visualization of Traumatic Hemoperitoneum at CT: Assessment of Feasibility and Comparison with Subjective Categorical Estimation. Radiol Artif Intell 2:e190220. https://doi.org/10.1148/ryai.2020190220
79. Lee S, Elton DC, Yang AH, et al. (2022) Fully Automated and Explainable Liver Segmental Volume Ratio and Spleen Segmentation at CT for Diagnosing Cirrhosis. Radiol Artif Intell 4:e210268. https://doi.org/10.1148/ryai.210268
80. Magudia K, Bridge CP, Bay CP, et al. (2023) Utility of Normalized Body Composition Areas, Derived From Outpatient Abdominal CT Using a Fully Automated Deep Learning Method, for Predicting Subsequent Cardiovascular Events. AJR Am J Roentgenol 220:236–244. https://doi.org/10.2214/AJR.22.27977
81. Pierre K, Haneberg AG, Kwak S, et al. (2023) Applications of Artificial Intelligence in the Radiology Roundtrip: Process Streamlining, Workflow Optimization, and Beyond. Semin Roentgenol 58:158–169. https://doi.org/10.1053/j.ro.2023.02.003
82. Kalra A, Chakraborty A, Fine B, Reicher J (2020) Machine Learning for Automation of Radiology Protocols for Quality and Efficiency Improvement. J Am Coll Radiol 17:1149–1158. https://doi.org/10.1016/j.jacr.2020.03.012
83. Chung R, Demers JP, Tiberio R, et al. (2024) Implementation of an Institution-Wide Rules-Based Automated CT Protocoling System. AJR Am J Roentgenol 222:e2329806. https://doi.org/10.2214/AJR.23.29806
84. (n.d.) GH. AI auto-positioning: White paper. Available from: https://www.gehealthcare.com/-/jssmedia/gehc/us/images/products/revolution-ascend/files/ai-auto-positioning-white-paper.pdf?srsltid=AfmBOoogz_b73VmzV6otBoQACJ8aoaFbeqXeHGAbBI1mBUwjqELfo5is.
85. Phiips. AI to save time and improve precision in CT patient positioning. 2021. Available from: https://www.philips.com/c-dam/b2bhc/master/resource-catalog/landing/precise-suite/incisive_precise_position.pdf.
86. Winkel DJ, Heye T, Weikert TJ, Boll DT, Stieltjes B (2019) Evaluation of an AI-Based Detection Software for Acute Findings in Abdominal Computed Tomography Scans: Toward an Automated Work List Prioritization of Routine CT Examinations. Invest Radiol 54:55–59. https://doi.org/10.1097/RLI.0000000000000509
87. Flory MN, Napel S, Tsai EB (2024) Artificial Intelligence in Radiology: Opportunities and Challenges. Semin Ultrasound CT MR 45:152–160. https://doi.org/10.1053/j.sult.2024.02.004

Publisher's note Springer Nature remains neutral with regard to jurisdictional claims in published maps and institutional affiliations.

Springer Nature or its licensor (e.g. a society or other partner) holds exclusive rights to this article under a publishing agreement with the author(s) or other rightsholder(s); author self-archiving of the accepted manuscript version of this article is solely governed by the terms of such publishing agreement and applicable law.