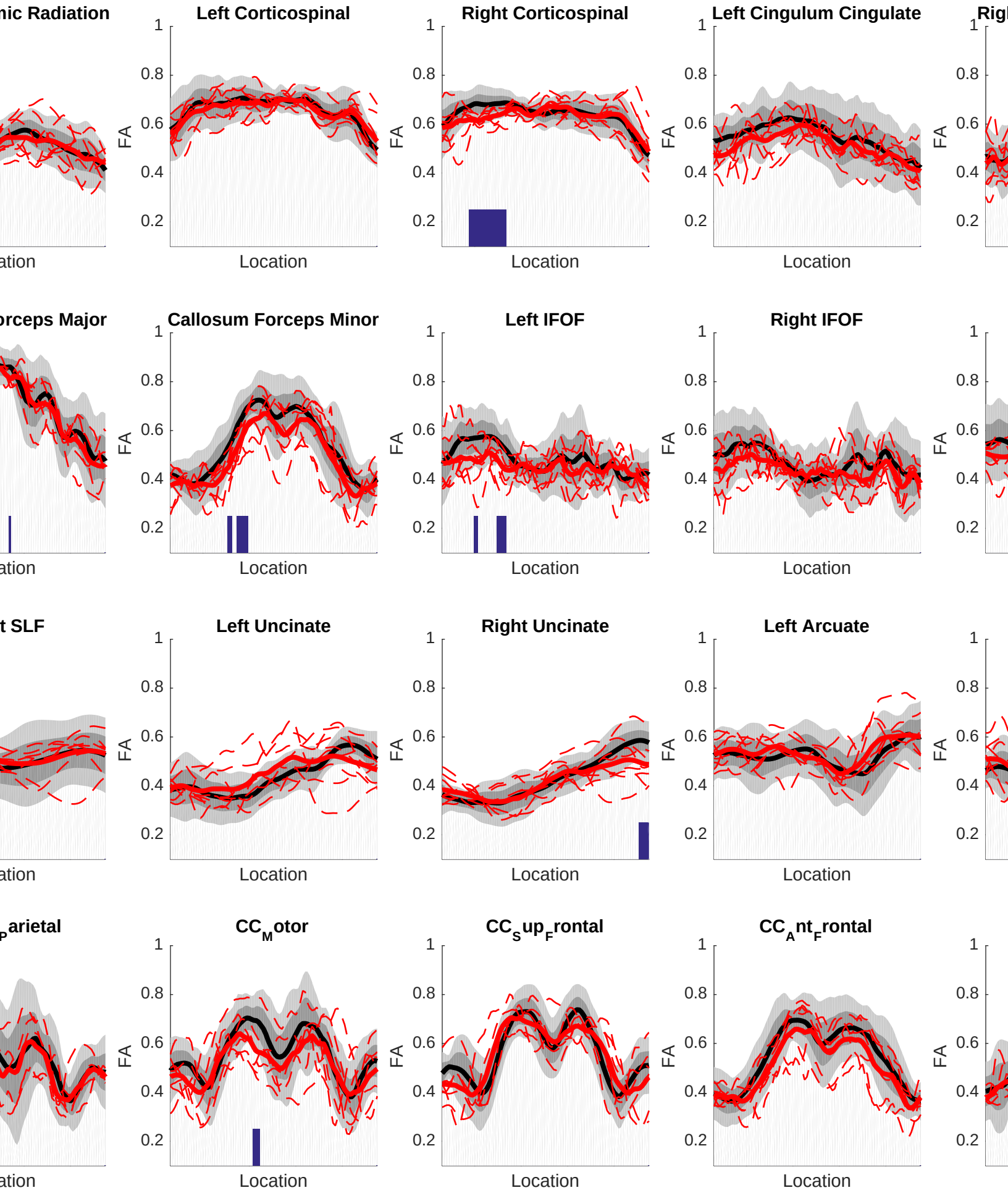
nic Radiation
Left Corticospinal
Right Corticospinal
Left Cingulum Cingulate
Rigl
orceps Major
Callosum Forceps Minor
Left IFOF
Right IFOF
t SLF
Left Uncinate
Right Uncinate
Left Arcuate
arietal
CC_Motor
CC_Supfrontal
CC_Antfrontal
FA
Location
1
0.8
0.6
0.4
0.2