CARDIOVASCULAR
PATHOLOGY



27.12.2020

פרופ' שמואל פרל

פתולוגיה - בית ספר וטרינרי

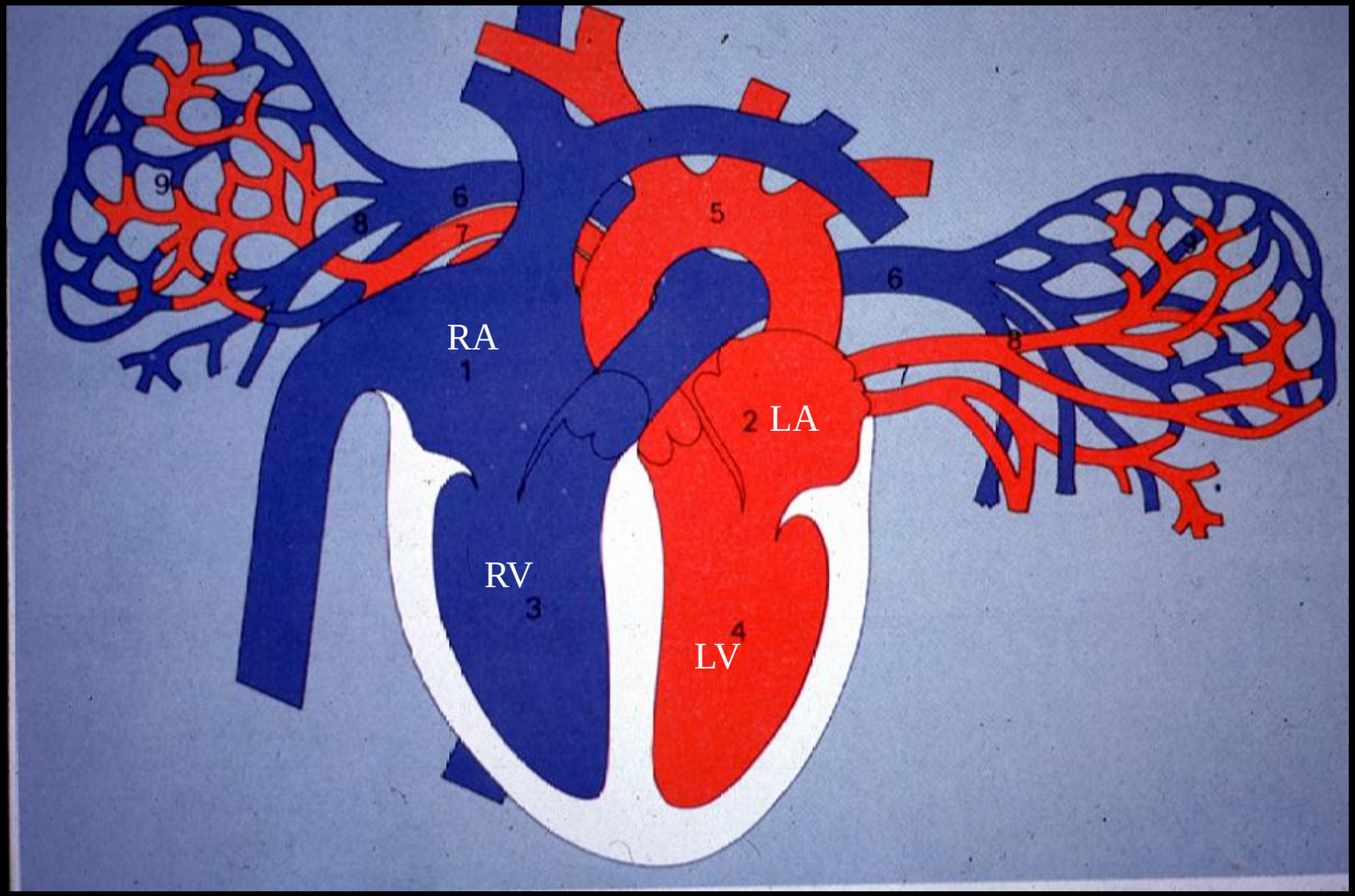
9
6
8
7
5
6
9
8
7
RA
1
2 LA
RV
3
4
LV

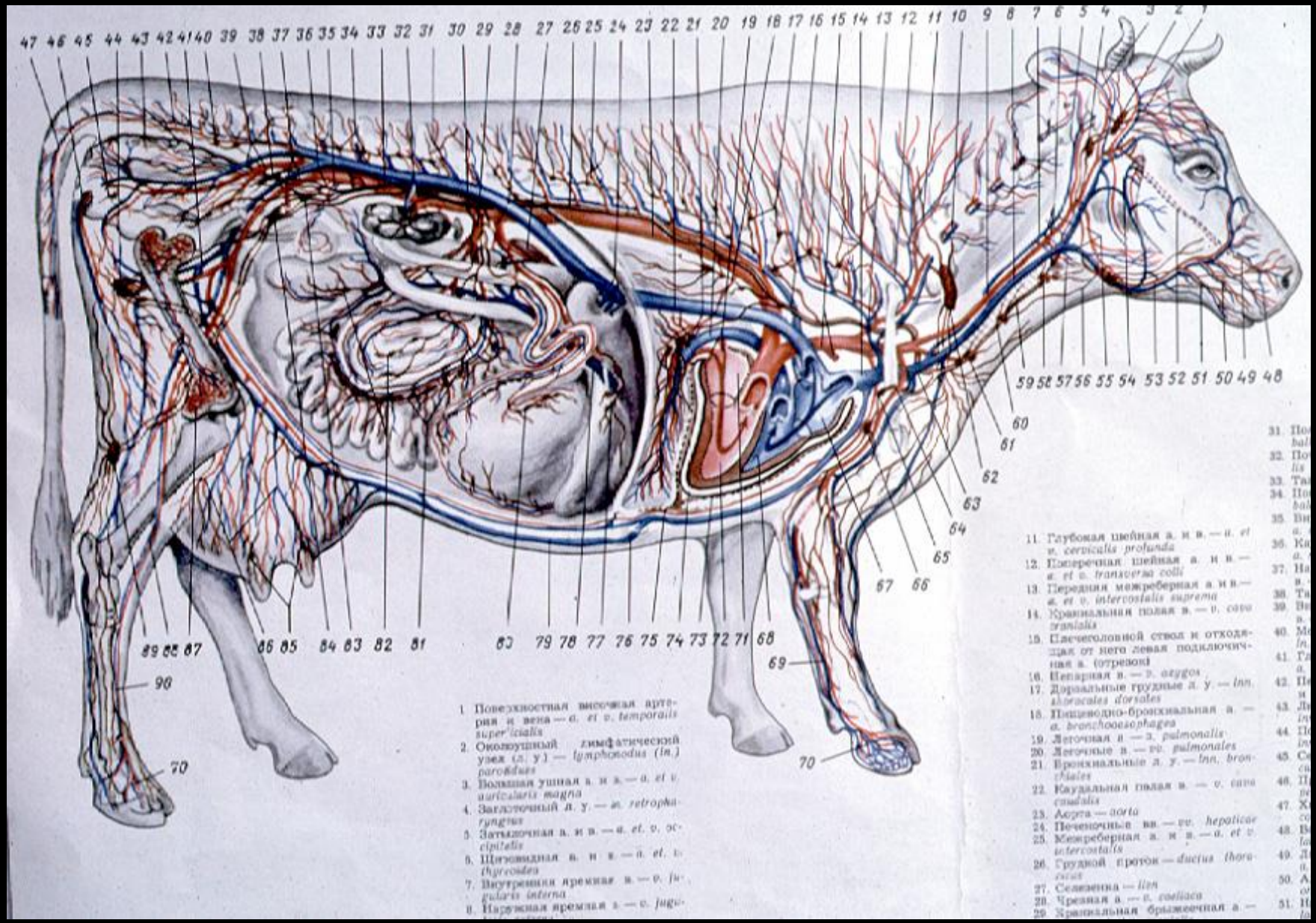

1. Поверхностная височная артерия и вена — *a. et v. temporalis superficialis*
2. Околоушный лимфатический узел (л. у.) — *lymphonodus (ln.) parotideus*
3. Большая ушная а. и в. — *a. et v. auricularis magna*
4. Заглоточный л. у. — *ln. retropharyngeus*
5. Затылочная а. и в. — *a. et v. occipitalis*
6. Щитовидная а. и в. — *a. et v. thyreoidea*
7. Внутренняя яремная в. — *v. jugularis interna*
8. Наружная яремная в. — *v. jugularis externa*
11. Глубокая шейная а. и в. — *a. et v. cervicalis profunda*
12. Поперечная шейная а. и в. — *a. et v. transversa colli*
13. Передняя межреберная а. и в. — *a. et v. intercostalis suprema*
14. Краниальная полая в. — *v. cava cranialis*
15. Плечеголовной ствол и отходящая от него левая подключичная а. (отрезок)
16. Непарная в. — *v. azygos*
17. Дорзальные грудные л. у. — *lnn. thoracales dorsales*
18. Пищеводно-бронхиальная а. — *a. bronchooesophagea*
19. Легочная в. — *v. pulmonalis*
20. Легочные в. — *vv. pulmonales*
21. Бронхиальные л. у. — *lnn. bronchiales*
22. Каудальная полая в. — *v. cava caudalis*
23. Аорта — *aorta*
24. Печеночные вв. — *vv. hepaticae*
25. Межреберная а. и в. — *a. et v. intercostalis*
26. Грудной проток — *ductus thoracicus*
27. Селезенка — *lien*
28. Чревная а. — *a. coeliaca*
29. Краниальная брыжеечная а. —

Cardiovascular pathology

Congenital cardiovascular diseases

Acquired cardiovascular diseases

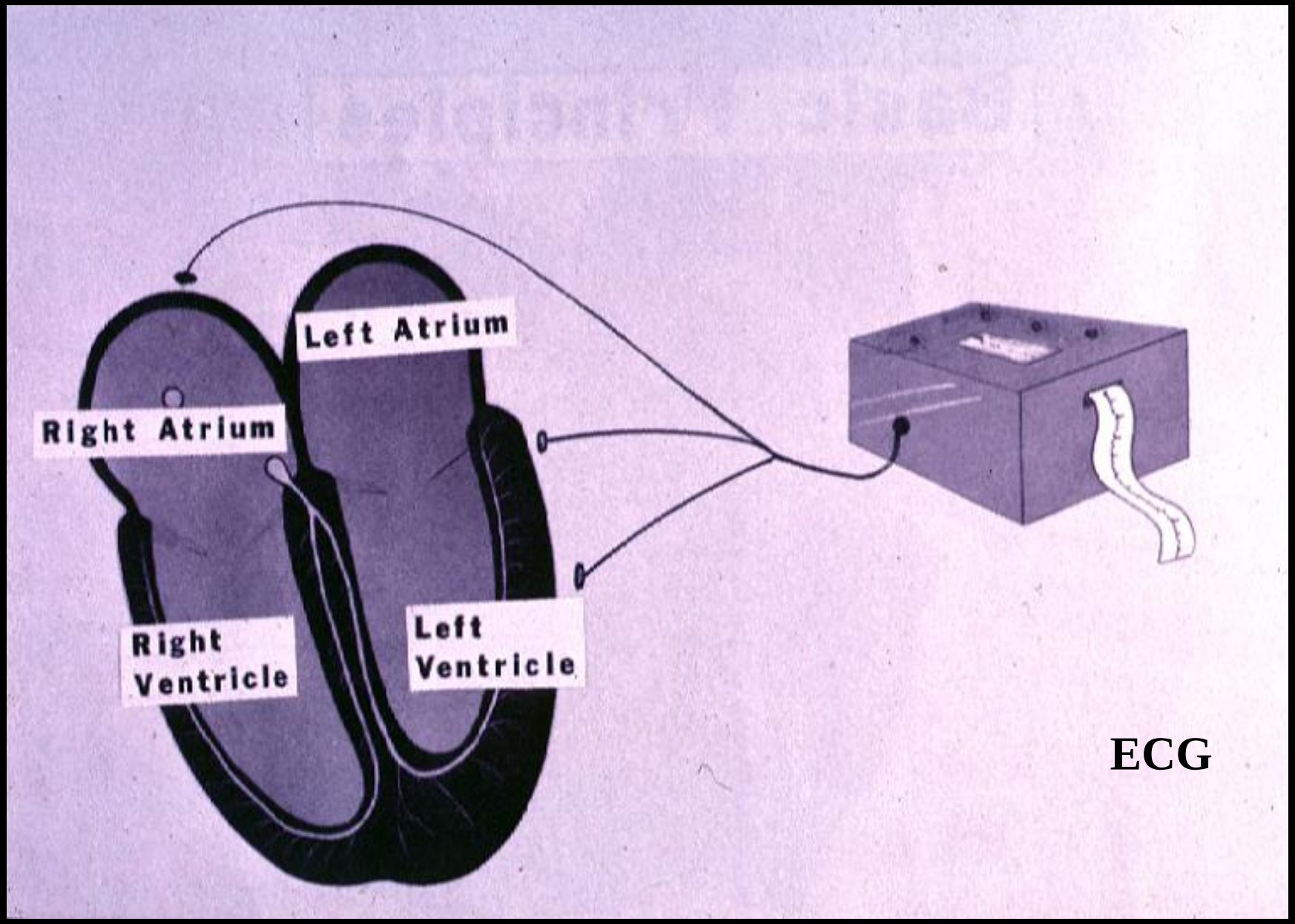

ECG

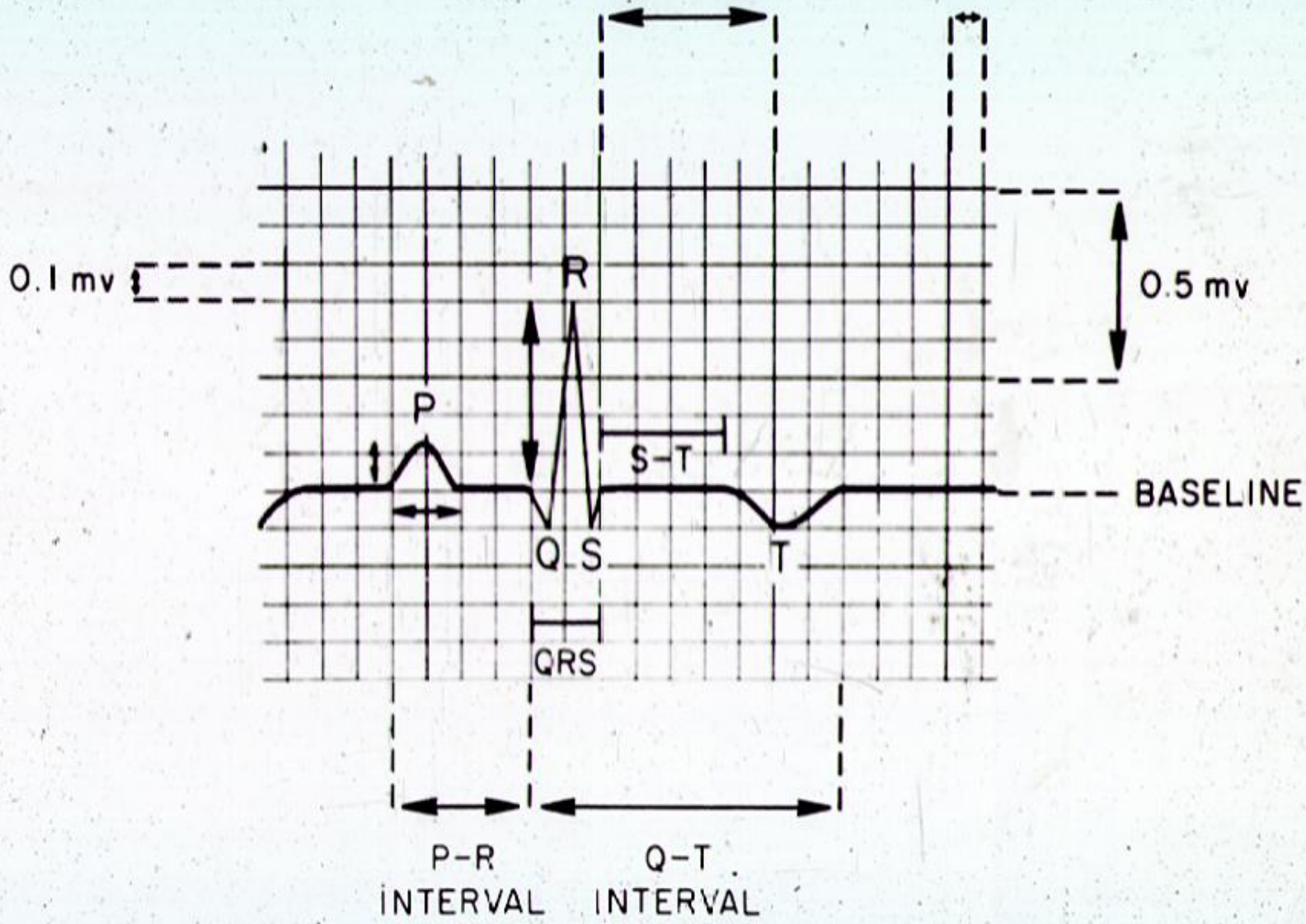

Closeup of a normal feline lead II P-QRS-T complex with labels and intervals.

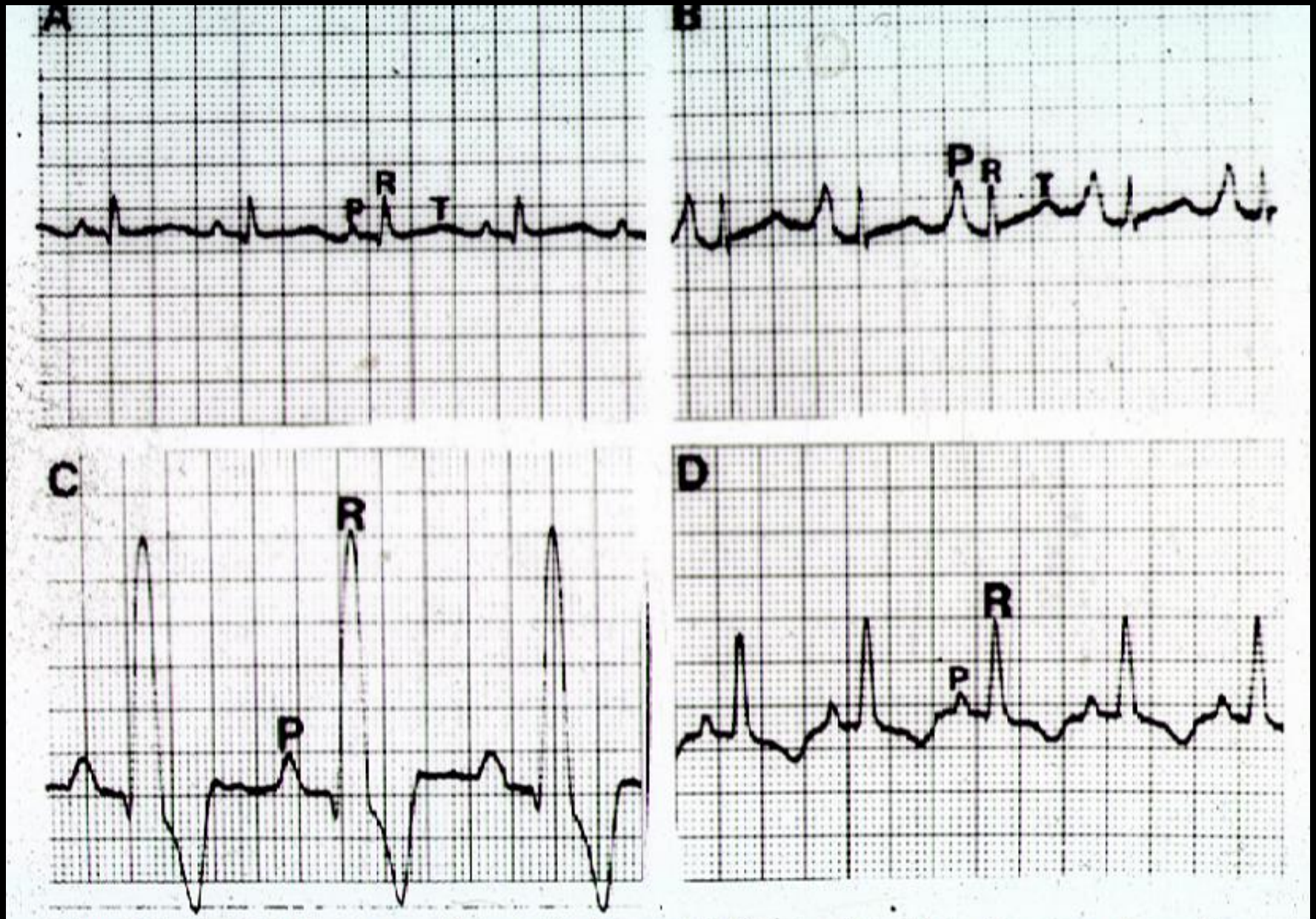

Fig. 3-4. P-QRS-T abnormalities. (A) Normal feline tracing. Note the normal small am-

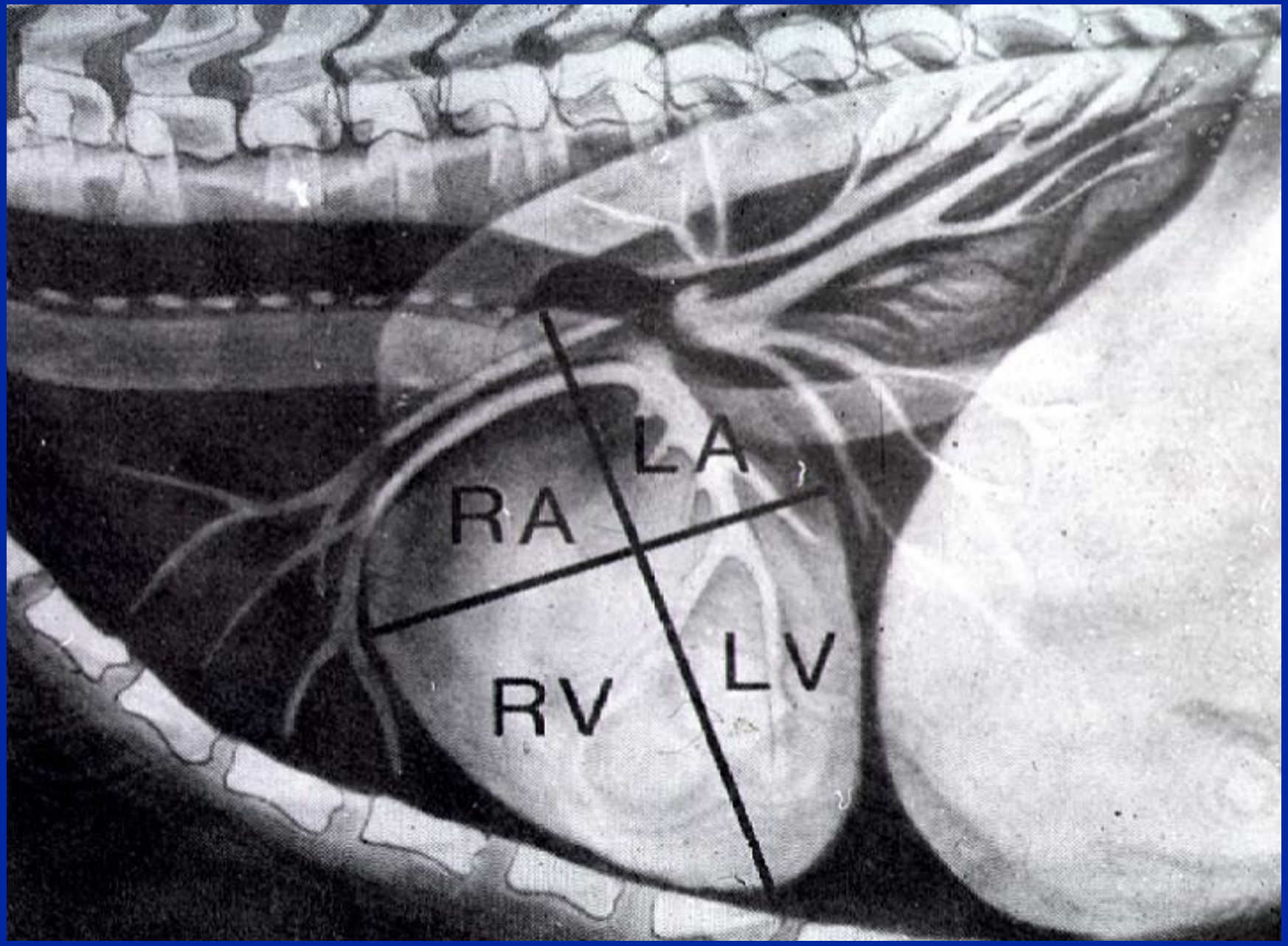
LA
RA
LV
RV

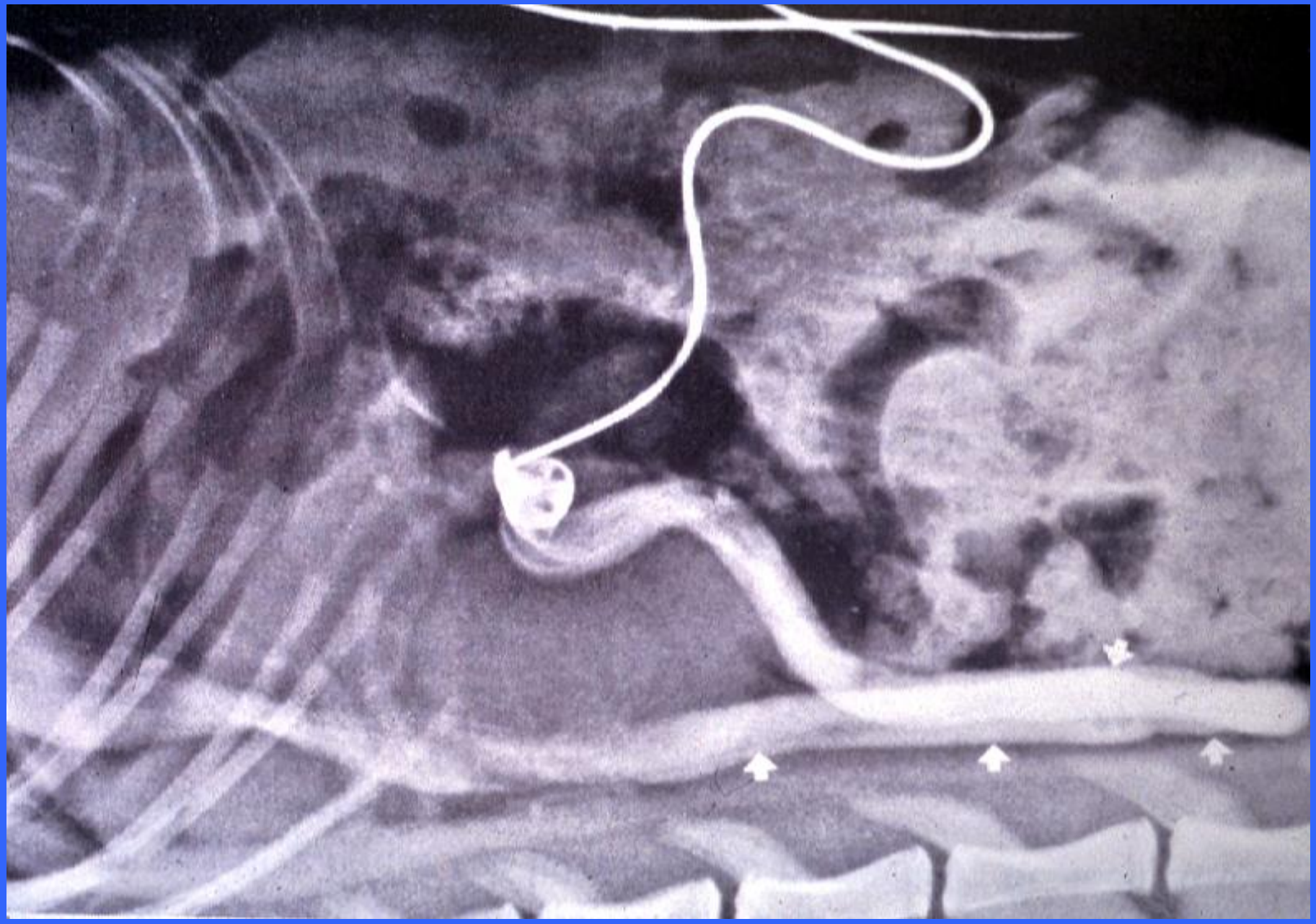

Echo

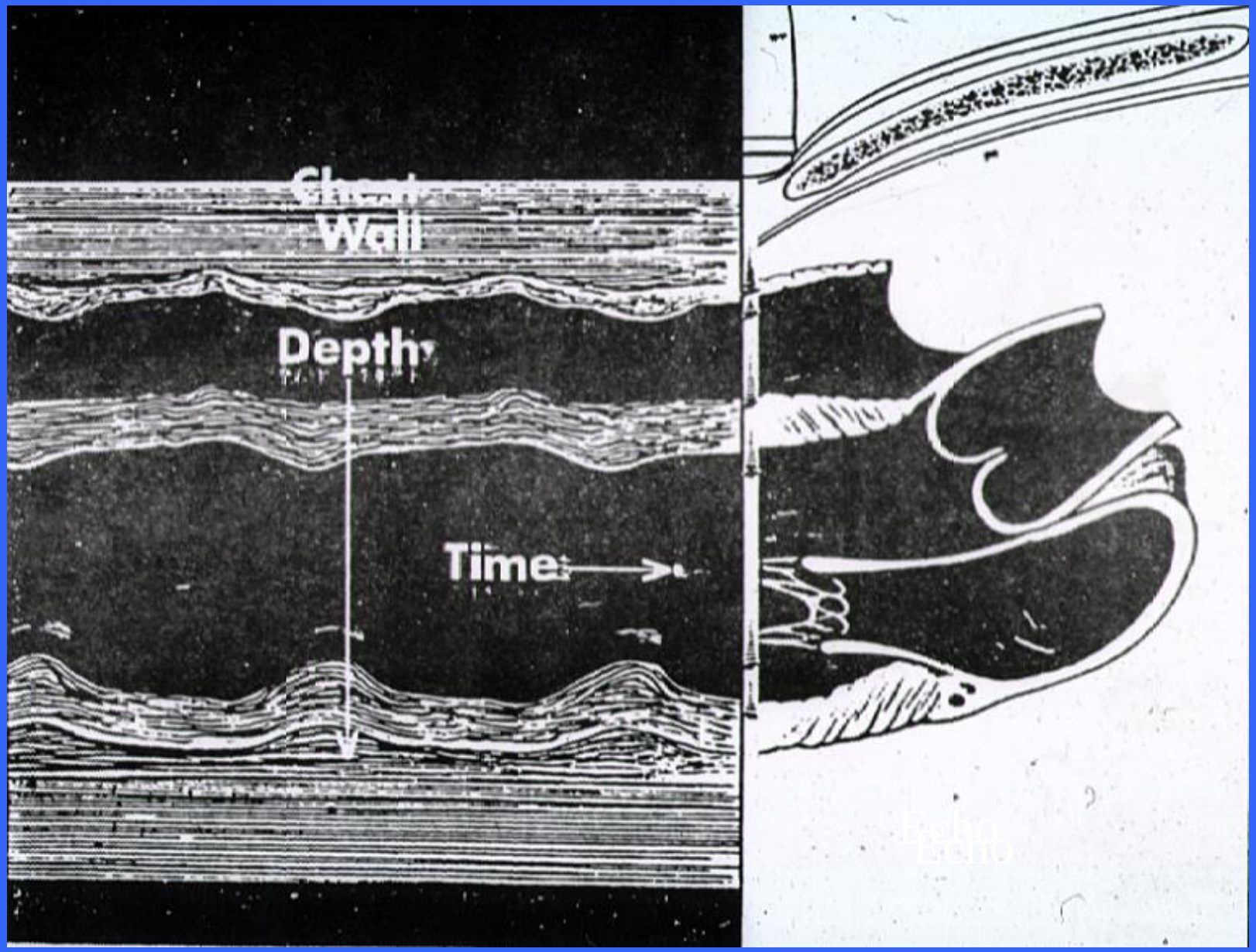

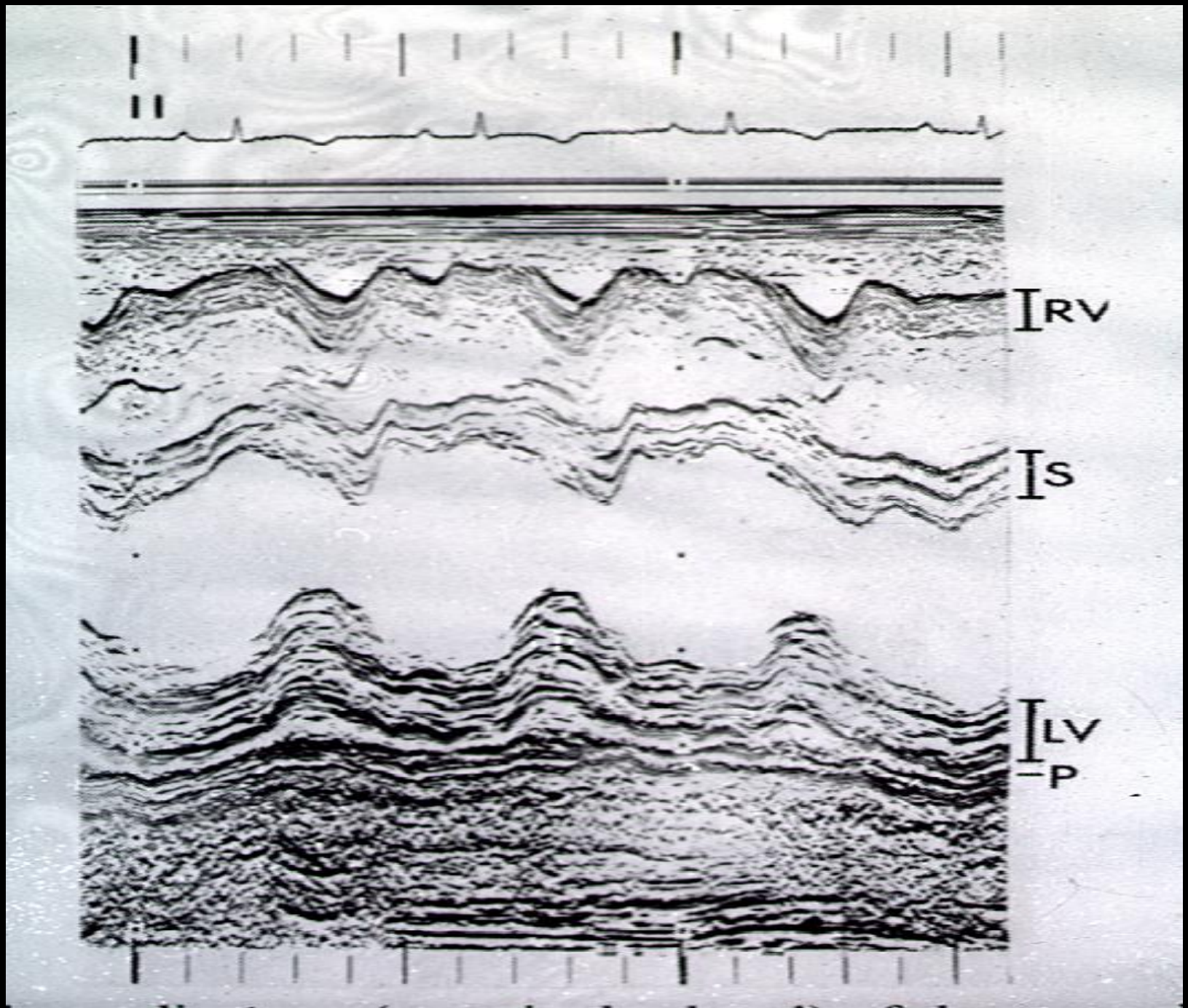
II
RV
S
LV
P

Cardiovascular pathology

Methods of clinical diagnosis

- Auscultation
- Cardiac catheterization
- Contrast radiography
- Echocardiography

Congenital abnormalities of the heart and large vessels

Congenital cardiovascular

Causes of congenital cardiac malformations

- Incidence of defects is higher in purebred populations (genetic factors)
- There is a higher incidence than recognized clinically

Trisomia in a calf

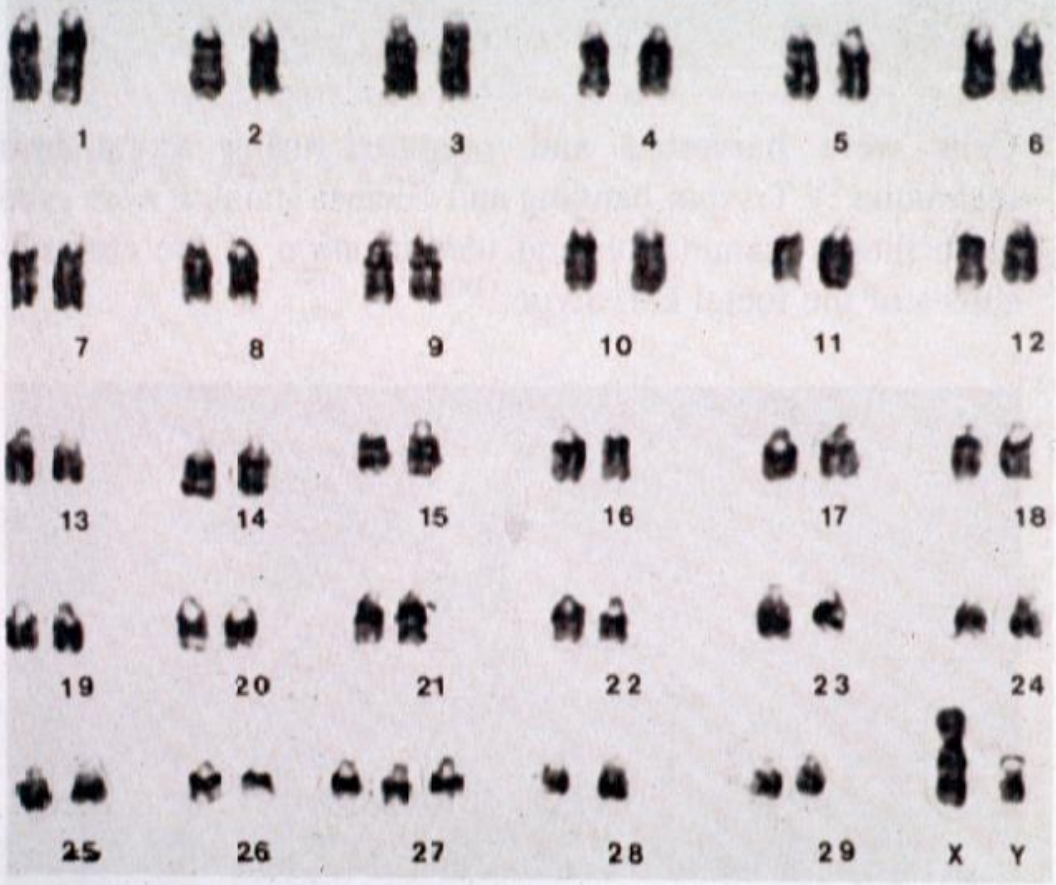

G-banded karyotype of the trisomic (T 27) foetus.

Septal defect
Pulmonary hypoplasia
Cleft palate
Kyphoscoliosisosis

Ref: J.W.Coates et al., Univ. of Saskatchewan, Canada

Congenital cardiovascular-pathology

When suspected congenital cardiac anomaly it is important to examine the heart in situ

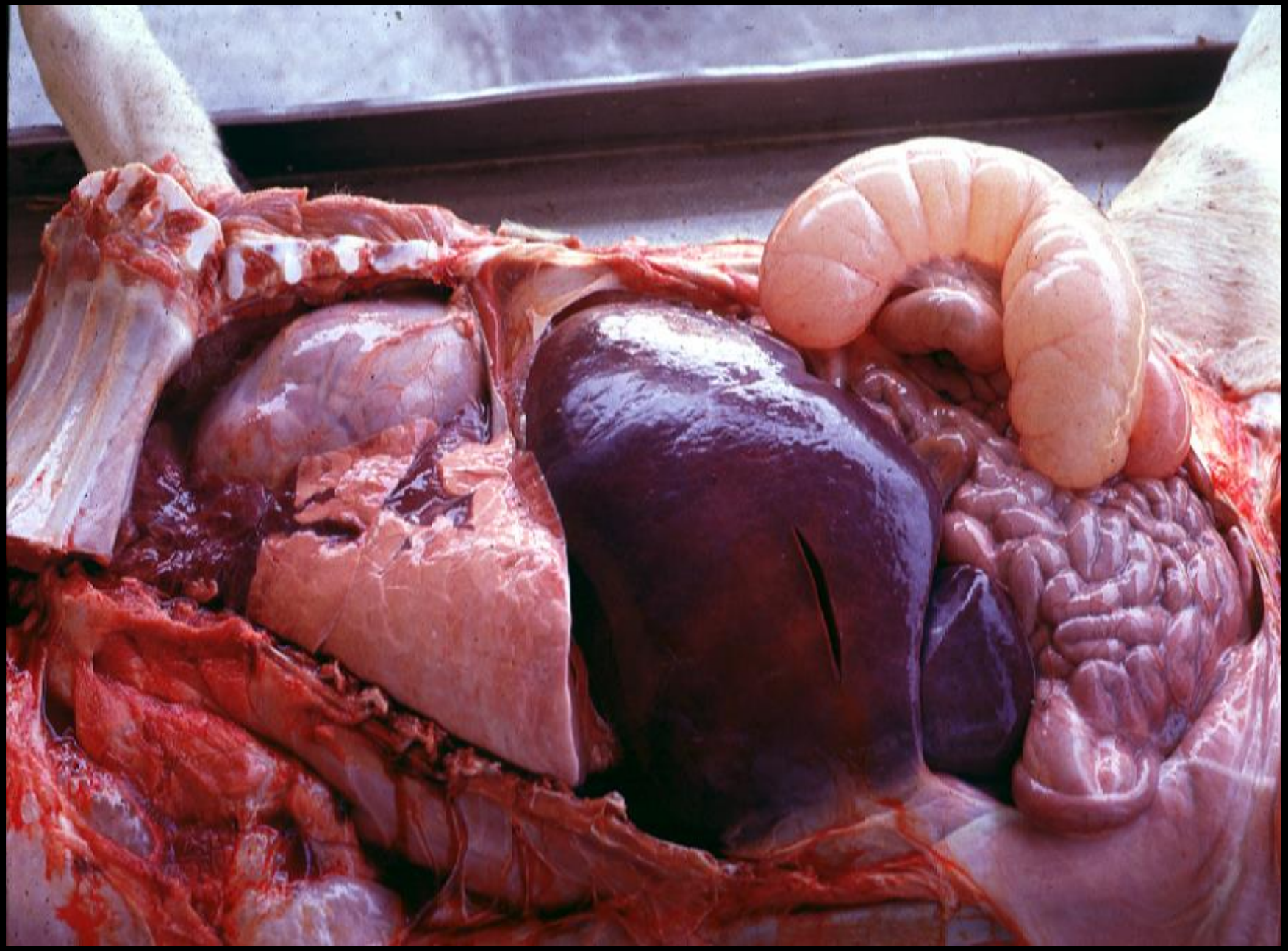

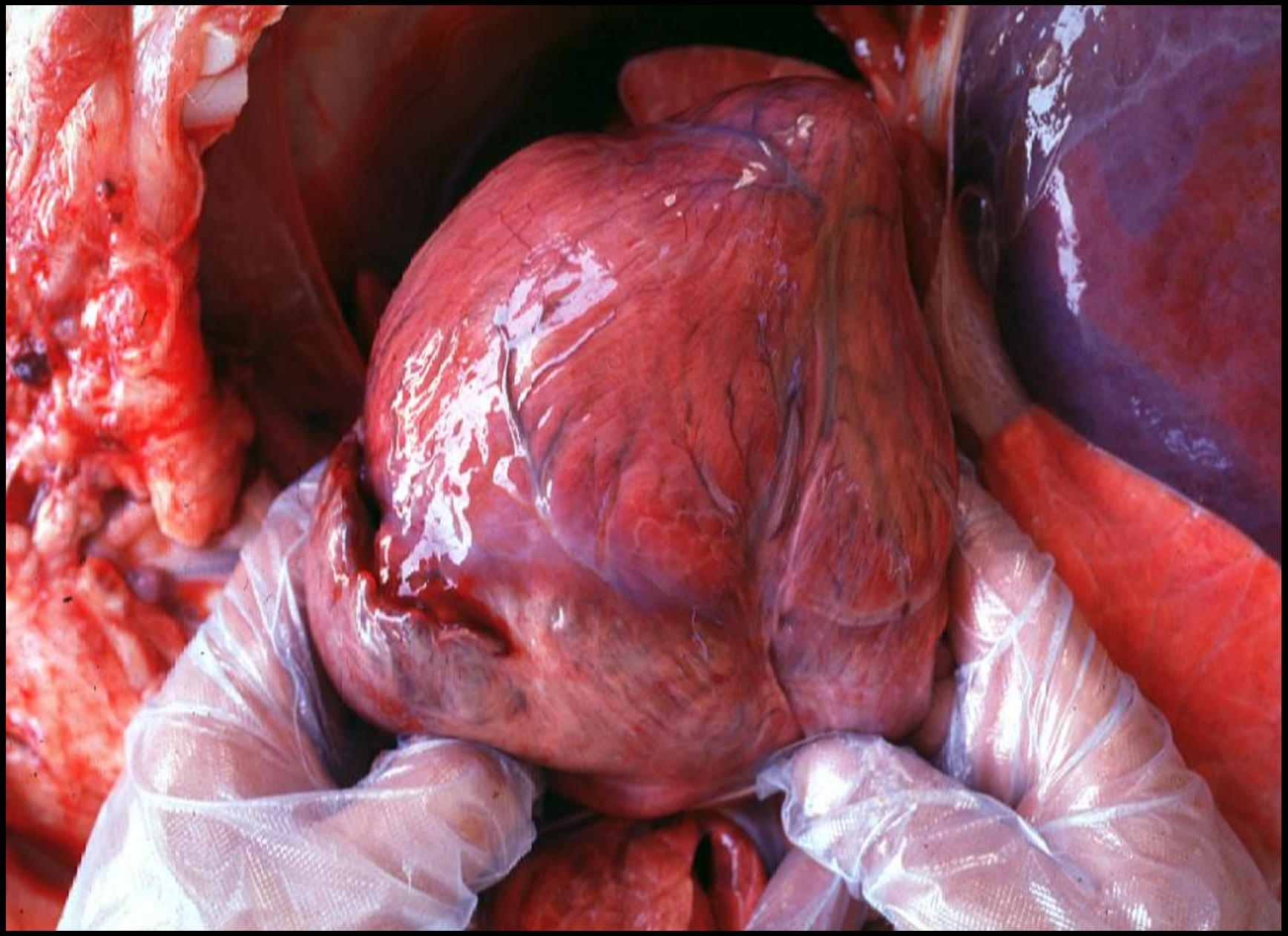

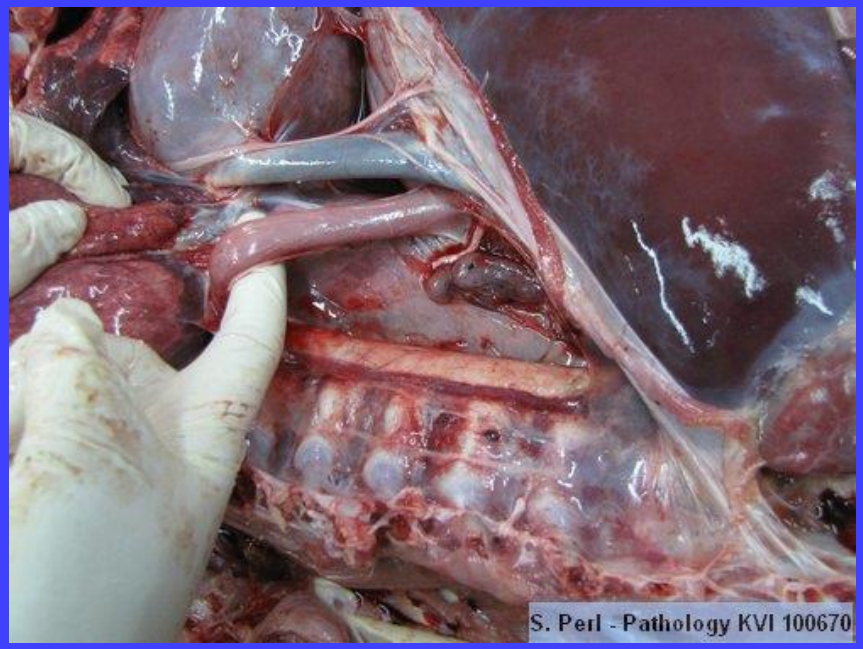
S. Perl - Pathology KVI 100670

S. Perl - Pathology KVI 100670

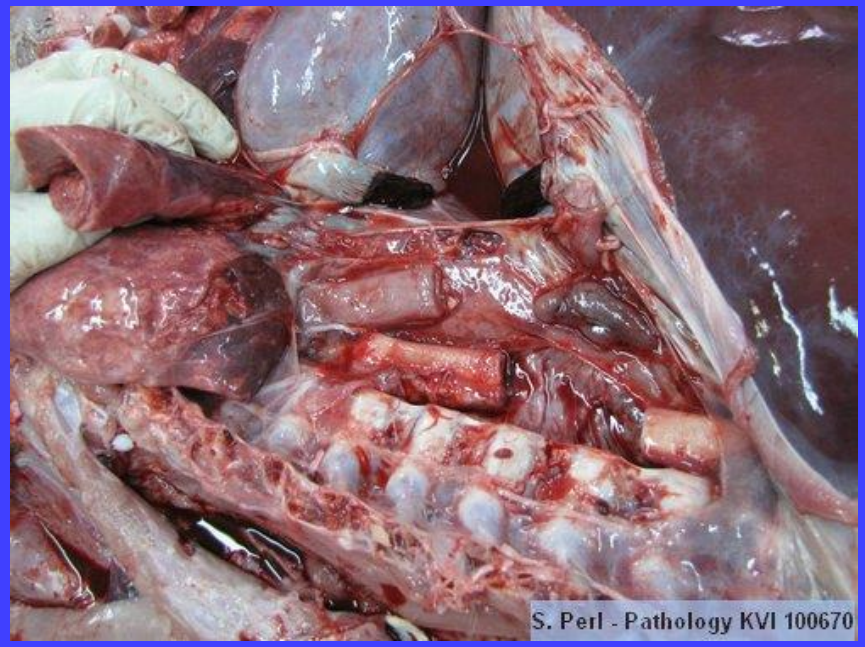
S. Perl - Pathology KVI 100670

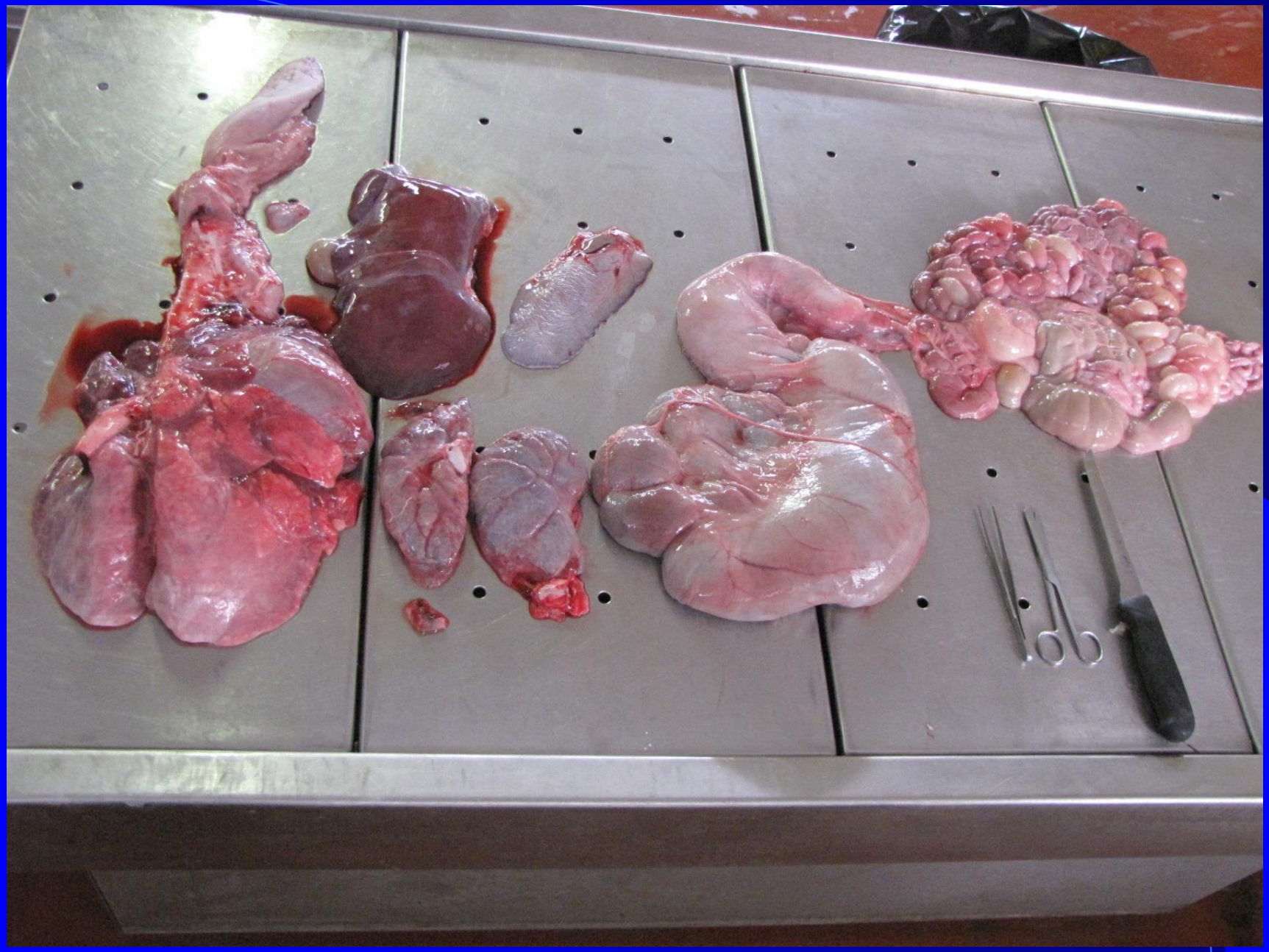

KVI-08/505663
S. Perl - Pathology KVI
S. Perl - Pathology KVI
S. Perl - Pathology KVI

Congenital heart defects

A. Failure of closure of fetal or neonatal arteriovenous communication

B. Conotruncal abnormalities

C. Failure of adequate development of semilunar or atrioventricular valves

D. Incomplete separation of, or abnormally positioned, vessels

E. Miscellaneous cardiac anomalies

Congenital heart defects

A. Failure of closure of fetal or neonatal arteriovenous communication

1. Patent ductus arteriosus - PDA
2. Atrial septal defect - ASD
3. Ventricular septal defect - VSD

Patent ductus arteriosus (PDA)

Patent ductus arteriosus

Ductus arteriosus

- **A short blood vessel**
- **Diverts a major portion of blood from the pulmonary artery to the aorta in the fetus**
- **Ductus becomes functionally closed in the first few hours after birth**

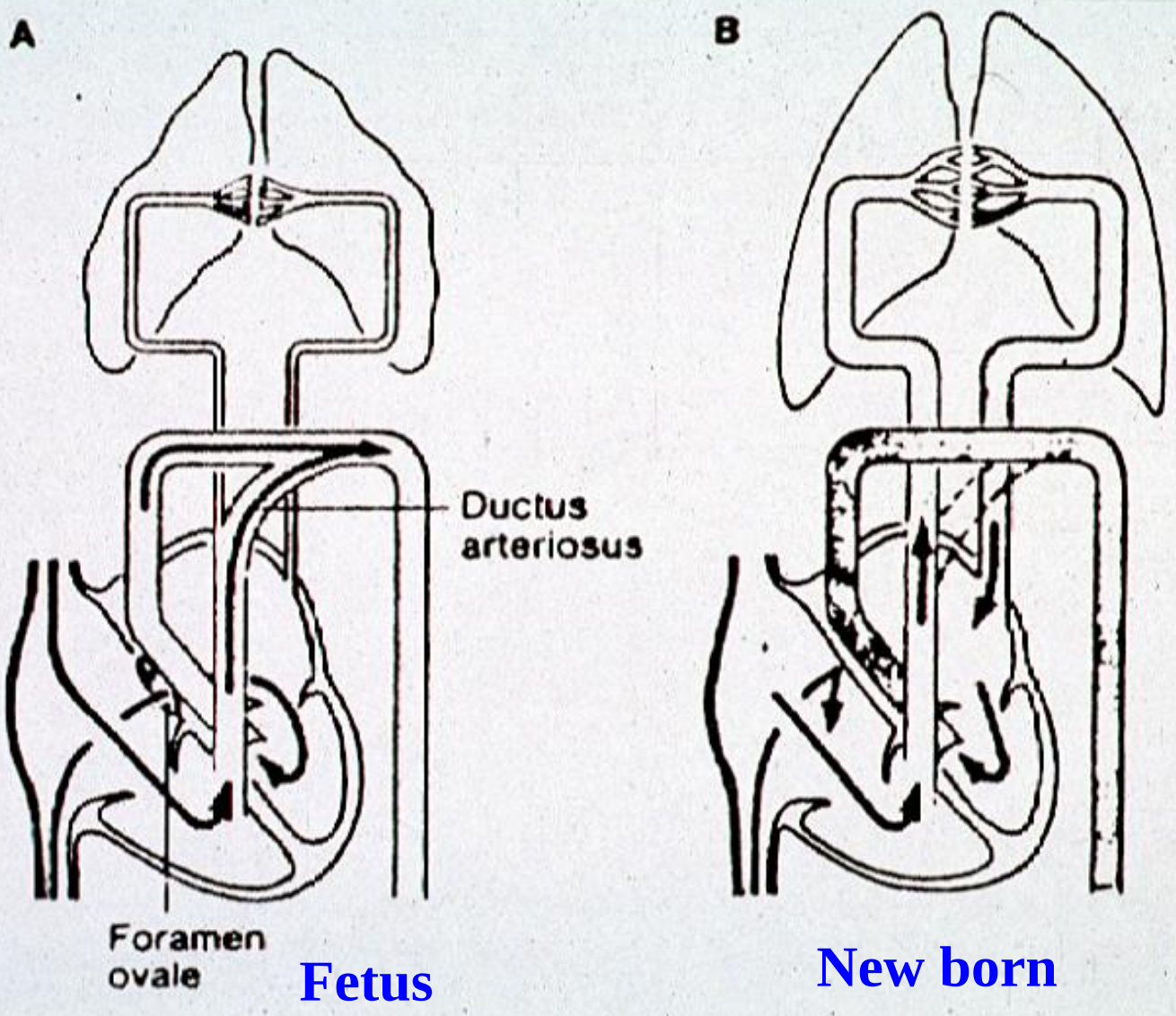
A
B
Ductus
arteriosus
Foramen
ovale
Fetus
New born

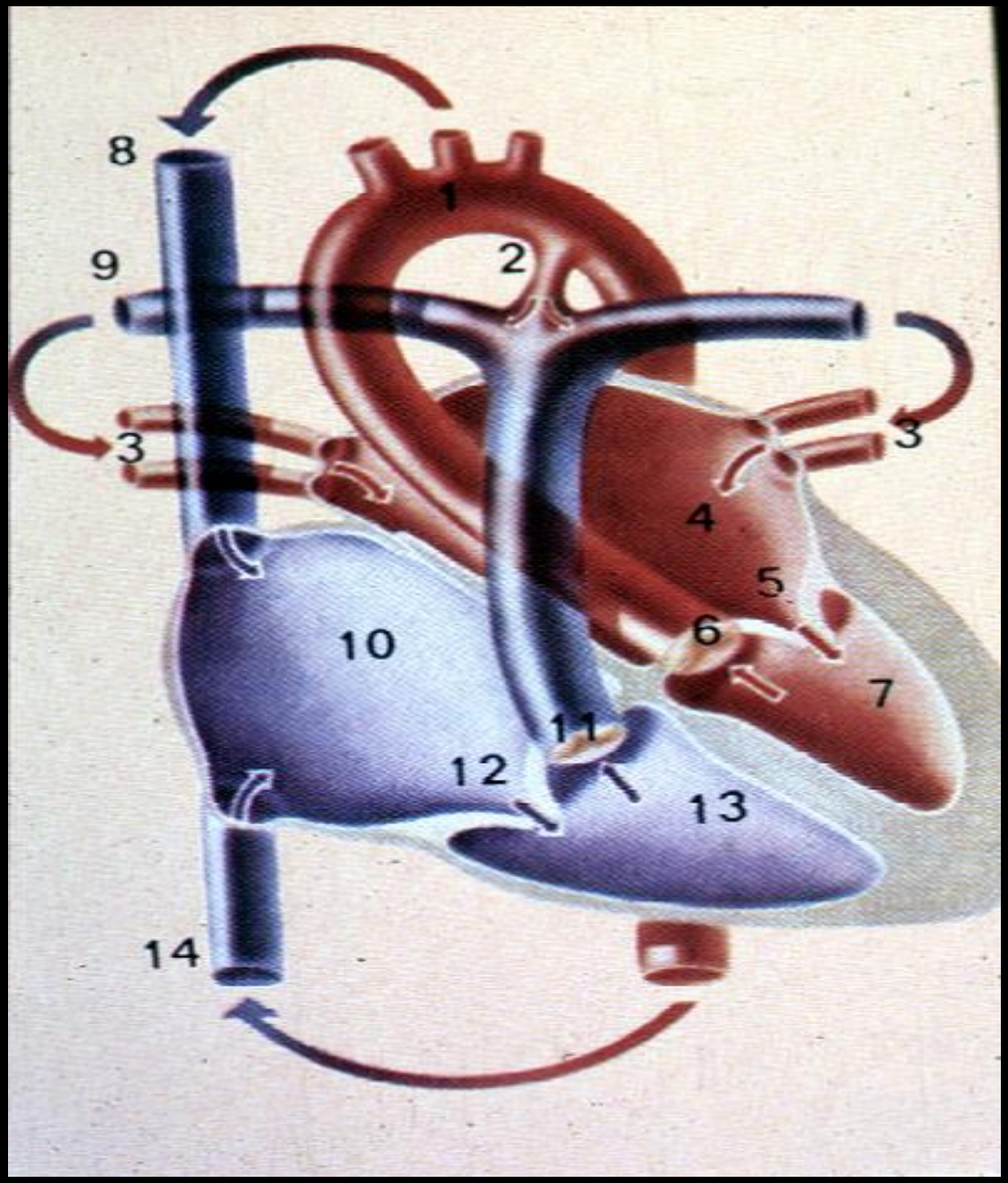

Ductus arteriosus

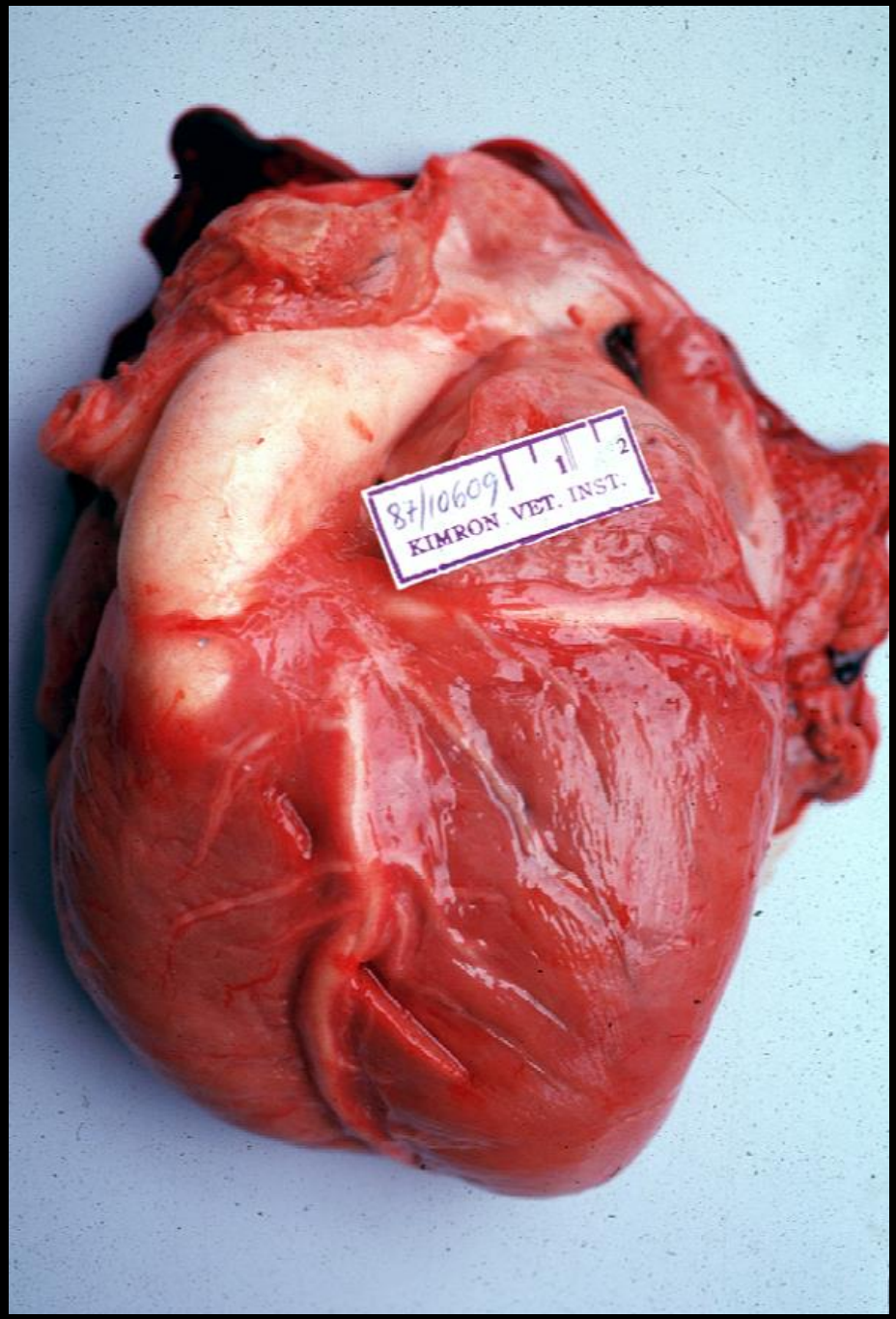

PDA

Tiger

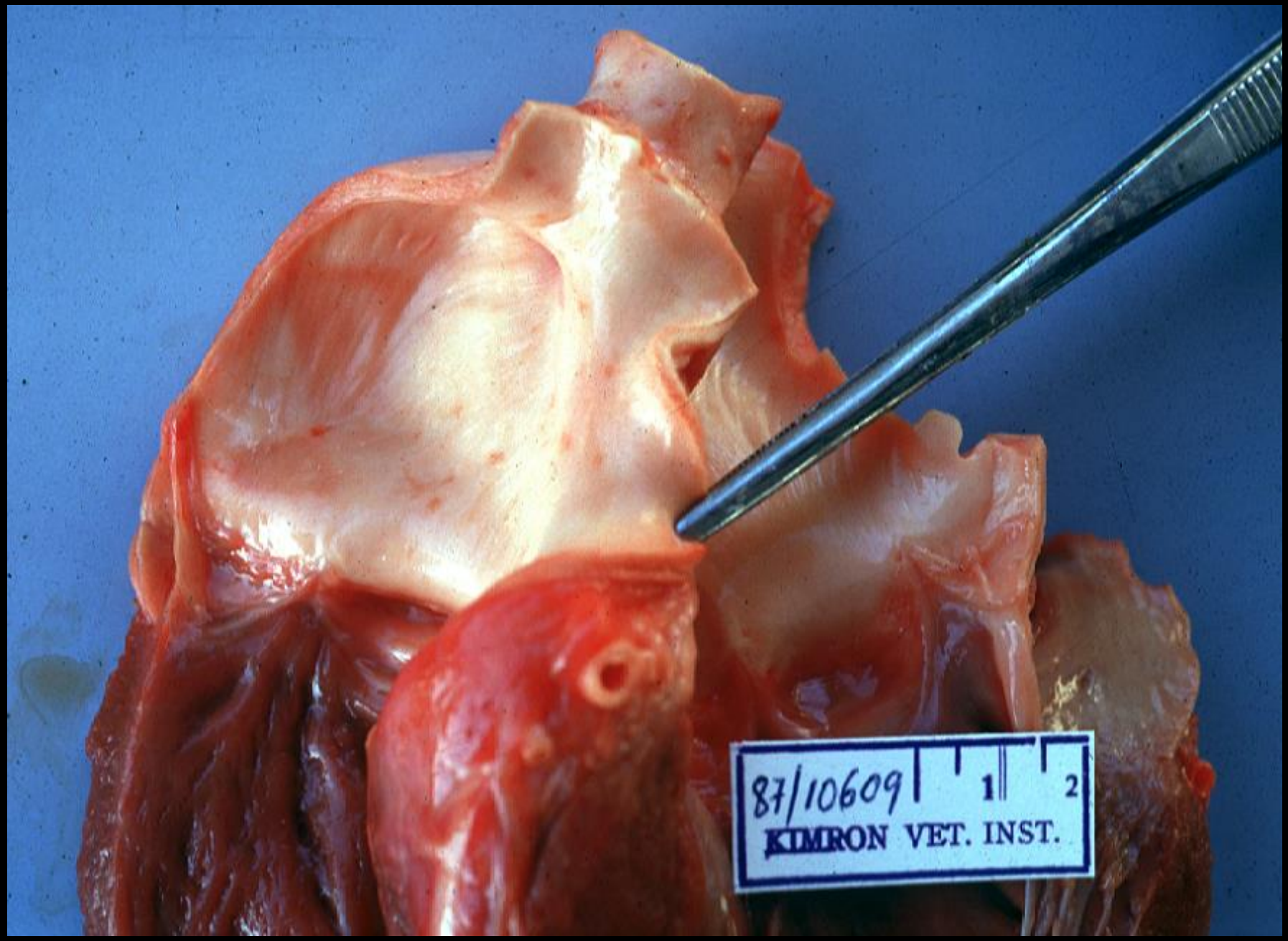
87/10609
1
2
KIMRON VET. INST.

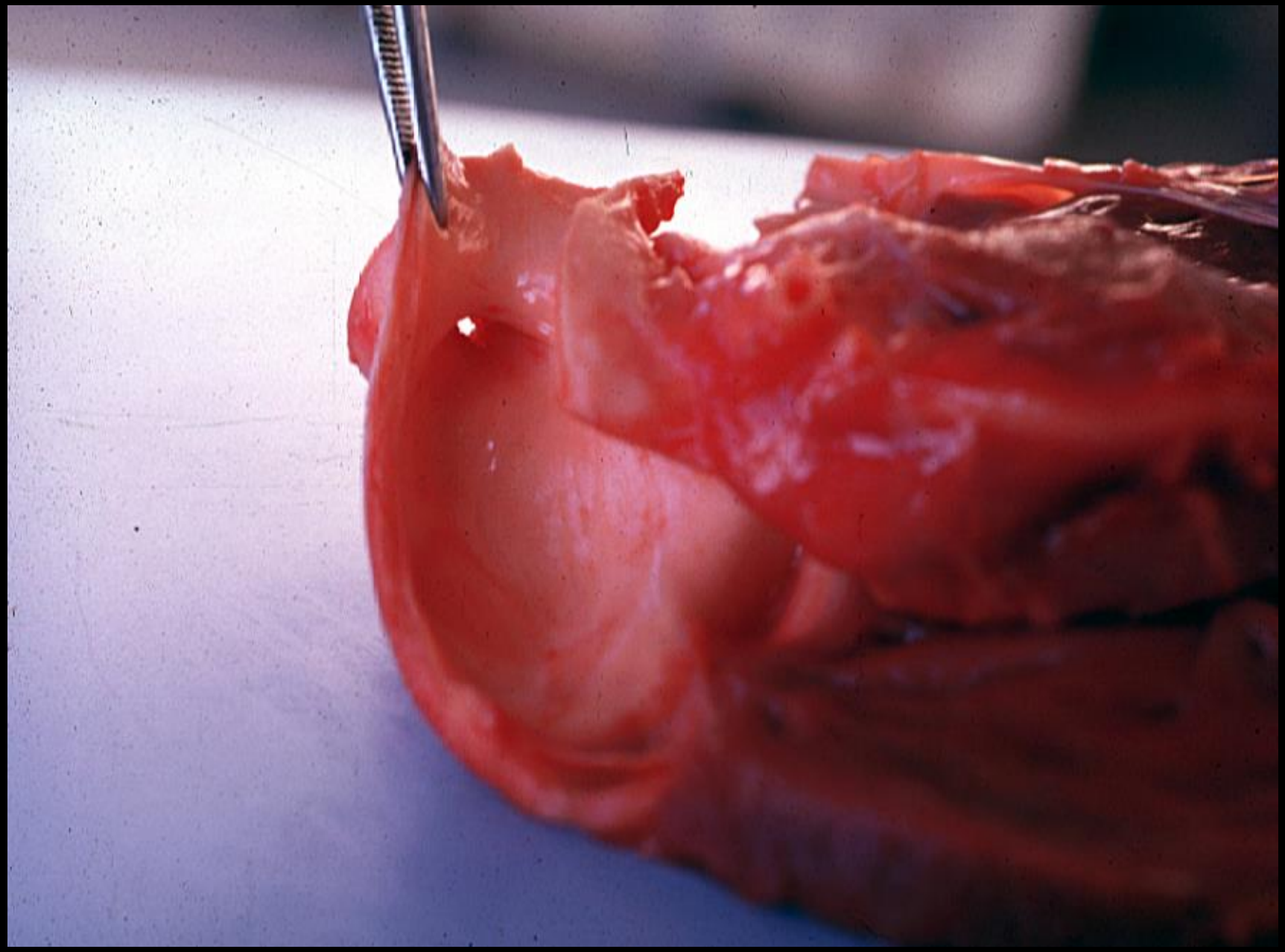

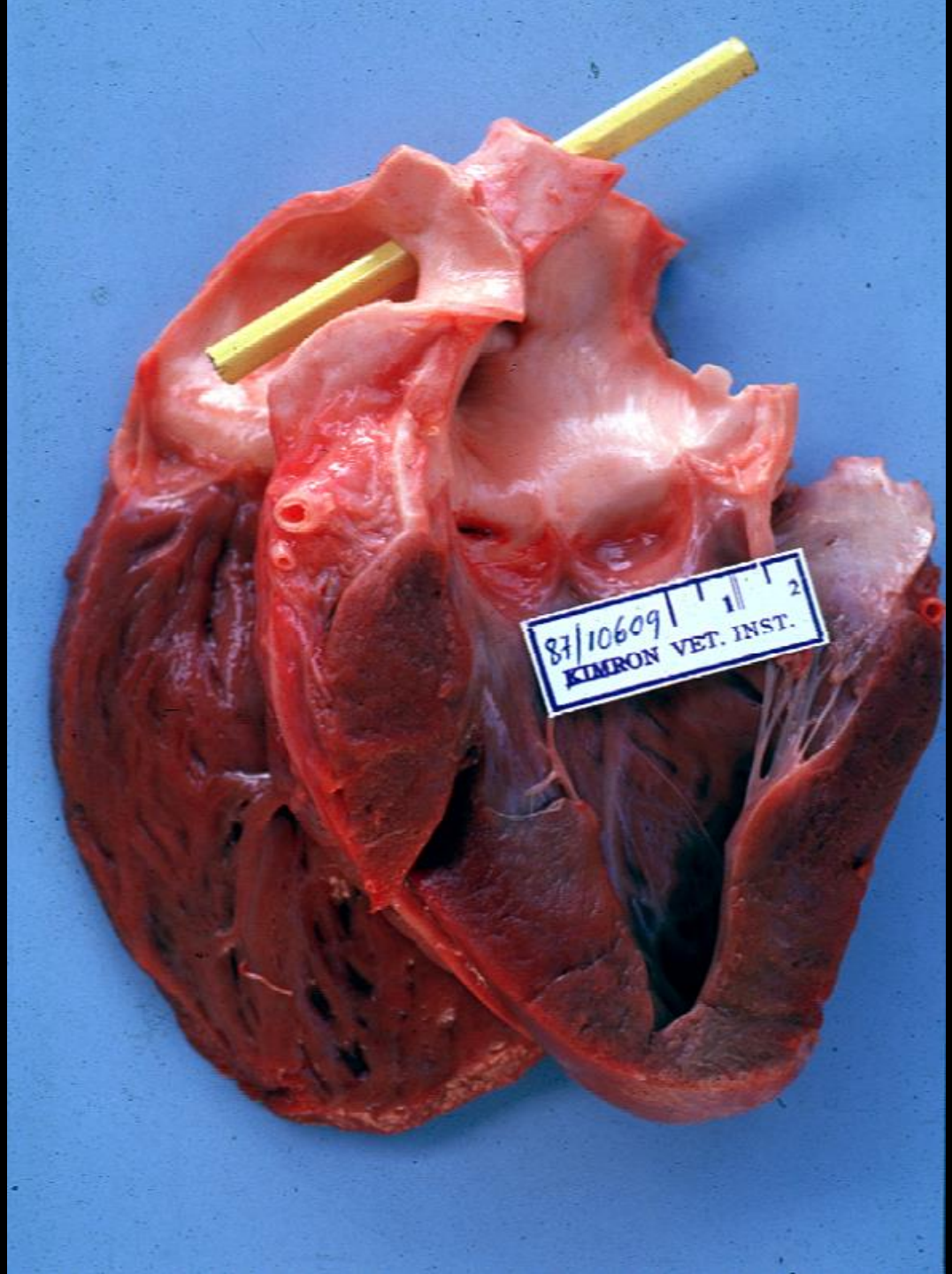
87/10609
1
2
KIMRON VET. INST.

Patent ductus arteriosus

- Ductus becomes functionally closed in the first few hours after birth
- In some foals may remain patent up to 5 days
- Ductus arteriosus patent beyond this time is considered to be abnormal

Patent ductus arteriosus

Several days after birth

Lumen closed

Ligamentum arteriosum

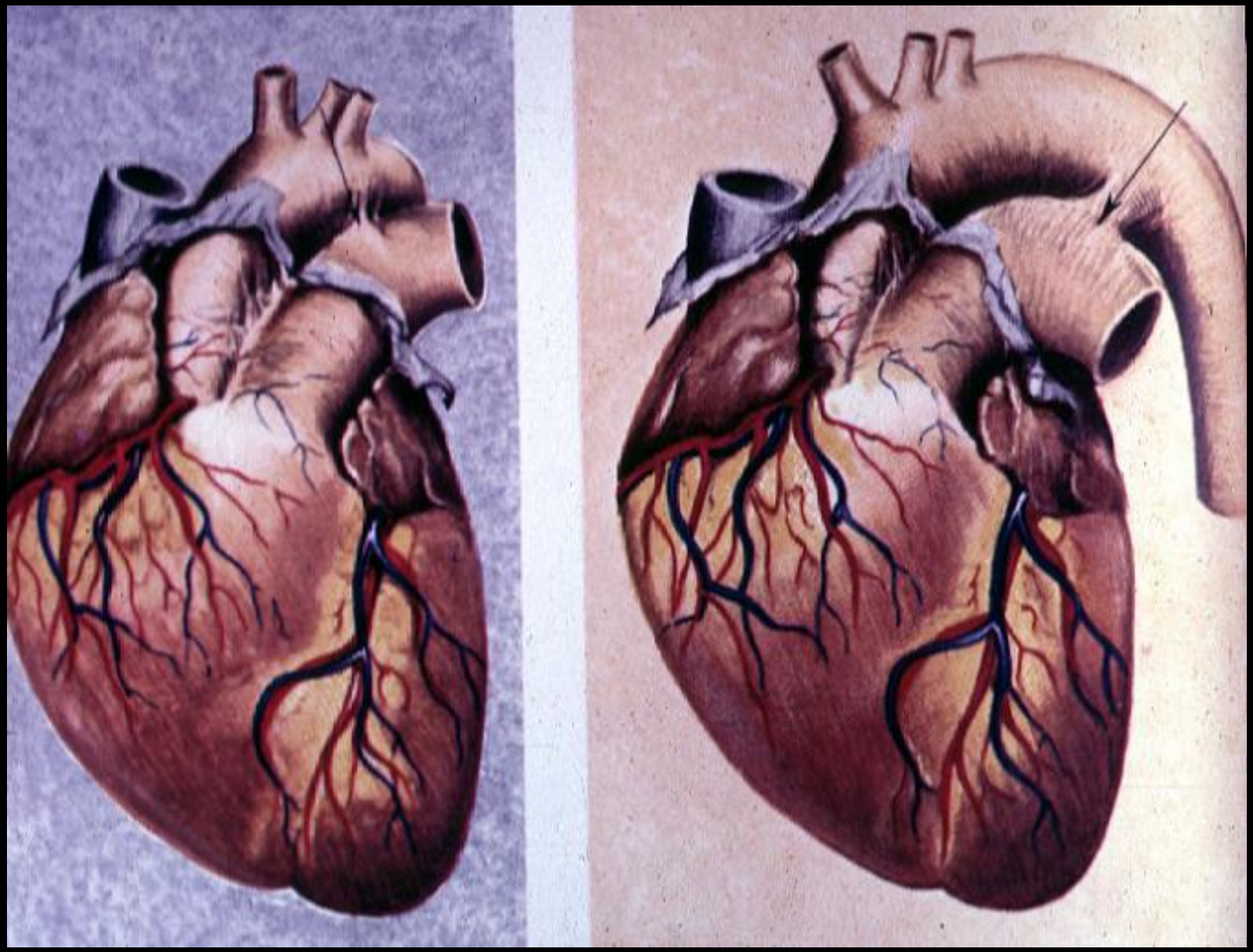

Patent ductus arteriosus

- **Effects**

  Turbulent flow at the opening

  Left to right shunt

  Pulmonary hypertension

  Reversed shunt > cyanosis

  Ventricular hypertrophy (right)

  Congestive heart failure

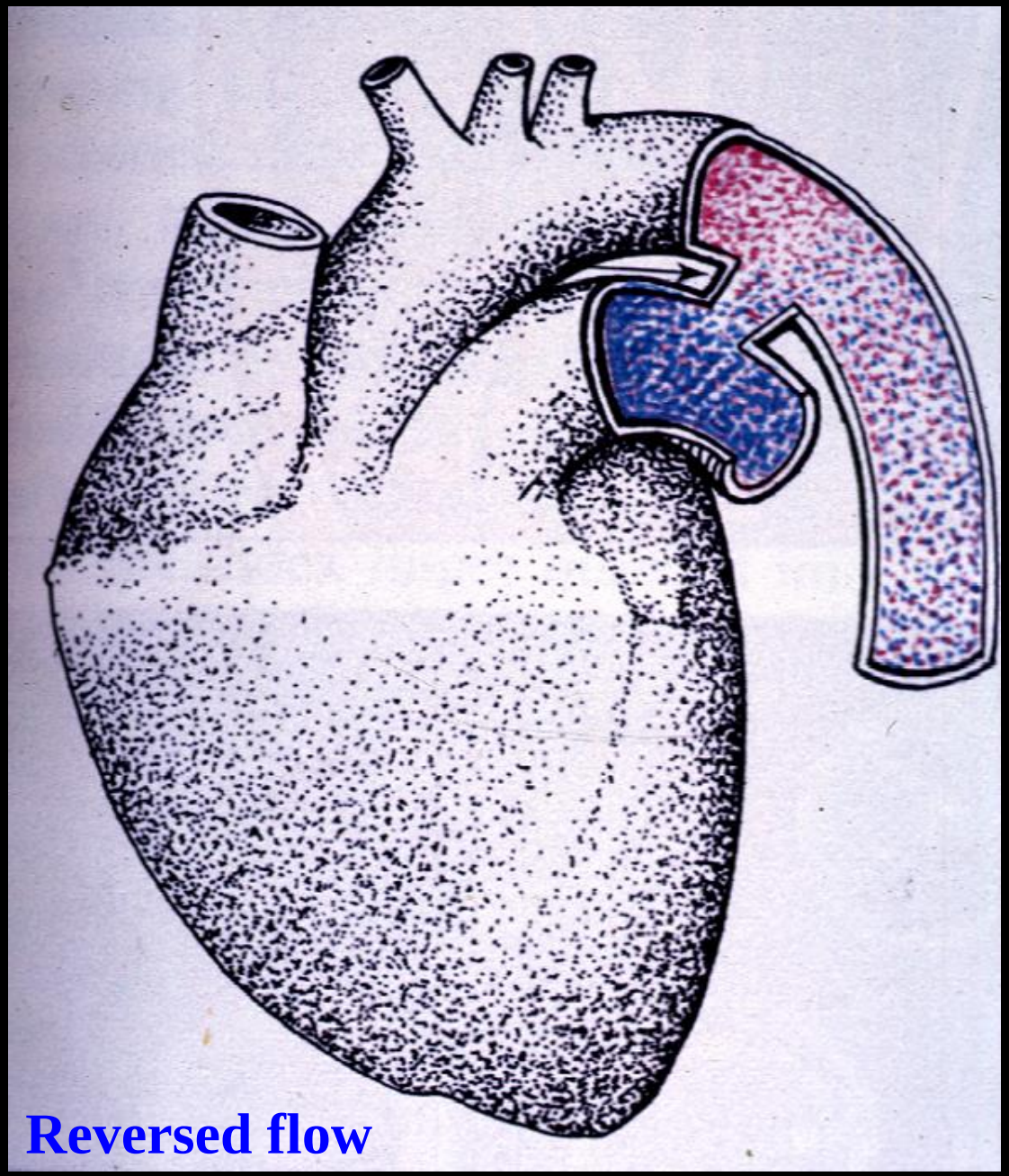

PDA

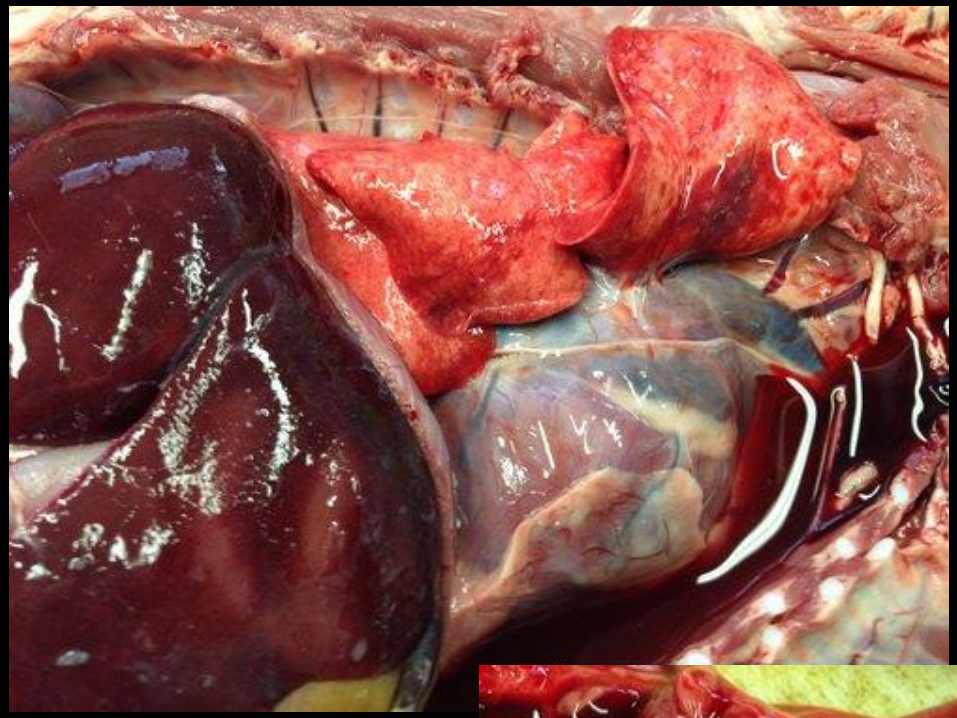

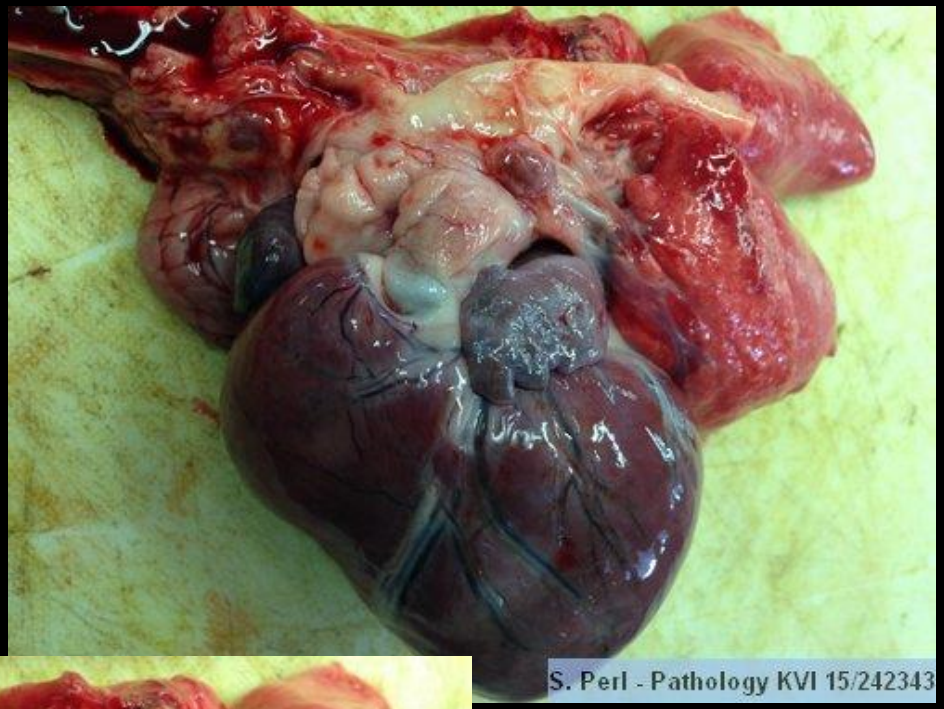
S. Perl - Pathology KVI 15/242343

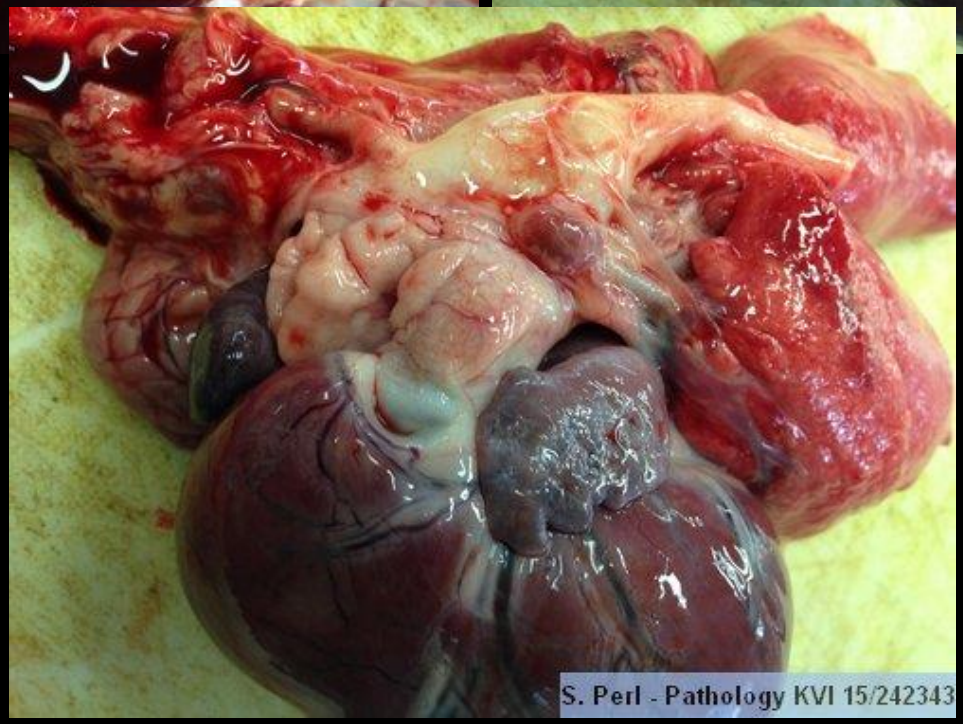
S. Perl - Pathology KVI 15/242343

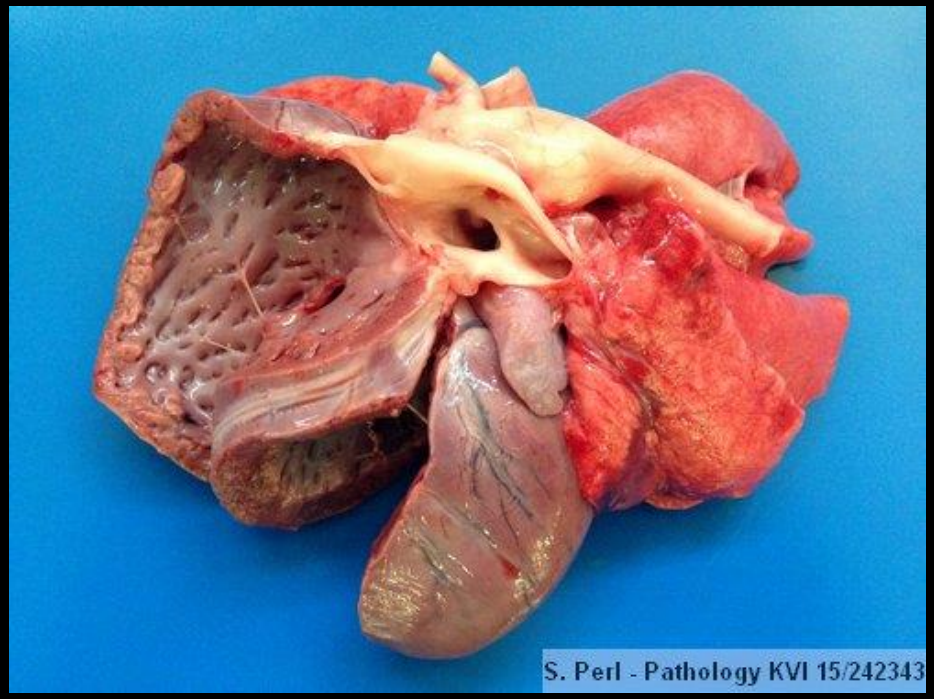
S. Perl - Pathology KVI 15/242343

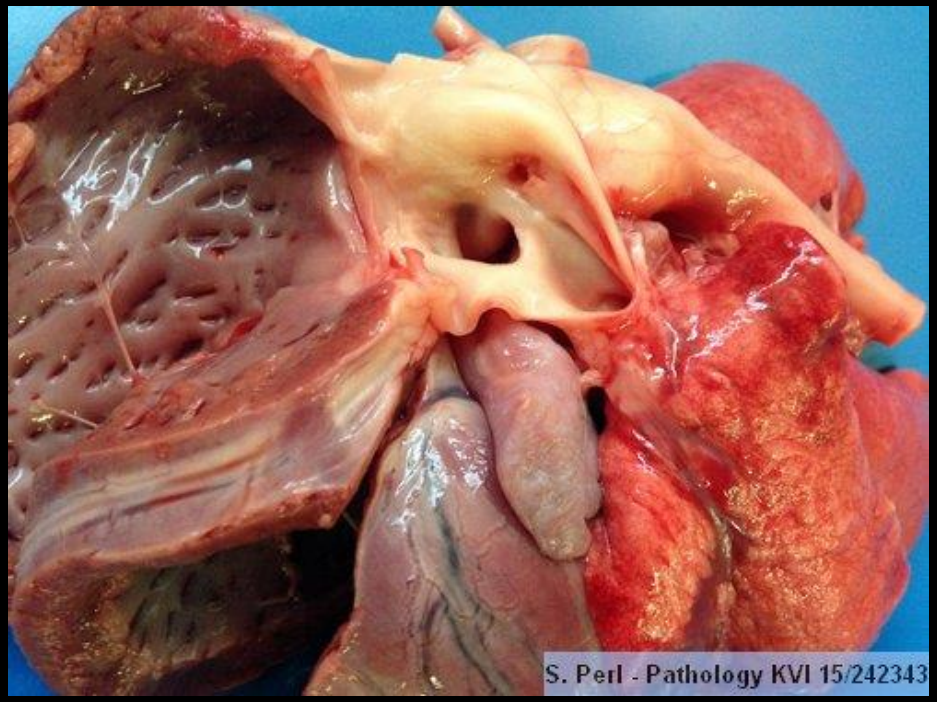
S. Perl - Pathology KVI 15/242343

Maltese 4 mo.

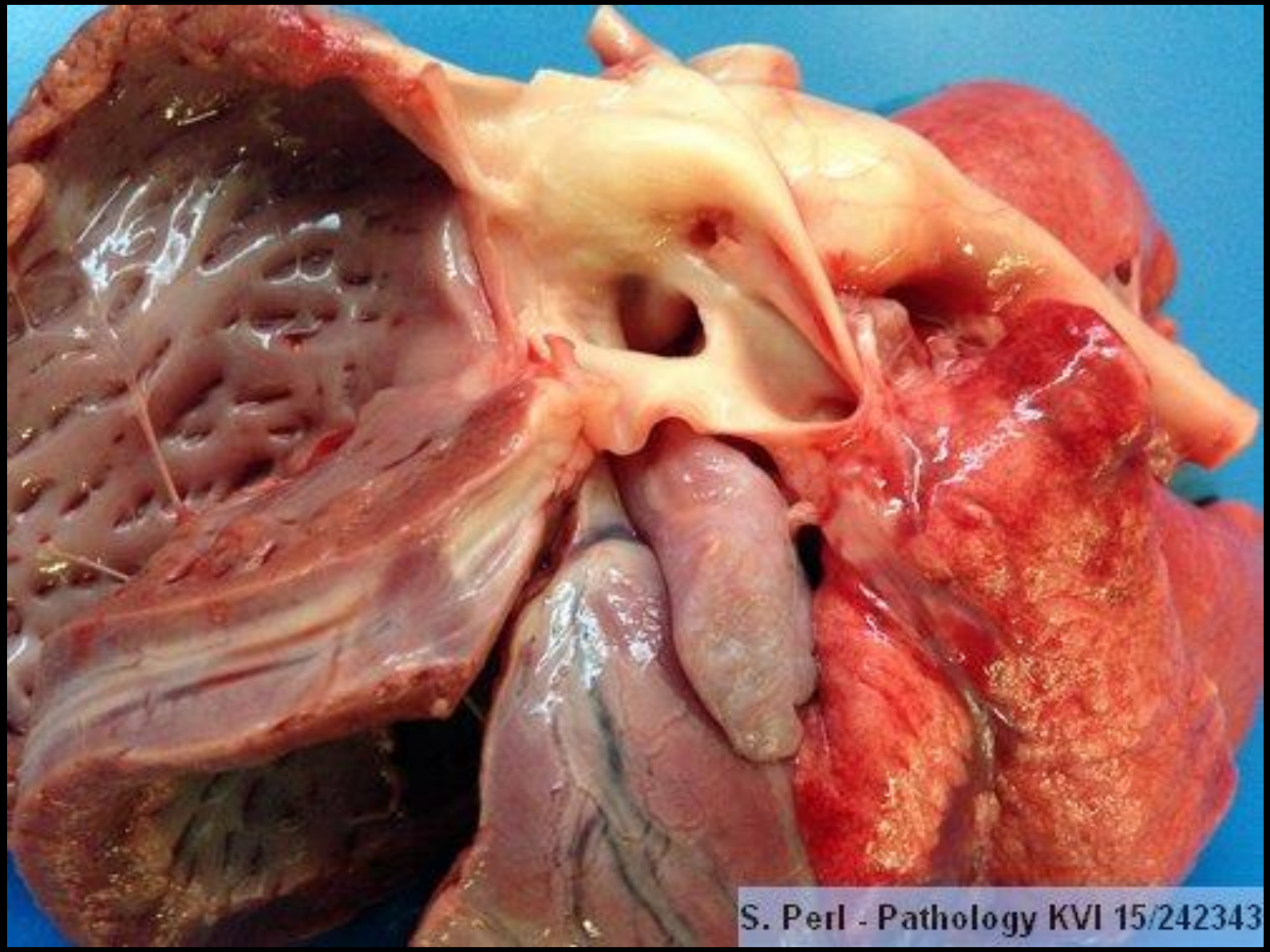
S. Perl - Pathology KVI 15/242343

Patent ductus arteriosus

Chihuahua
Collie
Miniature Poodle
Pomeranian
English springer spaniel
Keeshound
Shetland Sheepdog
Maltese
German Shepherd
Yorkshire Terrier

Atrial septal defect (ASD)

ATRIAL SEPTAL DEFECT

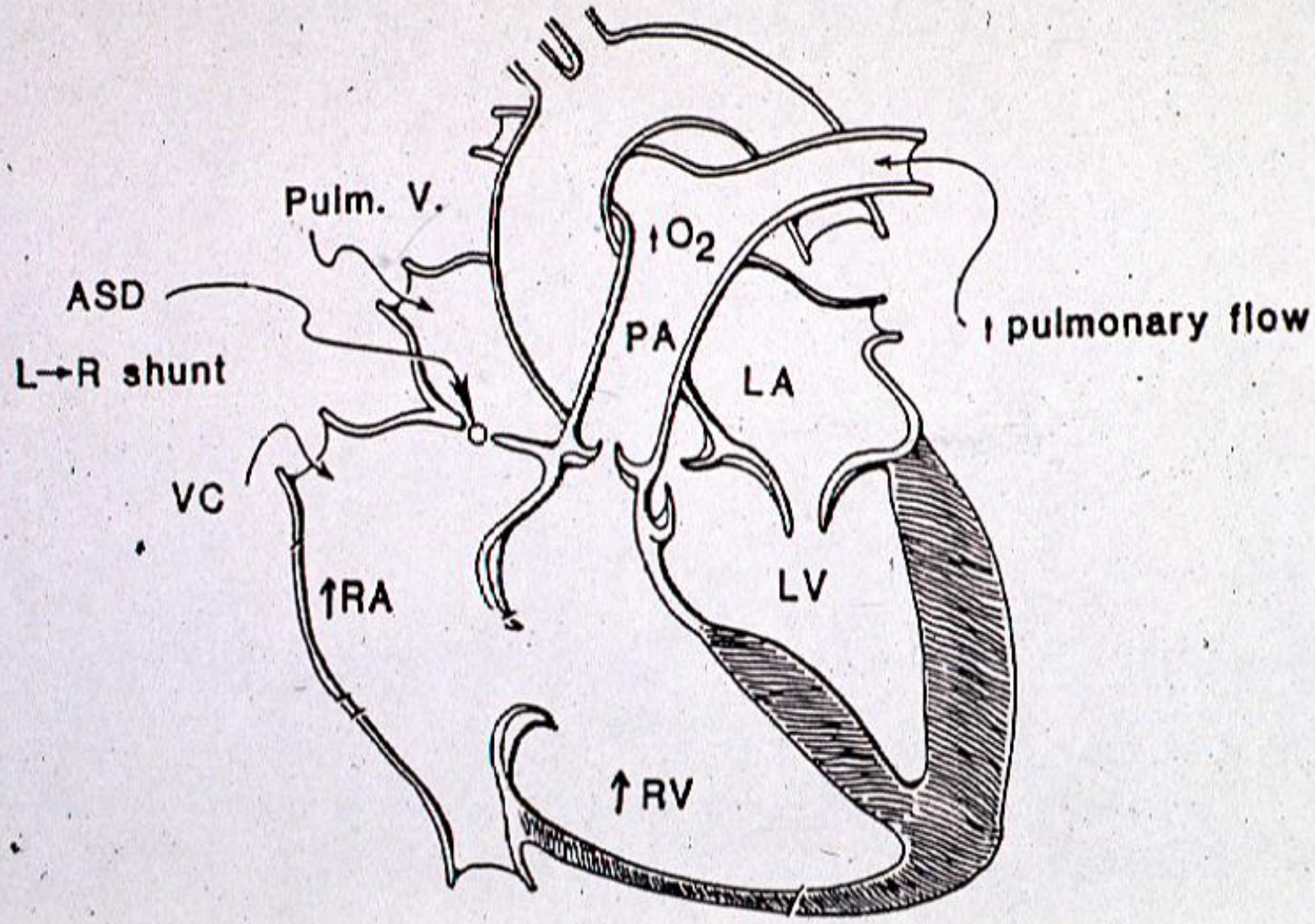

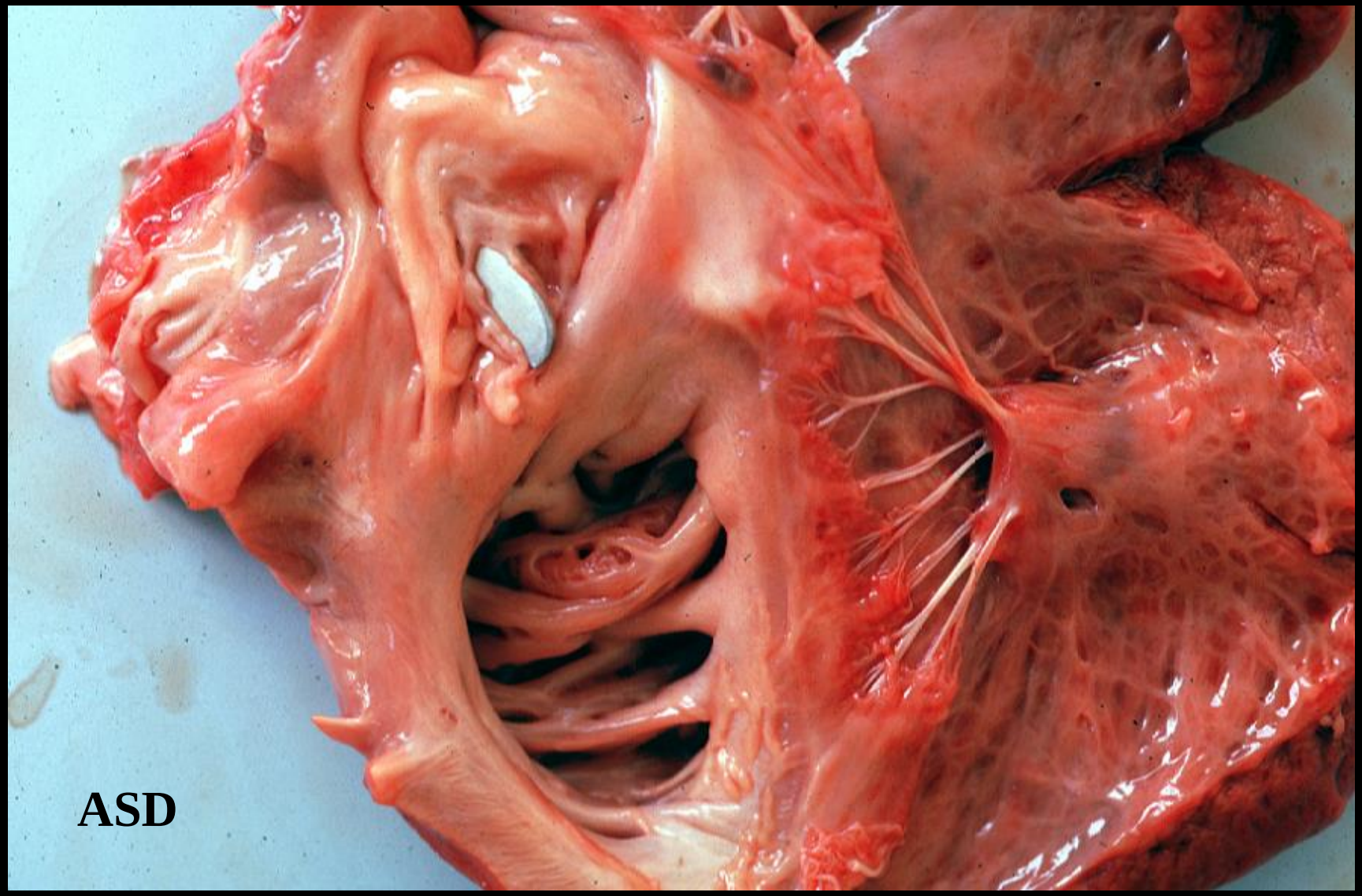
ASD

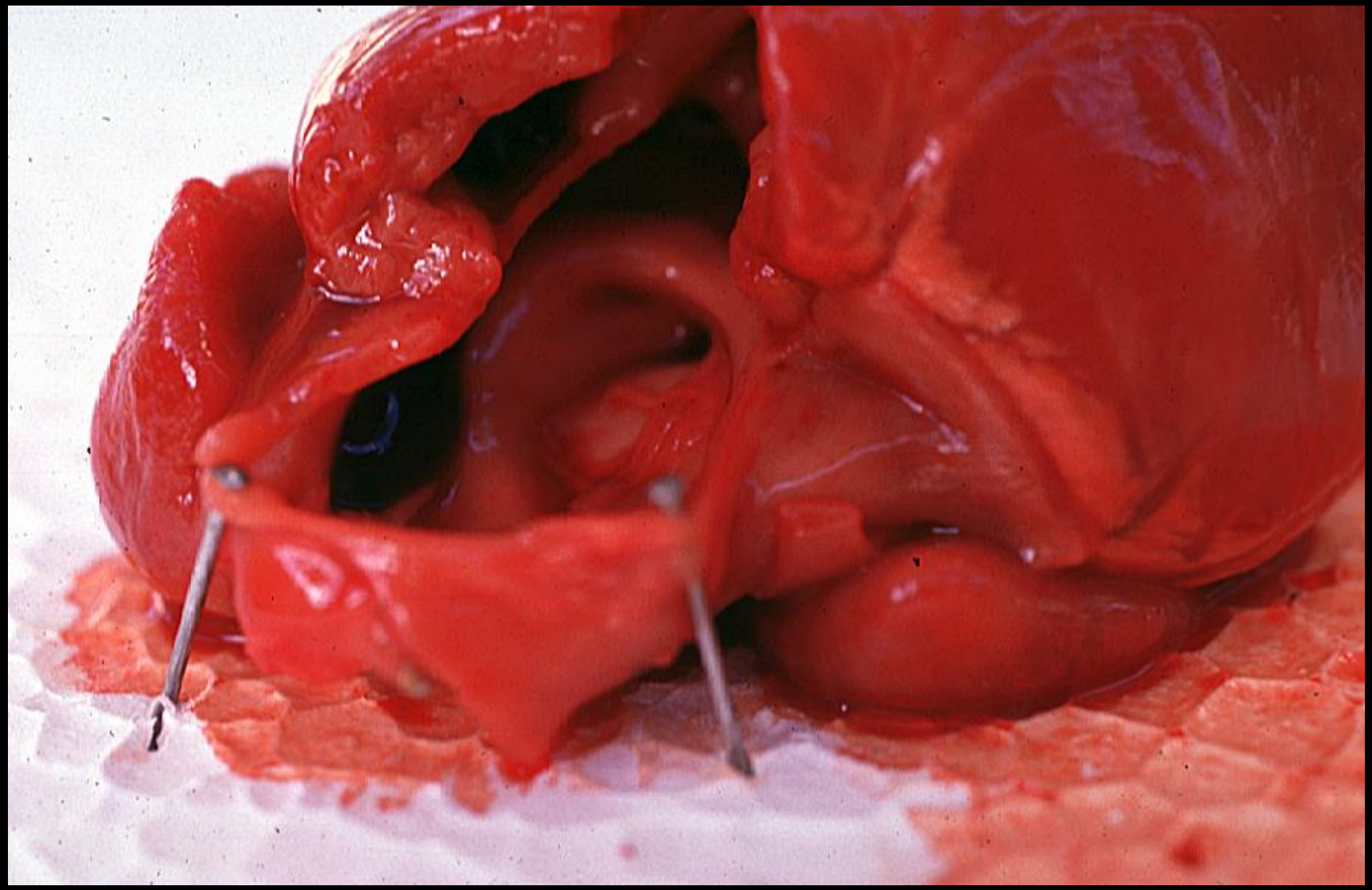

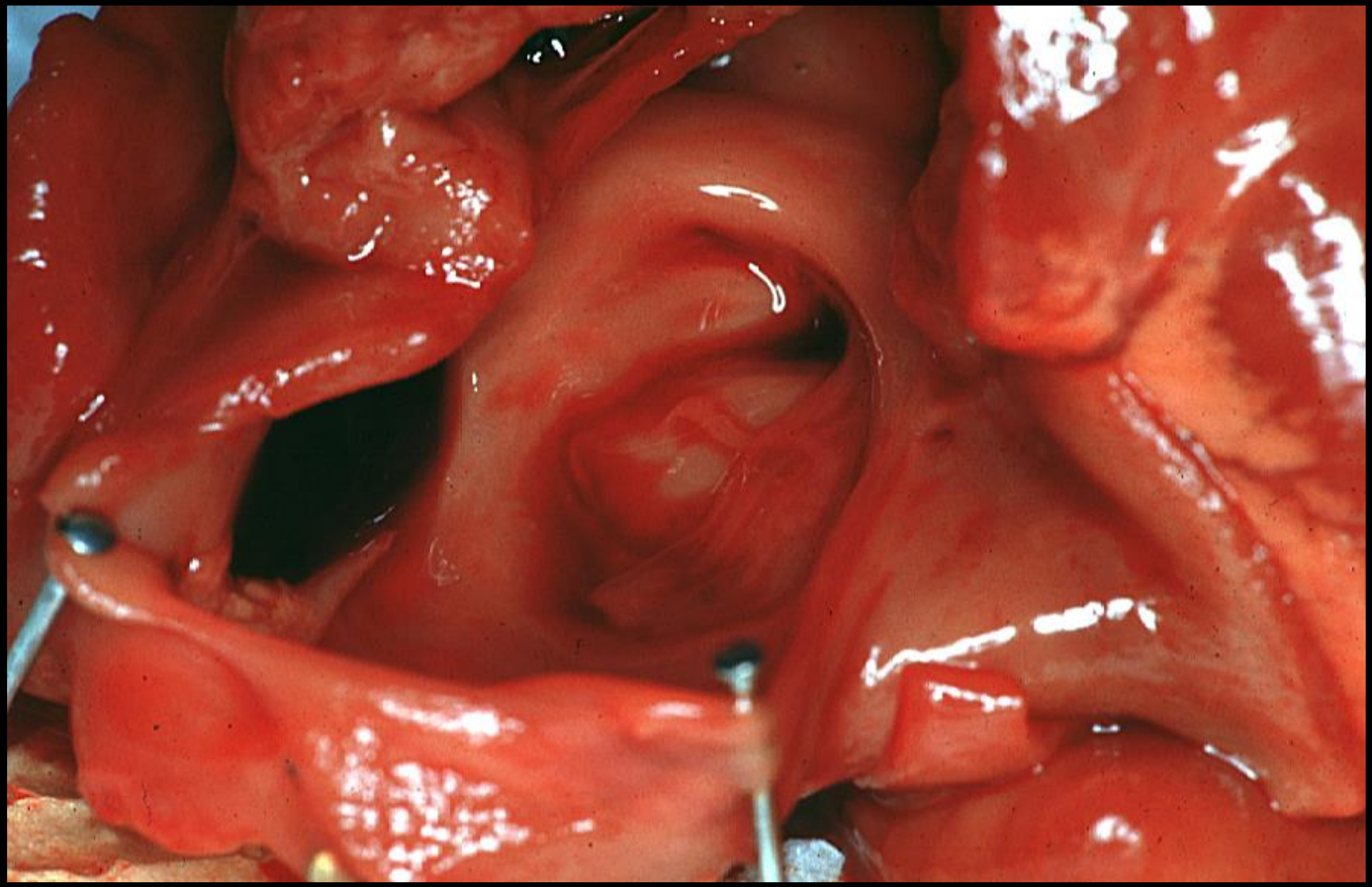

Atrial septal defect

- Failure of fusion of septum primum with the endocardial cushions (ostium primum)
- Failure of growth of septum secundum
- Failure of closure of the foramen ovalae

Atrial septal defect

- **Effects**

  Excessive flow from the left to right atrium

  Continued overload of right side of heart

  Hypertrophy of right heart

  Pulmonary hypertension

  Cyanosis, reversed flow

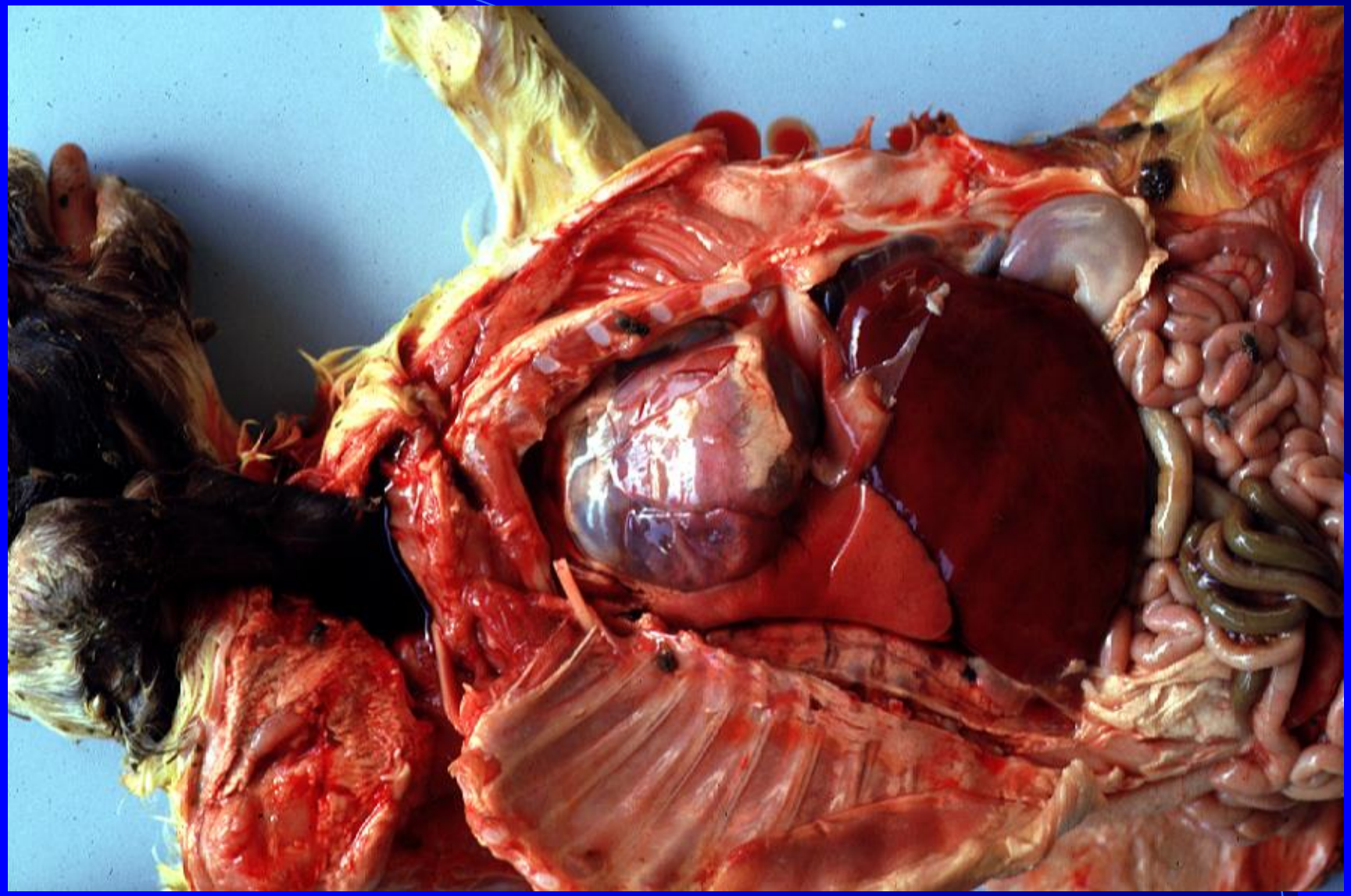

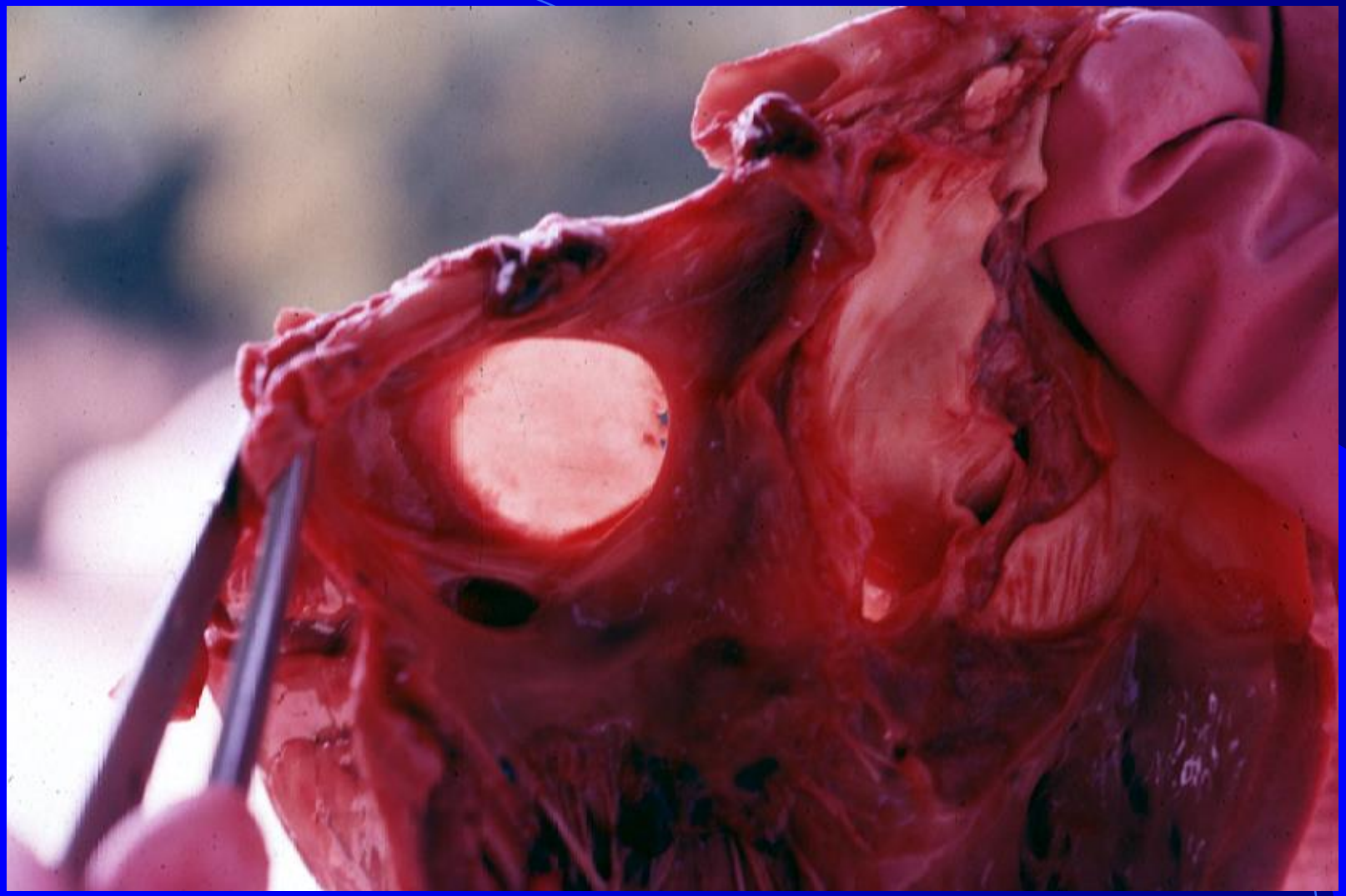

Atrial septal defect

Boxer

Doberman pinscher

Samoyed

Ventricular septal defect (VSD)

VENTRICULAR SEPTAL DEFECT

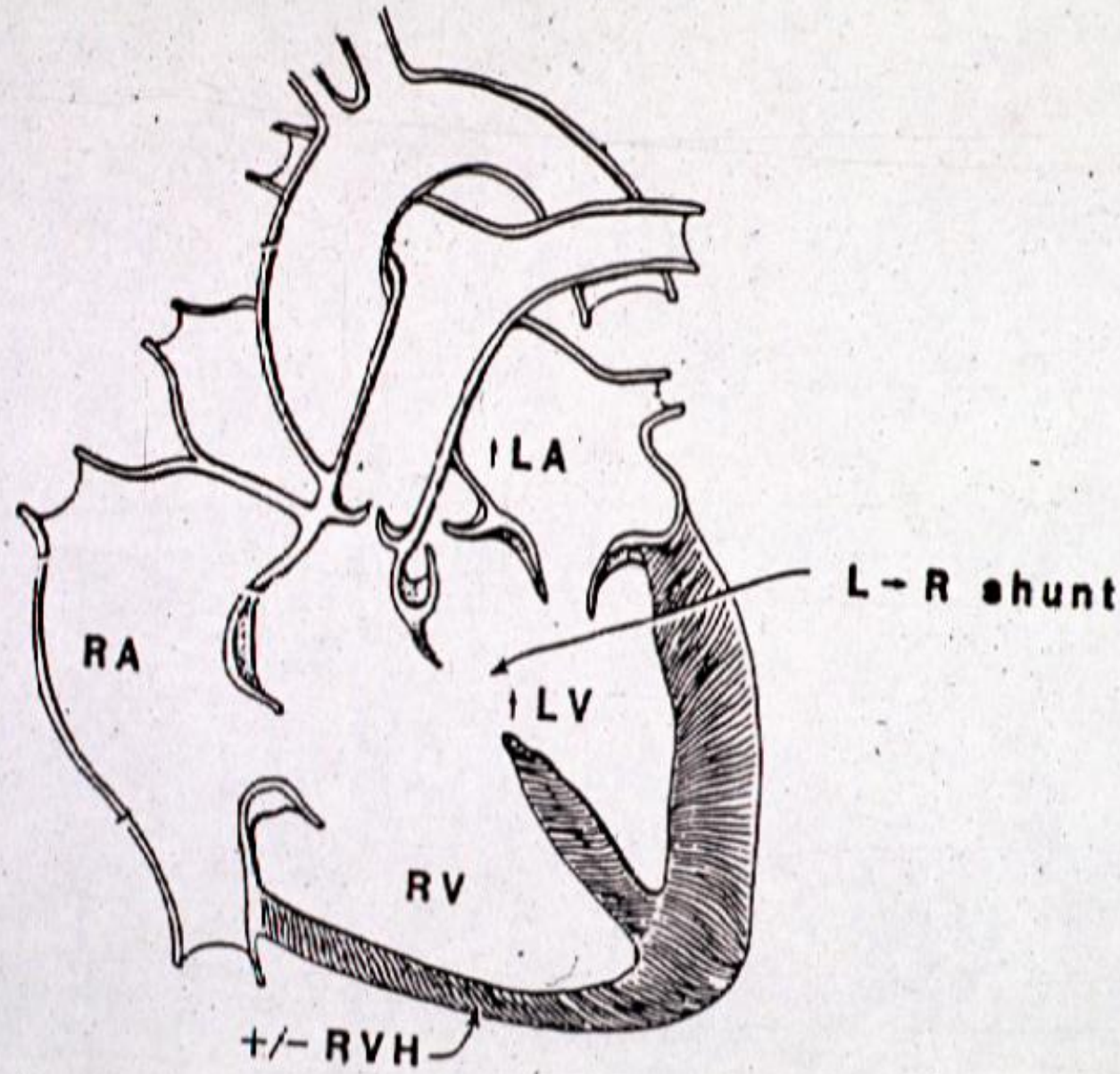

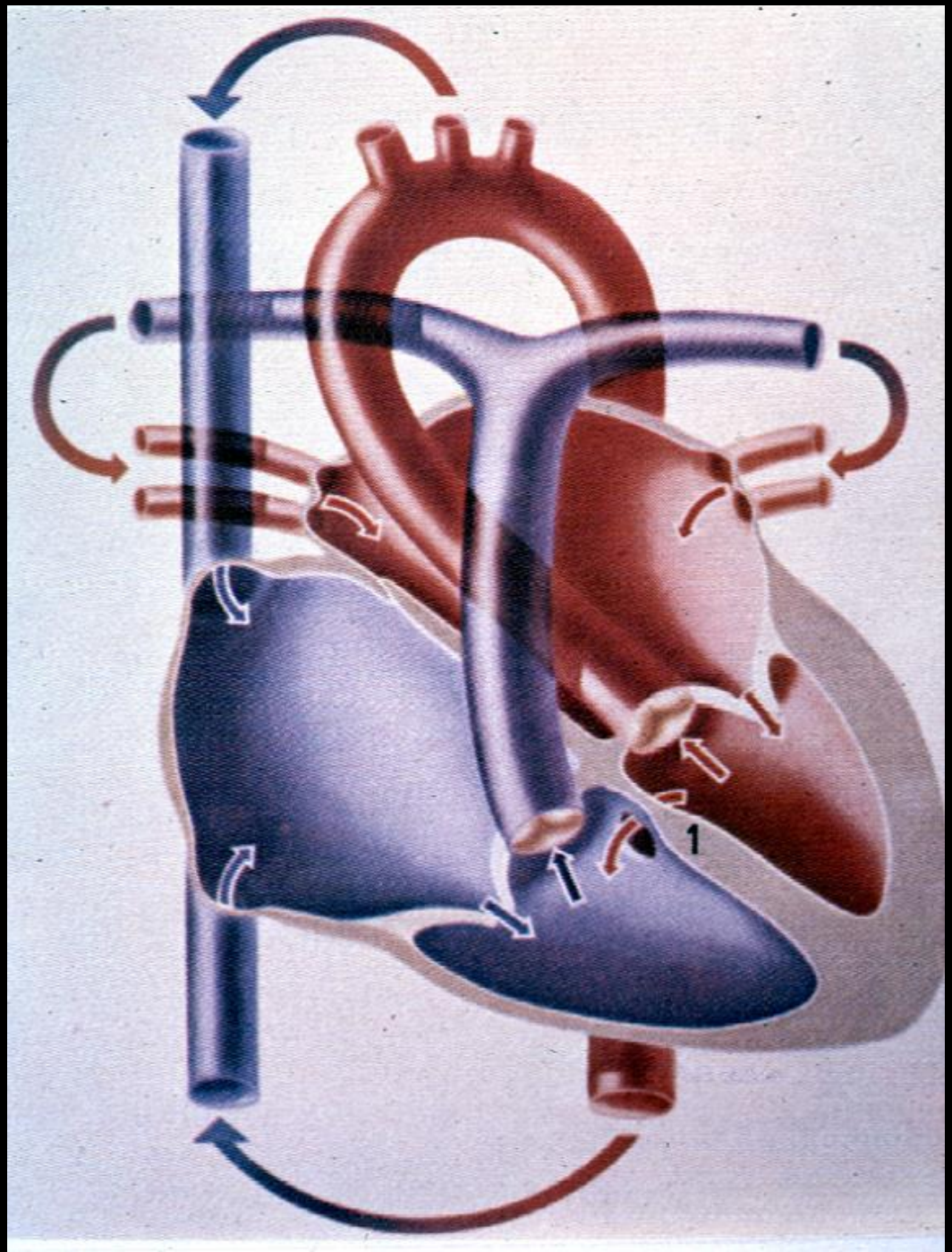

VSD

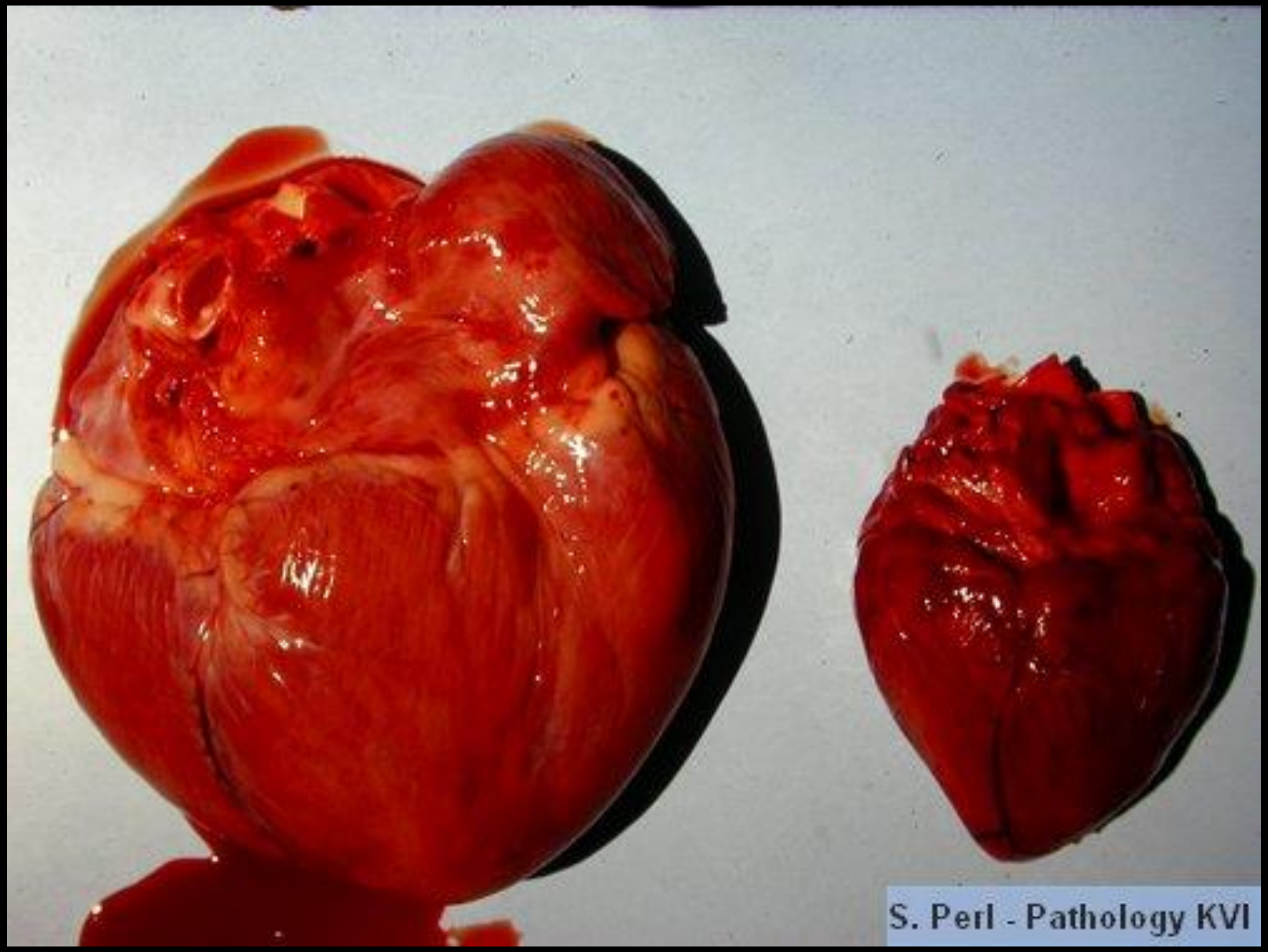
S. Perl - Pathology KVI

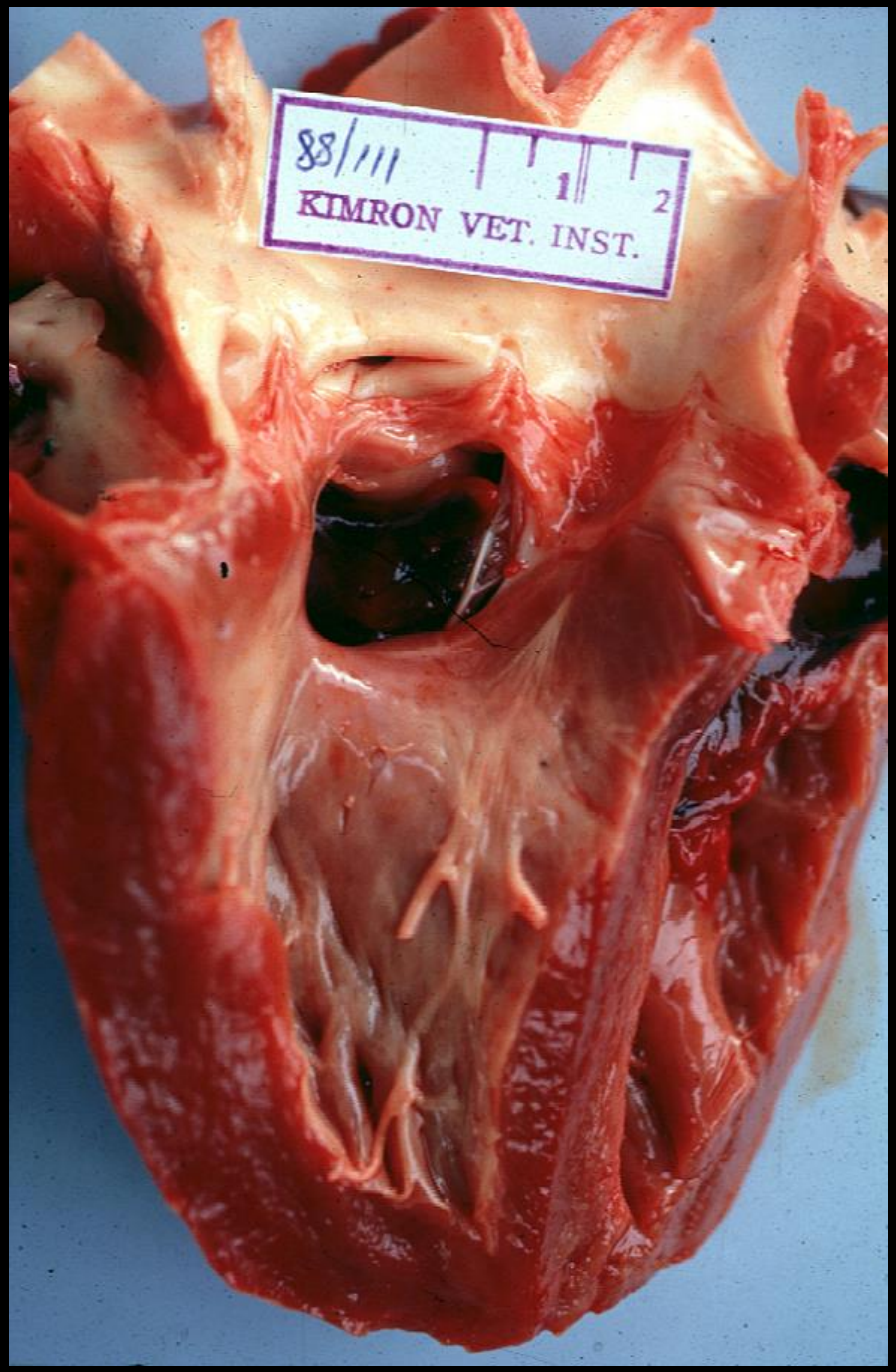
88/111
1
2
KIMRON VET. INST.

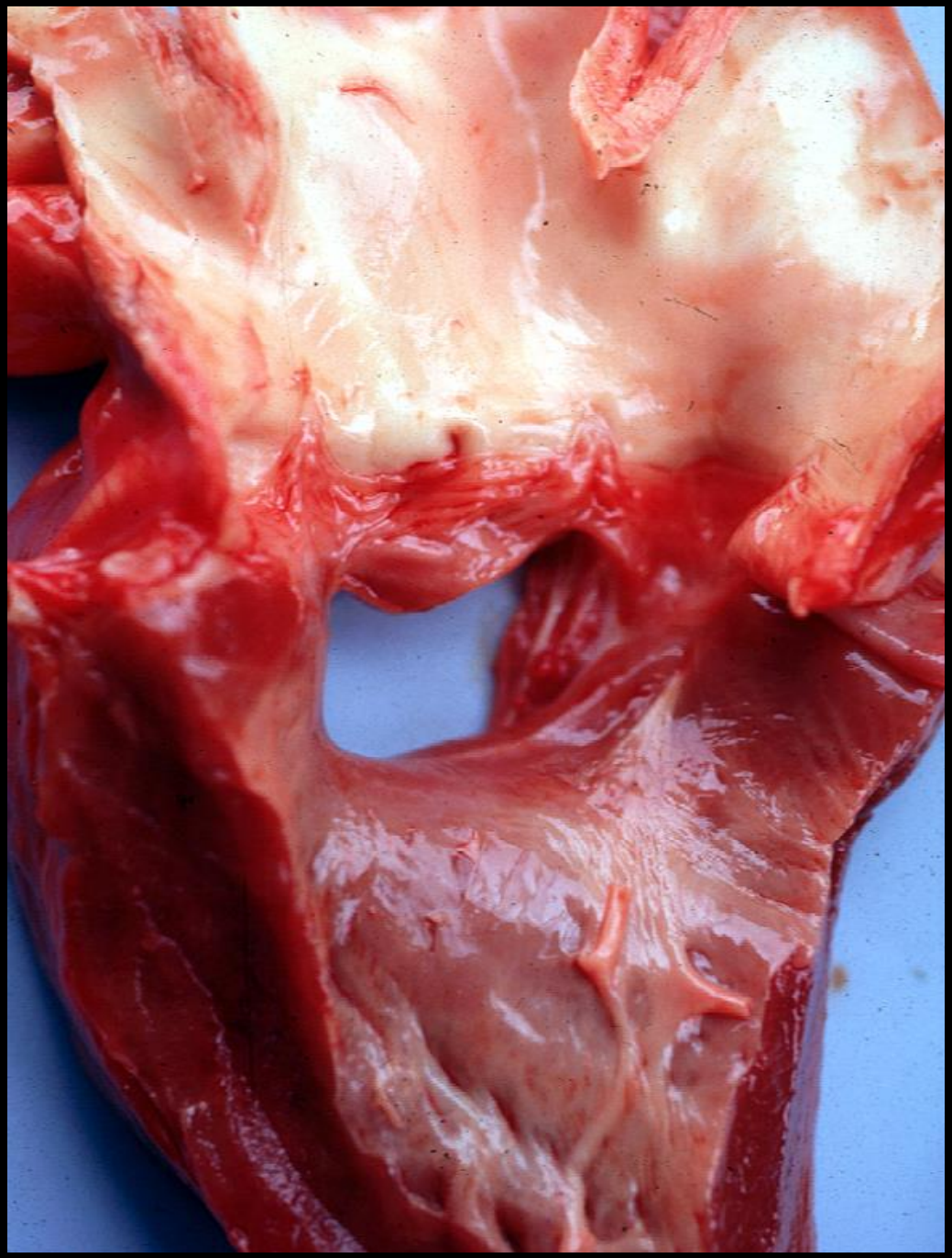

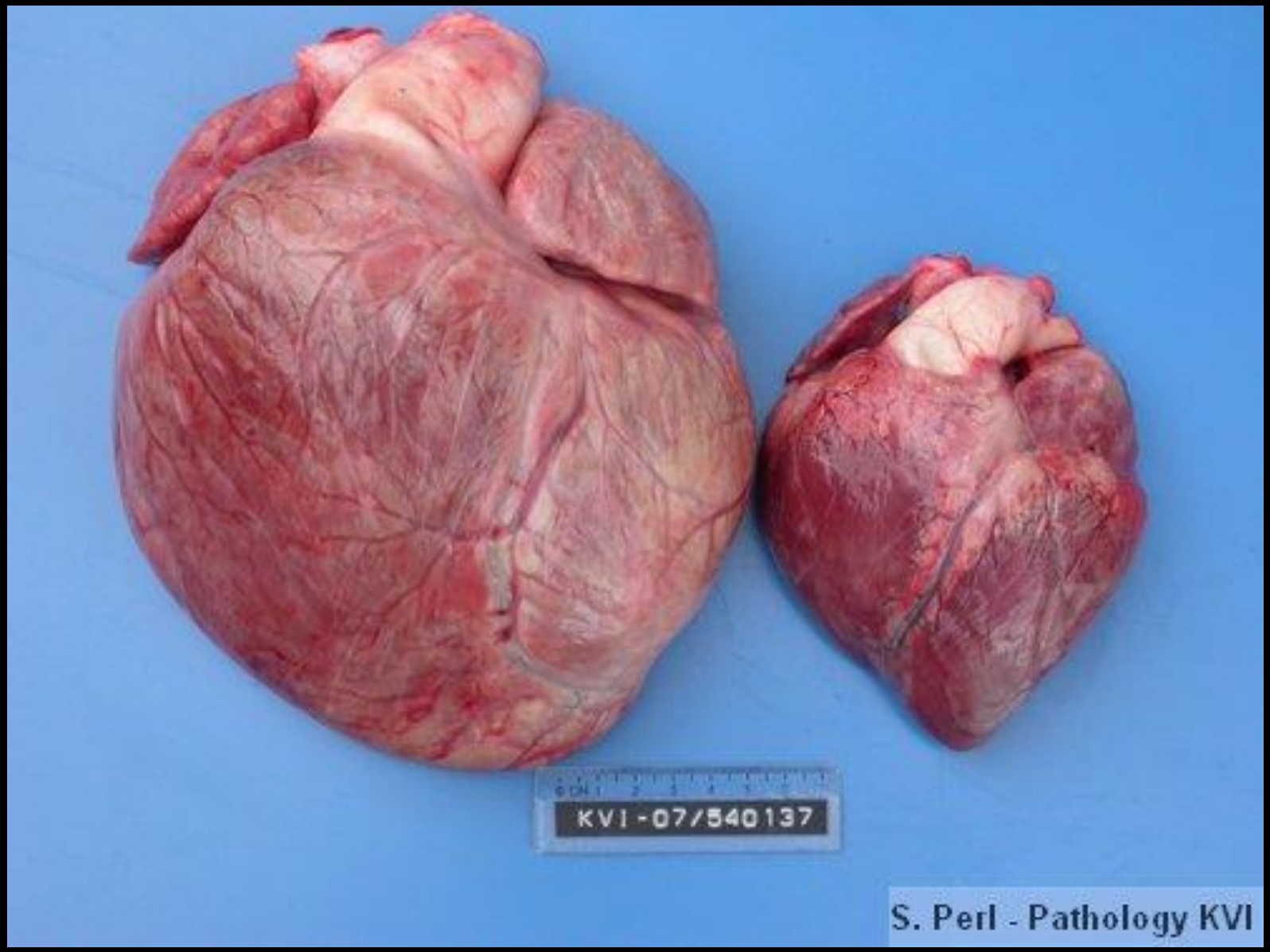
KVI-07/540137
S. Perl - Pathology KVI

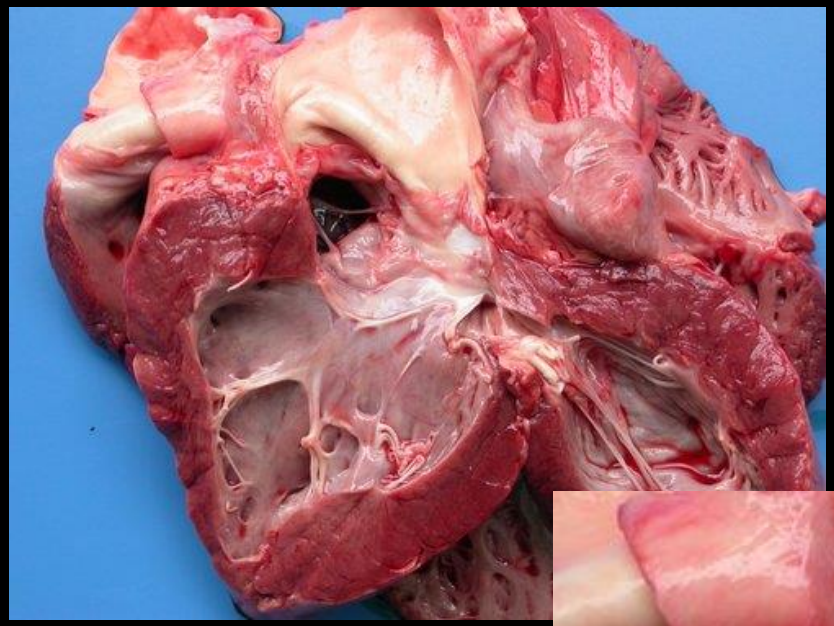

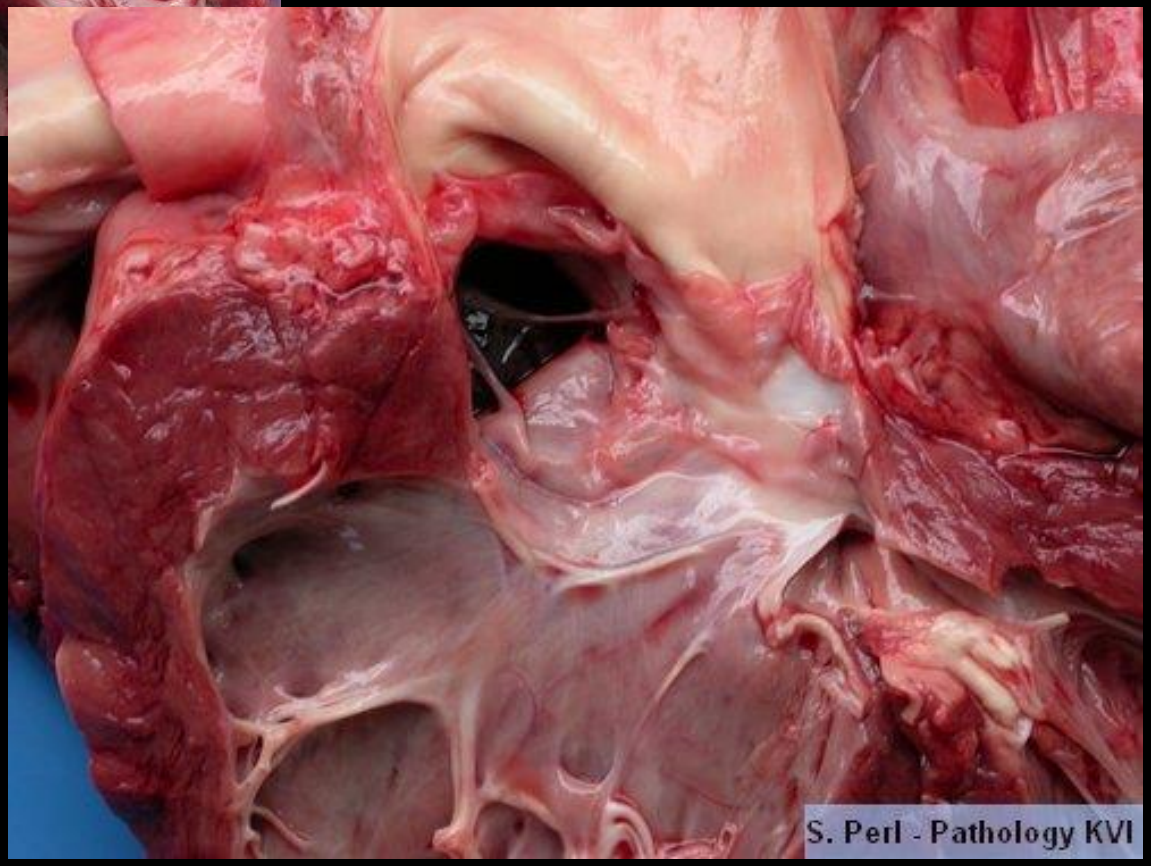
S. Perl - Pathology KVI

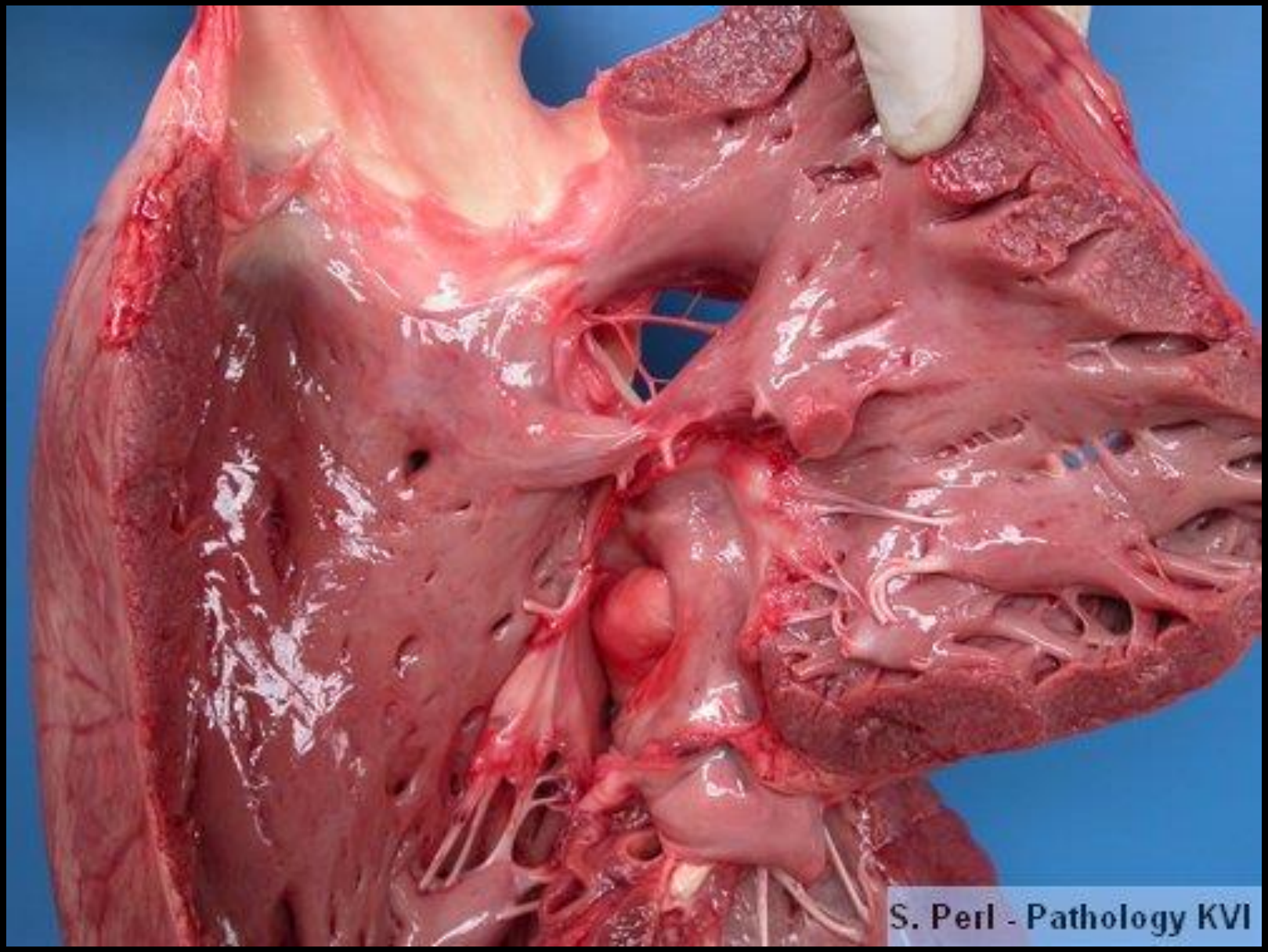
S. Perl - Pathology KVI

Ventricular septal defect

- Separation of the ventricles completed by
  - muscular portion of septum
  - membranous portion of septum
- Defective development of any of the parts leads to ventricular septal defect

Ventricular septal defect

- **Effects**

  Thickening and roughening of endocardium around the orifice between ventricles (turbulence).

  Thickening of endocardium of right ventricle opposite to the opening (jet stream).

  Continued overload of the right heart.

  Reversed flow of blood from the right to the left => cyanosis

  Fluid in body cavities

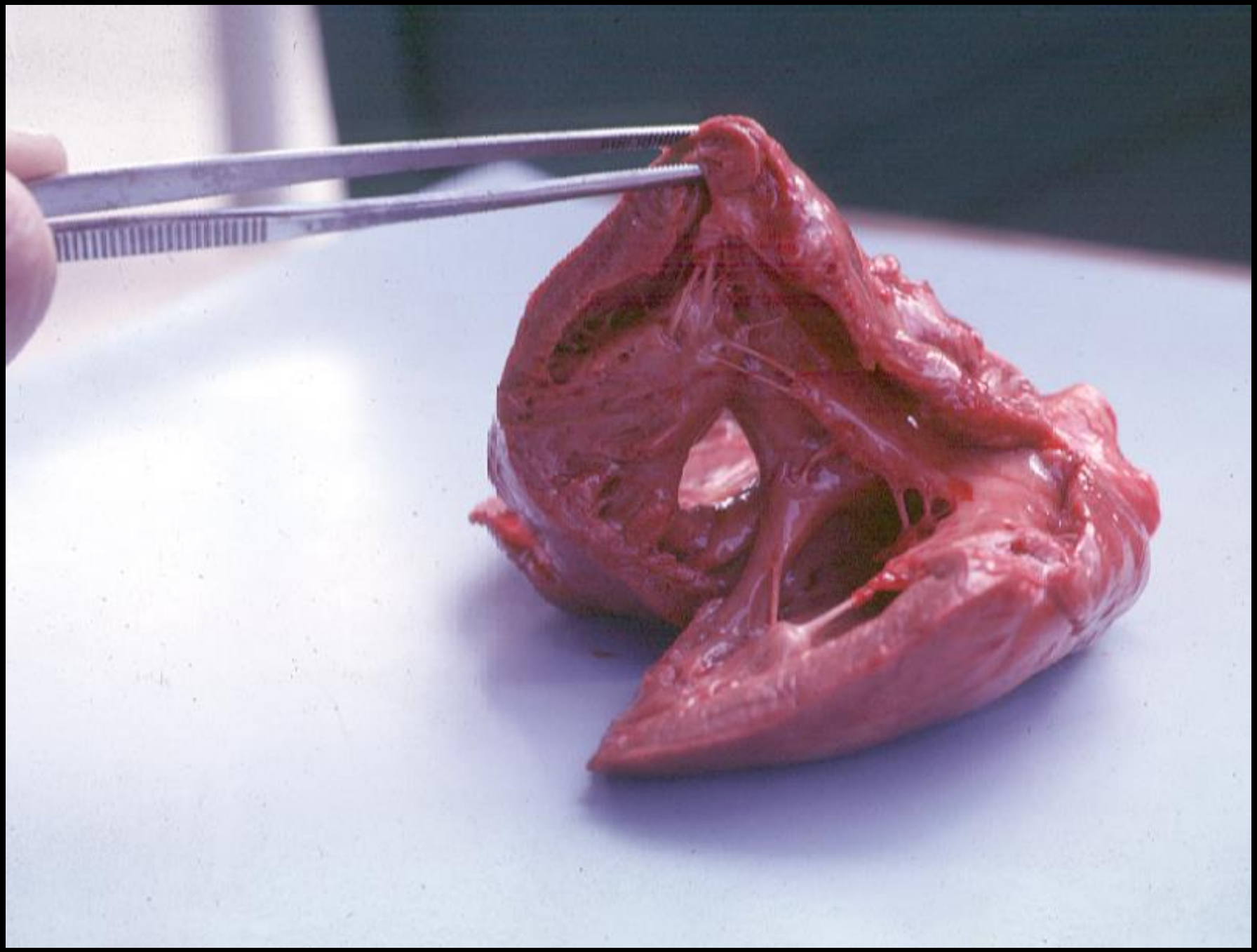

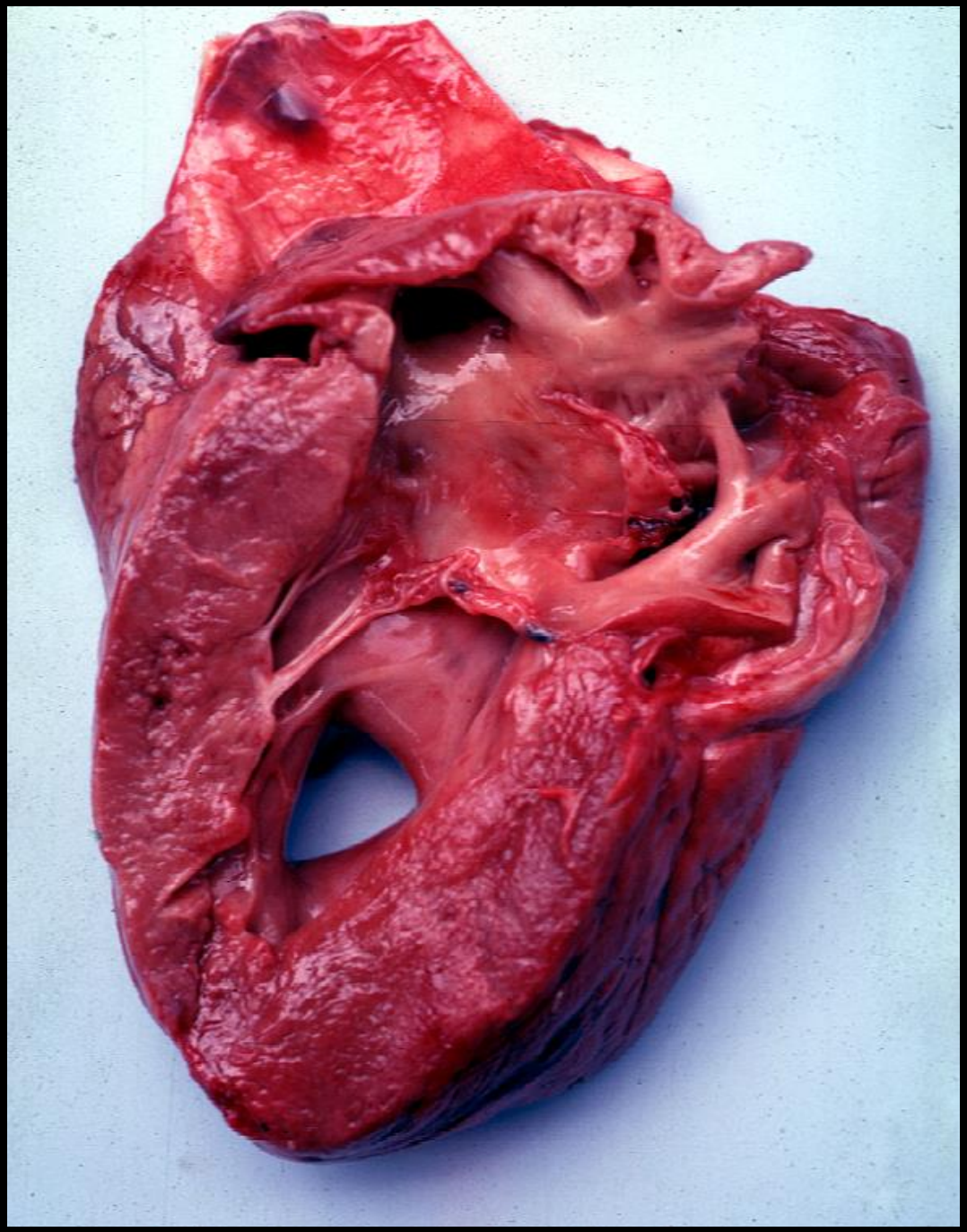

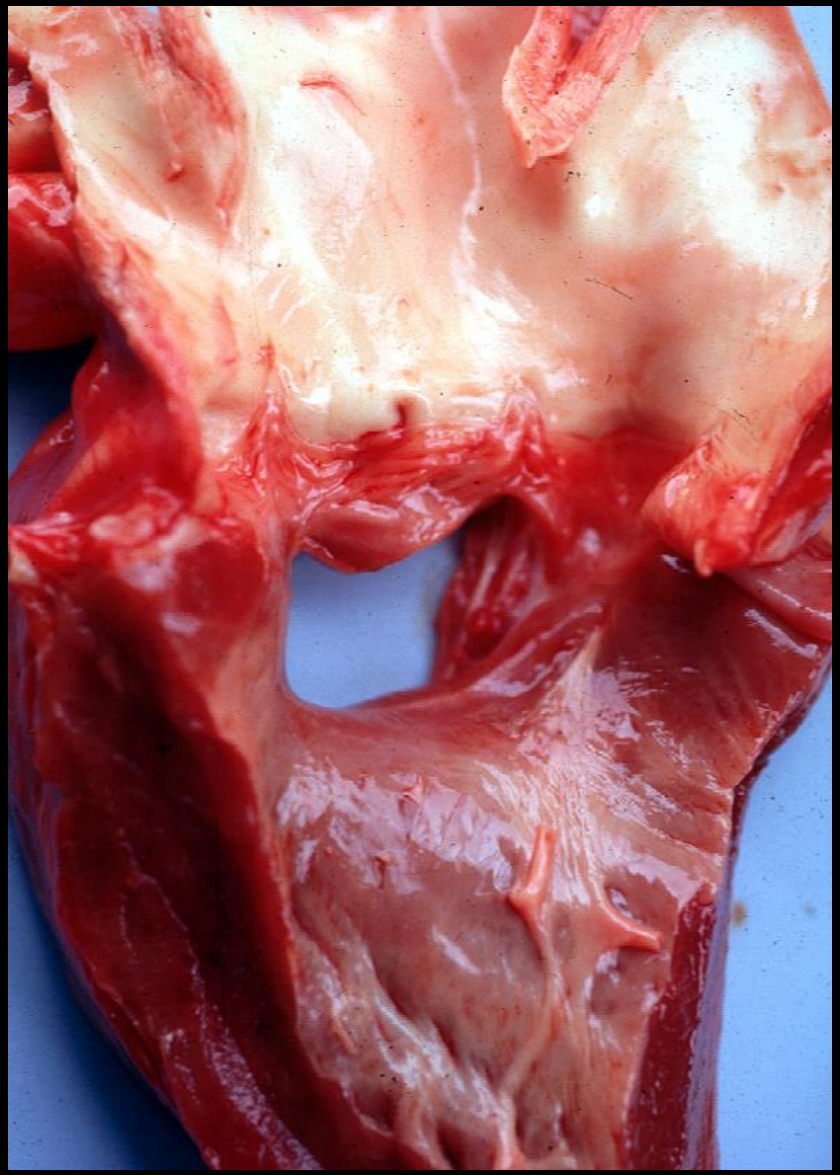

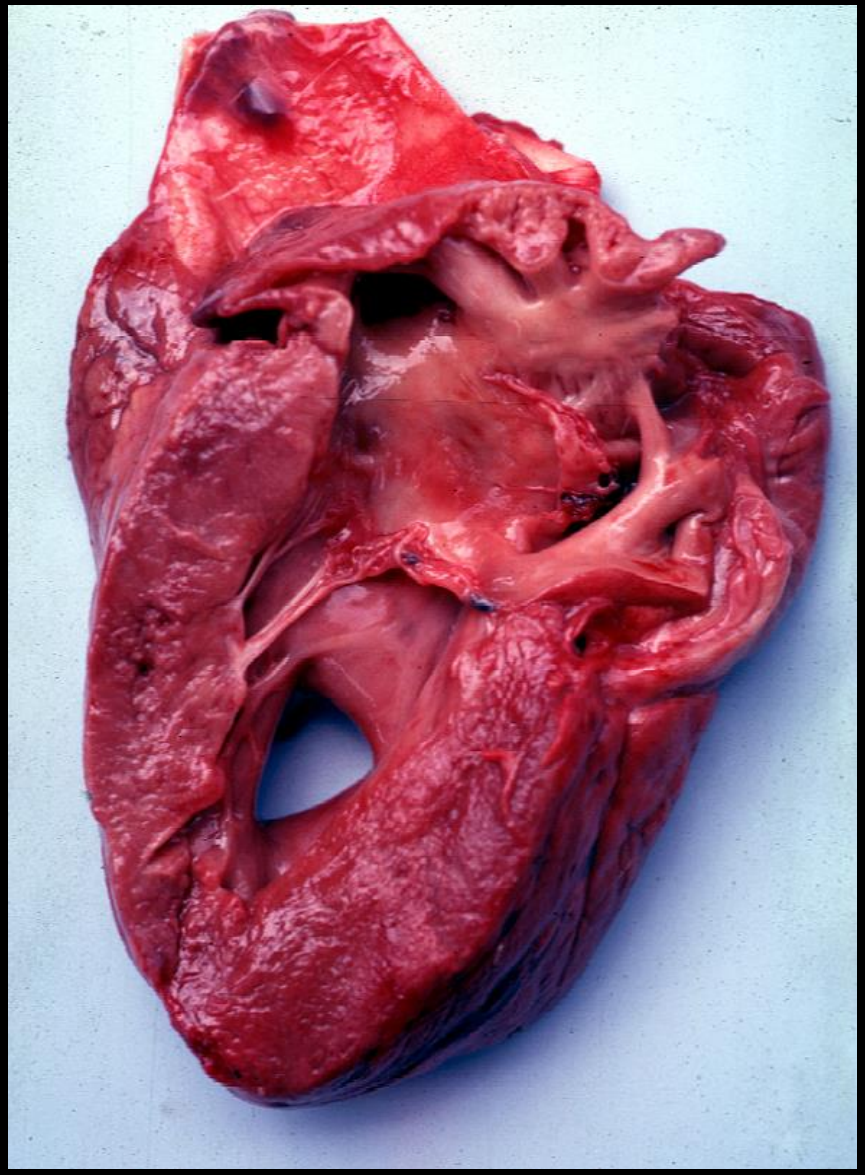

S. Perl - Pathology KVI 11/95028

S. Perl - Pathology KVI 11/95028

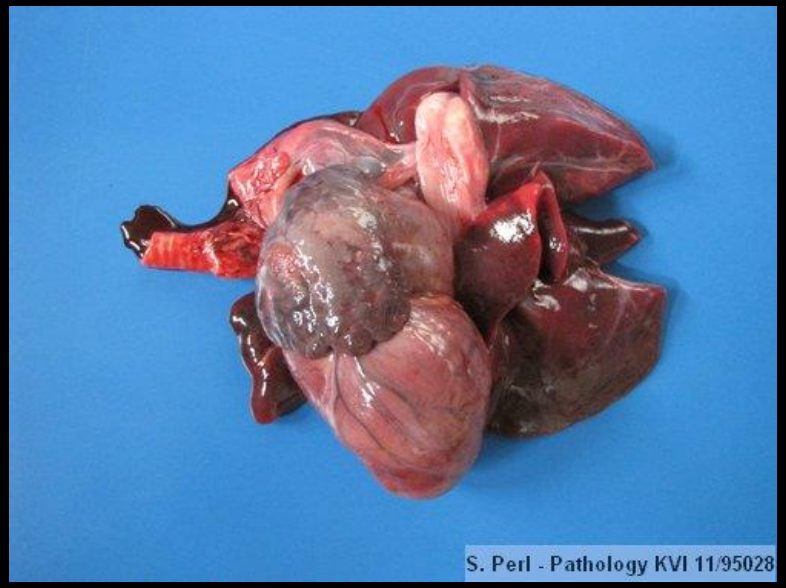
S. Perl - Pathology KVI 11/95028

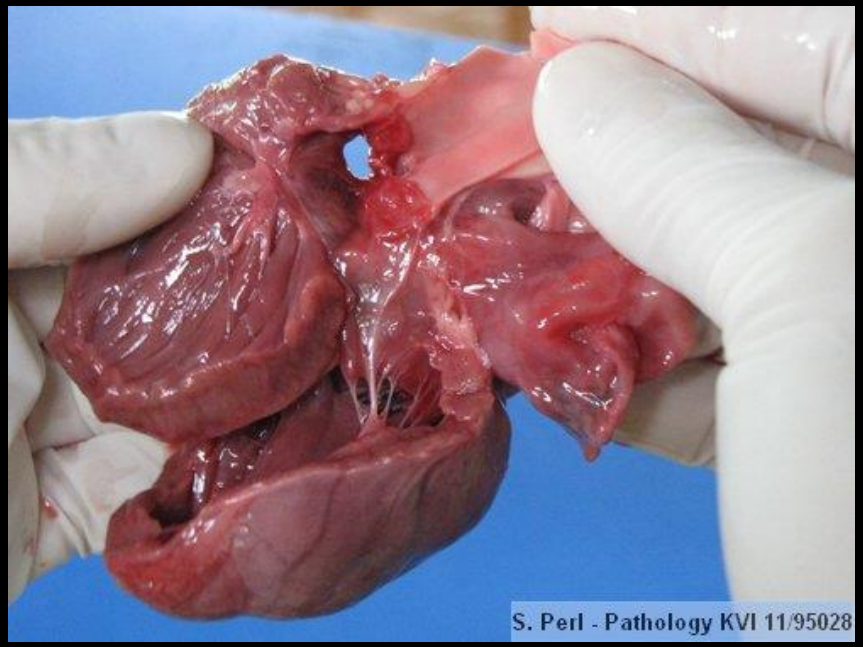
S. Perl - Pathology KVI 11/95028

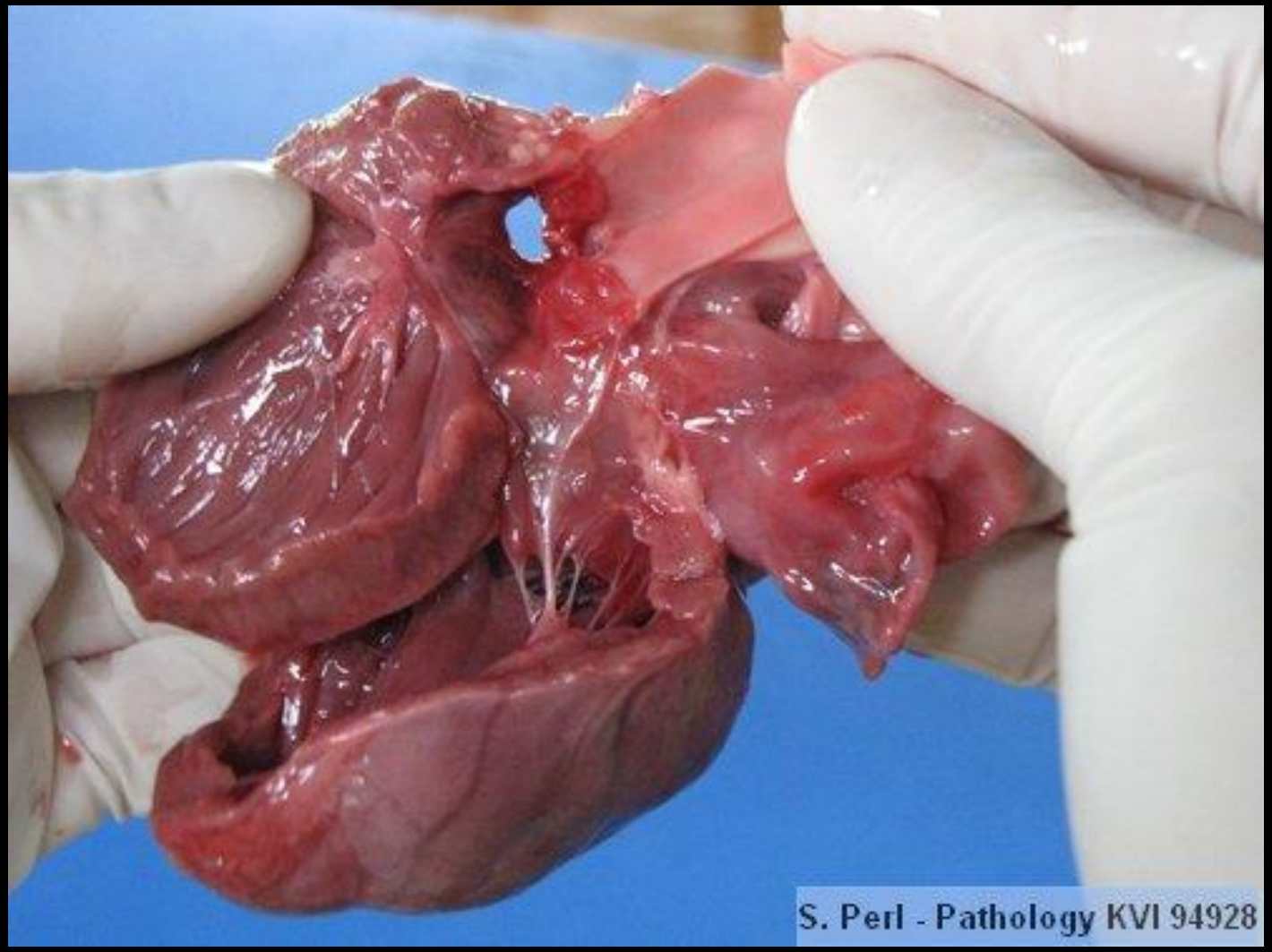
S. Perl - Pathology KVI 94928

Ventricular septal defect

- Effects

  Thickening of endocardium

  Cyanosis

  Fluid in body cavities

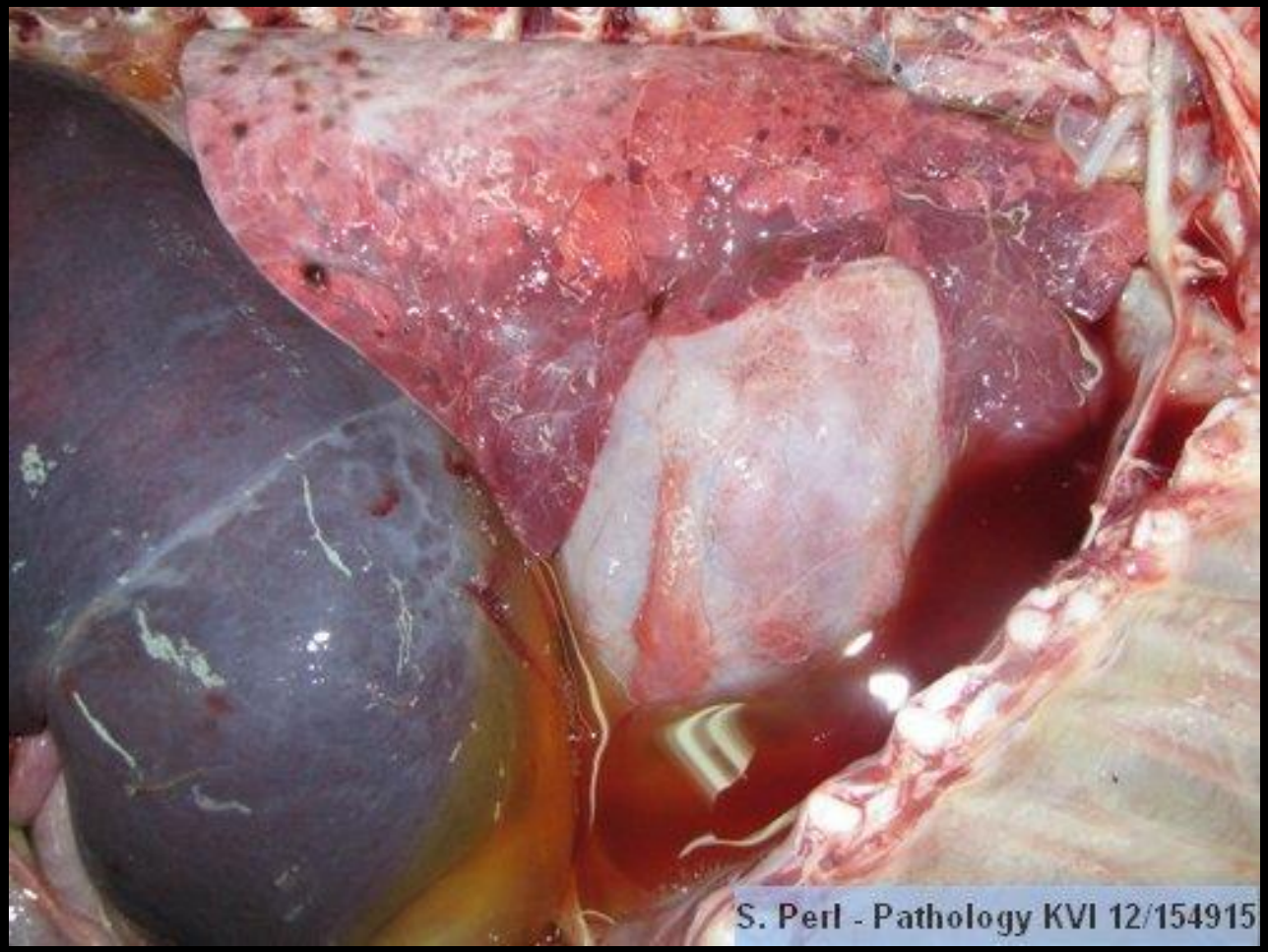
S. Perl - Pathology KVI 12/154915

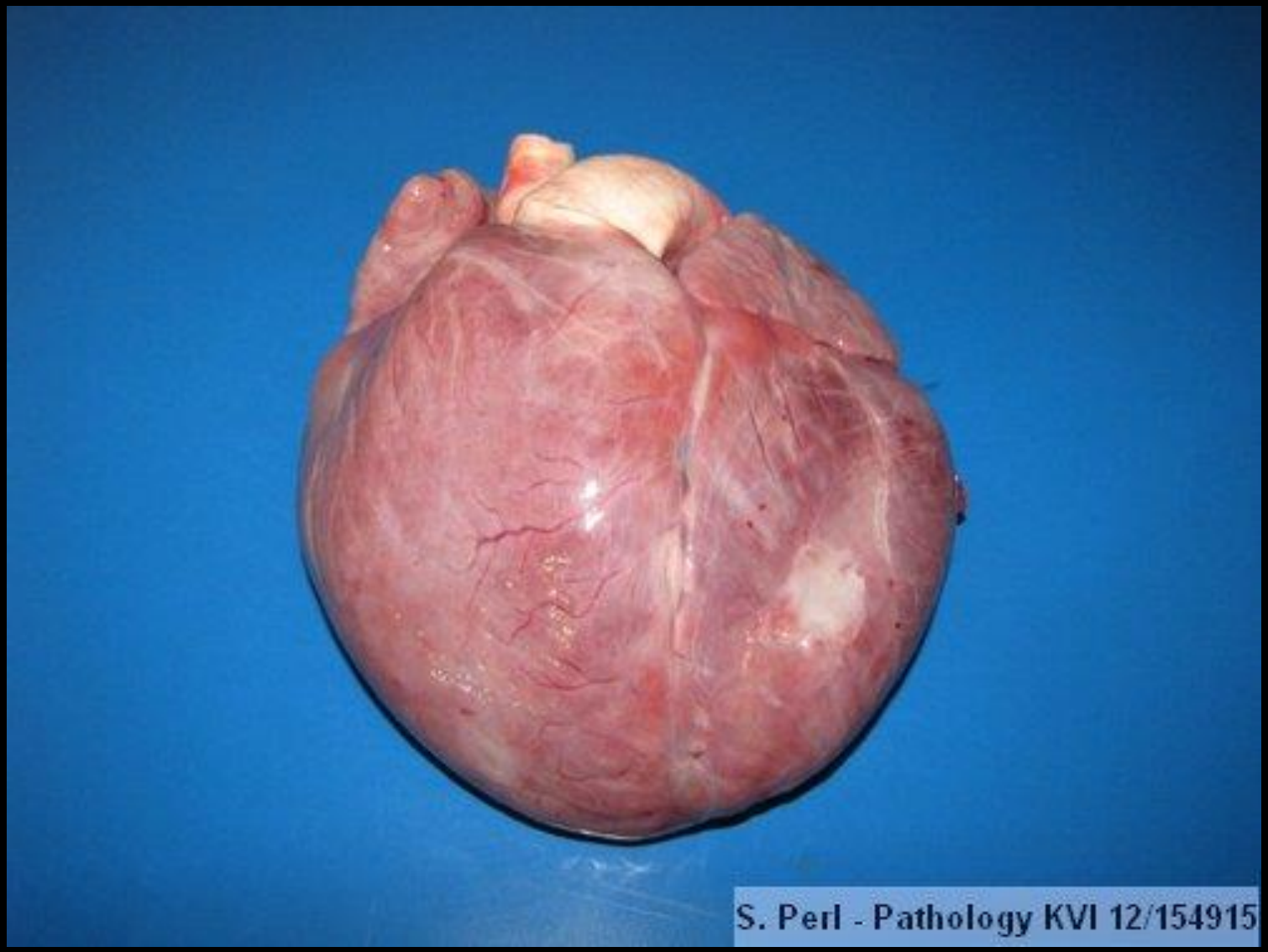
S. Perl - Pathology KVI 12/154915

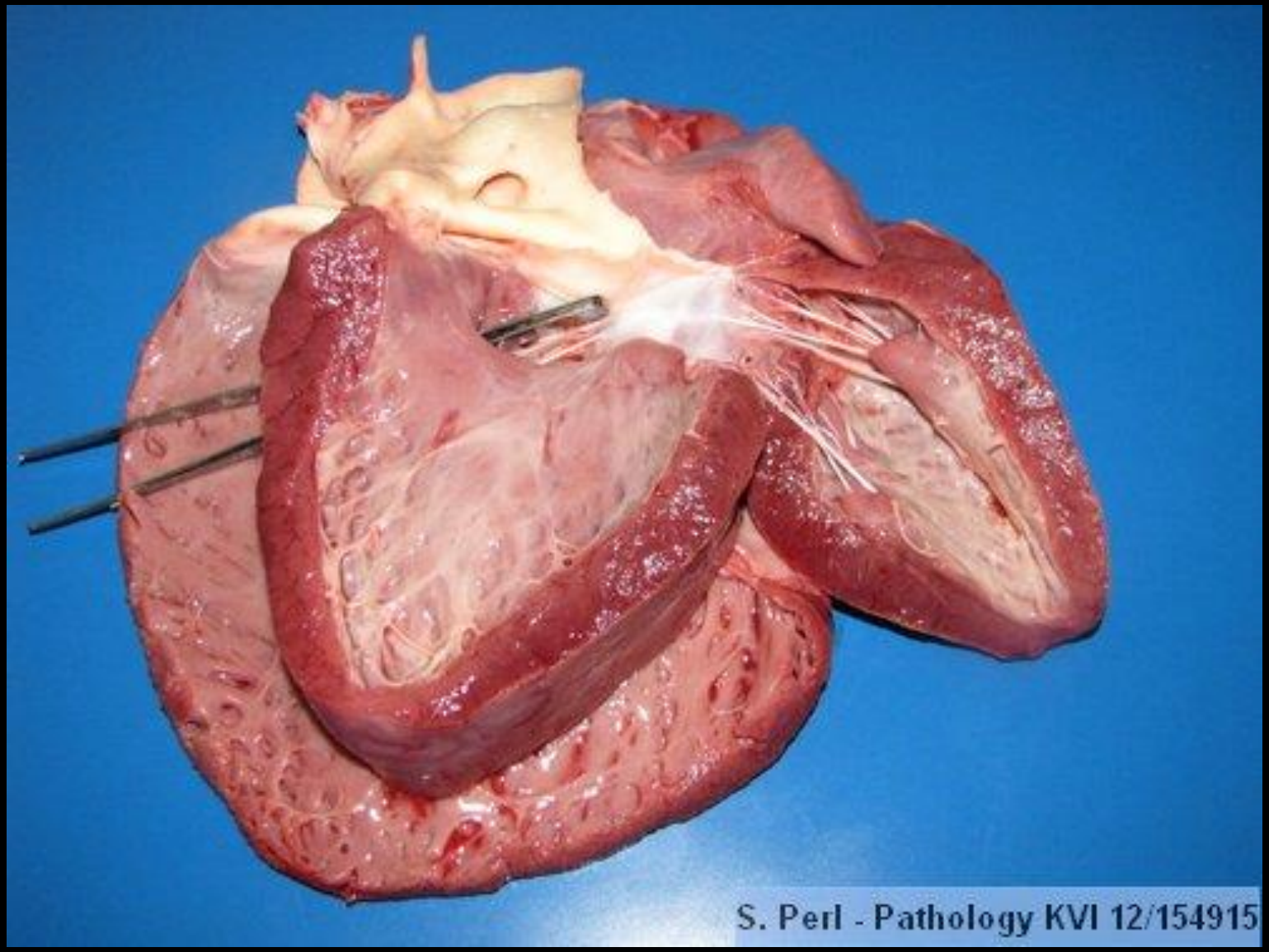
S. Perl - Pathology KVI 12/154915

Ventricular septal defect

Bovines

English bulldog

English springer spaniel

West highland white terrier

Congenital defects

B. Conotruncal abnormalities

1. Tetralogy of Fallot

Tetralogy of Fallot

Tetralogy of Fallot

- **Characteristics**

  Overriding aorta

  Ventricular septal defect

  Pulmonic stenosis

  Hypertrophy of right ventricle

TETRALOGY OF FALLOT

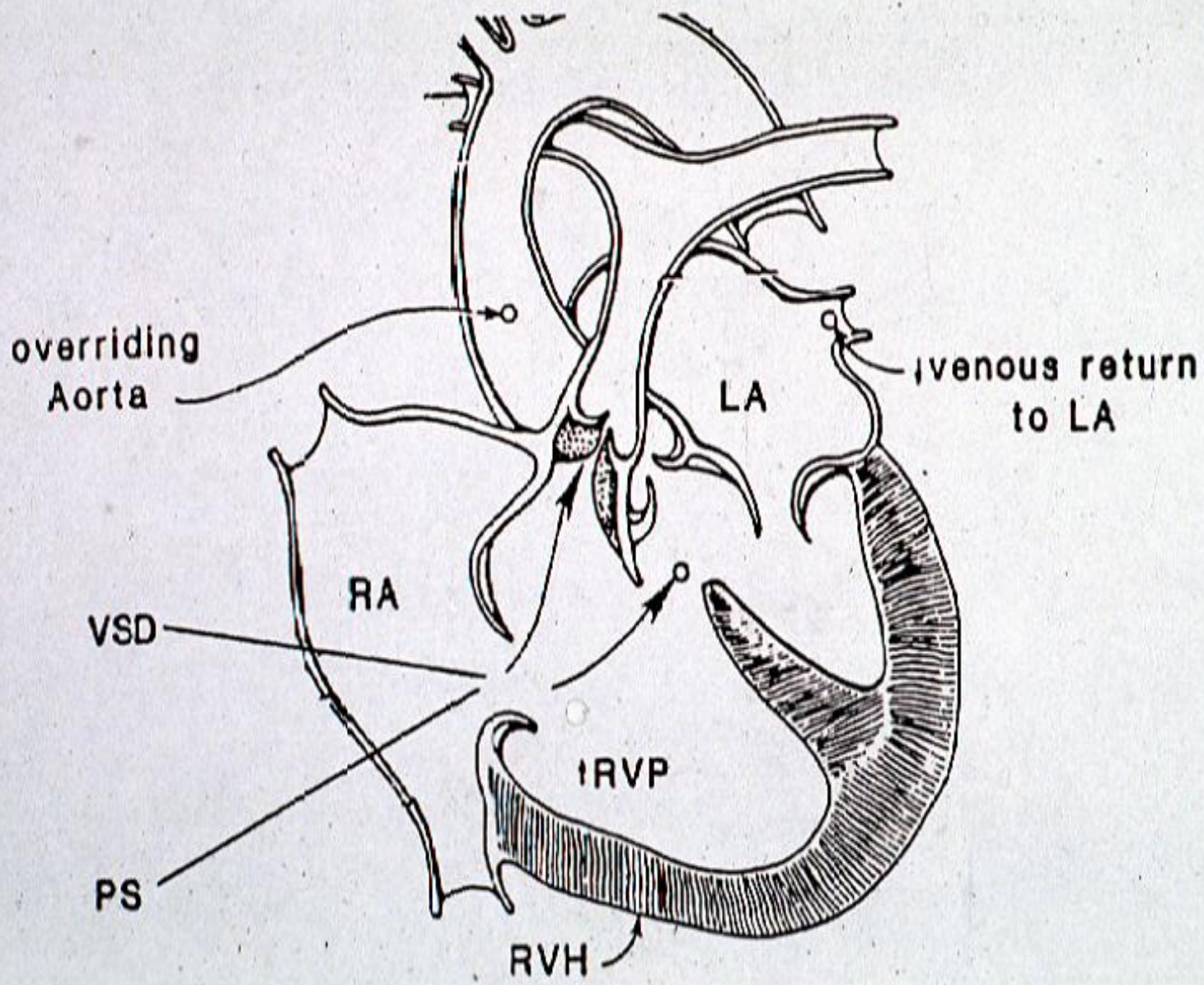

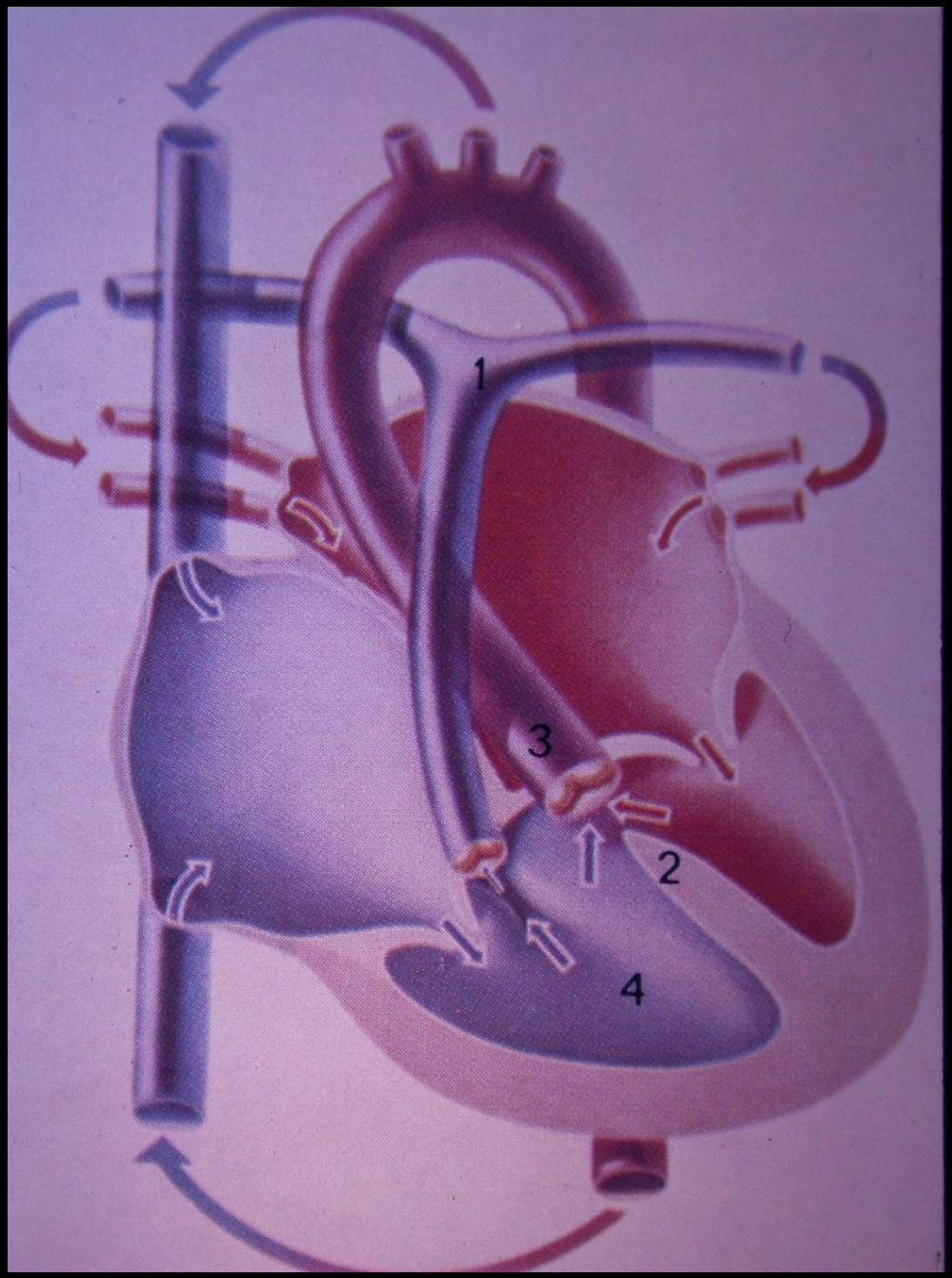

Overriding aorta

Tetralogy of Fallot

- **Effects**

  Severe cyanosis

  Hypoxia

  Retarded growth

Tetralogy of Fallot

Keeshound dogs

English bulldog

In hearts of human beings = blue babies

C.Failure of adequate development of semilunar or atrioventricular valves

1. Pulmonary stenosis
2. Aortic and subaortic stenosis
3. Dysplasia or aplasia of tricuspid valve
4. Mitral valvular insufficiency
5. Congenital hematomas

Pulmonary stenosis

PULMONIC STENOSIS

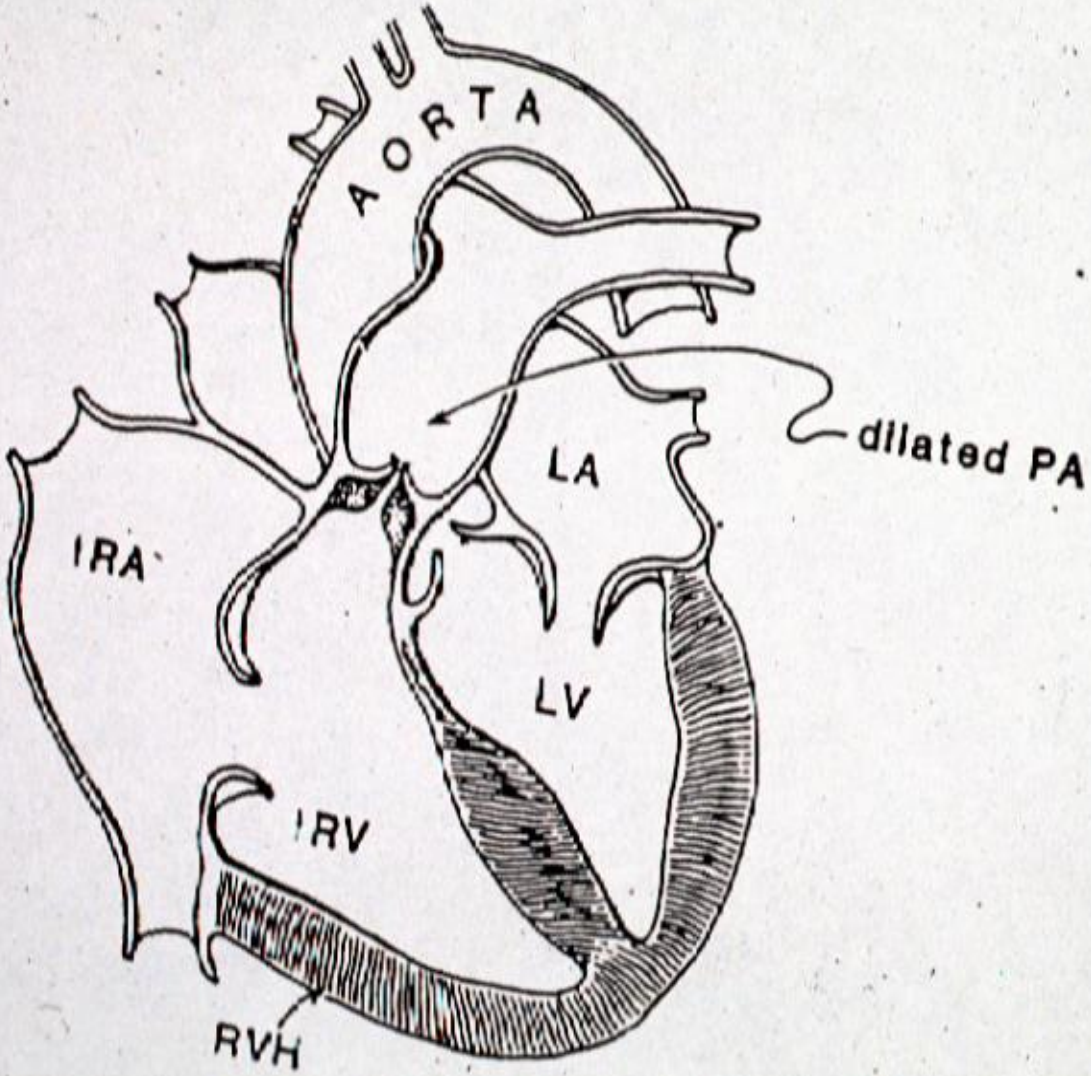

Pulmonary stenosis

- **Characteristics**

  Valvular

  Supravalvular

  Subvalvular

Pulmonary stenosis

- **Effects**

  Post stenotic dilatation

  Right ventricular hypertrophy

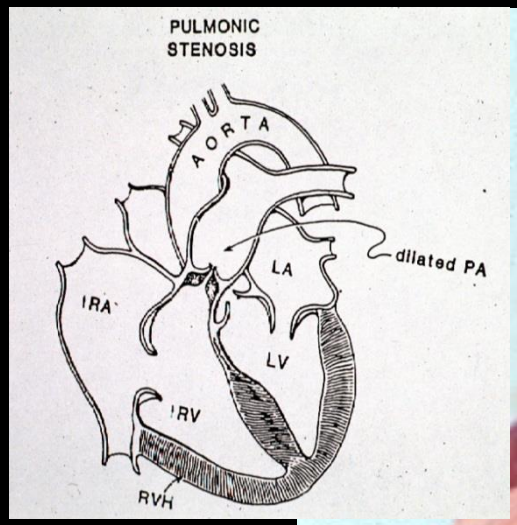

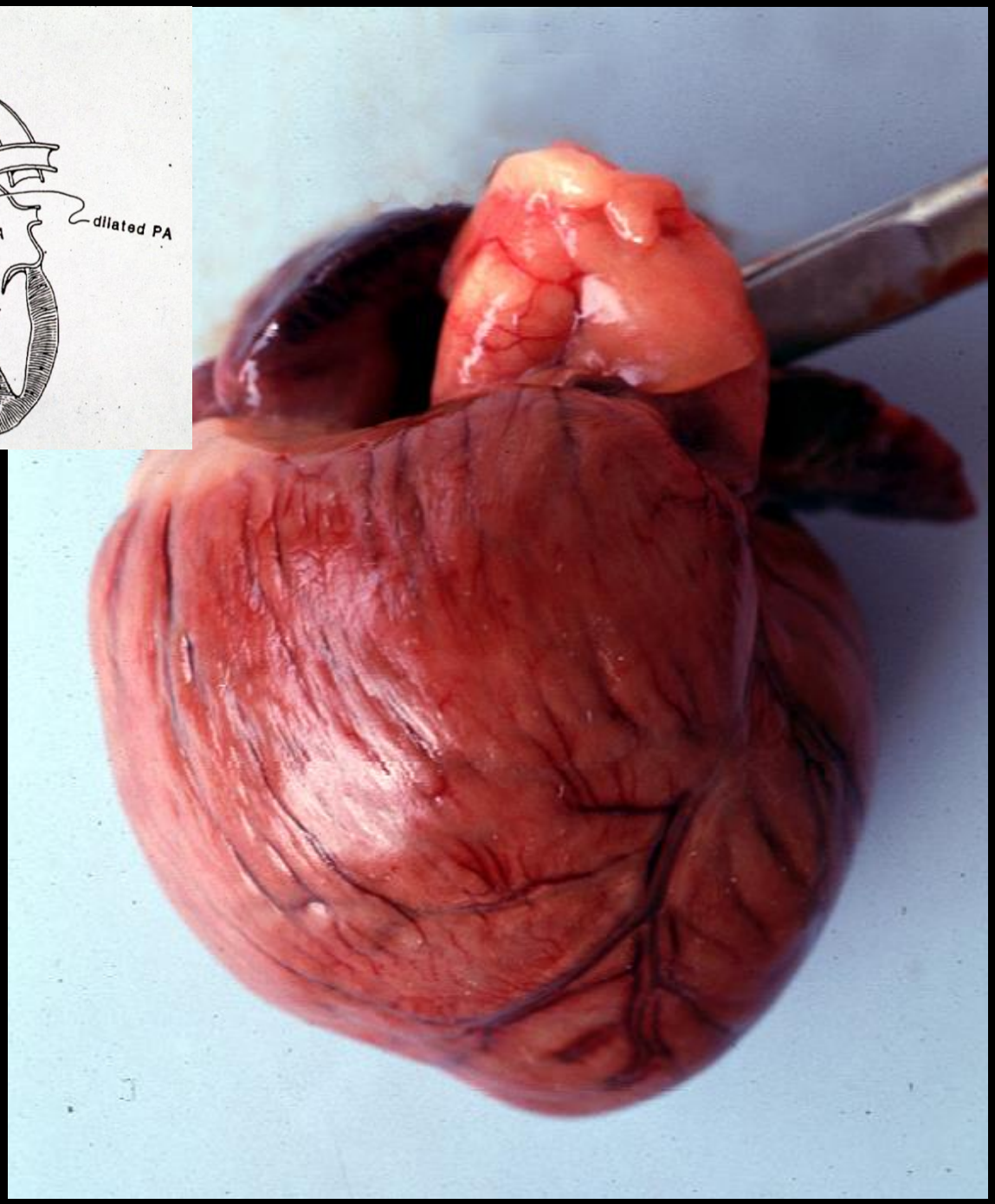

Right ventricle hypertrophy due to pulmonary stenosis

Pulmonary stenosis

- Beagles
- English Bulldogs
- Chihuahuas
- Basset hound
- Boxer
- Cocker spaniel
- Labrador retriever
- Mastiff
- Newfoundland
- Samoyed
- Miniature Schnauzer
- Fox Terrier

Aortic and subaortic stenosis

Aortic and subaortic stenosis

- **Characteristics**

  - Constricting band at the the aortic valve

    supravalvular

    valvular

    subvalvular

  - Congenital defects in the aortic valve

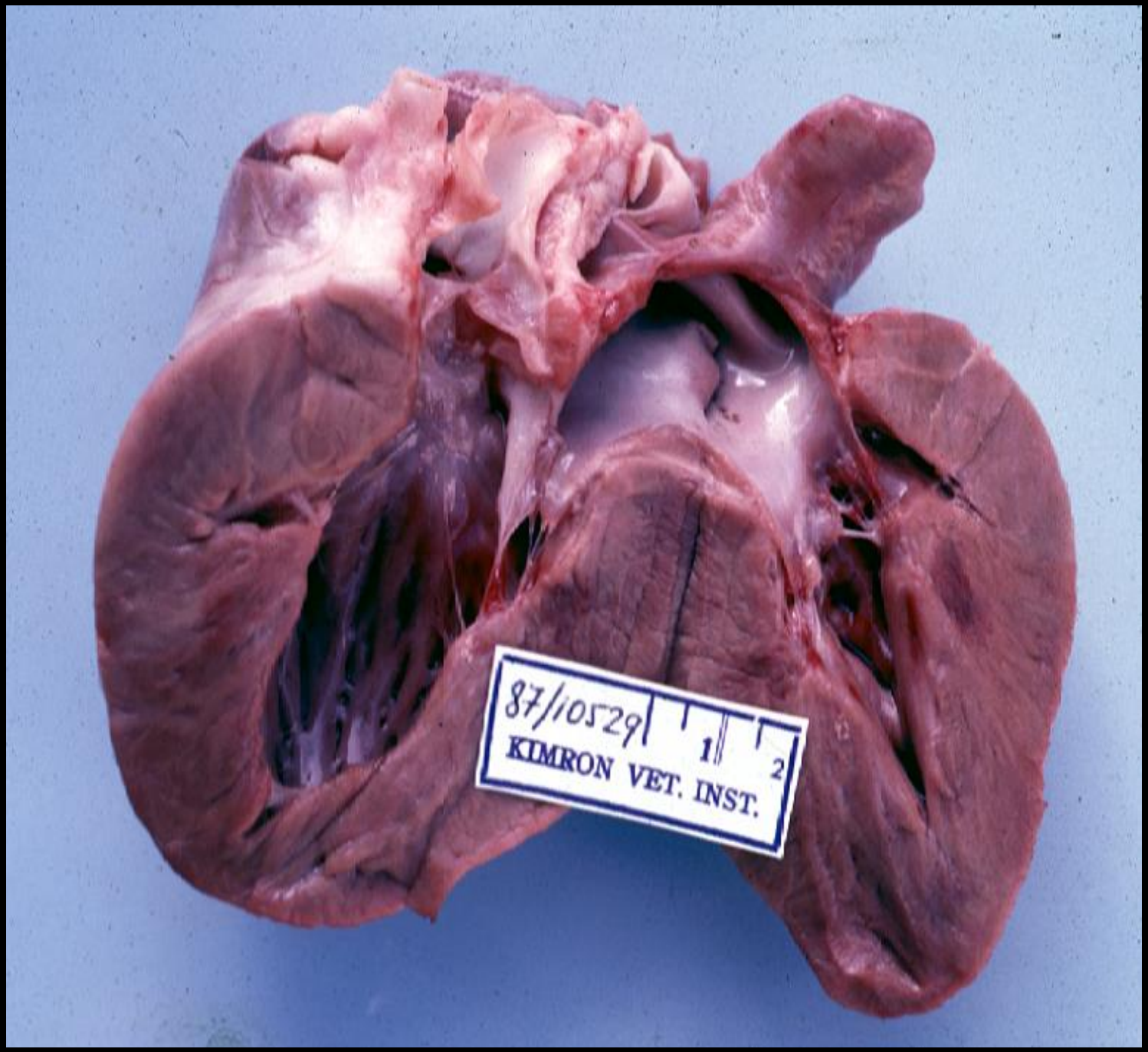
87/10529
1
2
KIMRON VET. INST.

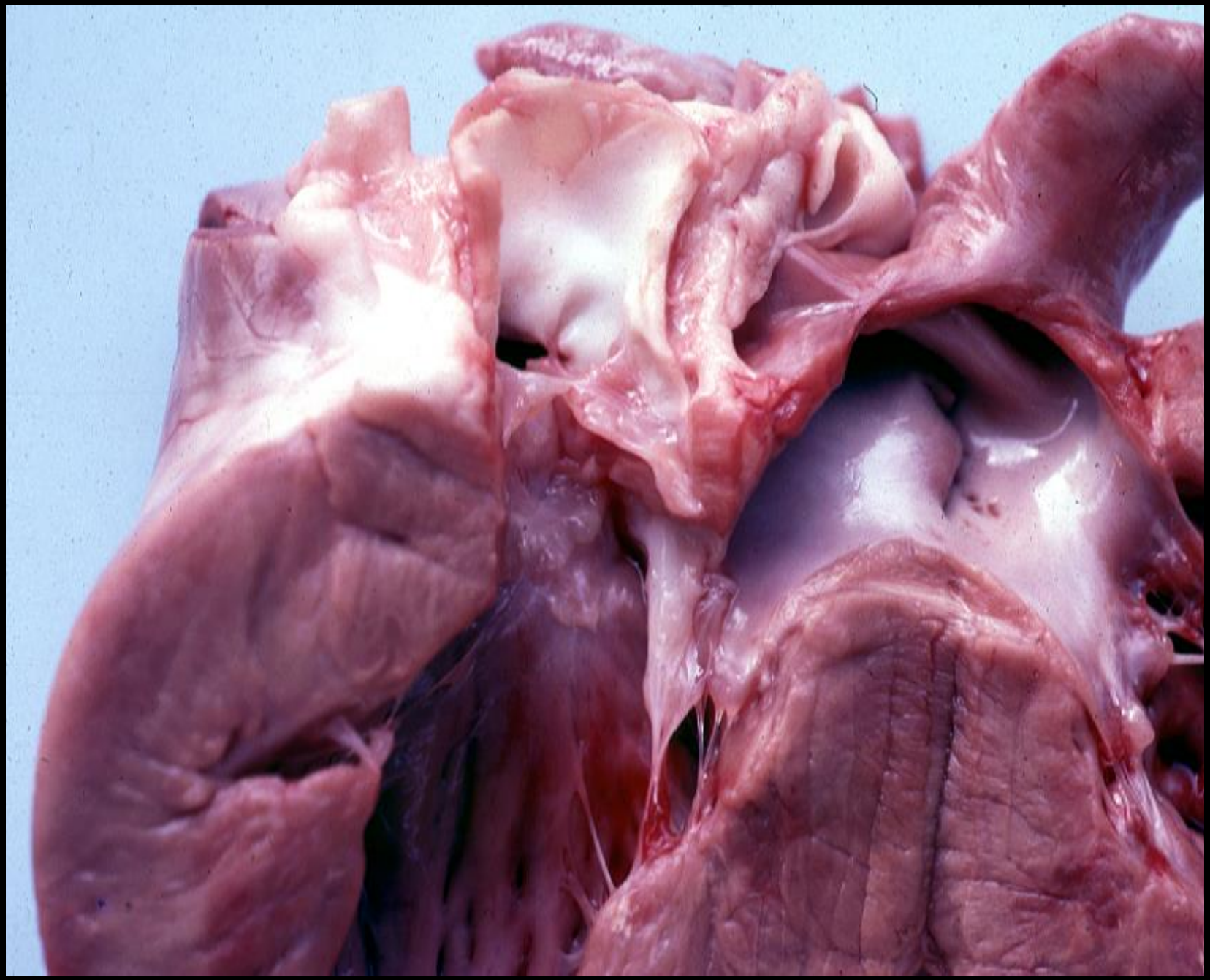

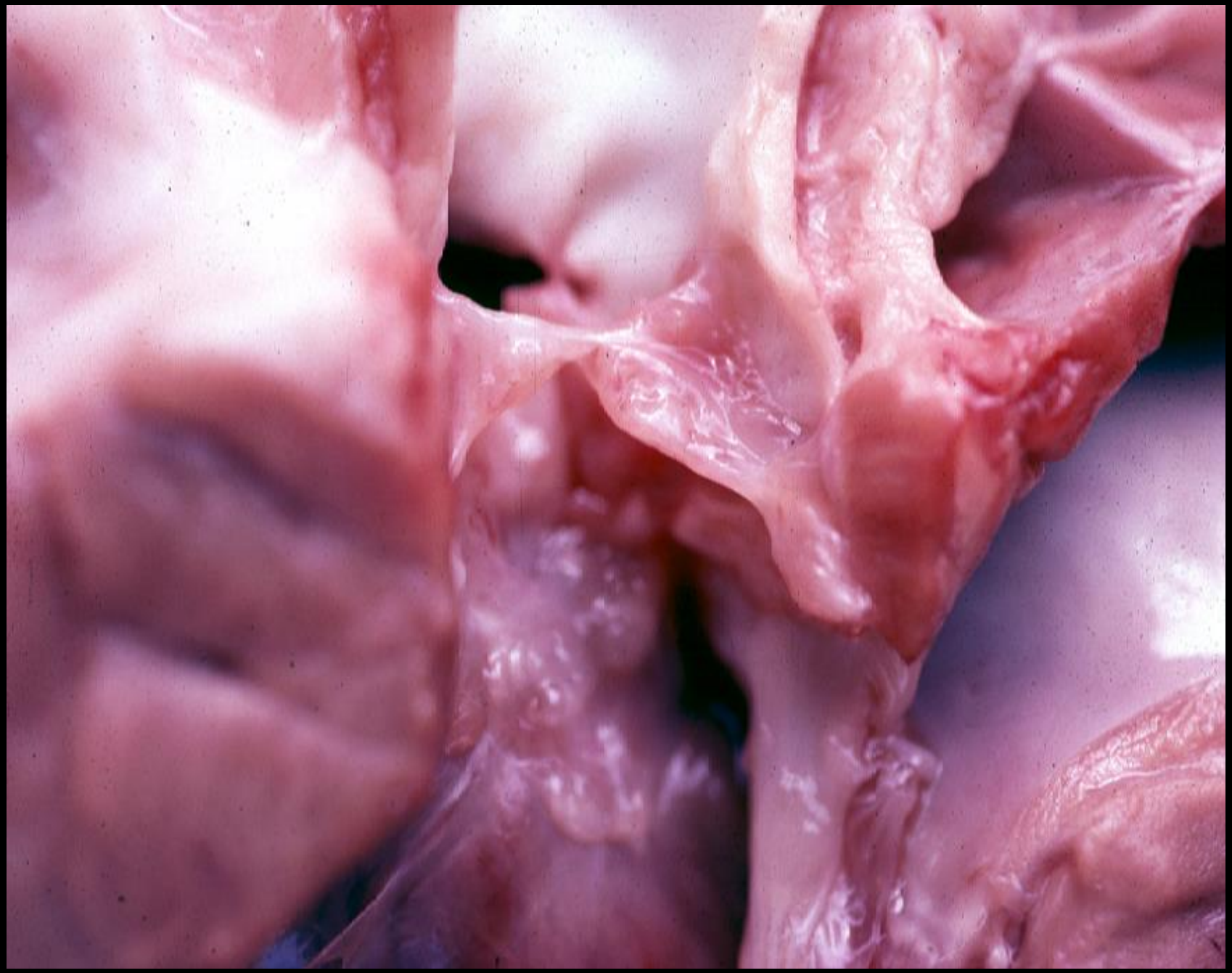

Aortic and subaortic stenosis

- **Effects**

  Post stenotic dilatation of the aorta

  Hypertrophy of the left ventricle.

  Multifocal myocardial necrosis

  Clinically

  Ventricular arrhythmias

  Sudden death

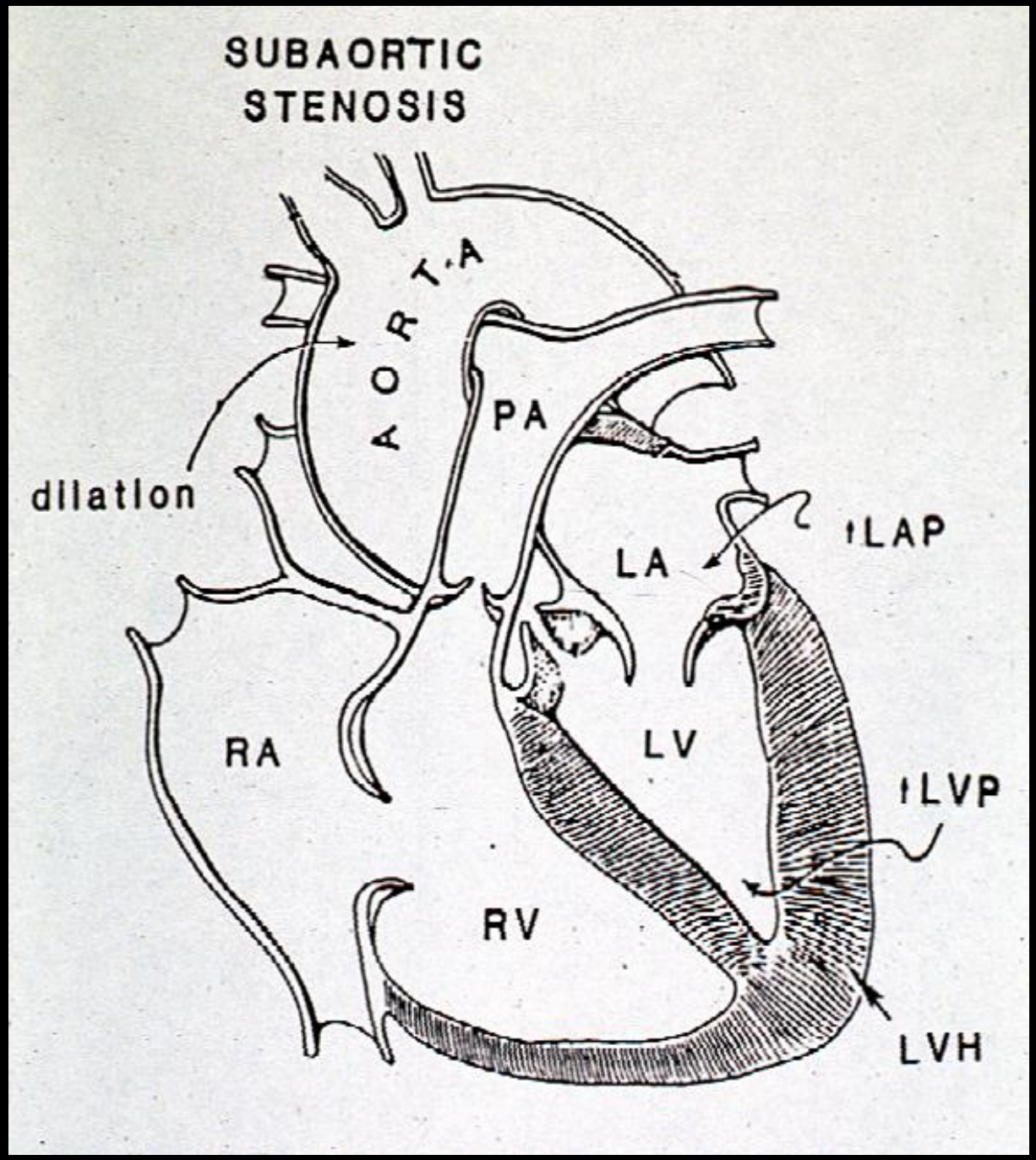
SUBAORTIC
STENOSIS
AORTA
PA
dilation
LAP
LA
RA
LV
LVP
RV
LVH

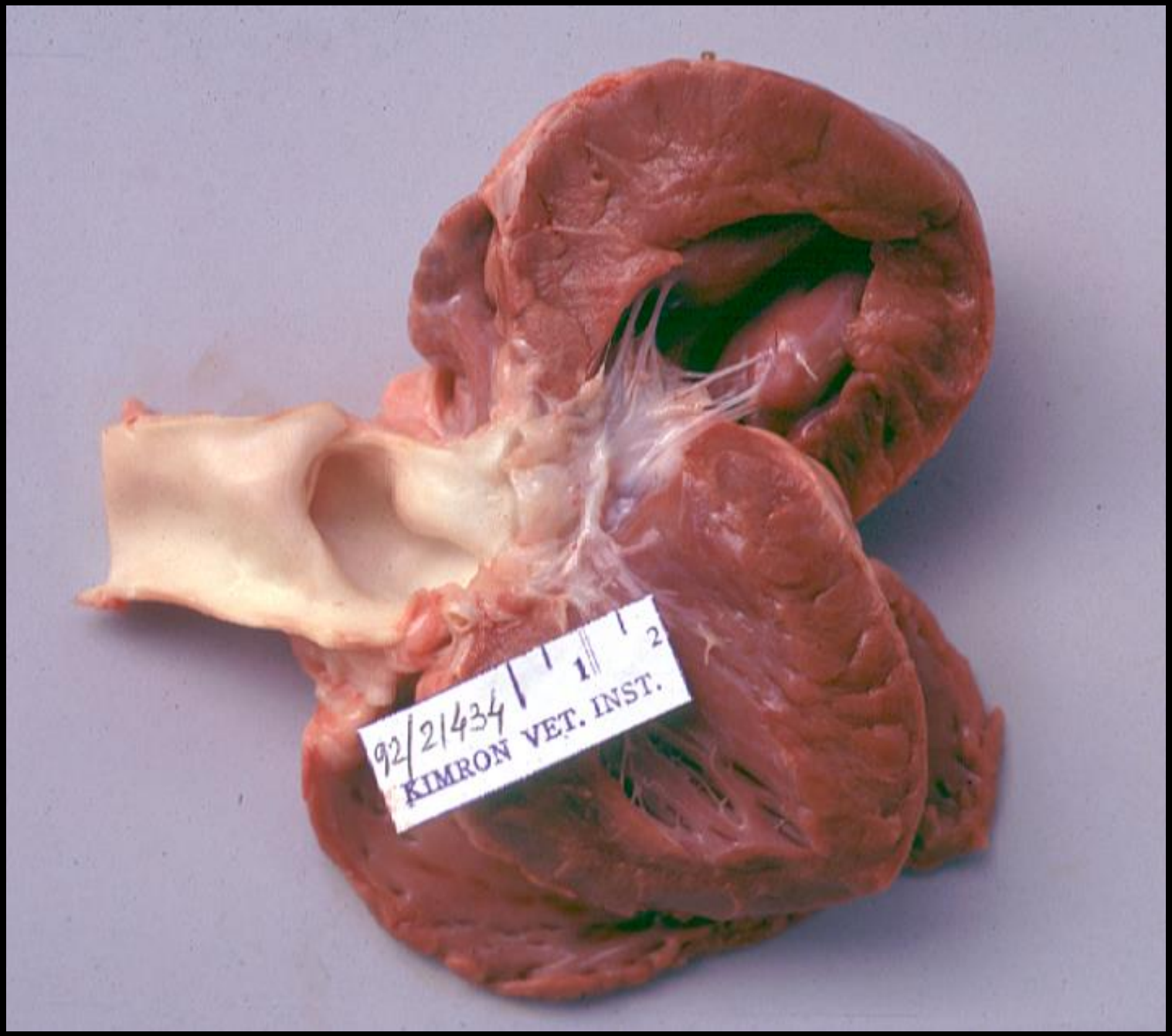
92/21434
KIMRON VET. INST.

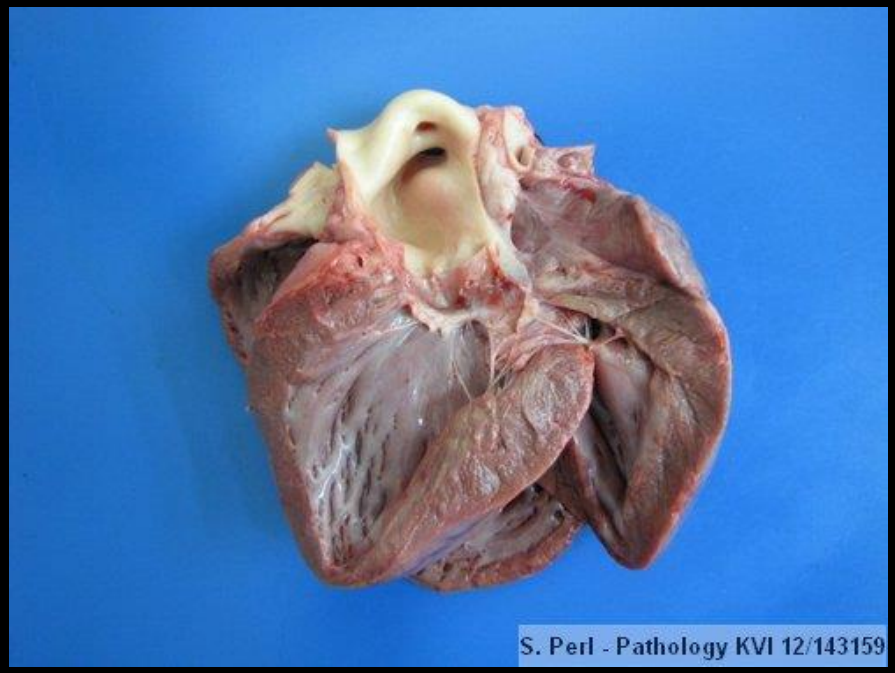
S. Perl - Pathology KVI 12/143159

S. Perl - Pathology KVI 12/143159

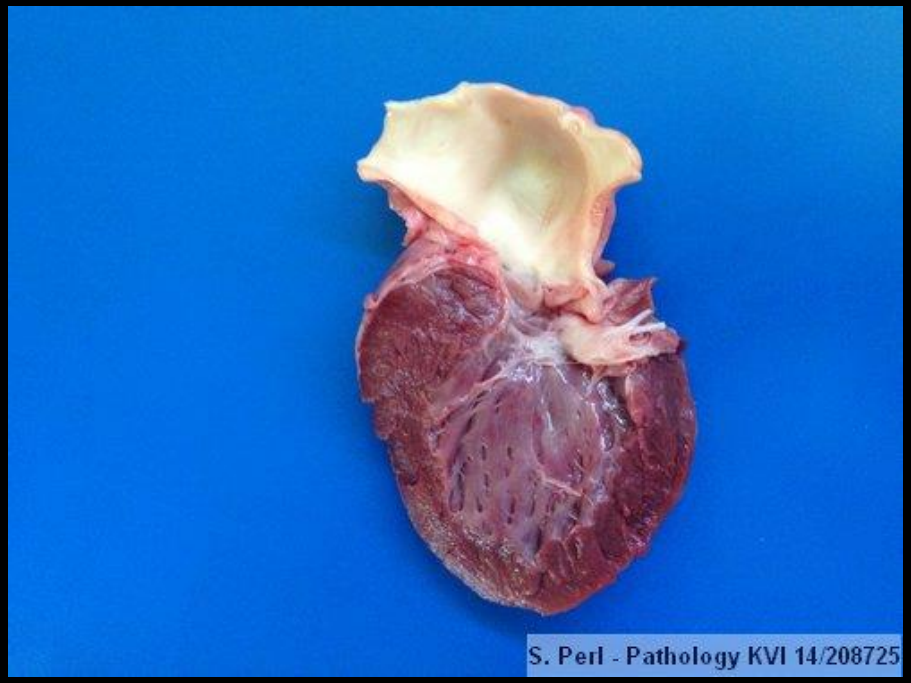
S. Perl - Pathology KVI 14/208725

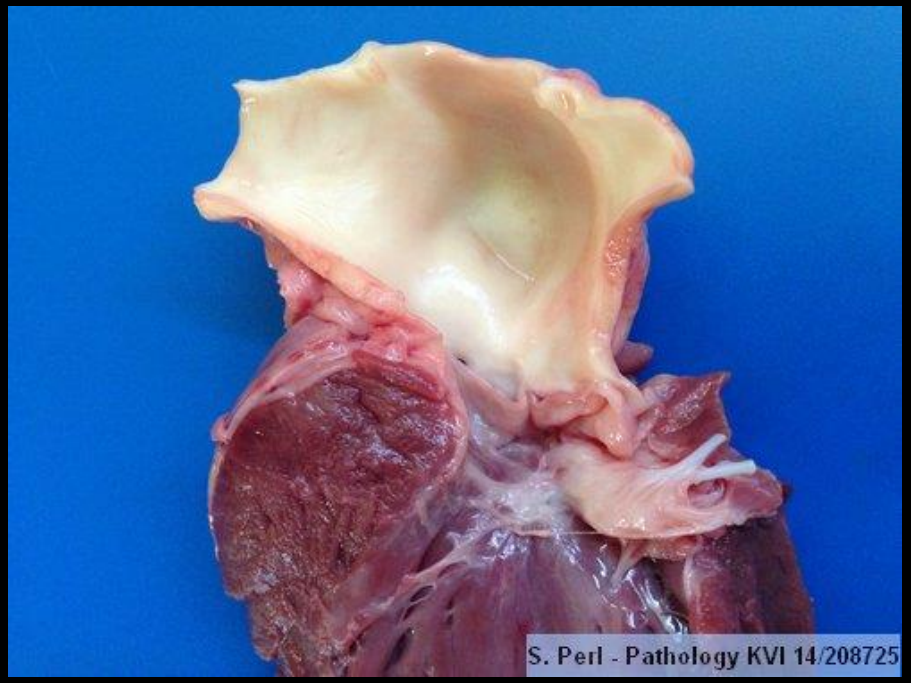
S. Perl - Pathology KVI 14/208725

Aortic stenosis

German shepherd	Rottweiler
Boxer	Samoyed
Newfoundland	Bull terrier breeds
Pointer	Great Dane
Golden retriever	English Bulldog

Dysplasia of tricuspid valve

Displasia of trcuspid valve

- Characteristics
  - Focal or diffuse thickening of leaflets
  - Absence of a leaflet
  - Short cordae tendineae
  - Short papillary muscles
  - Fusion of affected valve with the ventricular wall

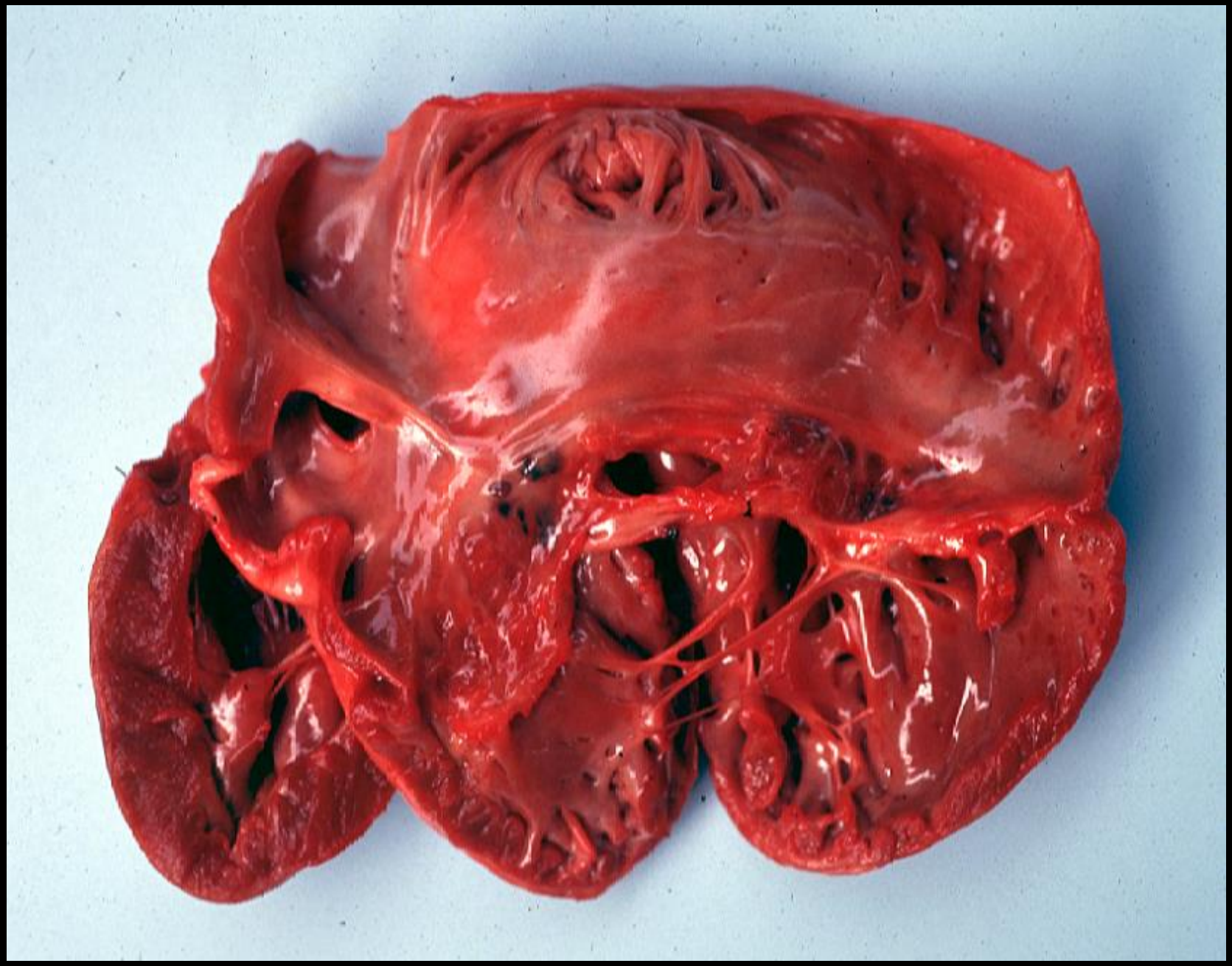

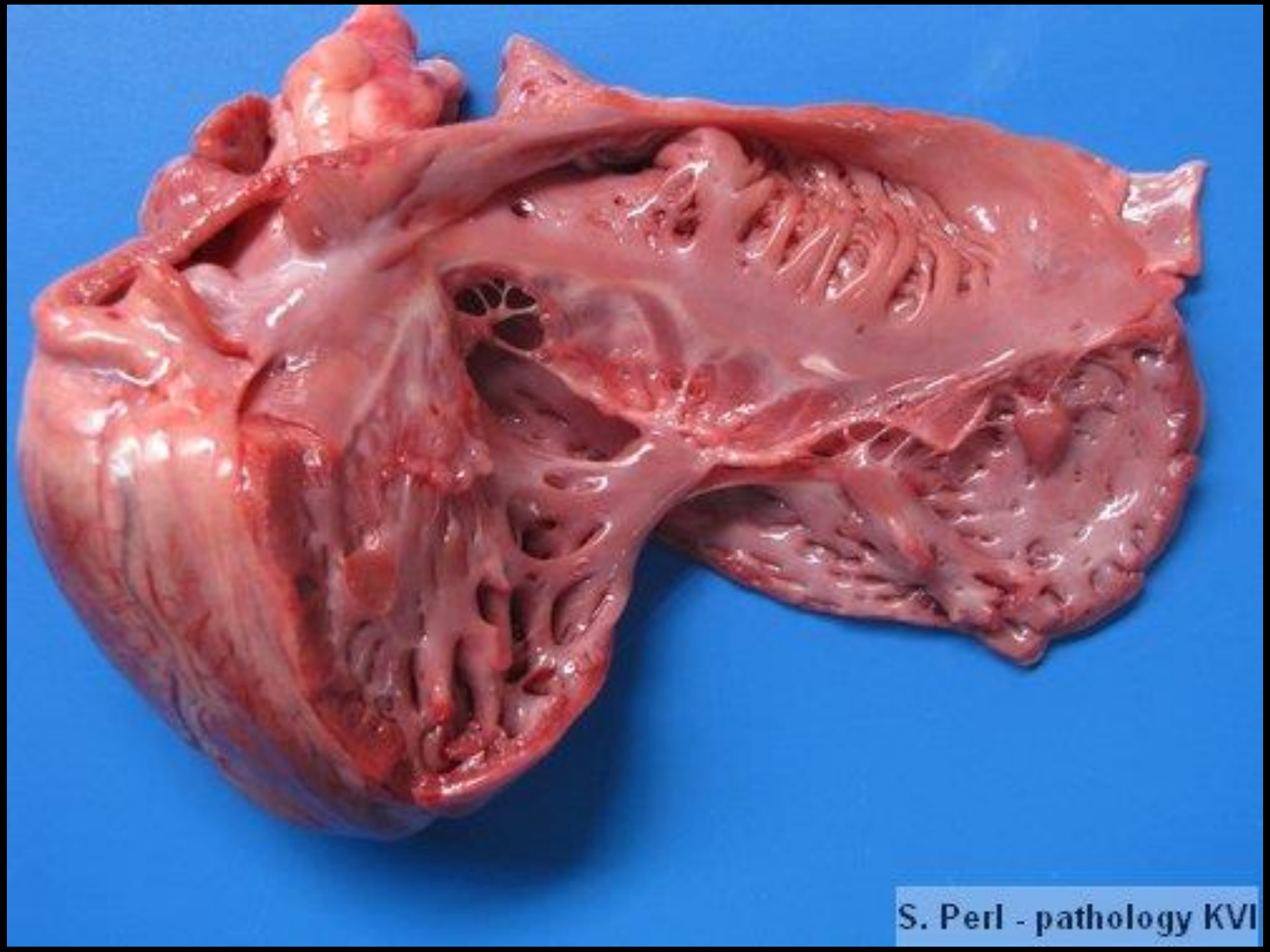
S. Perl - pathology KVI

Dysplasia of tricuspid valve

- **Effects**

  Enlarged right atrium

  Enlarged right ventricle

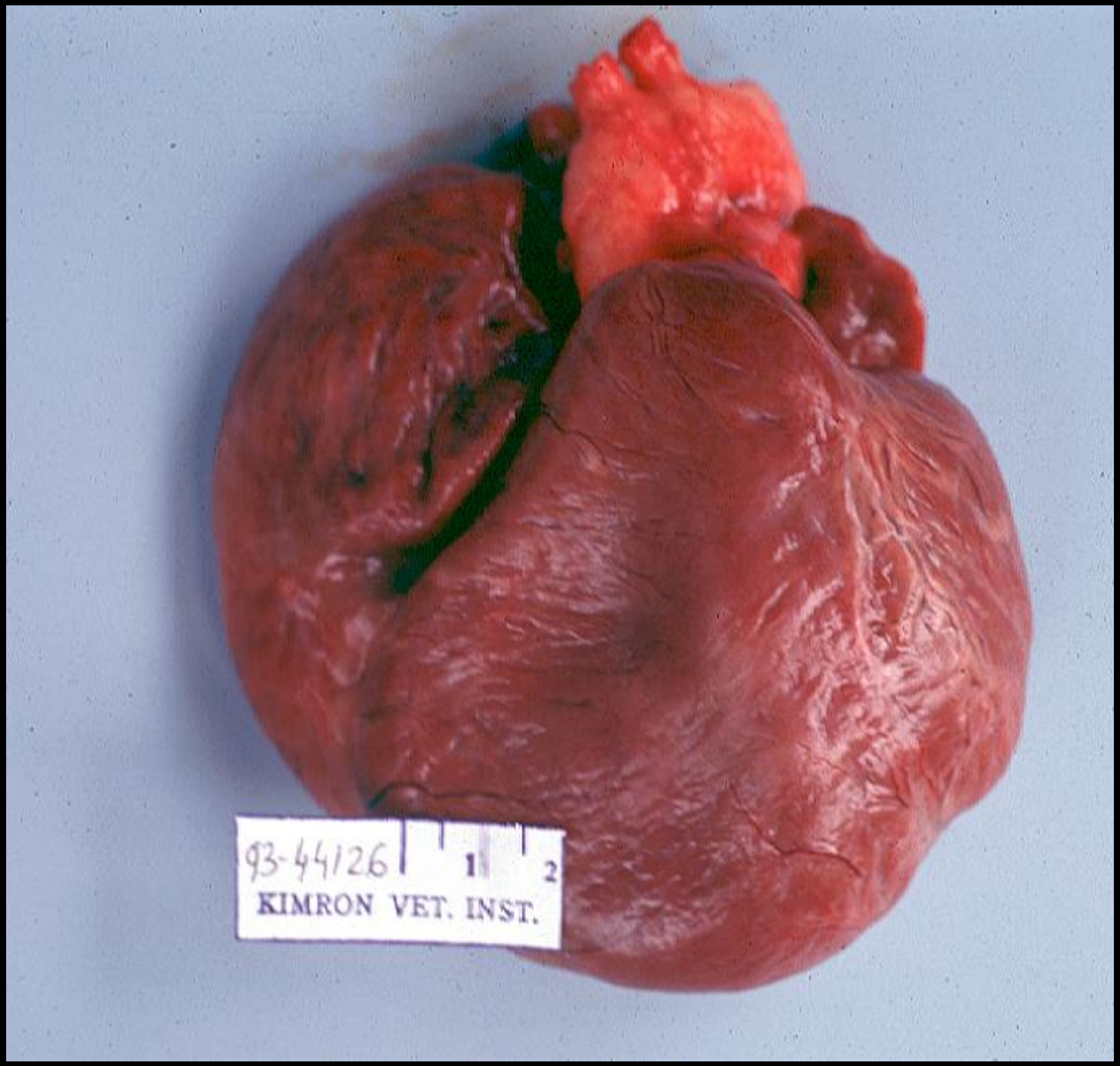
93-44126
1
2
KIMRON VET. INST.

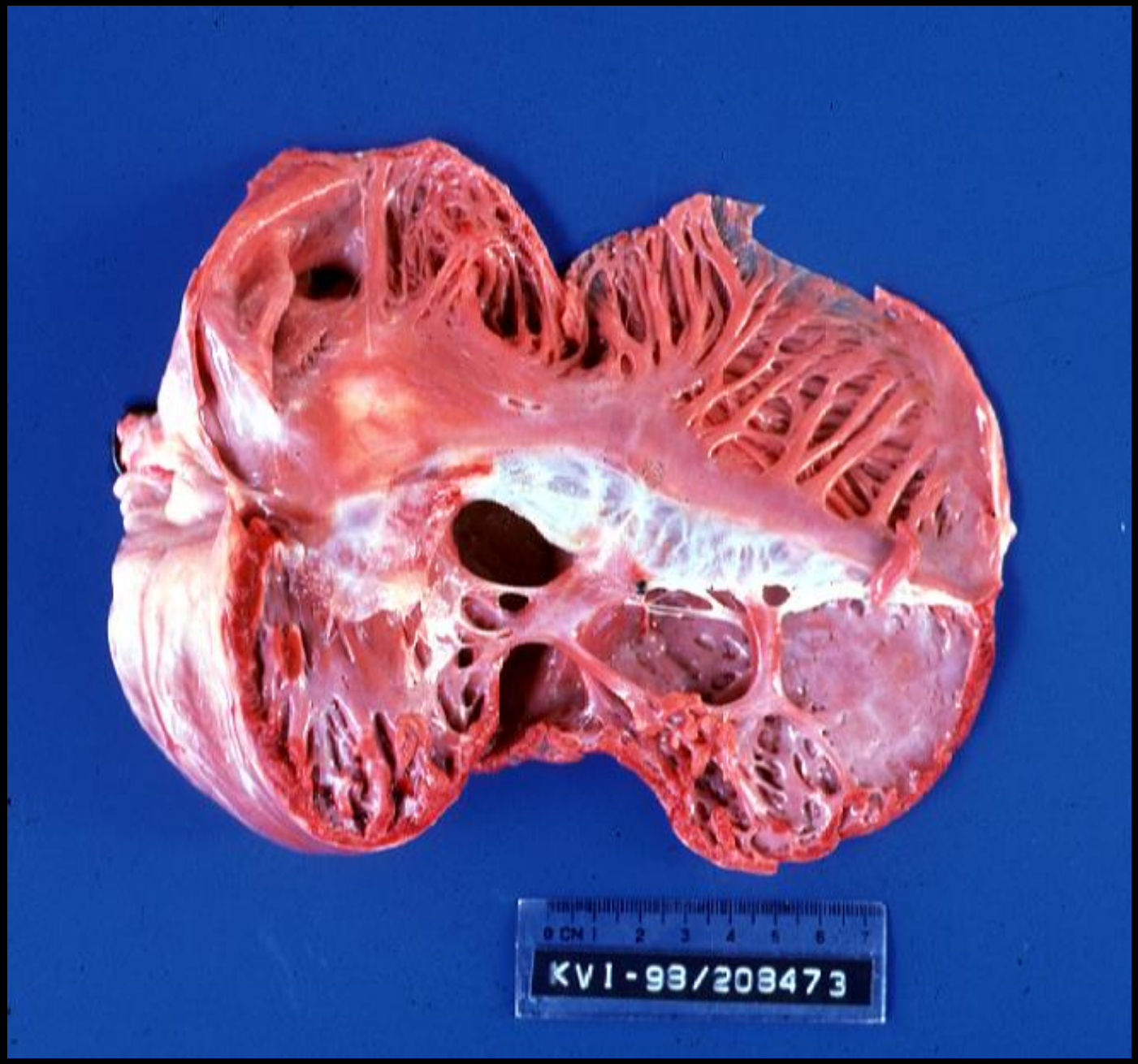
0 CM 1 2 3 4 5 6 7
KVI-98/208473

Mitral valvular insufficiency

Mitral valvular insufficiency

- **Characteristics**

  Malformation of the mitral valve:

  enlarged anulus

  short thick leaflets

  short thick cordae tendinea

  atrophic or hypertrophic papillary muscle

S. Perl - Pathology KVI 93218

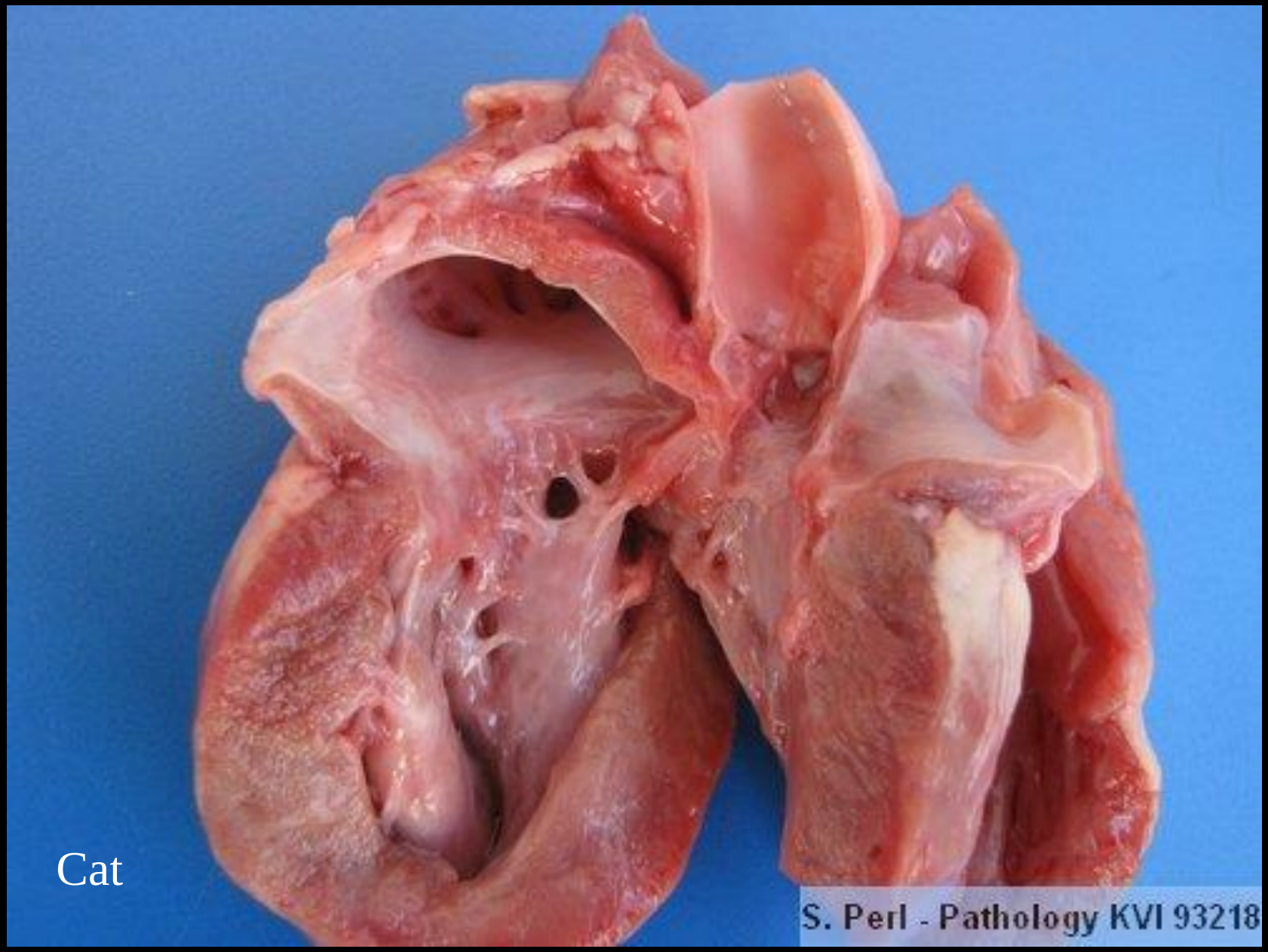
Cat
S. Perl - Pathology KVI 93218

Mitral valvular insufficiency

- **Effects**

  Enlargement of left atrium

  Enlargement of left ventricle

  Diffuse endocardial fibrosis

Congenital hematomas

Congenital hematomas

Blood - filled cysts lined by an endothelium

- Measure up to 1.0 cm in diameter
- May be single or multiple
- Persist usually for a few months

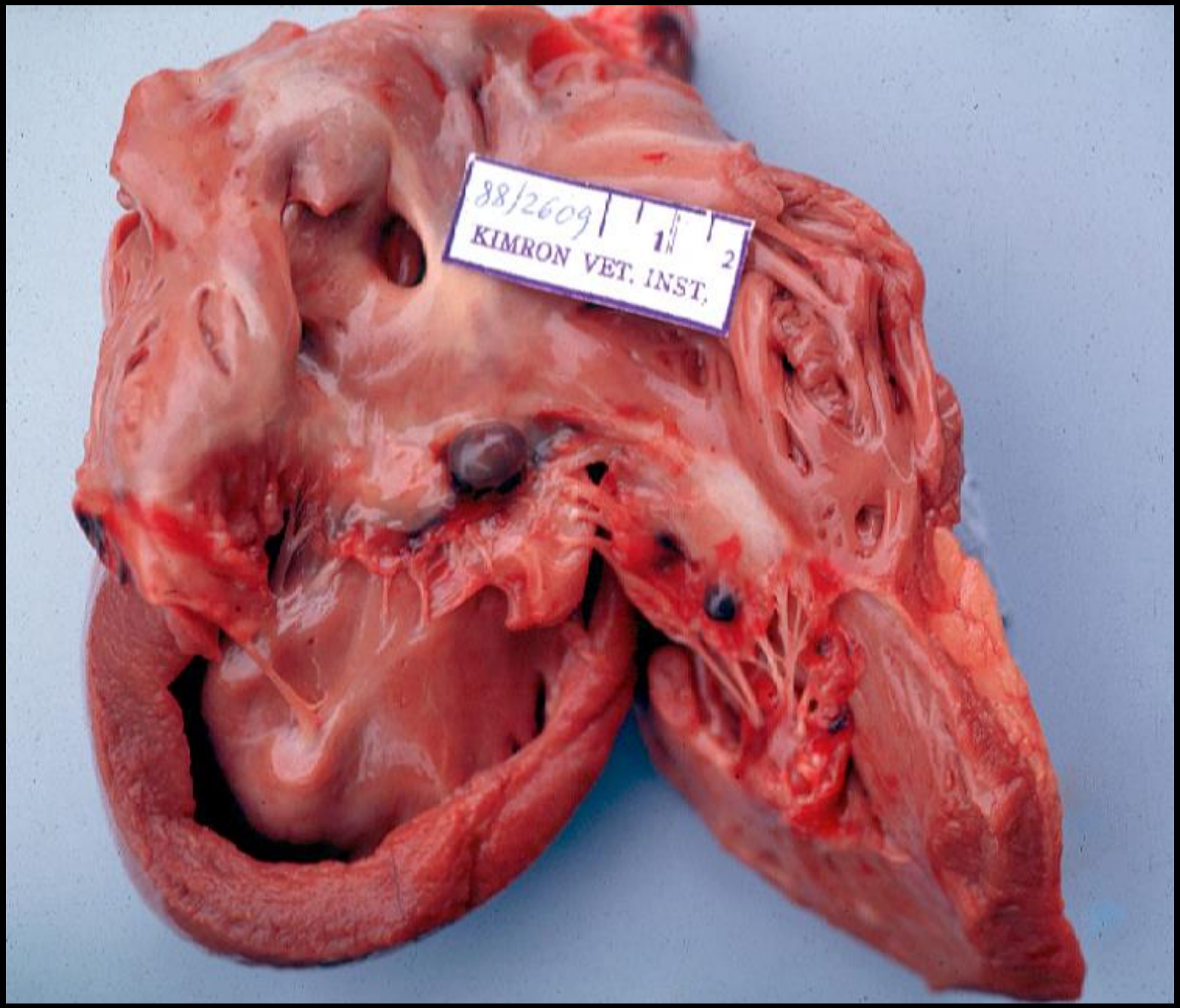
88/2609
1
2
KIMRON VET. INST.

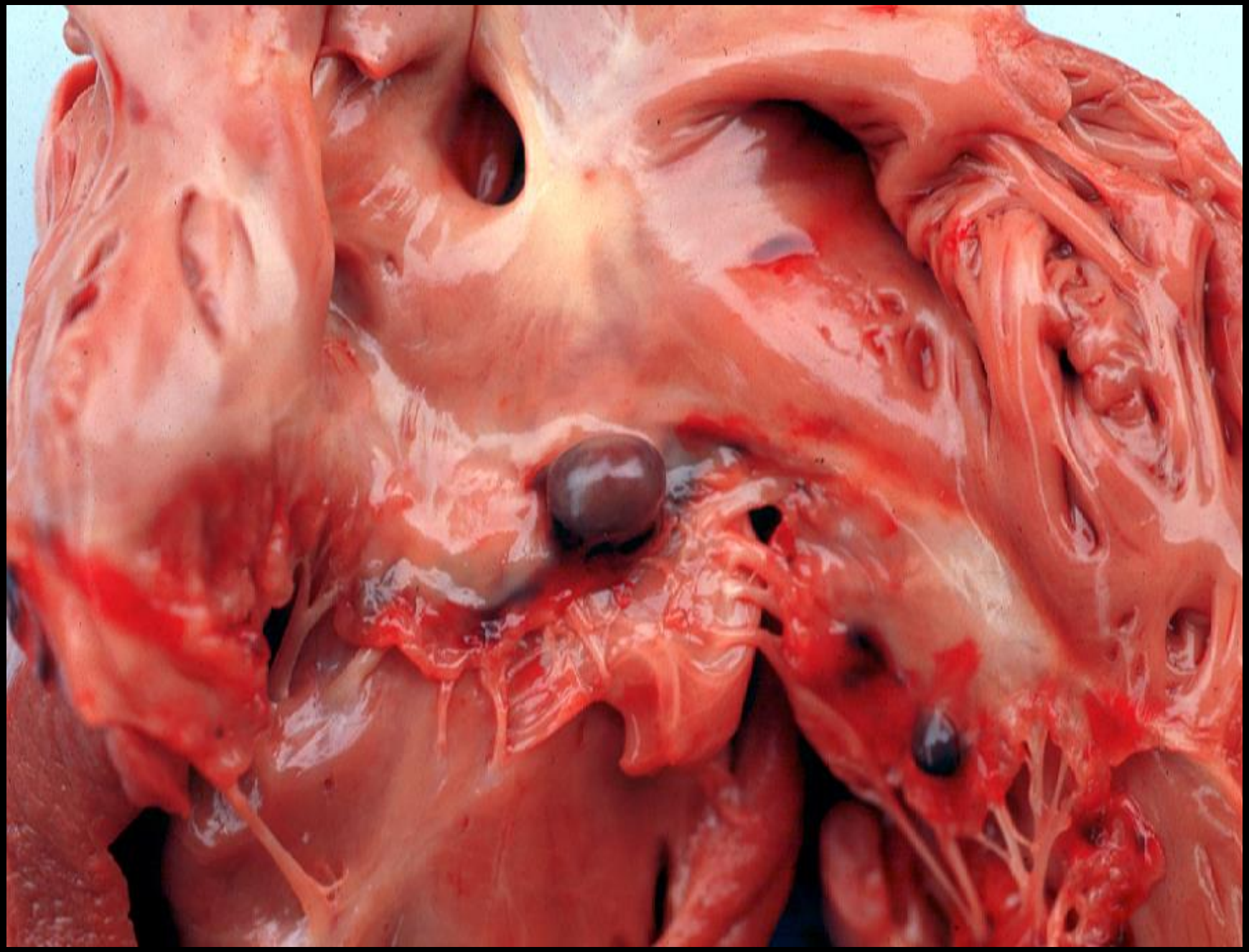

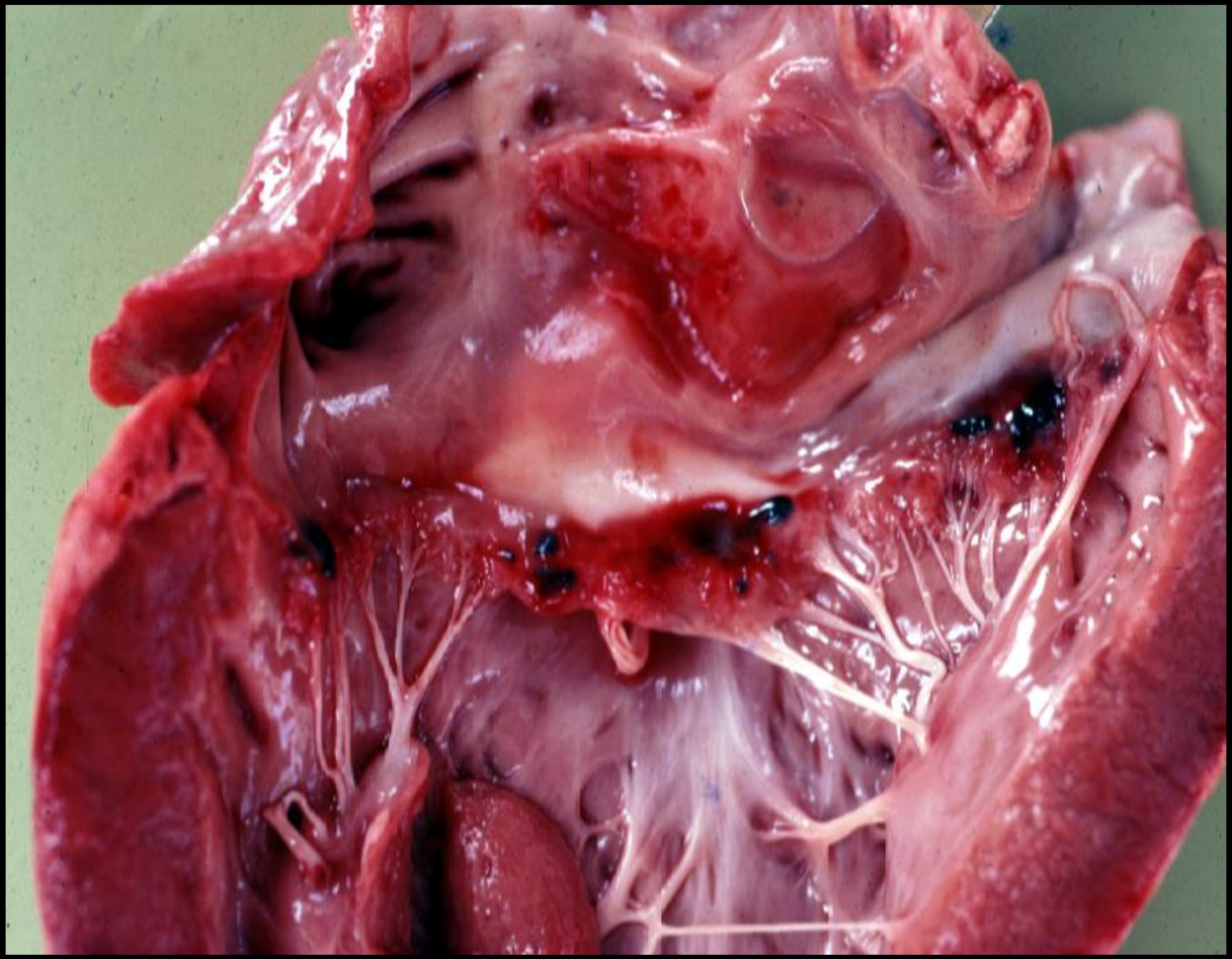

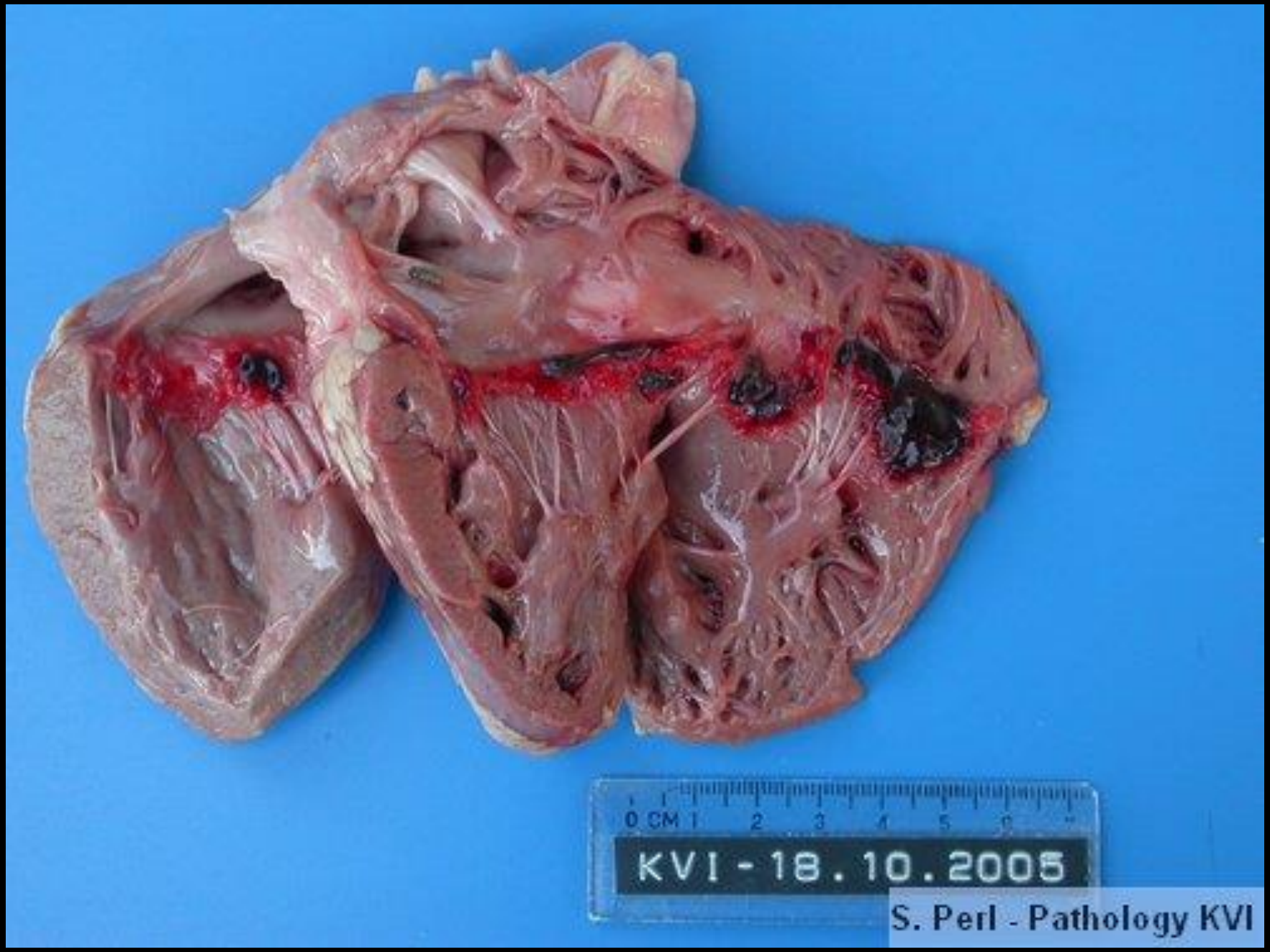
0 CM 1 2 3 4 5
KVI - 18.10.2005
S. Perl - Pathology KVI

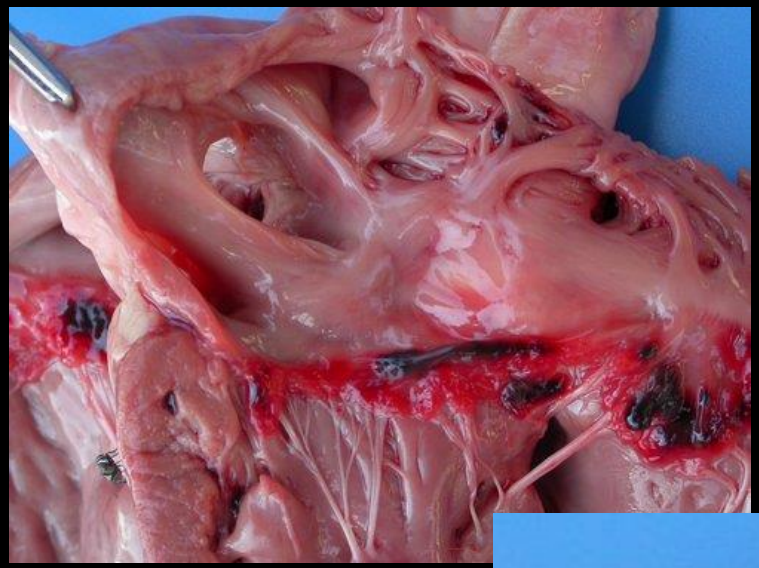

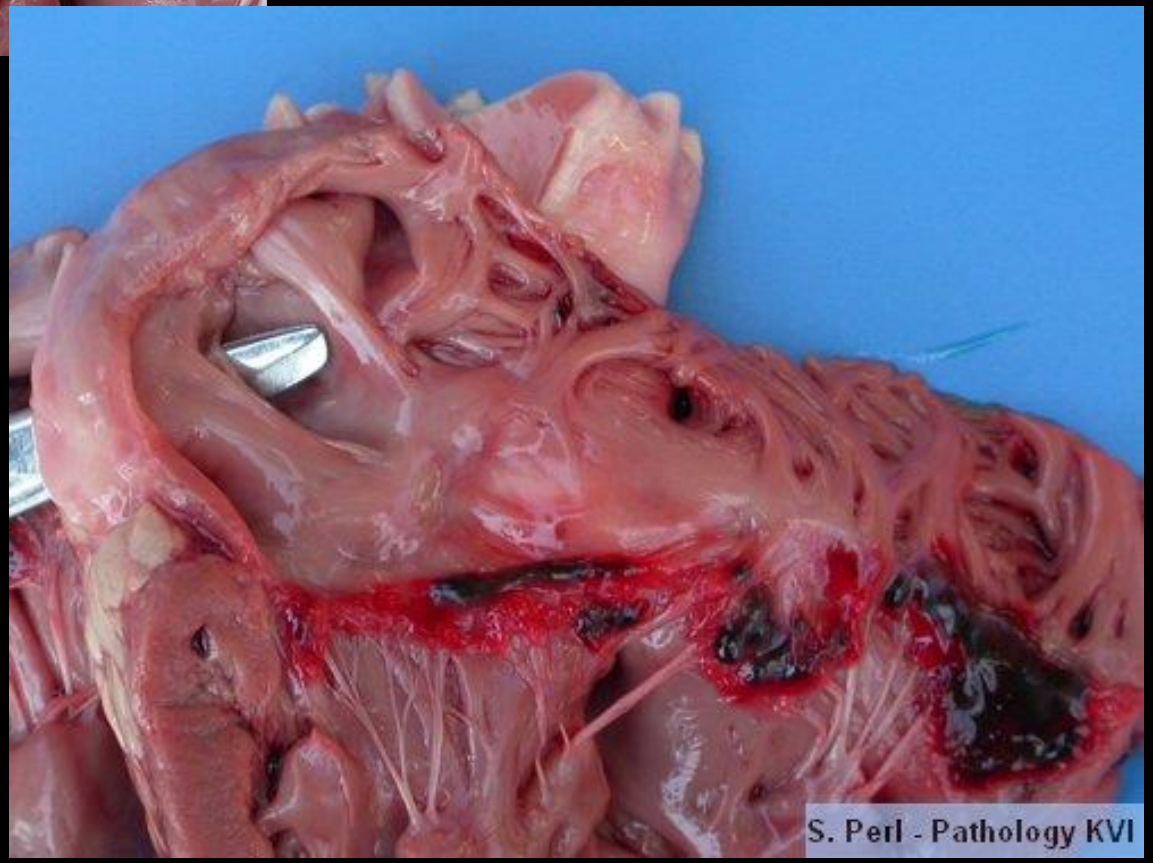
S. Perl - Pathology KVI

Pathology books

- Pathology of domestic animals, Vol. 1,2,3. - *sixth edition*

  Jubb, Kennedy, and Palmer's
- Pathologic basis of veterinary disease - *fifth edition*

  M. Donald McGavin, James F. Zachary
- Pathologic basis of veterinary disease - *sixth edition*

  James F. Zachary

http://www.vetserv.moag.gov.il/vet

לרשום בגוגל – מכון וטרינרי פתולוגיה Teaching

D. Incomplete separation of, or abnormally positioned, vessels

1. Persistent right aortic arch
2. Transposition of great vessels
3. Common trunk

Persistent right aortic arch (PRAA)

Persistent right aortic arch

- **Characteristics**

  Vascular ring around the trachea and esophagus

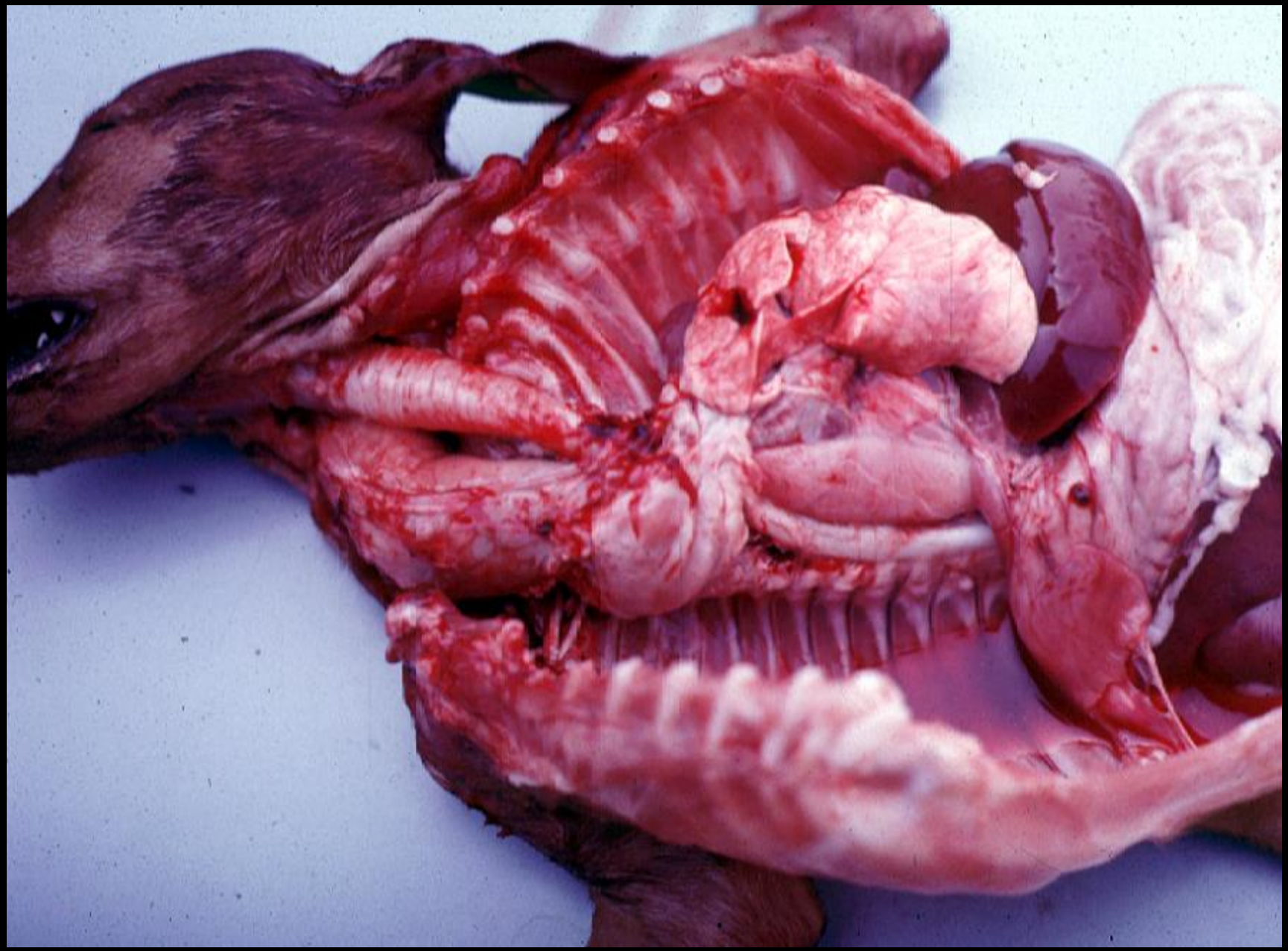

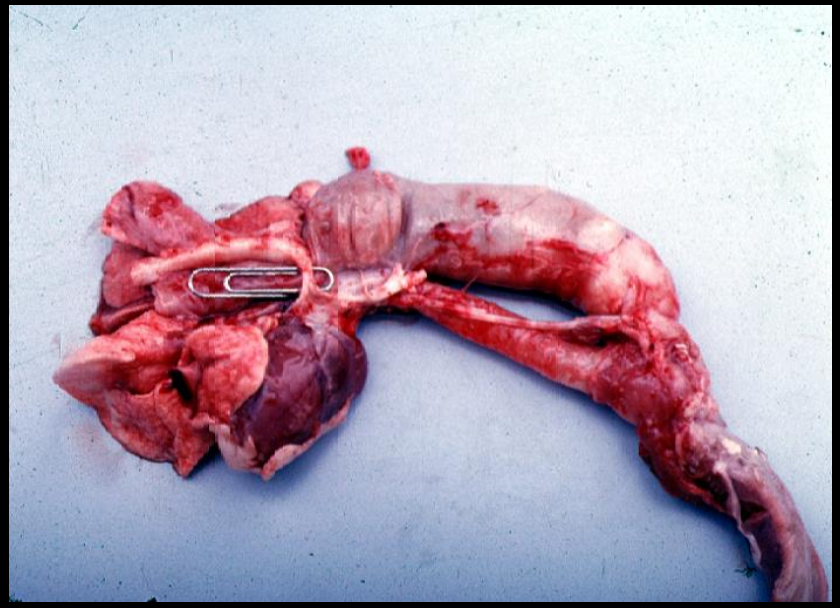

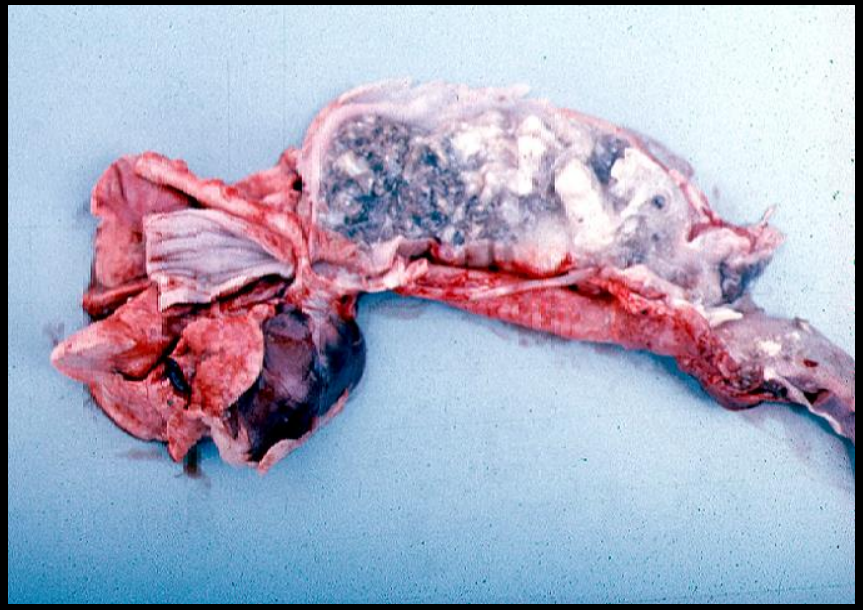

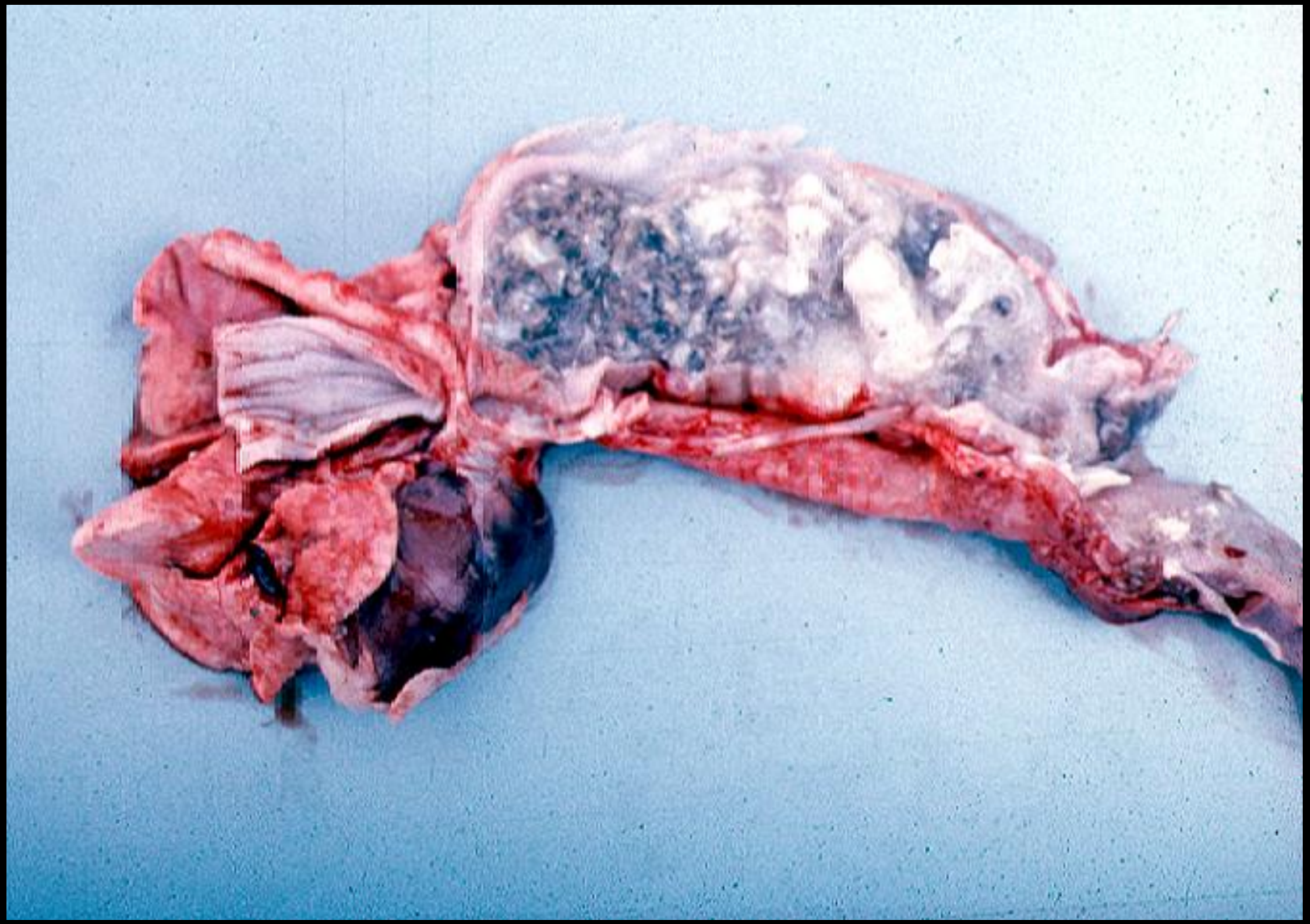

Ligamentum arteriosum

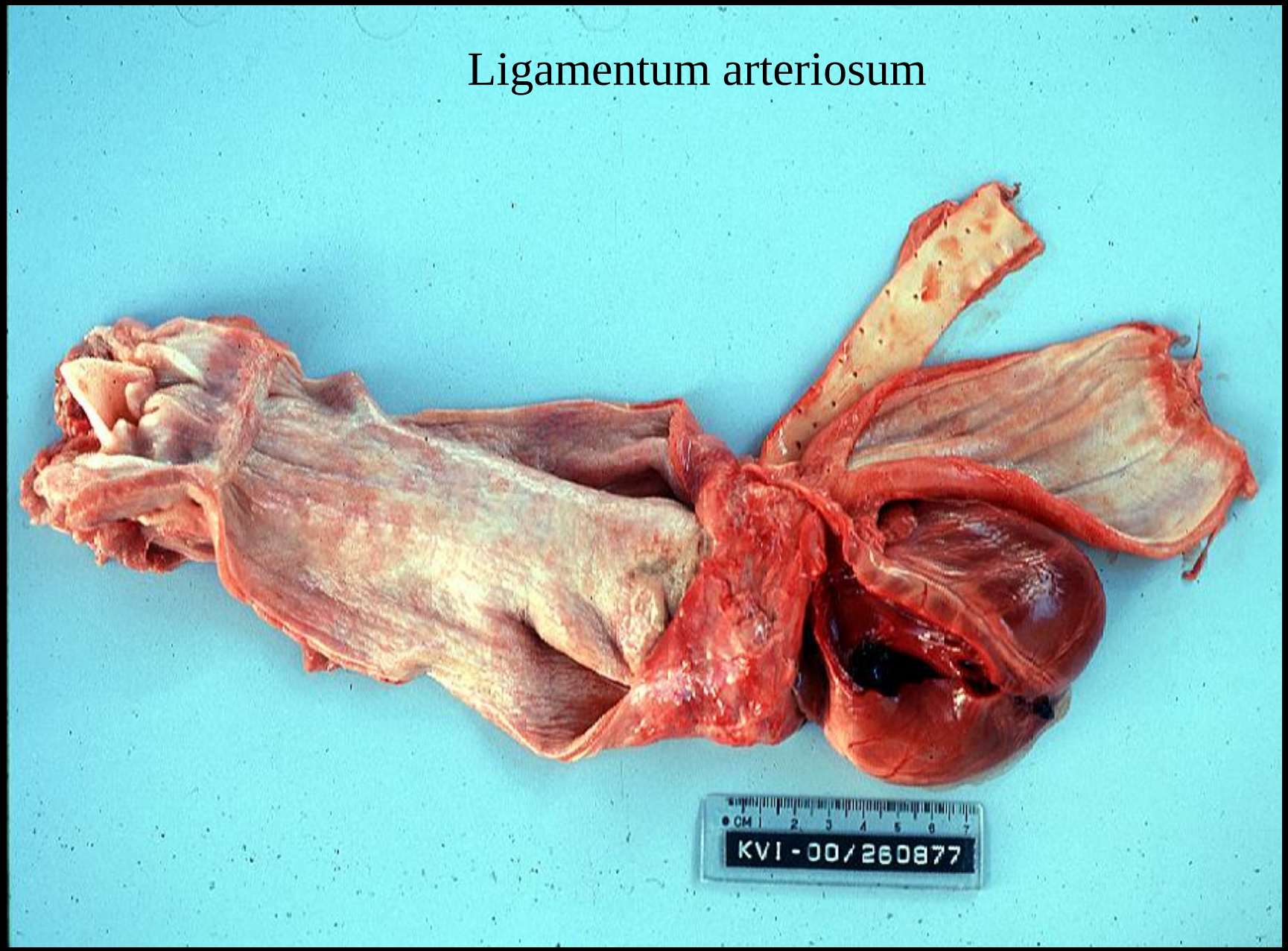

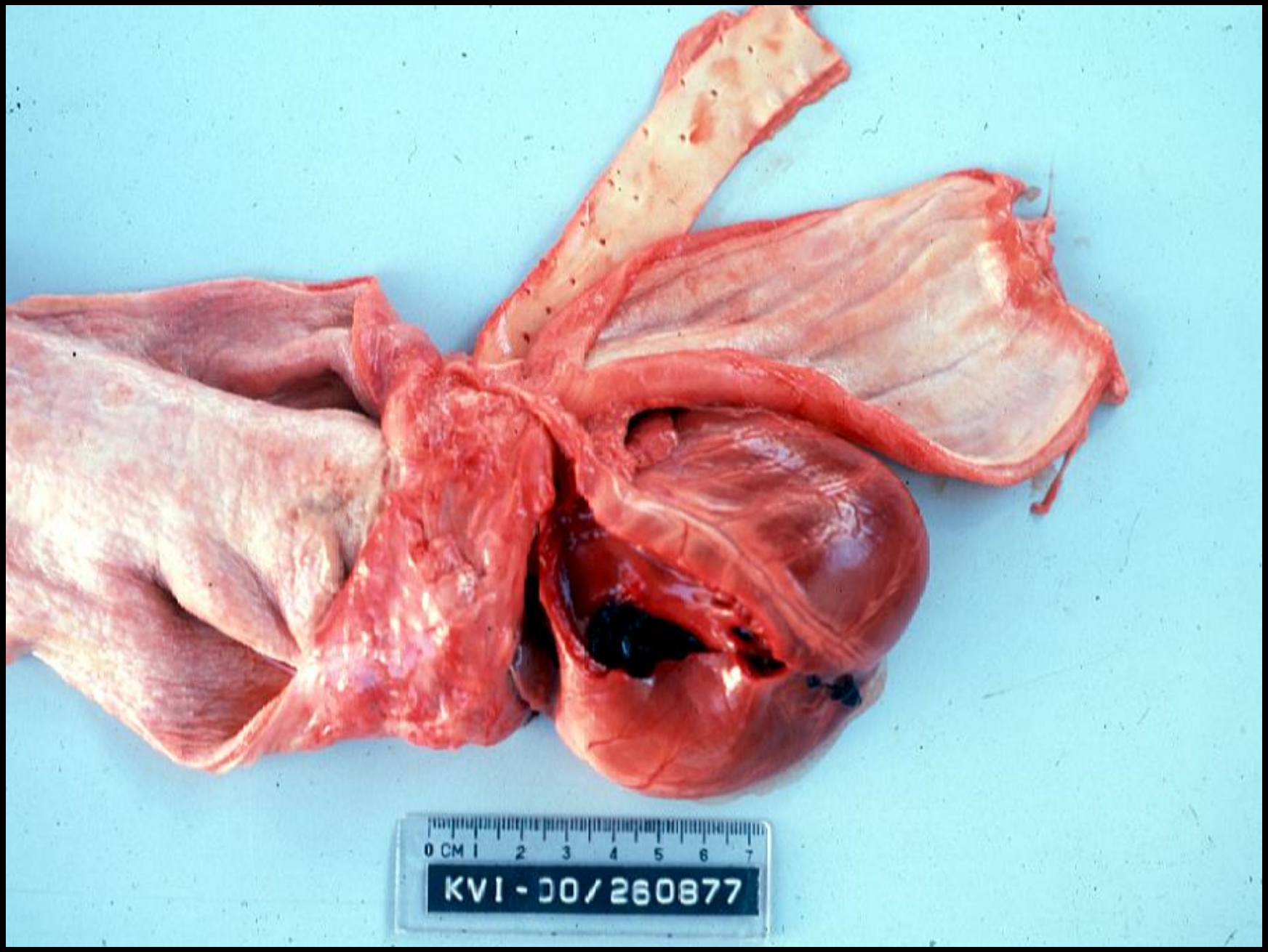
0 CM 1 2 3 4 5 6 7
KVI-00/260877

Persistent right aortic arch

- **Effects**

  Partially occlusion of the esophagus.

  Dysphagia - dilatation of the cervical portion of the esophagus.

  Secondary aspiration pneumonia.

  Partially occlusion of the trachea.

Persistent right aortic arch

German shepherd

Irish setter

Great Dane

Transposition of great vessels

Transposition of great vessels

- Characteristics
  - Complete transposition
  - Overriding aorta
  - Both vessels leave the right ventricle
  - Truncus arteriosus

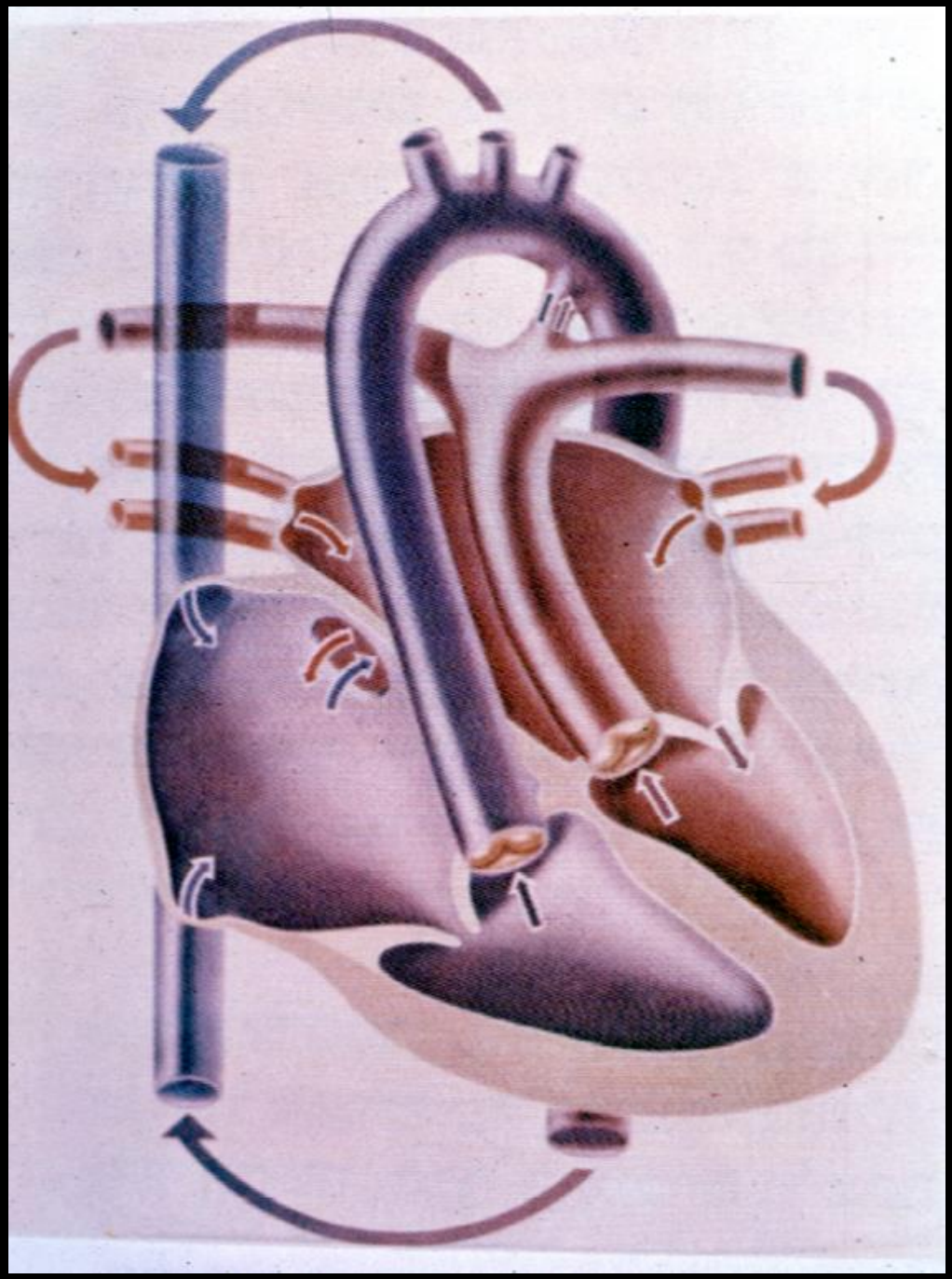

Transposition of great vessels

Transposition of great vessels

- **Effects**

  Some anomalies are compatible with life

  Some are incompatible with life

88/2861
1
2
KIMRON VET. INST.

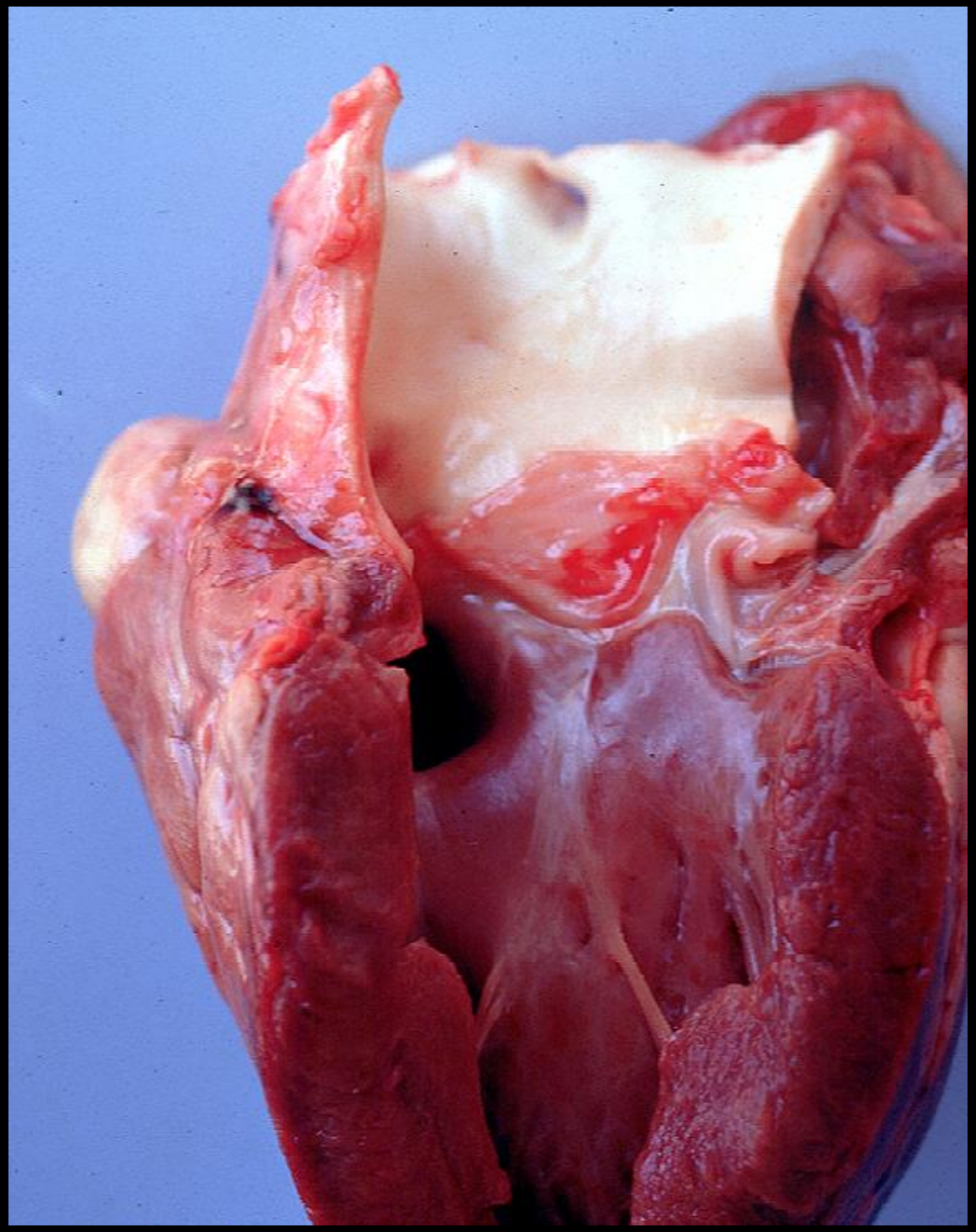

Truncus arteriosus/
Common trunc

Miscellaneous cardiac anomalies

1. Ectopia cordis
2. Two hearts
3. Pericadial anomalies
4. Endocardial fibroelastosis
5. Epithelial inclusions in the myocardium

Ectopia cordis

Ectopia cordis

Heart lies outside the thorax

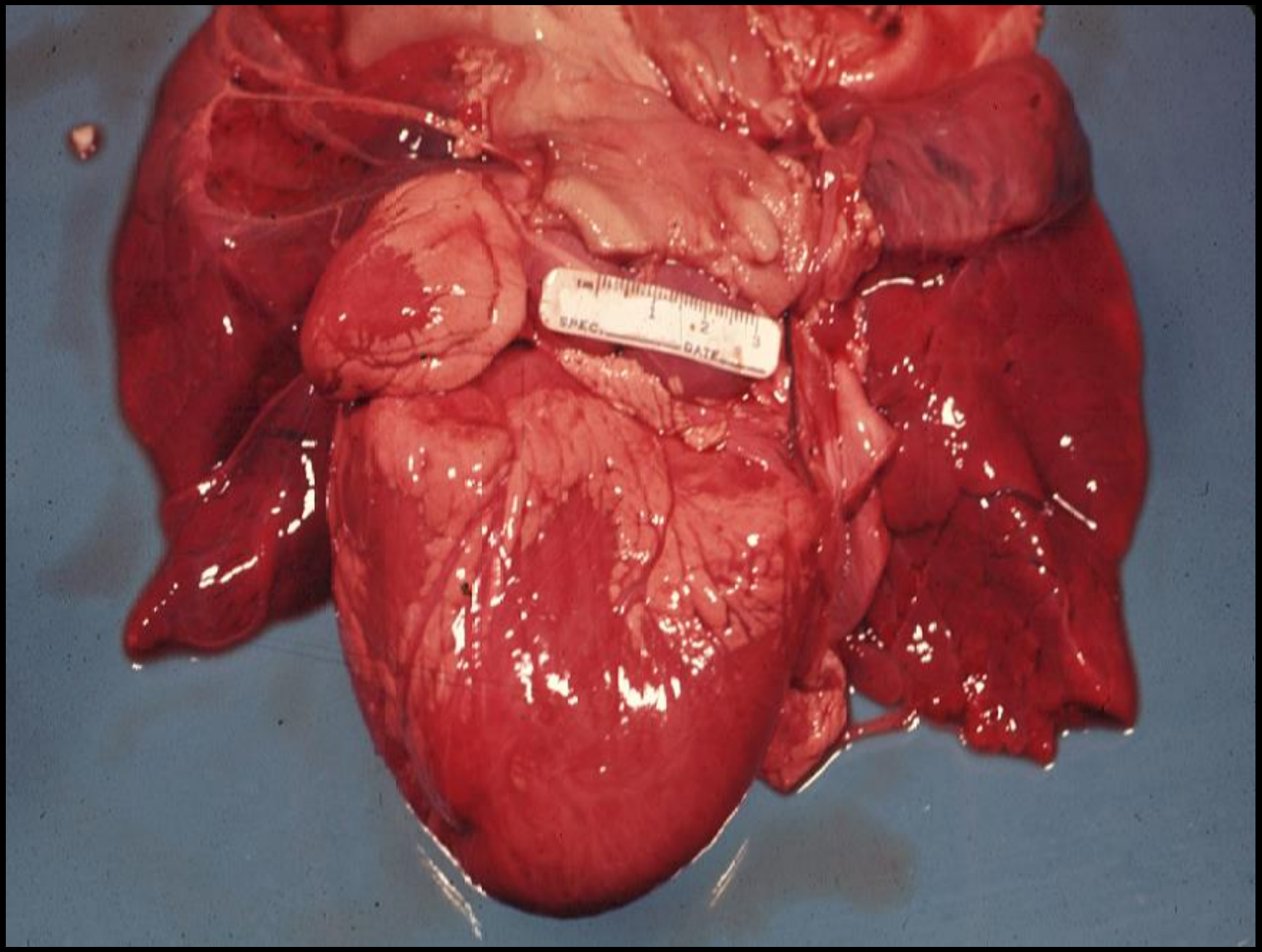
SPEC.
DATE

Anomalies of the pericardium

Anomalies of the pericardium

- Orifice in the pericardium
- Pericardium is partially absent
- Pericardium is totally absent
- Incomplete development of the diaphragm

Pekingese

0 CM 1 2 3 4 5 6
KVI-04/451028

Peritoneopericardial-diaphragmatic hernia - PPDH

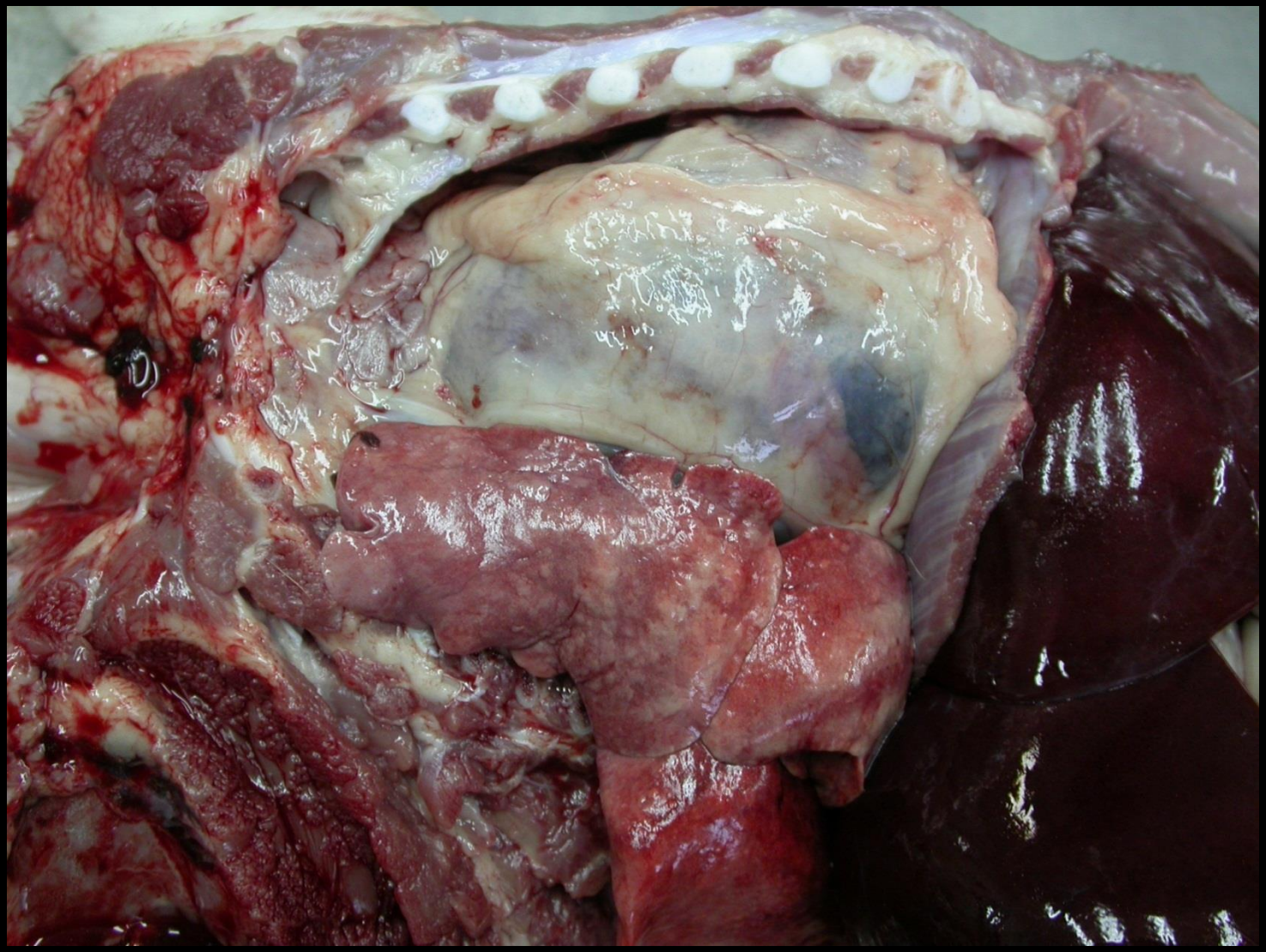

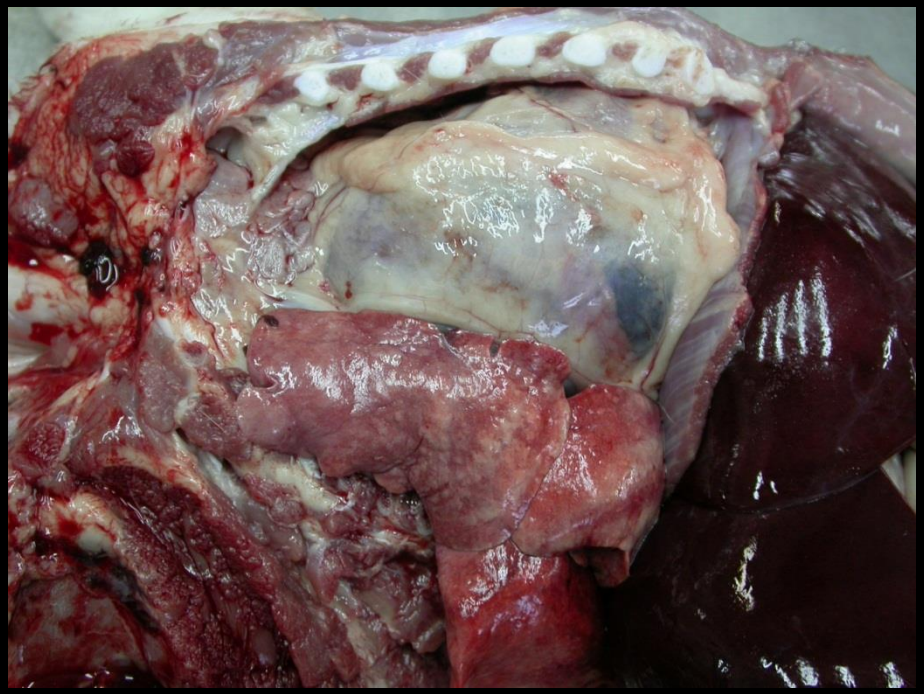

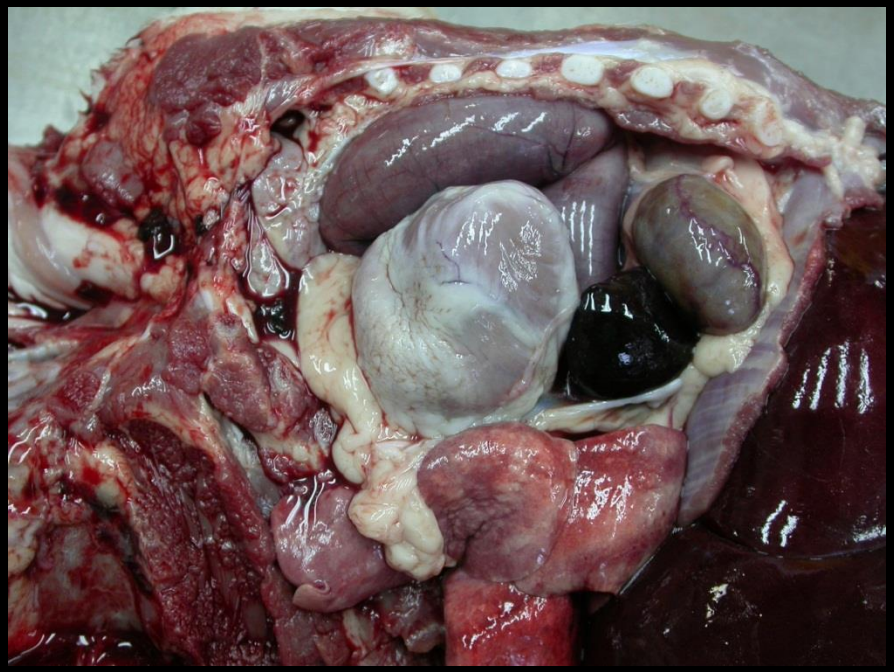

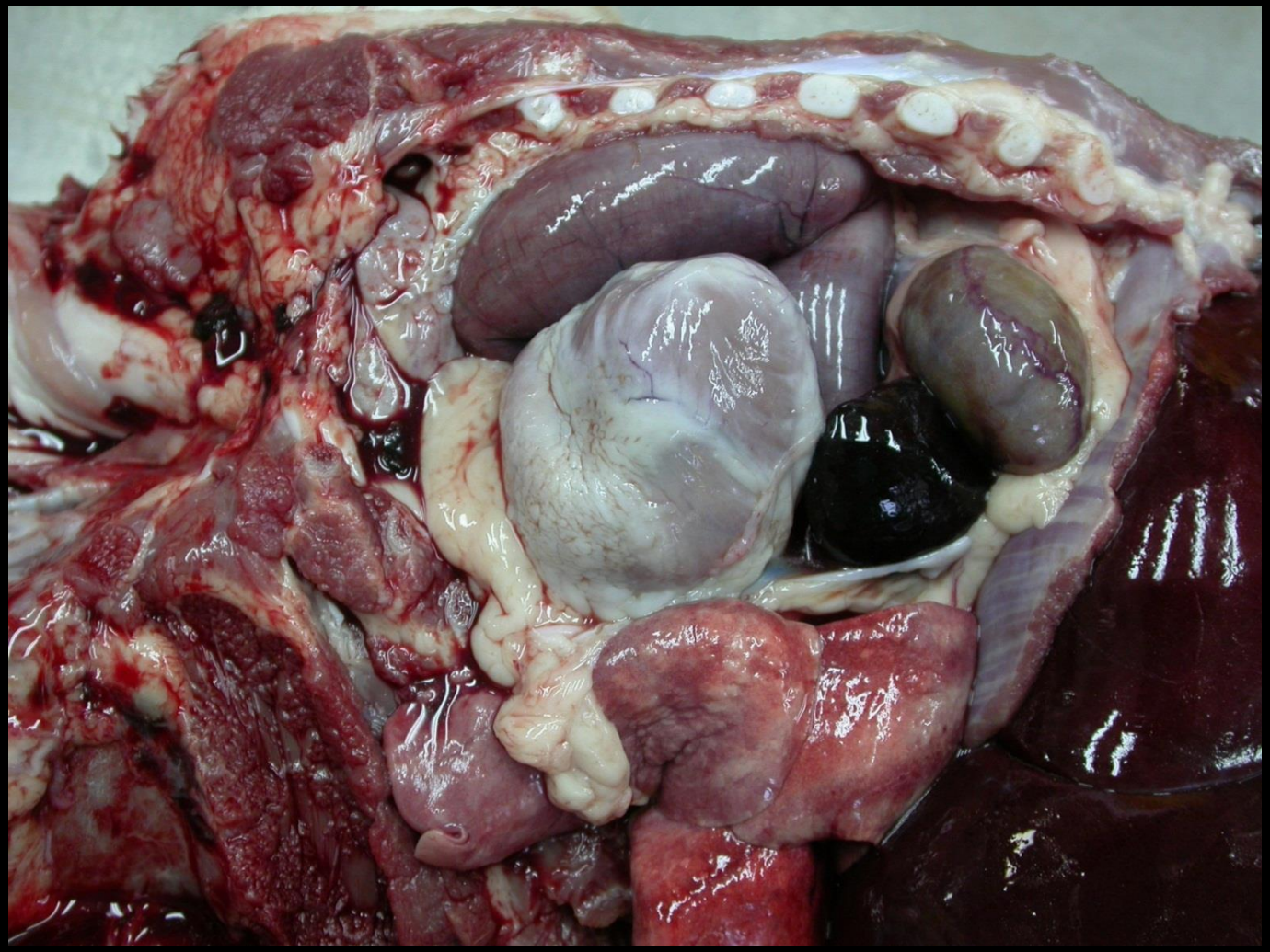

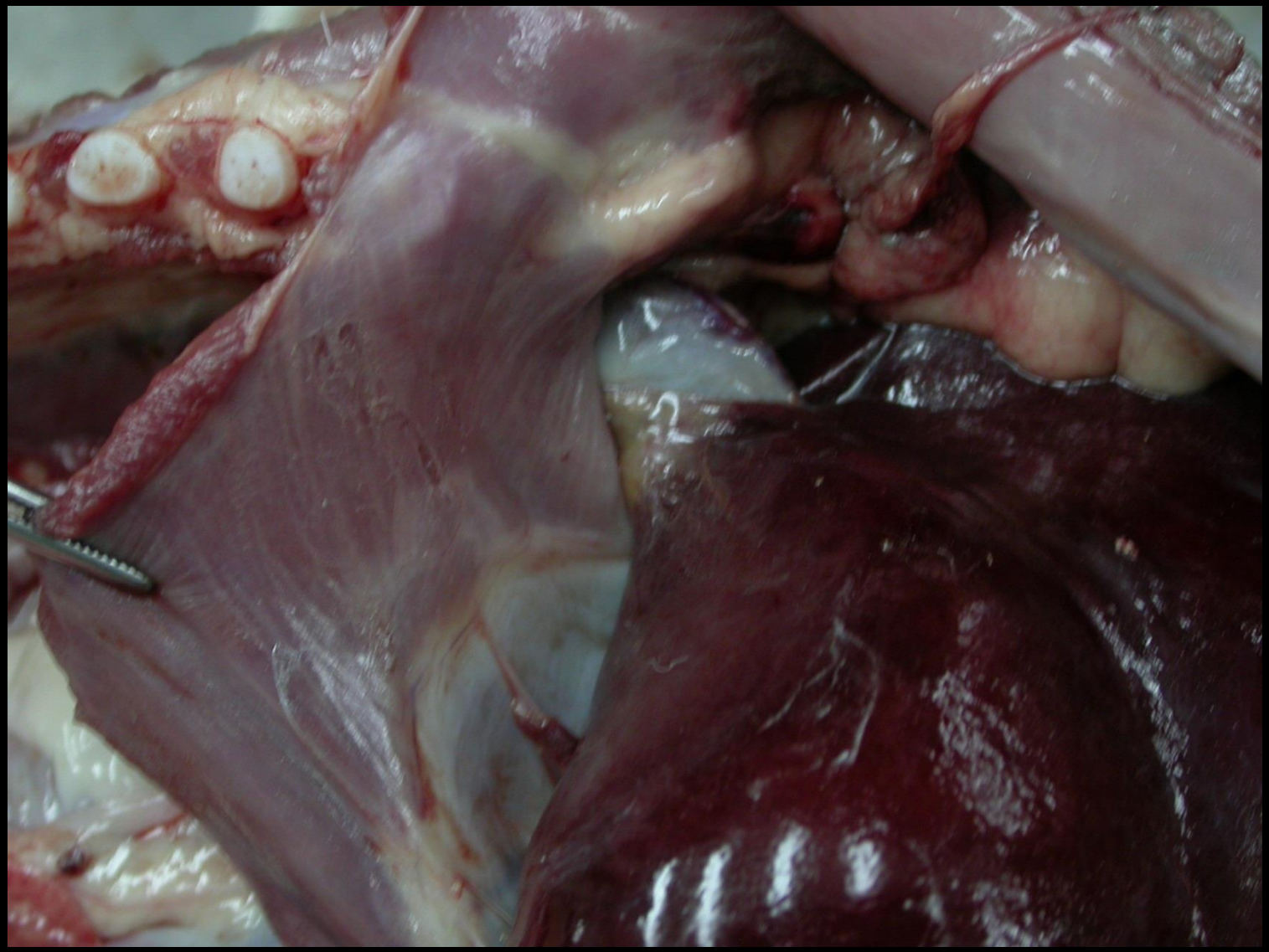

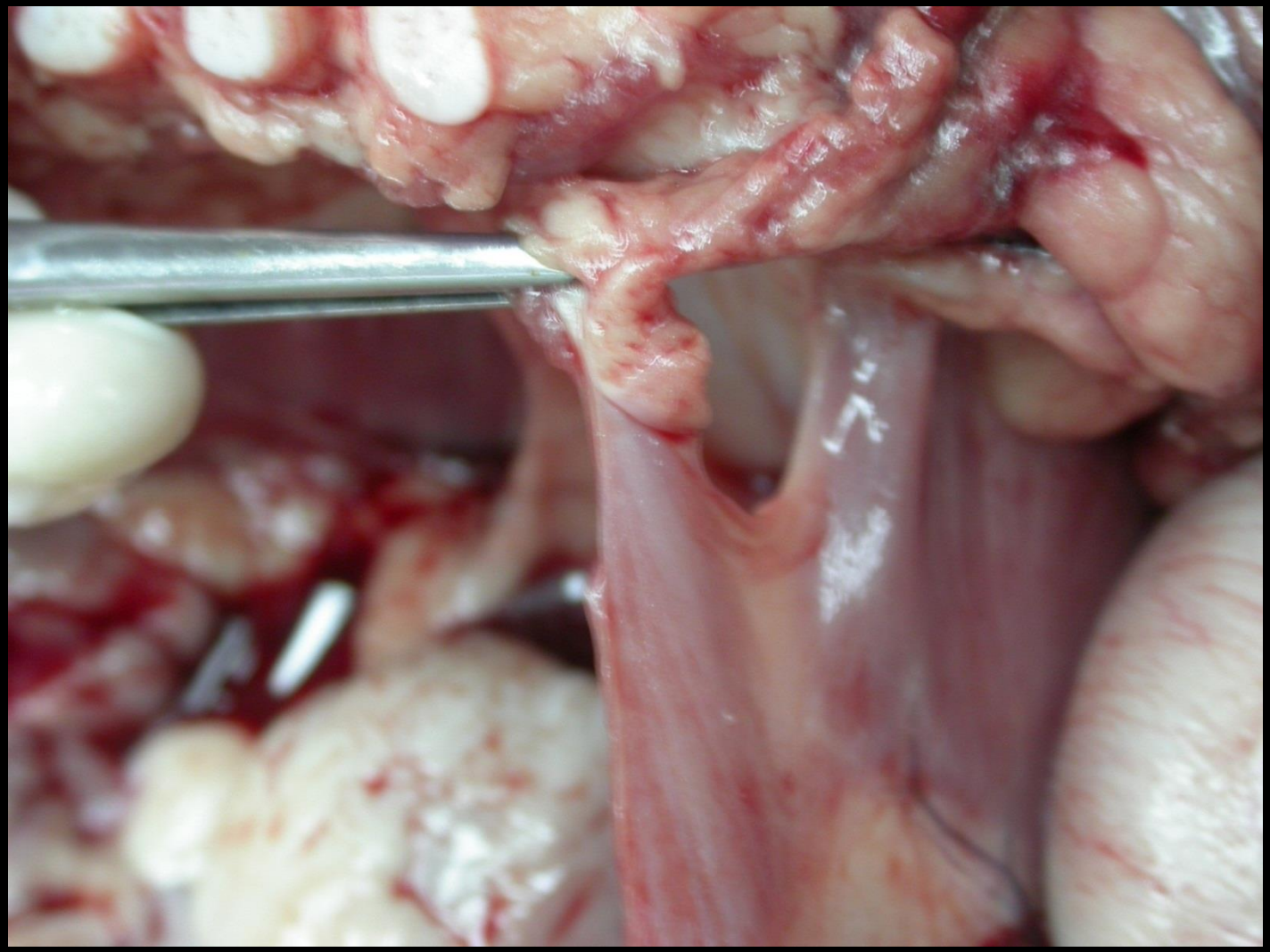

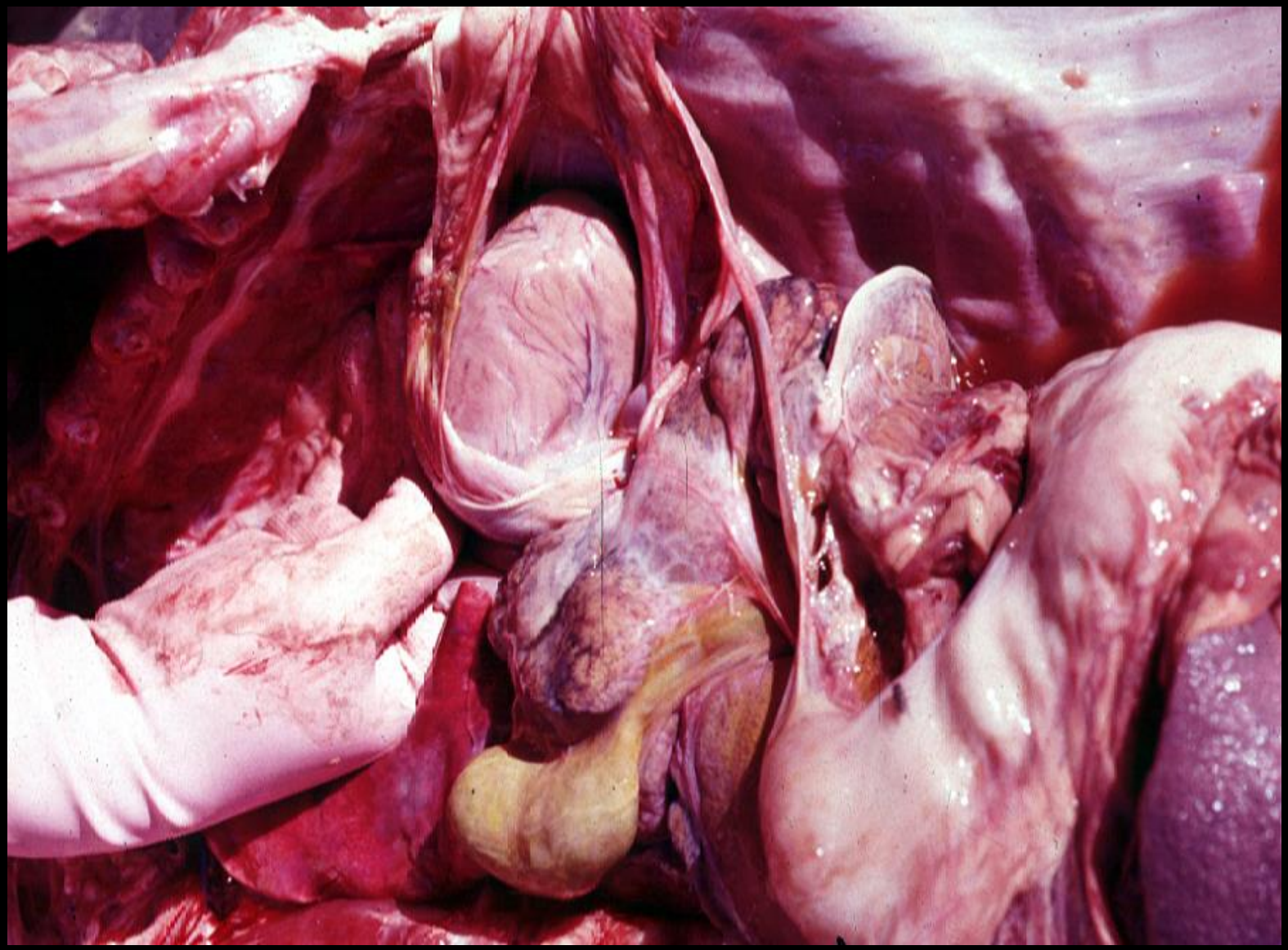

Endocardial fibroelastosis

- Characteristics

  Thickening of the endocardium

  Usually in the left atrium and left ventricle

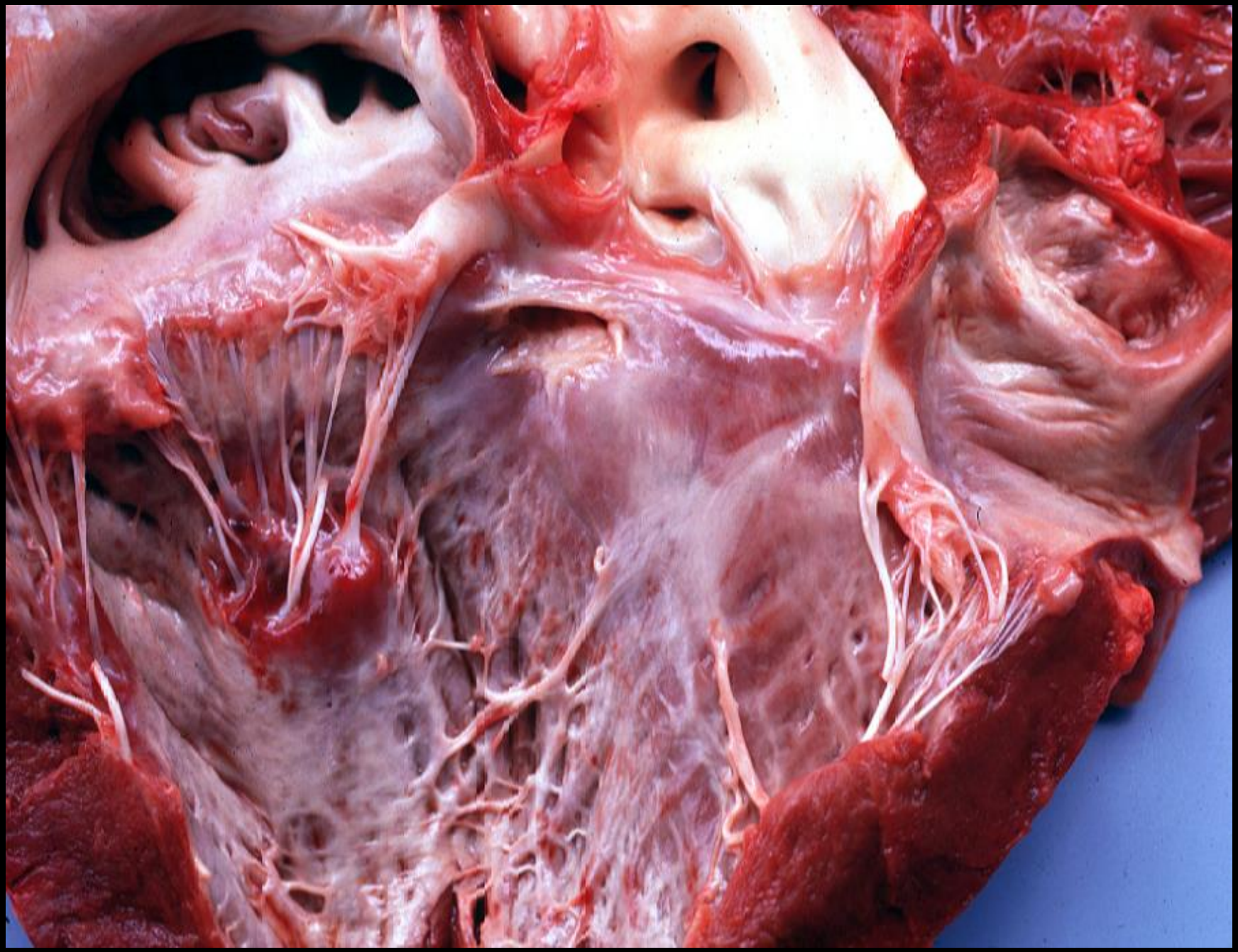

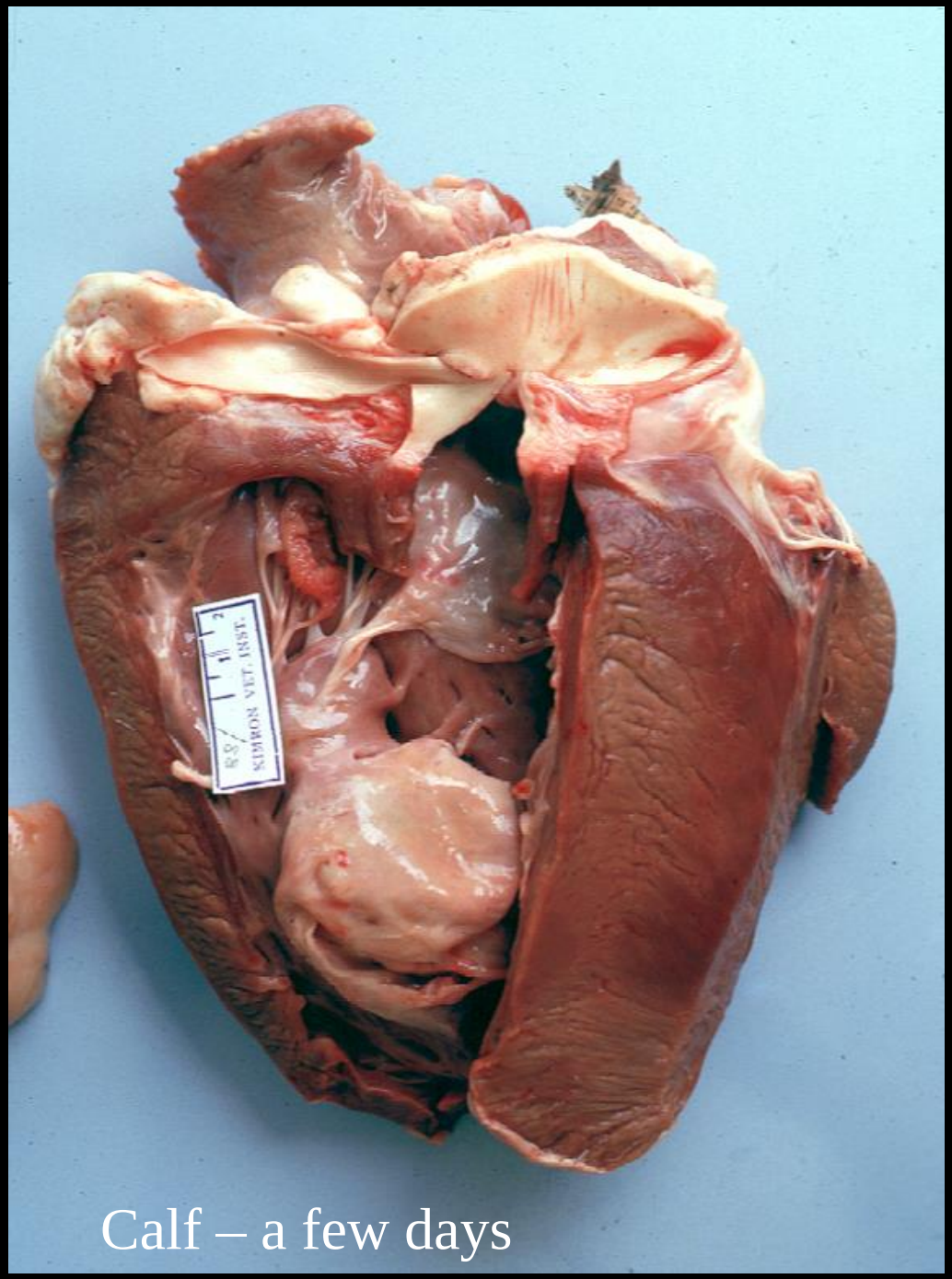

Calf – a few days

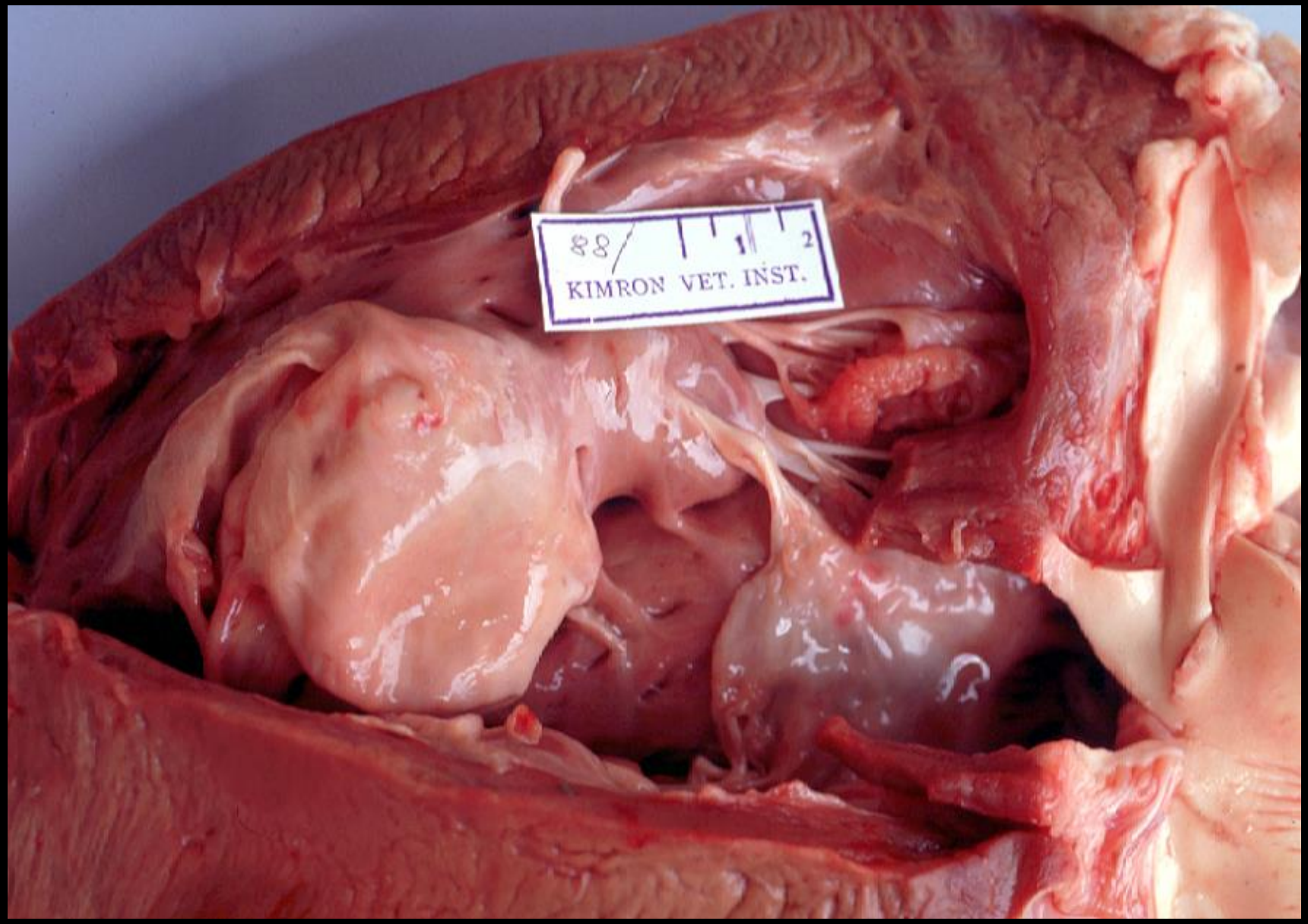
88
1
2
KIMRON VET. INST.

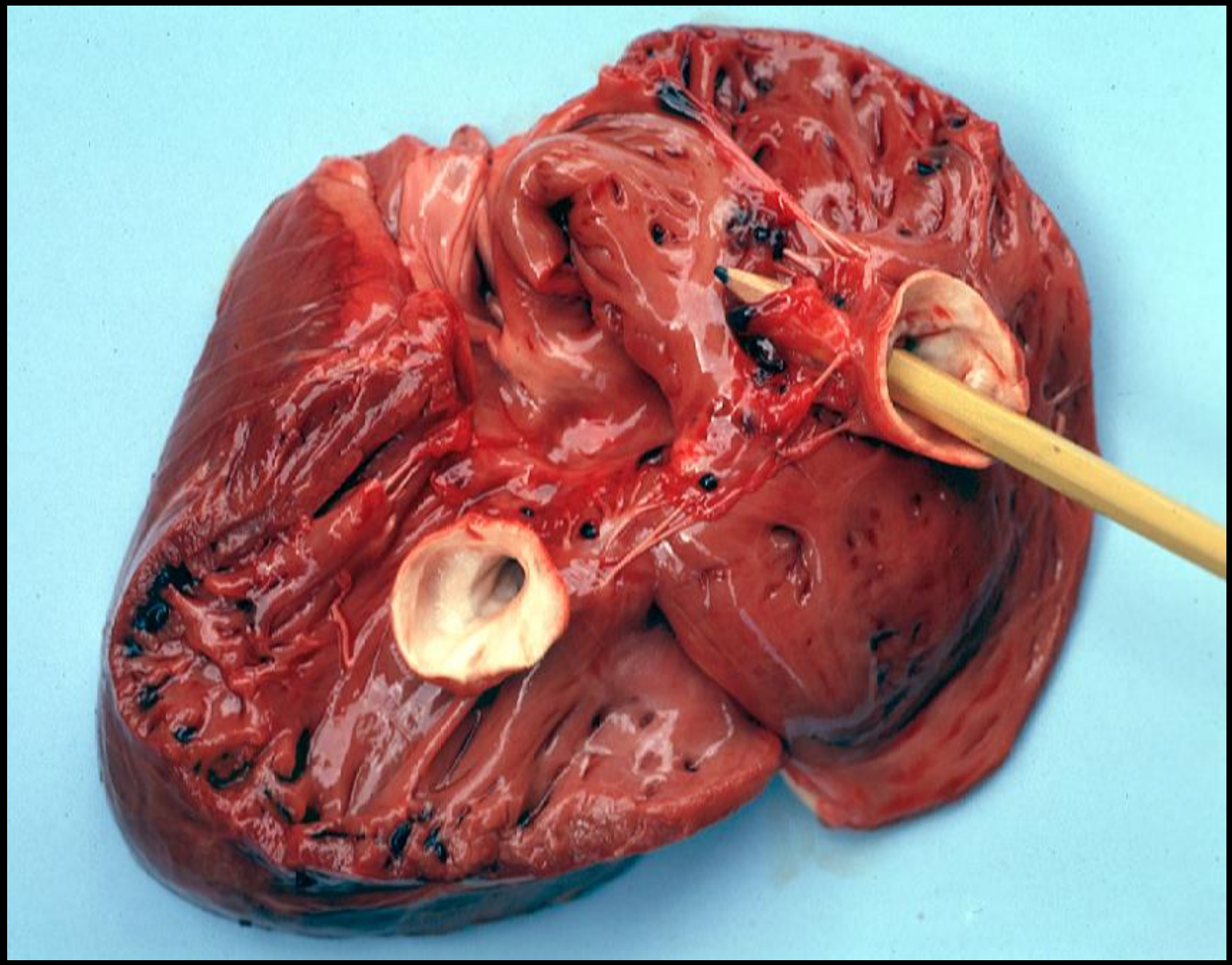

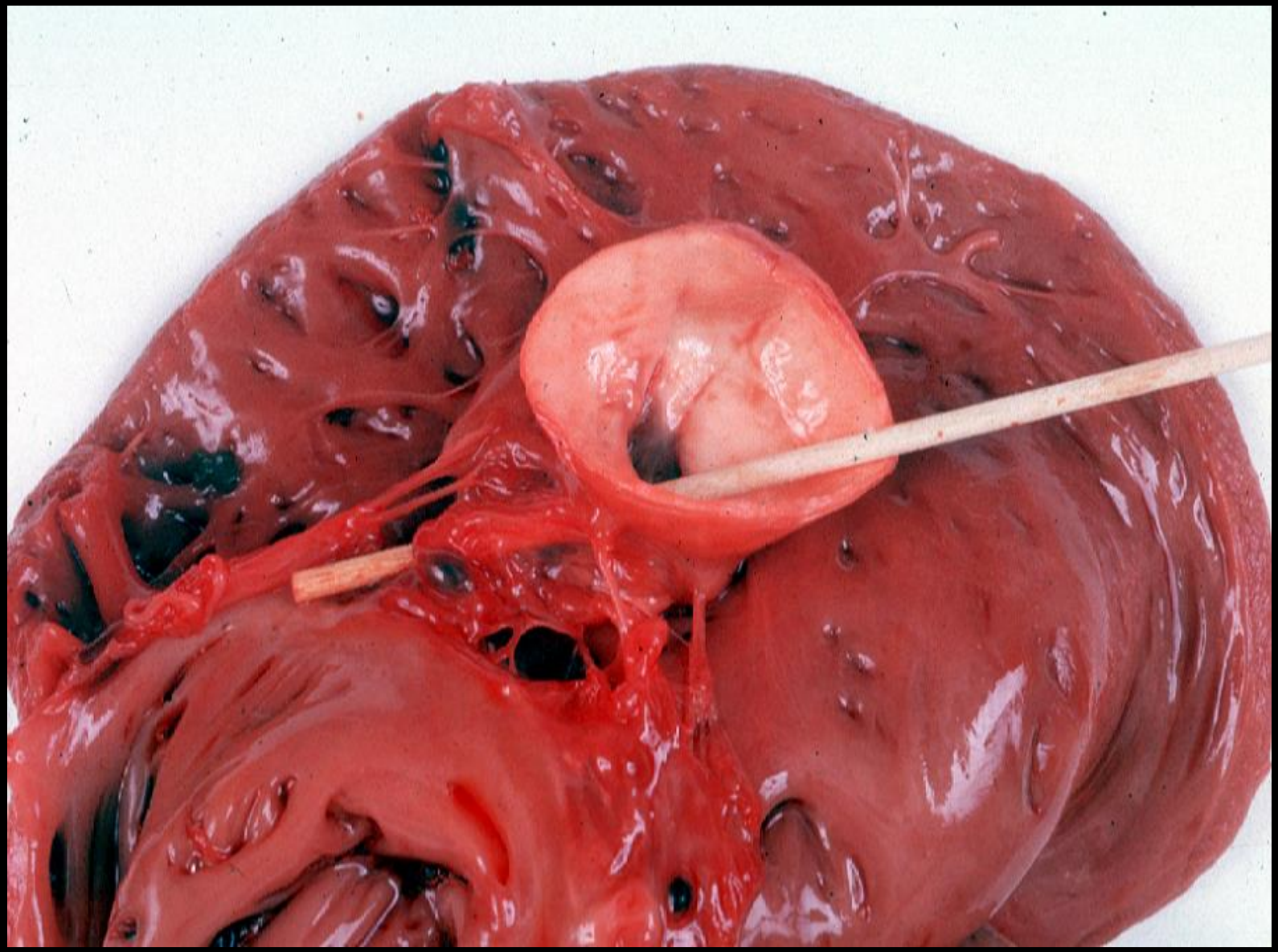

Incidence of congenital cardiac diseases

Incidence of congenital cardiac disease

- In cattle

  Atrial septal defect

  Ventricular septal defect

  Transposition of great vessels

  Congenital hamatomas

Incidence of congenital cardiac disease

- In dogs

  Patent ductus arteriosus

  Pulmonic stenosis

  Subaortic stenosis

  Persistent right aortic arch

  Pericardial anomalies

Incidence of congenital cardiac disease

- In cats

  Congenital mitral malformation

  Dysplasia of tricuspid valve

  Endocardial fibroelastosis

Incidence of congenital cardiac disease

- **In pigs**

  Subaortic stenosis

Incidence of congenital cardiac disease

- **In horses**

  Uncommon

כלב - 188919

- גורת בוקסר
- בעיית לב מולדת

Five mo. old

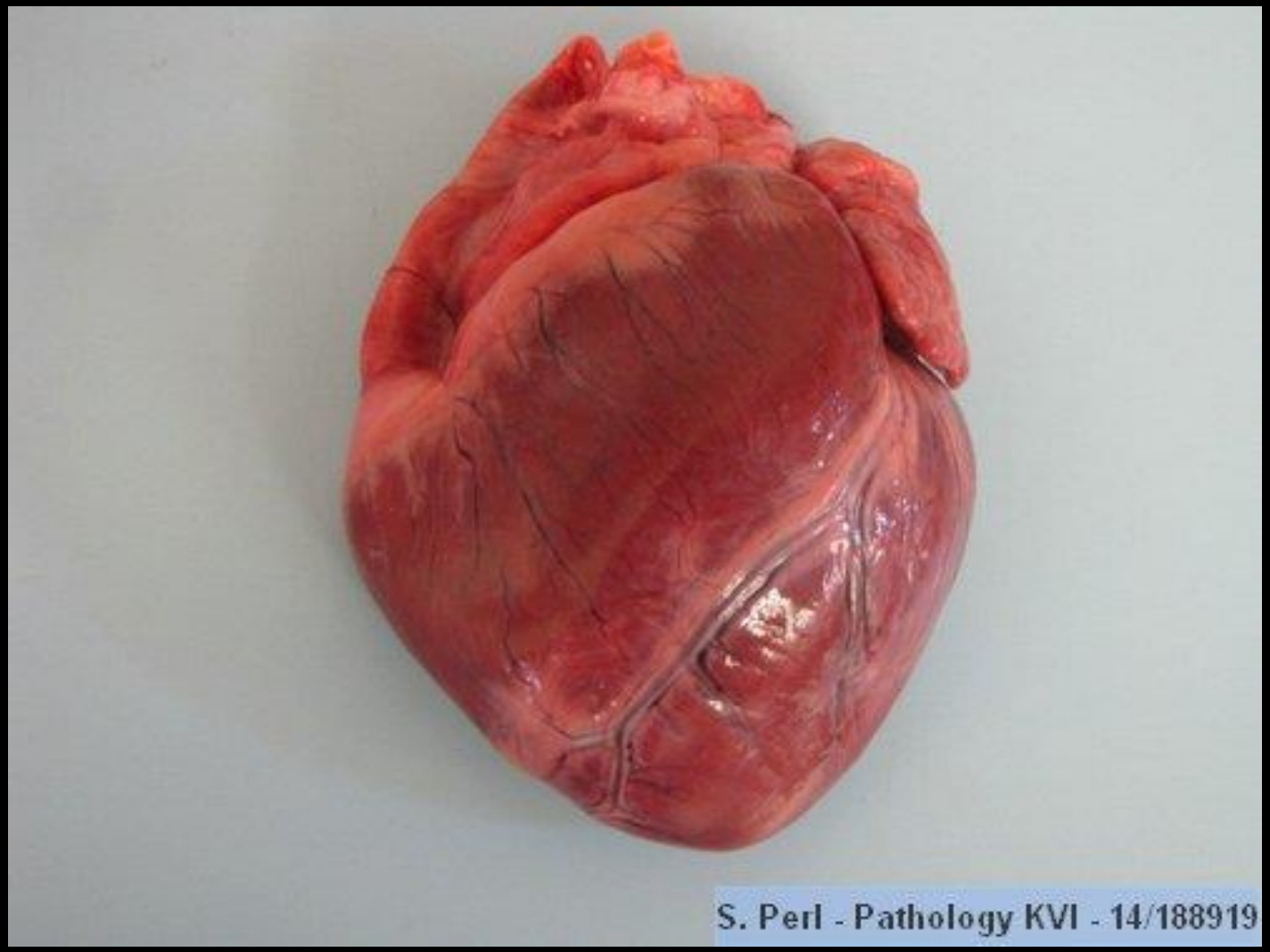
S. Perl - Pathology KVI - 14/188919

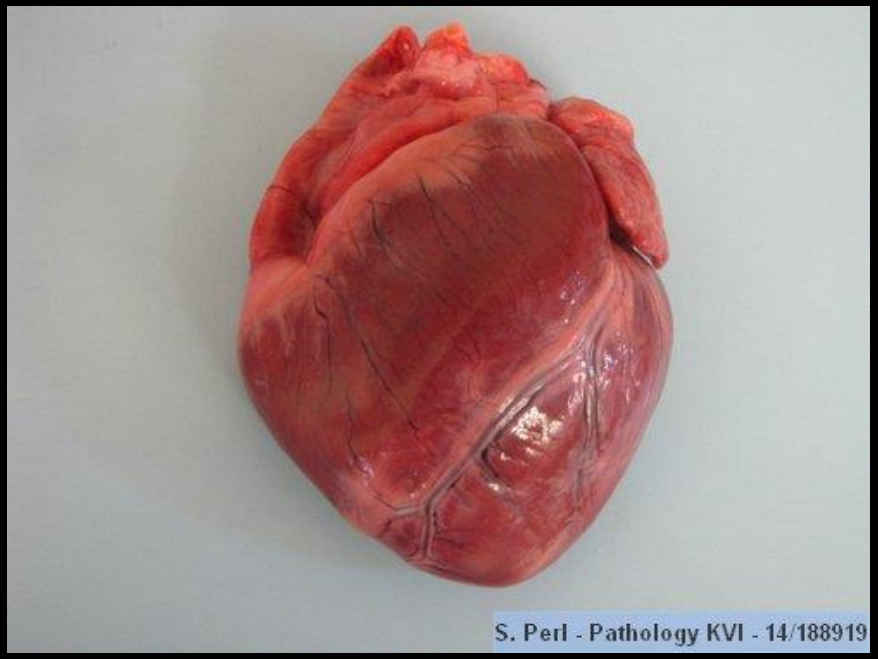

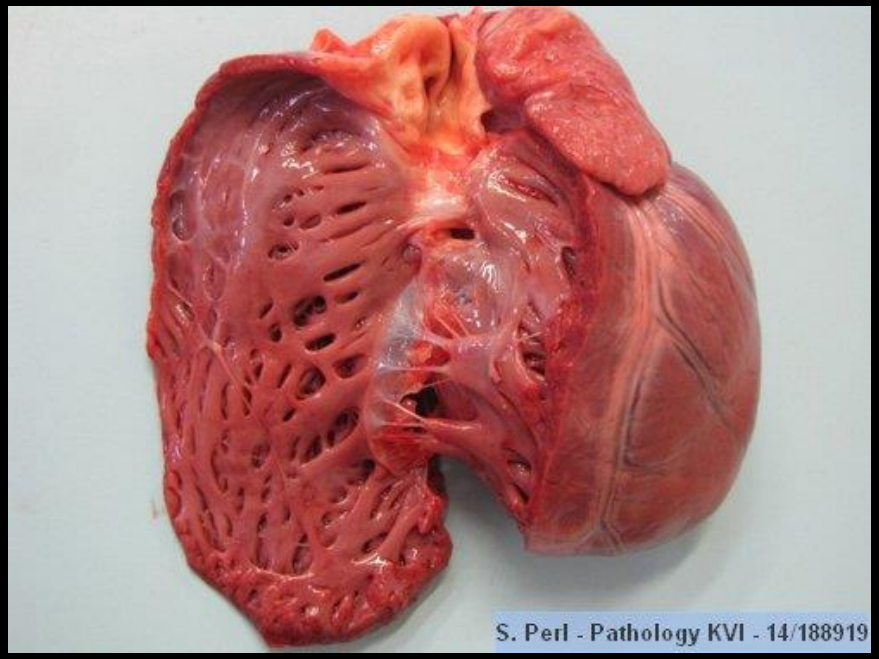

Right

Dysplasia of tricuspid valve
Pulmonic stenosis
VSD

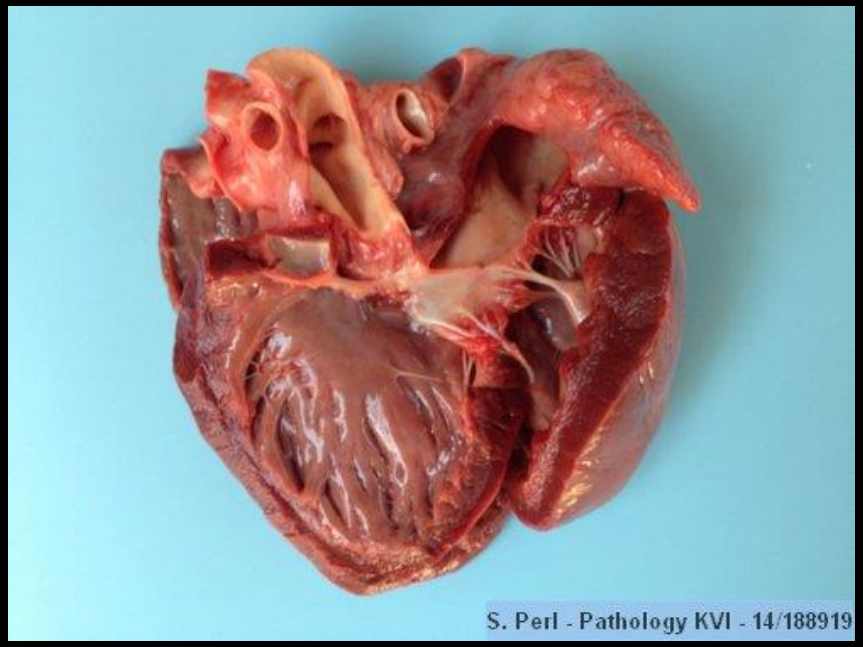

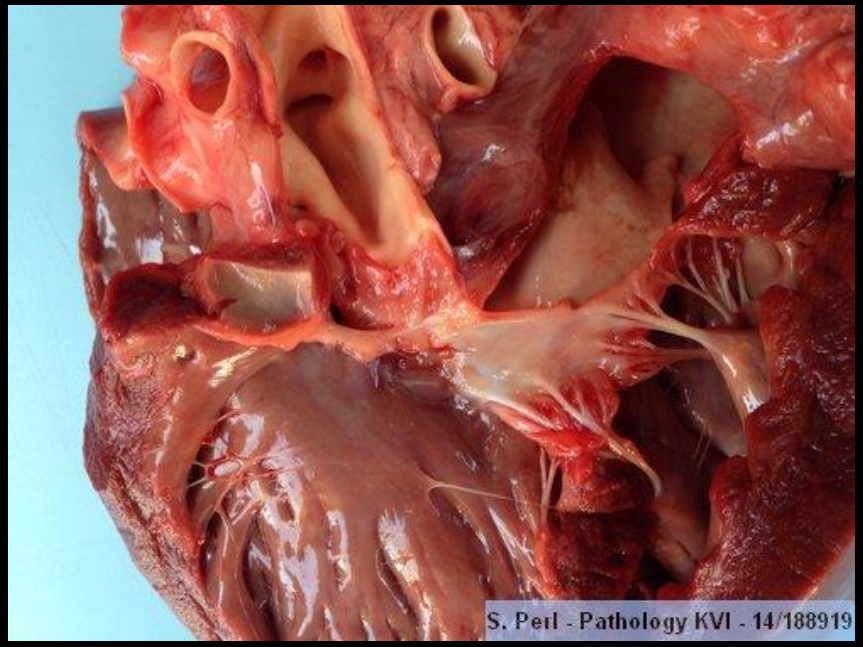

Left

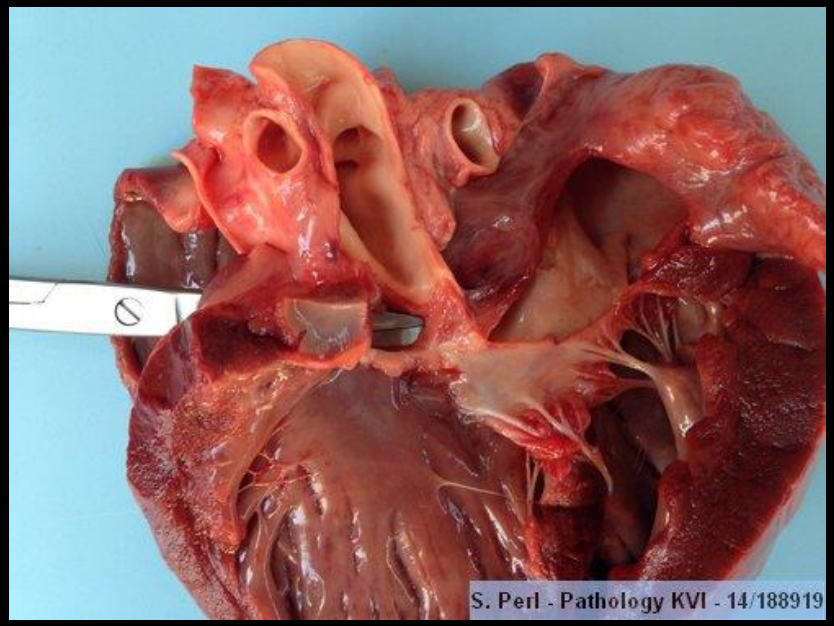

VSD
Aortic /subaortic stenosis