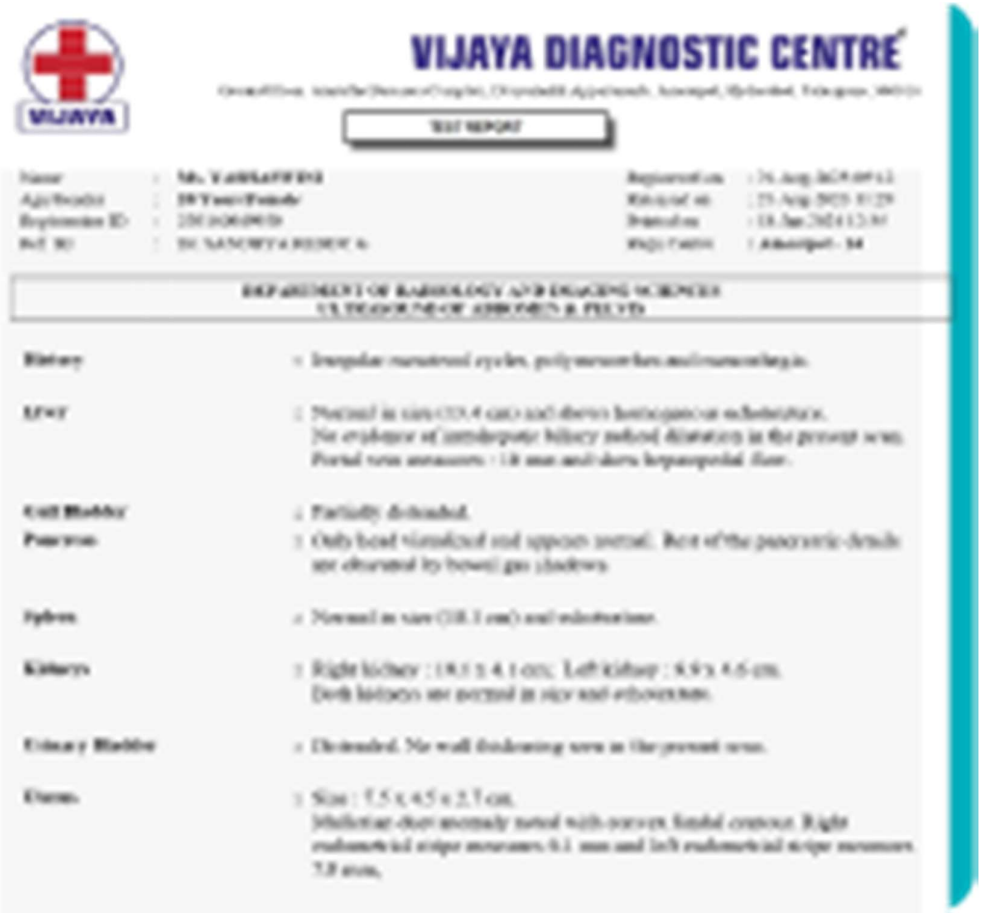

VIJAYA DIAGNOSTIC CENTRE

TEST REPORT

Name : Mr. VAMSAFFRIS
Age/Sex/Date : 39 Years/Female
Registration ID : [illegible]
Ref. By : Dr. SANDHYA REDDY K.
Registration : [illegible]
Reported on : [illegible]
Examined on : [illegible]
Registered at : Jubilee Hills - 34

DEPARTMENT OF RADIOLOGY AND IMAGING SCIENCES
ULTRASOUND OF ABDOMEN & PELVIS

Bladder : Irregular menstrual cycles, polymenorrhea and menorrhagia.

Liver : Normal in size (13.4 cm) and shows homogeneous echotexture. No evidence of intrahepatic biliary ductal dilatation in the present scan. Portal vein measures 1.0 mm and shows hepatopetal flow.

Gall Bladder : Partially distended.

Pancreas : Only head visualized and appears normal. Rest of the pancreatic details are obscured by bowel gas shadows.

Spleen : Normal in size (10.1 cm) and echotexture.

Kidneys : Right kidney : 10.5 x 4.1 cm; Left kidney : 9.9 x 4.5 cm. Both kidneys are normal in size and echotexture.

Urinary Bladder : Distended. No wall thickening seen in the present scan.

Uterus : Size : 7.5 x 4.5 x 2.7 cm. Midline uterus anteverted noted with normal fundal contour. Right endometrial stripe measures 0.1 mm and left endometrial stripe measures 7.0 mm.

A lots of info ……..