ASCO® Guidelines

COLLEGE of AMERICAN PATHOLOGISTS

Figure 1. Algorithm for evaluation of human epidermal growth factor receptor 2 (HER2) protein expression by immunohistochemistry (IHC) assay of the invasive component of a breast cancer specimen.

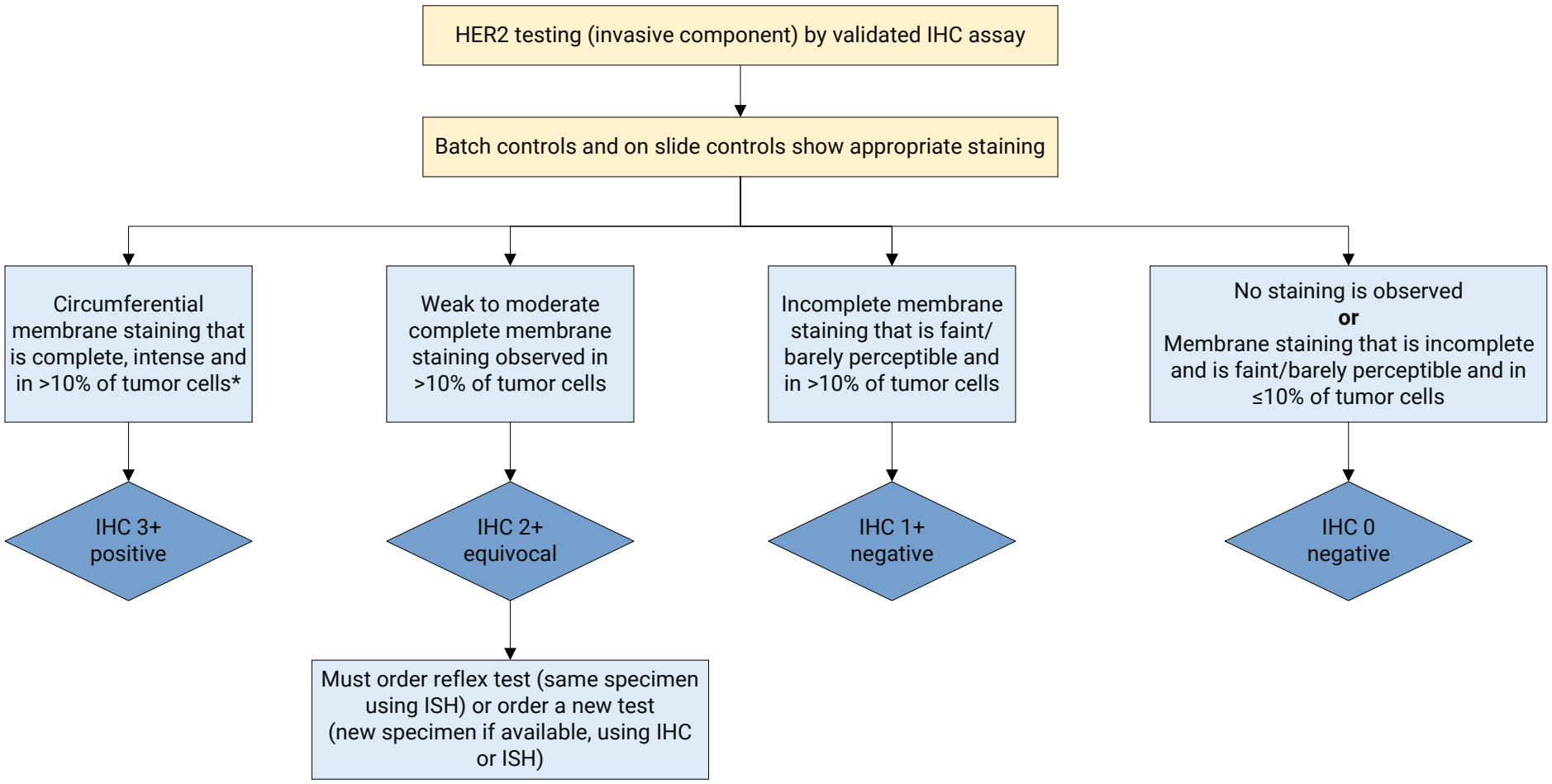

NOTE. The final reported results assume that there is no apparent histopathologic discordance observed by the pathologist. Unusual staining patterns of HER2 by IHC can be encountered that are not covered by these definitions. In practice, these patterns are rare and if encountered should be considered IHC 2+ equivocal. As one example, some specific subtypes of breast cancers can show IHC staining that is moderate to intense but incomplete (basolateral or lateral) and can be found to be HER2 amplified. Another example is circumferential membrane IHC staining that is intense but within ≤10% of tumor cells (heterogeneous but very limited in extent). Such cases can be considered 2+ equivocal but additional samples may reveal different percentages of HER2 positive staining.

It is best practice that pathology labs should include a footnote in their HER2 testing reports (IHC and ISH) with the following recommended comment:
"Patients with breast cancers that are HER2 IHC 3+ or IHC 2+/ISH amplified may be eligible for several therapies that disrupt HER2 signaling pathways. Invasive breast cancers that test 'HER2-negative' (IHC 0, 1+ or 2+/ISH not-amplified) are more specifically considered 'HER2-negative for protein overexpression/gene amplification' since non-overexpressed levels of the HER2 protein may be present in these cases. Patients with breast cancers that are HER2 IHC 1+ or IHC 2+ /ISH not-amplified may be eligible for a treatment that targets non-amplified/non-overexpressed levels of HER2 expression for cytotoxic drug delivery (IHC 0 results do not result in eligibility currently."

Importantly, the semiquantiative IHC score must always be reported as well to the ensure patients who meet eligibility for trastuzumab deruxtecan can be identified.
Example: HER2-negative for protein overexpression (1+ staining present).

(*)Readily appreciated using a low power objective and observed within a homogeneous and contiguous invasive cell population

This algorithm is derived from recommendations in *Human Epidermal Growth Factor Receptor 2 Testing in Breast Cancer: ASCO-CAP Guideline Update.* This is a tool based on an ASCO and CAP guideline and is not intended to substitute for the independent professional judgment of the treating physician. Practice guidelines do not account for individual variation among patients. This tool does not purport to suggest any particular course of medical treatment. Use of the guideline and this tool are voluntary.

Wolff AC, Somerfield MR, Dowsett M, et al. Human epidermal growth factor receptor 2 testing in breast cancer: ASCO-CAP guideline update [published online June 7, 2023]. *Arch Pathol Lab Med*. 2023. doi:10.5858/arpa.2023-0950-SA

©American Society of Clinical Oncology and College of American Pathologists 2023. All rights reserved. For licensing opportunities, contact licensing@asco.org

ASCO® Guidelines

COLLEGE of AMERICAN PATHOLOGISTS

Figure 2. Algorithm for evaluation of human epidermal growth factor receptor 2 (HER2) gene amplification by in situ hybridization (ISH) assay of the invasive component of a breast cancer specimen using a single-signal (HER2 gene) assay (single-probe ISH).

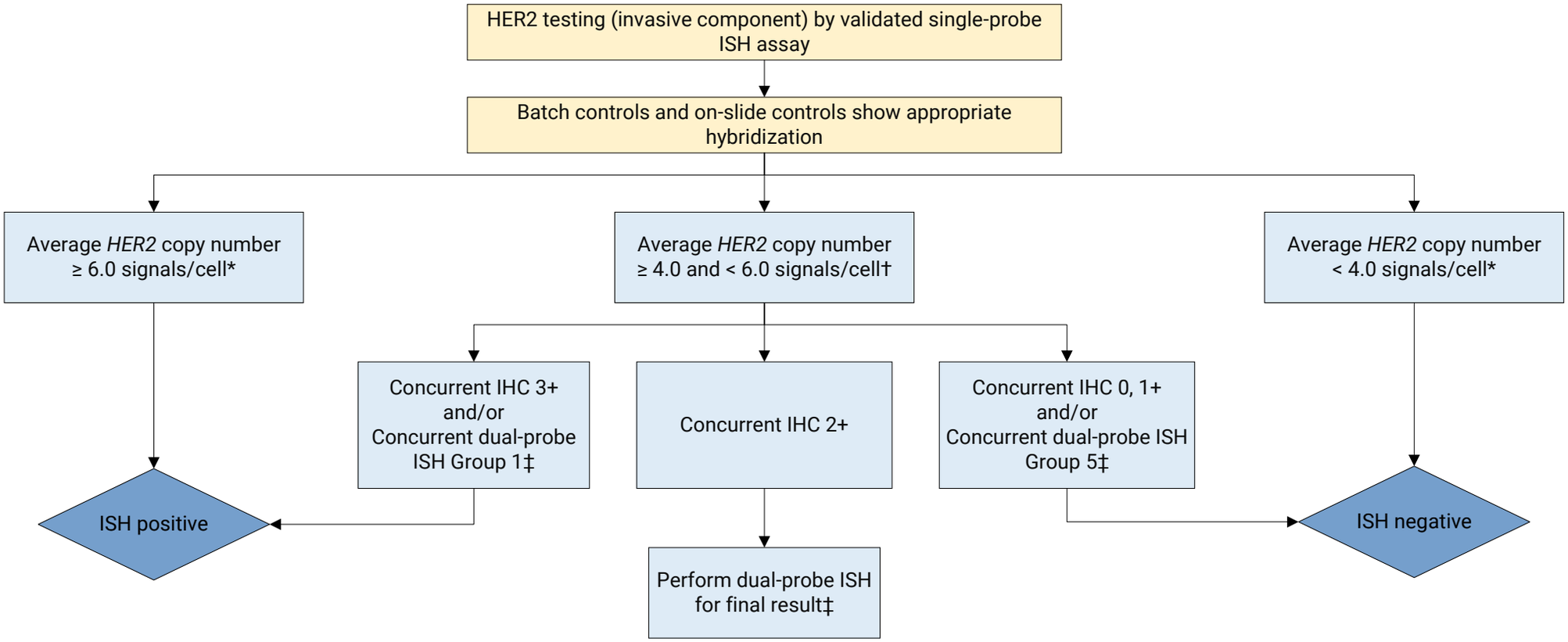

NOTE. The final reported results assume that there is no apparent histopathologic discordance observed by the pathologist
*It is recommended that concomitant IHC review should become part of the interpretation of single-probe ISH results. The Expert Panel also preferentially recommends the use of dual-probe instead of single-probe ISH assays.
†Using sections from the same tissue samples used for single-probe ISH, perform IHC (if not already done) and/or dual-probe ISH. If IHC results are 2+ equivocal, it is recommended to also perform dual probe ISH.
‡If initial assessment of dual-probe ISH suggestive of Groups 2, 3, or 4, follow the algorithm described in Figure 3.

This algorithm is derived from recommendations in *Human Epidermal Growth Factor Receptor 2 Testing in Breast Cancer: ASCO-CAP Guideline Update*. This is a tool based on an ASCO and CAP guideline and is not intended to substitute for the independent professional judgment of the treating physician. Practice guidelines do not account for individual variation among patients. This tool does not purport to suggest any particular course of medical treatment. Use of the guideline and this tool are voluntary.

Wolff AC, Somerfield MR, Dowsett M, et al. Human epidermal growth factor receptor 2 testing in breast cancer: ASCO-CAP guideline update [published online June 7, 2023]. *Arch Pathol Lab Med*. 2023. doi:10.5858/arpa.2023-0950-SA

©American Society of Clinical Oncology and College of American Pathologists 2023. All rights reserved. For licensing opportunities, contact licensing@asco.org

ASCO® Guidelines

COLLEGE of AMERICAN PATHOLOGISTS

Figure 3. Algorithm for evaluation of human epidermal growth factor receptor 2 (HER2) gene amplification by in situ hybridization (ISH) assay of the invasive component of a breast cancer specimen using a dual-signal (HER2 gene) assay (dual-probe ISH).

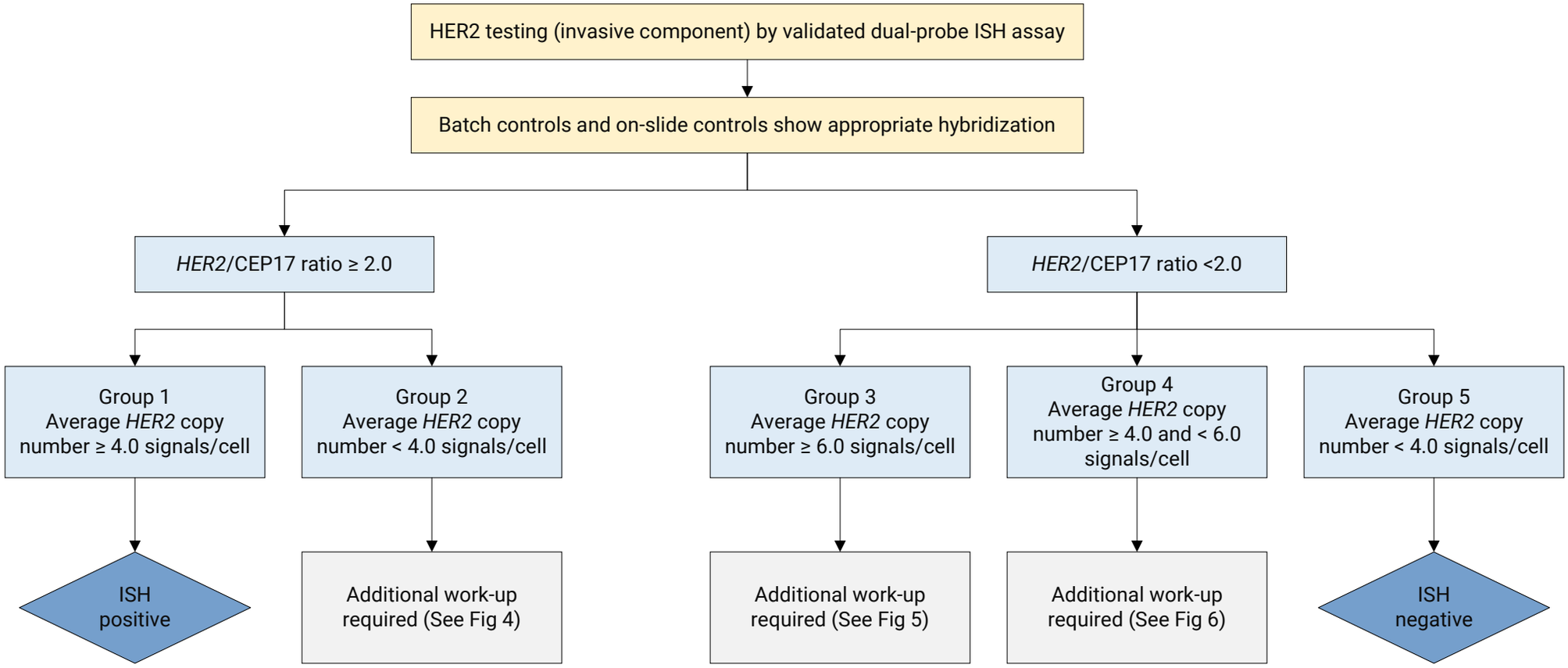

NOTE. The final reported results assume that there is no apparent histopathologic discordance observed by the pathologist. Regarding Groups 2, 3, and 4, If not already assessed by the institution/lab performing the ISH test, IHC testing for HER2 should be performed using sections from the same tissue sample used for ISH and the slides from both ISH and IHC be reviewed together to guide the selection of areas to score by ISH (local practice considerations will dictate the best procedure to accomplish this concomitant assessment).

This algorithm is derived from recommendations in *Human Epidermal Growth Factor Receptor 2 Testing in Breast Cancer: ASCO-CAP Guideline Update.* This is a tool based on an ASCO and CAP guideline and is not intended to substitute for the independent professional judgment of the treating physician. Practice guidelines do not account for individual variation among patients. This tool does not purport to suggest any particular course of medical treatment. Use of the guideline and this tool are voluntary.

Wolff AC, Somerfield MR, Dowsett M, et al. Human epidermal growth factor receptor 2 testing in breast cancer: ASCO-CAP guideline update [published online June 7, 2023]. *Arch Pathol Lab Med*. 2023. doi:10.5858/arpa.2023-0950-SA

©American Society of Clinical Oncology and College of American Pathologists 2023. All rights reserved. For licensing opportunities, contact licensing@asco.org

ASCO® Guidelines

COLLEGE of AMERICAN PATHOLOGISTS

Figure 4. Clinical Question 3 "Group 2"

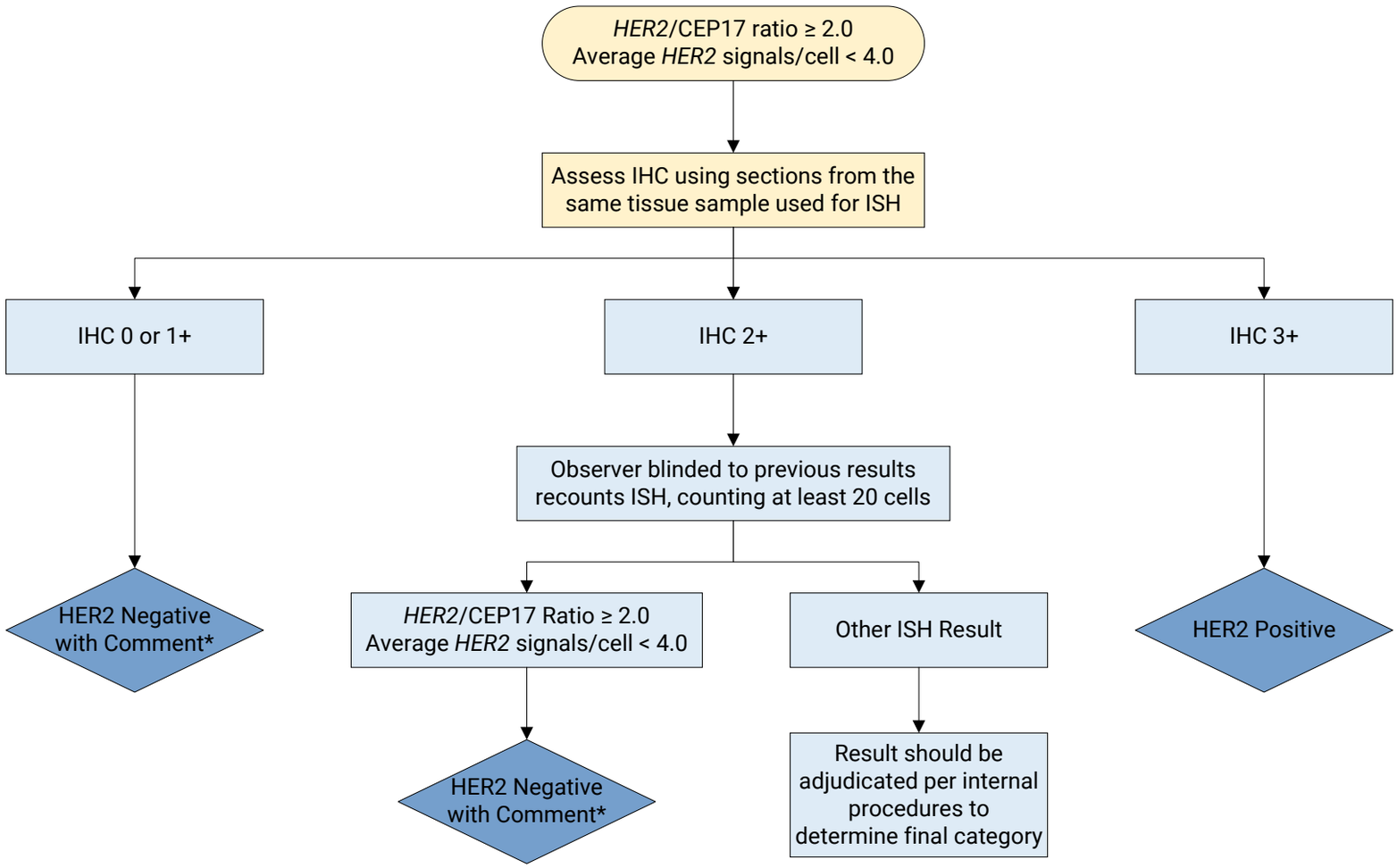

*Comment: Evidence is limited on the efficacy of HER2-targeted therapy in the small subset of cases with *HER2*/CEP17 ratio ≥2.0 and an average *HER2* copy number <4.0/cell. In the first generation of adjuvant trastuzumab trials, patients in this subgroup who were randomized to the trastuzumab arm did not appear to derive an improvement in disease free or overall survival, but there were too few such cases to draw definitive conclusions. IHC expression for HER2 should be used to complement ISH and define HER2 status. If IHC result is not 3+ positive, it is recommended that the specimen be considered HER2 negative because of the low *HER2* copy number by ISH and lack of protein overexpression.

This algorithm is derived from recommendations in *Human Epidermal Growth Factor Receptor 2 Testing in Breast Cancer: ASCO-CAP Guideline Update*. This is a tool based on an ASCO and CAP guideline and is not intended to substitute for the independent professional judgment of the treating physician. Practice guidelines do not account for individual variation among patients. This tool does not purport to suggest any particular course of medical treatment. Use of the guideline and this tool are voluntary.

Wolff AC, Somerfield MR, Dowsett M, et al. Human epidermal growth factor receptor 2 testing in breast cancer: ASCO-CAP guideline update [published online June 7, 2023]. *Arch Pathol Lab Med*. 2023. doi:10.5858/arpa.2023-0950-SA

©American Society of Clinical Oncology and College of American Pathologists 2023. All rights reserved. For licensing opportunities, contact licensing@asco.org

ASCO® Guidelines

COLLEGE of AMERICAN PATHOLOGISTS

Figure 5. Clinical Question 4 "Group 3"

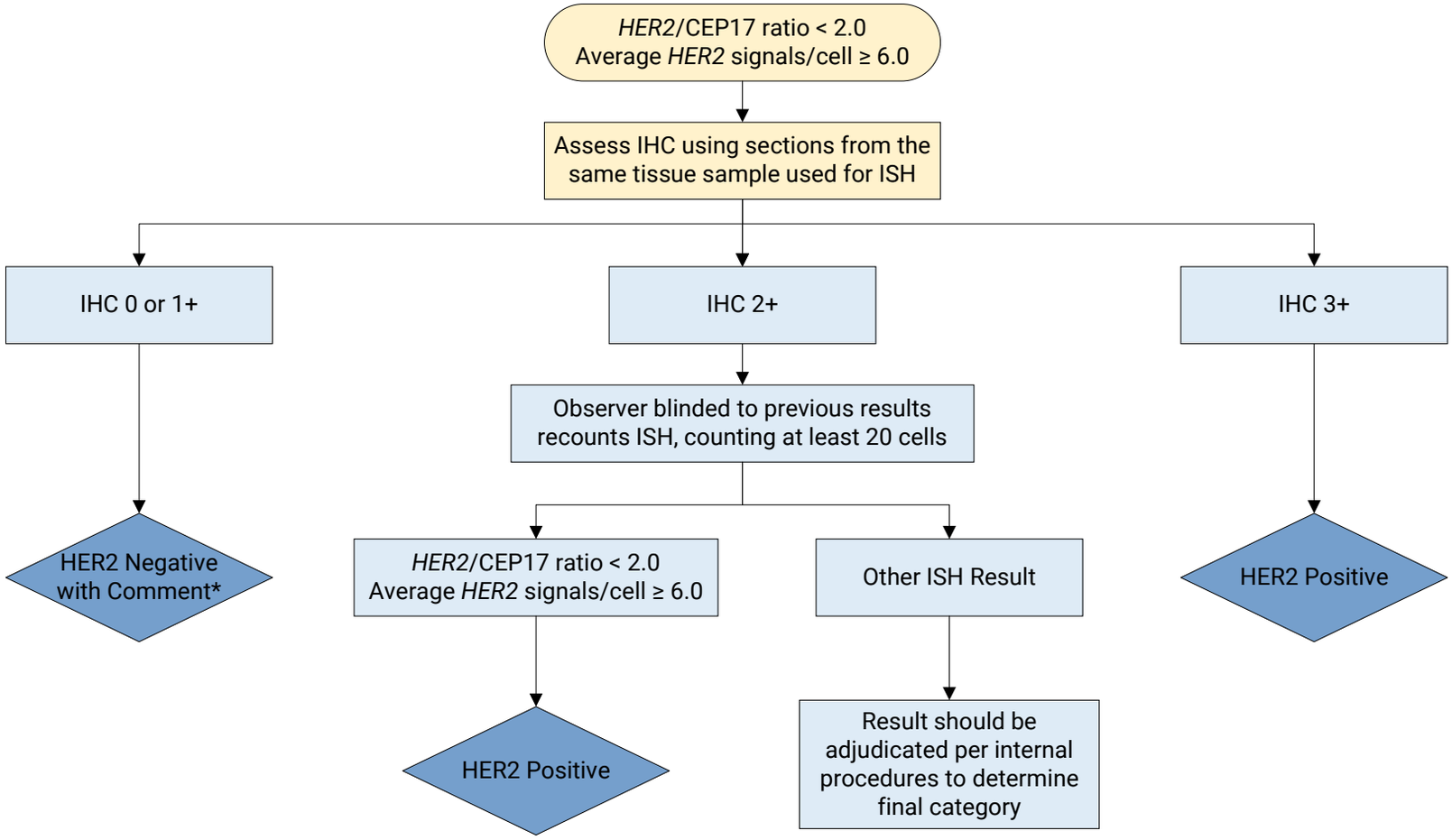

*Comment: There are insufficient data on the efficacy of HER2-targeted therapy in cases with HER2 ratio <2.0 in the absence of protein over-expression because such patients were not eligible for the first generation of adjuvant trastuzumab clinical trials. When concurrent IHC results are negative (0-1+), it is recommended that the specimen be considered HER2 negative.

This algorithm is derived from recommendations in *Human Epidermal Growth Factor Receptor 2 Testing in Breast Cancer: ASCO-CAP Guideline Update*. This is a tool based on an ASCO and CAP guideline and is not intended to substitute for the independent professional judgment of the treating physician. Practice guidelines do not account for individual variation among patients. This tool does not purport to suggest any particular course of medical treatment. Use of the guideline and this tool are voluntary.

Wolff AC, Somerfield MR, Dowsett M, et al. Human epidermal growth factor receptor 2 testing in breast cancer: ASCO-CAP guideline update [published online June 7, 2023]. *Arch Pathol Lab Med*. 2023. doi:10.5858/arpa.2023-0950-SA

©American Society of Clinical Oncology and College of American Pathologists 2023. All rights reserved. For licensing opportunities, contact licensing@asco.org

ASCO® Guidelines

COLLEGE of AMERICAN PATHOLOGISTS

Figure 6. Clinical Question 5 "Group 4"

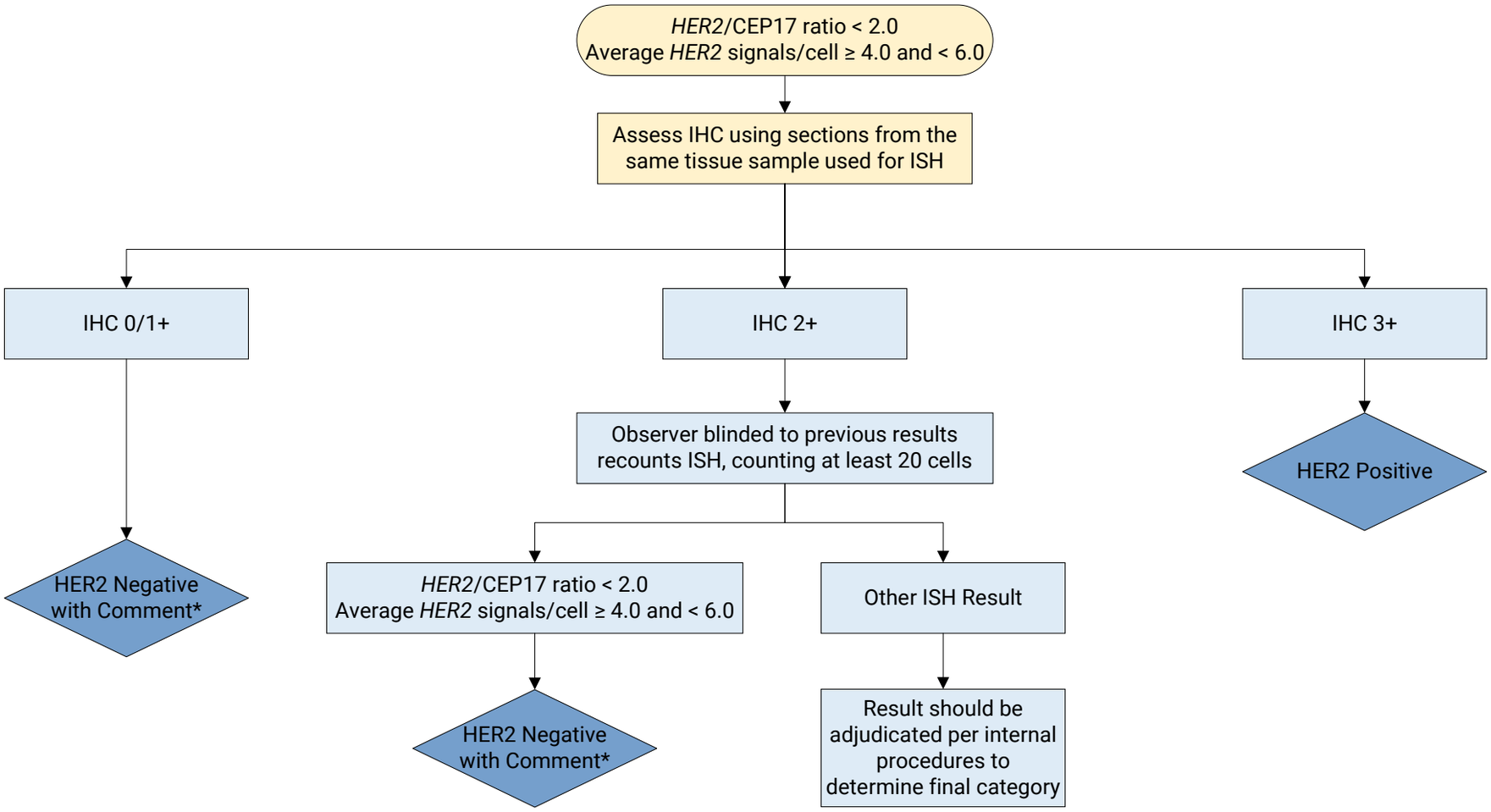

*Comment: It is uncertain whether patients with ≥4.0 and <6.0 average *HER2* signals/cell and *HER2*/CEP17 ratio <2.0 benefit from HER2 targeted therapy in the absence of protein overexpression (IHC 3+). If the specimen test result is close to the ISH ratio threshold for positive, there is a higher likelihood that repeat testing will result in different results by chance alone. Therefore, when IHC results are not 3+ positive, it is recommended that the sample be considered HER2 negative without additional testing on the same specimen.

This algorithm is derived from recommendations in *Human Epidermal Growth Factor Receptor 2 Testing in Breast Cancer: ASCO-CAP Guideline Update.* This is a tool based on an ASCO and CAP guideline and is not intended to substitute for the independent professional judgment of the treating physician. Practice guidelines do not account for individual variation among patients. This tool does not purport to suggest any particular course of medical treatment. Use of the guideline and this tool are voluntary.

Wolff AC, Somerfield MR, Dowsett M, et al. Human epidermal growth factor receptor 2 testing in breast cancer: ASCO-CAP guideline update [published online June 7, 2023]. *Arch Pathol Lab Med*. 2023. doi:10.5858/arpa.2023-0950-SA

©American Society of Clinical Oncology and College of American Pathologists 2023. All rights reserved. For licensing opportunities, contact licensing@asco.org