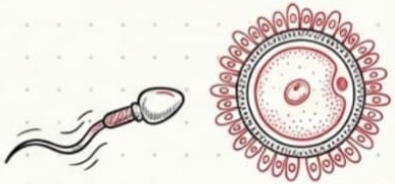

Human Reproduction

A Complete Masterclass Study Guide

Expert Note: This guide tracks the complete chronological journey of reproduction—from anatomical architecture to the miracle of birth.

Seminiferous Tubule Architecture

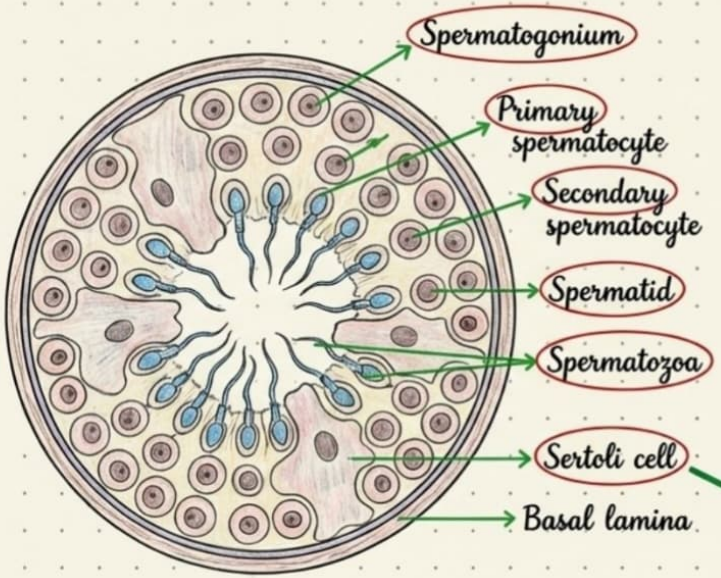

Note: Sertoli cells also form blood-testis barrier!

Seminiferous Tubule

Spermatogonia Cells

Sperms are produced. Meiotic div. occur leading to sperm form.

↳ Meiosis

Sertoli Cells

Provide {nourish} to germ cells

Interstitial Spaces

Has blood vessels & Leydig cells / interstitial cells

↓

Secrete androgens

Male Accessory Ducts & Glands

Seminiferous tubules
↓
Rete testis
↓
Vasa efferentia
↓
Epididymis
↓
Vas deferens { Ascends to abdomen, loops over urinary bladder
↓ receives duct from seminal vesicle
↓ becomes ejaculatory duct
↓ extends through penis
↓ urethral meatus

Urethra originates from urinary bladder → urethral meatus

Accessory Glands:
Seminal vesicles,
Prostate gland,
Bulbourethral gland

Seminal plasma produces.

Rich in fructose, Ca, enzymes.

The Female Reproductive System: Ovaries & Ducts

Note: Fimbriae help in collection of ovum after ovulation!

Ovaries

- Produce ovum & ovarian steroidal hormones.
- Dimensions: 2-4 cm long (connected to uterus & pelvic wall by ligaments).
- Structure: A thin epithelium covers the whole ovarian stroma (connective tissue inside ovary).
  - Peripheral cortex
  - Inner medulla

Female Accessory Ducts

Consists of: Oviduct, Uterus, Vagina.

Oviduct Details:

- 10-12 cm long.
- The part closer to the ovary is called the infundibulum.
- It has finger-like projections called fimbriae.

Infundibulum → Ampulla → Isthmus → Uterus

Mammary Glands: The Milk Pathway

1. Glandular tissue of each breast is divided into 15-20 clusters of mammary lobes → alveoli.
2. Alveoli secretes milk which stores into lumen (alveolar cavity).
3. They open into mammary tubules.
4. They join to form mammary duct.
5. They join to form wider mammary ampulla.
6. Connected to lactiferous duct → Milk comes out.

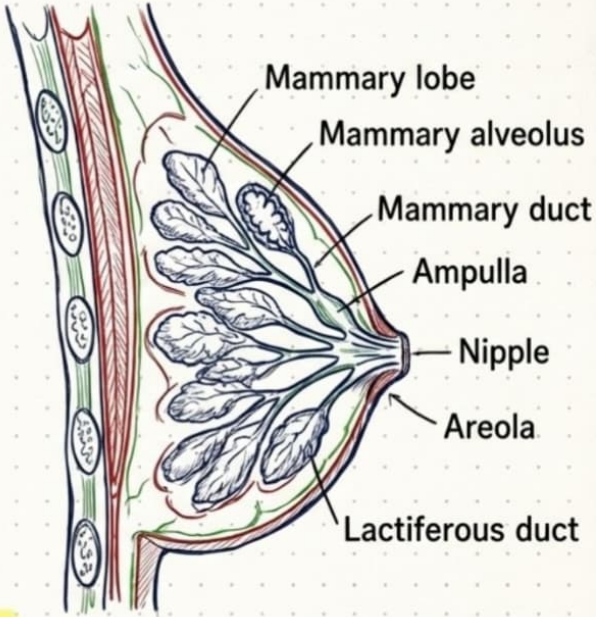

Uterus Layers & External Genitalia

Uterus

- **Perimetrium**: External thin membrane.
- **Myometrium**: Middle thick layer of smooth muscles. (Undergoes strong contractions during delivery)
- **Endometrium**: Inner glandular layer. (Undergoes cyclic changes during menstrual cycle)

Note: Endometrium thickness changes throughout cycle!

Female External Genitalia

- **Mons pubis**: It is a cushion of fatty tissue covered by skin & pubic hair.
- **Labia majora**: Fleshy folds of tissue surround vaginal opening.
- **Labia minora**: Paired folds of tissue under labia majora.
- **Hymen**: Membrane-like projection which lies at vaginal opening.
- **Clitoris**: Tiny finger-like structure lies at upper junction of two labia minora above urethral opening. Highly sensitive organ!

Gametogenesis: Spermatogenesis

Primary Spermatocytes (2n)
(Spermatogonia)

↓ Meiosis I

Secondary Spermatocyte (n)

↓ Meiosis II

Spermatids (n)

↓ Differentiation / Spermiogenesis

Spermatozoa (Sperms)

Sperm heads embed in the Sertoli cells & are then released through seminiferous tubules by spermiation.

Expert Clarification: '2n' means diploid (46 chromosomes). The meiotic divisions halve this to 'n' (haploid, 23 chromosomes) so the sperm can fuse with the ovum.

Hormonal Control of Spermatogenesis

Spermatogenesis starts at puberty

↓

GnRH inc

↓ Stimulates anterior pituitary

LH & FSH inc

↙ ↘

LH acts at Leydig cells

↓

androgens release

↓

Stimulates spermatogenesis

FSH acts at Sertoli cells

↓

factors secrete

↓

Helps in spermiogenesis

Architecture of a Sperm

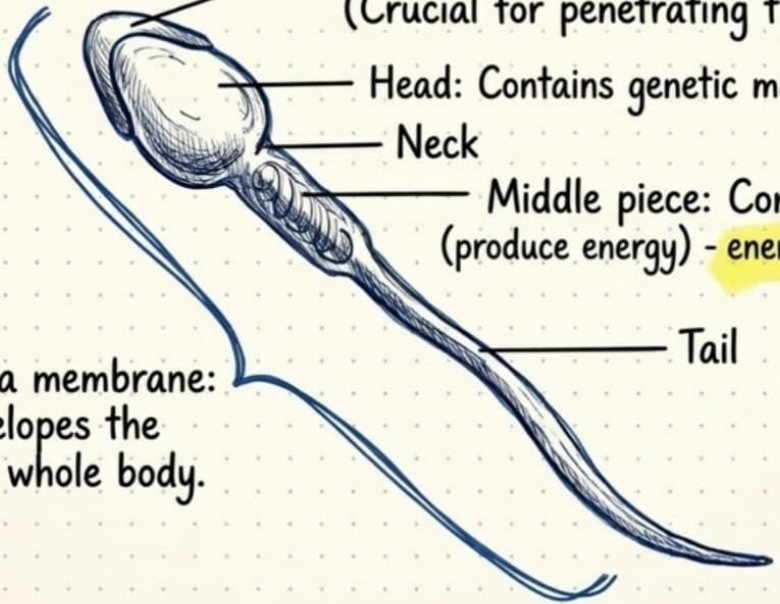

Oogenesis Cascade: Early Stages

Embryonic Stage

Oogenesis starts at embryonic development stage.

Oogonia (gamete mother cells)

Division occurs & gets temporarily arrested at prophase-I.

Primary oocytes

Gets surrounded by a layer of granulosa cells to become the Primary follicle.

Key Difference from Spermatogenesis!

A large number of these follicles degenerate.

Only 60,000–80,000 primary follicles are left in each ovary at puberty.

The Menstrual Cycle Phases

Menstrual Phase	Menstrual flow occurs and lasts for 3-5 days. Endometrial lining breaks which forms liquid through vagina.
Follicular Phase	Ovary grows → to become Graafian follicle & endometrium regenerates through proliferation (occurs at 14th day). Hormone Spike: LH & FSH along with estrogen increase rapidly which leads to follicular development & later rupture of graafian follicle to release ovum.
Luteal Phase	Remaining part of graafian follicle → converts to corpus luteum. It secretes progesterone which is essential for maintaining the endometrium.

Oogenesis Cascade: Follicular Maturation

Secondary Follicles: Primary follicles get surrounded by more layers of granulosa cells & a new theca.

Tertiary Follicles: Transforms from secondary, characterized by a fluid-filled cavity called the antrum. The theca layer is organised into an inner theca interna and outer theca externa.

Crucial Division: Primary oocyte within tertiary follicle grows in size & completes 1st meiotic division → unequal division resulting in formation of a large haploid secondary oocyte and a tiny first polar body.

Graafian Follicle (mature): Transforms from tertiary. The secondary oocyte forms a new membrane called zona pellucida around it.

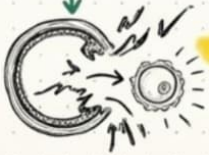

Ovulation: Graafian follicle ruptures to release secondary oocyte (ovum) from ovary.

Recall: Only ~60,000 primary follicles at puberty. This maturation process is continuous after puberty.

Fertilisation & The Block to Polyspermy

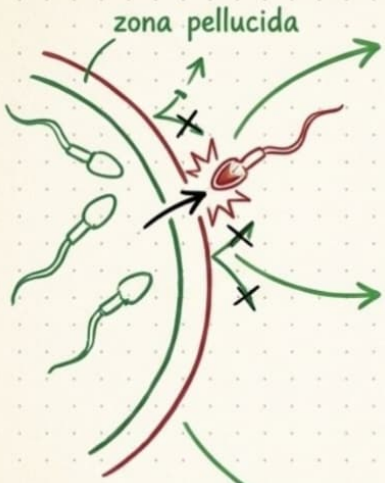

① Contact & Block

Sperm comes in contact with the zona pellucida, induces changes that block the entry of multiple sperms (polyspermy).

Expert Clarification: The block to polyspermy is crucial; ensures diploidy!

② Enzymatic Breach

Acrosome secretes certain enzymes which help sperm enter into the cytoplasm of the ovum through the zona pellucida & the plasma membrane.

③ Completion

Then the Secondary oocyte completes its development thereby forming a second polar body (ootid) & the ovum.

The Placenta: The Life Support Matrix

- Facilitates transport of O_2 & water.
- Removal of waste produced & CO_2 from uterus.
- Connected to embryo through umbilical cord which helps in transport of substances.

Chorionic villi + uterine tissue
↓
→ forms Placenta
(Present between foetus & maternal body).

Produces hormones:

- human chorionic gonadotropin (hCG)
- human placental lactogen (hPL)
- estrogens
- progestogens

Expert Clarification:
The presence of hCG is what over-the-counter pregnancy tests detect to confirm implantation!

Cleavage & Implantation Journey

Expert Clarification: The entire journey from fertilization to implantation takes about 7-10 days!

Zygote moves into uterus through cleavage (isthmus of oviduct).

↓

Cleavage creates blastomeres (2-16 daughter cells after mitosis).

↓

8-16 cells stage forms the morula.

↓

Morula becomes the Blastocyst.

Blastocyst Implantation Breakdown

1. Outer layer (trophoblast): Gets attached to endometrium.
2. Inner layer (inner cell mass): Differentiates to embryo.

Result: Uterine cells divide rapidly & blastocyst gets embedded. This is called implantation.

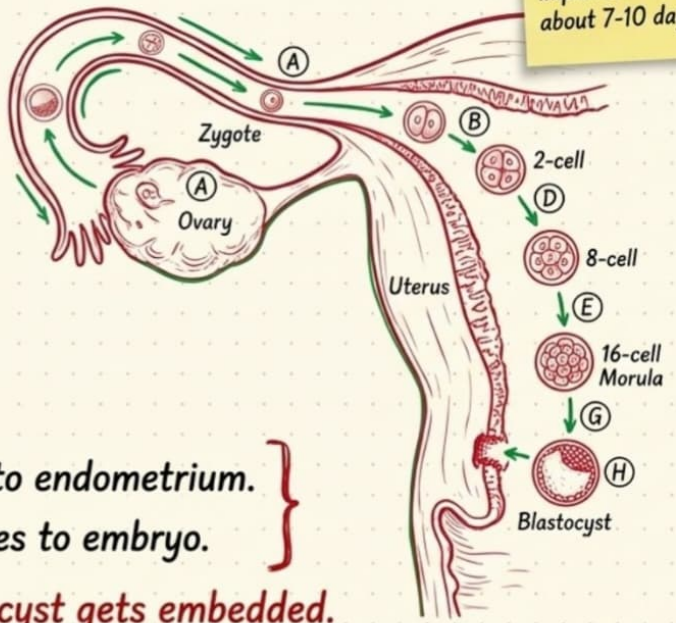

Figure 2.11

Embryonic Differentiation

Inner cell mass gets differentiated into 3 layers:

- Ectoderm
- Endoderm
- Mesoderm

differentiated

Priming

Give rise to tissues.

Tissues.

It also has stem cells capable of giving rise to tissues & organs.

Parturition: The Foetal Ejection Reflex

Left Side (The Origin)

Signals for parturition originate from foetus & placenta.

↳ Thus called as a neuro-endocrine mechanism.

Triggers oxytocin release from pituitary.

Acts on uterine muscles causing strong contraction.

Leads to further release of oxytocin.

More contraction occurs.

Expulsion of foetus occurs.

Expert Clarification: This cycle continues until the baby is expelled, a key example of positive feedback!

Foetus Growth Timeline

1 month:
Heart develops.

2 months:
Limbs & digits develop.

3 months (1st trimester):
Major organ system forms, limbs, external genitalia.

5 months:
Hair & movement of foetus.

6 months (2nd trimester):
Eyelids separate, eye lashes are formed, thin hair appear.

9 months:
Full development.

Expert Clarification:
Foetal movements are also called 'quickening' and are often felt by the mother around this time!