Value of Magnetic Resonance Imaging in Assessing Efficacy in Clinical Trials of Multiple Sclerosis Therapies

BRADLEY J. ERICKSON, M.D., PH.D., AND JOHN H. NOSEWORTHY, M.D.

Magnetic resonance imaging (MRI) has become an important technique for monitoring the effectiveness of putative treatments for multiple sclerosis (MS) because of its high sensitivity, objectivity, and noninvasive nature. Its importance as a surrogate measure of disease, however, is an issue that is more difficult to validate than might seem to be the case. In this review, we describe the role of MRI in the assessment of putative therapies for MS. New magnetic resonance techniques and methods of image analyses aimed at better demonstrating the nature and extent of disease are discussed, and the role of MRI in published MS therapeutic trials is examined. MRI is a frequently used secondary outcome measure for putative treatment strategies for MS. Although it is sensitive to changes in the inflammatory component of the MS disease process, poor correlation has been noted between MRI findings and long-term patient outcome. There is a widespread expectation that new magnetic resonance techniques—such as fluid-attenuated inversion recovery, magnetization transfer imaging, and magnetic resonance spectroscopy—will ultimately be useful for characterization of pathologic changes within the MS lesion and more generally of the MS disease process. Whether magnetic resonance changes seen in experimental therapies predict the long-term clinical course of the disease remains to be determined.

(Mayo Clin Proc 1997;72:1080-1089)

BBB = blood-brain barrier; Cr = creatine; CSF = cerebrospinal fluid; EDSS = Expanded Disability Status Scale; FLAIR = fluid-attenuated inversion recovery; MRI = magnetic resonance imaging; MRS = magnetic resonance spectroscopy; MS = multiple sclerosis; MTI = magnetization transfer imaging; NAA = *N*-acetylaspartate; NAWM = normal-appearing white matter; PD = proton density; PDWI = PD-weighted images; T1WI = T1-weighted images; T2WI = T2-weighted images

As outlined in this symposium, multiple sclerosis (MS) is an important inflammatory demyelinating central nervous system disease of unknown cause that frequently results in appreciable impairment. Although corticosteroids may hasten clinical recovery during acute attacks, currently only limited evidence indicates that any therapy can reduce progression of disability. Part of the difficulty in determining the effectiveness of a therapy in MS is the variability in disease course and the lack of a reproducible,[1] bias-resistant,[2] clinical measurement. Magnetic resonance imaging (MRI) is a sensitive, objective measure of MS plaques. The exact relationship between plaques and disability, however, is unclear, and the cost of MRI examination is considerable—particularly if large populations must be imaged frequently. Furthermore, approximately 5% of patients will not undergo scanning because of claustrophobia. In this review, we will examine some of the MS disease processes that can be monitored with use of standard MRI techniques, how these have been used in recent therapeutic trials, and new techniques that may be of greater value in assessing the effectiveness of a therapy.

From the Department of Diagnostic Radiology (B.J.E.) and Department of Neurology (J.H.N.), Mayo Clinic Rochester, Rochester, Minnesota.

Individual reprints of this article are not available. The entire Symposium on Multiple Sclerosis will be available for purchase as a bound booklet from the *Proceedings* Editorial Office at a later date.

PHYSIOLOGIC BASIS OF MRI

Conventional MRI pulse sequences can be divided into those that emphasize one of three physical characteristics: T1 relaxation time, T2 relaxation time, and proton density (PD). Examples of substances that are bright on T1-weighted images (T1WI) include fat, methemoglobin, gadolinium-based contrast agents, and melanin. T2-weighted images (T2WI) have high signal in areas where the T2 time is long. Examples of structures that are bright on T2WI are cerebrospinal fluid (CSF) and edema. PD-weighted images (PDWI) are primarily based on the number of protons that are able to produce a signal. Typically, both the PDWI and the T2WI are acquired at the same time as a "dual-echo" sequence. A discussion of the physical basis of MRI pulse sequences is beyond the scope of this article.

One of the early events that can occur during the formation of an MS plaque is the breakdown of the blood-brain

 © *1997 Mayo Foundation for Medical Education and Research*

For personal use. Mass reproduce only with permission from Mayo Clinic Proceedings.

barrier (BBB) due to inflammatory changes.[3-5] Intravenously administered contrast agents (such as gadolinium chelates) are normally excluded from the brain by the BBB but traverse into the extracellular compartment at sites of BBB disruption. In this setting, these paramagnetic agents enhance T1 relaxation locally and thereby identify when and where the BBB is incompetent on T1WI (Fig. 1). These foci of BBB abnormality are often multiple during clinically apparent disease activity and are less common during periods of remission. Contrast MRI studies frequently show BBB disruption during periods of apparent clinical remission.[4,6-8] Although the duration of persistence of the BBB abnormality is variable, it usually is between 1 and 4 months.[6,7] "Old" lesions can also regain enhancement,[4] presumably because of renewed inflammation.

T2WI and PDWI are not as sensitive to these early lesions as enhanced T1WI.[8] Unlike T1WI, however, the T2WI and PDWI abnormalities often persist indefinitely[9,10] (Fig. 2), although the size of the T2WI- and PDWI-detected changes often decrease during the first few months with resolution of edema. The MRI-detected lesion may also have a "target" appearance—presumably because, at certain stages, inflammation is most severe at the outer edge, with the gliosis extending out from the center (Fig. 3). Rarely, lesions may demonstrate gadolinium enhancement without corresponding T2WI or PDWI abnormalities.[11]

The well-established clinical subgroups of MS tend to have different imaging characteristics. On standard imaging sequences, patients with relapsing-remitting and secondary progressive MS most commonly have discrete and confluent periventricular, subcortical white matter, brain stem, and spinal cord lesions that vary substantially in number among patients. In patients with relapsing-remitting MS of less than 5 years' duration and in patients with secondary progressive MS, MRI "activity" (new, larger, and enhancing lesions) is common (on the average, 20 active lesions annually), but considerable variability exists among patients. Patients with benign MS (defined as at least 10 years' duration with mild or no permanent disability) have fewer annual MRI changes (fewer than 10 per year[12,13]). In contrast, patients with primary progressive MS (a variant more common with onset after age 40 years) have steady and slow progression of the disease for many years with few if any discrete relapses, have fewer active cerebral and spinal lesions (fewer than four per year), have less contrast enhancement, have noticeably fewer and smaller lesions on T2WI, and frequently have noticeable spinal cord atrophy.[6,14-16] Although cerebral atrophy has long been recognized in advanced cases, a recent report[17] suggested that atrophy may actually be present early in the disease. Spinal cord cross-sectional area may be a marker of atrophy, but this is a late and probably irreversible marker. MRI of the spinal cord is difficult because the cord is relatively small and both it and the surrounding CSF move; thus, image quality can be compromised.[18]

Fig. 1. T1-weighted gadolinium-enhanced magnetic resonance image of the brain of a patient with multiple sclerosis, demonstrating abnormal enhancement at multiple sites where blood-brain barrier has failed. *AI* = anteroinferior; *PS* = posterosuperior.

MRI TECHNIQUES FOR MS

MRI is a field of rapid improvements—indeed, it became clinically available less than 15 years ago. Because investigators cannot change imaging techniques in the middle of a trial that may last for years, long lead times exist from the time when a technology becomes available to the time when its results can be assessed. This overall pattern accounts for the lack of long-term studies with results that have used these newer techniques in treatment trials.

Methods for Imaging the BBB.—The most commonly used measures of MRI abnormality in studies of MS are attempts to determine the number of new lesions or the amount of brain tissue that has become abnormal (or both). The number or presence of gadolinium-enhancing lesions is an indicator of the inflammatory component of current disease activity and is another common measure. An effective treatment might be expected to reduce the number of active plaques. Therefore, MRI can be used for quick identification of therapies that have a reasonably rapid effect on preventing BBB breakdown or enhancing its repair. In studies that use gadolinium, various criteria may be applied. The presence of *any* enhancing lesions indicates an active scan; perhaps

For personal use. Mass reproduce only with permission from Mayo Clinic Proceedings.

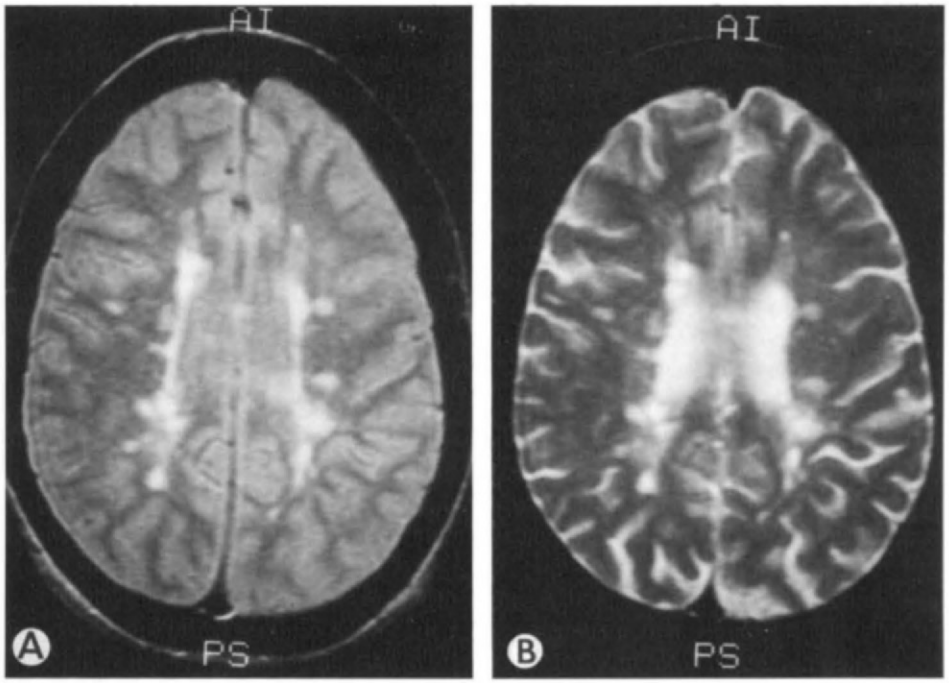

Fig. 2. Proton density (*A*) and T2-weighted (*B*) magnetic resonance images of the brain in a patient with multiple sclerosis. For explanation of abbreviations, see Figure 1.

the *number* of enhancing lesions would increase statistical power. Recent data suggest that the volume of enhancing tissue might be the best criterion.[19] Newer formulations of gadolinium agents (for example, gadoteridol) allow administration of 3 times more gadolinium, which often increases the number of lesions detected.[20,21] The increase is higher in patients with benign[22] or primary progressive[23] MS. Another factor that has been noted is that delayed imaging up to 30 minutes after the administration of gadolinium will increase the number of lesions seen, in comparison with immediate imaging. Suppression of background noise (such as with off-resonance pulse magnetization transfer suppression) can also increase the number of enhancing lesions detected. Magnetization transfer will be discussed in more detail subsequently in this review.

T2-Based Volume Quantification.—Because MS is a disease with an unpredictable clinical course characterized by periods of quiescence punctuated with episodes of activity, a technique that could "summarize" activity since the prior examination would seem to be most cost-effective. T2WI obtained yearly approximate such a summary. The size and number of lesions in comparison with findings on the previous examination tend to correlate with the MS disease activity; clearly, however, T2 lesions can both shrink and enlarge. This approach, however, requires measurement of the volume of involved tissue rather than the presence or absence of enhancement, and accurate measurement of T2 abnormalities on scans has proved difficult for several reasons. Changes in head position have been shown to have an important effect on lesion volume measurements.[24] With faster imaging sequences (such as rapid acquisition with relaxation enhancement [RARE] or fast spin-echo imaging[25]), more slices can be acquired in the amount of time that some patients can lie still (particularly patients with MS). Therefore, the thinner imaging slices should reduce partial volume artifact and enhance accuracy.[26] More recent reports, however, suggest that the blurring of edges inherent in this technique may decrease the accuracy.[27]

Many studies have described the reproducibility of T2WI measurements. Most reports have been based on hand-traced lesion boundaries. Early reports[28] showed variations of 17 to 30% among operators. The accuracy and reproducibility have improved as the pulse sequences, software, and computer operators improve. In the optimal situation, the intra-operator reproducibility with computer-assisted contouring methods can approach 5%.[29,30] This variation is similar in magnitude to the change that may occur during 1 year and may explain why T2WI volumetrics have been disappointing.

Automated or semiautomated computer measurement techniques have considerable appeal in MRI research on MS. Such techniques might be more reproducible than manual methods, and they are less labor intensive. Multiparametric techniques are based on the acquisition of

For personal use. Mass reproduce only with permission from Mayo Clinic Proceedings.

more than one type of image—for example, T2WI and PDWI. This approach attempts to group types of tissue on the basis of certain tissue intensity profiles on all types of images. The T2-PD pair of images has the advantage that they are typically acquired at the same time; therefore, intensities in different images at a specific *x-y* location in a particular slice are for the same piece of tissue. The addition of another data set—for example a T1WI—will provide further information to aid in the segmentation process (labeling each voxel with the type of tissue it represents) but necessitates that the patient not move between scans or that the image be reformatted to match the other sequences spatially. Although these approaches have shown limited success,[31,32] none is currently able to measure the MS disease burden in a totally automated fashion with high precision; thus, some element of user variability is introduced. Currently, we are involved in the development of a fully automated process based on multiparametric analysis combined with special MRI pulse sequences with a mean reproducibility between acquisitions of 7%[33] (Fig. 4).

Fluid-Attenuated Inversion Recovery.—Having bright signal from normal structures such as CSF adjacent to abnormal bright signal from plaques reduces sensitivity. The fluid-attenuated inversion recovery (FLAIR) sequence was developed in an attempt to solve this problem.[34] FLAIR images are heavily T2 weighted (making MS plaques bright) but include an inversion pulse that substantially reduces the signal from bulk water such as CSF.[35] With this sequence, the conspicuity of lesions, particularly cortical lesions, increases appreciably.[36] The problem with this sequence has been the long acquisition time—almost 30 minutes for a set of images. Patient motion during this time negates much of the advantage of the higher contrast. A faster version of this sequence has been developed, which maintains the high contrast ratio but reduces acquisition time to 5 to 8 minutes[37] (Fig. 5). Initial hopes were that the contrast would be so great that a simple threshold for the entire head would separate pathologic from normal features, but this has not proved to be the case. Flow artifacts can be bright, as can some normal structures (for example, ependymitis granulosa, septum pellucidum, and subcutaneous fat). A simple threshold would identify these normal findings as abnormalities. Shading artifacts (gradual changes in intensity due to magnetic field heterogeneity) also make a simple threshold ineffective. Nevertheless, correction for these structures and artifacts may be possible, and we believe that fast FLAIR will be an important technique for measuring the total volume of T2 abnormality in patients with MS.

T1 and T2 Relaxation Time Measurements.—MRI is extremely sensitive but often lacks specificity. Investigators originally hoped that measurements of the T1 and T2 relaxation times (as opposed to imaging that shows how many protons have long or short times) would be more specific. In the case of MS, T1 but not T2 relaxation times have been found to be weakly correlated with scores on the Expanded Disability Status Scale (EDSS).[38] Another investigative group found that a multiparametric fit of the T2 decay curve could distinguish purely inflammatory lesions from demyelination in laboratory animals.[39] In yet another study, a statistical difference in the T2 relaxation time of control patient white matter and the normal-appearing white matter (NAWM) in patients with MS was found, but with considerable overlap between normal and abnormal tissue relaxation times.[40] For these reasons, and because of technical challenges in implementing a clinically feasible sequence, T2 relaxation time imaging is not frequently used in the evaluation of MS.

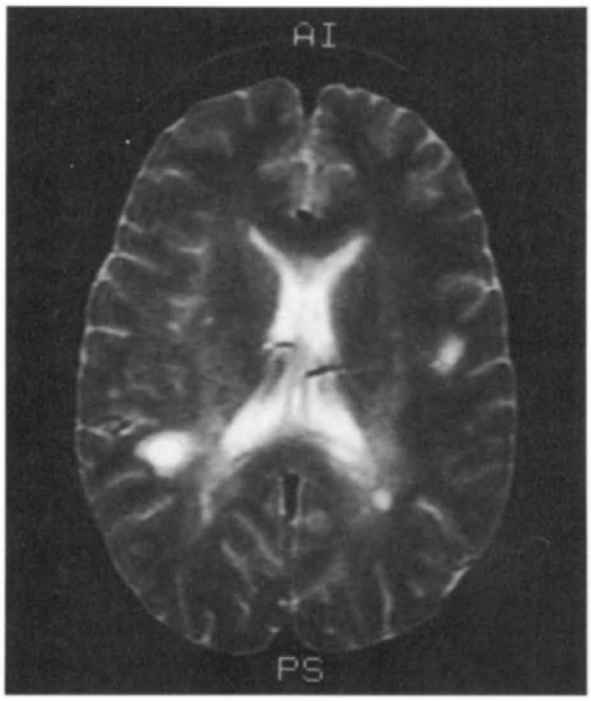

Fig. 3. "Target" appearance of multiple sclerosis lesion on T2-weighted magnetic resonance image of brain is due to edematous state at border of lesion with moderately increased free water, which is not as bright as gliosis in older central portion of lesion. (This lesion is the ring-enhancing feature in Figure 1.) For explanation of abbreviations, see Figure 1.

Magnetization Transfer Imaging.—Magnetization transfer is the exchange of magnetization between protons in distinct environments (such as bulk water versus bound to proteins) and is an important relaxation mechanism in biologic tissues.[41,42] Several investigators have proposed that magnetization transfer imaging (MTI) may provide a unique measure that could distinguish pathologic conditions. As with T2 measurements, MTI can detect differences in the

For personal use. Mass reproduce only with permission from Mayo Clinic Proceedings.

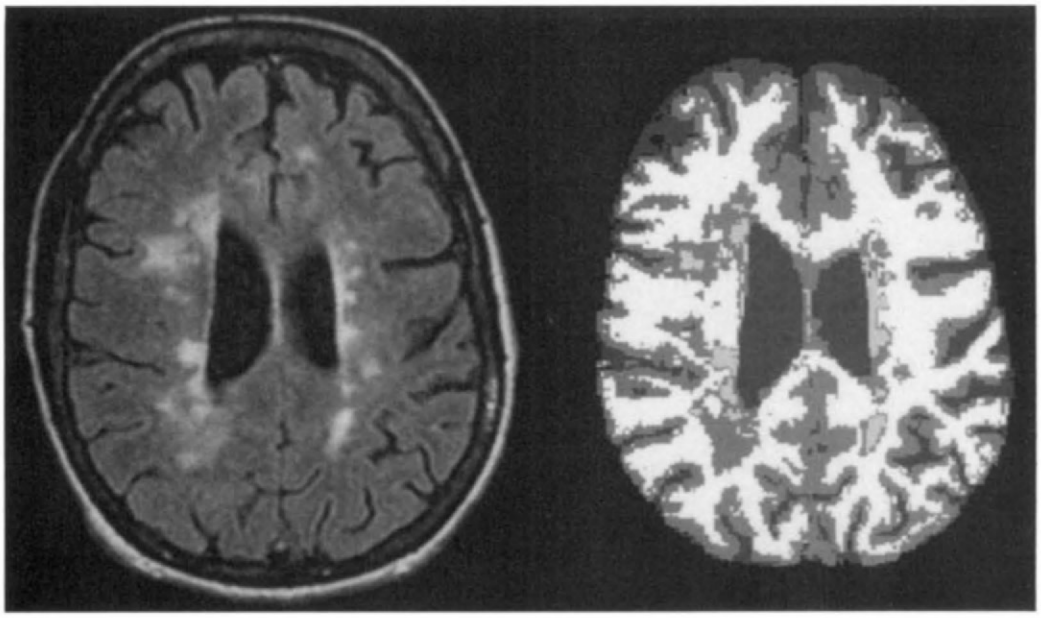

Fig. 4. Automated segmentation output. On the left is the fluid-attenuated inversion recovery (FLAIR) image of the brain, and on the right is the segmented image. Gray scale: *white* = white matter; *light gray* = T1 hypointense pathologic features; *medium gray* = T1 isointense pathologic features; *dark gray* = gray matter; *black* = cerebrospinal fluid and extradural tissues.

NAWM.[43,44] These findings may reflect the microscopic histopathologic changes known to be diffusely present in the NAWM of patients with MS. MTI may also be able to determine the age of plaques.[45] Other groups have suggested that the magnetization transfer ratio may be an important prognostic factor for patients with MS.[46] The lack of a standard method for measuring the amount of magnetization transfer occurring in a tissue has impeded the validation and use of this technique. Recent efforts have focused on changes in the shape of the histogram of brain pixels,[47] although the value of this factor as a measure of progression of disease has not been substantiated.

Just as suppression of signals from fat protons can increase the conspicuity of enhancing tissue surrounded by fat, suppression of magnetization transfer seems to increase the detectability of both enhancing and nonenhancing lesions.[48] One recommendation is to obtain precontrast images with magnetization transfer suppressed images because the suppression may unmask areas of increased T1 (presumed to be lipids) that might be mistaken for areas of enhancement.

T1 "Holes."—Although T2WI and FLAIR images are sensitive to most MS plaques, several studies are now focusing on the value of areas of hypointensity on T1WI (T1 "holes") as indicators of disease state. In comparison with T2WI, a stronger correlation seems to exist between the volume of T1 holes and the scores on the EDSS.[19] T1 hypointensity has also been shown to correlate with the magnetization transfer ratio,[49] which, in turn, is thought to represent areas of greater demyelination.[50] The volume of T1 holes may therefore eventuate as a better correlate of disability and disease progression than T2 abnormality.

Magnetic Resonance Spectroscopy.—Thus far, the MRI techniques discussed have been based on water protons. Magnetic resonance spectroscopy (MRS) measures the protons of other chemicals, such as the neuronal marker *N*-acetylaspartate (NAA); choline, which primarily reflects the phosphatidylcholine in membranes; and creatine (Cr), which is commonly used as a reference molecule. During early stages of MS plaque formation, investigators have found an increase in lipids[51] (in some cases, before gadolinium enhancement is seen) as well as an increase in choline and lactate. In chronic MS plaques, NAA is decreased but choline remains increased.[52] The ability to detect an increase in NAA or choline after treatment that corresponded with clinical improvement could be an important measure of the effectiveness of a specific therapy.

MRS is also able to demonstrate a diffuse abnormality in the NAWM—the NAA:Cr ratio is decreased in central white matter in comparison with that in control subjects.[53,54] Studies have also demonstrated a decrease in NAA:Cr ratio that was correlated with T2 lesion volume over time. This decrease in NAA:Cr ratio may reflect a diffuse loss in axons, perhaps related to wallerian degeneration extending from focal plaques.

For personal use. Mass reproduce only with permission from Mayo Clinic Proceedings.

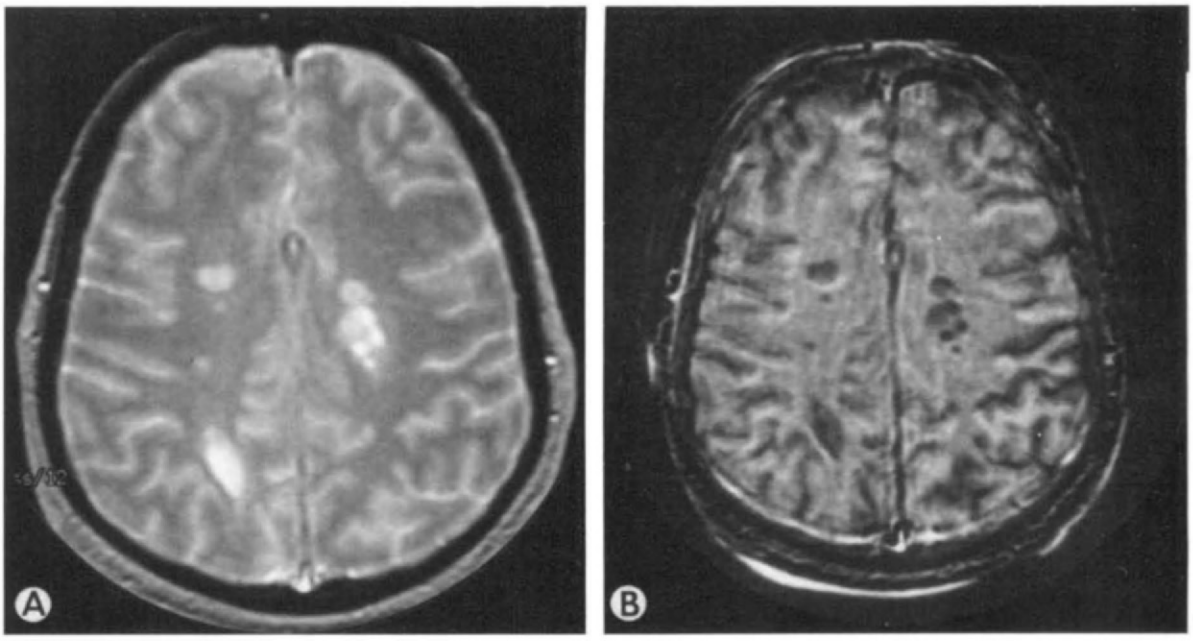

Fig. 5. Magnetic resonance images of the brain in a patient with multiple sclerosis. *A*, T2-weighted image. *B*, Apparent magnetization transfer ratio image. Note that the brighter (more cystic) lesions on T2-weighted image (*A*) are darker on *B* because they have a lower magnetization transfer ratio.

Diffusion Imaging.—MRI pulse sequences can be created that are sensitive to microscopic motion of water molecules. Layers of myelin around the axon restrict the directions in which diffusion can occur.[55] A summary by Hajnal and associates[56] detailed both the technical problems and the clinical examples in which abnormalities not demonstrated with conventional MRI were shown with diffusion-weighted pulse sequences. Like MTI, these sequences may be able to date plaques and to detect changes in NAWM.[57]

USE OF MRI IN STUDIES OF MS

MRI is a commonly used secondary outcome measure for the evaluation of putative MS treatments. Of importance, MRI is a laboratory test and not the final measure of clinical success. An important question is whether MRI-measured disease corresponds with the clinical disease course. Although early studies comparing scores on the EDSS[58] suggested a poor correlation,[59,60] more recent studies suggest a more optimistic role for MRI. Perhaps more accurate and reproducible measurement techniques have yielded this difference. In some studies, different types of MS were analyzed collectively, a factor that likely confounded the conclusions. MRI events, whether measured by number or volume of gadolinium-enhancing lesions, or T2WI volume does relate to attack rate.[61,62] In recent trials, the MRI data have been extremely useful in determining the effectiveness of therapies. Perhaps with further research, MRI changes and response to experimental therapies will accurately predict long-term disability. If so, MRI may be accepted as a primary outcome measure for MS treatment trials.

A recent international workshop on the design of MS therapeutic trials[63] recommended that phase I and II clinical trials of promising new therapies incorporate frequent (every 2 to 6 weeks) MRI studies with contrast agents (because contrast imaging increases the detection of MS "activity"[11,64]). Treatments that had positive results in phases I and II might then warrant a definitive phase III study—in which case, MRI studies would be performed every 6 to 12 months. This strategy will detect agents that favorably influence the BBB disruptions during phase I and II studies and will identify treatments that reduce the accumulation of permanent MRI-detected white matter changes over prolonged periods of observation during phase III studies.

How well MRI changes reflect clinical changes continues to be a controversial issue. As outlined in the foregoing material, extensive interpatient variability exists in the degree of MRI change seen at each clinically defined level of disability. Most MRI changes detected by serial scanning go undetected clinically.[15] Conversely, most patients suspected of having "active" MS (exclusive of primary progressive cases) will be found to have evidence of MRI activity.[9,65-67] In individual cases, little correlation is noted between MRI and clinical findings—minimally disabled patients may have extensive MRI changes and vice versa. Increasingly, how-

For personal use. Mass reproduce only with permission from Mayo Clinic Proceedings.

ever, large clinical series and clinical trials are able to show group differences and correlations (albeit with only modest correlation coefficients) of MRI change with clinical course (for example, relapse and progression[61,68] and disability[28,69-71]). As noted previously, a closer correlation of changes in clinical disability and MRI changes may be detected by T1WI than by T2WI.[19]

Symptoms and signs develop when the patient has conduction slowing, temporal dispersion (demyelination), or block (demyelination and axonal disruption) of action potentials in clinically eloquent pathways.[72] Currently, standard MRI techniques cannot be used to distinguish demyelination, edema, remyelination, axon loss, and gliosis because these techniques are sensitive only to changes in the absolute number and physicochemical environment of mobile protons, and considerable overlap exists among these pathologic states. In addition, T2WI detect changes in NAWM seen by magnetic resonance relaxation time mapping,[38,73,74] MTI,[44] and MRS.[54] An urgent need exists for validated, widely available magnetic resonance methods that distinguish demyelination from axon loss and that detect areas of remyelination. If magnetic resonance techniques can be convincingly shown to predict the clinical course of MS and the response to treatment, they may serve as surrogate outcome measures and thereby potentially reduce the cost, effort, and time of definitive trials. Almost certainly, such methods will improve the sensitivity of detecting important treatment effects. Until MRI can replace the clinical examination, however, MS investigators are resigned to other measures of disease activity and disability (such as relapse rate and confirmed change on MS disability scales) as the primary means of determining the treatment effect (primary outcome). MRI techniques will continue to be used in parallel to validate and extend these clinical observations.

Conventional MRI can detect cerebral and spinal cord atrophy in advanced cases but is insensitive to axon loss within a lesion. Contrast-enhanced imaging detects BBB disruption, a finding that is associated with inflammatory demyelination in MS. The biexponential decay of T2 relaxation curves may identify areas of axon loss.[75] MTI detects changes in the fraction of structured water, which seems to have unique values for demyelination and gliosis and may ultimately be useful in distinguishing acute from chronic lesions.[45] MRS can identify free lipid peaks in active, demyelinating lesions and, perhaps, areas of axon loss,[53,76-78] but it is likely to remain impractical for use in the performance of full-scale clinical trials.

Several pilot and definitive trials have used serial MRI studies as a measure of therapeutic value. In trials of interferon-α[79] and cyclosporine,[80,81] investigators reported no important differences between the active and the placebo arms in MRI evidence of worsening (new, larger lesions) and MRI-detected areas of change estimated by manual tracing of the MS lesions with use of a computer-assisted system. No apparent difference in MRI (or clinical) course was noted when azathioprine was compared with cyclosporine in a large European trial.[82] Pilot studies of interferon-α,[83] cladribine,[84] monoclonal antibodies,[85,86] mitoxantrone,[10,87] and azathioprine[82] and phase II and III trials of total lymphoid irradiation,[88,89] Copolymer 1,[90] linomide,[91,92] and interferon-β[28,69,70,93] have all reported that the putative experimental agent favorably influenced MRI evidence of disease activity. In the interferon-β-1b (Betaseron) trial, investigators were able to show a convincing MRI effect in patients who received 8 million IU of Betaseron in comparison with those who received placebo (see subsequent details). This dramatic MRI effect provided strong support for the clinical evidence (reduced relapse rate) that the drug had altered the natural history of relapsing MS. Approval by the Food and Drug Administration followed shortly thereafter. In this trial, all patients underwent annual MRI studies, and a cohort of 52 patients under surveillance at one center underwent scans at 6-week intervals. The patients in the group studied at 6-week intervals who were receiving 8 million IU of Betaseron had a sixfold reduction in the rate of active scans.[69] The positive initial report has now been complemented by the publication of the extension study,[70] in which compliant patients (217 of the original 372 patients) remained on the treatment to which they were assigned for a mean follow-up of more than 46 months. Whereas the median area of MRI change continued to increase by 18.7% in the patients who received placebo (a change of degree similar to that seen in the placebo and active arms of the aforementioned interferon-α and cyclosporine trials), no increase in "burden of disease" was apparent in those who received 8 million IU of Betaseron. In addition, an important MRI benefit (compared with placebo) was noted in the patients who received the lower dose of interferon. Despite this, however, the patients who received the lower dose seemed to have more rapid progression of disease ("time to confirmed progression") than the placebo-treated patients. This troublesome finding argues against use of current MRI techniques as surrogate outcome measures in MS trials. Furthermore, this finding suggests that T2WI measurements do not correlate well with clinical measures.

Although the recently completed Copolymer 1 trial[94] demonstrated a reduction in relapse rate, serial MRI studies were not widely used to corroborate clinical effectiveness. The interferon-β-1a (Avonex) study[93] did have a substantial MRI component. In that study, the number of gadolinium enhancements was significantly decreased at both year 1 and year 2. The median percentage change in T2 volume, however, was statistically significantly less at year 1 but not at year 2. Although the Betaseron study indicated a yearly

For personal use. Mass reproduce only with permission from Mayo Clinic Proceedings.

median increase in T2 volume of approximately 20% in the placebo group, the Avonex study reported a median *decrease* in T2 volume of about 3.3%. Clear differences existed in the patient populations (a wider range of EDSS scores had been accepted into the Betaseron study), and the Betaseron study had follow-up results for 5 years, in contrast with only 2 years of follow-up thus far reported for the Avonex study. Of note, the Betaseron study reanalyzed all the MRI data because operator variability resulted in a drift in the reported volume.[70] The reproducibility of the technique used in the Avonex study when applied to MS was not reported.

In both the Avonex[93] and the Betaseron[95] trials, the effect of neutralizing antibodies was discussed. In both studies, patients with neutralizing antibodies showed *less* progression of disability than did patients without such antibodies. At least as surprising is the finding that the subgroup with neutralizing antibodies that did well had increased relapse rates and increased MRI activity. This group of findings may lead to a breakthrough in thinking about MS. Although suppression of inflammatory activity has always been the goal (and, as described previously, is considered a useful method for identifying candidate therapies), inflammation may also be a marker for a reparative process that can slow progression of MS. As discussed herein and in the report by Hunter and colleagues[96] in this symposium, the pathologic processes that contribute to the clinical expression of MS (that is, relapse or permanent disability) are complex and are currently not well discriminated by T2WI alone.

CONCLUSION

Although MRI has considerably increased our knowledge of MS, it is by no means a perfect technology. MRI is probably a valuable technique for early-phase trials because it is sensitive to the effects that a therapy may have on the inflammatory changes seen in MS—which, in turn, may have a positive influence on progression of disability. Whether MRI can ultimately replace clinical assessment or considerably enhance long-term outcomes (such as disability) for phase III trials is unknown. The relationship between T2WI-detected abnormality and long-term clinical course is unclear. Newer MRI techniques may correlate better with clinical course, but the long lead time needed to validate them presents a hindrance to their use. Better techniques for measuring changes on standard MRI may improve the correlation between MRI and clinical findings and can be applied retrospectively.

REFERENCES

1. Noseworthy JH, Vandervoort MK, Wong CJ, Ebers GC (Canadian Cooperative MS Study Group). Interrater variability with the Expanded Disability Status Scale (EDSS) and Functional Systems (FS) in a multiple sclerosis clinical trial. Neurology 1990;40:971-975
2. Noseworthy JH. Clinical scoring methods for multiple sclerosis. Ann Neurol 1994;36(Suppl):S80-S85
3. Johnson MA, Li DK, Bryant DJ, Payne JA. Magnetic resonance imaging: serial observations in multiple sclerosis. AJNR Am J Neuroradiol 1984;5:495-499
4. Grossman RI, Braffman BH, Brorson JR, Goldberg HI, Silberberg DH, Gonzalez-Scarano F. Multiple sclerosis: serial study of gadolinium-enhanced MR imaging. Radiology 1988;169:117-122
5. Nesbit GM, Forbes GS, Scheithauer BW, Okazaki H, Rodriguez M. Multiple sclerosis: histopathologic and MR and/or CT correlation in 37 cases at biopsy and three cases at autopsy. Radiology 1991;180:467-474
6. Bastianello S, Pozzilli C, Bernardi S, Bozzao L, Fantozzi LM, Buttinelli C, et al. Serial study of gadolinium-DTPA MRI enhancement in multiple sclerosis. Neurology 1990;40:591-595
7. Harris JO, Frank JA, Patronas N, McFarlin DE, McFarland HF. Serial gadolinium-enhanced magnetic resonance imaging scans in patients with early, relapsing-remitting multiple sclerosis: implications for clinical trials and natural history. Ann Neurol 1991;29:548-555
8. Ormerod IE, Miller DH, McDonald WI, du Boulay EP, Rudge P, Kendall BE, et al. The role of NMR imaging in the assessment of multiple sclerosis and isolated neurological lesions: a quantitative study. Brain 1987;110:1579-1616
9. Wiebe S, Lee DH, Karlik SJ, Hopkins M, Vandervoort MK, Wong CJ, et al. Serial cranial and spinal cord magnetic resonance imaging in multiple sclerosis. Ann Neurol 1992;32:643-650
10. Noseworthy JH, Hopkins MB, Vandervoort MK, Karlik SJ, Lee DH, Penman M, et al. An open-trial evaluation of mitoxantrone in the treatment of progressive MS. Neurology 1993;43:1401-1406
11. Miller DH, Barkhof F, Nauta JJ. Gadolinium enhancement increases the sensitivity of MRI in detecting disease activity in multiple sclerosis. Brain 1993;116:1077-1094
12. Kidd D, Thompson AJ, Kendall BE, Miller DH, McDonald WI. Benign form of multiple sclerosis: MRI evidence for less frequent and less inflammatory disease activity. J Neurol Neurosurg Psychiatry 1994;57:1070-1072
13. Filippi M, Campi A, Mammi S, Martinelli V, Locatelli T, Scotti G, et al. Brain magnetic resonance imaging and multimodal evoked potentials in benign and secondary progressive multiple sclerosis. J Neurol Neurosurg Psychiatry 1995;58:31-37
14. Koopmans RA, Li DK, Grochowski E, Cutler PJ, Paty DW. Benign versus chronic progressive multiple sclerosis: magnetic resonance imaging features. Ann Neurol 1989;25:74-81
15. Koopmans RA, Li DK, Oger JJ, Kastrukoff LF, Jardine C, Costley L, et al. Chronic progressive multiple sclerosis: serial magnetic resonance brain imaging over six months. Ann Neurol 1989;26:248-256
16. Thompson AJ, Kermode AG, MacManus DG, Kendall BE, Kingsley DPE, Moseley IF, et al. Patterns of disease activity in multiple sclerosis: clinical and magnetic resonance imaging study. BMJ 1990;300:631-634
17. Losseff NA, Wang L, Lai HM, Yoo DS, Gawne-Cain ML, McDonald WI, et al. Progressive cerebral atrophy in multiple sclerosis: a serial MRI study. Brain 1996;119:2009-2019
18. Losseff NA, Webb SL, O'Riordan JI, Page R, Wang L, Barker GJ, et al. Spinal cord atrophy and disability in multiple sclerosis: a new reproducible and sensitive MRI method with potential to monitor disease progression. Brain 1996;119:701-708
19. van Walderveen MAA, Barkhof F, Hommes OR, Polman CH, Tobi H, Frequin STFM, et al. Correlating MRI and clinical disease activity in multiple sclerosis: relevance of hypointense lesions on short-TR/short-TE (T1-weighted) spin-echo images. Neurology 1995;45:1684-1690
20. Wolansky LJ, Bardini JA, Cook SD, Zimmer AE, Sheffet A, Lee HJ. Triple-dose versus single-dose gadoteridol in multiple sclerosis patients. J Neuroimaging 1994;4:141-145
21. Filippi M, Yousry T, Campi A, Kandziora C, Colombo B, Voltz R, et al. Comparison of triple dose versus standard dose gadolinium-DTPA for detection of MRI enhancing lesions in patients with MS. Neurology 1996;46:379-384
22. Filippi M, Capra R, Campi A, Colombo B, Prandini F, Marciano N, et al. Triple dose of gadolinium-DTPA and delayed MRI in patients

For personal use. Mass reproduce only with permission from Mayo Clinic Proceedings.

with benign multiple sclerosis. J Neurol Neurosurg Psychiatry 1996;60:526-530
23. Filippi M, Campi A, Martinelli V, Colombo B, Yousry T, Canal N, et al. Comparison of triple dose versus standard dose gadolinium-DTPA for detection of MRI enhancing lesions in patients with primary progressive multiple sclerosis. J Neurol Neurosurg Psychiatry 1995;59:540-544
24. Gawne-Cain ML, Webb S, Tofts P, Miller DH. Lesion volume measurement in multiple sclerosis: how important is accurate repositioning? J Magn Reson Imaging 1996;6:705-713
25. Hennig J, Nauerth A, Friedburg H. RARE imaging: a fast imaging method for clinical MR. Magn Reson Med 1986;3:823-833
26. Sheldon PE, Rothschild PA, Kramer DM, Hale JD, Kaufman L. Impact of section doubling on lesion contrast. Radiology 1991; 180:123-125
27. Rovaris M, Gawne-Cain ML, Wang L, Miller DH. A comparison of conventional and fast spin-echo sequences for the measurement of lesion load in multiple sclerosis using a semi-automated contour technique. Neuroradiology 1997;39:161-165
28. Paty DW. Magnetic resonance imaging in the assessment of disease activity in multiple sclerosis. Can J Neurol Sci 1988;15:266-272
29. Pannizzo F, Stallmeyer MJB, Friedman J, Jennis RJ, Zabriskie J, Plank C, et al. Quantitative MRI studies for assessment of multiple sclerosis. Magn Reson Med 1992;24:90-99
30. Paty DW, Li DKB, UBC MS/MRI Study Group, IFNB Multiple Sclerosis Study Group. Interferon beta-1b is effective in relapsing-remitting multiple sclerosis. II. MRI analysis results of a multicenter, randomized, double-blind, placebo-controlled trial. Neurology 1993;43:662-667
31. Jackson EF, Narayana PA, Wolinsky JS, Doyle TJ. Accuracy and reproducibility in volumetric analysis of multiple sclerosis lesions. J Comput Assist Tomogr 1993;17:200-205
32. Mitchell JR, Karlik SJ, Lee DH, Fenster A. Computer-assisted identification and quantification of multiple sclerosis lesions in MR imaging volumes in the brain. J Magn Reson Imaging 1994;4:197-208
33. Erickson BJ, Avula RTV. An automatic classification of tissues and multiple sclerosis lesions in magnetic resonance images of the brain [submitted for publication]
34. Hajnal JV, Bryant DJ, Kasuboski L, Pattany PM, De Coene B, Lewis PD, et al. Use of fluid attenuated inversion recovery (FLAIR) pulse sequences in MRI of the brain. J Comput Assist Tomogr 1992; 16:841-844
35. White SJ, Hajnal JV, Young IR, Bydder GM. Use of fluid-attenuated inversion-recovery pulse sequences for imaging the spinal cord. Magn Reson Med 1992;28:153-162
36. De Coene B, Hajnal JV, Pennock JM, Bydder GM. MRI of the brain stem using fluid attenuated inversion recovery pulse sequences. Neuroradiology 1993;35:327-331
37. Rydberg JN, Hammond CA, Grimm RC, Erickson BJ, Jack CR Jr, Huston J III, et al. Initial clinical experience in MR imaging of the brain with a fast fluid-attenuated inversion-recovery pulse sequence. Radiology 1994;193:173-180
38. Haughton VM, Yetkin FZ, Rao SM, Rimm AA, Fischer ME, Papke RA, et al. Quantitative MR in the diagnosis of multiple sclerosis. Magn Reson Med 1992;26:71-78
39. Zamaroczy D, Schluesener HJ, Jolesz FA, Sobel RA, Colucci VM, Weiner HL, et al. Differentiation of experimental white matter lesions using multiparametric magnetic resonance measurements. Invest Radiol 1991;26:317-324
40. Larsson HBW, Frederiksen J, Kjaer L, Henriksen O, Olesen J. In vivo determination of T1 and T2 in the brain of patients with severe but stable multiple sclerosis. Magn Reson Med 1988;7:43-55
41. Wolff SD, Balaban RS. Magnetization transfer contrast (MTC) and tissue water proton relaxation in vivo. Magn Reson Med 1989; 10:135-144
42. Eng J, Ceckler TL, Balaban RS. Quantitative 1H magnetization transfer imaging in vivo. Magn Reson Med 1991;17:304-314
43. Dousset V, Grossman RI, Ramer KN, Schnall MD, Young LH, Gonzalez-Scarano F, et al. Experimental allergic encephalomyelitis and multiple sclerosis: lesion characterization with magnetization transfer imaging [published erratum appears in Radiology 1992;183:878]. Radiology 1992;182:483-491
44. Hiehle JF Jr, Lenkinski RE, Grossman RI, Dousset V, Ramer KN, Schnall MD, et al. Correlation of spectroscopy and magnetization transfer imaging in the evaluation of demyelinating lesions and normal appearing white matter in multiple sclerosis. Magn Reson Med 1994;32:285-293
45. Tomiak MM, Rosenblum JD, Prager JM, Metz CE. Magnetization transfer: a potential method to determine the age of multiple sclerosis lesions. AJNR Am J Neuroradiol 1994;15:1569-1574
46. Filippi M, Campi A, Dousset V, Baratti C, Martinelli V, Canal N, et al. A magnetization transfer imaging study of normal-appearing white matter in multiple sclerosis. Neurology 1995;45:478-482
47. van Buchem MA, McGowan JC, Kolson DL, Polansky M, Grossman RI. Quantitative volumetric magnetization transfer analysis in multiple sclerosis: estimation of macroscopic and microscopic disease burden. Magn Reson Med 1996;36:632-636
48. Mehta RC, Pike GB, Enzmann DR. Improved detection of enhancing and nonenhancing lesions of multiple sclerosis with magnetization transfer. AJNR Am J Neuroradiol 1995;16:1771-1778
49. Loevner LA, Grossman RI, McGowan JC, Ramer KN, Cohen JA. Characterization of multiple sclerosis plaques in T1-weighted MR and quantitative magnetization transfer. AJNR Am J Neuroradiol 1995;16:1473-1479
50. Hiehle JF Jr, Grossman RI, Ramer KN, Gonzalez-Scarano F, Cohen JA. Magnetization transfer effects in MR-detected multiple sclerosis lesions: comparison with gadolinium-enhanced spin-echo images and nonenhanced T1-weighted images. AJNR Am J Neuroradiol 1995;16:69-77
51. Larsson HBW, Christiansen P, Jensen M, Frederiksen J, Heltberg A, Olesen J, et al. Localized in vivo proton spectroscopy in the brain of patients with multiple sclerosis. Magn Reson Med 1991;22:23-31
52. Matthews PM, Pioro E, Narayanan S, De Stefano N, Fu L, Francis G, et al. Assessment of lesion pathology in multiple sclerosis using quantitative MRI morphometry and magnetic resonance spectroscopy. Brain 1996;119:715-722
53. Arnold DL, Riess GT, Matthews PM, Francis GS, Collins DL, Wolfson C, et al. Use of proton magnetic resonance spectroscopy for monitoring disease progression in multiple sclerosis. Ann Neuol 1994;36:76-82
54. Sappey-Marinier D. High-resolution NMR spectroscopy of cerebral white matter in multiple sclerosis. Magn Reson Med 1990;15:229-239
55. Sakuma H, Nomura Y, Takeda K, Tagami T, Nakagawa T, Tamagawa Y, et al. Adult and neonatal human brain: diffusional anisotropy and myelination with diffusion-weighted MR imaging. Radiology 1991;180:229-233
56. Hajnal JV, Doran M, Hall AS, Collins AG, Oatridge A, Pennock JM, et al. MR imaging of anisotropically restricted diffusion of water in the nervous system: technical, anatomic, and pathologic considerations. J Comput Assist Tomogr 1991;15:1-18
57. Christiansen P, Gideon P, Thomsen C, Stubgaard M, Henriksen O, Larsson HB. Increased water self-diffusion in chronic plaques and in apparently normal white matter in patients with multiple sclerosis. Acta Neurol Scand 1993;87:195-199
58. Kurtzke JF. Rating neurologic impairment in multiple sclerosis: an Expanded Disability Status Scale (EDSS). Neurology 1983;33: 1444-1452
59. Kappos L, Stadt D, Ratzka M, Keil W, Schneiderbanger-Grygier S, Heitzer T, et al. Magnetic resonance imaging in the evaluation of treatment in multiple sclerosis. Neuroradiology 1988;30:299-302
60. Bastianello S, Pozzilli C, D'Andrea F, Millefiorini E, Trojano M, Morino S, et al. A controlled trial of mitoxantrone in multiple sclerosis: serial MRI evaluation at one year. Can J Neurol Sci 1994;21:266-270
61. Smith ME, Stone LA, Albert PS, Frank JA, Martin R, Armstrong M, et al. Clinical worsening in multiple sclerosis is associated with increased frequency and area of gadopentetate dimeglumine-enhancing magnetic resonance imaging lesions. Ann Neurol 1993;33:480-489
62. Stone LA, Smith ME, Albert PS, Bash CN, Maloni H, Frank JA, et al. Blood-brain barrier disruption on contrast-enhanced MRI in patients with mild relapsing-remitting multiple sclerosis: relationship to course, gender, and age. Neurology 1995;45:1122-1126

For personal use. Mass reproduce only with permission from Mayo Clinic Proceedings.

63. Whitaker JN, McFarland HF, Rudge P, Reingold SC. Outcomes assessment in multiple sclerosis: a critical analysis. Mult Scler 1995;1:37-47
64. Barkhof F, Scheltens P, Frequin ST, Nauta JJ, Tas MW, Valk J, et al. Relapsing-remitting multiple sclerosis: sequential enhanced MR imaging vs clinical findings in determining disease activity. AJR Am J Roentgenol 1992;159:1041-1047
65. Grossman RI, Gonzalez-Scarano F, Atlas SW, Galetta S, Silberberg DH. Multiple sclerosis: gadolinium enhancement in MR imaging. Radiology 1986;161:721-725
66. Willoughby EW, Grochowski E, Li DK, Oger J, Kastrukoff LF, Paty DW. Serial magnetic resonance scanning in multiple sclerosis: a second prospective study in relapsing patients. Ann Neurol 1989;25:43-49
67. Thompson AJ, Miller D, Youl B, MacManus D, Moore S, Kingsley D, et al. Serial gadolinium-enhanced MRI in relapsing/remitting multiple sclerosis of varying disease duration. Neurology 1992;42:60-63
68. Frank JA, Stone LA, Smith ME, Albert PS, Maloni H, McFarland HF. Serial contrast-enhanced magnetic resonance imaging in patients with early relapsing-remitting multiple sclerosis: implications for treatment trials. Ann Neurol 1994;36(Suppl):S86-S90
69. IFNB Multiple Sclerosis Study Group. Interferon beta-1b is effective in relapsing-remitting multiple sclerosis. I. Clinical results of a multicenter, randomized, double-blind, placebo-controlled trial. Neurology 1993;43:655-661
70. IFNB Multiple Sclerosis Study Group, University of British Columbia MS/MRI Analysis Group. Interferon beta-1b in the treatment of multiple sclerosis: final outcome of the randomized controlled trial. Neurology 1995;45:1277-1285
71. Khoury SJ, Guttman CR, Orav EJ, Hohol MJ, Ahn SS, Hsu L, et al. Longitudinal MRI in multiple sclerosis: correlation between disability and lesion burden. Neurology 1994;44:2120-2124
72. Waxman SG. Membranes, myelin, and the pathophysiology of multiple sclerosis. N Engl J Med 1982;306:1529-1533
73. Ormerod IE, Johnson G, MacManus D, du Boulay EP, McDonald WI. Relaxation times of apparently normal cerebral white matter in multiple sclerosis. Acta Radiol Suppl 1986;369:382-384
74. Miller DH, Johnson G, Tofts PS, MacManus D, McDonald WI. Precise relaxation time measurements of normal-appearing white matter in inflammatory central nervous system disease. Magn Reson Med 1989;11:331-336
75. Armspach JP, Gounot D, Rumbach L, Chambron J. In vivo determination of multiexponential T2 relaxation in the brain of patients with multiple sclerosis. Magn Reson Imaging 1991;9:107-113
76. Narayana PA, Wolinsky JS, Jackson EF, McCarthy M. Proton MR spectroscopy of gadolinium-enhanced multiple sclerosis plaques. J Magn Reson Imaging 1992;2:263-270
77. Wolinsky JS, Narayana PA, Fenstermacher MJ. Proton magnetic resonance spectroscopy in multiple sclerosis. Neurology 1990; 40:1764-1769
78. Davie CA, Hawkins CP, Barker GJ, Brennan A, Tofts PS, Miller DH, et al. Serial proton magnetic resonance spectroscopy in acute multiple sclerosis lesions. Brain 1994;117:49-58
79. Kastrukoff LF, Oger JJ, Hashimoto SA, Sacks SL, Li DK, Palmer MR, et al. Systemic lymphoblastoid interferon therapy in chronic progressive multiple sclerosis. I. Clinical and MRI evaluation. Neurology 1990;40:479-486
80. Multiple Sclerosis Study Group. Efficacy and toxicity of cyclosporine in chronic progressive multiple sclerosis: a randomized, double-blinded, placebo-controlled clinical trial. Ann Neurol 1990;27:591-605
81. Koopmans RA, Li DK, Zhao GJ, Redekop WK, Paty DW. MRI assessment of cyclosporine therapy of MS in a multi-center trial [abstract]. Neurology 1992;42(Suppl 3):210
82. Kappos L, Patzold U, Dommasch D, Poser S, Haas J, Krauseneck P, et al. Cyclosporine versus azathioprine in the long-term treatment of multiple sclerosis—results of the German multicenter study. Ann Neurol 1988;23:56-63
83. Durelli L, Bongioanni MR, Cavallo R, Ferrero B, Ferri R, Ferrio MF, et al. Chronic systemic high-dose recombinant interferon alfa-2a reduces exacerbation rate, MRI signs of disease activity, and lymphocyte interferon gamma production in relapsing-remitting multiple sclerosis. Neurology 1994;44:406-413
84. Sipe JC, Romine JS, Koziol JA, McMillan R, Zyroff J, Beutler E. Cladribine in treatment of chronic progressive multiple sclerosis. Lancet 1994;344:9-13
85. Lindsey JW, Hodgkinson S, Mehta R, Siegel RC, Mitchell DJ, Lim M, et al. Phase 1 clinical trial of chimeric monoclonal anti-CD4 antibody in multiple sclerosis. Neurology 1994;44:413-419
86. Moreau T, Thorpe J, Miller D, Moseley I, Hale G, Waldmann H, et al. Preliminary evidence from magnetic resonance imaging for reduction in disease activity after lymphocyte depletion in multiple sclerosis [published erratum appears in Lancet 1994;344:486]. Lancet 1994;344:298-301
87. Krapf H, Mauch E, Fetzer U, Laufen H, Kornhuber HH. Serial gadolinium-enhanced magnetic resonance imaging in patients with multiple sclerosis treated with mitoxantrone. Neuroradiology 1995;37:113-119
88. Wiles CM, Omar L, Swan AV, Sawle G, Frankel J, Grunewald R, et al. Total lymphoid irradiation in multiple sclerosis. J Neurol Neurosurg Psychiatry 1994;57:154-163
89. Cook SD, Bansil S, Boos J, Devereux C, Haffty B, Goldstein J, et al. Total lymphoid irradiation (TLI) and low-dose prednisone (LDP) in progressive multiple sclerosis (PMS) [abstract]. Neurology 1995;45(Suppl 4):A417
90. Cohen JA, Grossman RI, Udupa JK, Samarasekera S, Miki Y, Polansky M, et al. Assessment of the efficacy of Copolymer-1 in the treatment of multiple sclerosis by quantitative MRI [abstract]. Neurology 1995;45(Suppl 4):A418
91. Andersen O, Lycke J, Tollesson PO, Svenningsson A, Runmarker B, Linde AS, et al. Linomide reduces the rate of active lesions in relapsing-remitting multiple sclerosis. Neurology 1996;47:895-900
92. Karussis DM, Meiner Z, Lehmann D, Gomori JM, Schwarz A, Linde A, et al. Treatment of secondary progressive multiple sclerosis with the immunomodulator linomide: a double-blind, placebo-controlled pilot study with monthly magnetic resonance imaging evaluation. Neurology 1996;47:341-346
93. Jacobs LD, Cookfair DL, Rudick RA, Herndon RM, Richert JR, Salazar AM, et al (Multiple Sclerosis Collaborative Research Group [MSCRG]). Intramuscular interferon beta-1a for disease progression in relapsing multiple sclerosis. Ann Neurol 1996;39:285-294
94. Johnson KP, Brooks BR, Cohen JA, Ford CC, Goldstein J, Lisak RP, et al (Copolymer 1 Multiple Sclerosis Study Group). Copolymer 1 reduces relapse rate and improves disability in relapsing-remitting multiple sclerosis: results of a phase III multicenter, double-blind placebo-controlled trial. Neurology 1995;45:1268-1276
95. IFNB Multiple Sclerosis Study Group, University of British Columbia MS/MRI Analysis Group. Neutralizing antibodies during treatment of multiple sclerosis with interferon beta-1b: experience during the first three years. Neurology 1996;47:889-894
96. Hunter SF, Weinshenker BG, Carter JL, Noseworthy JH. Rational clinical immunotherapy for multiple sclerosis. Mayo Clin Proc 1997;72:765-780

End of **Symposium on Multiple Sclerosis,** Part V.
Part VI will appear in the December issue.

For personal use. Mass reproduce only with permission from Mayo Clinic Proceedings.