中國醫藥大學 111 學年度第 1 學期 期中 考試試卷

☑電腦卡作答、試題：☑收回 ☐不收回

科目	命題教師	考試時間	系級	學號	姓名	評分
解剖學(B)	授課老師	50 分鐘				

注意：請用正楷填寫學號及姓名，否則無從查考，該科以零分計。 （本試題共 4 頁）

1. Which embryonic germ layer are primordial germ cells located in?
   (A) endoderm (B) hypoblast
   (C) epiblast (D) mesoderm
2. Which of the following is most closely related to the formation of the extraembryonic mesoderm?
   (A) syncytiotrophoblast (B) epiblast
   (C) cytotrophoblast (D) yolk sac cells
3. Syncytiotrophoblast primarily originate from?
   (A) amnion (B) inner cell mass
   (C) outer cell mass (D) epiblast
4. Which of the following descriptions about the results of fertilization is the most CORRECT?
   (A) sperm pass freely through zona pellucid
   (B) restores the normal diploid number of chromosomes in oocyte
   (C) oocyte complete 1st meiotic division
   (D) only a single sperm is allowed to penetrate the corona radiata
5. Which of the following descriptions about the third week of embryonic development is the most CORRECT?
   (A) local thickening of hypoblast at the caudal end of embryonic disk→Formation of the primitive node
   (B) differentiation of three intraembryonic germ layers
   (C) prechordal plate primarily originate from prenotochordal cells
   (D) buccopharyngeal membrane tightly adherent ectoderm, mesoderm and endoderm
6. Which of the following will differentiate into exocoelomic cyst?
   (A) intermediate mesodermal germ layer (B) primitive yolk sac
   (C) secondary yolk sac (D) extraembryonic mesoderm
7. What is the last region of the vertebrae to ossify?
   (A) Transverse process (B) Spinous process
   (C) Superior ring of vertebral body (D) Inferior ring of vertebral body
8. Which of the following statements about somites is/are **Incorrect**:
   (A) Differentiate a covering epithelium in their early stages.
   (B) Somites contribute the body wall osteogenic, chrondrogenic and fibrogenic cells.
   (C) Contribute to a single vertebral level body and the intervertebral disc.
   (D) Myotomes contribute the smooth muscle associated with the gastrointestinal tract walls.
9. Which of the following is a derivative of the epimere musculature?
   (A) Intrinsic muscles of the back (B) External intercostal m.

(C) Muscles of tongue (D) Infrahyoid m.

10. What sternal deformity results from the failure of inferior fusion of the sternal bars?

(A) Manubrium cleft (B) Bifid xiphoid processs

(C) Sternal foramen (D) Obtuse angle of the sternal angle

11. What type of gene loss or disruptive mutation is likely to be present in Phocomelia patients?

(A) HEDGEHOG genes (SHH) (B) FGF genes (FGF 8)

(C) WNT-7a genes (D) BMP genes (BMP4)

12. Which of the following is the primary ossification center of a long bone?

(A) Diaphysis (B) Metaphysis

(C) Epiphysis (D) Periosteum

13. Indicate the orientation in the figure.

(A) the direction toward the cranial side

(B) the direction toward the distal side

(C) the direction toward the ventral side

(D) the direction toward the superficial side

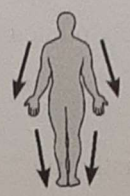

14. The leg is anatomically term known as?

(A) Tarsal (B) Crural (C) Pollex (D) Carpal

15. Which one looks in the posterior mediastinum of the thoracic cavity?

(A) Thymus (B) Esophagus

(C) Heart (D) Lung

16. Which vertebrae have a heart shaped body?

(A) Cervical (B) Thoracic (C) Lumbar (D) Sacrum

17. Which are the characteristics of the vertebra prominent? C7

(A) 2 lateral masses connected to 2 arches: ring-like

(B) Very long spinous process, not bifid; Transverse foramen is smallest

(C) Dens with its ligaments; Transverse processes are the smallest

(D) no spinous process, 2 demifacet

18. The following statements about the vertical column are **Correct**:

(A) Thoracic vertebra joined by vertebral arch and costal head

(B) The cervical curve is convex and bends forward

(C) The spinous process of the lumbar vertebra is facing backward and has double bifurcations

(D) Cervical vertebra has a transverse foramen, but the structure of special C7 lack of this structure.

19. Sacral hiatus is formed by:

(A) Space between the Sacral and Coccyx

(B) Absence of pedicles in S2 and S3

(C) Inferior articular processes of S5

(D) Absence of laminae and spinous process of S4 and S5

20. The bones that make up the outer wall of the nasal cavity do **NOT** contain:

(A) Maxilla bone (B) Vomer bone

(C) Palatine bone (D) Ethmoid bone

21. What is the name of the bone that forms the roof of the nasal cavity and part of the medial wall of the

orbit of the eye?

(A) Maxilla bone (B) Ethmoid bone

(C) Nasal bone (D) Frontal bone

22. The mandibular foramen is located on the

(A) Medial angle of the mandible (B) Floor of the mandible

(C) Medial ramus of the mandible (D) Body of the mandible

23. Which structures is located close to the optic nerve?

(A) Frontal crest (B) Anterior clinoid process

(C) Styloid process (D) Mastoid process

24. Which of the following processes is located just inferior and medial to the external acoustic meatus?

(A) Styloid process (B) Condylar process

(C) Mastoid process (D) Coronoid process

25. A sharp instrument passing through the superior orbital fissure would most likely sever which of the following structures?

(A) Mandibular nerve (B) Trochlear nerve

(C) Optic nerve (D) Maxillary nerve

26. All of the following are located in the middle cranial fossa **Except**?

(A) the anterior clinoid process (B) the trigeminal impression

(C) the superior orbital fissure (D) the hypophyseal fossa

27. The tegmen tympani is found in?

(A) Occipital (B) Ethmoid

(C) Temporal (D) Sphenoid

Medial rotation

28.Which of the following muscle can be extends the humerus, and rotates the humerus medially?

(A) teres major (B) trapezius (C) latissimus dorsi (D) deltoid

29.Which of the following muscle forms medial wall of axilla?

(A) deltoid (B) serratus anterior (C) pectoralis major (D) coracobrachialis

30.Which of the following muscle originating on the clavical?

(A) subclavius (B) serratus anterior (C) pectoralis minor (D)deltoid

31.The largest of carpal bones is_____.

(A)trapezium (B)trapezoid (C)capitate (D)hamate

32.Landmarks associated with the distal end of the humerus?

(A) surgical neck (B)greater tubercle (C)trochlea (D)olecranon

33.The furrow between the greater and lesser tubercles of the humerus lodges the_____.

(A)axillary artery (B) long head of biceps brachii

(C) long head of triceps brachii (D) lateral head of triceps brachii

34. Which of the following muscle can be flexion and abduction of the wrist joint?

外展

(A) brachioradialis (B) pronator teres

(C) flexor carpi ulnaris (D) flexor carpi radialis

35.Which of the following muscle produces adduction of finger? 内收

(A)palmaris brevis (B) dorsal interossei (C) palmar interossei (D) lumbricals

36.Which of the following is NOT true regarding the posterior view of quadrangular space?

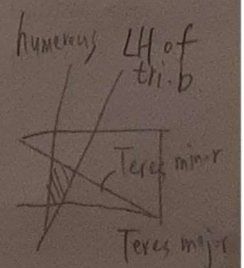

(A) subscapularis (B) long head of triceps brachii
(C) teres major (D) humerus

37. The smooth articular surface of the acetabulum is known as which of the following?
(A) Acetabular fossa (B) Acetabular notch
(C) Lunate surface (D) Transverse acetabular ligament

38. Which of the following muscles is part of the 'triceps coxae'?
(A) Tensor fasciae latae muscle (B) Piriformis muscle
(C) Obturator internus muscle (D) Quadratus femoris muscle

39. The 'greater sciatic notch' is located on which of the following bones?
(A) Ilium (B) Ischium (C) Pubis (D) Femur

40. Which of the following muscles has a tendon that does not form part of the 'pes anserinus'?
(A) Vastus medialis muscle (B) Sartorius muscle
(C) Gracilis muscle (D) Semitendinosus muscle

41. Which of the following muscles does not belong to 'two-joint muscle'?
(A) Sartorius muscle (B) Gracilis muscle
(C) Adductor magnus muscle (D) Semimembranosus muscle

42. Which of the following muscles could stabilize the knee joint?
(A) Plantaris muscle (B) Tibialis posterior muscle
(C) Soleus muscle (D) Popliteus muscle

43. Which of the following muscles' tendon does not form together the 'calcaneal tendon'?
(A) Gastrocnemius muscle (B) Soleus muscle
(C) Plantaris muscle (D) Popliteus muscle

44. The medial and lateral malleoli articulate with which of the following bones?
(A) Calcaneus (B) Talus (C) Navicular (D) Cuboid

45. Which of the following intrinsic muscles in the sole of foot has the structure of transverse head and oblique head?
(A) Abductor hallucis muscle (B) Quadratus plantae muscle
(C) Adductor hallucis muscle (D) Flexor hallucis brevis muscle

46. Two flat bones are joined by short, collagenous fibers and there is little movement. How would you classify the joint?
(A) Synchondrosis (B) Suture (C) Gomphosis (D) Symphysis

47. Person raises their chin to look at a plane flying overhead. This action is
(A) abduction of the neck
(B) elevation of the mandible
(C) extension of the neck
(D) dorsiflexion

48. Which joint has a meniscus?
(A) Hip (B) Elbow (C) Intervertebral (D) Temporomandibular

Ans（申覆後結果）

1-5	CDCBB	4送分
6-10	BBDAB	
11-15	BABBB	
16-20	BBBDB	20送分
21-25	BcBAB	
26-30	Ac(A/C)BD	28 A、C皆給分
31-35	CCBDC	
36-40	ACC(A/B)A	39 A.B皆給分
41-45	CDDBC	
46-48	BCD	46送分

中國醫藥大學 111 學年度第 1 學期 期中 考試試卷

☑電腦卡作答 、 試題：☑收回 ☐不收回

科目	命題教師	考試時間	系級	學號	姓名	評分
解剖學(B)	授課老師	50 分鐘				

注意：請用正楷填寫學號及姓名，否則無從查考，該科以零分計。 （本試題共 8 頁）

1. 下列那一構造源自輸尿管芽(ureteric bud) 的發育?
(A)集尿管 (collecting duct)
(B)亨利氏環 (loop of Henel)
(C)腎絲球 (glomerulus)
(D)遠曲小管 (distal convoluted tubules)

2. 中腎(mesonephros)在胚胎發育第幾週開始分化?
(A) 4th week
(B) 5th week
(C) 8th week
(D) 2th month

3. 胚胎發育時，髓質索(medullary sex cord)會分化形成:
(A)濾泡細胞 (follicular cells)
(B) Leydig 間質細胞 (Leydig cells)
(C)副睪 (epididymis)
(D)曲細精管 (seminiferous tubule)

4. 前列腺(prostatic gland)是由下列何者分化形成?
(A)輸尿管芽 (ureteric bud)
(B)中腎管 (mesonephric duct)
(C)中腎旁管 (paramesonephric duct)
(D)泌尿生殖竇 (urogenital sinus)

5. 下列何者分泌穆勒氏抑制物(Müllerian inhibiting substance, MIS）?
(A)濾泡細胞 (follicular cell)
(B)Sertoli 細胞 (Sertoli cell)
(C)Leydig 細胞 (Leydig cell)
(D)原始生殖細胞 (primordial germ cell)

6. 下列何者與大陰唇(Labia major)同源?
(A)陰莖 (penis)
(B)陰莖尿道 (penile urethra)
(C)陰囊 (scrotum)
(D)前列腺 (prostate gland)

7. 下列何者源自於體腔上皮層(coelomic epithelium)?
(A)Leydig 細胞 (Leydig cell)

(B)副睪 (epididymis)

(C)輸精管 (ductus deferens)

(D)濾泡細胞 (follicular cells)

8.下列關於女性子宮管(uterine canal)的胚胎發育敘述，何者『錯誤』？

(A)與泌尿生殖竇(urogenital sinus)銜接

(B)由中腎旁管(paramesonephric duct)形成

(C)在外陰部形成處女膜(hymen)

(D)陰道穹窿(vaginal fornix)由它發育發育形成

9. 上肢的主軸動脈(Axis arteries)源自下列何者?

(A)第五對頸節間動脈 (5th cervical intersegmental artery)

(B)第七對頸節間動脈 (7th cervical intersegmental artery)

(C)第五對腰節間動脈 (5th lumbar intersegmental artery)

(D)第六對主動脈弓 (6th aortic arch)

10. 下列何結構是由右靜脈瓣(right venous valve)發育形成的?

(A)第一中隔 (septum primum)

(B)主動脈半月瓣 (aortic semilunar valve)

(C)冠狀竇瓣膜 (valve of coronary sinus)

(D)假中膈 (septum spurium)

11. 下列何者源自於胚胎期上主靜脈(supracardinal vein)的發育?

(A)頭臂靜脈 (brachiocephalic vein)

(B)右腎靜脈 (right renal vein)

(C)下腔靜脈 (inferior vena cava)

(D)奇靜脈 (azygos vein)

12. 正常情況下，心環(cardiac loop)在胚胎發育的何時完成?

(A)day 23

(B)day 27

(C)day 28

(D)day 32

13. 左生殖腺靜脈(left gonadal vein) 是由下列何者發育形成?

The left gonadal vein derive from:

(A)左上主靜脈 (left supracardinal vein)

(B)卵黃囊靜脈 (vitelline vein)

(C)左下主靜脈 (left subcardinal vein)

(D)左右下主靜脈吻合(right and left subcardinal vein anastomosis)

14. 下列何者來自胚胎期的左竇角(left sinus horn）的發育?

(A)冠狀竇 (coronary sinus)

(B)靜脈竇 (sinus venarum)

(C)左肺靜脈 (left pulmonary vein)
(D)上腔靜脈 (superior vena cava)

15. 下列何者在胚胎發育第 5 週時閉鎖消失?
(A)右臍靜脈(right umbilical vein)
(B)左總主靜脈(left common cardinal vein)
(C)右卵黃囊靜脈(right vitelline vein)
(D)左臍靜脈(left umbilical vein)

16. 卵圓孔瓣膜(valve of foramen ovale)由下列何構造所形成？
(A)第一中隔 (septum primum)
(B)第二中隔 (septum secundum)
(C)假中膈 (septum spurium)
(D)主動脈肺動脈幹中隔 (aorticopulmonary septum)

17. 下列何者來自胚胎期第四主動脈弓(fourth aortic arch)的發育?
(A)舌骨動脈 (hyoid artery)
(B)總頸動脈 (common carotid artery)
(C)左鎖骨下動脈 (left subclavian artery)
(D)肺動脈 (pulmonary artery)

18. 胚胎期之下腔靜脈肝段(hepatic segment of inferior vena cava)是由何構造所形成?
(A)右上主靜脈 (right supracardinal vein)
(B)左右下主靜脈吻合(right and left subcardinal vein anastomosis)
(C)右臍靜脈 (right umbilical vein)
(D)右卵黃囊靜脈 (right vitelline vein)

19. The base of the occipital bone will be derived from
(A) Parachordal cartilage (B) Prechordal cartilage?
(C) Hypophyseal cartilage (D) Otic capsule

20. Where is Reichert's cartilage located on the pharyngeal arch?
(A) first (B) Second (C) Third (D) Fourth

21. In the process of face formation or construction, the first to come into being is the:
(A) orbital ridge (B) upper jaw
(C) lower jaw (D) ears

22.As shown in the right figure. The child is scheduled for surgical removal of the mass. During surgery, the mass is found to be connected to a tract that courses superiorly. The tract is most likely to be connected to which of the following structures?

(A) foramen cecum of the tongue (B) lingual tonsil
(C) sublingual papilla (D) palatine tonsils

23. The secondary palate is formed by:
(A) fusion of palatal shelves (B) anterior growth of the primary palate
(C) mesenchyme of the first arch (D) the oropharyngeal membrane

24.Which cranial nerve innervate the muscle of the third pharyngeal arch?
(A) Facial nerve (B) Vague nerve
(C) Trigeminal nerve (D) Glossopharyngeal nerve

25. Which of the following is **NOT** developed from the neural crest?
(A) Dorsal root ganglion (B) Cranial ganglion
(C) Microglial cell (D) Melanocytes

26. The alar plate neuron order in the metencephalon from lateral to medial are:
(A) SSA, GVA,GSA (B) GVA, GSA, SVA
(C) SSA, SVA, GSA (D) GSA, SVA, GVA

27. Which of the following statement about the development of the nervous system is **Incorrect**?
(A) the neural folds are composed of neuroepithelial cells
(B) sensory nuclei in the spinal cord lie ventral to the sulcus limitans
(C) the neural tube maintains temporary contact with the amniotic cavity via neuropores
(D) neuroepithelial cells give rise to both neuroblasts and glioblasts

28. From which embryonic layer does the dura mater arise?
(A) neural crest (B) paraxial mesoderm (C) lateral ectoderm (D) endoderm

29. GVE fibers are found in all of the following locations EXCEPT:
(A) C1-C7 (B) T1-L2 (C) S2-S4 (D) Brainstem

30.Which of the following statement about the development of the cerebellum is **Incorrect**?
(A) The cerebellum is derived from the alar plates of the metencephalon
(B) The rudiment of the cerebellum is first recognizable as cerebellar plates
(C) After the appearance of the external granule layer in the third month, it will exist permanently
(D) Some of the inwardly migrating neurons continue their migration ventrally to form the deep cerebellar nuclei

31. Which stage of the development of the lung will continue into postnatal life?
(A) Canalicular phase (B) Alveolar stage
(C) Saccular phase (D) Pseudoglandular stage

32. Which of the following is NOT a part of the developing pancreas?
(A) Dorsal bud (B) Ventral bud
(C) Ventral bile duct (D) Main pancreatic duct

33. The midgut begins with ____ and ends with ____.
(A) 1/2 jejunum; 2/3 transverse colon (B) 1/2 ileum; 2/3 sigmoid colon
(C) 1/2 duodenum; 2/3 transverse colon (D) 1/2 jejunum; 2/3 rectum

34. The first stomach rotation causes the ____ and ____ vagus nerves to become the ____and ____ vagal trunks, respectively
(A) Left; Right; Superior; Inferior (B) Right; Left; Lateral; Medial
(C) Left; Right; Right; Left (D) Left; Right; Anterior; Posterior

35. The mesentery is a ____ layer of peritoneum. The artery associated with the midgut region is called the ____.
(A) Single; Superior mesenteric (B) Single; Inferior mesenteric
(C) Double; Superior mesenteric (D) Double; Inferior mesenteric

36. Which of the following structures is NOT a derivative of ventral mesentery and is attached to the liver?

(A) greater omentum (B) Falciform ligament

(C) Coronary ligaments (D) Right and left triangular ligaments

37. The main difference between neurons and neuroglia is:
(A) Astrocyte is found only in the central nervous system
(B) Mature neurons do not normally divide; neuroglia do
(C) Neurons are more numerous than neuroglia
(D) Neurons are generally smaller than neuroglia

38. Which of the following types of fibers is/are NOT contained in the facial nerve?
(A) Motor information (B) Parasympathetic preganglionic
(C) Special sensory from taste buds (D) General sensory from the facial skin

39. Which of the following statements about the cranial nerve is **Correct**?
(A) The four pairs of cranial nerves CN III, V, VII, and X contain parasympathetic preganglionic fibers
(B) The four pairs of cranial nerves CN II, III, IV, VI mainly control the movement of eyeball muscles
(C) The CN VII cranial nerve controls the sensation of the tympanic membrane
(D) The CN IX cranial nerve controls the most organs in the body and is also the longest.

40. Which of the following is the **Correct** combination of cranial nerves?
(A) CN V --- ciliary ganglion ---ciliary muscle
(B) CN VII --- pterygopalatine ganglion --- lacrimal gland
(C) CN IX --- submandibular ganglion --- parotid gland
(D) CN X --- otic ganglion --- submandibular and sublingual glands

41. Where can see gray ramus communicans?
(A) between the spinal nerve and spinal cord
(B) between sympathetic ganglion and sympathetic ganglion
(C) between the spinal nerve and sympathetic ganglion
(D) the gray matter inside the spinal cord

42. The source of preganglionic nerves of celiac ganglion mainly comes from:
(A) Sympathetic chain (B) Gray communication ramus
(C) Great splanchnic nerve (D) Intercostals nerve

43. Which of the following descriptions is CORRECT?
A. Segmentation allows for the propulsion of contents beginning in the pharynx and ending in the anus.
B. The tongue attaches to the floor of the mouth with a web of tissue called the labial frenulum.
C. Dentin is capped by a crown made of highly mineralized and protective enamel.
D. The parotid gland produces the most saliva in the unstimulated state.

44. _____ is a semi-fluid pulp formed in the stomach made of partly digested food and the secretions of the gastrointestinal tract.
A. Chyle
B. Chyme
C. Bolus
D. Bile

45. Which of the following is WRONG?
A. Hepatopancreatic ampulla is a located at the site of the confluence of the common bile duct and pancreatic duct.
B. Unlike the gastric folds in the stomach, plicae circularis are not obliterated when the intestine is distended.
C. The fat-soluble vitamins are absorbed by the lacteals.

D. Epiploic appendages are three bands of longitudinal smooth muscle on the colon surface

46. The porta hepatis

A. is in the superior surface of the liver.

B. encompasses the portal triad.

C. connects the liver to the undersurface of the diaphragm.

D. separates the left and caudate lobes.

47. The _____ is a small, tube-like structure formed where the _____ and the _____ join.

A. common bile duct; common hepatic duct; cystic duct

B. common hepatic duct; common bile duct; cystic duct

C. common hepatic duct; common bile duct; pancreatic duct

D. common bile duct; common hepatic duct; pancreatic duct

48. Meissner's plexus is a neural network located

A. between two layers of the muscularis externa.

B. within the submucosa.

C. in the lamina propria

D. in the serosa

49. Juxtamedullary nephrons

A. have relatively short loops of Henle.

B. constitute the majority of all nephrons.

C. are located almost within the cortex.

D. have efferent arterioles that give rise to the vasa recta.

50. Which of the following is WRONG?

A. When ADH is present, the collecting duct becomes permeable to water

B. The lumen of the proximal convoluted tubule has many microvilli

C. The male urethra can be divided anatomically into three parts, including prostatic, membranous, and spongy urethras.

D. Slit diaphragms are fused basal laminae of the endothelium and the podocyte epithelium.

51. Granular cells

A. function as chemoreceptors for monitoring the solute concentration.

B. are also known as juxtaglomerular cells

C. signal macula densa to secrete renin.

D. mainly regulate the glomerular blood flow.

52. 下列哪一喉部軟骨位於環狀軟骨(cricoids cartilage)前上方

(A) epiglottis (B) arytenoid (C) thyroid (D) tracheal

53. 下列喉部肌肉，何者於喘氣時為主要的運動肌肉?

(A) transverse arytenoid (B) posterior cricoarytenoid

(C) lateral cricoarytenoid (D) cricothyroid

54. 發聲時，下列何者產生的震動最大?

(A) quadrangular membrane (B) cuneiform tubercle

(C) corniculate tubercle (D) conus elasticus

55. From which of the following structures is the cremaster fascia derived?

(A) Superficial fascia of the scrotum
(B) Transversalis fascia
(C) External oblique aponeurosis
(D) Internal oblique aponeurosis

56. Which of the following structure is not located within the spermatic cord?
(A) Ductus deferens
(B) Dartos muscle
(C) Pampiniform venous plexus
(D) The branch of genitofemoral nerve

57. Where is the duct opening of the bulbourethral gland located along the urethra?
(A) Preprostatic part
(B) Prostatic urethra
(C) Intermediate part
(D) Spongy urethra

58. Which of the following statements is incorrect?
(A) The ovarian ligament connects with the uterus.
(B) The broad ligament of uterus is a double-layered peritoneal structure.
(C) The round ligament of uterus is located within the broad ligament of uterus
(D) The suspensory ligament of ovary is responsible for the anteverted position of the uterus (upper part of the uterus is leaned forward towards the bladder).

59. Please arrange the structures of the uterus in the order from top to bottom: ① body of uterus, ② cervix of uterus, ③ fundus of uterus, ④ isthmus of uterus.
(A) ①②③④
(B) ②④①③
(C) ③①④②
(D) ④②①③

60. During the menstrual cycle, which phase is primarily stimulated by estrogens?
(A) Preovulatory phase
(B) Postovulatory phase
(C) Menstrual phase
(D) Secretory phase

61. Where is the most probable surface projection location of the cardiac apex on the body?
(A) Outside the midclavicular line of the 4th intercostal space
(B) At the left nipple
(C) Lies in the 5th intercostal space at the midclavicular line
(D) Outside the anterior axillary line of the 6th intercostal space

62. Which structure separates the group of arteries, including the ascending aorta and pulmonary trunk, from the group of veins, including the pulmonary vein and superior vena cava, above the heart?
(A) Coronary sinus
(B) Transverse pericardial sinus
(C) Oblique pericardial sinus

(D) Sternal surface of pericardial cavity

63. The septomarginal trabecula connects the interventricular septum to which of the following structures?

(A) Anterior papillary muscle of left ventricle

(B) Posterior papillary muscle of left ventricle

(C) Posterior papillary muscle of right ventricle

(D) Anterior papillary muscle of right ventricle

64. Which blood vessel runs along the posterior interventricular sulcus alongside the posterior interventricular artery?

(A) Great cardiac vein

(B) Middle cardiac vein

(C) Small cardiac vein

(D) Posterior cardiac vein

65. Which of the following intercostal veins does not typically drain into the azygos vein system?

(A) Left 1st intercostal vein (B) Left 8th intercostal vein

(C) Right 3rd intercostal vein (D) Right 10th intercostal vein

66. Which of the following is the main drainage site for the cardiac veins of the heart?

(A) Right ventricle (B) Coronary sinus (C) Superior vena cava (D) Left atrium

1~5	A	A	D	D	B
6~10	C	D	C	B	C
11~15	D	C	C	A	A
16~20	A	C(送分)	D	A	B
21~25	C	A	A	D	C
26~30	D	B	A or B	A	C
31~35	B	C(送分)	C	D	C
36~40	A(送分)	B	D	C	B
41~45	C	C	C	B	D
46~50	B	A	B	D	D
51~55	B	A or C	B	D	D
56~60	B	D	D	C	A
61~65	C	B	D	B	A
66	B				

中國醫藥大學 111 學年度第 2 學期 期末 考試試卷

☑電腦卡作答、試題：☐收回 ☒不收回

科目	命題教師	考試時間	系級	學號	姓名	評分
解剖學(B)	授課老師	50 分鐘	藥二	110001012	黃柏廷	

注意：請用正楷填寫學號及姓名，否則無從查考，該科以零分計。 （本試題共 5 頁）

1. Which of the following statements of the muscles of the back is CORRECT?
   (A) superficial muscle group consisting of the serratus posterior and splenius capitis m. etc
   (B) intermediate layer of intrinsic muscle group consisting of the iliocostalis, longissimus, and semispinalis m.
   (C) the main action of levatores costorum m. is aid control limb movements
   (D) trapezius m. is innervated by CN XI n.

2. Which of the following statements of the suboccipital region is CORRECT?
   (A) the roof boundary of suboccipital region is spinalis capitis
   (B) greater occipital nerve supply of four muscles in this region
   (C) the content of suboccipital region is vertebral artery
   (D) rectus capitis posterior minor m. has no attachment to the cranium

3. Which of the following statements of the nerve supply of the back muscles is CORRECT?
   (A) serratus posterior m. is innervated by posterior rami of spinal nerves
   (B) latissimus dorsi m. is innervated by dorsal scapular nerve
   (C) rhomboid minor m. is innervated by thoracodorsal nerve
   (D) rotatores m. is innervated by dorsal rami of spinal nerves

4. Which of the following statements of the joints of the vertebral column is CORRECT?
   (A) alar lig. is continuation of the posterior longitudinal lig.
   (B) ligamentum flavum runs between laminae within the vertebral canal
   (C) anulus fibrosus is an inner fibrous part of the IV disc
   (D) rotation of upper trunk primarily occurs in lumbar vertebral column

5. Which of the following statements of the contents of the vertebral canal is CORRECT?
   (A) the epidural space is a naturally existing gap located between the arachnoid and dura mater
   (B) the denticulate ligaments are bilateral triangular lateral projections originating from the arachnoid mater
   (C) subdural space contains CSF
   (D) the dura mater is a tough, fibrous meninges

6. If the intervertebral disc between the 3th and 4th thoracic vertebrae herniates, it will exert pressure on the:
   (A) 3th thoracic nerve root
   (B) 4th thoracic nerve root
   (C) 5th thoracic nerve root
   (D) 6th thoracic nerve root

7. Which of the following joints allows for the movement of the head in a nodding motion to indicate "YES"?

C

(A) atlanto-axial joint
(B) costorvertebral joint
(C) atlanto-occipital joint
(D) zygapophysial joints

8. In adults, the spinal cord terminates at the lowermost level known as:

(A) the coccyx
C (B) S1 to 3
(C) L1 to 3
(D)T2 to 3

9. What structures can be found within the suboccipital triangle?

A (A) suboccipital n.
(B) occiptial a.
(C) suboccipital a.
(D) greater occipital n.

10. Which muscles receive innervation from the spinal nerve C1?

(A) obliquus capitis inferior m.
A (B) semispinalis m.
(C) spinalis m.
(D) intertransverse m.

11. Which one not enclose with throacolumbar fascia of the back?

(A) multifidus ✓
C (B) levatores costorum m. ✓
(C) serratus posterior inferior m.
(D) interspinal m. ✓

12. Which of the following statements about intervertebral discs is CORRECT?

(A) are composed mainly of cartilage.
(B) are found only in the lumbar region.
C (C) provide flexibility and shock absorption between adjacent vertebrae.
(D) are primarily responsible for connecting the spinal nerves. ✗

13.關於 brachial plexus 的敘述何者為誤?.

(A) brachial plexus 的 root 部分位在 anterior scalene 之後方
A (B) long thoracic nerve 由第 5,6,7 頸神經根構成 ✓
(C) axillary nerve 由第 6,7 頸神經根構成
(D) axillary nerve 支配 deltoid m. ✓

14.下列何者非上肢淺層靜脈?

C (A) basilic v. (B) cephalic v.
(C) ulnar v. (D) 以上皆為淺層靜脈

15.suprascapular n.源自 brachial plexus?

C (A) posterior cord (B) inferior trunk

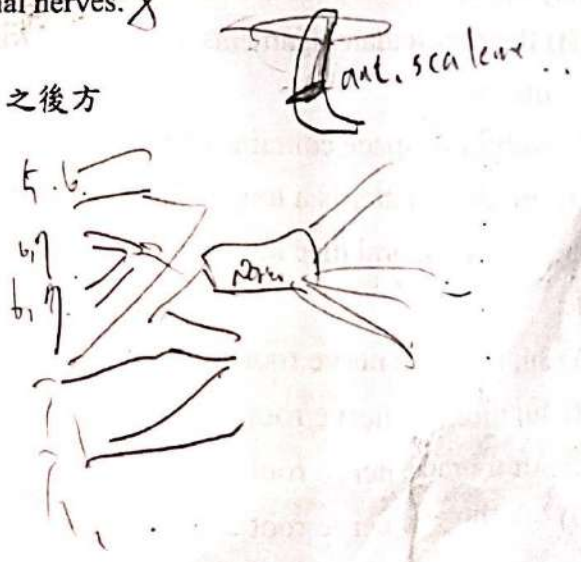

(C) superior trunk (D) lateral cord

16.位於前胸壁與 long thoracic n. 伴行?

(A) thoracoacromial a. (B) internal thoracic a.

(C) superior thoracic a. (D) lateral thoracic a.

17.下列何者直接穿越 pronator teres m.?

(A) radial n. (B) ulnar n.

(C) median n. (D) musculocutaneous n.

18. 自上臂後方之 quadrangular space 內穿出的神經,支配下列何者?

(A) rhomboid major m. (B) rhomboid minor m.

(C) teres major m. (D) teres minor m.

19. 下列何者不受 ulnar n.?

(A) adductor pollicis m. (B) palmar interosseous m.

(C) flexor pollicis brevis m. (D) palmaris brevis m.

20. 下列何者同時供應腋部的 medial and anterior wall?

(A) subscapular artery (B) lateral thoracic artery

(C) superior thoracic artery (D)neither

21. inferior lateral cutaneous nerve of arm是誰的分支？

(A) axillary nerve (B) radial nerve

(C) median nerve (D)musculocutaneous nerve。

22. Supinator m. innervated by?

(A) posterior interosseous nerve (B) anterior interosseous nerve

(C) ulnar n. (D) median nerve

23. medial epicondyle of humerus骨折最可能傷害下列何者?

(A) radial nerve (B) suprascapular nerve

(C) musculocutaneous nerve (D) ulnar nerve

24. 下列哪條肌肉不是正中神經(median nerve)支配的?

(A) Pronator teres (B) Brachioradialis

(C) Flexor digitorum superficialis (D)Palmaris longus

25. Considering the respiratory muscles and nerves, which of the following statements is **incorrect**?

(A) The diaphragm is innervated by the phrenic nerve.

(B) The intercostal muscles are innervated by the lateral pectoral nerve.

(C) Contraction of the smooth muscles in the trachea is caused by stimulation of the vagus nerve.

(D) Stimulation of the sympathetic nerve indirectly increases the respiratory frequency.

26. Which of the following statements of intercostal spaces is correct?

(A) There are 11 intercostal spaces.

(B) Intercostal nerves go through the space between the external and internal intercostal muscles.

(C) The 5th intercostal space refers to the space between the 4th and 5th ribs.

(D) Branches of the long thoracic nerve enter the intercostal spaces.

27. The pain sensation from the parietal layer of the serous pericardium is transmitted by which of the following?

(A) Sympathetic trunk (B) Vagus nerve
(C) Phrenic nerve (D) Intercostal nerves

28. The intercostal nerves go along the "inside profile" of which of the following structures?
(A) External intercostal muscle
(B) Internal intercostal muscle
(C) Innermost intercostal muscle
(D) Transversus thoracic muscle

29. Which structure does the lingula of the lung belong to?
(A) Upper lobe of the right lung
(B) Lower lobe of the right lung
(C) Upper lobe of the left lung
(D) Lower lobe of the left lung

30. Which of the following statements is correct?
(A) Left internal thoracic vein returns to left branchialcephalic vein.
(B) Superior intercostal artery belongs to the branch of thoracic aorta.
(C) The right vagus nerve gives rise to the right recurrent laryngeal nerve, which branches off at the lower edge of the aortic arch.
(D) The esophagus plexus in front of the esophagus receives parasympathetic fibers from the right vagus nerve

31. Gas exchange can occur in which of the following locations?
① Bronchi ② Alveoli ③ Terminal bronchioles ④ Respiratory bronchioles
(A) ①, ③, and ④
(B) ②, ③, and ④
(C) Only ① and ②
(D) Only ② and ④

32. Which of the following is not responsible for the blood supply to the mammary gland?
(A) Lateral thoracic artery
(B) Intercostal artery
(C) Subcostal artery
(D) Internal thoracic artery

33. In standing adult males, the horizontal fissure of the right lung is located approximately near which rib?
(A) 2nd rib
(B) 4th rib
(C) 6th rib
(D) 8th rib

34. The thymus is primarily located in which of the following regions?
(A) Anterior inferior mediastinum
(B) Posterior inferior mediastinum
(C) Middle inferior mediastinum
(D) Superior mediastinum

35. The *ligamentum arteriosum* is located between which two blood vessels?

(A) Aorta and pulmonary artery

(B) Aorta and superior vena cava

(C) Aorta and pulmonary vein

(D) Pulmonary artery and superior vena cava

36. Through which of the following structures does the vagus nerve enter the abdominal cavity?

(A) Caval opening

(B) Aortic hiatus

(C) Esophageal hiatus

(D) Inferior to the medial arcuate ligament

37. Which of the following statements about the sternal angle is correct?

(A) Its horizontal position corresponds to the space between the 4th and 5th thoracic vertebrae.

(B) It articulates with the 1st rib on both sides.

(C) It is a synovial joint in youth but undergoes ossification in middle age.

(D) It marks the junction between the body of the sternum and the xiphoid process.

38. Which of the following statements about false ribs is correct?

(A) They do not have a costal groove.

(B) They have costotransverse joints as points of attachment.

(C) Their anterior ends are directly attached to the sternum by cartilage.

(D) Ribs 7 to 12 are false ribs.

39. Which of the following statements of the lungs is correct?

(A) The left lung has three lobes, while the right lung has two lobes.

(B) The hilum of the left lung is located between the descending aorta and the esophagus.

(C) The horizontal fissure of the right lung approximately corresponds to the lower border of the fourth rib.

(D) The hilum of the right lung is located between the esophagus and the azygos vein.

DCDBD
ACCAA
CCCCC
DCDCB
BADBB
ACBCA
DCBDA
CABC