Processing and Segmentation of Medical Images

March 2026

The Clinical Problem and the Dataset

Pediatric Pneumonia

- 14% of deaths in children under 5
- Diagnosis relies on chest X-ray
- Shortage of specialists in primary care

PneumoniaMNIST

- 5,856 pediatric X-rays (28×28 px)
- Guangzhou Women and Children's Medical Center
- 74.2% pneumonia / 25.8% normal

Yang et al., 2023; Kermany et al., 2018

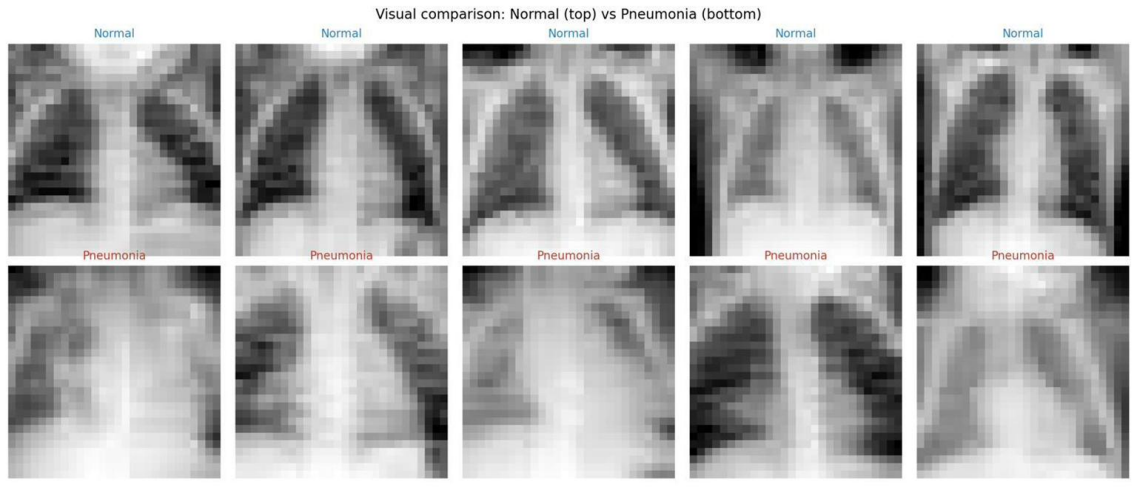

The 74/26 imbalance is not a defect: it reflects the actual prevalence of a symptomatic cohort (verification bias). Children arrive with clinical suspicion, hence the higher proportion of positives.

Image Format Selection

Format	Compression	Loss	Medical Imaging
JPEG	Lossy	Yes	Not recommended
PNG	Lossless	No	Suitable
TIFF	Lossless	No	Optimal

JPEG introduces block artifacts that can simulate or mask real radiological findings. The choice of format is not trivial in medical imaging.

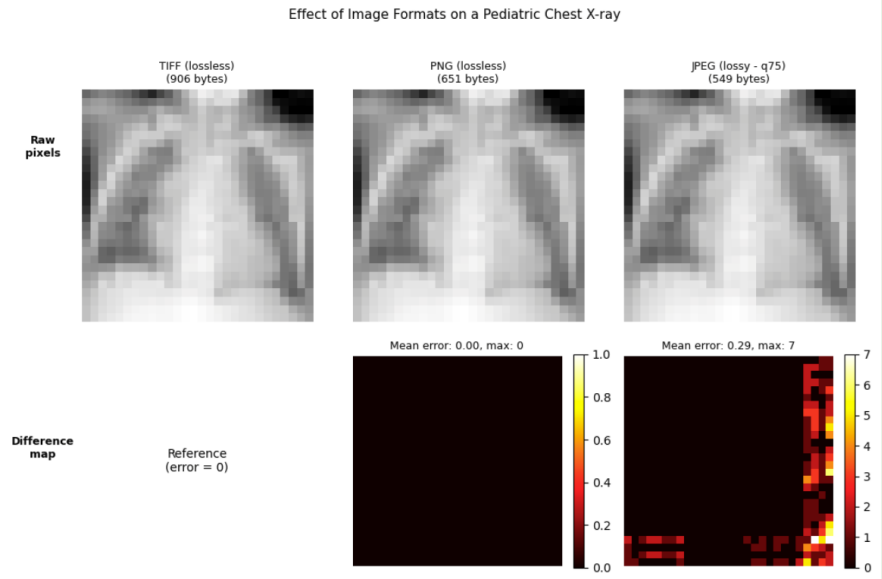

TIFF is the optimal format for medical imaging. We use PNG because PneumoniaMNIST distributes in uint8 (256 gray levels), a range that PNG preserves completely without loss.

Preprocessing: Filtering Before Segmentation

Why filter? Noise distorts histograms (Otsu), generates false edges (Canny), and creates artificial regions (Watershed).

Gaussian

Low-pass smoothing

Convolution with Gaussian kernel. Attenuates high frequencies (general noise) without preserving edges.

Median

Nonlinear order filter

Replaces each pixel with the median of its neighborhood. Removes impulse noise (salt and pepper) while preserving edges.

Global Equal.

Cumulative histogram

Redistributes intensities to span the full range [0, 255]. Improves global contrast.

CLAHE

Adaptive local contrast

Region-based equalization with clipping. Best balance between contrast enhancement and local detail.

▶ **We selected CLAHE for segmentation: best balance between contrast enhancement and local detail preservation.**

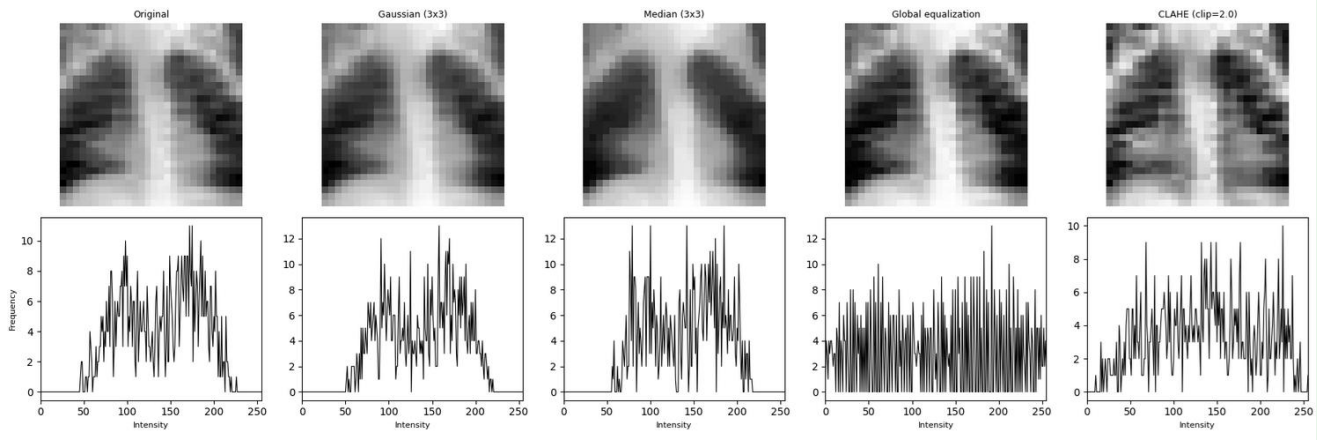

Image + histogram for each filter — Case 2 (moderate pneumonia). CLAHE provides the greatest visible structural detail.

Segmentation: Otsu Thresholding

Otsu automatically selects the threshold that maximizes the inter-class variance (background / object). Assumes a bimodal histogram.

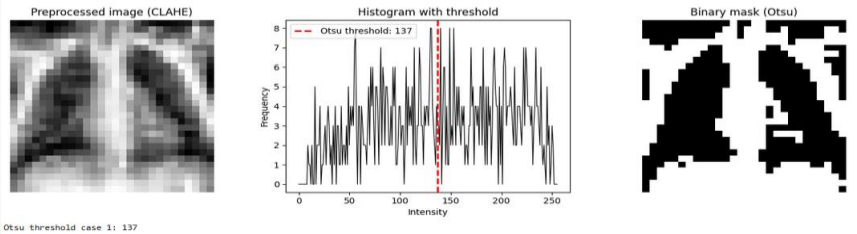

Case 1: Normal | **Threshold: 137** — Recognizable cardiac silhouette and lung fields

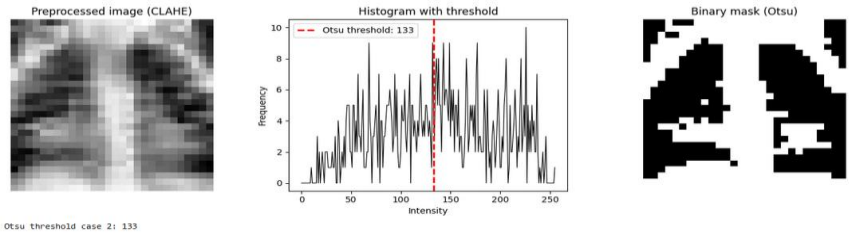

Case 2: Moderate | **Threshold: 133** — Opacity in right lung field differentiated

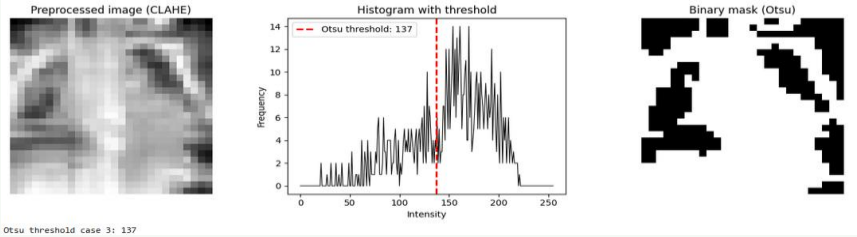

Case 3: Intense | **Threshold: 137** — Expanded silhouette, reduced lung fields

Interpretation

Otsu maximizes inter-class variance. All three cases produce similar thresholds (137, 133, 137) because CLAHE homogenized the distributions. The masks are useful for delineating structures, but do not constitute a diagnosis.

Otsu does not distinguish anatomy from pathology: it separates light pixels from dark ones. The masks reflect structures but do not constitute a diagnosis. The homogenization of the image in Case 3 (severe pneumonia) hinders class separation.

Edge Detection: Sobel and Canny

Sobel

- Gradient in X and Y; magnitude as edge strength
- Sensitive to noise: computes gradients without prior smoothing
- Result: edge map showing tissue density transitions

Canny

- 4 stages: Gaussian smoothing → gradient → non-max suppression → hysteresis thresholding
- Two thresholds used: T_L=30, T_H=100
- More robust than Sobel: eliminates weak edges not connected to strong ones



At 28×28 px edges accumulate without clear structure. The limitation is resolution, not the algorithm.

Segmentation: Watershed Pipeline

9-Step Pipeline (from CLAHE)

1. Original image
2. Otsu thresholding
3. Morphological opening
4. Sure background (dilation)
5. Distance transform
6. Sure foreground
7. Unknown region
8. Connected components (markers)
9. Watershed segmentation

Parameters

- Sure foreground threshold: 0.5 → **0.3** (for 28×28 px)

Regions Detected

Normal: **7** · Moderate: **8** · Severe: **3**

More severe pneumonia → fewer regions: extensive opacity homogenizes the image, reducing internal contrast

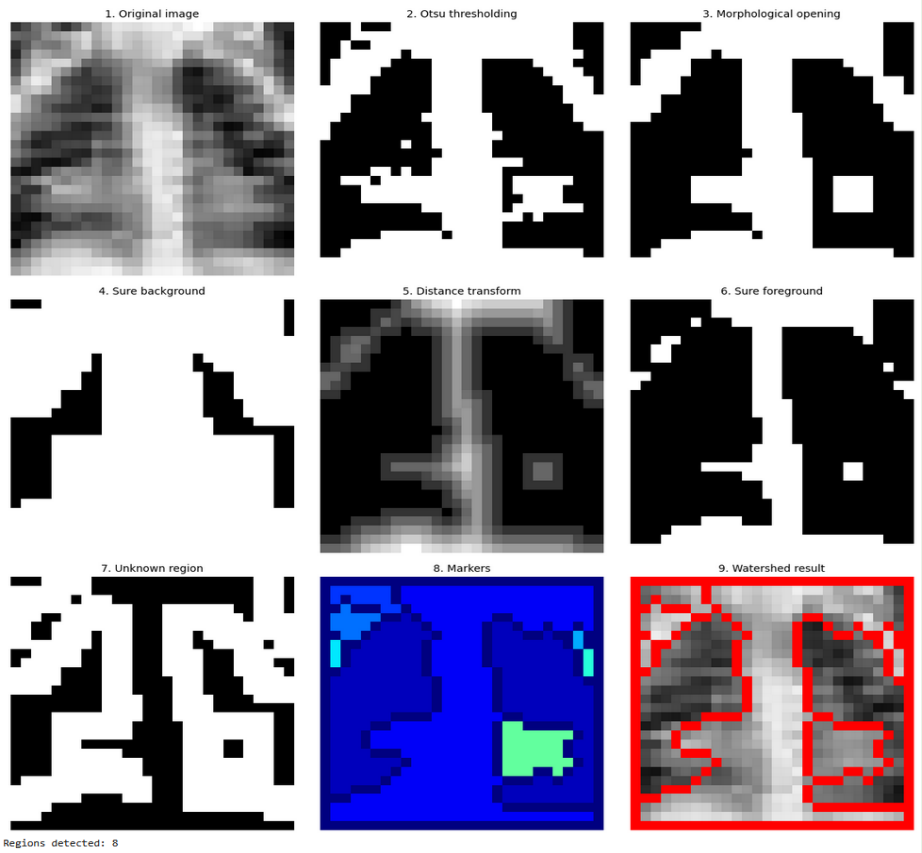

Watershed has no anatomical knowledge: it segments all contrast regions it finds. Without reference masks, the result is exploratory, not diagnostic.

Conclusions and Future Outlook

Where it works

- Otsu delineates anatomical structures when sufficient contrast exists
- Watershed separates regions with differentiated edges
- The pipeline is coherent and reproducible

Limitations

- Extensive opacities homogenize the image
- 28x28 limits all algorithms
- Without anatomical knowledge, no diagnosis is possible

Future Horizon

MedSAM	Segmentation with deep learning (1.5M image-mask pairs)	*Ma et al., 2024*
Federated Learning	Train across hospitals without sharing patient data	*Rieke et al., 2020*
Interpretability	The physician needs to understand why the algorithm flags a region	*Rudin, 2019*

References

[1] **Kermany, D. S., et al. (2018).** *Identifying medical diagnoses and treatable diseases by image-based deep learning.* Cell, 172(5), 1122-1131.
https://doi.org/10.1016/j.cell.2018.02.010

[2] **Ma, J., et al. (2024).** *Segment anything in medical images.* Nature Communications, 15, 654.
https://doi.org/10.1038/s41467-024-44824-z

[3] **Rieke, N., et al. (2020).** *The future of digital health with federated learning.* npj Digital Medicine, 3, 119.
https://doi.org/10.1038/s41746-020-00323-1

[4] **Rudin, C. (2019).** *Stop explaining black box machine learning models for high stakes decisions and use interpretable models instead.* Nature Machine Intelligence, 1, 206-215.
https://doi.org/10.1038/s42256-019-0048-x

[5] **UNICEF. (2023).** *Pneumonia in children.*
https://data.unicef.org/topic/child-health/pneumonia/

[6] **Yang, J., et al. (2023).** *MedMNIST v2: A large-scale lightweight benchmark for 2D and 3D biomedical image classification.* Scientific Data, 10(1), 41.
https://doi.org/10.1038/s41597-022-01721-8