Note: This copy is for your personal non-commercial use only. To order presentation-ready copies for distribution to your colleagues or clients, contact us at *www.rsna.org/rsnarights*.

Left Atrial Appendage Thrombi in Stroke Patients: Detection with Two-Phase Cardiac CT Angiography versus Transesophageal Echocardiography[1]

Jin Hur, MD
Young Jin Kim, MD
Hye-Jeong Lee, MD
Jong-Won Ha, MD
Ji Hoe Heo, MD
Eui-Young Choi, MD
Chi-Young Shim, MD
Tae Hoon Kim, MD
Ji Eun Nam, MD
Kyu Ok Choe, MD
Byoung Wook Choi, MD

Purpose: To assess the diagnostic accuracy of two-phase 64-section cardiac computed tomographic (CT) angiography for detection of left atrial appendage (LAA) thrombi and differentiation between thrombus and circulatory stasis in patients with stroke, with transesophageal echocardiography (TEE) as the reference standard.

Materials and Methods: This study was institutional review board approved, and all patients gave written informed consent. Fifty-five consecutive patients (36 men, 19 women; mean age, 61 years) who had recently experienced a stroke, had high-risk factors for thrombus formation, and underwent both two-phase 64-section cardiac CT angiography and TEE up to 5 days apart were examined. Agreement between CT and TEE for detection of thrombus was assessed with κ statistics. For quantitative analysis, the LAA–ascending aorta attenuation ratio (LAA/AA, in Hounsfield units) was measured on early- and late-phase CT images. The significance of differences in CT attenuation measurements were assessed by using the Student *t* test.

Results: A total of 14 thrombi were detected in the 55 patients at TEE. With TEE as the reference standard, the overall sensitivity, specificity, and positive and negative predictive values of cardiac CT angiography for the detection of thrombus in the LAA were 100% (14 of 14 patients), 98% (40 of 41 patients), 93% (14 of 15 patients), and 100% (40 of 40 patients), respectively. Concordance between cardiac CT angiography and TEE for the detection of thrombus in the LAA was high (overall $\kappa = 0.953$). Mean LAA/AA values were significantly different between thrombus (0.29 HU ± 0.12 [standard deviation]) and circulatory stasis (0.85 HU ± 0.12) on late-phase CT images ($P < .001$).

Conclusion: Two-phase 64-section cardiac CT angiography is a noninvasive sensitive modality for detecting LAA thrombi and differentiating thrombus from circulatory stasis in stroke patients.

© RSNA, 2009

[1] From the Department of Radiology, Research Institute of Radiological Science (J.H., Y.J.K., H.J.L., T.H.K., J.E.N., K.O.C., B.W.C.); Division of Cardiology, Yonsei Cardiovascular Center (J.W.H., E.Y.C., C.Y.S.); and Department of Neurology, Severance Hospital (J.H.H.), Yonsei University College of Medicine, 250 Seongsanno, Seodaemun-gu, Seoul 120-752, South Korea. Received May 5, 2008; revision requested August 12; revision received October 13; accepted October 29; final version accepted January 12, 2009. **Address correspondence to** B.W.C. (e-mail: *bchoi@yuhs.ac*).

© RSNA, 2009

Thrombi of the left atrium and left atrial appendage (LAA) are common sources of stroke, and since left atrium and LAA thrombi are treatable causes of embolism, the detection of thrombi may affect patient treatment substantially (1,2).

Although transesophageal echocardiography (TEE) is relatively invasive, it has emerged as the most sensitive method for detecting intracardiac thrombi and is believed to be the single best modality for patients suspected of having intracardiac thrombi (3,4). However, concerns about the cost-effectiveness and invasiveness of TEE have been raised (5).

Computed tomography (CT) is a well-established—but until recently, rarely used—technique for imaging intracardiac thrombi (6–11). At CT, an intracardiac thrombus is depicted as a filling defect. However, spontaneous echo contrast (SEC) caused by slow blood flow during atrial fibrillation, as seen at ultrasonography, also can cause an apparent filling defect on CT images and thereby mimic a thrombus. These pseudo–filling defects seen on CT images represent incomplete mixing of CT contrast material and blood. Therefore, it may be difficult to differentiate between a thrombus and a pseudo–filling defect caused by circulatory stasis with single-phase CT scanning. Previous studies have shown that in addition to thrombi, circulatory stasis can cause a pseudo–filling defect on early-phase CT images and that it is possible to differentiate a thrombus from circulatory stasis with use of late-phase CT images (9–11). Therefore, the purpose of this study was to assess the diagnostic accuracy of two-phase 64-section cardiac CT angiography for the detection of LAA thrombi and the differentiation between a thrombus and circulatory stasis in patients with stroke, with TEE as the reference standard.

Advances in Knowledge

- Compared with transesophageal echocardiography (TEE), two-phase cardiac CT angiography, with a sensitivity of 100% and a specificity of 98%, is useful for detecting left atrial appendage thrombus.
- Two-phase cardiac CT angiography can be used to differentiate thrombus from circulatory stasis, which may cause a pseudo–filling defect on early-phase CT images.

Implication for Patient Care

- Two-phase 64-section cardiac CT angiography may be clinically useful for detecting and ruling out intracardiac thrombus in patients at risk for cardioembolic stroke.

Materials and Methods

Patient Selection

Our institutional review board approved this study, and all participating patients provided written informed consent. From December 2007 to March 2008, 88 consecutive patients who were admitted to our hospital owing to recent stroke (onset within previous 7 days) were prospectively enrolled in the current study. Seventy-eight of these patients underwent TEE because they were suspected of having had a cardioembolic stroke within the previous 2 weeks (mean time, 7.8 days; range, within 5–13 days after initial stroke). TEE was not performed in 10 patients: three patients with decreased consciousness, one patient with findings that indicated impending brain herniation, three patients with poor systemic conditions, two patients with an inserted tracheal tube, and one patient in whom an esophageal transducer could not be introduced. Inclusion criteria based on high-risk factors for thrombus formation were *(a)* continuous atrial fibrillation confirmed at electrocardiography (12,13); *(b)* valve disease assessed at echocardiography (14–16); *(c)* mitral stenosis of at least moderate severity, previous mitral valve surgery (valve replacement or repair), or severe aortic regurgitation; *(d)* left ventricular dysfunction (17), defined as severe systolic dysfunction (ejection fraction < 30%) or cardiomyopathy with moderate systolic dysfunction (ejection fraction < 40%); and/or *(e)* history of atrial fibrillation documented with 12-lead electrocardiography before the index TEE examination (18). Twenty-three patients were excluded: 19 patients did not meet the inclusion criteria, two were allergic to the contrast agent, one had renal dysfunction, and one did not provide informed consent.

The remaining 55 patients with high-risk factors for thrombus formation were included in the study. All patients had more than one risk factor for coronary artery disease (old age, hypertension, diabetes mellitus, hypercholesterolemia, history of current smoking). All examinations were performed within an interval of 5 days (mean, 2.5 days) to determine the source of the potential cardioembolism. We included patients with all stroke subtypes—of both the anterior and the posterior circulation. All patients underwent brain CT or brain magnetic resonance imaging to characterize and confirm the stroke type and to exclude hemorrhage and other abnormalities. The patients were 36 men (mean age, 62 years; age range, 37–85 years) and 19 women (mean age, 60 years; age range, 43–82 years). The overall mean age was 61 years. There was no significant difference in age between the male

Published online before print
10.1148/radiol.2513090794

Radiology 2009; 251:683–690

Abbreviations:
LAA = left atrial appendage
LAA/AA = LAA–ascending aorta attenuation ratio
LAA/AA_E = early-phase LAA/AA
LAA/AA_L = late-phase LAA/AA
SEC = spontaneous echo contrast
TEE = transesophageal echocardiography

Author contributions:
Guarantors of integrity of entire study, J.H., Y.J.K., E.Y.C., K.O.C., B.W.C.; study concepts/study design or data acquisition or data analysis/interpretation, all authors; manuscript drafting or manuscript revision for important intellectual content, all authors; manuscript final version approval, all authors; literature research, J.H., Y.J.K., H.J.L., J.W.H., E.Y.C., B.W.C.; clinical studies, all authors; statistical analysis, J.H., J.W.H., B.W.C.; and manuscript editing, J.H., J.W.H., E.Y.C., T.H.K., K.O.C., B.W.C.

Authors stated no financial relationship to disclose.

and female patients (P = .925). The patients' baseline clinical characteristics, including systemic hypertension, hyperlipidemia, diabetes mellitus, and smoking habits, were determined from medical records and routine laboratory examination findings.

Cardiac CT Angiography

Two-phase cardiac CT angiography was performed in the craniocaudal direction during a single breath hold by using a 64-section helical CT unit (Sensation 64; Siemens Medical Solutions, Forchheim, Germany). The scanning protocol included both early-phase imaging to evaluate the coronary arteries and intracardiac thrombus and late-phase imaging to differentiate thrombus from circulatory stasis.

Before the CT examination, the patients' heart rates were measured. Patients with a heart rate higher than 65 beats per minute received a β-blocker (40 mg of propranolol hydrochloride, Pranol; Dae Woong, Seoul, Korea) orally to reduce the heart rate. At our institution, patients are screened for medical conditions that may preclude them from receiving β-blockers. These contraindications are sinus bradycardia, defined as a heart rate lower than 60 beats per minute; systolic blood pressure lower than 100 mm Hg; allergy to the β-blocker or its components; decompensated cardiac failure; asthma; active bronchospasm; and second- or third-degree atrioventricular blockage. The patients' mean heart rate during the CT examination was 61 beats per minute ± 13 (standard deviation) (range, 53–89 beats per minute). Scanning parameters were as follows: 330-msec gantry rotation time, 120 kV, 800 mAs, 0.6-mm section collimation, 1-mm section width, and 3.3-mm table feed per rotation. Electrocardiography-based tube current modulation was applied to 65% of the R-R interval. Nonionic contrast material (60–90 mL of iopamidol, 370 mg of iodine per milliliter, Iopamiro; Bracco Diagnostics, Milano, Italy) followed by 50 mL of saline solution was administered intravenously at a rate of 5 mL/sec by using a power injector (Envision CT; Medrad, Indianola, Pa).

With use of retrospective electrocardiographic gating, early-phase scanning was started, with the time delay determined by using a real-time bolus-tracking technique. A region of interest was drawn in the ascending aorta to monitor an attenuation threshold of 100 HU above the baseline attenuation. Scanning was started 6 seconds after the threshold attenuation trigger of 100 HU was reached. Late-phase scanning was started 30 seconds later, after the end of the early-phase acquisition. To reduce the radiation dose, we used 30 × 0.6 mm (detectors × section collimation), 120 kV, and 200 mAs to encompass the aortic arch to the middle of the left ventricle. Scans were acquired by using prospective electrocardiographic gating. Radiation exposure was estimated from the dose-length product. The calculated radiation dose was 6–10 mSv (dose-length product range, 359–578 mGy · cm) for early-phase imaging and 0.5–1.2 mSv (dose-length product range, 28–69 mGy · cm) for late-phase imaging, depending on the scanning range and the patient's body weight.

Images were reconstructed at the scanner workstation by using commercially available software (Syngo and Somaris/5; Siemens Medical Solutions). For image reconstruction, segmented adaptive cardiac volume reconstruction based on a half-rotation reconstruction technique was used and yielded a heart rate–dependent temporal resolution of between 83 and 165 msec from a 330-msec gantry rotation. The reconstruction parameters were as follows: 0.6-mm section thickness, 0.4-mm increment, 512 × 512-pixel image matrix, medium smooth kernel, and 18–20-cm field of view. The early- and late-phase image data sets were downloaded to the workstation and reviewed by two radiologists (Y.J.K., B.W.C.).

TEE Examination

An experienced cardiologist (C.Y.S., 6 years experience with TEE) performed the TEE examinations by using a 5-MHz phased-array transducer attached to the tip of a commercially available gastroscope (Acuson-Siemens, Mountain View, Calif). All TEE images obtained in each patient were recorded as movie images on a digital videotape for display and evaluation in real time. TEE images of the left atrium and LAA were evaluated in the horizontal (0°) plane and in the plane at rotation of the imaging sector (0°–180°) during continuous visualization of the LAA. SEC was characterized by dynamic clouds of echoes curling slowly into a circular or spiral shape within the LAA cavity. The severity of SEC was assigned one of four grades based on appearance and echogenicity, as follows: none, indicating the absence of SEC; mild, indicating minimal echogenicity that was only transiently detectable with optimal gain settings during the cardiac cycle; moderate, indicating a dense swirling pattern during the entire cardiac cycle; and severe, indicating intense echogenicity and very slow swirling patterns in the LAA that usually had a similar echogenicity in the main cavity.

Image Analysis

Two experienced radiologists (Y.J.K., B.W.C., 6 and 9 years experience with cardiac CT, respectively), each of whom was blinded to the results of the other examinations and the clinical data, prospectively and independently reviewed the cardiac CT angiographic images obtained in the 55 patients. The two readers disagreed on the interpretation of two cases, for which a consensus was reached at joint reading: One case was finally diagnosed as a thrombus, and the other case was finally diagnosed as no thrombus.

At CT, we defined a thrombus as a filling defect that was oval or round on both the early-phase and the late-phase images. Circulatory stasis was defined as a filling defect that appeared with a triangular shape in the LAA on only the early-phase images but was absent on the late-phase images.

We hypothesized that by using a quantitative measurement of CT attenuation (in Hounsfield units) in the LAA relative to a reference point, we could grade the severity of SEC at CT. Therefore, for quantitative analysis, we calculated the LAA–ascending aorta attenuation ratio (LAA/AA) for thrombus and SEC on the early- and late-phase CT

images (10). For this purpose, regions of interest of approximately 10 mm^2 (range, 5–17 mm^2) were placed inside the LAA filling defect seen on the early-phase images and inside the ascending aorta on the same section to generate an early-phase LAA/AA (LAA/AA_E). The late-phase LAA/AA (LAA/AA_L) was calculated by using the same section on the late-phase images that corresponded to the filling defects (Fig 1). Two radiologists (Y.J.K., B.W.C.) independently measured the CT attenuation at two selected points, and the mean LAA/AA was used for analysis.

Figure 1

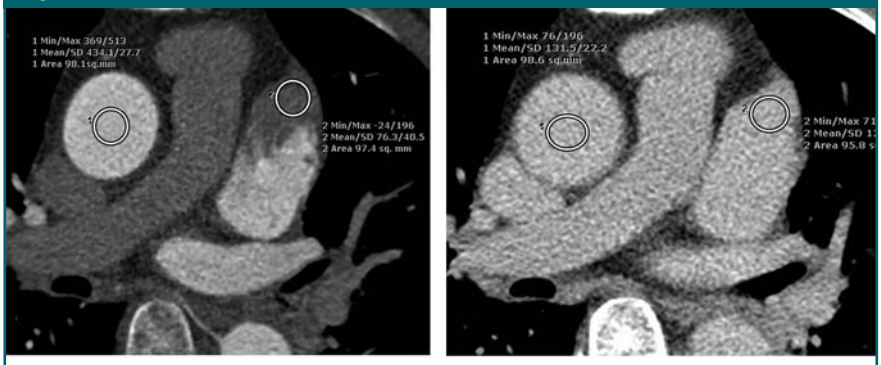

a. b.

Figure 1: Axial cardiac CT angiographic images of thrombus and circulatory stasis obtained in 67-year-old man for calculation of **(a)** mean LAA/AA_E and **(b)** mean LAA/AA_L at quantitative analysis. Two regions of interest (regions *1* and *2*) of approximately 10 mm^2 are placed inside the filling defect in the LAA seen on the early-phase images and in the ascending aorta of the same section.

Table 1

Clinical Characteristics of 55 Patients with Stroke

Characteristic*	Patients with Thrombus (n = 14)	Patients without Thrombus (n = 41)	P Value
Age (y)†	63 ± 10	59 ± 14	.709
Male patients	11 (78)	25 (61)	.243
Hypertension	9 (61)	27 (66)	.915
Hyperlipidemia	1 (7)	9 (22)	.215
Diabetes mellitus	1 (7)	6 (14)	.468
Current smoker	5 (36)	14 (34)	.783
Old CVA	2 (14)	6 (16)	.975
History of congestive heart failure	2 (14)	4 (10)	.639
Continuous atrial fibrillation‡	10 (71)	18 (44)	.045
Severe left ventricular dysfunction			
Systolic dysfunction (EF < 30%)‡	2 (14)	6 (15)	.975
Cardiomyopathy§	0	2 (5)	.400
Valvular heart disease			
Mitral valve prosthesis or repair‡	1 (7)	4 (10)	.769
Mitral stenosis of moderate or greater severity‡	2 (14)	6 (15)	.975
Aortic regurgitation (severe)‡	0	1 (2)	.555
Previously documented atrial fibrillation‡	1 (7)	4 (10)	.769

Note.—All except age data are numbers of patients, with the percentage of patients in parentheses.

* AF = atrial fibrillation, CVA = cerebrovascular accident, EF = ejection fraction.

† Mean ages ± standard deviations.

‡ Predefined high risk factor for thrombus formation.

§ Dilated cardiomyopathy with systolic dysfunction.

Two experienced cardiologists (C.Y.S., E.Y.C., 6 and 10 years experience with TEE, respectively) prospectively and independently reviewed the TEE images obtained in the 55 patients and graded the severity of SEC. The recorded TEE images were presented sequentially to the two reviewers within 3 days after the TEE examination. There were no disagreements regarding the diagnosis of thrombus between the two reviewers. However, the reviewers disagreed on the SEC severity grade in three cases, and a consensus was reached at joint reading: Two cases were finally diagnosed as severe SEC, and the remaining case was finally diagnosed as mild SEC. At TEE, thrombus was defined as a well-circumscribed, uniformly consistent echo-reflective mass with a texture different from that of the LAA wall. Measurements of thrombus size were based on the largest long and short axes seen in the CT and two-dimensional TEE imaging planes.

Statistical Analyses

Categorical baseline characteristics were expressed as numbers of patients and percentages and were compared between the patients with and those without thrombus by using the χ^2 test. Continuous variables were expressed as means ± standard deviations and were compared by using the Student t test for independent samples.

We recorded the number and size of the thrombi detected with all imaging modalities and characterized the diagnoses made by the reviewers as true-positive, true-negative, false-positive, or false-negative. With TEE as the reference standard, the sensitivity, specificity, accuracy, and positive and negative predictive values of cardiac CT angiography for the detection of LAA thrombi were calculated. Significant differences between the mean sizes of the thrombi measured at cardiac CT angiography and those measured at TEE were assessed at paired t testing. Agreement between CT and TEE in the detection of thrombi was assessed with κ statistics. The significance of differences in cardiac CT angiography–derived mean LAA/AA_E and mean LAA/AA_L between thrombus and circulatory

Figure 2

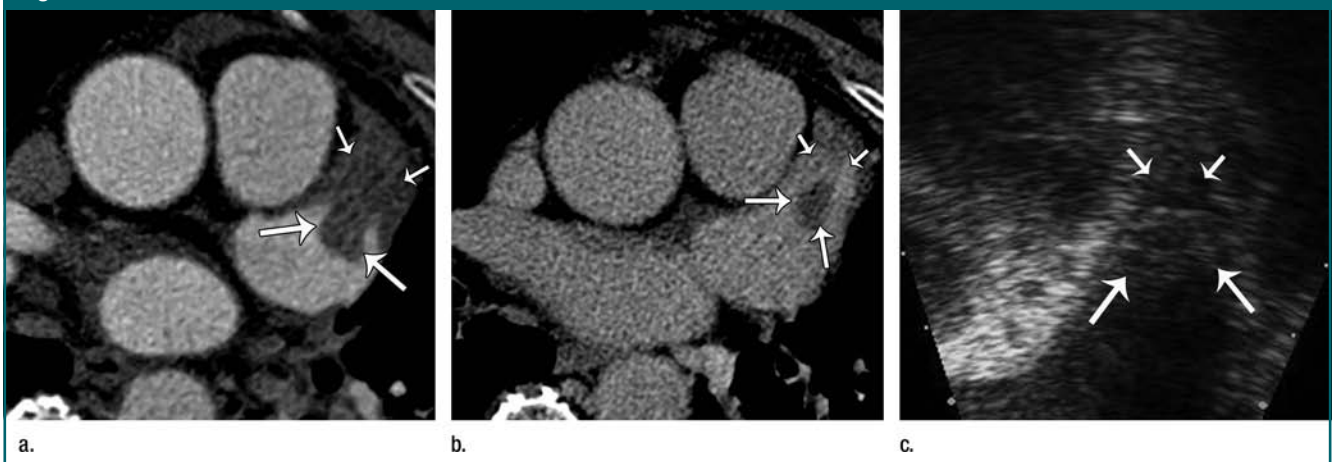

Figure 2: Axial cardiac images in 61-year-old man with stroke. **(a)** Early-phase and **(b)** late-phase cardiac CT angiographic images show oval filling defect (large arrows) in LAA and circulatory stasis (small arrows) just distal to the thrombus. The defect distal to the thrombus caused by stasis disappeared at late-phase imaging. **(c)** TEE image obtained 2 days after CT image acquisition shows the thrombus (large arrows) with SEC (small arrows) just distal to the thrombus.

stasis was assessed by using the Student *t* test. The significance of differences in mean LAA/AA_E and mean LAA/AA_L for thrombus and circulatory stasis based on different SEC grades determined at TEE was assessed by using one-way analysis of variance with the Scheffé method.

Pearson correlation analysis was used to determine correlations in mean CT attenuation ratios between the two observers. $P < .05$ was considered to indicate a significant difference. All statistical analyses were performed by using SPSS, version 10.0, software (Statistical Package for the Social Sciences, Chicago, Ill).

Results

The image quality of all cardiac CT scans was evaluated by the two experienced radiologists (Y.J.K., B.W.C.) in consensus and was considered acceptable for evaluation of intracardiac abnormalities. The clinical characteristics of the 55 patients are summarized in Table 1. Clinical characteristics were not significantly different between the patients with and those without thrombus; patients with atrial fibrillation were the exception. Twenty-eight (51%) patients were experiencing atrial fibrillation at the time of their stroke. Atrial fibrillation was more commonly observed at TEE in the patients with thrombus.

A total of 14 thrombi in 14 patients were detected with TEE, and all of them were located in the LAA. With cardiac CT angiography, 25 filling defects were detected in the LAA. Fifteen of these filling defect lesions were diagnosed as thrombi (13 as thrombus with circulatory stasis, two as thrombus without circulatory stasis), and 10 were diagnosed as circulatory stasis without thrombus (Figs 2, 3). One of the 15 filling defects diagnosed as thrombi at cardiac CT angiography was diagnosed as severe SEC at TEE (Fig 4). In this case, the time between CT and TEE was 5 days. With TEE as the reference standard, the overall sensitivity, specificity, accuracy, and positive and negative predictive values of 64-section cardiac CT angiography for the detection of thrombi in the LAA were 100% (14 of 14 patients), 98% (40 of 41 patients), 98% (54 of 55 patients), 93% (14 of 15 patients), and 100% (40 of 40 patients), respectively.

The mean sizes of the thrombi measured at cardiac CT angiography and TEE were 1.82 cm^2 (range, 0.72–2.94 cm^2) and 1.95 cm^2 (range, 0.90–2.85 cm^2), respectively ($P > .05$). The mean size of the thrombi measured with TEE was 7% larger (difference, 0.13 cm^2; difference range, 0.09–0.28 cm^2) than that measured with CT.

The concordance between LAA thrombus detection with 64-section cardiac CT angiography and that with TEE was high: Thirty patients had no thrombus at either CT or TEE; 14 patients had a thrombus at both CT and TEE; 10 patients had circulatory stasis without thrombus at both CT and TEE; and one patient had a thrombus at CT but not at TEE (overall $\kappa = 0.953$) (Table 2). There were no patients in whom a thrombus was detected at TEE but not at cardiac CT angiography. The 14 filling defects diagnosed correctly as thrombus at CT involved SEC that was categorized at TEE as severe in six cases, moderate in four cases, mild in two cases, and "none" (no SEC) in two cases. The one filling defect depicted as a thrombus at CT but not at TEE involved SEC categorized as severe. The two readers disagreed on the diagnosis of this case, and a consensus interpretation of thrombus was reached at the joint reading. The 10 pseudo–filling defects diagnosed correctly as circulatory stasis without thrombus at CT involved SEC that was categorized as severe in two cases, moderate in six cases, and mild in two cases.

On the early-phase CT images, the mean LAA/AA_E values for thrombus and circulatory stasis were 0.12 HU ± 0.12 (range, 0.05–0.23 HU) and 0.19 HU ± 0.06 (range, 0.08–0.35 HU), re-

spectively. Mean LAA/AA_E measurements were not significantly different between thrombus and circulatory stasis ($P = .651$). On the late-phase CT images, the mean LAA/AA_L values for thrombus and circulatory stasis were 0.29 HU ± 0.12 (range, 0.09–0.45 HU) and 0.85 HU ± 0.12 (range, 0.59–1.06 HU), respectively. Mean LAA/AA_L measurements were significantly different between thrombus and circulatory stasis ($P < .001$).

Mean LAA/AA_E and LAA/AA_L values did not vary significantly among the severe, moderate, and mild grades of SEC determined with TEE ($P > .05$) (Table 3) (Fig 5). Interobserver agreement was good in the determination of mean LAA/AA_E and LAA/AA_L values for thrombus and circulatory stasis ($r = 0.861$ and $r = 0.912$, respectively).

Discussion

Rhythm abnormalities, such as atrial fibrillation, and various cardiac chamber and valvular abnormalities have been associated with the formation of LAA thrombi (14–18). The detection of left atrium or LAA thrombus has important clinical and prognostic implications. Although TEE is effective for detecting LAA thrombi, it is invasive and associated with inherent risks.

For clinical practice, a less invasive modality that enables assessment of the cardiovascular system in the setting of embolic stroke is desirable. CT can be used as an alternative modality in this

Figure 3

a. b. c.

Figure 3: Axial cardiac images in 69-year-old man with stroke. **(a)** Early-phase CT angiographic image shows triangular filling defects (arrows) in LAA. **(b)** Late-phase CT angiographic image shows no filling defects (arrows) in LAA. **(c)** TEE image obtained 1 day after CT image acquisition shows moderate SEC with no thrombus in LAA.

Figure 4

a. b. c.

Figure 4: Axial cardiac images in 64-year-old woman with stroke. **(a)** Early-phase CT angiographic image shows small oval filling defect (large arrows) in LAA. A triangular filling defect (small arrow) is seen in anterior region of LAA. **(b)** Late-phase CT angiographic image shows small oval filling defect (large arrows) suggestive of small thrombus in LAA. Filling defect in anterior region of LAA caused by circulatory stasis has disappeared (small arrow). **(c)** TEE image obtained 5 days after CT image acquisition shows severe SEC with no thrombus in LAA. *LA* = left atrium.

Table 2

Concordance between CT and TEE for Detection of Thrombus and SEC in LAA

	TEE Finding		
CT Finding	Thrombus	SEC	No Thrombus
Thrombus*	14	1	0
Circulatory stasis†	0	10	0
No thrombus	0	0	30

Note.—Data are numbers of patients.

* Includes thrombus combined with circulatory stasis.

† Includes circulatory stasis without thrombus.

Table 3

Early- and Late-Phase CT Attenuation Ratios of Thrombus and SEC

Defect	LAA/AA_E (HU)	LAA/AA_L (HU)
Thrombus	0.12 ± 0.05 (0.05–0.23)	0.28 ± 0.12 (0.09–0.45)
SEC		
Mild	0.19 ± 0.07 (0.08–0.21)	0.94 ± 0.11 (0.81–1.06)
Moderate	0.18 ± 0.05 (0.09–0.26)	0.85 ± 0.13 (0.63–0.97)
Severe	0.21 ± 0.15 (0.09–0.35)	0.80 ± 0.15 (0.59–0.98)

Note.—Data are mean CT attenuation ratios ± standard deviations. Numbers in parentheses are attenuation ratio ranges.

Figure 5

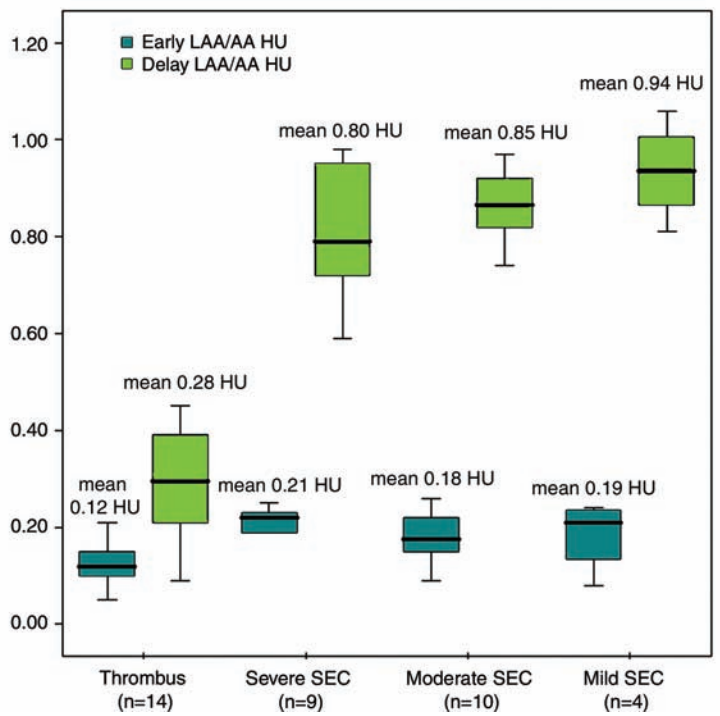

Figure 5: Box-whisker graph illustrates CT attenuation values (y-axis; LAA/AA_E and LAA/AA_L) for thrombus and various degrees of SEC determined at TEE. Each box represents the distribution of attenuation values within one standard deviation: Horizontal line inside each box represents mean attenuation value. Lines extending from top and bottom of boxes represent the distributions of attenuation values.

setting because it is a sensitive, noninvasive and reproducible tool for detecting intracardiac thrombus (6–11). In our previous study (11) involving 101 stroke patients, the sensitivity and specificity of 64-section cardiac CT angiography, as compared with TEE, for the detection of thrombi in the LAA were 100% and 96%, respectively. However, we had four false-positive findings at cardiac CT angiography, which were diagnosed as blood stasis with TEE. In our current study, the presence of circulatory stasis in the patients with a pseudo–filling defect at CT indicated that blood stasis and lack of exchange with the left atrial blood pool may have precluded sufficient contrast enhancement in the LAA. Because it is difficult to differentiate LAA thrombus from blood stasis during the first pass of contrast material, we hypothesized that one might be able to delineate these two phenomena with more certainty on a delayed image because a thrombus exhibits a persistent filling defect at late-phase CT scanning.

In this study, two-phase cardiac CT angiography, as compared with TEE, had high sensitivity (100%) and high specificity (98%) in the detection of thrombus in the LAA in stroke patients. The negative predictive value was 100%. The high sensitivity and high negative predictive value strongly suggest that two-phase cardiac CT angiography is useful for detecting and ruling out intracardiac thrombi. For quantitative analysis, we calculated mean LAA/AA values for the early- and late-phase CT images. According to our study results, mean LAA/AA values for the early-phase images were not significantly different between the patients with thrombus and those with circulatory stasis. However, mean LAA/AA values for the late-phase images were significantly different between these two patient groups. These quantitative analysis results suggest that late-phase imaging is important for differentiating between thrombus and circulatory stasis. However, our quantitative analysis also revealed that cardiac CT angiography, as compared with TEE, cannot be used to differentiate SEC severity. We believe that CT attenuation values are not sufficient for accurate characterization of slow flow states in the left atrium and LAA.

In our study, we observed one false-positive filling defect on both the early-

phase and the late-phase CT images that was not diagnosed as a true thrombus at TEE. There are several possible explanations for this one false-positive result. First, we may have misdiagnosed a prominent pectinate muscle as a thrombus. Second, there is a possibility that the small thrombus was missed at TEE, although we used this examination as the reference standard (19).

Left atrium and LAA thrombi are significantly more common in patients with specific risk factors for thrombus formation (ie, atrial fibrillation, left atrium dilatation, left ventricular dysfunction, mitral stenosis or prosthesis) (20–22). In our study, the prevalence of LAA thrombus was 25% (14 of 55 patients) in a high-risk patient group.

Our study had several limitations. First, we did not perform the two examinations on the same day: In all cases, the two procedures were performed up to 5 days apart to evaluate for intracardiac thrombus. Therefore, it was difficult to validate the one false-positive result at cardiac CT angiography. Second, we did not perform contrast material–enhanced echocardiography for assessment of LAA thrombus and SEC. A further limitation was the radiation exposure to the patient at CT. The delivered radiation dose was estimated to be 6–10 mSv for early-phase imaging and 0.5–1.2 mSv for late-phase imaging. Although we performed two-phase imaging, we lowered the amperage to 200 mAs for late-phase imaging to reduce the radiation dose.

In conclusion, our study results show that two-phase 64-section cardiac CT angiography is a noninvasive and sensitive modality for detecting thrombi in the LAA of stroke patients. Furthermore, two-phase cardiac CT angiography can be used to differentiate thrombus from circulatory stasis, which may cause a pseudo–filling defect on early-phase CT images. Two-phase 64-section cardiac CT angiography may be clinically useful for detecting and ruling out intracardiac thrombus in patients at risk for cardioembolic stroke and may prove to be an alternative to TEE as a diagnostic tool.

References

1. Agmon Y, Khandheria BK, Gentile F, Seward JB. Echocardiographic assessment of the left atrial appendage. J Am Coll Cardiol 1999;34:1867–1877.
2. Al-Saady NM, Obel OA, Camm AJ. Left atrial appendage: structure, function and role in thromboembolism. Heart 1999;82:547–555.
3. Carerj S, Trifiro MP, Granata A, Luzza F, Arrigo F, Oreto G. Comparison between transesophageal echocardiography and transthoracic echocardiography with harmonic tissue imaging for left atrial appendage assessment. Clin Cardiol 2002;25:268–270.
4. Omran H, Jung W, Rabahieh R, et al. Imaging of thrombi and assessment of left atrial appendage function: a prospective study comparing transthoracic and transesophageal echocardiography. Heart 1999;81:192–198.
5. Wolber T, Maeder M, Atefy R, et al. Should routine echocardiography be performed in all patients with stroke? J Stroke Cerebrovasc Dis 2007;16:1–7.
6. Tomoda H, Hoshiai M, Furuya H, et al. Evaluation of intracardiac thrombus with computed tomography. Am J Cardiol 1983;51:843–852.
7. Love BB, Struck LK, Stanford W, Biller J, Kerber R, Marcus M. Comparison of two-dimensional echocardiography and ultrafast cardiac computed tomography for evaluating intracardiac thrombi in cerebral ischemia. Stroke 1990;21:1033–1038.
8. Kitayama H, Kiuchi K, Endo T, Hayakawa H. Value of cardiac ultrafast computed tomography for detecting right atrial thrombi in chronic atrial fibrillation. Am J Cardiol 1997;79:1292–1295.
9. Shapiro MD, Neilan TG, Jassal DS, et al. Multidetector computed tomography for the detection of left atrial appendage thrombus: a comparative study with transesophageal echocardiography. J Comput Assist Tomogr 2007;31:905–909.
10. Kim YY, Klein AL, Halliburton SS, et al. Left atrial appendage filling defects identified by multidetector computed tomography in patients undergoing radiofrequency pulmonary vein antral isolation: a comparison with transesophageal echocardiography. Am Heart J 2007;154:1199–1205.
11. Hur J, Kim YJ, Nam JE, et al. Thrombus in the left atrial appendage in stroke patients: detection with cardiac CT angiography—a preliminary report. Radiology 2008;249:81–87.
12. Stroke Prevention in Atrial Fibrillation Study: final results. Circulation 1991;84:527–539.
13. Risk factors for stroke and efficacy of antithrombotic therapy in atrial fibrillation: analysis of pooled data from five randomized controlled trials. Arch Intern Med 1994;154:1449–1457.
14. Daimee MA, Salama AL, Cherian G, Hayat NJ, Sugathan TN. Left atrial appendage function in mitral stenosis: is a group in sinus rhythm at risk of thromboembolism? Int J Cardiol 1998;66:45–54.
15. Ozkan M, Kaymaz C, Kirma C, et al. Predictors of left atrial thrombus and spontaneous echo contrast in rheumatic valve disease before and after mitral valve replacement. Am J Cardiol 1998;82:1066–1070.
16. Chiang CW, Lo SK, Ko YS, Cheng NJ, Lin PJ, Chang CH. Predictors of systemic embolism in patients with mitral stenosis: a prospective study. Ann Intern Med 1998;128:885–889.
17. Vigna C, Russo A, De Rito V, et al. Frequency of left atrial thrombi by transesophageal echocardiography in idiopathic and ischemic dilated cardiomyopathy. Am J Cardiol 1992;70:1500–1501.
18. Hart RG, Pearce LA, Rothbart RM, McAnulty JH, Asinger RW, Halperin JL. Stroke with intermittent atrial fibrillation: incidence and predictors during aspirin therapy. J Am Coll Cardiol 2000;35:183–187.
19. Hwang JJ, Chen JJ, Lin SC, et al. Diagnostic accuracy of transesophageal echocardiography for detecting left atrial thrombi in patients with rheumatic heart disease having undergone mitral valve operations. Am J Cardiol 1993;72:677–681.
20. Brickner ME, Friedman DB, Cigarroa CG, Grayburn PA. Relation of thrombus in the left atrial appendage by transesophageal echocardiography to clinical risk factors for thrombus formation. Am J Cardiol 1994;74:391–393.
21. Agmon Y, Khandheria BK, Gentile F, Seward JB. Clinical and echocardiographic characteristics of patients with left atrial thrombus and sinus rhythm. Circulation 2002;105:27–31.
22. Ha JW, Lee BK, Kim HJ, et al. Assessment of left atrial appendage filling pattern by using intravenous administration of microbubbles: comparison between mitral stenosis and mitral regurgitation. J Am Soc Echocardiogr 2001;14:1100–1106.