JACC Vol. 23, No. 4
March 15, 1994:961–9

Relations Between Left Atrial Appendage Blood Flow Velocity, Spontaneous Echocardiographic Contrast and Thromboembolic Risk In Vivo

DIANE FATKIN, MB, BS, BSc(MED), FRACP, RAYMOND P. KELLY, MD, FRACP, MICHAEL P. FENELEY, MD, FRACP, FACC

Sydney, New South Wales, Australia

Objectives. The aim of this study was to determine the relations between spontaneous echo contrast, left atrial appendage blood flow velocity and thromboembolism.

Background. Left atrial thrombus and spontaneous echo contrast, a putative marker of thromboembolic risk, are frequently located in the left atrial appendage. Measurement of left atrial appendage outflow Doppler velocity by transesophageal echocardiography is a recent technique for assessment of left atrial appendage function, which may be important in thrombus formation.

Methods. Transthoracic and transesophageal echocardiographic studies were performed in 140 patients with atrial fibrillation (chronic in 80 patients, paroxysmal in 50 patients, first episode <2 weeks in 10 patients). The left atrium and appendage were inspected for thrombus and spontaneous echo contrast, which was graded from 0 (none) to 4+ (severe). Outflow velocity profiles were obtained by pulsed wave Doppler at the orifice of the left atrial appendage.

Results. Left atrial spontaneous echo contrast was present in 78 patients (56%). In multivariate logistic regression analysis, spontaneous echo contrast was the only significant correlate of left atrial thrombus and was present in 14 (93%) of 15 patients. Spontaneous echo contrast and age were associated positively, and anticoagulant therapy was associated negatively, with previous thromboembolic events. Increasing grades of spontaneous echo contrast were associated with decreasing left atrial appendage blood velocity. The velocity in patients with thrombus was not significantly different from that in patients with 4+ spontaneous echo contrast. In multivariate linear regression analysis, the grade of spontaneous echo contrast was significantly and negatively associated with left atrial appendage velocity ($p = -0.0001$) and mitral regurgitation ($p = -0.0002$) and significantly and positively associated with left atrial area ($p = 0.0005$). The odds ratio for spontaneous echo contrast was 28:1 for low left atrial appendage blood flow velocity (<35 cm/s) and 96:1 for low velocity and the absence of mitral regurgitation.

Conclusions. Spontaneous echo contrast is the cardiac factor most strongly associated with left atrial appendage thrombus and embolic events. Spontaneous echo contrast formation is promoted by reduced blood flow velocity and increased left atrial size but is diminished by mitral regurgitation.

(J Am Coll Cardiol 1994;23:961–9)

Spontaneous echo contrast is an echogenic swirling pattern of blood flow that has been proposed as a marker of increased thromboembolic risk (1–7). It has been observed particularly in the left atrium and left atrial appendage in low flow states, such as atrial fibrillation and rheumatic mitral valve disease. In vitro studies have demonstrated qualitative increases in blood echogenicity with the onset of stasis (8–10). Videodensitometric methods have been used in more recent in vitro experiments to quantify increased blood echogenicity with decreasing blood flow rates (11,12). A quantitative relation between blood flow velocity and increasing grades of severity of spontaneous echo contrast within the human left atrium has not been demonstrated previously in vivo.

In view of the predilection of both spontaneous echo contrast and thrombus to form in the left atrial appendage (13,14), the extent of blood stasis within the appendage and its contractile function may be important determinants of thromboembolic risk. Measurement of left atrial appendage Doppler velocity profiles by transesophageal echocardiography is a recently described technique for assessing left atrial appendage function (15–18). The aims of the present study were to determine 1) the relation between left atrial appendage outflow Doppler velocity and the severity of left atrial spontaneous echo contrast, 2) the relative importance of blood flow velocity and other clinical and echocardiographic variables in the pathogenesis of spontaneous echo contrast, and 3) the relation among left atrial appendage blood flow

From the Cardiology Department, St. Vincent's Hospital, Sydney, New South Wales, Australia. Dr. Fatkin is the recipient of a Postgraduate Medical Research Scholarship from the National Health and Medical Research Council of Australia, Canberra, Australian Capital Territory, Australia.

Manuscript received July 30, 1993; revised manuscript received October 26, 1993, accepted November 1, 1993.

Address for correspondence: Dr. Michael P. Feneley, Cardiology Department, St. Vincent's Hospital, Victoria Street, Darlinghurst, New South Wales 2010, Australia.

©1994 by the American College of Cardiology

0735-1097/94/$7.00

velocity, left atrial spontaneous echo contrast, thrombus formation and thromboembolism.

Methods

Patients. Transthoracic and transesophageal echocardiographic studies were performed in 140 consecutive patients with atrial fibrillation referred for evaluation of potential thromboembolic risk (90 patients), recent thromboembolic events (43 patients), infective endocarditis (3 patients), prosthetic valve function (2 patients) or aortic dissection (2 patients). There were 84 men and 56 women, aged 28 to 82 years (mean age 64 years). Eighty patients had chronic atrial fibrillation, which was defined as the persistence of atrial fibrillation for at least 2 weeks before the study. The duration of atrial fibrillation in this group of patients was >3 months in 68 patients (85%) and >12 months in 56 patients (70%). Ten patients had a first episode of atrial fibrillation <2 weeks in duration. Fifty patients had paroxysmal atrial fibrillation, of whom 24 were studied during an episode of atrial fibrillation, and 26 were studied during sinus rhythm. Patients with paroxysmal atrial fibrillation had a minimum of two documented episodes of atrial fibrillation, at least one of which occurred within the 4 weeks preceding the study. Seventy-eight patients were receiving anticoagulant therapy; 34 patients were receiving aspirin, and 28 patients were receiving neither therapy at the time of study.

Fifty-one patients had sustained a previous thromboembolic event (stroke in 29, reversible ischemic neurologic deficit in 1, transient ischemic attack in 20, peripheral embolus in 1), which was defined on the basis of one or more of the following: sudden onset of symptoms, absence of hemodynamically significant symptom-related carotid artery disease, complete resolution of symptoms within 24 h (transient ischemic event) or after 24 h (reversible ischemic neurologic deficit), persistent neurologic deficit or evidence of cerebral infarction at one or more sites on cerebral computed tomography (stroke). In 36 patients (71%), the thromboembolic event had occurred within the 4 weeks preceding the study.

Echocardiography. Transthoracic echocardiography was performed with a Hewlett-Packard Sonos 1000 ultrasonograph (HP77030A) and a 2.5-MHz transducer. Left atrial diameter and left ventricular fractional shortening were obtained from M-mode tracings (19). Left atrial area was measured by planimetry in the parasternal short-axis view. Transesophageal echocardiography was performed with a biplane 5-MHz transducer (HP21363A). Patients were studied in the fasted state after sedation with midazolam hydrochloride (1 to 2 mg intravenously) and topical anesthesia of the hypopharynx with 10% lidocaine spray. In addition to standard examination of the cardiac chambers and valves in the four-chamber view, the left atrial appendage was visualized from the basal short-axis view, with the tip of the probe flexed to display its maximal diameter and length (20). The left atrium and the left atrial appendage were inspected closely for the presence of thrombus and spontaneous echo contrast.

The severity of spontaneous echo contrast was graded from 0 to 4+ by two independent observers who were unaware of the blood velocity data (see later), according to the following criteria: 0 = none (absence of echogenicity); 1+ = mild (minimal echogenicity located in the left atrial appendage or sparsely distributed in the main cavity of the left atrium; may be detectable only transiently during the cardiac cycle; imperceptible at operating gain settings for two-dimensional echocardiographic analysis); 2+ = mild to moderate (more dense swirling pattern than 1+ but with similar distribution; detectable without increased gain settings); 3+ = moderate (dense swirling pattern in the left atrial appendage; generally associated with somewhat lesser intensity in the main cavity; may fluctuate in intensity but detectable constantly throughout the cardiac cycle); 4+ = severe (intense echodensity and very slow swirling patterns in the left atrial appendage, usually with similar density in the main cavity). Interobserver differences in the grading of spontaneous echo contrast were resolved by consensus. The observation of spontaneous echo contrast was standardized by varying both the gain and compress settings throughout their full range during each study.

Left atrial appendage velocity profiles were obtained by pulsed wave Doppler interrogation at the orifice of the appendage. Peak outflow velocity signals within each RR interval were averaged over a minimum of six cardiac cycles for patients studied during atrial fibrillation and over three cardiac cycles for patients studied during sinus rhythm. Interobserver differences in the measurement of left atrial appendage velocities were determined from values obtained by two observers in 73 patients. The shear rate of blood at the orifice of the left atrial appendage was estimated from the average peak outflow velocity and the radius of the orifice (end-diastolic diameter/2) with the formula Shear rate = 8/3 × Velocity/Radius (21). Left atrial appendage velocity measurements from patients in the study group were compared with those obtained from an age- and gender-matched control group of 25 patients with a normal heart who had undergone transesophageal echocardiography for exclusion of cardiogenic sources of thromboembolism.

The first 73 patients in this series were included in a previous study in which the hematologic correlates of spontaneous echo contrast were determined (22). Values for the erythrocyte sedimentation rate, low shear blood viscosity and anticardiolipin antibody, which were the significant correlates of spontaneous echo contrast in that study, are included with the hemodynamic data from the present study in a separate multivariate analysis of spontaneous echo contrast.

Statistical analysis. Differences in clinical and echocardiographic characteristics between patients with each left atrial appendage Doppler velocity type were established using one-factor analysis of variance. In various patient subgroups, differences between continuous variables were

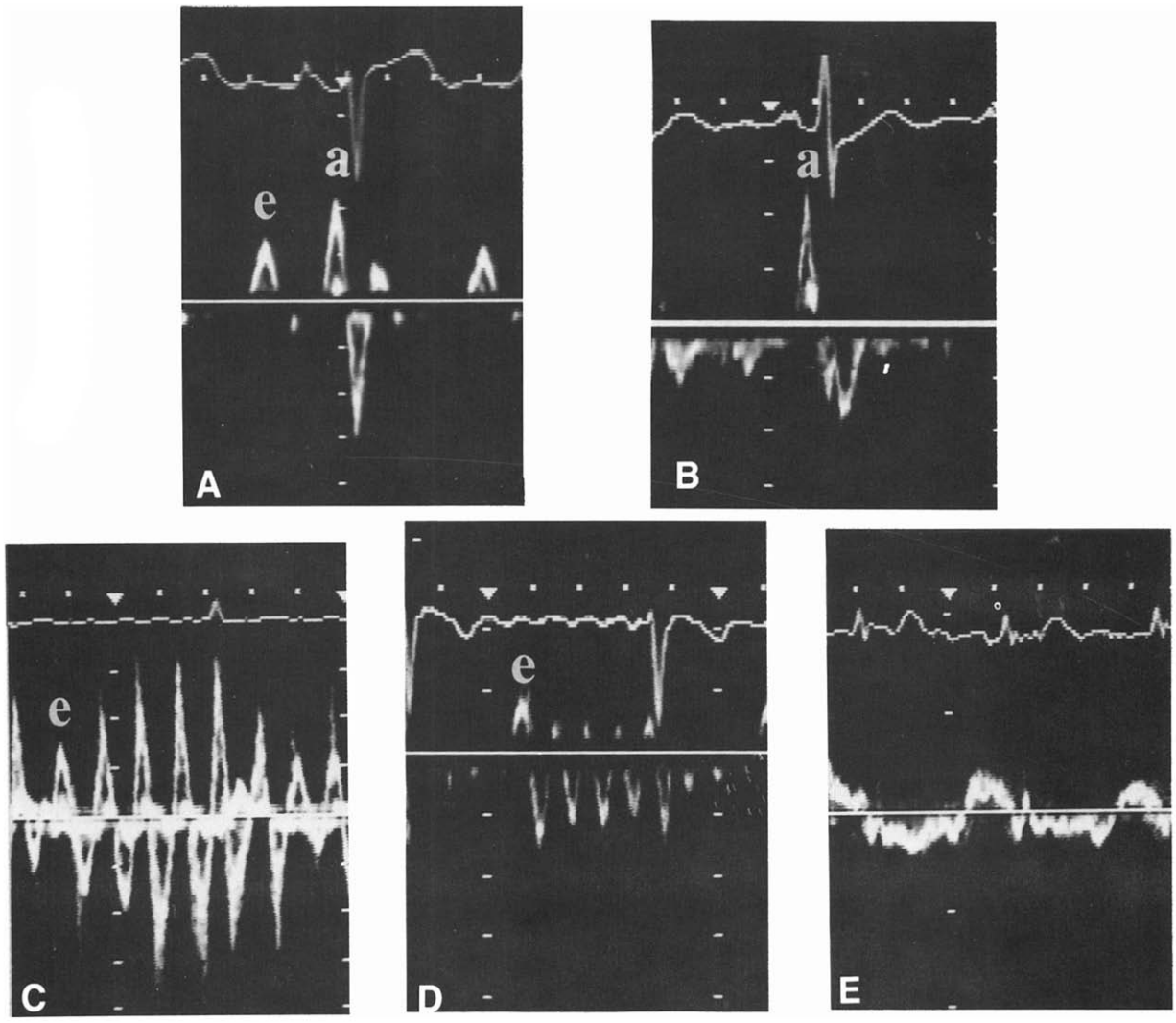

Figure 1. Left atrial appendage blood flow velocity patterns: A, Type I. B, Type II. C, Type III. D, Type IV. E, Type V. (See Results.) a = *a* wave; e = *e* wave.

compared using the unpaired Student *t* test. The significance of differences between categoric variables was determined from 2 × 2 contingency tables with the chi-square test. The relation between various abnormalities and the formation of spontaneous echo contrast was determined by multivariate linear regression analysis, with the grade of spontaneous echo contrast considered a continuous variable. A predictive model for spontaneous echo contrast was formulated using odds ratios obtained from multivariate logistic regression with left atrial appendage velocity dichotomized >35 and <35 cm/s (upper 95% percentile for patients with spontaneous echo contrast). Multivariate logistic regression analysis was used to determine the relative importance of individual variables to left atrial thrombus formation. Interobserver variability in the measurement of left atrial appendage outflow velocities was expressed as the mean coefficient of variation: Σ[(Observer 1 − Observer 2)/Observer 1]/n, expressed as a percent. Interobserver variability in the grading of spontaneous echo contrast was determined as the number of cases in which a discrepancy of grade occurred, expressed as a percent of the total group. Values are expressed as mean value ± SD. A p value < 0.05 was considered significant.

Results

Left atrial appendage velocity patterns. Five distinct left atrial appendage outflow Doppler velocity profiles were observed (Fig. 1). Patients studied during sinus rhythm (control patients and those with episodic atrial fibrillation) demonstrated two patterns. The type I pattern was characterized by a small *e* wave that corresponded to mitral valve opening and an initial reduction in left atrial appendage diameter, followed by a larger *a* wave immediately after the electrocardiographic (ECG) P wave that corresponded to left atrial appendage contraction. The type II pattern consisted of a single *a* wave, without a preceding *e* wave.

Patients studied during atrial fibrillation demonstrated three patterns. In the type III pattern, an outflow *e* wave was followed by multiple irregular waves of higher velocity within each cardiac cycle that were associated with vigorous fibrillatory motion of the left atrial appendage. The *e* wave

Table 1. Clinical and Echocardiographic Characteristics of Patients With Various Left Atrial Appendage Doppler Velocity Patterns

	Left Atrial Appendage Velocity Pattern					
	I (n = 8)	II (n = 19)	III (n = 26)	IV (n = 76)	V (n = 11)	p Value*
LA SEC	0 (0%)	3 (16%)	11 (42%)	54 (71%)	10 (91%)	0.001
LA thrombus	0 (0%)	1 (5%)	0 (0%)	7 (9%)	7 (58%)	0.001
LAA vel (cm/s)	61 ± 16	57 ± 25	38 ± 15	21 ± 12	8 ± 7	0.001
LAA diam (cm)	1.7 ± 0.3	1.6 ± 0.3	1.8 ± 0.3	2.0 ± 0.4	2.2 ± 0.4	0.001
MS/MVR	1 (13%)	2 (11%)	2 (8%)	18 (24%)	9 (82%)	0.001
Chronic AF	0 (0%)	0 (0%)	15 (58%)	54 (71%)	[illegible] (0%)	0.001
LA area (cm²)	16.6 ± 4.3	19.1 ± 3.7	19.4 ± 4.8	27.9 ± 18.9	34.0 ± 12.6	0.004
Age (yr)	54 ± 16	65 ± 10	60 ± 13	66 ± 10	66 ± 12	0.008
T/E events	0 (0%)	11 (58%)	6 (30%)	31 (41%)	3 (27%)	0.021

*Statistical significance determined by one-factor analysis of variance. Values presented are mean value ± SD or number (%) of patients. AF = atrial fibrillation; LA = left atrial; LA diam = left atrial appendage diameter; LAA vel = mean peak left atrial appendage outflow velocity; MS/MVR = mitral stenosis, mitral valve replacement/repair; SEC = spontaneous echo contrast; T/E = thromboembolic.

could be distinguished from the fibrillatory waves by its broader and well defined contour and the temporal association with mitral valve opening. The proximity of the *e* wave to the ensuing QRS complex decreased with shorter RR intervals. The most frequently observed pattern was type IV, which consisted of a dominant *e* wave with or without smaller fibrillatory waves and with little fibrillatory motion of the appendage. The type V pattern consisted of a prolonged low velocity wave that was associated with minimal changes in left atrial appendage diameter.

The clinical and echocardiographic characteristics of patients with the various Doppler flow profiles are shown in Table 1. Progressive derangements of the left atrial appendage velocity profile, from type I to V, were associated with progressive abnormalities of all the variables examined. No patient with the type I pattern had spontaneous echo contrast, but the prevalence of spontaneous echo contrast increased from type II to V. Left atrial and left atrial appendage diameters increased, and left atrial appendage velocity decreased from type I to V. Patients with the type V pattern all had longstanding atrial fibrillation; most had mitral stenosis or a prosthetic mitral valve; and the prevalence of both left atrial spontaneous echo contrast and left atrial thrombus was high in this group. On the other hand, although no patient with type I pattern had a thromboembolic event, the prevalence of thromboembolic events was not positively associated with progressive derangement of the velocity pattern.

Left atrial appendage velocity and spontaneous echo contrast. Left atrial appendage spontaneous echo contrast was present in 78 patients (56%): 1+ in 33 patients, 2+ in 21 patients, 3+ in 18 patients, 4+ in 6 patients. Interobserver differences in the grading of spontaneous echo contrast were determined in 80 patients, with differences of only one grade in 5 patients (6%). The average of the peak left atrial appendage velocities in patients with spontaneous echo contrast (18.5 ± 11.3 cm/s) was significantly lower than the average velocity in patients without spontaneous echo contrast (44.7 ± 22.8 cm/s, $p < 0.001$) (Table 2) and control patients (81.5 ± 19.4 cm/s, $p < 0.001$). Increasing grades of left atrial spontaneous echo contrast were associated with decreasing peak left atrial appendage velocities (Fig. 2). The velocity in patients with thrombus was not significantly different from that in patients with 4+ spontaneous echo contrast. The mean coefficient of variation for measurement of left atrial appendage velocity between observers was 1% (range 0% to 20.3%).

Patients with left atrial spontaneous echo contrast had lower left atrial appendage shear rates, were older and had a greater prevalence of chronic atrial fibrillation and anticoagulant therapy than patients without spontaneous echo contrast (Table 2). Spontaneous echo contrast was present in 13 (54%) of 24 patients with paroxysmal atrial fibrillation studied during an episode of atrial fibrillation. However, it was

Table 2. Clinical and Echocardiographic Characteristics of Patients With and Without Left Atrial Spontaneous Echo Contrast

	Left Atrial Spontaneous Echo Contrast		
	No (n = 62)	Yes (n = 78)	p Value
LAA vel (cm/s)	45 ± 23	19 ± 11	< 0.001
LAA shear rate (s^{-1})	144 ± 91	54 ± 39	< 0.001
Paroxysmal AF (SR)	23 (37%)	3 (4%)	< 0.001
Age (yr)	61 ± 13	67 ± 10	0.001
Chronic AF	26 (42%)	54 (69%)	0.002
Anticoagulation (H/C)	28 (45%)	50 (64%)	0.028
Aspirin therapy	16 (26%)	18 (23%)	NS
Paroxysmal AF (AF)	11 (18%)	13 (17%)	NS
1st episode AF	2 (3%)	8 (10%)	NS
Mitral regurgitation	20 (32%)	20 (26%)	NS
MS/MVR	10 (16%)	21 (27%)	NS
LA area (cm²)	22 ± 11	27 ± 18	NS
LV FS <28%	6 (10%)	16 (21%)	NS

Values presented are mean value ± SD or number (%) of patients. H/C = heparin or coumadin therapy; LV FS = left ventricular fractional shortening; Paroxysmal AF (AF) = paroxysmal atrial fibrillation studied during an episode of atrial fibrillation; Paroxysmal AF (SR) = paroxysmal atrial fibrillation studied during sinus rhythm; other abbreviations as in Table 1.

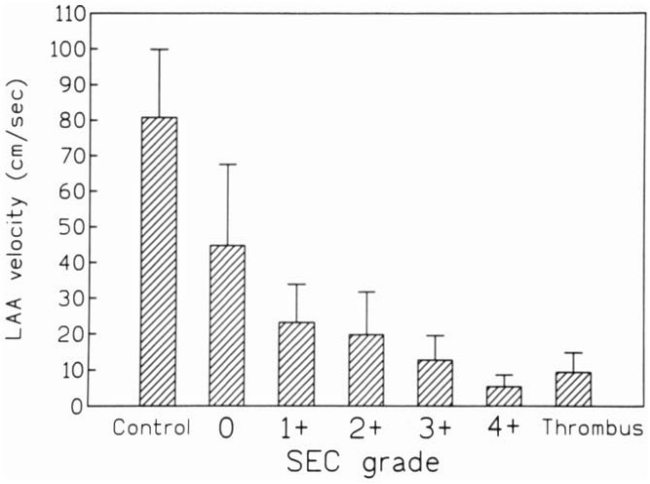

Figure 2. Mean left atrial appendage (LAA) Doppler velocity in control patients and in subgroups of patients with increasing grades of severity of left atrial spontaneous echo contrast (SEC) and left atrial thrombus.

Table 3. Clinical and Echocardiographic Characteristics of Patients With and Without Left Atrial Thrombus

	Left Atrial Thrombus		
	No (n = 125)	Yes (n = 15)	p Value
LAA vel (cm/s)	32 ± 21	9 ± 6	<0.001
LA SEC	64 (51%)	14 (93%)	0.005
MS/MVR	23 (18%)	8 (53%)	0.006
Paroxysmal AF	50 (40%)	0 (0%)	0.006
LAA shear rate (s^{-1})	51 ± 95	99 ± 77	0.027
Chronic AF	67 (54%)	13 (87%)	0.033
1st episode AF	8 (7%)	2 (13%)	NS
Mitral regurgitation	35 (28%)	5 (33%)	NS
LA area (cm^2)	25 ± 15	28 ± 10	NS
LV FS <28%	21 (17%)	1 (7%)	NS
Age (yr)	64 ± 12	66 ± 10	NS
Anticoagulation (H/C)	66 (53%)	12 (80%)	NS
Aspirin therapy	32 (26%)	2 (13%)	NS

Values presented are mean value ± SD or number (%) of patients. Abbreviations as in Tables 1 and 2.

observed in only 3 (12%) of 26 patients with paroxysmal atrial fibrillation studied during sinus rhythm and was only mild or mild to moderate in all patients.

In multivariate linear regression analysis, the grade of spontaneous echo contrast was significantly and negatively associated with left atrial appendage velocity ($p = -0.0001$) and mitral regurgitation ($p = -0.0002$) and positively associated with left atrial area ($p = 0.0005$). The odds ratio for spontaneous echo contrast was 28:1 (95% confidence interval [CI] 9.1 to 84.4) for low left atrial appendage velocity (<35 cm/s) and 3:1 (95% CI 1.4 to 12.8) for the absence of mitral regurgitation. The combination of low left atrial appendage velocity and the absence of mitral regurgitation was associated with a multiplicative odds ratio of 96:1 for spontaneous echo contrast formation.

In a subgroup of 73 patients, both hematologic and hemodynamic variables were examined, and significant correlations were found between the grade of spontaneous echo contrast and left atrial appendage blood flow velocity ($p < -0.0005$), mitral regurgitation ($p < -0.0005$) and left atrial area ($p = 0.008$) but not with the erythrocyte sedimentation rate, low shear blood viscosity or anticardiolipin antibody.

Left atrial thrombus. Left atrial thrombus was present in 15 patients (11%) (left atrial appendage only in 13 patients, main cavity and appendage in 2 patients). The clinical and echocardiographic characteristics of patients with and without left atrial thrombus are shown in Table 3. Fourteen of the patients with left atrial thrombus (93%) also had left atrial spontaneous echo contrast. The one patient with left atrial thrombus without spontaneous echo contrast was studied during sinus rhythm <24 h after reversion from a first episode of atrial fibrillation of 6 days in duration. Compared with patients without left atrial thrombus, those with thrombus had lower left atrial appendage velocities and an increased prevalence of mitral valve disease and chronic atrial fibrillation. No patient with paroxysmal atrial fibrillation had left atrial thrombus. In multivariate logistic regression analysis, the grade of spontaneous echo contrast was the only factor significantly associated with left atrial thrombus ($p < 0.0005$). In patients with spontaneous echo contrast, the odds ratio for thrombus was 13:1 (95% CI 1.7 to 101.4).

Systemic thromboembolic events. Fifty-one patients had a history of systemic thromboembolic events. Older age and the presence of spontaneous echo contrast were positively associated with thromboembolic events (Table 4). Thirty-five (69%) of 51 patients with previous events had left atrial spontaneous echo contrast at the time of the study (1+ in 18 patients, 2+ in 8 patients, 3+ in 7 patients, 4+ in 2 patients); only 3 of these patients were in sinus rhythm. There was a significant negative association between anticoagulant therapy and embolic events. Only 4 of the 35 patients with spontaneous echo contrast and embolic events were receiving anticoagulant therapy at the time of the event. No difference in the prevalence of left atrial thrombus was observed between those with and without embolic events. Although lower mean left atrial appendage velocities were found in the patients with previous events compared with those without events, these differences did not achieve statistical significance, even when patients with sinus rhythm were excluded.

Discussion

The phenomenon of spontaneous echo contrast has been attributed to increased ultrasonic backscatter from aggregation of the cellular components of blood in conditions of blood stasis (8–12,23–25). The association of spontaneous echo contrast with low flow states known to predispose to thromboembolism, such as mitral valve disease and atrial

Table 4. Clinical and Echocardiographic Characteristics of Patients With and Without Systemic Thromboembolic Events

	Systemic Thromboembolic Events		
	No (n = 89)	Yes (n = 51)	p Value
Age (yr)	62 ± 12	68 ± 9	< 0.001
Anticoagulation (H/C)	47 (53%)	6 (12%)	< 0.001
LA SEC	43 (48%)	35 (69%)	0.031
LA thrombus	9 (10%)	6 (12%)	NS
LAA vel (cm/s)			
All patients	32 ± 23	26 ± 20	NS
All AF, except paroxysmal AF (SR)	27 ± 18	20 ± 11	0.053
Paroxysmal AF (SR)	61 ± 19	51 ± 25	NS
LAA shear rate (s^{-1})	103 ± 87	79 ± 66	NS
Chronic AF	48 (54%)	32 (63%)	NS
Paroxysmal AF	35 (39%)	15 (29%)	NS
1st episode AF	6 (7%)	4 (8%)	NS
Mitral regurgitation	24 (27%)	16 (31%)	NS
MS/MVR	21 (24%)	10 (20%)	NS
LA area (cm^2)	25 ± 12	25 ± 21	NS
LV FS <28%	14 (16%)	8 (16%)	NS
Aspirin therapy	19 (21%)	10 (20%)	NS

Values presented are mean value ± SD or number (%) of patients. Abbreviations as in Tables 1 and 2.

fibrillation, and its occurrence in patients with left atrial thrombus and previous thromboembolic events have led to the hypothesis that spontaneous echo contrast may be a marker of increased thromboembolic risk (1–7). In early experiments to determine the pathogenesis of spontaneous echo contrast, Sigel et al. (8) noted qualitative increases in blood echogenicity with the onset of blood stasis after mechanical agitation of a series of test tubes. Similar results have been obtained by other investigators using various in vitro flow chambers and animal models (9,10). More recently, videodensitometric analyses have been used in in vitro studies to demonstrate quantitative increases in blood echogenicity with decreasing flow rates (11,12).

Spontaneous echo contrast may be confined to the left atrial appendage alone, and when distributed throughout the main body of the left atrium, it is usually more intense within the appendage. For this reason, it was hypothesized that left atrial appendage velocity might be a useful indicator of the propensity for spontaneous echo contrast formation. In the present study, the severity of spontaneous echo contrast within the human left atrium was found to be inversely related to left atrial appendage blood flow velocity.

The left atrial appendage is a blind-ended pouch that is embryologically distinct from the main body of the left atrium and has been demonstrated in both surgical and autopsy series to be the most common site of left atrial thrombus formation (13,14). Although the function of the left atrial appendage has not been elucidated completely, it has been shown to contribute significantly to the overall compliance and reservoir function of the left atrium (26). Impairment of the contractile function of the appendage, particularly with the onset of atrial fibrillation, might result in blood stasis and predispose to thrombus development.

Transesophageal echocardiography has been used recently to study left atrial appendage function. Pollick and Taylor (15) studied two-dimensional echocardiographic and Doppler patterns of left atrial appendage function in 82 patients. In 42 of the 63 patients with sinus rhythm, a biphasic pattern was obtained, with a single outflow wave that coincided with left atrial appendage cavity contraction and color flow evidence of blood flow from the appendage. In four patients with atrial fibrillation or flutter, there was an irregular outflow signal that appeared to result from rapid but minimal left atrial appendage emptying and filling associated with fibrillatory contractions. In three patients with atrial fibrillation or flutter, a prolonged low velocity signal was found that was attributed by these investigators to passive emptying of the appendage by inward and upward displacement of its medial wall by the adjacent left ventricular wall during ventricular filling. In 9 of the 17 patients with atrial fibrillation or flutter, the left atrial appendage appeared to behave as a "static pouch," and no outflow signals were obtained. Patients with atrial fibrillation or flutter with spontaneous echo contrast had a larger left atrial appendage diameter than those without.

In a series of 84 patients, Pozzoli et al. (16) found absent or low left atrial appendage velocities in all of the 20 patients with left atrial spontaneous echo contrast or thrombus, 16 of whom had atrial fibrillation. Garcia-Fernandez et al. (17) observed left atrial appendage spontaneous echo contrast in 2 of 8 patients with atrial fibrillation with multiphasic left atrial appendage velocity patterns, in 12 of 14 patients with atrial fibrillation with no detectable flow and in 2 of 17 patients with sinus rhythm. Left atrial area was significantly greater in the patients with absent appendage blood flow. In a series of 54 patients with nonrheumatic atrial fibrillation, Verhorst et al. (18) found significantly lower peak left atrial appendage velocities and a higher prevalence of left atrial spontaneous echo contrast in the 16 patients with documented systemic thromboembolic events compared with patients without events.

Left atrial appendage velocity. In the present study, five characteristic left atrial appendage outflow blood velocity patterns were observed that could be differentiated by the presence or absence of *e* waves in patients with sinus rhythm and by the relative extent of flow associated with fibrillatory activity of the left atrial appendage in patients with atrial fibrillation. Significant differences were found in clinical and echocardiographic variables between the subgroups of patients with each velocity type. These velocity patterns suggest that a variable degree of preservation of left atrial appendage function can be expected in patients with atrial fibrillation.

Although biphasic velocity signals were noted, only the

peak outflow velocities were measured in this study. Previous studies (15–18) have used the peak outflow velocity as an indicator of left atrial appendage function and have demonstrated that both outflow and inflow velocities are generally of similar magnitude, consistent with the continuity equation (27). Thus, the outflow velocity is not only a marker of left atrial appendage contraction and the emptying rate but is also a surrogate marker of the filling rate.

Left atrial appendage velocity and spontaneous echo contrast. Left atrial appendage outflow velocity was found to be the most significant correlate of spontaneous echo contrast in this study. Decreasing left atrial appendage velocities were associated with increasing grades of severity of left atrial spontaneous echo contrast. The presence of mitral regurgitation reduced the grade of spontaneous echo contrast for any given left atrial appendage velocity. The apparent protective effect of mitral regurgitation has been observed in other studies (5,6) and may be due to disruption of blood stasis in the left atrium by the regurgitant jet. The new appearance of left atrial spontaneous echo contrast after surgical correction of mitral regurgitation has been reported recently in two patients with atrial fibrillation and dilated left atria (28).

The importance of low blood shear rate in promoting red cell aggregation and increased blood echogenicity has been demonstrated previously (1,11,23). Patients with spontaneous echo contrast in the present study had significantly lower left atrial appendage blood shear rates than patients without spontaneous echo contrast. The lack of significance of left atrial appendage shear rate in multivariate analysis of spontaneous echo contrast was most likely due to its very high correlation with left atrial appendage velocity ($r^2 = 0.92$, $p = 0.0001$). Significant correlations were found between left atrial appendage shear rate and thrombus formation but not with previous embolic events. Although shear rate may be a more precise index of atrial stasis, measurement of left atrial appendage velocity provides comparable information in the clinical setting.

In this study, increased left atrial size correlated significantly with the severity of spontaneous echo contrast in multivariate linear regression, but statistical significance was not achieved when spontaneous echo contrast was treated as a dichotomous outcome variable in logistic regression analysis. Although Tsai et al. (6) found no difference in left atrial diameters in patients with nonvalvular atrial fibrillation between those with and without spontaneous echo contrast, significant correlations between atrial size and spontaneous echo contrast have been demonstrated by other investigators (2,4,5).

The erythrocyte sedimentation rate and low shear blood viscosity (indexes of red cell aggregation) and anticardiolipin antibody have been demonstrated previously to correlate significantly with the grade of spontaneous echo contrast in 185 patients with atrial fibrillation (22). The loss of significance when these factors were combined with hemodynamic data in a smaller subgroup of 73 patients in the present study suggests that left atrial appendage blood stasis is a relatively stronger indicator of the propensity for spontaneous echo contrast formation, but some caution is warranted in this interpretation, given the smaller patient numbers.

Left atrial thrombus. The results of this study support previous observations of the high prevalence of left atrial spontaneous echo contrast in patients with left atrial thrombus (2–7). The single patient with left atrial thrombus without spontaneous echo contrast had sinus rhythm at the time of the study. Although low left atrial appendage velocities and shear rates, chronicity of atrial fibrillation and the presence of mitral valve stenosis or prostheses were significant univariate correlates of left atrial thrombus, spontaneous echo contrast was the only significant correlate in multivariate analysis.

Thromboembolic events. Age and the presence of spontaneous echo contrast correlated positively, and anticoagulant therapy correlated negatively, with previous thromboembolic events. No relation was evident between the grade of spontaneous echo contrast and embolic events, but the number of patients with the more severe grades was relatively small. No significant differences in mean left atrial appendage velocities were found between those with and without embolic events. Even when we excluded the higher velocities in patients who had paroxysmal atrial fibrillation but were studied during sinus rhythm, the differences were marginally nonsignificant ($p = 0.053$). It is possible that statistical significance may have been achieved in a larger patient group. Potential fluctuations in left atrial appendage velocities and in the grade of spontaneous echo contrast between the time of the event and the time of study may also contribute to these findings. It is also possible that there are significant differences in the pathophysiology of thrombosis and embolism. Although low left atrial appendage blood flow velocities may promote spontaneous echo contrast and thrombus formation, the mechanism of embolism may be more complex. Fuster and Halperin (29) noted the importance of the dynamic forces of the circulation in promoting embolization from ventricular thrombus. The relatively high prevalence of events in patients with paroxysmal atrial fibrillation and in those with more preserved left atrial appendage function (such as the type III velocity pattern) suggests that embolism of preformed thrombus may be favored by more dynamic flow conditions and more vigorous left atrial appendage contraction.

Study limitations and clinical implications. The identification of echocardiographic criteria for thromboembolic risk stratification in patients with atrial fibrillation has achieved greater importance because of recent controversy with regard to the relative benefits of prophylactic coumadin or aspirin therapy in these patients (30–34). The increased prevalence of spontaneous echo contrast in patients receiving anticoagulant therapy in this study is unlikely to be a drug effect and is more likely due to selection bias, given that 40% of these patients had commenced anticoagulant therapy after previous embolic events and were independently at

increased risk for spontaneous echo contrast. The efficacy of prophylactic anticoagulation in patients with spontaneous echo contrast could not be determined from this study because of the small patient numbers and the retrospective nature of the analysis. The retrospective nature of the thromboembolism data is a limitation of the present study and other studies to date that have examined thromboembolic risk in patients with spontaneous echo contrast. Large prospective studies are clearly required to establish definitively the relation between spontaneous echo contrast and thromboembolism in the total population of patients with atrial fibrillation and in subgroups with various grades of spontaneous echo contrast and various etiologies of atrial fibrillation. Thromboembolic risk in atrial flutter is also controversial, but this was not addressed in this study.

Low left atrial appendage blood flow velocity was a significant univariate correlate of thrombus formation, but this reflected the fact that it is the major determinant of spontaneous echo contrast formation. The pathogenesis of spontaneous echo contrast is complex and includes not only the velocity or shear rate of local blood flow but also factors, such as abnormalities of blood composition, that may independently contribute to a prothrombotic state (22,35). Although left atrial appendage velocity is an objective index of blood stasis, variables such as the protective effect of mitral regurgitation limit the value of low velocity per se as a predictor of thromboembolism. The high velocities in patients with paroxysmal atrial fibrillation during sinus rhythm do not preclude embolic potential. In fact, although low velocities promote thrombus formation, intermediate or high velocities may be required for embolization. The potential for variation in blood flow velocity between the time of thrombus formation and the time of study may also limit the predictive value of a single velocity measurement. The qualitative echocardiographic recognition of spontaneous echo contrast thus appears the best single echocardiographic discriminant of thromboembolic risk.

We gratefully acknowledge Kate Downs, M App Stats, for assistance with statistical analysis.

References

1. Beppu S, Nimura Y, Sakakibara H, Nagata S, Park Y-D, Izumi S. Smoke-like echo in the left atrial cavity in mitral valve disease: its features and significance. J Am Coll Cardiol 1985;6:744–9.
2. Daniel WG, Nellessen U, Schroder E, et al. Left atrial spontaneous echo contrast in mitral valve disease: an indicator for an increased thromboembolic risk. J Am Coll Cardiol 1988;11:1204–11.
3. Chia BL, Choo MH, Yan PC, Ee BK, Lee C-N, Shears JH. Intra-atrial smoke-like echoes and thrombi formation. Chest 1989;95:912–4.
4. Castello R, Pearson AC, Labovitz AJ. Prevalence and clinical implications of atrial spontaneous contrast in patients undergoing transesophageal echocardiography. Am J Cardiol 1990;65:1149–53.
5. Black IW, Hopkins AP, Lee LCL, Walsh WF. Left atrial spontaneous echo contrast: a clinical and echocardiographic analysis. J Am Coll Cardiol 1991;18:398–404.
6. Tsai L-M, Chen J-H, Fang C-J, Lin L-J, Kwan C-M. Clinical implications of left atrial spontaneous echo contrast in non-rheumatic atrial fibrillation. Am J Cardiol 1992;70:327–31.
7. de Bekker MA, Lovat LB, Tourikis L, Leech G, Camm A. Left atrial spontaneous contrast echoes—markers of thromboembolic risk in patients with atrial fibrillation. Eur Heart J 1993;14:326–35.
8. Sigel B, Coelho JCU, Spigos DG, et al. Ultrasonography of blood during stasis and coagulation. Invest Radiol 1981;16:71–6.
9. Wolverson MK, Nouri S, Joist JH, Sundaram M, Heiberg E. The direct visualization of blood flow by real-time ultrasound: clinical observations and underlying mechanisms. Radiology 1981;140:443–8.
10. Mikell FL, Asinger RW, Elsperger J, Anderson WR, Hodges M. Regional stasis of blood in the dysfunctional left ventricle: echocardiographic detection and differentiation from early thrombosis. Circulation 1982;66:755–63.
11. Merino A, Hauptman P, Badimon L, et al. Echocardiographic "smoke" is produced by an interaction of erythrocytes and plasma proteins modulated by shear forces. J Am Coll Cardiol 1992;20:1661–8.
12. de Kroon MGM, Slager CJ, Gussenhoven WJ, Serruys PW, Roelandt JRTC, Bom N. Cyclic changes of blood echogenicity in high frequency ultrasound. Ultrasound Med Biol 1991;17:723–8.
13. Jordan RA, Scheifley CH, Edwards JE. Mural thrombosis and arterial embolism in mitral stenosis: a clinicopathologic study of 51 cases. Circulation 1951;3:363–7.
14. Shrestha NK, Moreno FL, Narciso FV, Torres L, Calleja HB. Two-dimensional echocardiographic diagnosis of left atrial thrombus in rheumatic heart disease: a clinicopathologic study. Circulation 1983;67:341–6.
15. Pollick C, Taylor D. Assessment of left atrial appendage function by transesophageal echocardiography. Implications for the development of thrombus. Circulation 1991;84:223–31.
16. Pozzoli M, Febo O, Torbicki A, et al. Left atrial appendage dysfunction: a cause of thrombosis? Evidence by transesophageal echocardiography-Doppler studies. J Am Soc Echocardiogr 1991;4:435–41.
17. Garcia-Fernandez MA, Torrecilla EG, San Roman D, et al. Left atrial appendage Doppler flow patterns: implications on thrombus formation. Am Heart J 1992;124:955–60.
18. Verhorst PMJ, Kamp O, Visser CA, Verheugt FWA. Left atrial appendage flow velocity assessment using transesophageal echocardiography in non-rheumatic atrial fibrillation and systemic embolism. Am J Cardiol 1993;71:192–6.
19. Sahn DJ, De Maria A, Kisslo J, Weyman A. Recommendations regarding quantitation in M-mode echocardiography, results of a survey of echocardiographic measurements. Circulation 1978;58:1072–83.
20. Seward JB, Khandheria BJ, Oh JK, et al. Transesophageal echocardiography: technique, anatomic correlations, implementation, and clinical applications. Mayo Clin Proc 1988;63:649–80.
21. Shung KK. Physics of blood echogenicity. J Cardiovasc Ultrasound 1983;2:401–6.
22. Fatkin D, Herbert E, Feneley MP. Hematological correlates of spontaneous echo contrast in patients with atrial fibrillation and implications for thromboembolic risk. Am J Cardiol. In press.
23. Shung KK, Cloutier G, Lim CC. The effects of hematocrit, shear rate and turbulence on ultrasound Doppler spectrum from blood. IEEE Trans Biomed Eng 1992;39:462–7.
24. Wang X-F, Liu L, Cheng TO, Li Z-A, Deng Y-B, Wang J-E. The relation between intracardiovascular smoke-like echo and erythrocyte rouleaux formation. Am Heart J 1992;124:961–5.
25. Mahony C, Ferguson C. The effects of heparin versus citrate on blood echogenicity in vitro: the role of platelet and platelet-neutrophil aggregates. Ultrasound Med Biol 1992;18:851–9.
26. Holt BD, Shao Y, Tsai L-M, Patel R, Gabel M, Walsh RA. Altered left atrial compliance after atrial appendectomy. Influence on left atrial and ventricular filling. Circ Res 1993;72:167–75.
27. Skjaerpe T, Hegrenaes L, Hatle L. Non-invasive estimation of valve area in patients with aortic stenosis by Doppler ultrasound and two-dimensional echocardiography. Circulation 1985;72:810–8.
28. Chow W-H, Chow T-C, Cheung K-L. Formation of left atrial spontaneous echocardiographic contrast after surgical correction of mitral regurgitation. JCU 1993;21:209–10.
29. Fuster V, Halperin JL. Left ventricular thrombi and cerebral embolism. N Engl J Med 1989;320:392–4.
30. Petersen P, Boysen G, Gotfredsen J, Andersen ED, Andersen B. Placebo-controlled, randomised trial of warfarin and aspirin for prevention of

thromboembolic complications in chronic atrial fibrillation. The Copenhagen AFASAK study. Lancet 1989;1:175–9.

31. The Boston Area Anticoagulation Trial for Atrial Fibrillation Investigators. The effect of low-dose warfarin on the risk of stroke in nonrheumatic atrial fibrillation. N Engl J Med 1990;323:1505–11.
32. Connolly JA, Laupacis A, Gent M, Roberts RS, Cairns JA, Joyner C, and CAFA study Co-investigators. Canadian Atrial Fibrillation Anticoagulation (CAFA) study. J Am Coll Cardiol 1991;18:349–55.
33. Stroke Prevention in Atrial Fibrillation Investigators. Predictors of thromboembolism in atrial fibrillation: I. Clinical features of patients at risk. Ann Intern Med 1992;116:1–5.
34. Stroke Prevention in Atrial Fibrillation Investigators. Predictors of thromboembolism in atrial fibrillation: II. Echocardiographic features of patients at risk. Ann Intern Med 1992;116:6–12.
35. Black IW, Chesterman CN, Hopkins AP, Lee LC, Chong BH, Walsh WF. Hematologic correlates of left atrial spontaneous echo contrast and thromboembolism in non-valvular atrial fibrillation. J Am Coll Cardiol 1993;21:451–7.