Clinical Note

Plaques in the Descending Aorta: A New Risk Factor for Stroke? Visualization of Potential Embolization Pathways by 4D MRI

Andreas Harloff, MD,[1] Christoph Strecker,[1] Alex P. Frydrychowicz, MD,[2] Patrick Dudler,[1] Andreas Hetzel, MD,[1] Annette Geibel, MD,[3] Marc Kollum, MD,[3] Cornelius Weiller, MD,[1] Jürgen Hennig, PhD,[2] and Michael Markl, PhD[2]*

The combination of morphologic and hemodynamic information can help in assessing the risk of embolic stroke associated with thrombi and plaques in the descending aorta. For two acute stroke patients, the determination of individual embolic pathways using flow-sensitive four-dimensional (4D) MRI are reported. 3D visualization of local flow patterns, i.e., retrograde flow channels originating at the site of the atheroma, in conjunction with exact plaque localization, suggested potential embolization of high-risk plaques in the descending aorta although they are located downstream from the supraaortic arteries. Our findings indicate that taking plaques of the descending aorta into consideration may help improve the spectrum of pathologies considered as high-risk sources for brain ischemia.

Key Words: flow sensitive MRI; phase contrast MRI; stroke; flow pattern; aorta; plaque
J. Magn. Reson. Imaging 2007;26:1651–1655.
© 2007 Wiley-Liss, Inc.

PLAQUES AND THROMBI of the aorta are by far the most frequent high-risk sources in patients with stroke of undetermined etiology. With a prevalence comparable to that of carotid artery stenosis and atrial fibrillation, the exact diagnosis of aortic plaques as a leading source for stroke is of high importance (1,2). Due to their location distal to the brain feeding arteries, plaques in the descending aorta are typically not considered as a potential source of thromboembolic strokes (3).

Early MRI studies on basic three-dimensional (3D) flow research visualized normal physiological retrograde flow in the ascending aorta providing sufficient perfusion of coronary arteries. Moreover, it was shown that flow originating in the distal aortic arch aorta continued into the supraaortic vessels (4). However, particularly in presence of severe atherosclerosis and thus increased aortic stiffness, the extent of diastolic retrograde flow in the ascending aorta demonstrates a marked increase compared to young normal volunteers, as recently reported (5). As a result, even plaques in the descending aorta could thus become a relevant source of stroke by retrograde embolization pathways carrying ruptured plaque material into the brain feeding arteries. A more detailed analysis of local vascular hemodynamics at the site of plaque or thrombi may thus have the potential to determine the risk associated with descending aortic plaque.

Next to the semiinvasive reference standard transesophageal echocardiography (TEE), MRI is increasingly used for the assessment of aortic plaques (6). However, previously reported MRI methods lack an assessment of cerebral embolization probability in case of plaque rupture. Hence, we report two patients with stroke of undetermined etiology for which we employed additional high-resolution 3D MRI for plaque localization and flow-sensitive 4D MRI and 3D flow pattern visualization to demonstrate individual potential embolization pathways toward the brain feeding arteries (7,8).

MATERIALS AND METHODS

All experiments were conducted on a 3 Tesla MR system (TRIO; Siemens, Erlangen, Germany) using an eight-element phased-array body coil. Two acute stroke patients with an aortic arch thrombus (patient 1) and a 4.8-mm-thick atheroma in the proximal descending aorta (patient 2) as confirmed by TEE underwent additional MR imaging.

[1]Department of Neurology and Clinical Neurophysiology, University Hospital Freiburg, Freiburg, Germany.
[2]Department of Diagnostic Radiology, Medical Physics, University Hospital Freiburg, Freiburg, Germany.
[3]Department of Cardiology and Angiology, University Hospital Freiburg, Freiburg, Germany.
Contract grant sponsor: Deutsche Forschungsgemeinschaft (DFG); Contract grant number: MA 2383/3-1.
*Address reprint requests to: M.M., University Hospital Freiburg, Department of Diagnostic Radiology, Medical Physics, Hugstetter Strasse 55, 79106 Freiburg, Germany.
E-mail: michael.markl@uniklinik-freiburg.de
Received January 17, 2007; Accepted July 13, 2007.
DOI 10.1002/jmri.21126
Published online 6 November 2007 in Wiley InterScience (www.interscience.wiley.com).

© 2007 Wiley-Liss, Inc.

For plaque and thrombus localization, a T1-weighted fat-saturated 3D gradient-echo (T1-GRE) sequence (1 mm^3 spatial resolution) was used. Subsequently, standard contrast-enhanced MR angiography (CE-MRA) was performed using gadolinium contrast agent (Multihance®; Bracco Altana, ABC, Germany). For further plaque analysis T1-GRE imaging was repeated after CE-MRA. Respiration and wall motion artifacts were minimized by electrocardiograph (ECG) and respiratory gating (7–9).

For the assessment of global and local hemodynamics, time-resolved flow-sensitive 4D MRI was employed. Time-resolved 3D particle traces resemble the imaginary paths of massless particles tracking the temporal and spatial evolution of the measured blood flow velocity, thereby depicting local and global flow patterns over the cardiac cycle (7). For the patient data, particle traces were originated from emitter planes closely positioned at the site of the thrombus or plaque and in the ascending aorta. Imaging parameters were: velocity sensitivity = 150 cm/second, spatial resolution = $2.1 \times 3.2 \times 3.5$ mm^3 in a sagittal-oblique 3D volume with rectangular field-of-view (FOV) = 400×300 mm^2, flip angle = 15°, TE = 3.5 msec, TR = 6.1 msec, bandwidth = 480 Hz/pixel, and temporal resolution = 48.8 msec. 3D blood flow was visualized by use of a commercially available software package (EnSight; CEI, Apex, NC, USA).

RESULTS

Patient 1

A 71-year-old female patient presented with acute recurrent aphasia and right-sided hemiparesis. Routine cranial MRI revealed a left-hemispheric embolic infarction in the middle cerebral artery (MCA) territory and an occlusion of the ipsilateral distal MCA (M2 segment). During diagnostic workup, a 4-mm-thick atheroma with a superimposed 4-mm mobile thrombus in the large curvature of the descending aorta approximately 4 cm distal to the left subclavian artery (LSA) was diagnosed by TEE. Only minimal aortic valve insufficiency (grade I) was found in transthoracic echocardiography (TTE). CE-MRA and high-resolution MRI for characterization of plaques confirmed TEE findings (Fig. 1a).

Additionally, flow-sensitive 4D MRI and subsequent 3D blood flow visualization was performed in the same session. Results of 3D blood flow visualization are shown for an emitter plane positioned in the ascending aorta (Fig. 2a) and at the site of the thrombus (Fig. 2b). Compared to representative data from a normal volunteer (Fig. 3), 3D particle traces originating in the ascending aorta predominantly revealed marked late systolic and early diastolic retrograde flow (white arrows) along the inner curvature of the aorta arch and ascending aorta.

Additional 3D particle trace visualization originating at the thrombus location (Fig. 2b) demonstrated the development of a potential retrograde flow channels (open yellow arrows) directed toward the left subclavian artery (LSA). Such additional visualization of flow starting at the thrombus location might constitute potential embolization pathways in case of thrombus rupture in this stroke patient.

Patient 2

A 78-year-old female patient presented with acute recurrent sensorimotor deficit of her right leg. Consistent with clinical symptoms, cerebral MRI revealed multiple acute embolic infarction in the territory of both the left anterior and middle cerebral artery. Stroke etiology in this patients was classified as undetermined according to the Trial of Org 10172 in Acute Stroke Treatment (TOAST) criteria, based on routine diagnostics (Doppler ultrasound of the brain-supplying arteries, ECG, and TTE) (10). Under the suspicion of an embolic etiology of brain ischemia, the patient underwent additional TEE revealing an inhomogeneous partially ulcerated aortic plaque distal to the outlet of the LSA measuring 4.8 mm in thickness as confirmed by high-resolution 3D MRI (Fig. 1b). Similar to patient 1, a retrograde flow channel originating from the descending aorta could be observed. Moreover, a direct flow channel originating at the site of the plaque directed toward the LSA can clearly be identified, thus suggesting

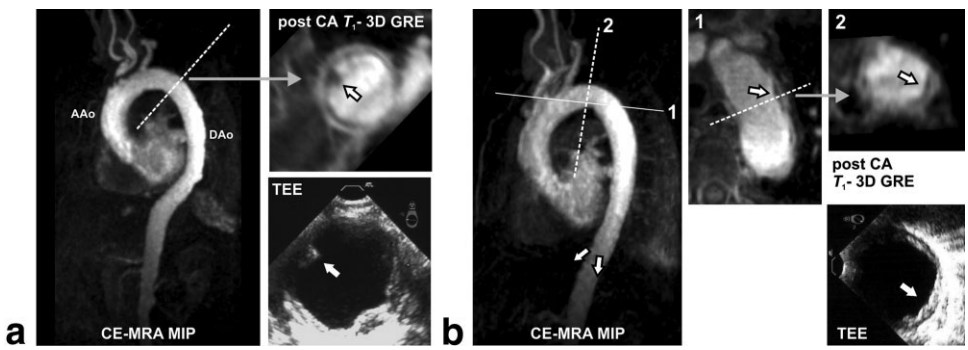

Figure 1. **a:** Patient 1. Contrast-enhanced MRA (left) indicates the localization of the aortic thrombus. Corresponding axial postcontrast imaging (post CA T_1-3D GRE, upper right) shows the hypointense structure protruding into the lumen of the proximal descending aorta without contrast enhancement (open arrow). TEE imaging (lower right) demonstrated a superimposed, echolucent, and mobile aortic thrombus in the descending aorta measuring ≥8 mm in length (white arrow). **b:** Patient 2. Localization of the 4.8-mm-thick plaque in the proximal descending aorta as demonstrated by CE-MRA and post CA T_1-3D GRE. TEE confirmed plaque (4.8 mm in thickness) distal to the outlet of the LSA.

15222586, 2007, 6, Downloaded from https://onlinelibrary.wiley.com/doi/10.1002/jmri.21126 by Western University, Wiley Online Library on [08/03/2026]. See the Terms and Conditions (https://onlinelibrary.wiley.com/terms-and-conditions) on Wiley Online Library for rules of use; OA articles are governed by the applicable Creative Commons License

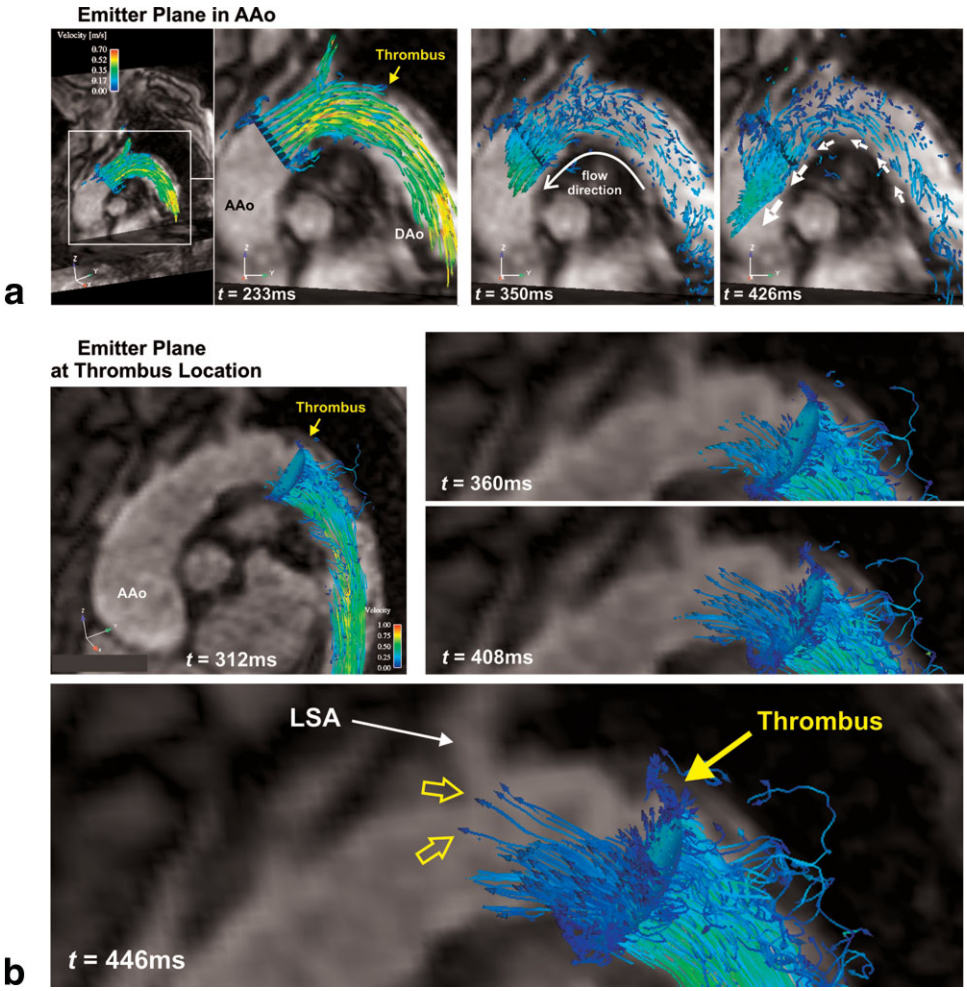

Figure 2. **a:** Temporal and spatial evolution of measured 3D blood flow in ascending aorta (AAo), aortic arch, and ascending aorta (DAo) in patient 1 with a thrombus located in the proximal descending aorta (yellow arrow). In contrast to early diastolic flow in the normal volunteer (see Fig. 3), substantially enhanced retrograde flow along the inner curvature of the aorta (flow direction schematically indicated by white arrows) can be clearly identified. **b:** 3D particle trace visualization of blood flow originating from an emitter plane at the site of the thrombus. The resulting retrograde flow pathways (open yellow arrows) might represent potential embolization pathways connecting thrombus location and the left subclavian artery (LSA) in case of rupture.

potential cerebral embolization via the left branching vertebral artery (Fig. 4).

This complex plaque in the descending aorta, i.e., a not-yet-established source of cerebral embolism, is the only probable origin for multiple, acute embolic and left hemispheric brain infarctions in this patient. The occurrence of infarction solely in the left hemisphere underlines the hypothesis of retrograde flow from a ruptured plaque in the descending aorta with embolization via the left common carotid artery.

DISCUSSION

Findings in two acute stroke patients demonstrate the potential of MRI for the visualization of 3D blood flow patterns in the region of known plaques of the descending aorta. In contrast to other imaging modalities such as TEE, flow-sensitive MRI provides the opportunity to evaluate the extent of retrograde flow channels at any user-defined location in the entire thoracic aorta.

Most noticeably, MR-based 3D blood flow visualization may help to identify potential embolic pathways originating from the site of the aortic thrombus or plaque directed toward the supraaortic arteries. Our results indicate that even a thrombus located several centimeters downstream from the LSA outlet should be considered as a high-risk factor for stroke. This finding might be especially relevant for patients with enhanced retrograde flow due to severe atherosclerosis and thus increased stiffness or aortic valve insufficiency. Since aortic valve pathologies were excluded in our patients by echocardiography, we hypothesize that in concordance with Bogren et al (5) the enhancement of retrograde flow was predominantly related to the loss of aortic compliance.

Although the incidence of aortic high risk plaques increases from the ascending to the descending aorta (11), descending aortic atheroma are usually not considered as potential sources of embolic stroke. The combination of plaque in the descending aorta and retrograde flow channels passing the left supraaortic arteries, however, suggest that such plaques offer an alternative embolic high-risk source, especially in patients with undetermined stroke etiology.

Drawbacks of our study include limited spatial and temporal resolution for the detailed depiction of blood flow within the supraaortic branches. Furthermore, incomplete coverage of the entire cardiac cycle due to prospective ECG gating did not permit the evaluation of late diastolic blood flow patterns, thus limiting the evaluation of the full extent of the retrograde flow channels. Methodological developments with respect to temporal and spatial coverage are therefore necessary to improve the assessment of retrograde flow patterns.

15222586, 2007, 6, Downloaded from https://onlinelibrary.wiley.com/doi/10.1002/jmri.21126 by Western University, Wiley Online Library on [08/03/2026]. See the Terms and Conditions (https://onlinelibrary.wiley.com/terms-and-conditions) on Wiley Online Library for rules of use; OA articles are governed by the applicable Creative Commons License

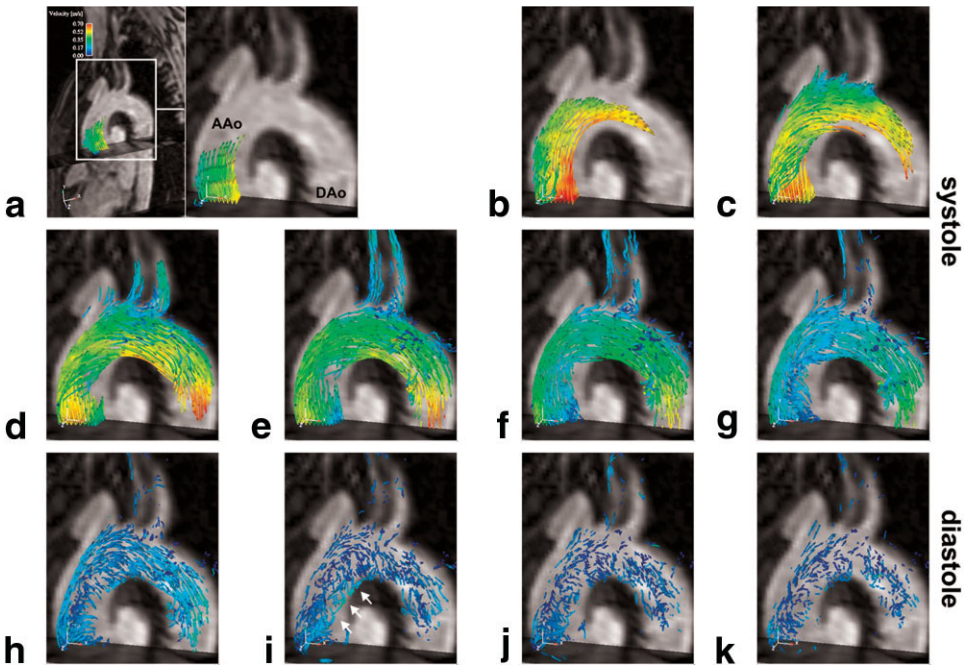

Figure 3. Temporal evolution of normal thoracic aortic blood flow characteristics in a healthy volunteer visualized by time-resolved 3D particle traces originating from an emitter plane above the aortic valve. Filling of the ascending aorta (AAo), aortic arch, and descending aorta (DAo), as well as the supraaortic vessels during systole (time-frames in **a**–**g**) is clearly visible. During early diastole (time-frames in **h**–**k**) the typical formation of a small retrograde flow channel at the inner curvature of the ascending aorta (time frame in (i), white arrows) is evident. Note that only minimal retrograde flow can be observed in the aortic arch and descending aorta.

It should be noted that ruptured plaque or thrombus material might be subject to much greater antegrade systolic forces that retrograde diastolic forces. An additional limitation of this study is thus related to the uncertainty about antegrade vs. retrograde displacement of potentially ruptured plaque fragments. Future studies thus should include more precise measurements of the length and orientation of individual embo-

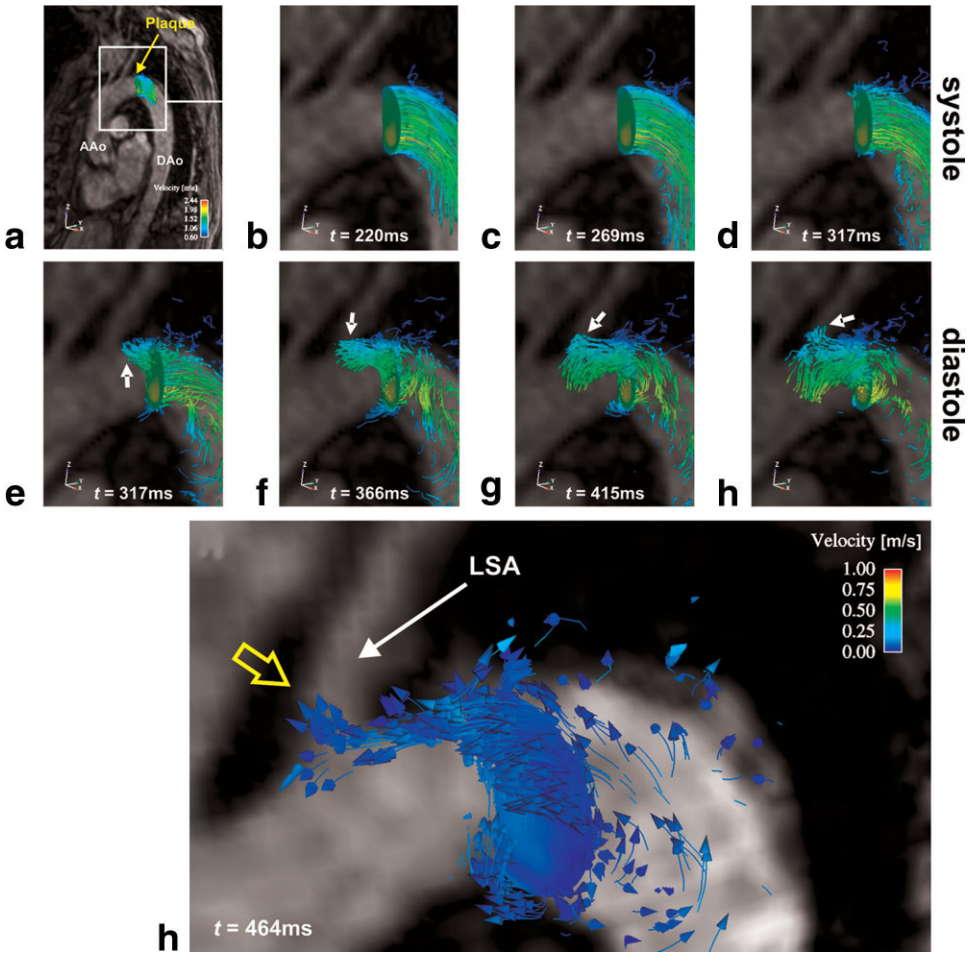

Figure 4. Time-resolved 3D particle trace visualization of 3D blood flow for patient 2 with a descending aortic plaque of 4.8-mm thickness. The emitter plane was positioned distal to the origin of the subclavian artery. Next to the marked late systolic and early diastolic flow reversal (**e**–**h**), the direct visualization of retrograde flow into the LSA can clearly be appreciated in the enlarged image (h, open yellow arrow). In case of aortic plaque rupture, such flow channels may carry thrombotic material from the descending aorta into the brain supplying arteries.

15222586, 2007, 6, Downloaded from https://onlinelibrary.wiley.com/doi/10.1002/jmri.21126 by Western University, Wiley Online Library on [08/03/2026]. See the Terms and Conditions (https://onlinelibrary.wiley.com/terms-and-conditions) on Wiley Online Library for rules of use; OA articles are governed by the applicable Creative Commons License

lization pathways originating from the site of the aortic plaque. Moreover, in addition to already reported optimized image processing strategies, e.g., Napel et al (12) and Buonocore (13), the calculation of embolization probability maps relating plaque location and likelihood of entry into supraaortic arteries may help to determine the clinical significance of aortic high risk plaques.

Further 4D MRI studies in a larger cohort of patients are mandatory to determine the diagnostic impact of this technique and to investigate the role of plaques in the descending aorta for embolic brain ischemia in patients with cryptogenic stroke.

REFERENCES

1. Kronzon I, Tunick PA. Aortic atherosclerotic disease and stroke. Circulation 2006;114:63–75.
2. Harloff A, Handke M, Reinhard M, Geibel A, Hetzel A. Therapeutic strategies after examination by transesophageal echocardiography in 503 patients with ischemic stroke. Stroke 2006;37:859–864.
3. Cohen A, Tzourio C, Bertrand B, Chauvel C, Bousser MG, Amarenco P. Aortic plaque morphology and vascular events: a follow-up study in patients with ischemic stroke. FAPS Investigators. French study of aortic plaques in stroke. Circulation 1997;96:3838–3841.
4. Bogren HG, Mohiaddin RH, Kilner PJ, Jimenez-Borreguero LJ, Yang GZ, Firmin DN. Blood flow patterns in the thoracic aorta studied with three-directional MR velocity mapping: the effects of age and coronary artery disease. J Magn Reson Imaging 1997;7: 784–793.
5. Bogren HG, Buonocore MH, Valente RJ. Four-dimensional magnetic resonance velocity mapping of blood flow patterns in the aorta in patients with atherosclerotic coronary artery disease compared to age-matched normal subjects. J Magn Reson Imaging 2004;19: 417–427.
6. Fayad ZA, Nahar T, Fallon JT, et al. In vivo magnetic resonance evaluation of atherosclerotic plaques in the human thoracic aorta: a comparison with transesophageal echocardiography. Circulation 2000;101:2503–2509.
7. Markl M, Harloff A, Bley TA, et al. Time-resolved 3D MR velocity mapping at 3T: Improved navigator-gated assessment of vascular anatomy and blood flow. J Magn Reson Imaging 2007;25:824–831.
8. Frydrychowicz A, Weigang E, Harloff A, et al. Images in cardiovascular medicine. Time-resolved 3-dimensional magnetic resonance velocity mapping at 3 T reveals drastic changes in flow patterns in a partially thrombosed aortic arch. Circulation 2006;113:e460–e461.
9. Harloff A, Dudler P, Frydrychowicz A, et al. High resolution 3D MR plaque characterization in the thoracic aorta at 3T. In: Proceedings of 23rd Scientific Meeting, European Society for Magnetic Resonance in Medicine and Biology, Warsaw, Poland, 2006, p 50.
10. Adams HP Jr, Bendixen BH, Kappelle LJ, et al. Classification of subtype of acute ischemic stroke. Definitions for use in a multicenter clinical trial. TOAST. Trial of Org 10172 in Acute Stroke Treatment. Stroke 1993;24:35–41.
11. Amarenco P, Cohen A, Tzourio C, et al. Atherosclerotic disease of the aortic arch and the risk of ischemic stroke. N Engl J Med 1994;331:1474–1479.
12. Napel S, Lee DH, Frayne R, Rutt BK. Visualizing three-dimensional flow with simulated streamlines and three-dimensional phase-contrast MR imaging. J Magn Reson Imaging 1992;2:143–153.
13. Buonocore MH. Algorithms for improving calculated streamlines in 3-D phase contrast angiography. Magn Reson Med 1994;31:22–30.

15222586, 2007, 6, Downloaded from https://onlinelibrary.wiley.com/doi/10.1002/jmri.21126 by Western University, Wiley Online Library on [08/03/2026]. See the Terms and Conditions (https://onlinelibrary.wiley.com/terms-and-conditions) on Wiley Online Library for rules of use; OA articles are governed by the applicable Creative Commons License