JACC: CARDIOVASCULAR IMAGING
VOL. 2, NO. 1, 2009
© 2009 BY THE AMERICAN COLLEGE OF CARDIOLOGY FOUNDATION
ISSN 1936-878X/09/$36.00
PUBLISHED BY ELSEVIER INC.
DOI:10.1016/j.jcmg.2008.09.011

# Utility of Nongated Multidetector Computed Tomography for Detection of Left Atrial Thrombus in Patients Undergoing Catheter Ablation of Atrial Fibrillation

Matthew W. Martinez, MD, Jacobo Kirsch, MD, Eric E. Williamson, MD, Imran S. Syed, MD, DaLi Feng, MD, Steve Ommen, MD, Douglas L. Packer, MD, Peter A. Brady, MD, FRCP

*Rochester, Minnesota*

**OBJECTIVES** The aim of this study was to determine whether multidetector computed tomography (MDCT) is able to exclude left atrial appendage (LAA) thrombus in patients referred for catheter ablation of atrial fibrillation (CAAF).

**BACKGROUND** MDCT is commonly used to render pulmonary vein and left atrial anatomy before CAAF. Transesophageal echocardiography (TEE) is also often performed before the ablation to exclude LAA thrombus. Whether MDCT alone is sufficient to exclude LAA thrombus is unknown.

**METHODS** Patients referred for CAAF at the Mayo Clinic between March 2004 and October 2006 were included. Clinical data, 64-slice MDCT (nonelectrocardiography-gated), and TEE were all analyzed. Image data were independently reviewed by 2 cardiac radiologists blinded to the TEE findings. The appearance of the LAA was defined as normal (fully opacified) or abnormal (underfilled).

**RESULTS** Four hundred two patients (mean age 56 ± 10 years; 76% male; ejection fraction 56 ± 10%) were included. Three hundred sixty-two had no evidence of a filling defect by ungated MDCT or left atrial spontaneous echo contrast or thrombus by TEE. In 40 patients, the LAA was "underfilled" with 9 definite thrombi confirmed by TEE. Sensitivity and specificity was 100% and 92%, respectively, with a negative predictive value of 100% and positive predictive value of 23%. In patients with LAA underfilling, Doppler-derived LAA emptying velocities were substantially reduced (mean 19 cm/s; range 6 to 61 cm/s) below the normal range. A higher $CHADS^2$ (congestive heart failure, hypertension, age older than 75 years, and diabetes) score (1.6 vs. 1.1) was observed in patients with LAA filling defects. No cases of LAA thrombus were observed in patients age <52 years with $CHADS^2$ score <1.

**CONCLUSIONS** In patients referred for CAAF, MDCT is a sensitive (100% sensitivity) imaging modality that could be used alone especially in patients age <52 years with a $CHADS^2$ score <1. Incorporation of these findings could decrease the need for multiple imaging modalities and thereby reduce cost of the procedure. (J Am Coll Cardiol Img 2009;2:69–76) © 2009 by the American College of Cardiology Foundation

From the Division of Cardiovascular Diseases and Department of Radiology, Mayo Clinic, Rochester, Minnesota.
Manuscript received June 20, 2008; revised manuscript received September 25, 2008, accepted September 30, 2008.

JACC: CARDIOVASCULAR IMAGING, VOL. 2, NO. 1, 2009
JANUARY 2009:69–76

Catheter ablation within the left atrium is increasingly used as a therapeutic option for patients with symptomatic atrial fibrillation (AF) (1). Imaging of the heart and intrathoracic structures before the ablative procedure by computed tomography (CT), cardiac magnetic resonance, or transesophageal echocardiography (TEE) might be useful in planning the procedure, because it allows identification of the number and topology of the pulmonary veins as well as the relationship of the left atrium to proximate thoracic structures, in particular the esophagus. In addition, pre-acquired CT and cardiac magnetic resonance images might be integrated with advanced 3-dimensional electroanatomic mapping systems to assist in mapping and ablation (2) and during follow-up for detection of complications such as pulmonary vein stenosis (3). Because patients with AF are at increased risk of stroke from a left atrial (LA) thrombus (4) most commonly from within the left atrial appendage (LAA), (5) preoperative imaging of the left atrium and appendage is also necessary to exclude the presence of a mass or thrombus before instrumentation of the left atrium. In current clinical practice TEE is considered to be the "gold standard" imaging tool and is performed in most cases within 24 to 48 h of the procedure to exclude LAA thrombus. However, TEE requires moderate sedation and esophageal intubation and might not allow complete visualization and assessment of all of the pulmonary veins nor their precise relationship to other thoracic structures. Additionally, TEE imaging is not generally useful during the ablative procedure. Thus, before a catheter ablation procedure for AF patients frequently undergo evaluation with multiple imaging modalities, increasing the potential for complications not directly related to the ablative procedure as well as increasing cost of the procedure.

See page 77

**ABBREVIATIONS AND ACRONYMS**

**AF** = atrial fibrillation

**CAAF** = catheter ablation of atrial fibrillation

**CHADS2** = congestive heart failure, hypertension, age older than 75 years, and diabetes

**CI** = confidence interval

**CT** = computed tomography

**LA** = left atrial

**LAA** = left atrial appendage

**MDCT** = multidetector computed tomography

**OR** = odds ratio

**SEC** = spontaneous echo contrast

**TEE** = transesophageal echocardiography

**TIA** = transient ischemic attack

Multidetector computed tomography (MDCT) is a widely available and reproducible imaging technique that can quickly, accurately, and noninvasively determine pulmonary vein and LA anatomy in addition to providing accurate data regarding their relationship to other thoracic structures. In addition, MDCT allows excellent visualization of the LAA and might be useful in excluding LAA thrombus. Prior studies have investigated various generations of CT scanners, including electron beam CT and different iterations of MDCT scanners (6–13). However, sensitivity and specificity of gated MDCT in excluding LAA thrombus has varied in prior studies, and there have been no studies published to evaluate the utility of ungated MDCT for assessment of LAA thrombus. In addition, few have used only 64 MDCT in a homogenous study population with a uniform protocol for all study participants.

To determine this, we sought to compare the sensitivity and specificity of MDCT with TEE in excluding an LAA thrombus in patients before catheter ablation of AF.

## METHODS

**Patient population.** The study included all consecutive patients referred to the Mayo Clinic between March 2004 and October 2006 for LA catheter ablation of symptomatic AF who completed preoperative screening and evaluation. Clinical characteristics of the study population are summarized (Table 1).

**Pre-AF ablation imaging.** Before catheter ablation all patients underwent imaging of the left atrium and appendage with ungated MDCT and TEE to determine the number and topology of the pulmonary veins and exclude intracardiac mass or thrombus. In most cases, MDCT was performed on the day before the procedure; TEE was performed either the day before or the day of the ablation procedure. To account for the possibility of clot development between studies, only patients who underwent a pre-ablation CT and TEE within 3 days of one another were included.

**CT scanning.** Ungated contrast-enhanced CT of the chest was performed with a 64-slice CT scanner (Siemens Medical Solutions, Forchheim, Germany) with a standardized protocol that has been described previously (3). In brief, a bolus of 150 ml of iodinated contrast media with a concentration of 300 mgI/ml (Iohexol/Omnipaque 300, GE Healthcare, Milwaukee, Wisconsin) was injected intravenously at an injection rate of 4 ml/s. After injection, there was a 5-s delay before the monitoring scan began in the ascending aorta. Images were then obtained every 2 s until the necessary threshold was achieved (up to 10 s to complete). Once the signal in the ascending aorta reached a predefined threshold of 150 HU, automated breath-hold instructions

**Table 1. Patient Population Demographic Data**

| | No Thrombus (n = 362) | LAA Underfilled (n = 40) | p Value |
|---|---|---|---|
| Male, n (%) | 278 (77) | 30 (75) | NS |
| Female, n (%) | 84 (23) | 10 (25) | |
| Age (yrs), mean (SD) | 56 ± 10 | 59 ± 10 | NS |
| Mean ejection fraction, % (SD) | 56 ± 10 | 55 ± 10 | NS |
| Persistent atrial fibrillation, n (%) | 210 (58) | 29 (73) | 0.08 |
| Paroxysmal atrial fibrillation, n (%) | 152 (42) | 11 (27) | |
| Anticoagulation therapy, n (%) | 265 (73) | 33 (83) | 0.20 |
| Antiplatelet therapy, n (%) | 191 (53) | 16 (40) | 0.13 |
| Stroke risk factors | | | |
| Hypertension, n (%) | 203 (56) | 31 (78) | 0.009 |
| Diabetes mellitus, n (%) | 25 (7) | 4 (10) | NS |
| Prior CVA/TIA, n (%) | 14 (4) | 3 (8) | NS |
| LV dysfunction/CHF, n (%) | 59 (16) | 15 (38) | 0.001 |
| Age >65 yrs, n (%) | 73 (20) | 7 (18) | NS |
| Mean $CHADS^2$ score | 1.1 | 1.6 | 0.004 |

n = 402. All study participant demographic data divided by normal or underfilled ungated multi-detector computed tomography (MDCT) findings including clinical variables and $CHADS^2$ score.
$CHADS^2$ = congestive heart failure, hypertension, age older than 75 years, and diabetes; CHF = congestive heart failure; CVA/TIA = cerebrovascular accident/transient ischemic attack; LAA = left atrial appendage; LV = left ventricular.

were given and the table moved into position to scan, typically 5 s in total to complete before the scan was initiated. The entire volume of the heart was then scanned during 1 breath-hold at expiration in 15 to 20 s. The entire process from injection to complete scanning of the heart took approximately 40 s. No adjustments to the scans on the basis of left atrium or LAA opacification were performed. Detector collimation was 64 × 0.6 mm, gantry rotation speed was 330 ms/rotation, pitch was 1.1, and tube voltage was 120 kVp with a variable tube current set at a quality reference of 850 mAs. Reconstructions were performed with a B40f Kernel to generate 1.5-mm-thick slices with a reconstruction interval of 0.6 mm with a medium field of view (300 mm) centered at the heart. This produced an axial set of 300 to 400 images for review with an Advantage workstation or Vitrea workstation. This was the standard protocol, reconstruction, and method of evaluation at our institution for pre-ablation MDCT imaging.

All images were acquired in the supine position and reviewed independently by 2 experienced cardiac radiologists who were blinded to the results of the TEE. No attempt was made to "optimize" imaging of the LAA. All images were reviewed simultaneously by both cardiac radiologists, and final interpretation in all cases was agreed upon by consensus.

The LAA was reported as either "normal" if the entire LAA was filled with contrast and fully opacified (Fig. 1A) or as abnormal and "underfilled" if there was any difficulty visualizing the LAA due to not being fully opacified with contrast media (Fig. 1B). If the interpreting physician was unable to visualize the entire LAA filled with contrast, the appendage was considered underfilled and abnormal. With this method, any difficulty viewing the entire LAA was considered abnormal. All images were viewed in the axial plane only without the use of multi-planar reconstructions (MPR) or 3-dimensional volume rendering views. The use of "delayed" imaging of an underfilled LAA was not used for this study. Differences in the pattern or extent of the LAA filling defects were not systematically reported or compared with TEE.

**TEE.** Transesophageal echocardiography was performed with a 3.5- to 7-MHz multiplane probe positioned at the appropriate level within the esophagus. Imaging was focused on each of the pulmonary veins, and when possible Doppler velocities were measured. For the LA and LAA multiple views were recorded along with a "sweeping" view to optimize visualization of the entire structure with a careful search for the presence of thrombus within the LA or LAA. All images were interpreted by 2 echocardiographers blinded to the results of the CT. In cases where a pulsed wave Doppler signal was obtained at the mouth of the LAA, all the Doppler values were averaged and recorded. A definite thrombus was said to be present if an echo-dense material acoustically separate from the endocardium was found within the LA or LAA. No echo contrast agents were used in any of the TEEs to identify thrombus within the LAA. The LAA in

JACC: CARDIOVASCULAR IMAGING, VOL. 2, NO. 1, 2009
JANUARY 2009:69–76

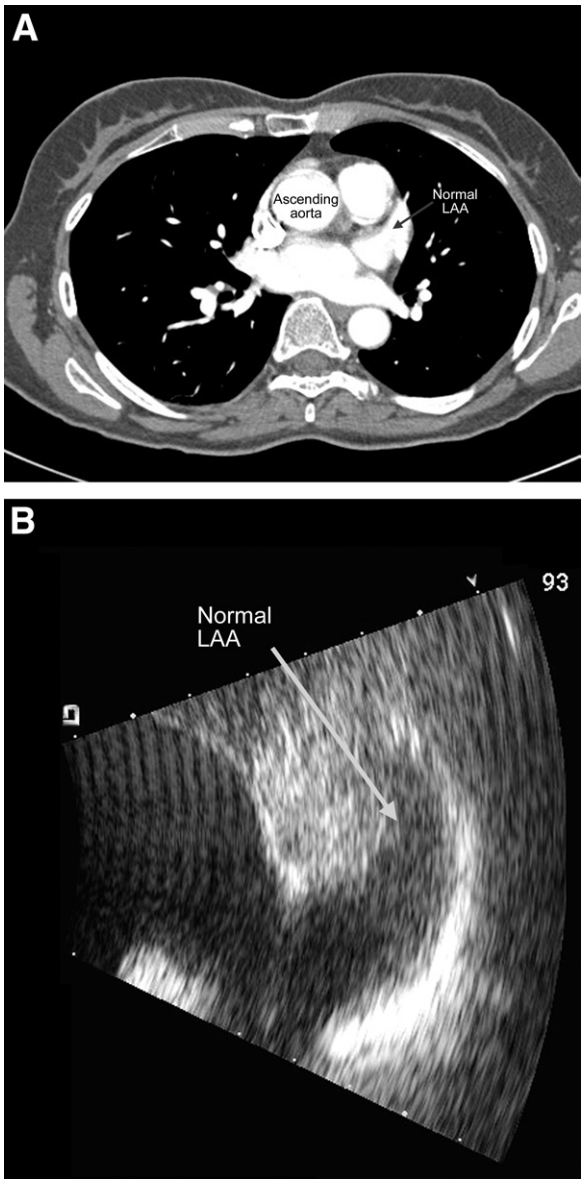


**Figure 1. Normal LAA by MDCT and TEE**

**(A)** Axial image by multidetector computed tomography (MDCT) demonstrating complete opacification of the left atrial appendage **(arrow)** considered "normal" without thrombus. **(B)** Transesophageal echocardiographic (TEE) image of the left atrial appendage (LAA) in the same patient demonstrating a normal LAA without thrombus or moderate/severe spontaneous echo contrast.

each study was graded as none, mild spontaneous echo contrast (SEC), moderate SEC, severe SEC, or as thrombus on the basis of previous descriptions (9,14). The finding of moderate SEC or above was considered as abnormal.

**Thrombus risk.** Risk factors for stroke in AF on the basis of the $CHADS^2$ scoring system (15–17) whereby 1 point is given for each risk factor (congestive heart failure, hypertension, age older than 75 years, and diabetes) and 2 points for a history of transient ischemic attack (TIA) or prior stroke were used to determine clinical stroke risk. Use of anticoagulation with warfarin or low molecular weight heparin was based upon stroke risk assessment by the referring physician. In all cases, warfarin was discontinued at least 2 days before the ablation procedure, most often the day before MDCT or TEE. The decision to use bridging therapy with heparin while off warfarin was based upon clinical risk assessment or the presence of prosthetic heart valves and the like. The number of patients receiving oral anticoagulation and/or antiplatelet therapy before the initial imaging study (either MDCT or TEE) was recorded.

All clinical and imaging data were entered into a centralized database prospectively and analyzed retrospectively.

**Statistical analysis.** Logistic regression analysis was performed to assess the association between abnormal filling in the LAA and $CHADS^2$ score. The $CHADS^2$ score was used as a single variable (the score value) to look for prediction of an abnormal filling defect. Categorical comparisons between groups were completed with chi-square test for independence. Continuous variables were compared with Wilcoxon rank-sum tests. All data were reviewed in a manner consistent with Mayo Clinic Institutional Review Board requirements.

## RESULTS

**Study population.** Between March 2004 and October 2006, a total of 402 consecutive patients who were referred for LA ablation because of symptomatic AF underwent complete clinical assessment and pre-ablation imaging with ungated MDCT and TEE and comprised the study population. Patients without evidence of intracardiac thrombus underwent subsequent LA ablation with either an ostial circumferential pulmonary vein or wider area approach incorporating linear ablation guided by electroanatomic mapping (1). Patients were of mean age 56 ± 10 years with ejection fraction of 56 ± 10% and were mostly male (76%) with more than one-half (59%) in AF at the time of clinical assessment and imaging (persistent clinical pattern). Characteristics of the study population are summarized in Table 1 and presented according to the presence or absence of LAA filling defect observed with ungated MDCT. Almost three-quarters (74%) were therapeutically anticoagulated with warfarin

before and during pre-operative evaluation per usual guidelines (1), which was discontinued just before the ablative procedure, as is our current practice.

**Timing of pre-ablation imaging.** In all cases, imaging with MDCT and TEE was performed within 72 h of each other and within 24 h in 57% of cases.

**MDCT.** The LAA by ungated MDCT was reported as normal and without filling defect in 362 of 402 patients (90%) and abnormal or "under-filled" due to incomplete filling of the LAA with contrast in 40 patients (10%). In 9 of the 40 patients in whom a filling defect within the LAA was reported, further evaluation by TEE confirmed the presence of thrombus within the LAA (Figs. 2A and 2B).

**Transesophageal imaging.** Pre-ablation TEE was reported as normal (without definite thrombus or evidence of moderate to severe SEC) in each of the 362 patients reported as having a normal LAA by ungated MDCT. Of the remaining 40 patients in whom underfilling of the LAA was present by ungated MDCT, TEE was found to be abnormal in all cases. In 78% (31 of 40) of these, at least moderate SEC but without clear identifiable thrombus was present. In the remaining 9 patients, in addition to SEC, a definite thrombus was present by TEE (9 of 401 or 2.2%; 100% sensitivity for detection of LAA thrombus).

**Clinical characteristics of patients with "under-filled" LAA.** To determine whether clinical risk factors for stroke in AF impacted the findings on pre-ablation imaging, a $CHADS^2$ score was calculated for each patient and analyzed according to the presence or absence of a filling defect (Table 2). The most common cardiovascular risk factor for thromboembolism on the basis of the $CHADS^2$ score was hypertension (58%) followed by congestive heart failure (18%), diabetes mellitus (7%), and prior history of cerebrovascular accident/TIA (4%). The $CHADS^2$ score was lower in patients without evidence of LAA underfilling when compared with those with underfilling of the LAA (1.1 vs. 1.6, respectively, $p < 0.004$) and was mostly due to the greater prevalence of hypertension and congestive heart failure in patients with abnormal LAA findings. No differences were apparent in age, gender, or left ventricular ejection fraction variables between those patients with definite thrombus or underfilling of the LAA and those without these findings. Patients with underfilling of the LAA by ungated MDCT were more likely to have a persistent rather than a paroxysmal pattern of AF (73% vs. 58%, $p = 0.08$) and were more likely to have reduced emptying velocity of the LAA by Doppler interrogation when compared with those without underfilling or thrombus within the LAA (19 cm/s

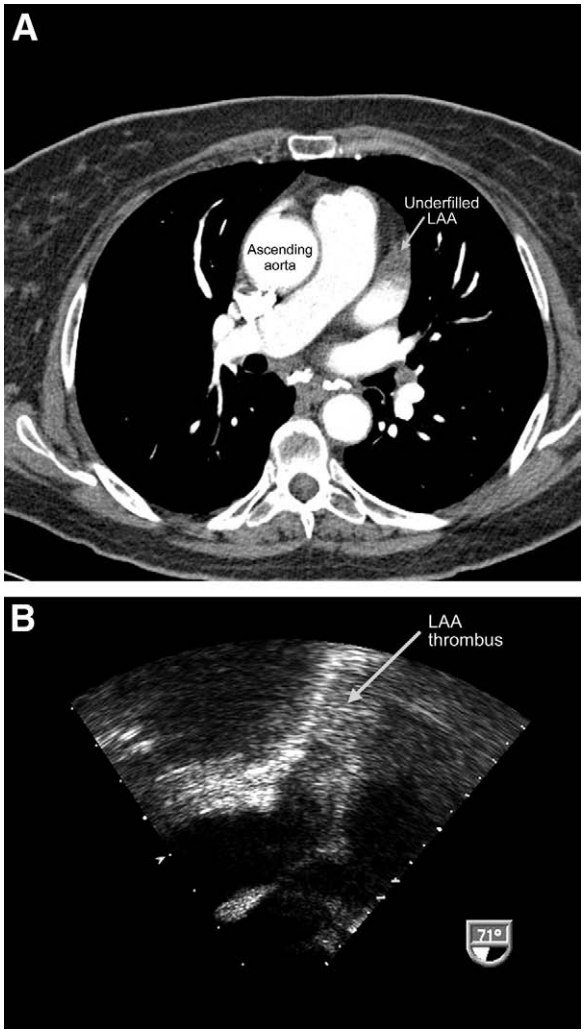


**Figure 2. Underfilled LAA by MDCT and TEE Showing Evidence of LAA Thrombus**

**(A)** Axial image by MDCT demonstrating underfilled or "abnormal" LAA with failure of contrast to fill the LAA **(arrow)**. **(B)** Transesophageal echocardiographic image in the same patient demonstrating obvious thrombus present within the LAA **(arrow)**. Abbreviations as in Figure 1.

**Table 2. Patient Demographic Data $CHADS^2$ Score Values**

| $CHADS^2$ Score | MDCT+ TEE+ | MDCT+ TEE− | MDCT− TEE− |
|---|---|---|---|
| 0 | 0 | 5 | 120 |
| 1 | 3 | 14 | 135 |
| 2 | 2 | 9 | 78 |
| 3 | 1 | 3 | 22 |
| ≥4 | 3 | 0 | 7 |

$CHADS^2$ score findings based on normal or underfilled ungated findings. Abbreviations as in Table 1.

JACC: CARDIOVASCULAR IMAGING, VOL. 2, NO. 1, 2009
JANUARY 2009:69–76

vs. "normal" of >45 cm/s) (5,6). With a regression model, only the presence of congestive heart failure (odds ratio [OR]: 3.0; 95% confidence interval [CI]: 1.5 to 6.2, $p < 0.001$) and hypertension (OR: 2.7; 95% CI: 1.3 to 6.2; $p < 0.001$) were predictive of LAA underfilling, whereas AF duration, age, gender, or prior cerebrovascular accident/TIA or diabetes mellitus were not predictive. As a combined predictor, for each 1-point increase in the $CHADS^2$ score, an increase in the OR of 1.5 was observed ($p < 0.001$; 95% CI: 1.2 to 2.0). No patients <52 years of age with a $CHADS^2$ score <1 were found to have LAA thrombus.

In those with a filling defect and confirmed thrombus by TEE there were notable differences. The $CHADS^2$ score was significantly higher in those patients with a definite thrombus when compared with those without any filling defect (2.4 vs. 1.1, $p < 0.004$), with most patients having a diagnosis of hypertension. In addition, most (78%) were older than 65 years with a history of congestive heart failure or ejection fraction of <50% in more than one-half (56%). All were in persistent AF and anticoagulated with a therapeutic international normalized ratio at the time of the evaluation with ungated MDCT and TEE.

## DISCUSSION

The most important finding of this study is that, in patients with symptomatic AF referred for LA catheter ablation, the sensitivity and specificity of ungated MDCT for excluding LAA thrombus and for detection of features associated with LAA thrombus when compared with TEE is high. In all cases, abnormalities of the LAA observed with ungated MDCT were associated with either definite LAA thrombus or high-risk features such as moderate to severe SEC at the time of TEE. Specifically, in each of the 40 cases where ungated MDCT reported a filling defect within the LAA, the LAA was also abnormal by TEE, with at least moderate SEC being present in 31 patients and definite thrombus present in 9 patients (sensitivity of CT for detection of thrombus = 100%, specificity = 92%, negative predictive value = 100%, positive predictive value = 23%). A second finding was that the prevalence of LAA thrombus in this population is low. The most important clinical predictors of the presence of an LAA thrombus were history of congestive heart failure and hypertension. Therapeutic anticoagulation with warfarin before catheter ablation did not definitely rule out the presence of intracardiac thrombus. Taken together, these findings suggest that ungated MDCT, in addition to providing accurate anatomic rendering of the left atrium and pulmonary veins before catheter ablation in patients with AF, might also be a useful tool to exclude the presence of LAA thrombus. This would allow one to avoid multiple imaging modalities before LA ablation, thereby reducing the cost of the procedure.

Although the specificity of MDCT to detect the presence of a definite thrombus was not 100% in this study, all patients who were subsequently found to have an LAA abnormality, such as moderate to severe SEC or definite thrombus, were reliably identified by MDCT (sensitivity 100%). This is important, because although ungated MDCT could not visually distinguish SEC from definite thrombus (i.e., reduced specificity), all such patients would in any case require further evaluation to exclude LAA abnormality and would therefore most likely undergo TEE. Further assessment with delayed imaging of the LAA at 1 to 2 min might also improve the specificity for distinguishing SEC from thrombus (10). Further investigation of a larger population of patients with underfilled LAA for differentiation of SEC and thrombus might improve the positive predictive value and specificity. However, patients with underfilling of the LAA represent only a small proportion of individuals referred for catheter ablation. Thus, a normal ungated MDCT, especially in patients at low clinical risk for thrombus in the setting of AF (i.e., $CHADS^2$ score ≤2), would obviate the need for additional TEE in 90% of patients, leading to significant cost savings.

Previous studies have evaluated the efficacy of CT to identify LA and LAA thrombus but were limited by small numbers of patients and use of earlier generation scanners with lower spatial and temporal resolution and employed a variety of scanning protocols (6,8–10). In contrast, our study reports on a large cohort evaluated by a standardized scanning technique, protocol, and operators, allowing a more robust assessment of the efficacy of ungated MDCT in excluding LAA abnormality. Additionally, our methods relied only on a visual assessment of the LAA rather than a more cumbersome quantitative assessment of contrast density ratios with Hounsfield units. Differentiation between moderate/severe SEC and true thrombus is more difficult and could not be achieved reliably by visual assessment alone in this study. However, the purpose of this study was not to prove that MDCT was superior to TEE in identification of SEC versus formed thrombus but rather the sensitivity of

ungated MDCT in identifying an abnormal LAA that would prompt further evaluation. Whether different scanning protocols or patient positioning could increase specificity of ungated MDCT deserves further study.

Unsurprisingly, increasing $CHADS^2$ score was associated with an abnormal LAA by MDCT with marked differences in $CHADS^2$ score between patients with an LAA thrombus confirmed by MDCT and TEE versus those with a positive MDCT and negative TEE and those with a normal MDCT ($CHADS^2$ score of 2.4, 1.6, and 1.1, respectively). Of note, in our study, an LAA thrombus was not observed in any patient ≤52 years of age with a $CHADS^2$ score of <1. However, increasing $CHADS^2$ score was associated with increased likelihood of LAA thrombus, with each point increasing the odds of an LAA thrombus by 1.5 times. Last, the finding that all 9 patients with confirmed LAA thrombus were therapeutically anticoagulated with warfarin just before evaluation argues for appropriate imaging of the LAA in most if not all patients before catheter ablation of AF, regardless of anticoagulation history.

**Study limitations.** One limitation of our study is that TEE was considered the "gold standard" against which MDCT was judged, and the presence or absence of LAA thrombus was not confirmed by direct visual inspection of anatomic or surgical specimens. Thus, cases of merely "severe" SEC could have hidden a formed thrombus that was undiagnosed by TEE. Despite this, our conclusion that MDCT is a sensitive (rather than specific) tool is valid, because the important clinical question is whether further evaluation is needed on the basis of the MDCT findings. A second limitation is that we did not attempt to "optimize" imaging of the LAA, such as patient positioning, or compare with other imaging protocols, such as gated MDCT, which might favorably alter the specificity of MDCT when compared with TEE. However, the use of gated MDCT data would increase radiation exposure to the patient and therefore is less desirable. Last, although the majority of images from MDCT and TEE were obtained within 48 h of one another such that the risk of "new" thrombus formation would be low, we cannot entirely rule out the possibility that this did occur between studies, thereby altering our findings.

## CONCLUSIONS

In patients referred for catheter ablation of AF, noninvasive imaging with ungated MDCT within 72 h of the ablation, in addition to providing useful anatomic data, is a sensitive (100% sensitivity) and fairly specific (92% specificity) imaging modality for LAA thrombus assessment that could be used as a stand-alone evaluation in most patients. On the basis of these findings a reasonable approach would be for "low-risk" patients, on the basis of $CHADS^2$, to undergo MDCT alone, with further imaging performed only if underfilling of the LAA was present. In contrast, older patients with a higher $CHADS^2$ score would undergo evaluation by both MDCT and TEE or intraoperative imaging with intracardiac echocardiography before proceeding with transseptal access to the left atrium. This would reduce the need for multiple imaging in the preoperative assessment in patients sent for LAA ablation, significantly reducing costs of the procedure.

**Reprint requests and correspondence:** Dr. Peter A. Brady, Mayo Clinic College of Medicine, 200 First Street Southwest, Rochester, Minnesota 55905. *E-mail: brady.peter@mayo.edu.*

## REFERENCES

1. Calkins H, Brugada J, Packer DL, et al. HRS/EHRA/ECAS expert consensus statement on catheter and surgical ablation of atrial fibrillation: recommendations for personnel, policy, procedures and follow-up. A report of the Heart Rhythm Society (HRS) Task Force on Catheter and Surgical Ablation of Atrial Fibrillation. Heart Rhythm 2007;4:816–61.
2. Dong J, Dickfeld T, Dalal D, et al. Initial experience in the use of integrated electroanatomic mapping with three-dimensional MR/CT images to guide catheter ablation of atrial fibrillation. J Cardiovasc Electrophysiol 2006;17:459–66.
3. Packer DL, Keelan P, Munger TM, et al. Clinical presentation, investigation, and management of pulmonary vein stenosis complicating ablation for atrial fibrillation. Circulation 2005; 111:546–54.
4. Kok LC, Mangrum JM, Haines DE, Mounsey JP. Cerebrovascular complication associated with pulmonary vein ablation. J Cardiovasc Electrophysiol 2002;13:764–7.
5. Agmon Y, Khandheria BK, Gentile F, Seward JB. Clinical and echocardiographic characteristics of patients with left atrial thrombus and sinus rhythm: experience in 20 643 consecutive transesophageal echocardiographic examinations. Circulation 2002;105: 27–31.
6. Gottlieb I, Pinheiro A, Brinker JA, et al. Diagnostic accuracy of arterial phase 64-slice multidetector CT angiography for LAA thrombus in patients undergoing atrial fibrillation ablation. J Cardiovasc Electrophysiol 2008;19:247–51.

7. Khan MN, Usmani A, Noor S, et al. Low incidence of left atrial or left atrial appendage thrombus in patients with paroxysmal atrial fibrillation and normal EF who present for pulmonary vein antrum isolation procedure. J Cardiovasc Electrophysiol 2008;19:356–8.
8. Jaber WA, White RD, Kuzmiak SA, et al. Comparison of ability to identify left atrial thrombus by three-dimensional tomography versus transesophageal echocardiography in patients with atrial fibrillation. Am J Cardiol 2004;93:486–9.
9. Kim YY, Klein AL, Halliburton SS, et al. Left atrial appendage filling defects identified by multidetector computed tomography in patients undergoing radiofrequency pulmonary vein antral isolation: a comparison with transesophageal echocardiography. Am Heart J 2007;154:1199–205.
10. Shapiro MD, Neilan TG, Jassal DS, et al. Multidetector computed tomography for the detection of left atrial appendage thrombus: a comparative study with transesophageal echocardiography. J Comput Assist Tomogr 2007;31:905–9.
11. Patel A, Au E, Donegan K, et al. Multidetector row computed tomography for identification of left atrial appendage filling defects in patients undergoing pulmonary vein isolation for treatment of atrial fibrillation: comparison with transesophageal echocardiography. Heart Rhythm 2008;5:253–60.
12. Saremi F, Channual S, Gurudevan SV, Narula J, Abolhoda A. Prevalence of left atrial appendage pseudothrombus filling defects in patients with atrial fibrillation undergoing coronary computed tomography angiography. J Cardiovasc Comput Tomogr 2008;2:164–171.
13. Tomoda H, Hoshiai M, Furuya H, et al. Evaluation of intracardiac thrombus with computed tomography. Am J Cardiol 1983;51:843–52.
14. Fatkin D, Kelly RP, Feneley MP. Relations between left atrial appendage blood flow velocity, spontaneous echocardiographic contrast and thromboembolic risk in vivo. J Am Coll Cardiol 1994;23:961–9.
15. Gage BF, van Walraven C, Pearce L, et al. Selecting patients with atrial fibrillation for anticoagulation: stroke risk stratification in patients taking aspirin. Circulation 2004;110:2287–92.
16. Gage BF, Waterman AD, Shannon W, Boechler M, Rich MW, Radford MJ. Validation of clinical classification schemes for predicting stroke: results from the National Registry of Atrial Fibrillation. JAMA 2001;285:2864–70.
17. Go AS, Hylek EM, Chang Y, et al. Anticoagulation therapy for stroke prevention in atrial fibrillation: how well do randomized trials translate into clinical practice? JAMA 2003;290:2685–92.

**Key Words:** atrial fibrillation ▪ left atrial appendage ▪ thrombus ▪ computed tomography.