Transthoracic Echocardiography Documents Prompt Resolution of Right Atrial Thrombus After Thrombolytic Therapy

Kamthorn S. Lee, MD, Fredric J. Pashkow, MD, David A. Homa, and Ernesto E. Salcedo, MD, *Cleveland, Ohio*

Right atrial thrombi represent pulmonary emboli in transit, and they may be fatal in patients treated conservatively with anticoagulation. This case provides an opportunity to review echocardiographic findings and management decisions in this disease entity. As the literature now favors thrombolytic therapy in suitable patients, we present a case in which transthoracic echocardiography provided rapid assessment of the outcome of this form of therapy. (J AM SOC ECHOCARDIOGR 1992;5:541-3.)

Right atrial thromboembolism represents a sublcass of thrombotic disease that carries grave prognostic implications.[1,2] In the literature, it is well documented that, if only treated medically with anticoagulation, the mortality rate from these pulmonary emboli in transit ranges from 40% to 50%.[1] As recently as 1987, surgery was the therapy of choice. The literature now favors primary thrombolytic therapy as an alternative to surgery.[3-5] To our knowledge, the immediate time course of thrombolytic efficacy in these patients has not been documented. We present a case in which thrombolytic therapy was used, and transthoracic echocardiography, performed 3 hours after beginning of thrombolytic infusion, demonstrated substantial resolution of the thrombus.

CASE REPORT

A 21-year-old man came to a local community hospital with a 1-month history of exertional dyspnea and a 3-day history of left leg swelling and pain. He enjoyed excellent health until 1 month before admission, when he first noted gradual onset of effort dyspnea and nonproductive cough. Two weeks into his symptoms, a physician treated him with antibiotics for "bronchitis." A chest x-ray film done at that time was reported to be normal. Three days before presentation, he experienced pain and increased warmth in the left calf and thigh areas. A venogram done at the Emergency Department demonstrated extensive deep vein thrombosis of his left leg. He was hospitalized and began receiving intravenous heparin.

To evaluate his exertional dyspnea and pleuritic chest pain, a ventilation-perfusion scan was ordered. The scan demonstrated two areas of ventilation-perfusion mismatch consistent with pulmonary emboli. An echocardiogram showed a large right atrial mass. The patient was transferred to the Cleveland Clinic Hospital for further treatment.

On admission he was in no acute distress. Vital signs were normal. No jugular venous distension was seen. His chest and heart examination were normal. Extremities examination showed his left leg was slightly warmer than the right, with Homans' sign present. The physical examination was unremarkable for rash, nodules, ulcers, ecchymoses, or lymphadenopathy.

An urgent echocardiogram was performed and demonstrated a multilobed, highly mobile mass measuring 3 × 1 cm located in the right atrium attached to the eustachian valve. The right ventricle showed mild impairment of function. Left ventricular function was normal. The echocardiographic diagnosis was right atrial thrombus. The management options in this patient included (1) continued anticoagulation with intravenous heparin, advancing to warfarin later, (2) surgical removal of the right atrial thrombus, or (3) intravenous thrombolytic therapy.

In this patient, we chose intravenous thrombolytic therapy for several reasons. First, in view of documented thrombi in his left leg, right atrium, and lungs, we deemed it desirable to achieve a systemic lytic state targeting the above organs. Second, if the patient were to go to surgery, it would be difficult in the first few postoperative days to institute anticoagulation for his deep venous thrombosis. This situation would mandate vena caval interruption

From The Cleveland Clinic Foundation, Department of Cardiology.

Reprint requests: Dr. Fredric Pashkow, Desk F15, Department of Cardiology, The Cleveland Clinic Foundation, 9500 Euclid Avenue, Cleveland, OH 44195.

27/1/38610

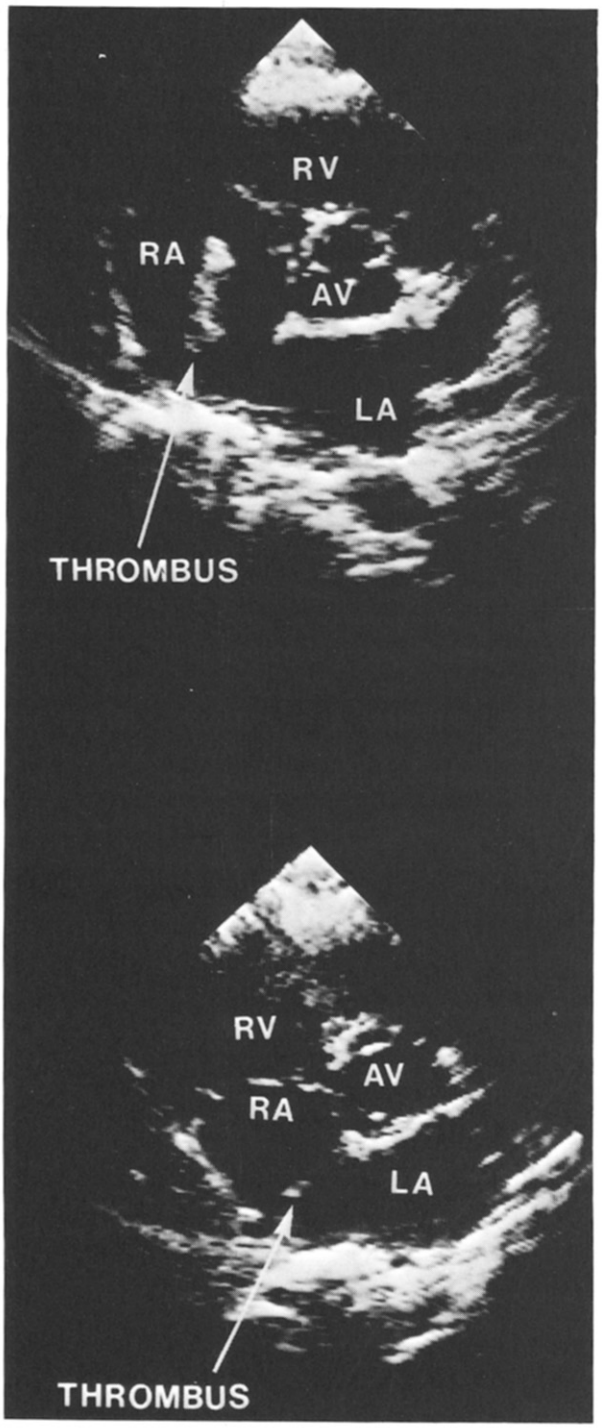

Figure 1 Parasternal short-axis view demonstrating substantial resolution of RA thrombus. *RV,* Right ventricle; *RA,* right atrium; *AV,* aortic valve; *LA,* left atrium.

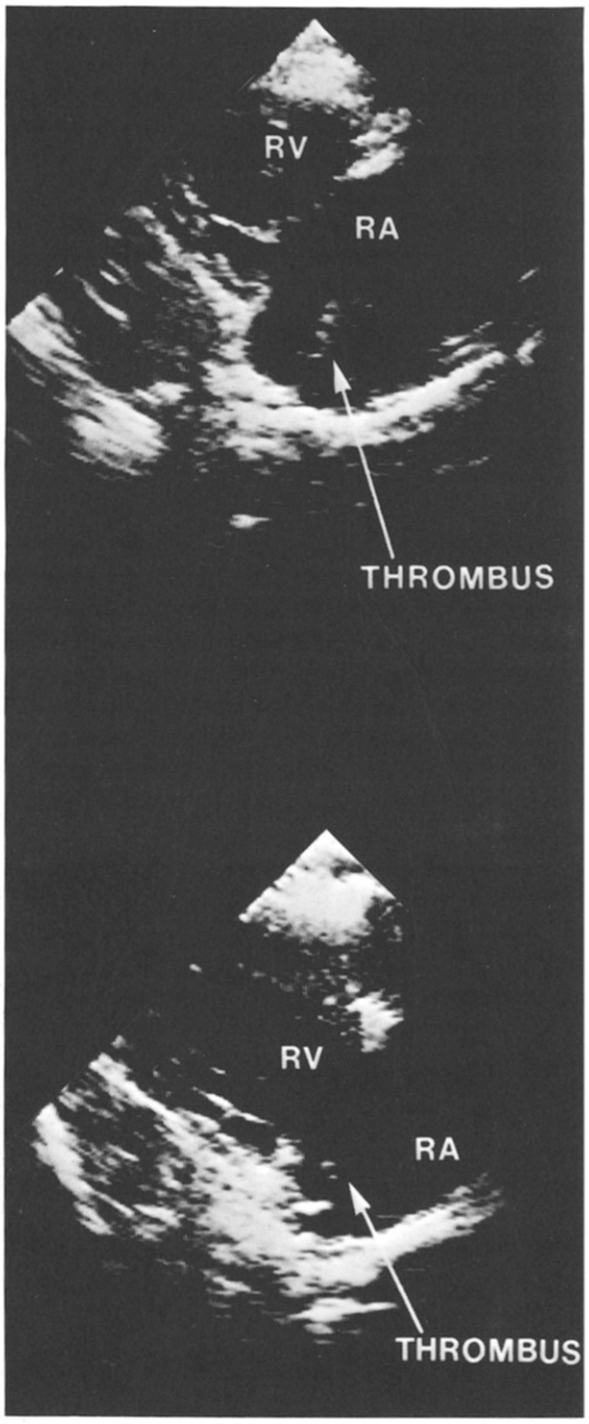

Figure 2 RV inflow view demonstrating substantial resolution of RA thrombus. *RV,* Right ventricle; *RA,* right atrium.

with a Greenfield umbrella. Third, there had been a short series in the literature since 1988 documenting the efficacy of intravenous thrombolytic therapy in the lysis of right atrial thrombus without significant complication rate.[3-5] For these reasons we proceeded with thrombolytic therapy.

The initial pulmonary arterial pressure was 50/14 mm Hg. The thrombolytic regimen instituted con-

sisted of 50 mg of recombinant tissue-type plasminogen activator (t-PA) infused over 1 hour followed by continuous intravenous urokinase at 300,000 U/hr for the next 24 hours. The patient tolerated the infusions well. Three hours after the t-PA infusion began, a repeat transthoracic echocardiogram demonstrated marked decrease in the size of the right atrial clot, with only a small remnant seen (Figures 1 and 2). The possibilities at that time were (1) effective dissolution of the thrombus by therapy, or (2) embolization of the thrombus distally into the pulmonary circulation.

The patient was doing well clinically, reporting the feeling of well-being. The pulmonary artery catheter did not register increase in pulmonary arterial pressure that would suggest embolism. Echocardiographic imaging of the right ventricle and the proximal pulmonary arterial tree at the level of bifurcation showed no clots. We believe the right atrial thrombus was effectively dissolved by thrombolytic therapy instituted only 3 hours previously. In the next morning, a pulmonary angiogram done demonstrated no pulmonary emboli. The patient was subsequently found to have plasminogen deficiency, and was advised of his need for lifetime anticoagulation.

DISCUSSION

The indication for use of thrombolytic therapy in pulmonary embolism currently extends only to patients with hemodynamic instability refractory to vasopressors. Right atrial thrombi, as noted by previous studies, are associated with a substantial mortality rate if treated conservatively with anticoagulation alone.[1] This case concurs with the others reported in recommending thrombolytic therapy as the treatment of choice in patients without contraindications to its use.

The reasons for such high mortality rates in patients with right atrial thrombi are not well defined. Obviously one could postulate massive pulmonary embolization as the cause of death. Unfortunately, of the limited patients reported in literature, autopsy studies were not obtained in all of them, making the exact cause of death difficult to pinpoint. There are very few reports in the literature documenting embolization after thrombolysis. At this point, it appears that the use of thrombolytic therapy is safe and efficacious for the management of patients with right atrial thrombi.

The use of transthoracic echocardiogram demonstrated the prompt efficacy of intravenous thrombolytic therapy in this patient with right atrial thrombus. Echocardiography, transthoracic or transesophageal, allows visualization of thrombi in the chambers of the right side of the heart and the proximal pulmonary arterial trunk, making preliminary assessment of embolization possible should clinical deterioration occur promptly after thrombolytic therapy. In patients with right atrial thrombus, we recommend the use of transthoracic echocardiography for prompt assessment of effectiveness or complications of thrombolytic therapy.

REFERENCES

1. Cameron J, Pohlner P, Stafford G, et al. Right heart thrombus: recognition, diagnosis and management. J Am Coll Cardiol 1985;5:1239-41.
2. Farfel Z, Schechter M, Vered Z, et al. Review of echocardiographically diagnosed right heart entrapment of pulmonary emboli-in-transit with emphasis on management. Am Heart J 1987;171-8.
3. Proano M, Frye R, Johnson M, et al. Successful treatment of pulmonary embolism and associated mobile right atrial thrombus with use of a central thrombolytic infusion. Mayo Clin Proc 1988;63:1181-5.
4. DallAglio V, Nicolosi G, Zanuttini D, et al. Transthoracic and transesophageal echocardiographic documentation of disappearance of massive right atrial and pulmonary artery thromboemboli after fibrinolytic therapy and normalization of left ventricular dimensions and functions. Eur Heart J 1990;9: 863-5.
5. Jolly N, Kaul U, Khalilullah M, et al. Right atrial thrombus over eustachian valve—successful lysis with streptokinase. Int J Cardiol 1991;3:354-6.