Check for updates

Complex Plaques in the Proximal Descending Aorta

An Underestimated Embolic Source of Stroke

Andreas Harloff, MD; Jan Simon; Stefanie Brendecke; Dawit Assefa, MD; Thomas Helbing, MD; Alex Frydrychowicz, MD; Johannes Weber, MD; Manfred Olschewski, MS; Christoph Strecker, MD; Jürgen Hennig, PhD; Cornelius Weiller, MD; Michael Markl, PhD

Background and Purpose—To investigate the incidence of retrograde flow from complex plaques (≥4-mm-thick, ulcerated, or superimposed thrombi) of the descending aorta (DAo) and its potential role in embolic stroke.

Methods—Ninety-four consecutive acute stroke patients with aortic plaques ≥3-mm-thick in transesophageal echocardiography were prospectively included. MRI was performed to localize complex plaques and to measure time-resolved 3-dimensional blood flow within the aorta. Three-dimensional visualization was used to evaluate if diastolic retrograde flow connected plaque location with the outlet of the left subclavian artery, left common carotid artery, or brachiocephalic trunk. Complex DAo plaques were considered an embolic source if retrograde flow reached a supra-aortic vessel that supplied the territory of visible acute and embolic retinal or cerebral infarction.

Results—Only decreasing heart rate was correlated ($P<0.02$) with increasing flow reversal to the aortic arch. Retrograde flow from complex DAo plaques reached the left subclavian artery in 55 (58.5%), the left common carotid artery in 23 (24.5%), and the brachiocephalic trunk in 13 patients (13.8%). Based on routine diagnostics and MRI of the ascending aorta/aortic arch, stroke etiology was determined in 57 and cryptogenic in 37 patients. Potential embolization from DAo plaques was then identified in 19 of 57 patients (33.3%) with determined and in 9 of 37 patients (24.3%) with cryptogenic stroke.

Conclusions—Retrograde flow from complex DAo plaques was frequent in both determined and cryptogenic stroke and could explain embolism to all brain territories. These findings suggest that complex DAo plaques should be considered a new source of stroke. **(*Stroke*. 2010;41:1145-1150.)**

Key Words: acute stroke ■ aorta ■ atherosclerosis ■ magnetic resonance ■ pathogenesis

Downloaded from http://ahajournals.org by on March 8, 2026

Complex aortic plaques defined as ≥4-mm-thick, ulcerated or containing mobile thrombi are considered a major source of stroke.[1] Although their incidence is highest in the proximal descending aorta (DAo), such plaques are only considered an embolic source of stroke in the unlikely coincidence of severe aortic valve insufficiency causing retrograde flow and embolization in case of plaque rupture.[1,2]

However, there is growing evidence that diastolic retrograde flow in the DAo may be a frequent phenomenon in the presence of atherosclerosis and thus an overlooked mechanism of retrograde embolization in stroke patients. Oscillating thrombus mobility[3] and Doppler flow curves in the DAo in transesophageal echocardiography (TEE) indirectly proved the existence of flow reversal.[4] In contrast to TEE, flow-sensitive 4-dimensional MRI permits the precise analysis of individual 3-dimensional flow patterns at the site of complex DAo plaques.[5–7] Moreover, it allows for a more reliable detection and characterization of aortic plaques compared to TEE.[8,9] In this context, retrograde embolization from complex DAo plaques was recently described as a proof-of-principle and constituted the only probable source of ischemia in the posterior circulation in individual stroke patients of this cohort.[10]

Because of the incomplete coverage of late diastolic retrograde flow by MRI in this study,[10] we hypothesized that its true frequency and the potential to reach all supra-aortic arteries was still underestimated. Therefore, in a newly and consecutively recruited patient cohort we applied both an MRI protocol providing complete temporal coverage and a visualization strategy coregistering plaque location with 3-dimensional blood flow. This allowed analyzing potential embolization pathways from DAo plaques to all brain-supplying arteries. The frequency of this mechanism was systematically evaluated in acute stroke patients with advanced aortic atherosclerosis and determined or cryptogenic stroke etiology.

Received January 2, 2010; accepted February 1, 2010.

From Department of Neurology (A.H., J.S., S.B., C.S., C.W.), Department of Cardiology and Angiology (D.A., T.H.), Department of Diagnostic Radiology Medical Physics (A.F., J.H., M.M.), Department of Neuroradiology (J.W.), University Hospital Freiburg, Freiburg, Germany; Institute of Medical Biometrics and Statistics (M.O.), University of Freiburg, Freiburg, Germany.

Correspondence to Andreas Harloff, MD, University Hospital Freiburg, Department of Neurology, Breisacher Straße 64, 79106 Freiburg, Germany. E-mail andreas.harloff@uniklinik-freiburg.de

© 2010 American Heart Association, Inc.

***Stroke* is available at http://stroke.ahajournals.org** **DOI: 10.1161/STROKEAHA.109.577775**

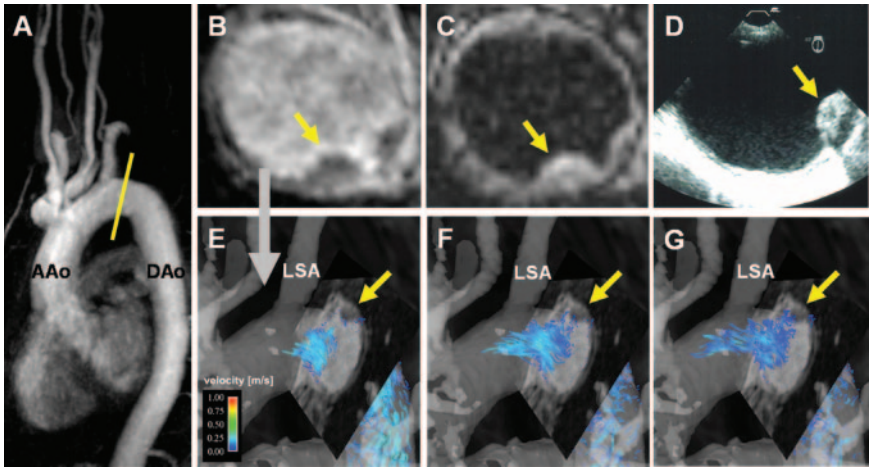

Figure 1. A, Contrast-enhanced angiography indicating the location of a complex plaque 8 mm distal to the outlet of the LSA (yellow bar). The 8-mm-thick, hypointense atheroma can be clearly distinguished in the 2-dimensional T1- and T2-weighted slices (B, C) and was confirmed by TEE (D). The 3-dimensional time-resolved particle traces originating from a virtual emitter plane at the site of this plaque (yellow arrows) demonstrate retrograde blood flow in early (E, F) and late diastole (D) connecting plaque and LSA and almost reaching the outlet of the left CCA. AAo indicates ascending aorta; Dao, descending aorta. Color coding indicates absolute velocities in m/sec.

Materials and Methods

Study Population

Between June 19, 2008 and March 24, 2009, a total of 734 consecutive and unselected patients were admitted to our institution because of acute retinal/cerebral ischemia. Three hundred fourteen of them underwent TEE following a previously recommended algorithm[11] if stroke etiology was cryptogenic after routine diagnostics. Subjects with atrial fibrillation/flutter or symptomatic high-grade ICA stenosis undergoing TEE were excluded because of the known stroke etiology, incompatibility with the ECG trigger in MRI, or both. One hundred seventy-two consecutive patients fulfilled the inclusion criteria of acute retinal/cerebral ischemia, age 18 years or older, and aortic plaque thickness ≥3 mm in TEE.

Thirty-two patients declined participation and 20 patients had contraindications against MRI at 3 T. Fourteen patients were excluded because of unstable clinical conditions (n=2), incomplete compliance (n=4), body mass index exceeding 42 (n=2), transfer to another clinic before MRI (n=4), or because of severe back pain or infectious diarrhea (n=2).

Twelve of the remaining 106 patients interrupted MRI examination before completion or MRI data quality was insufficient. Thus, our prospective analyses focused on the remaining 94 patients. Written informed consent was obtained from each participant. The study was approved by the local ethics committee.

Routine Diagnostics

Cardiovascular risk factors and severity of stroke on admission were assessed according to the National Institute of Health stroke severity score.[12]

Brain MRI was performed in 88 patients (93.6%). In 6 patients (6.4%) brain MRI could not be realized before discharge and these patients received only brain CT. MRI and CT were performed in 41 patients (43.6%). Eighty-four patients (89.4%) underwent intracranial time-of-flight MR angiography; 3 received additional CT or digital subtraction angiography. All 94 patients underwent Doppler or 2-dimensional Duplex sonography of extracranial and intracranial arteries, transthoracic echocardiography (TTE), TEE, 12 lead ECG, and Holter ECG. One patient with persistent monocular visual loss underwent funduscopy.

Echocardiographic Examinations

TTE and TEE were performed by 2 experienced echocardiographers using 2 to 4 MHz and 5 to 7 MHz multiplane probes (HDI 5000; Philips). All videotaped echocardiograms were reviewed offline regarding plaque location and morphology by 1 echocardiographer who was blinded to patients' demographics and results of diagnostic tests. Identification of aortic pathologies included grading of aortic valve insufficiency.[11,13]

The aortic arch (AA) reached from the outlet of the brachiocephalic trunk (BCT) to the left subclavian artery (LSA). Segments proximal to the BCT and distal to the LSA outlet were defined ascending aorta and DAo, respectively. Maximum aortic wall thickness was measured manually in magnification using electronic calipers. Ulcerated plaques showed an indentation of the luminal surface with base width and maximum depth of at least 2 mm.

Brain Imaging

One neuroradiologist who had only access to brain imaging data determined the existence of acute brain ischemia or vessel occlusion, the brain territory affected, stroke pattern,[10] and calculated narrowing of intracranial and vertebrobasilar arteries based on criteria of a former study.[14]

MRI of the Aorta

MRI of the aorta (n=94) was performed using a 3-T MRI (TRIO; Siemens). Patients with a glomerular filtration rate ≥40 mL/min underwent time-resolved contrast-enhanced 3-dimensional MR angiography (0.1 mL/kg gadobenate dimeglumine at 3.5 mL/sec) of the aorta. High-resolution MRI ($0.9\times1.1\times1.1$ mm^3) covering the entire upper thoracic aorta was performed for plaque detection (ECG-gated T1-weighted fat-saturated 3-dimensional gradient echo imaging; diastolic acquisition window=157 ms; time to echo [TE]/time to repeat [TR]=2.3 ms/5.5 ms; flip angle=20°).[8] At the site of DAo plaques ≥4 mm, additional ECG-gated T2-weighted 2-dimensional turbo spin-echo imaging (TE=78 ms) was performed (TR=2 cardiac cycles; spatial resolution=$1.1\times1.2\times3$ mm^3). The 3-dimensional T1 cinematographic (CINE) imaging (TE/TR=1.8 ms/3.3 ms; temporal/spatial resolution=53 ms/$1.3\times1.5\times1.3$ mm^3) was used to detect mobile plaque components. Finally, ECG-synchronized flow-sensitive 4-dimensional MRI was executed (TE/TR=2.6 to 3.5 ms/5.1–6.1 ms; flip angle=7°–15°; temporal/spatial resolution=40.8 ms/$1.7\times2.0\times2.2$ mm^3). Data were acquired with 3-directional velocity encoding (velocity sensitivity= 150 cm/sec) and complete coverage of the thoracic aorta. Respiratory gating was used for both 3-dimensional T1 and flow-sensitive 4-dimensional MRI.[15] Blood pressure levels of the upper arm were recorded before and after MRI examination. Heart rate was documented every 4 minutes during flow measurement.

Multiplane reformatting (J-Vision; Tiani Medgraph AG) was used to localize complex plaques in analysis planes normal to the aortic lumen and to determine maximum wall thickness.[8] Aortic thrombi were defined as plaques with eccentric protrusion into the lumen, hypointense signal in T1, and motion of plaque components in 3-dimensional T1-CINE images. The definition of plaque ulceration was identical to that in echocardiography. Two readers blinded to patients' data and the results of other diagnostics evaluated MR plaque images in consensus reading and involved a third blinded reader in case of disagreement for final decision.

On a case-by-case basis, 2-dimensional analysis planes of complex DAo plaques were coregistered with flow-sensitive

Downloaded from http://ahajournals.org by on March 8, 2026

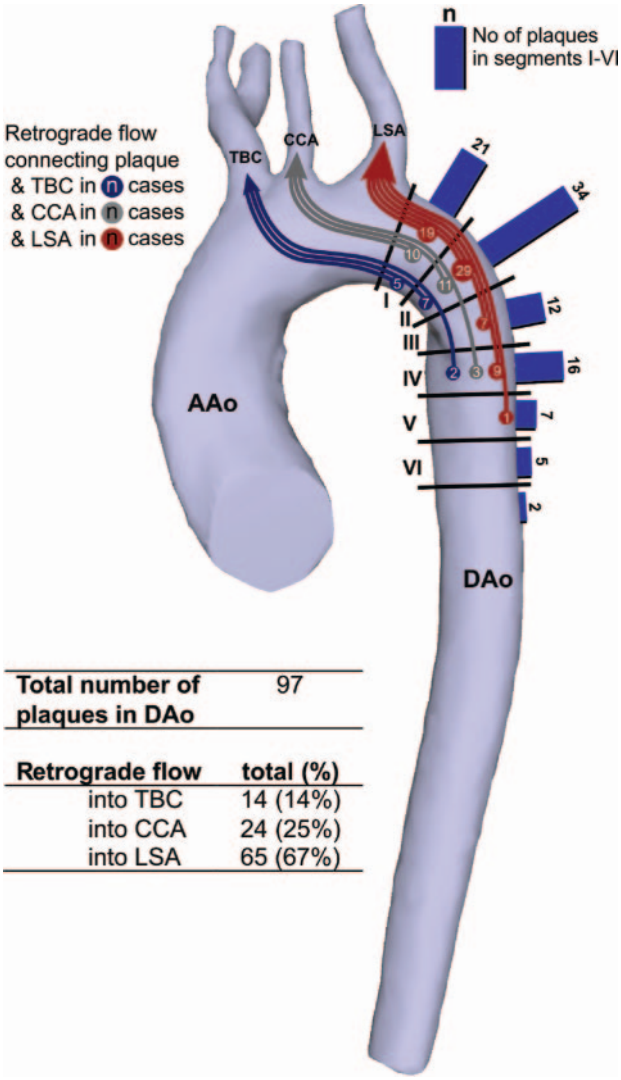

Figure 2. Cumulative results regarding the numbers of complex descending aortic plaques (blue bars) and retrograde flow (arrows) to the brain-supplying arteries in 94 patients. Plaque location and origin of flow are grouped into 6 sections of the DAo with an intersegment distance of 10 mm. Arrows illustrate the number of directly visualized 3-dimensional flow channels originating from complex plaques in sections I to VI and reaching the LSA (red), the CCA (gray), and the brachiocephalic trunk (TBC, dark blue).

4-dimensional MRI data via image fusion (EnSight; CEI). An emitter plane was positioned exactly at the site of the plaque and used to generate time-resolved 3-dimensional particle traces. The calculated traces resembled time-resolved 3-dimensional blood flow[10] and could thus visualize diastolic retrograde flow originating from the atheroma as shown in Figure 1.

Stroke Subtyping

Based on modified TOAST criteria,[16] stroke etiology was classified by 1 neurologist blinded to patients identity and to MRI results regarding the DAo (Table 2). Spontaneous echo contrast of the left atrium, left atrial appendage velocity <30 cm/sec, persistent foramen ovale with associated atrial septum aneurysm and acute evidence of a deep venous thrombosis or pulmonary embolism or recent prolonged travel/immobilization or Valsalva maneuver preceding the event (cardioembolism), and complex plaques of the ascending aorta/aortic arch as detected by TEE or MRI (large-artery atherosclerosis) were also considered probable stroke etiologies.[11] Cases of a definite cause of stroke (including multiple probable sources) were classified as determined; those with no definite source were classified as cryptogenic etiology.

Table 1. Baseline Characteristics of the 94 Stroke Patients

Characteristic	Value
Age, yr	67.5±8.6
Female, N (%)	32 (34.0)
Hypertension, N (%)	81 (86.2)
Hyperlipidemia, N (%)	33 (35.1)
Diabetes, N (%)	26 (27.7)
Smokers, N (%)	25 (26.6)
Obesity, N. (%)	24 (25.5)
Previous stroke/TIA, N (%)	18 (19.1)
Coronary heart disease, N (%)	12 (12.8)
Peripheral arterial disease, N (%)	9 (9.6)
NIH stroke scale	
0, N (%)	21 (22.3)
1, N (%)	15 (16.0)
2–4, N (%)	35 (37.2)
5–10, N (%)	19 (20.2)
≥11, N (%)	4 (4.3)

Values are given as mean±SD or as absolute numbers (%).

Retrograde Embolization

Maximum retrograde flow and location of complex DAo plaques was assessed as described previously.[10] On a visual basis, 1 reader assessed the presence of individual embolic pathways from complex plaques located in predefined 10-mm sections of the DAo as illustrated in Figure 2. Retrograde embolization was defined present if: (1) retrograde flow originating at the site of a complex DAo plaque reached the outlet of a supra-aortic great artery; (2) that artery matched with the territory affected by acute ischemia; and (3) it was clearly documented by an embolic pattern of infarction in funduscopy or brain imaging. In patients with flow reaching all 3 brain-feeding arteries, retrograde embolization was judged existent even if acute infarction or vessel occlusion was not visible in brain imaging.

Statistical Analysis

Data are presented as mean±standard deviation for continuous and absolute and relative frequencies for categorical variables. Univariate logistic regression analysis was performed to detect a correlation of the extent of retrograde flow <25 mm vs ≥25 mm with patients' baseline characteristics, MRI (maximum wall thickness, aortic lumen diameter), or echocardiographic data (ejection fraction, grade of aortic valve insufficiency); 25 mm was the median of retrograde flow of all patients and was chosen as the cut-off. Results are presented as odds ratios (OR) with 95% confidence intervals (CI). All tests performed were 2-sided and used 0.05 as level of statistical significance (SAS statistical package, version 8.2; SAS).

Results

Baseline Findings

Patients' characteristics and stroke subtypes according to the modified TOAST classification are summarized in Tables 1 and 2. All patients underwent TEE and MRI of the aorta within a median of 6 days after admission. The median for the time between TEE and aortic MRI was 3 days. MRI scan duration was 64±16 minutes (range, 37–120 minutes).

Downloaded from http://ahajournals.org by on March 8, 2026

Table 2. Stroke Subtypes of the 94 Stroke Patients

TOAST Classification	Value
Group I, Determined etiology	57 (60.6%)
Cardioembolism	11 (11.7%)
Large artery atherosclerosis	42 (44.7%)
Small vessel disease	3 (3.2%)
Other	1 (1.1%)
Group II, Cryptogenic stroke	37 (39.4%)

Classification of stroke etiology is based on the findings of routine diagnostics including TEE and on MRI of the ascending aorta/aortic arch. Accordingly, the proposed stroke mechanism of retrograde embolization was not considered. Values are given as absolute numbers (%).

Retrograde Embolization: Analysis on a Plaque Level

In Figure 2, the distribution of the 97 complex plaques of all patients is displayed along the predefined sections of the DAo. Furthermore, the frequency of flow reversal able to connect plaque location with the outlet of the LSA, left CCA, or BCT is given. As an example, retrograde flow originating in the most proximal 10 mm of the DAo (section I) reached the LSA from 19 of 21 (90.5%) and the CCA from 10 of 21 (47.6%) plaques. Flow reversal to the BCT was least likely but still present in 5 of 21 plaques (23.8%). The probability that retrograde flow reached the LSA, CCA, or even the BCT steadily decreased with the distance of plaque location from the LSA (compare flow reversal from segment I vs V). Summarizing all potential embolic pathways, retrograde flow reached the LSA from 65 (67.0%), reached the CCA from 24 (24.7%), and reached the BCT from 14 (14.4%) complex plaques.

Analysis on a Patient Level

Some patients showed multiple complex DAo plaques. Therefore, analysis of potential retrograde embolization on a patient level (Figure 3) is different from findings on a plaque level (Figure 2). Reverse flow connected complex DAo atheroma with the LSA in 55 (58.5%), the CCA in 23 (24.5%), and BCT in 13 patients (13.8%; Figure 3). When results of all routine diagnostics, including TEE and MRI of the ascending aorta/aortic arch, were considered, 57 patients (60.6%) were classified as having determined stroke and 37 patients (39.4%) were classified as having cryptogenic stroke. In these 2 subgroups the proposed mechanism (retrograde embolization from DAo plaques) was found in 19 of 57 patients (33.3%) with determined and in 9 of 37 patients (24.3%) with cryptogenic stroke. Brain infarction affected the posterior circulation in 6, the left hemisphere in 2, and the right hemisphere in 1 of the patients with cryptogenic stroke.

Plaque and Retroflow Characteristics

The 97 complex DAo plaques detected by MRI in 71 patients (Figure 2) were located 21.9±15.3 mm (range, 0–72.7 mm) distal to the LSA outlet; 67 of 97 plaques (69.1%) were located in the first 3 cm and 30 of 71 patients also had complex plaques in the ascending aorta/aortic arch. In the 94 patients of this study, MRI detected the following number of complex plaques/thrombi: ascending aorta, 13/0; aortic arch, 34/2; and Dao, 97/7.

In the 20 complex DAo plaques of the 19 patients with determined stroke etiology and the proposed stroke mechanism, plaque thickness was 6.6±2.4 mm (range, 4.2–14.0 mm), 3 of them contained superimposed thrombi, and 1 was ulcerated. Analogously, in the 11 complex DAo plaques of the 9 patients with cryptogenic stroke, plaque thickness was 5.0±1.2 mm (range, 4.1–8.0 mm), 1 plaque had a superimposed thrombus, and 1 was ulcerated.

The average distance covered by reverse flow in the proximal DAo that reached the LSA outlet was 26.6±12.1 mm (range, 0–50 mm). Only decreasing heart rate correlated with increasing retrograde flow length in the proximal DAo ($r=-0.24$; $P=0.018$), whereas cardiovascular risk factors, age, aortic valve insufficiency, or aortic wall thickness did not. The OR for increasing retrograde flow per decreasing 10 heartbeats per minute was 0.63 (95% CI, 0.42–0.93).

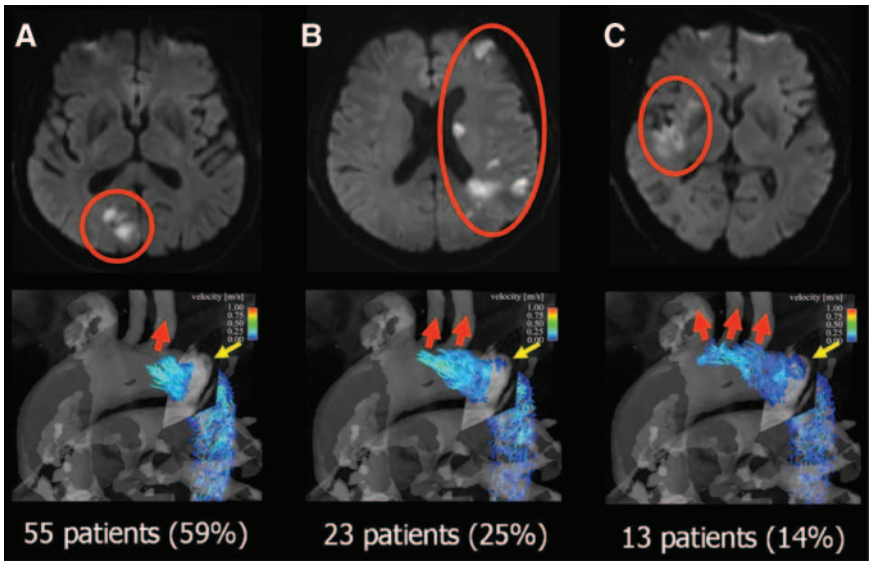

Figure 3. Upper row, Diffusion-weighted cranial MR imaging. Lower row, Time-resolved 3-dimensional particle traces visualize potential embolization pathways from complex plaques in the proximal descending aorta (2-dimensional plane, yellow arrow) to the outlet of the brain-supplying arteries (red arrows). Flow reversal to the LSA potentially causes stroke (red circles) in the posterior circulation (A) or to the CCA, or brachiocephalic trunk potentially causes stroke in the left (B) or right hemisphere (C). The number of patients with potential retrograde embolization into the particular supra-aortic great artery is given in absolute values and in percentages in relation to the 94 patients.

Downloaded from http://ahajournals.org by on March 8, 2026

Discussion

Complete coverage of late diastolic flow, improved data analysis, and inclusion of stroke patients with advanced aortic atherosclerosis revealed that flow reversal from complex DAo plaques potentially reaches all supra-aortic arteries. This was previously not demonstrable[10] and extends the hazard of this potential stroke mechanism to all brain territories. In addition, retrograde embolization was frequent. It constituted the only probable source of retinal or cerebral infarction in 24% of the patients with cryptogenic stroke etiology. None of these had stenoses of the internal carotid or vertebral arteries of ≥30%. Moreover, retrograde embolization was an alternative source in 33% of the patients with determined stroke etiology. Based on these findings and the high incidence of complex DAo plaques of 8% in determined and 28% in cryptogenic stroke,[17] one could speculate that retrograde embolization may be found in up to 3% (one-third of 8%) and 7% (one-fourth of 28%) in serial unselected patients with determined and cryptogenic stroke.

The association of complex plaques and cerebral embolization was demonstrated in previous stroke cohorts[17–21] but questioned in 2 population-based studies.[22,23] In the present study, plaque rupture in the DAo and subsequent thromboembolism to the brain was not proven. However, the following factors suggest a causal link: the mechanism of retrograde embolization was directly visualized, constituted the only embolic source in a number of patients with cryptogenic stroke despite a detailed diagnostic work-up, and was associated with a visible embolic pattern of retinal or cerebral infarction. Moreover, flow reversal reached the adjacent outlet of the left subclavian artery more frequently than the distant brachiocephalic trunk. Accordingly, the posterior circulation was affected more often compared to the right and left hemisphere in the 9 patients with otherwise cryptogenic stroke. Finally, the mechanism is biologically plausible because incidence, thickness of plaques, and thus the risk of rupture is highest in the proximal DAo.[10,17] The proposed stroke mechanism may be confirmed using emboli detection in Doppler ultrasound.[24] Thus, a synchronous examination of both middle cerebral arteries and of the basilary artery should be performed in future studies.

Our results are supported by the large, case-control study by Amarenco et al[17] demonstrating a crude OR of 13.8 for complex plaques in the ascending aorta/aortic arch and stroke. In this study, the OR for stroke was still 5.5 for the proximal but only 1.5 for the distal straight segment of the descending aorta. [17] Our study provides 1 pathophysiological explanation for these findings: there is a high likelihood of retrograde cerebral embolization originating from complex plaques of the proximal but not of the distal DAo.

In the current cohort, aortic valve insufficiency did not correlate with retrograde flow. This confirms our previous findings[10] and contradicts current beliefs that flow reversal is rare and only present in coincidence with aortic valve insufficiency.[1,2] An increase of retrograde flow with age[10] as a result of the decrease of the Windkessel function of the aorta was not reproduced and could be attributable to the limited number or different characteristics of the patients. Currently, only decreasing heart rate correlated with increasing flow reversal. Future examinations of larger cohorts are thus necessary to identify robust predictors for retrograde flow.

The best medical treatment of aortic plaques has not yet been determined.[1,25,26] This is the aim of the ongoing first prospective, randomized, controlled Aortic Arch-Related Cerebral Hazard trial comparing aspirin plus clopidogrel with warfarin in aortic high-risk plaques. However, this trial and 2 other large but retrospective studies[25,26] do not consider plaques in the DAo as a source of stroke. This fact may significantly limit the results with respect to the true embolic relevance and best medical treatment of complex aortic atheroma.

Our study focused on consecutive acute patients with cryptogenic stroke and aortic wall thickness ≥3 mm in TEE. Therefore, we cannot exclude that some individuals with complex aortic plaques were erroneously excluded because of the limited visualization of the aortic arch by TEE.[8] In addition, 18% of the patients suitable for the study refused to participate and ≈12% had contraindications against 3-T MRI, which may have biased our findings. Furthermore, future improvements of the MRI protocol are needed for robust multicontrast MR imaging[9,27] to optimally assess the risk of plaque rupture.

Conclusion

In conclusion, retrograde flow originating from complex plaques of the proximal DAo was frequent and has the potential, as demonstrated here for the first time to our knowledge, to cause embolic stroke in all brain territories. These findings suggest that complex DAo plaques should be considered a new source of stroke. The true incidence and clinical relevance of this mechanism in unselected patients should be evaluated in larger stroke cohorts.

Acknowledgments

The authors thank Adriana Komancsek, Manuela Rick, Annette Merkle, Jutta Will, and Hansjörg Mast for their help and continuous support with respect to the MRI examinations.

Sources of Funding

Dr A. Harloff was supported by Deutsche Forschungsgemeinschaft (DFG), grant MA 2383/4-1. Dr M. Markl is supported by DFG, grant MA 2383/4-1, and by the Bundesministerium für Bildung und Forschung (BMBF), grant 01EV0706.

Disclosures

None.

References

1. Kronzon I, Tunick PA. Aortic atherosclerotic disease and stroke. *Circulation*. 2006;114:63–75.
2. Reimold SC, Maier SE, Aggarwal K, Fleischmann KE, Piwnica-Worms D, Kikinis R, Lee RT. Aortic flow velocity patterns in chronic aortic regurgitation: implications for Doppler echocardiography. *J Am Soc Echocardiogr*. 1996;9:675–683.
3. Tenenbaum A, Motro M, Feinberg MS, Schwammenthal E, Stroh CI, Vered Z, Fisman EZ. Retrograde flow in the thoracic aorta in patients with systemic emboli: a transesophageal echocardiographic evaluation of mobile plaque motion. *Chest*. 2000;118:1703–1708.
4. Svedlund S, Wetterholm R, Volkmann R, Caidahl K. Retrograde blood flow in the aortic arch determined by transesophageal Doppler ultrasound. *Cerebrovasc Dis*. 2009;27:22–28.

Downloaded from http://ahajournals.org by on March 8, 2026

5. Bogren HG, Buonocore MH, Valente RJ. Four-dimensional magnetic resonance velocity mapping of blood flow patterns in the aorta in patients with atherosclerotic coronary artery disease compared to age-matched normal subjects. *J Magn Reson Imaging*. 2004;19:417–427.
6. Kilner PJ, Yang GZ, Mohiaddin RH, Firmin DN, Longmore DB. Helical and retrograde secondary flow patterns in the aortic arch studied by three-directional magnetic resonance velocity mapping. *Circulation*. 1993;88:2235–2247.
7. Wigstrom L, Sjoqvist L, Wranne B. Temporally resolved 3-dimensional phase-contrast imaging. *Magn Reson Med*. 1996;36:800–803.
8. Harloff A, Dudler P, Frydrychowicz A, Strecker C, Stroh AL, Geibel A, Weiller C, Hetzel A, Hennig J, Markl M. Reliability of aortic MRI at 3 Tesla in patients with acute cryptogenic stroke. *J Neurol Neurosurg Psychiatry*. 2008;79:540–546.
9. Fayad ZA, Nahar T, Fallon JT, Goldman M, Aguinaldo JG, Badimon JJ, Shinnar M, Chesebro JH, Fuster V. In vivo magnetic resonance evaluation of atherosclerotic plaques in the human thoracic aorta: a comparison with transesophageal echocardiography. *Circulation*. 2000;101: 2503–2509.
10. Harloff A, Strecker C, Dudler P, Nussbaumer A, Frydrychowicz A, Olschewski M, Bock J, Stalder AF, Stroh AL, Weiller C, Hennig J, Markl M. Retrograde embolism from the descending aorta: visualization by multidirectional 3-dimensional velocity mapping in cryptogenic stroke. *Stroke*. 2009;40:1505–1508.
11. Harloff A, Handke M, Reinhard M, Geibel A, Hetzel A. Therapeutic strategies after examination by transesophageal echocardiography in 503 patients with ischemic stroke. *Stroke*. 2006;37:859–864.
12. Lyden P, Brott T, Tilley B, Welch KM, Mascha EJ, Levine S, Haley EC, Grotta J, Marler J. Improved reliability of the NIH Stroke Scale using video training. NINDS TPA Stroke Study Group. *Stroke*. 1994;25: 2220–2226.
13. Evangelista A, del Castillo HG, Calvo F, Permanyer-Miralda G, Brotons C, Angel J, González-Alujas T, Tornos P, Soler-Soler J. Strategy for optimal aortic regurgitation quantification by Doppler echocardiography: agreement among different methods. *Am Heart J*. 2000;139:773–781.
14. Samuels OB, Joseph GJ, Lynn MJ, Smith HA, Chimowitz MI. A standardized method for measuring intracranial arterial stenosis. *AJNR Am J Neuroradiol*. 2000;21:643–646.
15. Markl M, Harloff A, Bley TA, Zaitsev M, Jung B, Weigang E, Langer M, Hennig J, Frydrychowicz A. Time-resolved 3-dimensional MR velocity mapping at 3T: improved navigator-gated assessment of vascular anatomy and blood flow. *J Magn Reson Imaging*. 2007;25:824–831.
16. Adams HP Jr, Bendixen BH, Kappelle LJ, Biller J, Love BB, Gordon DL, Marsh EE III. Classification of subtype of acute ischemic stroke. Definitions for use in a multicenter clinical trial TOAST Trial of Org 10172 in Acute Stroke Treatment. *Stroke*. 1993;24:35–41.
17. Amarenco P, Cohen A, Tzourio C, Bertrand B, Hommel M, Besson G, Chauvel C, Touboul PJ, Bousser MG. Atherosclerotic disease of the aortic arch and the risk of ischemic stroke. *N Engl J Med*. 1994;331: 1474–1479.
18. The French Study of Aortic Plaques in Stroke Group. Atherosclerotic disease of the aortic ach as a risk factor for recurrent ischemic stroke. *N Engl J Med*. 1996;334:1216–1221.
19. Ward RP, Don CW, Furlong KT, Lang RM. Predictors of long-term mortality in patients with ischemic stroke referred for transesophageal echocardiography. *Stroke*. 2006;37:204–208.
20. Sen S, Hinderliter A, Sen PK, Simmons J, Beck J, Offenbacher S, Ohman EM, Oppenheimer SM. Aortic arch atheroma progression and recurrent vascular events in patients with stroke or transient ischemic attack. *Circulation*. 2007;116:928–935.
21. Fujimoto S, Yasaka M, Otsubo R, Oe H, Nagatsuka K, Minematsu K. Aortic arch atherosclerotic lesions and the recurrence of ischemic stroke. *Stroke*. 2004;35:1426–1429.
22. Meissner I, Khandheria BK, Sheps SG, Schwartz GL, Wiebers DO, Whisnant JP, Covalt JL, Petterson TM, Christianson TJ, Agmon Y. Atherosclerosis of the aorta: risk factor, risk marker, or innocent bystander? A prospective population-based transesophageal echocardiography study. *J Am Coll Cardiol*. 2004;44:1018–1024.
23. Russo C, Jin Z, Rundek T, Homma S, Sacco RL, Di Tullio MR. Atherosclerotic disease of the proximal aorta and the risk of vascular events in a population-based cohort: the Aortic Plaques and Risk of Ischemic Stroke (APRIS) study. *Stroke*. 2009;40:2313–2318.
24. Ritter MA, Dittrich R, Thoenissen N, Ringelstein EB, Nabavi DG. Prevalence and prognostic impact of microembolic signals in arterial sources of embolism. A systematic review of the literature. *J Neurol*. 2008;255: 953–961.
25. Tunick PA, Nayar AC, Goodkin GM, Mirchandani S, Francescone S, Rosenzweig BP, Freedberg RS, Katz ES, Applebaum RM, Kronzon I; NYU Atheroma Group. Effect of treatment on the incidence of stroke and other emboli in 519 patients with severe thoracic aortic plaque. *Am J Cardiol*. 2002;90:1320–1325.
26. Di Tullio MR, Russo C, Jin Z, Sacco RL, Mohr JP, Homma S; Patent Foramen Ovale in Cryptogenic Stroke Study Investigators. Aortic arch plaques and risk of recurrent stroke and death. *Circulation*. 2009;119: 2376–2382.
27. Saam T, Hatsukami TS, Takaya N, Chu B, Underhill H, Kerwin WS, Cai J, Ferguson MS, Yuan C. The vulnerable, or high-risk, atherosclerotic plaque: noninvasive MR imaging for characterization and assessment. *Radiology*. 2007;244:64–77.

Downloaded from http://ahajournals.org by on March 8, 2026