View metadata, citation and similar papers at core.ac.uk
brought to you by CORE
provided by Elsevier - Publisher Connector

JACC Vol. 13, No. 7
June 1989:1514–20

Left Ventricular Thrombus Incidence and Behavior Studied by Serial Two-Dimensional Echocardiography in Acute Anterior Myocardial Infarction: Left Ventricular Wall Motion, Systemic Embolism and Oral Anticoagulation

ALBERT J. FUNKE KÜPPER, MD, FREEK W.A. VERHEUGT, MD, FACC,
CATHINKA H. PEELS, MD, TJEBBE W. GALEMA, MD, JAN P. ROOS, MD
Amsterdam, The Netherlands

Serial two-dimensional echocardiography was performed to detect left ventricular thrombus in 92 consecutive patients with a confirmed first acute anterior myocardial infarction. Thirty left ventricular thrombi were diagnosed in these 92 patients. The cumulative percent of identified thrombus in each echocardiographic examination in the surviving patients was 27% at <24 h; 57% at 48 to 72 h; 75% at 1 week and 96% at 2 weeks. The thrombus shape was defined as mural in 53% and protruding in 47% of patients. Systemic embolism (stroke) was noted during hospitalization in two patients with a protruding thrombus.

At 12 weeks of follow-up, patients with thrombus had poorer (and almost unchanged from baseline) global left ventricular function as expressed by wall motion score compared with that of patients without thrombus, who exhibited significant improvement. Global left ventricular wall motion in patients with persisting or resolved thrombus was similar during follow-up. Apical wall motion worsened in 70% of the patients with persisting thrombus and in 25% of the patients with resolved thrombus ($p < 0.1$). In the 22 surviving patients with thrombus, resolution or change in thrombus shape or size was noted in 14 of the 15 patients receiving anticoagulant therapy and in 4 of the 7 untreated patients. Six of the 18 patients with an early- (48 to 72 h) and none of the 12 patients with a later-formed thrombus died. Maximal serum enzyme levels, percent with Killip functional class III to IV and left ventricular wall motion score were higher in the patients with an early- than in those with a later-formed thrombus.

Thus, left ventricular thrombus was found in 33% of patients with a first anterior myocardial infarction. Thrombus formation within 48 to 72 h was associated with a poor prognosis. Two-dimensional echocardiography performed the 3rd day and after 2 weeks had the most clinical value in assessing early prognosis and identifying left ventricular thrombus. The presence or absence of thrombus was strongly correlated with a change in left ventricular function during follow-up. In patients treated with oral anticoagulant agents, 93% of the left ventricular thrombi showed resolution or change in size or shape.

(J Am Coll Cardiol 1989;13:1514–20)

Two-dimensional echocardiography has proved to be a reliable tool in the diagnosis of left ventricular thrombus (1–3). Many investigators (4–19) have studied the pathogenesis of left ventricular thrombus and the effect of different antithrombotic regimens. Only a few studies (1,18,20–25) have prospectively investigated with serial two-dimensional echocardiography the prognostic significance of left ventricular thrombus and the occurrence of spontaneous or drug-induced regression of the left ventricular thrombus in a large group of patients.

We performed serial two-dimensional echocardiography at short intervals during the acute phase of anterior myocardial infarction and after 12 weeks in a consecutive series of 100 patients. The objectives of the study were 1) to identify patients at risk for left ventricular thrombus by means of echocardiographic and clinical data, and 2) to study the relation between the left ventricular wall motion, the occur-

From the Department of Cardiology, Free University Hospital, Amsterdam, The Netherlands. This study was supported in part by Grant 85.048 from the Dutch Heart Foundation, Den Haag, The Netherlands.

Manuscript received September 29, 1988; revised manuscript received December 7, 1988, accepted December 16, 1988.

Address for reprints: Albert J. Funke Küpper, MD, Department of Cardiology, Free University Hospital, De Boelelaan 1117, 1007 MB Amsterdam, The Netherlands.

©1989 by the American College of Cardiology

0735-1097/89/$3.50

rence and regression of thrombus, thrombus shape and the effect of treatment with oral anticoagulant agents.

Methods

Study patients. With serial two-dimensional echocardiography, we studied 100 consecutive patients with a first acute anterior myocardial infarction and interpretable echocardiographic images. The diagnosis of acute anterior myocardial infarction was based on the following criteria: a typical history of anginal pain, elevation of serum creatine kinase (CK) and creatine kinase isoenzyme (MB CK) and characteristic electrocardiographic (ECG) changes with ≥2 mm ST segment elevation in leads V_1 to V_6 or ≥1 mm elevation in lead I or aVL, or both. The diagnosis of first anterior myocardial infarction was based on the patient's history and interpretation of the first ECG. Of the 100 patients, 8 were excluded from the study (5 who did not develop myocardial infarction, 1 whose echocardiographic images were of poor quality and 2 who died before the first echocardiogram).

All 92 patients received standard coronary care. Antithrombotic therapy consisted of aspirin in 50 patients (part of a randomized placebo-controlled trial), heparin (5,000 IU twice daily subcutaneously during immobilization in all patients) and thrombolytic therapy (streptokinase, 1.5×10^6 IU intravenously) in patients <71 years old who were admitted within 4 h after the onset of symptoms.

Collected clinical data were clinical or hemodynamic Killip classification, maximal serial CK, MB CK and lactate dehydrogenase (LDH) levels, occurrence of systemic embolism and ventricular arrhythmia and the use of beta-adrenergic blocking agents or calcium channel antagonists.

Oral anticoagulant therapy was given after detection of left ventricular thrombus in patients with no contraindication for oral anticoagulation. It was begun after the fourth echocardiogram at hospital discharge and was managed by a special outpatient laboratory. The thrombotest was kept between 120 and 150 s.

Two-dimensional echocardiography. In the 92 patients, a total of 379 two-dimensional echocardiographic examinations were performed at <24 h, 48 to 72 hours and 1, 2 and 12 weeks after the onset of symptoms. Echocardiograms were obtained with an ADR 4000 or ATL Mark VIII or HP-77020A ultrasound system with a mechanical or phased array sector scan with use of 2.5, 3.5 and 5 MHz transducers. Optimal gain setting and reject control were used. A systematic echocardiographic examination, performed with the patients in the left supine position, included multiple parasternal short-axis views and apical two, three and four chamber views (Fig. 1).

Left ventricular thrombus was defined as an echo-dense mass in the left ventricular cavity, distinguishable in at least two views and attached to an asynergic left ventricular wall segment (26). The shape of the thrombus was described as mural if its free margin was concave and followed the curvature of the left ventricular wall. If its blood interface showed a curvature opposite to that of the left ventricular wall, the shape was termed protruding. The thrombus was defined as mobile if it showed motion independent of that of the adjacent left ventricular wall segment. A significant decrease in thrombus shape and size was defined, respectively, as a change from protruding to mural and a >5 mm decrease in maximal thickness. Measurement of maximal thrombus thickness was made perpendicular to the myocardium from the epicardial-pericardial interface to the innermost border of thrombus-blood interface.

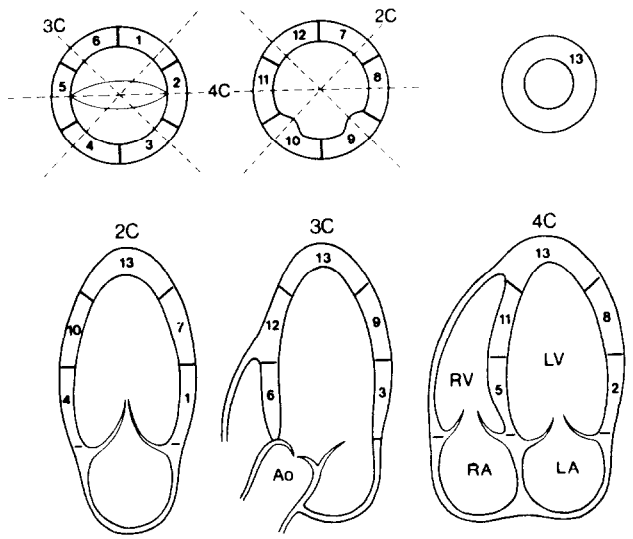

Figure 1. Apical two (2C), three (3C) and four (4C) chamber views of the left ventricle on two-dimensional echocardiography. The left ventricle (LV) is divided into 13 segments. Left ventricular wall motion score is calculated from the cumulative numeric score of each segment: normokinesia = 0, hypokinesia = +1, akinesia = +2, dyskinesia = +3, aneurysm = +4, hyperkinesia = −1. LA = left atrium; RA = right atrium; RV = right ventricle.

All images were stored on videotape and interpreted at the end of the entire study without knowledge of date by two independent observers experienced in echocardiography. When images were equivocal, the interpretation of a third investigator was decisive.

Left ventricular wall motion analysis. Wall motion was assessed from the echocardiographic short-axis and apical two, three and four chamber views. In these two-dimensional planes, the left ventricle was divided into 13 segments as previously described (Fig. 1) (26). The left ventricular wall motion score was calculated from a numeric score of each segment on the basis of the wall motion during systole (normal = 0, hypokinetic = +1, akinetic = +2, dyskinetic = +3, aneurysm = +4, hyperkinetic = −1). Left ventricular wall motion was scored by two observers; when

JACC Vol. 13, No. 7
June 1989:1514–20

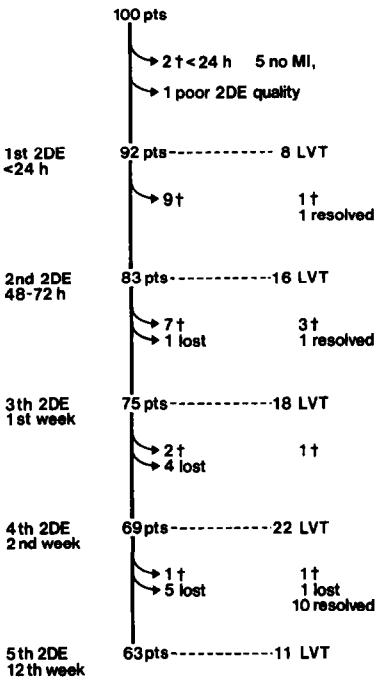

Figure 2. Number of patients studied with serial two-dimensional echocardiography (2DE) during the 12 week follow-up period. lost = lost to follow-up (acute cholecystitis in 1, admission to another hospital in 3, not cooperative or living in another area in 6 patients), LVT = left ventricular thrombus; MI = myocardial infarction; pts = patients; † = died.

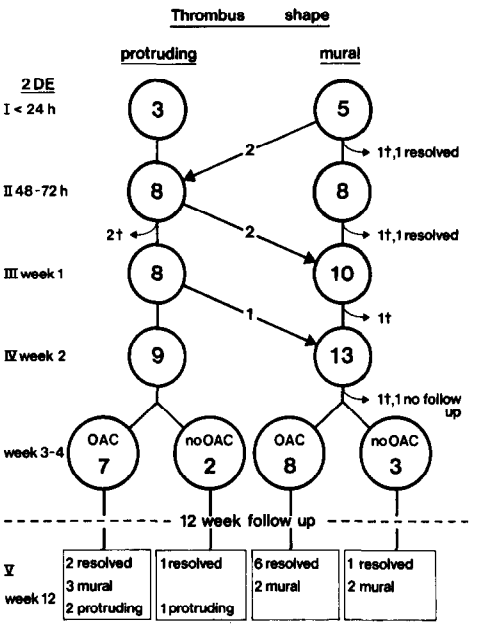

Figure 3. Follow-up data in 30 patients with left ventricular thrombus. Relation of clinical course to thrombus shape and treatment with oral anticoagulation. † = died.

the result was equivocal, the score was averaged. Interobserver agreement was 93%.

Results

Incidence of left ventricular thrombus. Figure 2 summarizes the number of patients who were followed up by two-dimensional echocardiography or were lost to the study or died during the study period. With serial echocardiography, a cumulative number of 8, 18, 24, 29 and 30 left ventricular thrombi were detected in the 92 patients. We calculated the percent of identified thrombus at each echocardiographic examination in the surviving patients (resolved thrombi not included). The cumulative percents was 27% (8 of 30) at <24 h; 57% (16 of 28) at 48 to 72 h; 75% (18 of 24) at 1 week and 96% (22 of 23) at 2 weeks. Thus, an echocardiogram performed approximately 2 weeks after the onset of symptoms offered the best chance to detect persisting left ventricular thrombus in patients surviving anterior myocardial infarction.

Left ventricular thrombus shape, treatment and follow-up. Figure 3 indicates the shape of the thrombus at first detection and the change in shape or resolution during follow-up and the relation to anticoagulant therapy. In 53% of patients, the shape of the thrombus was mural only, and in 47%, the thrombus was protruding in one or more echocardiographic examinations. Transient thrombus mobility was noted in three patients. During the hospitalization period, five thrombi showed a change in shape and two resolved spontaneously. Oral anticoagulant therapy was started in the 3rd and 4th weeks after infarction in seven of the nine patients with a protruding thrombus and resulted in thrombus resolution, decrease in size and change in shape in two, one and three patients, respectively. Eight of the 11 patients with a mural thrombus were given an anticoagulant; in 6 the thrombus resolved and in 2 it decreased in size. In 7 of the 20 patients with left ventricular thrombus who were not treated with an oral anticoagulant, two thrombi showed resolution during hospitalization, two resolved during follow-up and three remained unchanged or increased in size.

The use of aspirin did not influence the incidence of left ventricular thrombus. In both the aspirin (n = 45) and the placebo (n = 47) groups 15 thrombi were found. No difference was observed in the number of left ventricular thrombi detected in patients receiving streptokinase (15 of 43) and those without thrombolytic therapy (15 of 49) in the acute phase of myocardial infarction.

Left ventricular wall motion. Figure 4 shows left ventricular wall motion in patients with or without left ventricular thrombus in one of the five echocardiographic studies obtained. These results suggest that the severity of left ventricular damage plays a role in the development of left ventricular thrombus. Resolution of thrombus was not correlated with improvement in global left ventricular function. There was no difference in the wall motion score of the 10 patients

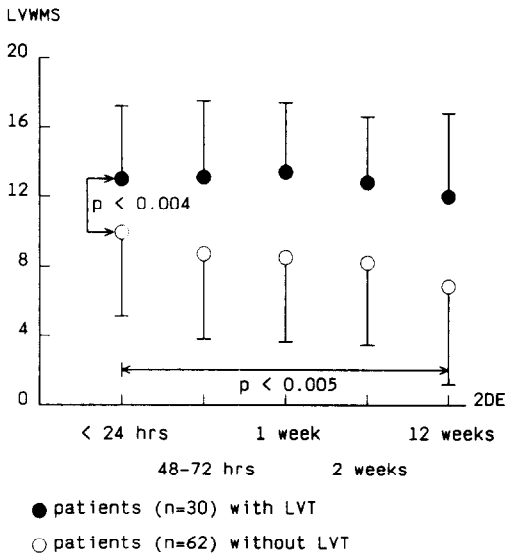

Figure 4. Serial two-dimensional echocardiography (2DE) and left ventricular wall motion score (LVWMS) in 92 patients with and without left ventricular thrombosis (LVT).

Table 1. Relation Between Change in Left Ventricular Apical Wall Motion and Thrombus Resolution or Persistence on Two-Dimensional Echocardiography in 22 Patients

First Study With LVT	12th Week Study
Resolution of thrombus	
6 Akinetic →	1 Normokinetic 3 Akinetic 2 Dyskinetic
4 Dyskinetic →	2 Akinetic 1 Dyskinetic 1 Aneurysm
2 Aneurysm →	2 Aneurysm
Persistence of thrombus	
5 Akinetic →	4 Dyskinetic 1 Aneurysm
4 Dyskinetic →	2 Dyskinetic 2 Aneurysm
1 Aneurysm →	1 Aneurysm

LVT = left ventricular thrombus.

with persisting thrombus and that of the 12 patients whose thrombus showed resolution (Fig. 5).

Table 1 shows the relation between the change in left ventricular apical wall motion and thrombus resolution. Among the 12 patients with thrombus resolution, apical wall motion improved in 3, remained unchanged in 6 and worsened in 3. Among the 10 patients with persisting thrombus, apical wall motion worsened in 7 and improved in none ($p < 0.1$).

Fourteen of the 92 patients developed left ventricular aneurysm during the study, and thrombus was identified in 10 (70%) of this group and in 20 (25%) of the 78 patients without aneurysm ($p < 0.05$).

Clinical correlations and prognosis. The clinical characteristics of patients with and without left ventricular thrombus are listed in Table 2. Differences were observed in maximal serum enzyme levels and Killip functional class. The number of Q waves in leads I, aVL and V_1 to V_6 on the last ECG during hospitalization or just before death did not differ between these groups.

Although the mortality rate in patients with (6 [20%] of 30) and without (13 [21%] of 62) left ventricular thrombus was not different, all 6 patients with thrombus who died had detectable thrombus at the first or second echocardiographic study (Table 1). No patient died who developed thrombus 48 to 72 h after acute myocardial infarction ($p < 0.02$). Left ventricular wall motion score calculated from the first echocardiogram (<24 h) was higher in patients with early thrombus formation than in patients with late or no thrombus formation.

Cerebral embolism occurred in two patients during hospitalization, both with a protruding left ventricular thrombus and not treated with an oral anticoagulant agent. No other clinical thromboembolic event was noted during the study period.

Figure 5. Serial two-dimensional echocardiography (2DE) and left ventricular wall motion score (LVWMS) in 22 surviving patients with and without left ventricular thrombus (LVT) resolution during follow up.

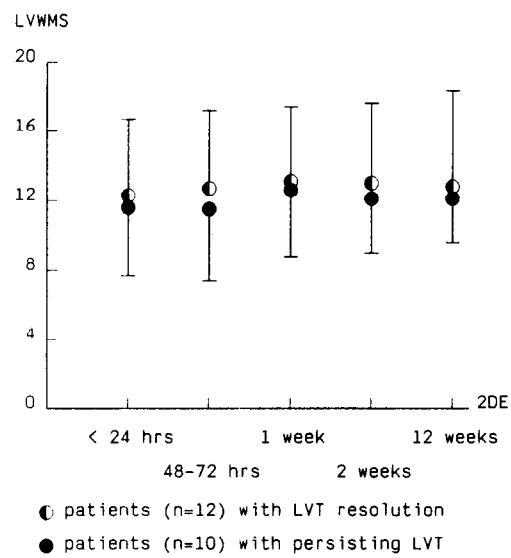

Table 2. Clinical Data for 92 Patients With Early (<48 to 72 h), Late (>48 to 72 h) and No Formed Left Ventricular Thrombus

	LVT Early (n = 18)	Late (n = 12)	No LVT (n = 62)
Male (%)	78	67	73
Age (yr)	67 ± 10	63 ± 11	62 ± 14
Q waves (n)*	4.9 ± 1.8	4.1 ± 1.4	3.4 ± 2.8
Max CK (U/liter)*	2,374 ± 1227	2,049 ± 1338	1,477 ± 933
Max MB CK (U/liter)*	210 ± 106	159 ± 110	145 ± 101
Max LDH (U/liter)*	1,287 ± 623	941 ± 438	787 ± 427
LVWM score 1st 2DE*	14.8 ± 3.3	10.3 ± 4	9.9 ± 4.7
Killip class*	2.6 ± 1.1	1.7 ± 0.7	1.9 ± 1.0
Killip class III–IV (%)	61	18	30
No LVT resolved (%)	33	41	0
Mortality at 12 weeks (%)	33	0	21
Beta-blocker† (%)	17	50	42
Calcium antagonist†	0	8	11

*Mean ± SD; †medication during hospitalization. LVT = left ventricular thrombosis; LVWMS = left ventricular wall motion score; CK = serum creatine kinase; LDH = serum lactate dehydrogenase; MB CK = creatine kinase isoenzyme; Q waves = number of Q waves in leads I, AVL and V_1 to V_6; 2DE = two-dimensional echocardiography.

Discussion

Incidence of left ventricular thrombus. The 33% incidence rate of left ventricular thrombus in the 92 patients with anterior myocardial infarction in this study is concordant with the rate noted in previous reports (3,4,20,22,23). The echocardiogram performed at 2 weeks after infarction yielded the best result with respect to the percent of left ventricular thrombi diagnosed (96%) in the surviving patients. With this week echocardiogram, we missed the thrombus in the four patients who died, the two patients with early resolution of thrombus and the patient with a later-formed thrombus.

One limitation of our study is the lack of anatomic validation of the presence or absence of left ventricular thrombus. Two-dimensional echocardiography has a sensitivity ranging from 92% to 100% and a specificity ranging from 50% to 88%, as reported in two studies (1,2) with anatomic validation. Although equivocal echocardiographic images were considered negative, by repeated performance of echocardiographic studies, we limited equivocal studies to one case only.

Left ventricular thrombus shape, treatment and follow-up. Thromboembolism is the only and, in most cases, disabling complication of left ventricular thrombosis. From previous reports (15,20,27–32), it is clear that patients with a protruding or mobile rather than a flat mural thrombus are at risk for embolism. Haugland et al. (28) noted an embolization rate of 60% in patients with a mobile thrombus and of 41% in patients with a protruding thrombus compared with 13% in patients with a mural thrombus. Other studies (30–33) indicate that thrombi that embolize are more likely to be protruding. Thus, it is of clinical importance to identify patients in this high risk group. In our study, 53% of the 30 left ventricular thrombi showed protrusion and 47% were mural, a finding that is concordant with the results of other studies (20,25,28,32). Only two patients, both with a protruding thrombus, had a clinical embolic event (a stroke 5 and 7 days after myocardial infarction, respectively). No other embolic phenomenon was noted during the 12 week follow-up period in these study patients. This incidence of embolism (6.6%) is within the range reported by others (3,4,20,22,23,25). An explanation for this rather low incidence rate is that most of the patients received an antithrombotic drug during the study, and only 10 patients had persisting thrombus during the 12 week study period. Although the value of oral anticoagulant therapy is not confirmed, two review articles (34,35) suggested that the incidence of systemic embolism in patients with left ventricular thrombus who are treated with anticoagulant agents varies from 0% to 2% and in untreated patients from 24% to 33%, which warrants the use of such anticoagulant agents. Using frequent serial two-dimensional echocardiograms, Domenicucci et al. (25) demonstrated spontaneous changes in thrombus shape. In our study, thrombus shape changed spontaneously during hospitalization in 17% of the patients who were not treated with an anticoagulant agent and 7% of thrombi resolved. After hospital discharge, 53% of the left ventricular thrombi in the patients given anticoagulant therapy showed complete resolution, and 40% had significant change in thrombus shape or size. Of the untreated patients, 40% had complete resolution of thrombus.

Left ventricular wall motion and follow-up. Although serial two-dimensional echocardiography to detect and monitor left ventricular thrombus has been evaluated previously, this is the first study to use serial (more than two) left ventricular wall motion analysis (1,16,18,20,25,31). Left ventricular wall motion analysis in patients with and without left ventricular thrombus showed significant differences in our study. As expected, patients with thrombus had a higher left ventricular mall motion score on the first echocardiogram. However, the wall motion score of these patients did not change significantly during follow-up as compared with that in patients without thrombus. In addition to having a significantly lower left ventricular wall motion score on the first echocardiogram patients without thrombus manifested significant improvement during follow-up. The reason for these findings is unclear. Thrombolytic therapy in the acute phase of infarction did not reduce the incidence of left ventricular thrombus and could not have been responsible for these changes. In any event, the absence of left ventricular thrombus predicted improvement of left ventricular function.

Earlier reports (1–4,20,22,25) noted a high incidence of

left ventricle apical akinesia or dyskinesia in patients with left ventricular thrombus. In our series, apical akinesia or dyskinesia was observed within 24 h in 96% and 84% of patients with and without left ventricular thrombus, respectively. This finding may be a result of our selection criteria (anterior infarction with significant ST segment elevation). The percent of patients with an aneurysm was significantly higher in the thrombus group. These and earlier findings suggest that the combination of left ventricular wall motion abnormalities with subsequent stasis of blood, damaged endocardium and possibly a hypercoagulable condition in patients with acute myocardial infarction may be the main etiologic factors in early left ventricular thrombus formation.

Of the 22 surviving patients with ventricular thrombus who were followed up for 12 weeks, 12 showed resolution of the thrombus. No differences in left ventricular wall motion score were noted between patients with persisting or resolved thrombus. Thus, improvement in global left ventricular function did not play a role in thrombus resolution. This finding is unexpected and cannot be explained from our data. Analysis of the wall motion changes in the apical segment did not demonstrate significant improvement in patients with thrombus resolution as compared with results in patients with thrombus persistence. Worsening in apical wall motion was observed in 70% of the patients with persistent thrombus and in 25% of those with thrombus resolution. Although there was a trend, this finding did not reach statistical significance. Apparently, other factors such as endocardial healing, asymptomatic embolization or changes in hemostasis may play a role in the resolution of left ventricular thrombus.

Clinical correlation and prognosis. In addition to left ventricular wall motion, maximal cardiac enzyme levels and Killip classification are important variables in relation to infarct size. In patients with left ventricular thrombus, we found higher peak enzyme levels, higher incidence of Killip class III to IV, higher left ventricular wall motion scores and more Q waves. These results indicate that patients with more severely impaired left ventricular function in acute myocardial infarction run a risk for left ventricular thrombosis.

The frequent two-dimensional echocardiographic examinations in our study during hospitalization allowed the identification of early (<48 to 72 h) and late (>48 to 72 h) left ventricular thrombi. Our results are identical to those of Spirito et al. (20) with respect to differences in mortality, Killip class III to IV and wall motion score. Six of the 18 patients with an early-formed thrombus but none of the 12 patients with a late-formed thrombus ($p < 0.05$) died. Formation of left ventricular thrombus within 48 to 72 h of myocardial infarction occurred in patients with the most extensive infarction and was associated with a high mortality rate. With the analysis of left ventricular contractility and other clinical variables, these findings substantiate the conclusion that detection of early formation of left ventricular thrombus identifies patients with a different clinical profile and prognosis.

Conclusion. This large prospective study in 100 patients with a first acute anterior myocardial infarction indicates that left ventricular thrombus can be detected in 33% of such patients and carries a strong prognostic significance. Early thrombus formation within 48 to 72 h was observed in patients with the most extensive infarction and was associated with a poor prognosis. Most left ventricular thrombi in surviving patients were detected approximately 2 weeks after the onset of symptoms, indicating that the echocardiograms obtained on day 3 and after 2 weeks had the greatest clinical value in assessing early prognosis and identifying left ventricular thrombus.

The presence of left ventricular thrombus was correlated with persisting poor left ventricular function, whereas its absence predicted improved function. Left ventricular wall motion analysis as performed by serial two-dimensional echocardiography did not predict left ventricular thrombus regression or resolution. Significant change in shape, reduction in size or resolution of the thrombus was noted in 93% of the patients treated with anticoagulant agents. Finally, the incidence of thromboembolism was low in this study, and occurred during hospitalization only in two patients with a protruding left ventricular thrombus.

We thank Magreet Koelemay and Ankie Muller for their secretarial assistance, and Johan Karreman for his help with the data management. Echocardiographic support was given by Annette Brauns, Lidwien Admiraal and Ellen Rothuis.

References

1. Visser CA, Kan G, David GK, Lie KI, Durrer D. Two-dimensional echocardiography in the diagnosis of left ventricular thrombus: a prospective study of 67 patients with anatomic validation. Chest 1983;83:228–32.
2. Reeder GS, Tajik AJ, Seward JB. Left ventricular mural thrombus: two-dimensional echocardiographic diagnosis. Mayo Clin Proc 1981;56:82–6.
3. Asinger RW, Mikell FL, Elsperger J, Hodges M. Incidence of left-ventricular thrombosis after acute myocardial infarction: serial evaluation by two-dimensional echocardiography. N Engl J Med 1981;305:297–302.
4. Keating EC, Gross SA, Schlamowitz RA, et al. Mural thrombi in myocardial infarction: prospective evaluation by two-dimensional echocardiography. Am J Med 1983;74:969–95.
5. Funke Küpper AJ, Verheugt FWA, Jaarsma W, et al. Detection of ventricular thrombosis in acute myocardial infarction. Value of indium-111 platelet scintigraphy in relation to two-dimensional echocardiography and clinical course. Eur J Nucl Med 1986;12:337–41.
6. Stratton JR, Ritchie JL. The effects of antithrombotic drugs in patients with left ventricular thrombi: assessment with indium-111 platelet imaging and two-dimensional echocardiography. Circulation 1984;69:561–8.
7. Cokkinos DV, Ioannou N, Dellos C, Salpeas D. Failure of anticoagulant therapy to prevent left ventricular thrombus formation in acute myocardial infarction (abstr). Eur Heart J 1984;5(suppl 1):203.

8. Nordrehaug JE, Johannessen K-A, Von der Lippe G. Usefulness of high-dose anticoagulants in preventing left ventricular thrombus in acute myocardial infarction. Am J Cardiol 1985;55:1491–3.

9. Johannessen K-A, Nordrehaug JE, Von der Lippe G. Left ventricular thrombi after short-term high-dose anticoagulants in acute myocardial infarction. Eur Heart J 1987;8:975–80.

10. Johannessen K-A, Von der Lippe G, Taulow E. Platelet inhibition, coagulation variables and left ventricular thrombi in acute myocardial infarction (abstr). J Am Coll Cardiol 1987;9:189A.

11. Ezekowitz MD, Smith EO, Cox AC, Taylor FB. Failure of aspirin to prevent incorporation of indium-111 labelled platelets into cardiac thrombi in man. Lancet 1981;1:440–3.

12. Kremer P, Fiebig R, Tilsner V, Bleifeld W, Mathey DG. Lysis of left ventricular thrombi with urokinase. Circulation 1985;72:112–8.

13. Sharma B, Carvalho A, Wyeth R, Franciosa JA. Left ventricular thrombi diagnosed by echocardiography in patients with acute myocardial infarction treated with intracoronary streptokinase followed by intravenous heparin. Am J Cardiol 1985;56:422–5.

14. Eigler N, Maurer G, Shah PK. Effect of early systemic thrombolytic therapy on left ventricular mural thrombus formation in acute anterior myocardial infarction. Am J Cardiol 1984;54:261–3.

15. Scholl JM, Castillo-Fenoy A, Morice MC, et al. Does heparin prevent left ventricular thrombus formation in acute myocardial infarction? (abstr). Eur Heart J 1984;5(suppl 1):53.

16. Davis MJE, Ireland MA. Effect of early anticoagulation on the frequency of left ventricular thrombi after anterior wall acute myocardial infarction. Am J Cardiol 1986;57:1244–7.

17. Arvan S, Boscha K. Prophylactic anticoagulation for left ventricular thrombi after acute myocardial infarction: a prospective randomized trial. Am Heart J 1987;113:688–93.

18. Gueret P, Dubourg O, Ferrier A, Farcot JC, Rigaud M, Bourdarias JP. Effects of full-dose heparin anticoagulation on the development of left ventricular thrombosis in acute transmural myocardial infarction. J Am Coll Cardiol 1986;8:419–26.

19. Turpie AGG, Robinson J, Mulji AS, et al. Prevention of left ventricular mural thrombosis in acute myocardial infarction: a double blind trial comparing high dose with low dose subcutaneous calcium heparin (abstr). J Am Coll Cardiol 1988;11:26A.

20. Spirito P, Bellotti P, Chiarella F, Domenicucci S, Sementa A, Vecchio C. Prognostic significance and natural history of left ventricular thrombi in patients with acute anterior myocardial infarction: a two-dimensional echocardiographic study. Circulation 1985:72:774–80.

21. Tramarin R, Pozzoli M, Febo O, Opasich C, Cobelli F, Specchia G. Two-dimensional echocardiographic assessment of anticoagulant therapy in left ventricular thrombosis early after acute myocardial infarction. Eur Heart J 1986;7:482–9.

22. Weinreich DJ, Burke JF, Pauletto FJ. Left ventricular mural thrombi complicating acute myocardial infarction: long-term follow-up with serial echocardiography. Ann Intern Med 1984;100:789–94.

23. Visser CA, Kan G, Meltzer R. Long-term follow-up of left ventricular thrombus after acute myocardial infarction: a two-dimensional echocardiographic study in 96 patients. Chest 1984;86:532–6.

24. Asinger RW, Mikell FL, Sharma B, Hodges M. Observations on detecting left ventricular thrombus with two-dimensional echocardiography: emphasis on avoidance of false positive diagnoses. Am J Cardiol 1981;47:145–56.

25. Domenicucci S, Belloti P, Charella F, Lupi G, Vechio C. Spontaneous morphologic changes in left ventricular thrombi: a prospective two-dimensional echocardiographic study. Circulation 1987;75:737–42.

26. Jaarsma W, Visser CA, Eenige van MJ, et al. Prognostic implications of regional hyperkinesia and remote asynergy of noninfarcted myocardium. Am J Cardiol 1986;58:394–8.

27. Bhatnager SK, Hudak A, Al-Ysuf AR. Left ventricular thrombosis, wall motion abnormalities, and blood viscosity changes after first transmural anterior myocardial infarction. Chest 1985;88:40–4.

28. Haugland JM, Asinger RW, Mikkel FL, Elsperger J, Hodges M. Embolic potential of left ventricular thrombi detected by two-dimensional echocardiography. Circulation 1984;70:588–98.

29. Johannessen K-A. Peripheral emboli from left ventricular thrombi of different echocardiographic appearance in acute myocardial infarction. Arch Intern Med 1987;147:641–4.

30. Stratton JR, Resnick AD. Increased embolic risk in patients with left ventricular thrombi. Circulation 1987;75:1004–10.

31. Arvan S. Left ventricular mural thrombi secondary to acute myocardial infarction: predisposing factors and embolic phenomenon. J Clin Ultrasound 1983;11:467–73.

32. Visser CA, Kan G, Meltzer RS, Dunning AJ, Roelandt J. Embolic potential of left ventricular thrombus after myocardial infarction: a two-dimensional echocardiographic study of 119 patients. J Am Coll Cardiol 1985;5:1276–80.

33. Meltzer RS, Visser CA, Kan G, Roelandt J. Two-dimensional echocardiographic appearance of left ventricular thrombi with systemic emboli after myocardial infarction. Am J Cardiol 1984;53:1511–3.

34. Chesebro JH, Fuster V. Antithrombotic therapy for acute myocardial infarction: mechanisms and prevention of deep venous, left ventricular, and coronary artery thromboembolism. Circulation 1986;74(suppl III): III-1–10.

35. Kaplan K. Prophylactic anticoagulation following acute myocardial infarction. Arch Intern Med 1986;146:593–7.