Neuroscience Letters 688 (2019) 62–75

Contents lists available at ScienceDirect

Neuroscience Letters

journal homepage: www.elsevier.com/locate/neulet

Review article

The cerebellum and cognition

Jeremy D. Schmahmann

Ataxia Unit, Cognitive Behavioral Neurology Unit, Laboratory for Neuroanatomy and Cerebellar Neurobiology, Department of Neurology, Massachusetts General Hospital and Harvard Medical School, 100 Cambridge Street, Suite 2000, Boston, MA 02114, United States

ARTICLE INFO

Keywords:
Functional topography
Distributed neural networks
Cerebellar cognitive affective/Schmahmann syndrome
Cerebrocerebellar connections
Neuropsychiatry
Social cognition
Mutism
Ataxia
Dysmetria of thought
Universal cerebellar transform

ABSTRACT

What the cerebellum does to sensorimotor and vestibular control, it also does to cognition, emotion, and autonomic function. This hypothesis is based on the theories of dysmetria of thought and the universal cerebellar transform, which hold that the cerebellum maintains behavior around a homeostatic baseline, automatically, without conscious awareness, informed by implicit learning, and performed according to context. Functional topography within the cerebellum facilitates the modulation of distributed networks subserving multiple different functions. The sensorimotor cerebellum is represented in the anterior lobe with a second representation in lobule VIII, and lesions of these areas lead to the cerebellar motor syndrome of ataxia, dysmetria, dysarthria and impaired oculomotor control. The cognitive / limbic cerebellum is in the cerebellar posterior lobe, with current evidence pointing to three separate topographic representations, the nature of which remain to be determined. Posterior lobe lesions result in the cerebellar cognitive affective syndrome (CCAS), the hallmark features of which include deficits in executive function, visual spatial processing, linguistic skills and regulation of affect. The affective dyscontrol manifests in autism spectrum and psychosis spectrum disorders, and disorders of emotional control, attentional control, and social skill set. This report presents an overview of the rapidly growing field of the clinical cognitive neuroscience of the cerebellum. It commences with a brief historical background, then discusses tract tracing experiments in animal models and functional imaging observations in humans that subserve the cerebellar contribution to neurological function. Structure function correlation studies following focal cerebellar lesions in adults and children permit a finer appreciation of the functional topography and nature of the cerebellar motor syndrome, cerebellar vestibular syndrome, and the third cornerstone of clinical ataxiology – the cerebellar cognitive affective syndrome. The ability to detect the CCAS in real time in clinical neurology with a brief and validated scale should make it possible to develop a deeper understanding of the clinical consequences of cerebellar lesions in a wide range of neurological and neuropsychiatric disorders with a link to the cerebellum.

1. Historical background

Jean Marie Pierre Flourens [1] demonstrated that cerebellar damage in pigeons impaired flight, not because of weakness, but because of loss of coordination of voluntary wing movements. Bolstered by subsequent experimental observations, physiologists "interpret[ed] the phenomena observed after extirpation of the cerebellum in animals…as definite, distinct, and invariable,…lead[ing] inevitably to but one conclusion… When the greatest part or the whole of the cerebellum is removed from a bird or mammal, the animal being, before the operation, in a perfectly normal condition, and no other parts being injured, there are no phenomena constantly and invariably observed except certain modifications of the voluntary movements…The movements are always exceedingly irregular and incoördinate; the animal cannot maintain its equilibrium…Whatever other functions the cerebellum may have, it acts as the centre presiding over equilibration and general muscular coordination" ([2] pp 368–371). While acknowledging cases of cerebellar pathology "in which the movements were unaffected" (p. 383), Flint's conclusion reflected the prevailing wisdom about the cerebellum at the time that "(t)he only view that has any positive experimental or pathological basis is that it presides over equilibration and the coordination of certain muscular movements, and is in some way connected with the generative function". ([2] p. 392). Investigations in monkey by Luciani [3], Ferrier and Turner [4] and Russell [5], and observations by pioneering clinical neuroscientists including Sanger Brown [6], Pierre Marie [7], Felix Babinski [8], and [9–11] bolstered this notion that cerebellum is engaged exclusively in motor control, a view that became solidified as a fundamental truism in brain science and clinical neurology.

What is less well known, or not appreciated at all, is that a half

E-mail address: jschmahmann@mgh.harvard.edu.

https://doi.org/10.1016/j.neulet.2018.07.005
Received 3 April 2018; Received in revised form 3 July 2018; Accepted 4 July 2018
Available online 08 July 2018
0304-3940/ © 2018 Elsevier B.V. All rights reserved.

century before Flourens, Vincenzo Malacarne [12] set out to describe, for the first time, the structures of cerebellum (including the vermis, tonsil, nodulus, lingula) because he was exploring the relationship between cerebellar size and intellectual prowess [13]. Within a decade of Flourens' experiments, Combette [14] reported intellectual and emotional disability in a patient with cerebellar agenesis, as did occasional case reports that followed over the next century. The relationship between cerebellum and intellectual and emotional processing has a checkered history, with case reports of "remarkable pathological proof of a relation existing between the cerebellum and the instinct of reproduction" [15] based on association and possibly speculation. The fields of cognitive neuroscience, and clinical and experimental neuropsychology, psychiatry and neuropsychiatry did not emerge until the early to mid-20th century, and there was an antipathy towards "psychosomatic medicine" by luminaries in clinical neurology and neuroscience who had "developed a very high degree of sophistication in analysing the symptomatology of organic neurological disease based on precise observation, [but] did not consider that, in the mental sphere, there was a need for equal precision and penetrating analysis" [16,17]. Force of influence and personality of pioneers such as Flourens likely contributed to the lack of appreciation of the role of the cerebellum beyond motor control. Against this background, Franz Joseph Gall morphed his ideas about cerebral association areas into clinical phrenology, and by extending his conclusion that the cerebellum was the seat of sexual prowess and the "instinct of generation" [18] he may have unwittingly contributed to the rejection of, or at least the refusal to consider, a role for cerebellum beyond the coordination of voluntary motor activity.

For these reasons, and perhaps others, for almost 200 years the cerebellum has been regarded as engaged only in motor control. The cerebellar syndrome has been equated with ataxia - impairment of balance and gait, dysmetria (impaired coordination and fine control) of the arms and legs, dysarthria (speech problems), and oculomotor abnormalities that interfere with visual focus and stability.

Rediscovery of the primary literature pointing to a nonmotor role for the cerebellum [19,20], together with the introduction of novel theoretical formulations [19,21,22] and hypothesis-driven anatomical investigations [23–25] precipitated a paradigm shift in the understanding of the cerebellum. It is now clear that what was previously regarded as the cerebellar syndrome must be recontextualized as the cerebellar motor syndrome, which together with the two other major cerebellar clinical phenomena – the vestibular cerebellar syndrome, and the cerebellar cognitive affective syndrome, constitute the triad of clinical ataxiology [26].

2. The contemporary era – the early days

Flourens endorsed the ideas of Albrecht von Haller (1708–1777) that the cerebral hemispheres and cerebellum are uniformly organized with homogeneous function throughout, all parts capable of being engaged in all behaviors (functional omnivalence, equipotentiality). Lodewick Bolk [27] drew on comparative morphology to refute this notion, postulating that there is a somatotopically arranged body map in the cerebellum. Bolk's conclusions received experimental confirmation in physiological studies that dispelled the equipotentiality notion, revealing that, like cerebral cortex [28], the cerebellum has primary and secondary somatosensory areas [29–33]. In the primary representation, the legs are represented in the rostral part of the anterior lobe, the arms further behind, and the head and neck representation is in the posterior part of the cerebellar vermis. The second sensorimotor representation is in the medial part of the cerebellar posterior lobe, in lobule VIII. In addition, the posterior cerebellar vermis of lobules VI and VII receives peripheral and central inputs from the visual and auditory systems. One of the noteworthy aspects of these physiological findings is another important principle, namely, that there are large swaths of the hemispheres of the cerebellar posterior lobes that have no body part representation at all. Later studies demonstrated physiological interactions between the cerebellar hemisphers and parietal association areas [34], and between the cerebellar vermis and limbic structures of the Papez circuit [35] leading to the suggestion that the cerebellum is relevant not only to neurology but also to psychiatry [36].

Physiological and behavioral studies in animal models revealed spinal afferents directed exclusively to the somatomotor homunculus avoiding the lateral hemispheres entirely [37], fastigial nucleus stimulation and ablation produced a range of autonomic and complex behavioral phenomena [38–40], associative learning was identified in the interpositus nucleus and lobule VI [41], and patient studies provided clinical correlates of cerebellar vermis stimulation on emotion and social interaction [42–45]. This accumulating evidence paved the way for in-depth examination of the emerging role of the cerebellum in higher function [19].

3. Substrates of cerebellar cognition - anatomy and circuitry defined by tract tracing in monkey

Cerebellar cortical architecture is essentially invariant throughout. This arrangement is fundamental to the idea that the architecture of a brain region determines the nature of the information processing that takes place in that region [46], the principle expressed in the notion of the universal cerebellar transform (UCT [47]). Superimposed upon this UCT principle is the presence of highly organized and functionally specific heterogeneity of cerebellar connections with the spinal cord, brainstem and cerebral cortex [48–52,24,53,54].

The anatomical circuits linking cerebellum with the cerebral cortex are arranged in a two-stage feed-forward loop (the corticopontine - pontocerebellar projection) and a two-stage feed-back loop (cerebellothalamic – thalamocortical projection). These loops are formed by multiple parallel but partially overlapping subcircuits that link different areas of the cerebral cortex with topographically precise regions of the cerebellum.

The cerebellar anterior lobe (lobules I through V) and parts of lobule VI, together with lobule VIII (Fig. 1), receive spinal afferents through the spinocerebellar tracts [37]. They are also reciprocally interconnected with the motor cortices via the feed-forward motor corticopontine projections [55–57] and through feed-back to motor regions from cerebellar nuclei via the thalamus [58,59]. These cerebellar regions (i.e., anterior lobe, adjacent parts of lobule VI, and lobule VIII) are also reciprocally linked with the medial and dorsal accessory nuclei of the inferior olivary complex, which in turn receive afferents from the spinal cord [48,54]. The deep cerebellar nuclei (DCN) that are linked with these cerebellar cortical areas are the anterior and posterior interpositus in the monkey (equivalent to the globose and emboliform in humans); and the dorsal part of the dentate nucleus. The cerebellar vermis and fastigial nucleus are interconnected with the vestibular and other brainstem nuclei which are engaged in midline body control, gait and equilibrium, as well as with brainstem nuclei linked with limbic and paralimbic cortical and subcortical regions [60].

In contrast to the connections of the anterior lobe and lobule VIII, the great expansion of the human cerebellum, i.e., the remainder of lobule VI, all of lobule VII (that includes lobule VIIA in the vermis and crus I and crus II in the hemispheres, lobule VIIB and most of lobule IX) has no connections with the cerebral cortical sensorimotor areas, and no spinal cord inputs from the spinocerebellar tracts [48,54]. These areas are linked instead in a reciprocal feed-forward and feed-back manner with the association areas of the cerebral cortex concerned with higher order behavior, namely, the prefrontal cortex, posterior parietal cortex, superior temporal polymodal regions, cingulate gyrus, and posterior parahippocampal area [19,23,50,61–64,24,59]. The dentate nucleus of the cerebellum conveys the cerebellar posterior lobe efferents to these higher order regions of the cerebral cortex [25], The ventral and lateral parts of the dentate nucleus most involved in these projections [65] have expanded through evolution along with the

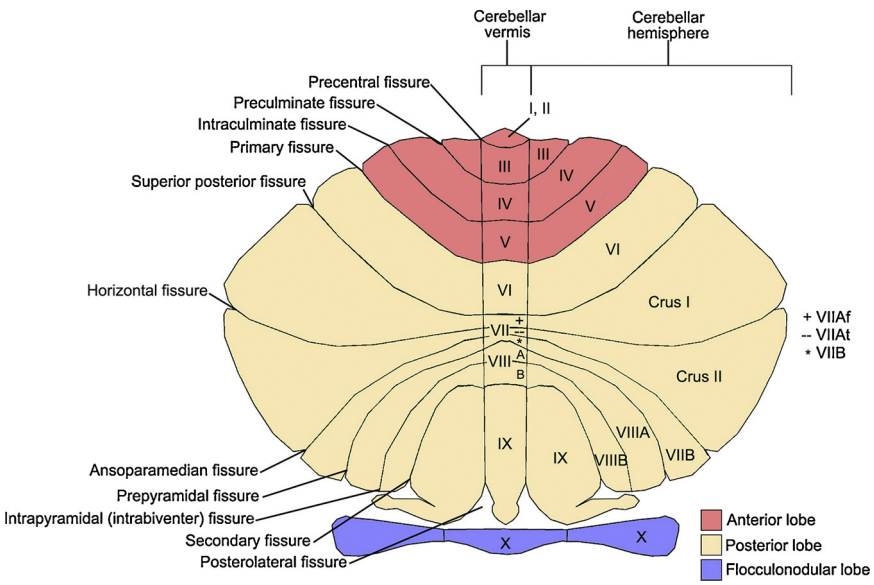

Fig. 1. Flattened representation of the cerebellum and its major fissures, lobes and lobules. The anterior lobe (lobules I to V) is shaded red; the posterior lobe (lobules VI through IX) is cream, and the flocculonodular lobe (lobule X) is purple. Lobules I through X are identified in the vermis and the hemispheres. In lobule VII, VIIAf at the vermis expands in the hemisphere to become Crus I, lobule VIIAt at the vermis merges with Crus II in the hemisphere, and lobule VIIB retains its designation both at the vermis and in the hemispheres. (For interpretation of the references to colour in this figure legend, the reader is referred to the web version of this article).
Author's diagram adapted from Makris et al. (2003) [currently reference [228]228] and first published in D'Mello et al [currently reference [227]227].

cerebellar posterior lobe, the cerebral cortical association areas [21,66,67], and the pathways that link them [68]. The inferior olivary nucleus reciprocal interconnections with the cerebellar posterior lobe are distinct from those with the cerebellar motor regions, as they are derived from the principal olivary nucleus which has minimal or no spinal cord input [69].

These anatomical connections set up a dichotomy of cerebellar linkage with the cerebral cortex, brainstem and spinal cord, and portray a complex connectional and functional heterogeneity. The sensorimotor cerebellum mostly in the anterior lobe, adjacent parts of lobule VI, and lobule VIII appears to be an integral part of the distributed neural circuits subserving the motor system; whereas the cognitive cerebellum in the posterior lobe, and the limbic cerebellum (likely represented principally in the vermis), are incorporated into the distributed neural circuits necessary for cognition and emotion.

4. Substrates of cerebellar cognition - circuitry defined by imaging in humans

Resting state functional connectivity MRI (rsfcMRI) provides new insights into cerebellar organization and functional connections in humans [70–73]. Distributed networks throughout the brain subserve movement, attention, and limbic valence, as well as fronto-parietal and default systems concerned with creativity and imagination. These cerebral networks map onto cerebellum with topographic specificity. The motor networks map onto sensorimotor parts of the cerebellum in the anterior lobe and lobule VIII. The dorsal attention, ventral attention, frontoparietal, default mode and salience networks map onto focal areas within the posterior lobe of the cerebellum. This realization that most of the human cerebellum is linked with cerebral association areas concerned with intellect, social cognition and emotion control epitomizes the revolution that has occurred in the understanding of the cerebellum and of the organization of the human brain.

Task-based functional MRI within single subjects and at the group level provides independent confirmation of the cerebellar sensorimotor-cognitive dichotomy [74–76] (Fig. 2). Tasks such as moving the arm or leg activate the primary sensorimotor cerebellum - anterior lobe and adjacent parts of lobule VI, as well as the second sensorimotor area in lobule VIII. Cognitive paradigms activate topographically distinct regions within the cerebellar posterior lobe. Lobules VI and Crus I are engaged in language and verbal working memory; lobule VI in spatial tasks; lobules VI, Crus I and VIIB are activated by executive functions such as working memory, planning, organizing and strategy formation;

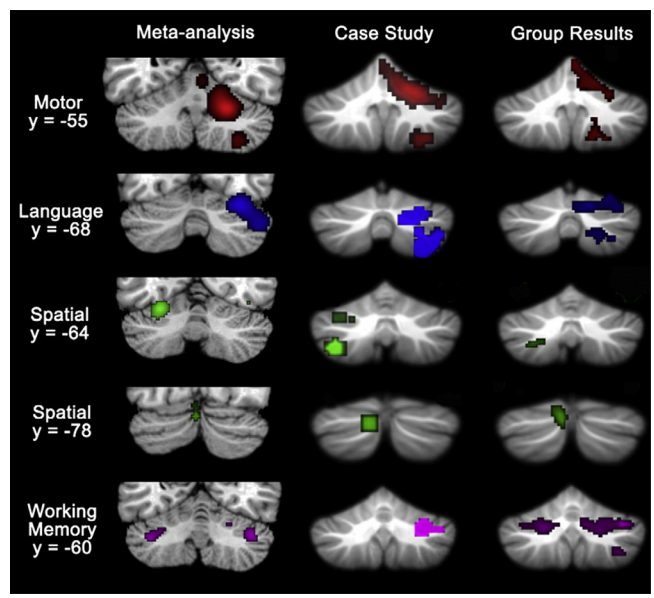

Fig. 2. Functional topography in the human cerebellum revealed by engaging in tasks in the functional MRI scanner. The results of a meta-analysis of prior studies (left panel), a single-case study (middle panel), and a group of 9 subjects (right panel) shows that right-handed finger movement, language, spatial cognition, and working memory activate discrete and different areas within the cerebellum. Coronal plane (y = − * mm posterior to the posterior commissure), left is shown on the left.
From Stoodley and Schmahmann [75,76,95].

and vermal lobules VI and VII are involved in emotional processing. Language is heavily right lateralized and spatial functions left-lateralized, reflecting crossed cerebro-cerebellar projections. Hemispheric lobules VI, Crus I, and VIIB appear to be involved in encoding generalized aversive processing. Threatening stimuli such as noxious heat and viewing unpleasant pictures activate these cerebellar regions together with limbic system structures – the anterior hypothalamus, subgenual anterior cingulate cortex, and parahippocampal gyrus [77].

Recent rsfcMRI and task-based MRI studies that tapped the large dataset (n = 787 subjects) of the Human Connectome Project (HCP; [78]) confirm the double motor representation in the anterior lobe and lobule VIII. They also confirm and extend Buckner et al.'s [73] demonstration with rsfcMRI of a triple representation of cognitive

domains in the cerebellar posterior lobe – (i) lobules VI-Crus I, (ii) Crus II-VIIB, and (iii) lobule IX. New analyses of rsfcMRI in the HCP (n = 1003 subjects) using intrinsic cerebellar functional connectivity [79] further reveal that the cerebellum demonstrates the same kind of sensorimotor-to-cognition hierarchical gradient pattern that has long been established in the cerebral cortex [80]. These fundamental organizing principles of cerebellar structure and function dovetail with the deeper understanding of cerebellar clinical neurology and neuropsychiatry.

5. Functional topography of the cerebellar motor syndrome

There is a long tradition of structure-function correlation in patients with focal brain injuries, notably stroke, to understand the functions of the nervous system. A stroke in the territory of the superior cerebellar artery mostly damages the cerebellar anterior lobe, and results in the cerebellar motor syndrome of gait ataxia, limb dysmetria, and dysarthria, as defined by the early neurologists who formulated the cerebellar motor exam in clinical practice [[82],11] and which remains in use today [81,82]. A similar sized stroke in the territory of the posterior inferior cerebellar artery damages the cerebellar posterior lobe. In these patients, once the nausea, vomiting and vertigo from damage to the vestibular regions has resolved, the patient has little or no ataxia.

The topography of motor vs nonmotor manifestations of cerebellar damage is affirmed by a review of studies focusing on the motor consequences of cerebellar infarction. Among 39 patients with stroke confined to the cerebellum, Schmahmann et al. [83] found that 26 patients (66.6%) examined 8.0 +/- 6.0 days after onset of stroke were impaired with findings that conformed to the cerebellar motor syndrome - ataxic gait, appendicular dysmetria, dysarthria, and oculomotor abnormalities among other problems. These features were quantitatively assessed using a modified version of the International Cooperative Ataxia Rating Scale [MICARS, [57,84]]. The remaining 13 patients (33%) were motorically normal (MICARS ≤ 4) when examined. The dichotomy between patients who were ataxic versus those who were not was accounted for by the location of the cerebellar lesion. In ataxic patients the lesions involved the anterior lobe (lobules I – V). In patients with minor or no motor findings, the lesions spared the anterior lobe and were confined instead to lobules VII – X of the posterior lobe. Patients with infarction involving lobule VI along with lobules VII – X, but sparing the anterior lobe, had a minor degree of motor impairment. In all 39 patients the cerebellar stroke included regions both medial to, and lateral to, the 10 mm dividing line that separates the cerebellar vermis from the paravermal regions [85], and thus medial versus lateral location of the stroke did not contribute to the differences in ataxia scores. Damage to the DCN had no additional effect on the degree of ataxia in the 25 (of these 39) acute stroke patients in whom the DCN were included in the lesion together with the cerebellar cortex. The voxel-based lesion symptom mapping study of Stoodley et al. [86] confirmed this dichotomy, in which the location of the cerebellar lesion determined the motor versus the cognitive consequences of cerebellar stroke (Fig. 3).

In an earlier voxel-based lesion-symptom mapping study of the effects of cerebellar stroke on motor function [87], patients developed ataxia following lesions involving the superior aspect of the cerebellar cortex (anterior lobe and parts of lobule VI), but not the inferior aspect (cerebellar posterior lobe). In the acute and subacute stages following the cerebellar strokes (23.8 +/− 17.5 days) there was somatotopic representation such that lesions of the vermal and paravermal lobules III–IV were correlated with lower limb ataxia; vermal, paravermal and hemispheral lobules IV–VI with upper limb ataxia; paravermal and hemispheral lobules V and VI with dysarthria; and superior vermis with ataxia of posture (lobule III) and gait (lobules II and III). Regions correlating with lower limb ataxia were located more medially than lesions correlating with upper limb ataxia. This study also included chronic cerebellar stroke patients (23.9 +/− 20.1 months post stroke) and unlike the acute or subacute patients, the regions that correlated most strongly with the degree of ataxia were the DCN. The interposed (globose and emboliform) and adjacent parts of the dentate nuclei correlated with limb ataxia, the fastigial nucleus with stance and gait, and the dentate nucleus with dysarthria. Involvement of the deep nuclei was critical for recovery of function.

The restriction of the cerebellar motor syndrome to the cerebellar somatomotor representation (cortex and nuclei) may account for the uncertainty in earlier times regarding patents with cerebellar lesions outside the motor representation who did not demonstrate the expected ataxia syndrome.

6. The cerebellar cognitive affective / Schmahmann's syndrome – identification first in adults

The silence of the cerebellar posterior lobe from the perspective of the cerebellar motor syndrome provides the backdrop to the existence and location of the cognitive / limbic cerebellum and its clinical manifestations.

Patient reports dating to the early 1830s [19] raised the question of potential relevance for cognition of damage to the cerebellum, or in inherited or neurodegenerative conditions affecting the cerebellum. Language problems following cerebellar stroke had been noted to include agrammatism [88], decreased verbal fluency [89], and inability to detect one's own errors in tasks such as the verb-for-noun generation paradigm [90].

In the study that defined the cerebellar cognitive affective syndrome (CCAS; [91,92]) 20 patients with lesions confined to the cerebellum were found to have clinically relevant deficits in executive function, visual spatial performance, linguistic processing and dysregulation of affect. Among the 20 patients (12 men; ages 23–74, mean age 48.2 years excluding one 12-year-old boy; mean education 13.9 years), 13 had infarcts in the territory of the posterior inferior cerebellar artery (PICA; 10 patients; 5 right, 3 left, 2 bilateral), superior cerebellar artery (2), and anterior inferior cerebellar artery (1). The remaining 7 patients had post-infectious cerebellitis (3), cerebellar cortical atrophy (3), and resection of a midline / paravermian cerebellar ganglioglioma (1).

Neurobehavioral tests showed that 18 of these patients had problems with executive functions, including poor working memory (in 11 of 16 tested), motor or ideational set shifting (in 16 of 19), and perseveration of actions or drawings (in 16 of 20). Verbal fluency was impaired in 18 patients, presenting as telegraphic speech, occasionally so limited as to resemble mutism. Decreased verbal fluency was unrelated to dysarthria. Visuospatial disintegration was found in 19 patients, who were disorganized in their sequential approach to drawing, and the conceptualization of figures was disorganized. Four patients had simultanagnosia. Naming was impaired in 13 patients, usually being spared in those with smaller lesions. Six with bilateral acute disease had agrammatic speech, and elements of abnormal syntactic structure were noted in others. Prosody was abnormal in 8 patients, with tone of voice characterized by a high pitched, whining, childish and hypophonic quality. Mental arithmetic was deficient in 14 patients. Verbal learning and recall were slightly abnormal in 11, and visual learning and recall were impaired in 4 (of 13 patients tested). Ideational apraxia was evident in 2 individuals. Difficulty modulating behavior and personality style was a prominent feature of the bedside mental state examination in 15 patients, particularly those with large or bilateral PICA territory infarcts, and in the patient with surgical excision of the vermis and paravermian structures. Flattening of affect or disinhibition were manifested as overfamiliarity, flamboyant and impulsive actions, and humorous but inappropriate and flippant comments. Behavior was regressive and childlike, and obsessive-compulsive traits were occasionally observed. Autonomic changes were a central feature in a patient with stroke involving the fastigial nucleus and paravermian cortex. This manifested as spells of hiccupping and coughing, which precipitated bradycardia and syncope.

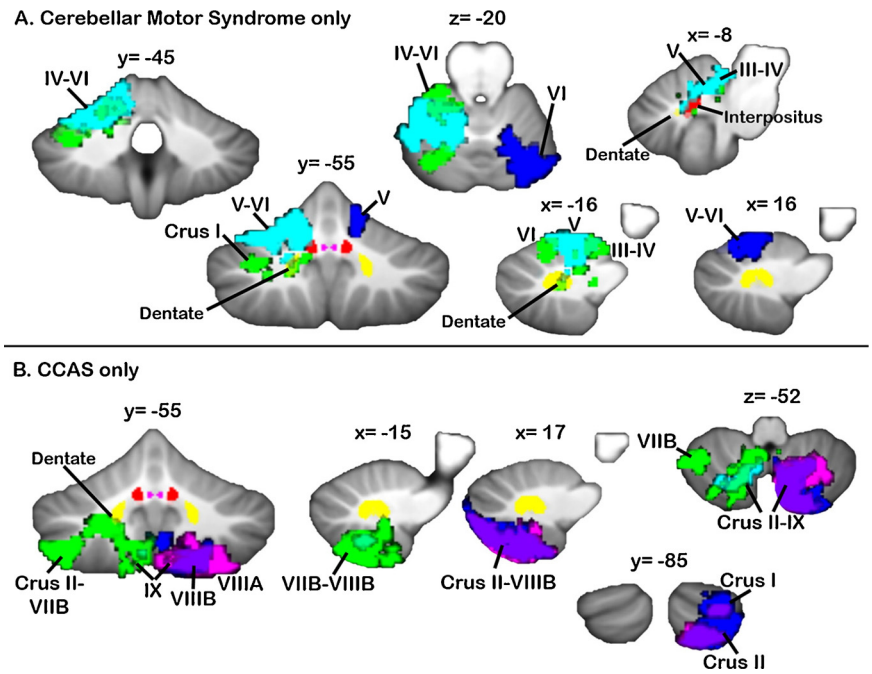

Fig. 3. Results of a voxel-based lesion symptom mapping study in 18 patients with cerebellar stroke. Individual patient lesion maps; different colors represent lesions of individual patients. (A) Damage to the cerebellar anterior lobe extending into lobule VI is associated with the cerebellar motor syndrome but not the cerebellar cognitive affective syndrome. Conversely, (B) patients with strokes in the cerebellar posterior lobe involving lobules VI through IX had the CCAS but no appreciable motor deficit. In patients with both the motor syndrome and CCAS stroke was present in anterior and posterior lobe regions (not shown). Cerebellar nuclei are color coded: fastigial nucleus – violet, interpositus – red, dentate – yellow. y = coronal plane * mm behind the posterior commissure, x = sagittal plane right (mm) or left (-mm) of midline, and z = horizontal plane * mm below the posterior commissure. (For interpretation of the references to colour in this figure legend, the reader is referred to the web version of this article).
From Stoodley et al. [86].

Neuropsychological testing confirmed the observations from the bedside evaluation. Deficits were more pronounced and generalized in patients with large, bilateral, or pancerebellar disorders, and particularly in those with acute onset cerebellar disease. Lesions of the posterior lobe were particularly important in generation of the CCAS; the vermis was consistently involved in patients with pronounced affective presentations; and the anterior lobe seemed to be less involved in the generation of these cognitive and behavioral deficits. Patients with stroke improved over time, although executive function remained abnormal.

The cerebellar cognitive affective syndrome is thus characterized by impairments in executive function (planning, set-shifting, abstract reasoning, verbal fluency, working memory), often with perseveration, distractibility or inattention; visual–spatial disorganization and impaired visual–spatial memory; personality change with blunting of affect or disinhibited and inappropriate behavior; and difficulties with language production including dysprosodia, agrammatism and mild anomia. The net effect of these disturbances in cognitive abilities is a general lowering of intellectual function. The CCAS arises from damage to the cognitive cerebellum in the cerebellar posterior lobe (lobules VI, VII, possibly lobule IX), and is postulated to reflect dysmetria of thought analogous to the dysmetria of motor control from damage to the sensorimotor cerebellum in the anterior lobe (lobules III through V) and lobule VIII [19,50,74,92,93–95,86]. The CCAS may occur separately or together with the cerebellar motor syndrome and the vestibular syndrome from damage to the flocculonodular lobe. It has been regarded as the third cornerstone of clinical ataxiology and eponymously named Schmahmann's syndrome [26].

7. Replication of the CCAS

The defining features of the CCAS have been extensively replicated across disease types and in patients of different ages [96–113]. Studies in patients with stroke have proven to be particularly effective in identifying the neurobehavioral consequences of cerebellar injury [96,99,100,114–124]. The focus of inquiry has now shifted to defining the extent and limits of cerebellar cognition, to the search for new approaches to treating neuropsychiatric and cognitive manifestations of cerebellar disease, and to utilizing previously unimagined cerebellar avenues of intervention in primary neurobehavioral / psychiatric conditions.

8. CCAS / Schmahmann syndrome scale

It became apparent that there was a need to develop a brief test of cognition and emotion for use in the office or at the bedside, to detect the presence of the CCAS in a patient with cerebellar disease. We studied 77 patients with cerebellar disease and a similar number of healthy matched controls, and a further 39 cerebellar patients in a validation cohort, to develop such a battery of tests [125] (Fig. 4). We confirmed the core executive, visual-spatial, linguistic and affective features of the CCAS, and then used the data to derive the CCAS / Schmahmann Scale. In the cerebellar patient population we found this scale to be more sensitive than the Mini Mental State Test or the Montreal Cognitive Assessment for the detection of the impairments identified with extensive neuropsychological testing. The expectation is that it will be helpful for clinical and research purposes to ascertain whether a patient with cerebellar disease has the CCAS, making it possible to follow progression or resolution over time and its response to treatment. The CCAS / Schmahmann scale has not yet been adapted for children < 18 years.

9. The cerebellar cognitive affective syndrome in children

The CCAS occurs in children as well as in adults. Central nervous system tumors disproportionately affect posterior fossa structures in childhood. The study of Levisohn et al. [98] first addressed this question in 19 children ages 3 to 14 who had undergone resection of cerebellar medulloblastomas, astrocytomas, and ependymomas but who had not received radiation therapy or methotrexate which can adversely impact cognitive outcome. Problems were noted with attention and executive function as evidenced by deficits in digit span (57% of the 14 tested), sequencing, and planning. Establishing and maintaining set was hampered in some cases by perseveration. Deficits in expressive language, present in 58% of the cohort, were characterized by brief responses, lack of elaboration, reluctance to engage in conversation, long response latencies, and word finding difficulties. Several children exhibited difficulties with language initiation and word finding difficulties even in the context of average scores on verbal tests. Deficits in confrontation naming were ameliorated with phonemic cues, a problem

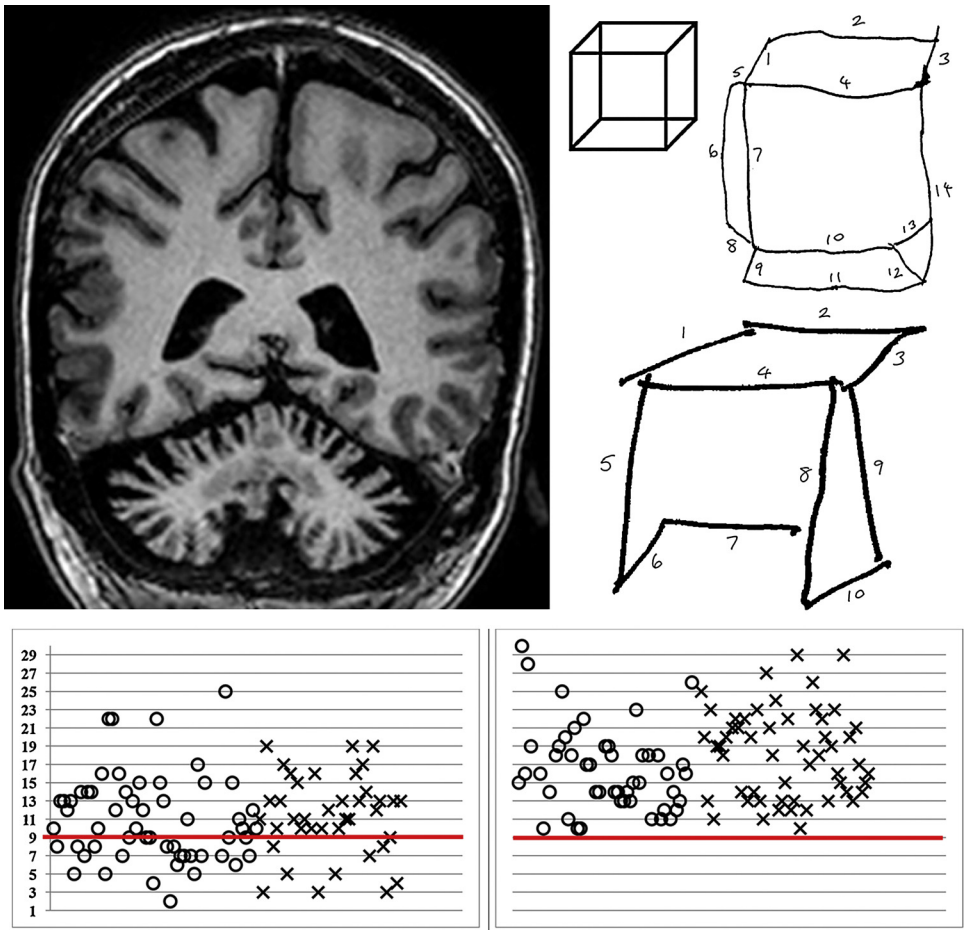

Fig. 4. Coronal image of a brain MRI (top left, BRAVO T1-weighted sequence) shows diffuse cerebellar atrophy in autosomal recessive cerebellar ataxia type 1. The drawings at right are attempts by patients with cerebellar diseases to draw a 3-dimensional diagram of a cube from a verbal description (middle), or copy (bottom) the example shown (at the top). The number of lines drawn by each patient is noted by the examiner and used to score the performance. The tables show the results of a phonemic verbal fluency task. Individuals are asked to name as many words as they can in 1 min starting with the letter F. Left panel – patients with cerebellar disorders; right panel – healthy controls. Circles are the exploratory cohort (77 patients, 54 controls) and Xs are the validation cohort (39 patients, 55 controls) in the study that developed and introduced the CCAS / Schmahmann scale. The red line indicates the cut-off number of words on this task (≤9 words is a failing score) that distinguished cerebellar patients from healthy controls. (For interpretation of the references to colour in this figure legend, the reader is referred to the web version of this article).
From Hoche et al. [125].

of lexical access likely reflecting disrupted cerebellar-prefrontal connections. Many demonstrated difficulty with initiation of responses and with problem-solving strategies. Visual spatial difficulties were present in 37% and were characterized by impairments in the planning and organizational aspects of tasks. Verbal memory was impaired in 33% of 15 children tested, particularly for unstructured recall of information, being able to recall only a few details from stories two paragraphs long. Story retrieval improved with multiple-choice prompts. It appeared that there was failure to organize verbal or visual-spatial material for encoding and that this impacted retrieval of the information. The affective component of the CCAS was also noted. Impaired regulation of affect was particularly evident when the damage to the cerebellum included the vermis, manifesting as irritability, impulsivity, disinhibition, and lability of affect with poor attentional and behavioral modulation.

Impaired executive functions have been reported in subsequent studies of children with cerebellar tumors, including impaired planning, sequencing, mental flexibility and hypothesis generation and testing, visual-spatial function, expressive language, and verbal memory [126–131]. In the series of Scott et al. [132] children with right cerebellar hemisphere tumors experienced a subsequent plateau in verbal and/or literacy skills, whereas those with left cerebellar damage were associated with delayed or impaired spatial skills. Similar phenomena were observed by Riva and Giorgi [97] in 26 children following resection of cerebellar tumors. They noted impairments in verbal intelligence, auditory sequential memory, and language following right-sided tumors; and deficient non-verbal tasks including spatial and visual sequential memory and impaired prosody after left cerebellar hemisphere tumors. Language deficits occurred more frequently following right cerebellar lesions whereas visual-spatial impairments tended to occur with left cerebellar damage, as noted also in other studies [117,124,133]. This is consistent with the crossed connections with the cerebral cortex, and with the findings of domain-specific asymmetry in functional imaging studies of healthy subjects [75]. The lateralized verbal-visual dichotomy appears to be less definitive following cerebellar lesions than it is following cerebral lesions, however.

As in adults, the CCAS occurs in children in the setting of stroke. Five boys ages 3–14 with cerebellar infarcts [134] were noted to have mood disturbances with a few days of outbursts of laughter and/or crying, and alternating agitation or prostration. The children had persistent cognitive deficits including mutism followed by anomia, and impaired comprehension, planning, visual-spatial organization, and attention. The cognitive difficulties improved slowly and incompletely despite intensive rehabilitation and were more disabling than the motor symptoms. The laughing and crying resemble the phenomenon of forced laughing (*fou rire prodromique*) that occurs in patients with basis pontine strokes [135], and the pathologic laughing and crying that occurs in adults with pontocerebellar lesions [136,137]. Post-stroke mutism recapitulates the phenomenon described following cerebellar tumor resection in children [98,138–140], but it also has been noted in less dramatic form in adults with acute cerebellar injury [92].

10. Cerebellar mutism following cerebellar tumor resection in children

More than half the children in Levisohn et al. [98] with extensive damage to the vermis experienced what for a time was called the posterior fossa syndrome [140,141]. This phenomenon was described initially as pseudobulbar palsy [138]; mutism without behavioral impairment [139,142], cerebellar speech syndrome [143]; cerebellar mutism [144], and cerebellar mutism and subsequent dysarthria [145]. After a latent period of 1–2 days of apparently normal behavior following surgery, children developed mutism, with hypotonia and buccal

and lingual apraxia. Recovery of speech ensued over many months, together with slowly improving dysarthria. The syndrome was notable also for behavioral changes including regressive personality, apathy and poverty of spontaneous movement. Emotional lability was marked, with rapid fluctuation of emotional expression gravitating between irritability with inconsolable crying and agitation, to giggling and easy distractibility.

Cerebellar mutism generally follows a surgical approach to tumor resection through the cerebellar vermis, occurring in 15 to 50% of patients according to different studies. The post-operative mutism is not a prerequisite for the development of the intellectual and emotional deficits that comprise the CCAS, either acutely (as in stroke or tumor patients) or more chronically as occurs in destructive or degenerative lesions of the cerebellum [146]. Cerebellar surgery is not required to develop mutism, as it has been reported in children with cerebellar stroke [134] and in adults as was evident in the original CCAS study [92] in which patients with post-infectious cerebellits developed diminished verbal fluency approaching mutism. The consensus understanding of post-operative pediatric cerebellar mutism syndrome [147] is that it is "characterized by delayed onset mutism / reduced speech and emotional lability after cerebellar or 4th ventricle tumor surgery in children. Additional common features including hypotonia and oropharyngeal dysfunction / dysphagia. It may frequently be accompanied by the cerebellar motor syndrome, the cerebellar cognitive affective syndrome, and brainstem dysfunction including long tract signs and cranial neuropathies. The mutism is always transient, but recovery from CMS may be prolonged, and other deficits of cognitive, affective and motor function often persist".

11. Developmental CCAS

It has become apparent that disruptions and gene disorders that cause cerebellar malformations result in a developmental form of the CCAS. Children who have cerebellar hemorrhages *in utero* or early postnatal life deal with a range of neurological limitations, but also problems with expressive and receptive language, and behavioral and social deficits that meet criteria for autism in more than 40 percent [148,149]. A review of published reports between 1997 and 2014 of neurodevelopmental outcomes in preterm infants following cerebellar injury or underdevelopment indicated that early life impairment of cerebellar growth plays a critical role in long-term motor, cognitive, behavioral, and social deficits [150]. Hickey et al. [151] observed this in three brothers with hindbrain malformation in Joubert syndrome, a mutation in the TMEM67 gene. The siblings were all developmentally delayed, demonstrating disproportionate cognitive weaknesses in selected aspects of executive function, language processing, and the visuospatial domain, as well as a pronounced neuropsychiatric constellation, consistent with the CCAS. An extreme version of cerebellar developmental disorder is cerebellar agenesis which has been known since the 1800s, in which there is only a nubbin of cerebellar tissue evident. Cerebellar agenesis likely represents a disruption such as stroke or hemorrhage *in utero* or very early in life, because genetic studies to date have not identified an underlying cause. Patients have a minimal cerebellar motor syndrome when they are older, although speech is somewhat child-like and there are usually eye movement irregularities. What stands out, though, is developmental motor and cognitive delay, and cognitive-emotional challenges with the full set of CCAS features including deficits in social cognition [152,153]. The mechanisms of the long-term consequences of cerebellar malformations on subsequent growth and development across domains are not yet known. Perhaps this reflects a deficit in sustaining projections between cerebellum and cerebral cortical and subcortical sites, functioning through trophic mechanisms required for the development and pruning of connections in the typically developing brain. This hypothesis remains to be tested.

12. The hereditary ataxias

In the sphere of clinical neurology, the cerebellum is perhaps best known for its involvement in the spinocerebellar ataxias (SCAs). These genetically mediated disorders cause progressive motor disability, degrade quality of life, and in many instances, lead to early death. It is now apparent that cognition is involved to varying degrees in every gene-defined SCA [154]. These deficits conform to the pattern of the CCAS – executive function, linguistic processing, spatial cognition, verbal and visual memory and changes in affect. Even SCA6, the purest cerebellar form of the SCAs, has problems with executive function, and in the study of Hoche et al. [125], there were no significant group differences in cognitive performance between patients with complex cerebrocerebellar disease versus isolated cerebellar pathology with the exception of a test of Similarities in which complex patients were more impaired. These observations supported the conclusions of Orsi et al. [155] who observed mnestic, linguistic, visuospatial, attentional, executive, and mood changes consistent with the CCAS in patients with SCA 1, 2, 6 and 8, with no significant differences between the SCA subgroups. Cognitive changes deepen during the course of the disease, as in SCA3 [156]. Moreover, we have observed true amestic dementia (i.e., loss of previously acquired memories rather than inability to recall spontaneously or with clue) in some patients in the late stages of their neurodegenerative ataxia. We regard this as likely reflecting neuropathology involving medial temporal lobe structures, because long term recall is usually relatively spared in the CCAS [92,98,125], even though access to stored events and facts through executive control of recall is impaired. This interpretation of memory function in cerebellar disorders is embedded in the scoring of the CCAS/Schmahmann Scale. This conclusion is consistent also with the appropriately cautious interpretation of cognition in the hereditary ataxias by Lindsay and Storey [157] who point out that disorders like SCA 17 may include widespread cognitive impairment including dementia in some patients.

Ataxia telangiectasia, a childhood onset disorder caused by mutations in the ATM gene known for its effect on the motor system, has recently been shown to be associated with cognitive impairments that become more appreciable as the disease evolves [110], and Friedreich's ataxia, a predominantly afferent ataxia with involvement of the deep cerebellar nuclei as well, was shown earlier to produce slowing of cognition [158] and more recent analyses indicate impairments in verbal fluency, working memory and social cognition [159]. These observations provide important guidance to patients and families, and help structure management in the school setting to maximize learning opportunities and quality of life. The National Ataxia Foundation, recognizing the need for patients and families to understand the non-motor aspects of the ataxias, produced a Fact Sheet for members addressing the topic of cognition and emotion in cerebellar disorders.

13. Neuropsychiatry of the cerebellum; the affective component of the CCAS

Emotional dysregulation can be a prominent aspect of the CCAS in both adults and children [92,98]. Adults with acute cerebellar infarcts involving the vermis and fastigial nucleus have developed abrupt onset panic disorder, persisting for 6 months before being able to resume normal activities free of the disabling anxiety [103]. Acquired panic may reflect overshoot of anticipatory fear [160] resulting from cerebellar-induced emotional dyscontrol, a phenomenon akin to cognitive overshoot as reported previously [22].

Pathological laughing and crying occurs after stroke in the pontocerebellar circuit [136,161] including the basis pontis [162,57] and cerebellum [163]. It is also described in post-infectious cerebellitis [164] and the cerebellar form of multiple system atrophy (MSA [137]). These findings provide support for the notion that the cerebellum is engaged in the voluntary control of emotional expression.

The behavioral changes in children following cerebellar tumor

resection include disinhibition, impulsivity and irritability [165], dysphoria, inattention and irritability [128]. Anxiety, aggression [166], and stereotypies and aberrant interpersonal relations are reported, meeting criteria for the diagnosis of autism [97].

The immune-mediated opsoclonus myoclonus syndrome (OMS) occurs in children [167] as a postinfectious, or more commonly, as a paraneoplastic phenomenon in the setting of neuroblastoma [168], and it also affects adults as a paraneoplastic phenomenon [169,170]. In children OMS produces a psychiatric constellation of mood changes and inconsolable irritability with lability, aggression and night terrors. Dysphoric mood, disinhibition and poor affect regulation, disruptive behaviors and temper tantrums occur together with the cognitive and language impairments typically seen in the CCAS. The emotional deficits in children, like the post-tumor cognitive components of the CCAS, may be persistent and clinically important (e.g. [103,168,171]). Further, these behavioral changes have a predilection for lesions involving the vermis and paravermian regions. This is consistent with earlier clinical studies [172] and electrophysiological investigations in animals [173] and patients [174] that led to notion of the cerebellum as an emotional pacemaker [43], and contemporary evidence also implicates the cerebellar vermis and fastigial nucleus as the limbic cerebellum [19,60,175].

Depression is quite common in patients with spinocerebellar ataxias, reaching a prevalence of 26% in the 300 participants with SCA 1, 2, 3 and 6 in the Clinical Research Consortium for Spinocerebellar Ataxias [176], and particularly in SCA 3 in which suicidal ideation reached 65%. Adults and children with cerebellar lesions may have altered regulation of mood and personality, psychotic thinking, and behaviors that meet criteria for diagnoses of attention deficit hyperactivity disorder, obsessive compulsive disorder, depression, bipolar disorder, disorders on the autism spectrum, atypical psychosis, and as noted, anxiety and panic disorder [103]. Other features include a lack of initiation, apathy and irritability. We conceptualized these behaviors as either excessive or reduced responses to the external or internal environment. The exaggerated, positive, released, or hypermetric responses may be regarded as analogous to motor [10,11] or cognitive overshoot [22]. The diminished, negative, restricted or hypometric responses may be likened to hypotonia [10], or to hypometric movements (undershoot) in the motor system following cerebellar lesions. Further, we conceptualized these manifestations as falling into five neuropsychiatric domains – attentional control, emotional control, social skill set, autism spectrum disorders, and psychosis spectrum disorders [103]. Some manifestations, such as the negative symptoms included in the social skill set, are reminiscent of observations regarding the cerebellar role in theory of mind studies [177,178], and provide a clinical underpinning to this observation from experimental psychology.

Schizophrenia remains an enigma in medicine and neuropsychiatry. The cerebellum has been implicated in studies identifying minor motor phenomena in schizophrenia patients, and morphometric analyses show loss of the normal cerebellar asymmetry [179] and enlargement of the IVth ventricle (see [19]). Contemporary investigations show that the cerebellum influences medial frontal networks. Frontal and cerebellar neurons have delta-frequency interactions, and optogenetic stimulation of thalamic synaptic terminals of lateral cerebellar projection neurons in a rodent model of schizophrenia-related frontal dysfunction rescue timing performance as well as medial frontal activity [180]. Further, cerebellar grey matter volume is reduced in schizophrenia, particularly in cerebellar regions showing functional connectivity with frontoparietal cortices [181]. In a proof of principle pilot study, we applied TMS to the cerebellum in patients with refractory schizophrenia and showed improvements on psychiatric rating scales, particularly the negative symptoms, as well as improvements in attention, alertness and depression [182]. This work is ongoing in our centre and elsewhere [183,184] under the umbrella of neuromodulation as a means of enhancing cerebellar regulation of neural networks engaged in intellect and emotion. Early infantile autism (discussed elsewhere in this special issue), once called juvenile schizophrenia, has pathology in cerebellum on imaging and post-mortem analysis [185]. Right Crus I – parietal lobe interactions appear relevant in the pathophysiology of autism spectrum disorder [186], and in the tuberous sclerosis complex mouse model of autism loss of the responsible Tsc1 gene in Purkinje neurons results in autistic-like behaviors, including abnormal social interaction, repetitive behavior and vocalizations [187].

14. Social cognition and the cerebellum

Social cognition is defined as the set of mental processes required to understand, generate and regulate social behavior [188,189], and deficits in social cognition underlie many neuropsychiatric disorders. It includes emotion attribution (EA), the detection or decoding of the mental states of others based on immediately available observable information [190]. The neural circuitry underlying social cognition involves frontolimbic connections [188,191], mirror neurons in ventral premotor and rostral posterior parietal cortices [192], the amygdala [193], insula [194], medial temporal gyrus [195], and middle temporal gyrus [194,196]. The cerebellum is incorporated into all these associative and paralimbic circuits [23,50,64,24,197]: The limbic cerebellum (vermis, adjacent regions of the posterior cerebellar hemispheres, and the associated fastigial nuclei; [47,103]) are linked anatomically with the amygdala, septum and hippocampus [173,198]; stimulation of the cerebellar vermis modulates firing patterns in these areas [199,200]; patients with midline lesions demonstrate social-emotional aberrant behaviors [19,92,98,201,202] and earlier studies using cerebellar vermal stimulation ameliorated aggression in patients [43].

Initial studies in cerebellar patients using story-based assessments of EA [203] were inconclusive: patients with spinocerebellar ataxia (SCA) 2 and SCA7 were impaired on this task [204], whereas those with superficial siderosis [102] and SCA3 and SCA6 [205] were not. Picture-based emotion attribution tasks did detect impaired EA performance in cerebellar patients: Photographs of faces adapted from the Florida Affect Battery [206] were administered to 15 patients with cerebellar stroke, demonstrating impaired emotional facial expression and emotional prosody in response to stimuli with negative valence [207]. And the Ekman 60 Faces battery and the Tamietto 50 Faces test [208] were administered to patients with SCA 2 (n = 9), SCA6 (n = 5), SCA 7 (n = 2), and SCA 8 (n = 4), showing that patients were impaired in comparison to controls in recognition of all emotional stimuli [209].

We assessed EA in 57 patients with cerebellar pathology [210] measured with the Reading the Mind in the Eyes task (RMET). Patient informants (usually family members) were administered a beta form of a novel questionnaire, the Cerebellar Neuropsychiatric Rating Scale (CNRS). The study revealed that EA was impaired in all patients when compared to controls. When analyzed for valence categories missed, cerebellar patients missed more negatively and positively charged targets than neutral targets. Further, they were less likely to identify positive valence eyes than neutral or negative valence eyes when compared with their corresponding control groups (Fig. 5). Emotion attribution impairments correlated with the informant reported measures of deficient social skills and autism spectrum behaviors identified using the CNRS, which also showed that patients were experiencing difficulties with emotion regulation, autism spectrum behaviors, and psychosis spectrum symptoms. This study provided further empirical evidence that patients with cerebellar damage are impaired on a task of emotion attribution associated with deficient social skills and autism spectrum behaviors, and they endorsed psychosocial difficulties on the beta version of the CNRS.

There are thus intriguing data pointing to a cerebellar contribution to social cognition, with the affective component of the CCAS interfering with the ability to understand, generate, and control social behavior.

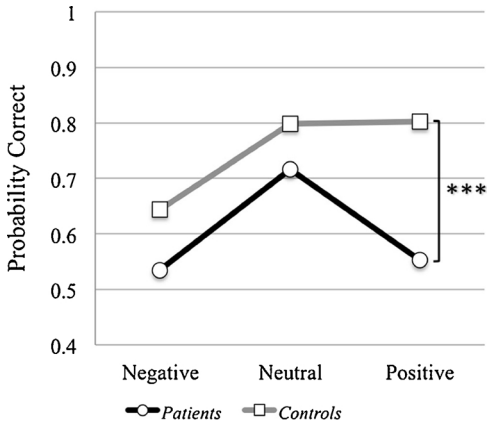

Fig. 5. Mean probability of correct responses per valence category (negative, neutral, and positive stimuli) on the Reading the Mind in the Eyes Task (RMET) for cerebellar patients and matched controls. Patients were more inaccurate on assessing positive stimuli than healthy controls (***$p < 0.001$).
From Hoche et al. [210].

15. Language and metalinguistic impairments in patients with cerebellar dysfunction

Language difficulties in the original descriptions of the CCAS [91,92] included dysprosodia, agrammatism, anomia, impaired syntax, and deficits in verbal fluency and telegraphic speech, while children with CCAS experienced expressive language deficits, word finding difficulties, and mutism in those with damage to the vermis [98]. Subsequent insights into the modulatory role of the cerebellum in language include the contribution of the cerebellum to speech and language perception (pitch discrimination, temporal organization of complex acoustic signals, integration of signals from multiple sensory modalities, and processing of durational parameters of acoustic stimuli), grammar (detection of deviations from grammar rules and search and retrieval of implicitly learned grammar rules), motor speech planning, syntax processing, and the dynamics of language production including writing, and reading skill - highlighting its connection with dyslexia [106,211]. Phonological and semantic verbal fluency tasks and verbal working memory tests that tap executive function also rely heavily on verbal output and therefore reflect the integrity of language processing. Patients with cerebellar damage are impaired on a word stem completion tasks [74], and functional neuroimaging paradigms demonstrate the cerebellar role in processing word stems that have few possible completions [212].

Superimposed upon the structure of language itself, is the way we use language to express thoughts and emotions. This is metalinguistics, higher level language functions essential for social interaction, namely, the ability to engage with and respond to the contextual and situational demands inherent in normal discourse. Metalinguistics includes the ability to (i) interpret ambiguities in the utterances of others, (ii) understand figurative language, (iii) make logical inferences, and (iv) construct meaningful sentences appropriate to context. We studied patients with cerebellar disease on a constrained language task - the Oral Sentence Production Test (OSPT; [213]) which assesses production of sentences with correct syntactic structure and semantic quality, and on the Test of Language Competence-Expanded (TLC-E [214]) that assesses metalinguistic ability. The OSPT failed to reveal differences between patients and controls. In contrast, all cerebellar patients were impaired on the four TLC-E subtests, that is, the ability to understand and use ambiguity (Table 1), inference and metaphor, and the ability to express thoughts in a grammatically coherent manner according to the context and environment. These results suggested three separate but related language impairments following cerebellar dysfunction: (1) disruption in automatic adjustment of intact grammatical and semantic abilities to a linguistic context in sentence production, (2) disruption in automatic adjustment to a linguistic context in sentence interpretation, and (3) disruption of cognitive processes essential for linguistic skills, such as analysis and sequential logical reasoning [215]. We conceptualized these findings as manifestations of dysmetria of thought, providing empirical support for the theory of the universal cerebellar transform. This may be compounded by deficits in theory of mind, the ability to interpret the thoughts or feelings of another person, further hampering optimal social engagement.

16. The dysmetria of thought theory

We conceptualized the new information about the cerebellar role in this wide range of nervous system functions with the dysmetria of thought theory, which states that in the same way that the cerebellum regulates the rate, rhythm, force and the accuracy of movements, so does it regulate the speed, consistency, capacity, and appropriateness of mental or cognitive processes [19] (Fig. 6). The dysmetria of thought theory is predicated on the mostly invariant trilaminar architecture of the cerebellar cortex on the one hand, coupled with the rich heterogeneity of cerebellar connections and functional topography on the other.

In this view, the essentially homogeneous cerebellar cortex and repeating corticonuclear microcomplexes [49] are the anatomical and physiological substrates that subserve a constant cerebellar computation [19,66], the universal cerebellar transform (UCT; [47,175]). The reason the cerebellum is engaged in different domains – comprising a sensorimotor anterior lobe, cognitive posterior lobe, and limbic vermis, is that the UCT is applied to the heterogeneous and precisely arranged cerebellar connections with the spinal cord, brainstem and cerebral hemispheres, enabling the cerebellum to modulate diverse streams of information. It does this by integrating multiple internal representations with external stimuli and self-generated responses, maintaining behavior around a homeostatic baseline, automatically, without conscious awareness, serving as an oscillation dampener to optimize performance according to context [19,50,47,175,23,24,92]. The corollary of the universal cerebellar transform is that when the cerebellum is dysfunctional, the manifestation should be consistent across modalities as well. This manifestation is dysmetria – the universal cerebellar impairment. Dysmetria from lesions of the cerebellar anterior lobe / motor syndrome manifests as gait ataxia, limb dysmetria and dysarthric speech. Dysmetria from damage to the cerebellar posterior lobe / cognitive-limbic syndrome manifests as the cerebellar cognitive affective / Schmahmann syndrome, the third cornerstone of clinical ataxiology.

17. Empirical tests of the dysmetria of thought theory

Two critical components of the dysmetria of thought theory have recently been tested by empirical observation: cerebrocerebellar connectional topography, and the UCT theory. The connectivity hypothesis was assessed by delivering intermittent theta burst transcranial magnetic stimulation (TMS) to the cerebellum in healthy human volunteers guided by subject-specific connectivity. TMS to vermal lobule VII influenced the dorsal-attention/fronto-parietal network, whereas TMS to lateral parts of Crus I and II modulated the cerebral default mode network [216]. These results provided novel insights into the distributed, but anatomically specific, modulatory impact of cerebellar effects on large-scale neural network function. Further, stimulating cerebellar nodes integrated in different networks produced the same effect on the temporal complexity of the different cortical signals. TMS applied to vermis lobule VII (linked with the dorsal-attention/fronto-parietal network) and right lateral cerebellar Crus I/II (coupled with the default-mode networks) increased the complexity of brain signals across multiple time scales in a network-specific manner identified through electroencephalography. There was also a region-specific shift in power of

Table 1
Examples of answers provided by cerebellar patients when shown ambiguous sentences on the Test of Language Competence-Expanded (at left) and asked to generate two possible interpretations of these sentences (Meanings 1 and 2).
From Guell et al. [215].

Ambiguous sentence	Meaning 1	Meaning 2
Right then and there the man drew a gun	He is trying to rob me	He will shoot to someone else
I saw the girl take his picture	She photographs things	She liked the guy
And then the man wiped the glasses carefully	He had to be very careful because the glasses might break	The glasses were already broken
Helen laughed at the library	Helen laughed at the library because there are no books in there	She could laugh at how small it is, big with no books or small with a lot of books
The man was sure the duck was ready to eat	He was cooking it	He was serving it
I have always known that flying planes can be dangerous	Being a passenger	Being a pilot
The boy was looking up the street	Looking up the street seeing the accident	Looking up the street looking for his mother
The roar of the fans disturbed the team	The white team lost and the fans roared	The coach was thrown out
I knew that glare really bothered Jane	Without sunglasses, it was very sunny, the glare bothered her	Glare is the name of a person, it bothered Jane
I don't know about you, but visiting relatives can be a nuisance	Visits from relatives can be a nuisance	Relatives that visit can be a nuisance
Can you believe Mary wanted to run as well as me	Run a race physically	Both run for class president
The woman finally decided to press the suit	Ironing the suit	Physically pressing the suit with the fingers
Bob did not blame the girl as much as her mother	Bob placed more blame on mother	Bob thought the mother was blamed for some of the girls actions

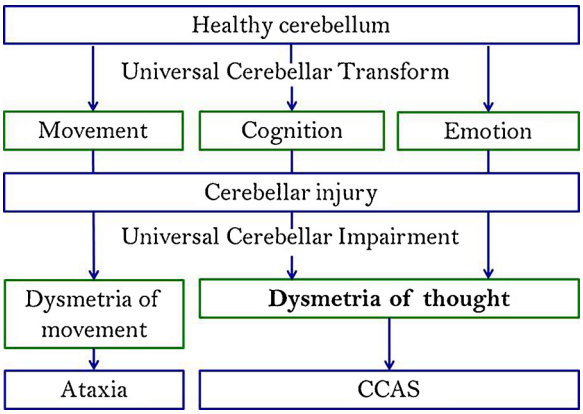

Fig. 6. Schematic of the dysmetria of thought and universal cerebellar transform theories.
From Guell et al. [215].

cortical oscillations towards higher frequencies consistent with the natural frequencies of targeted cortical areas. These findings provided new evidence and a novel mechanism for the nature of the UCT, namely, specific cerebellar subregions control the temporal dynamics of the networks they are engaged in [217].

18. Future directions

Investigations into the cognitive neuroscience of the cerebellum are rapidly advancing, extending far beyond the traditional view of the inherited and acquired cerebellar ataxias into other realms of traditional neurology and into neuropsychiatry.

There is a sizeable literature on the neuropathological, structural and functional neuroimaging studies of the cerebellum in Alzheimer's disease. This prompted the recent integrative hypothesis [218] that cerebellar involvement in Alzheimer's disease may manifest as a failure to modulate neurobehavioral repertoires in the cognitive and neuropsychiatric domain. The cerebellum has also been implicated in the behavioral, executive and language deficits in patients with frontotemporal dementia (FTD) by virtue of cerebellar atrophy identified with voxel-based morphometry across the amyotrophic lateral sclerosis (ALS) - behavioral variant FTD continuum [219]. This is particularly notable in the C9orf72 variant of frontotemporal lobar degeneration with ALS that includes cerebellar volume loss [220] and ubiquitin and p62 positive but TDP-43 negative neuronal cytoplasmic and intranuclear inclusions [221].Voxel based morphometric studies also reveal structural atrophy in the cerebellum in neurodegenerative diseases [222]: focal atrophy was present in cerebellar crus I and crus II bilaterally in Alzheimer's disease, and in anterior and superior portions of the cerebellum peaking in left lobule VI in behavioral variant frontotemporal dementia. These atrophied cerebellar regions shared selective intrinsic connectivity with the atrophied regions in the cerebral cortex.

Multiple sclerosis (MS) has long been identified as having cognitive and neuropsychiatric features as well as sensorimotor impairments [223]. MS plaques in the cerebellar white matter are well known, but there is new information about the topography of the cerebellar MS plaques and the clinical presentation. In relapsing remitting MS patients with cognitive impairment there is a predilection for involvement of the middle cerebellar peduncles (MCP) that convey information from the cerebral cortex to cerebellum, and voxel-based lesion symptom mapping shows that these MCP lesions are associated with the cognitive rather than the motor impairment [224].

The evolving understanding that patients with disease of the cognitive – limbic cerebellum have impairments in higher order behavior has a direct impact on patient care. The first implication is the need-to-know imperative. It is liberating as a patient and family member to learn that changes in intellect and emotion are not "in their head" (a psychological reaction to a medical situation) but are "in their brain" – a neuropsychiatric consequence of disruption of cerebellar influence on brain systems underlying behavior. This recognition also enables opportunities for novel treatments and cross-modal therapies [225]. The possibility of moving from theory to therapy, translating the new understanding of cerebellar contributions to higher order function into treatments for patients with disease, may now be attainable.

These approaches are nested within a re-examination of the role of the cerebellum, and the recognition that cerebellar incorporation into non-motor circuits enriches the understanding of the neural basis of higher function and the anatomical and clinical manifestations of neurodegenerative and neuropsychiatric disease [226].

19. Conclusion

The young field of the cognitive neuroscience of the cerebellum has matured. The clinical implications have become increasingly apparent, and the fundamental questions have deepened. There is now a more holistic and realistic view of the cerebellum and its necessary and unique contribution as an integral node in the distributed neural circuits

subserving human behavior across all domains. This revolution in our thinking about the cerebellum has introduced the possibility of novel interventions in neurology and neuropsychiatry to improve the lives of patients with nervous system disorders.

Acknowledgements

Supported in part by the National Ataxia Foundation, Ataxia Telangiectasia Children's Project, and the MINDlink Foundation. The assistance of Jason MacMore, Samantha Pierce and Xavier Guell is gratefully acknowledged.

References

[1] P. Flourens, Recherches experimentales sur les proprietes et les fonctions du systseme nerveux, dans les animaux vertebres, Crevot, Paris (1824).
[2] A. Flint Jr., The Physiology of Man: designed to represent the existing stat of physiological science as applied to the functions of the human body, D. Appleton and Co., New York, 1873.
[3] L. Luciani, Il cervelletto; nuovi studi di fisiologia normale e patologica. Firenze: Le Monnier. Translated in: Turner WA. Reviews and notices of books, Brain 15 (1892) (1891) 283–299.
[4] D. Ferrier, W.A. Turner, A record of experiments illustrative of the symptomatology and degenerations following lesions of the cerebellum and its peduncles and related structures in monkeys, Philos. Trans. R. Soc. 185 (1893) 719–778.
[5] J.S.R. Russell, Experimental researches into the functions of the cerebellum, Phil. Trans. Roy. Soc. 185 (1894) 819–861.
[6] S. Brown, On hereditary ataxy, with a series of twenty-one cases, Brain 15 (1892) 250–282.
[7] P. Marie, Sur l'hérédo-ataxie cérébelleuse, Sem. Méd. 13 (1893) 444–447.
[8] J. Babinski, De l'asynergie cérébelleuse, Revue Neurologique 7 (1899) 806–816.
[9] G. Holmes, A form of familial degeneration of the cerebellum, Brain 30 (1907) 466–488.
[10] G. Holmes, The symptoms of acute cerebellar injuries due to gunshot wounds, Brain 40 (1917) 461–535.
[11] G. Holmes, The cerebellum of man (Hughlings Jackson memorial lecture), Brain 62 (1939) 1–30.
[12] V. Malacarne, Nuova esposizione della vera struttura del cervelletto umano. G. Briolo, Torino, (1776).
[13] A. Zanatta, C. Cherici, A. Bargoni, Vincenzo Malacarne (1744–1816) and the first description of the human cerebellum, Cerebellum 17 (4) (2018) 461–464, https://doi.org/10.1007/s12311-018-0932-7.
[14] Combette, Observation d'une jeune fille, morte dans sa onzième annèe, chez laquelle il y avait absence complete du cervelet, des pédoncules postérieures et de la protubérance annulaire, Journal de physiologie (1831) 27 Paris. tome xi.
[15] J.D. Fisher, Contributions illustrative of the functions of the cerebellum, Am. J. Med. Sci., Philadelphia 55 (1838) 352–362.
[16] C.D. Aring, An appreciation. In a tribute to Sir Gordon Holmes, J. Nerv. Ment. Dis. 141 (1965) 497–502.
[17] I. McDonald, Gordon Holmes lecture: Gordon Holmes and the neurological heritage, Brain 130 (2007) 288–298.
[18] F.J. Gall, J. Vimont, F.J.V. Broussais, On the Functions of the Cerebellum. Translated from French by George Combe, George Combe and A Combe, MacLachlan & Stewart, Edinburgh: Longman & Co and Simpkin, Marshall and Co., London, 1838.
[19] J.D. Schmahmann, An emerging concept: the cerebellar contribution to higher function, Arch. Neurol. 48 (1991) 1178–1187.
[20] J.D. Schmahmann (Ed.), The Cerebellum and Cognition, 41 Academic Press, San Diego, 1997Int. Rev. Neurobiol..
[21] H.C. Leiner, A.L. Leiner, R.S. Dow, Does the cerebellum contribute to mental skills? Behav. Neurosci. 100 (1986) 443–454.
[22] J.D. Schmahmann, Dysmetria of thought. Clinical consequences of cerebellar dysfunction on cognition and affect, Trends Cogn. Sci. 2 (1998) 362–370.
[23] J.D. Schmahmann, D.N. Pandya, Anatomical investigation of projections to the basis pontis from posterior parietal association cortices in rhesus monkey, J. Comp. Neurol. 289 (1989) 53–73.
[24] J.D. Schmahmann, D.N. Pandya, The cerebrocerebellar system, in: J.D. Schmahmann (Ed.), The Cerebellum and Cognition. Int. Rev. Neurobiol. 41:31–60, Academic Press, San Diego, 1997.
[25] F.A. Middleton, P.L. Strick, Anatomical evidence for cerebellar and basal ganglia involvement in higher cognitive function, Science 266 (1994) 458–461.
[26] M. Manto, P. Mariën, Schmahmann's syndrome - identification of the third cornerstone of clinical ataxiology, Cerebellum 2 (2015) 2.
[27] L. Bolk, Das Cerebellum der Saugetiere: Jena, (1906).
[28] C.N. Woolsey, Summary of the papers on the cerebellum, Res. Publ. Assoc. Res. Nerv. Ment. Dis. 30 (1952) 334–336.
[29] R.S. Snider, A. Stowell, Receiving areas of the tactile, auditory, and visual systems in the cerebellum, J. Neurophysiol. 7 (1944) 331–357.
[30] R.S. Snider, E. Eldred, Cerebral projections to the tactile, auditory and visual areas of the cerebellum, Anat. Rec. 100 (1948) 714.
[31] R.S. Snider, Recent contributions to the anatomy and physiology of the cerebellum, Arch. Neurol. Psychiatry 64 (1950) 196–219.
[32] R.S. Snider, Interrelations of cerebellum and brainstem, Res. Publ. Assoc. Res. Nerv. Ment. Dis. 30 (1952) 267–281.
[33] E. Henneman, P.M. Cooke, R.S. Snider, Cerebellar projections to the cerebral cortex, in: P. Bard (Ed.), Patterns of Organization in the Central Nervous System. Res. Publ. Ass. Nerv. Ment. Dis. 30, 1952, pp. 317–333.
[34] G.I. Allen, N. Tsukahara, Cerebrocerebellar communication systems, Physiol. Rev. 54 (1974) 957–1006.
[35] P.D. MacLean, Psychosomatic disease and the visceral brain; Recent developments bearing on the Papez theory of emotion, Psychosom. Med. 11 (1949) 338–353.
[36] R.S. Snider, A. Maiti, Cerebellar contributions to the Papez circuit, J. Neurosci. Res. 2 (1976) 133–146.
[37] O. Oscarsson, Functional Organization of the Spino- and cuneocerebellar tracts, Physiol. Rev. 45 (1965) 495–522.
[38] G. Moruzzi, Sham rage and localized autonomic responses elicited by cerebellar stimulation in the acute thalamic car, Oxford, Proc. XVII Int. Congr. Physiol. (1947), pp. 114–115.
[39] D.J. Reis, N. Doba, M.A. Nathan, Predatory attack, grooming and consummatory behaviors evoked by electrical stimulation of cat cerebellar nuclei, Science 182 (1973) 845–847.
[40] J. Martner, Cerebellar influences on autonomic mechanisms, Acta Physiol. Scand. 424 (Suppl) (1975) 1–42.
[41] R.F. Thompson, Neuronal substrate of simple associative learning. Classical conditioning, Trends Neurosci. 6 (1983) 270–275.
[42] I.S. Cooper, L. Amin, S. Gilman, J.M. Waltz, The effect of chronic stimulation of cerebellar cortex on epilepsy in man, in: I.S. Cooper, M. Riklan, R.S. Snider (Eds.), The Cerebellum, Epilepsy and Behavior, Plenum Press, New York, 1974, pp. 119–172.
[43] R.G. Heath, Modulation of emotion with a brain pacemaker. Treatment for intractable psychiatric illness, J. Nerv. Ment. Dis. 165 (1977) 300–317.
[44] R.G. Heath, Foreword, in: J.D. Schmahmann (Ed.), The Cerebellum and Cognition. Int Rev Neurobiol, 41, Academic Press, San Diego, 1997xxiii – xxv.
[45] A.F. Berman, D. Berman, J.W. Prescott, The effect of cerebellar lesions on emotional behavior in the rhesus monkey, in: I.S. Cooper, M. Riklan, R.S. Snider (Eds.), The Cerebellum, Epilepsy and Behavior, Plenum Press, New York, 1978, pp. 277–284.
[46] J.D. Schmahmann, D.N. Pandya, Disconnection syndromes of basal ganglia, thalamus, and cerebrocerebellar systems, Cortex 44 (2008) 1037–1066.
[47] J.D. Schmahmann, The role of the cerebellum in affect and psychosis, J. Neurolinguist. 13 (2000) 189–214.
[48] A. Brodal, Neurological Anatomy in Relation to Clinical Medicine, Oxford University Press, New York, Oxford, 1981.
[49] M. Ito, New York, The Cerebellum and Neural Control, Raven Press, 1984.
[50] J.D. Schmahmann, From movement to thought: anatomic substrates of the cerebellar contribution to cognitive processing, Hum. Brain Mapp. 4 (1996) 174–198.
[51] J.D. Schmahmann, Cerebellum and brainstem, in: A. Toga, J. Mazziotta (Eds.), Brain Mapping. The Systems, Academic Press, San Diego, 2000, pp. 207–259.
[52] J.D. Schmahmann, Cerebellum and spinal cord - principles of development, anatomical organization, and functional relevance, in: A. Brice, S. Pulst (Eds.), Spinocerebellar Degenerations: The Ataxias and Spastic Paraplegias, Elsevier, New York, 2007, pp. 1–60.
[53] J. Voogd, M. Glickstein, The anatomy of the cerebellum, Trends Neurosci. 21 (1998) 370–375.
[54] J. Voogd, Cerebellum and precerebellar nuclei, in: G. Paxinos, J.K. Mai (Eds.), The Human Nervous System, Elsevier Academic Press, Amsterdam, 2004pp. 321–-392.
[55] P. Brodal, The corticopontine projection in the rhesus monkey: origin and principles of organization, Brain 101 (1978) 251–283.
[56] K. Hartmann-von Monakow, K. Akert, H. Kunzle, Projection of precentral, premotor and prefrontal cortex to the basilar pontine grey and to nucleus reticularis tegmenti pontis in the monkey (Macaca fascicularis) Schweiz, Arch. Neurol. Neurochir. Psychiatr. 129 (1981) 189–208.
[57] J.D. Schmahmann, R. Ko, J. MacMore, The human basis pontis: motor syndromes and topographic organization, Brain 127 (2004) 1269–1291.
[58] W.T. Thach, Cerebellar inputs to motor cortex, Ciba. Found. Symp. 132 (1987) 201–220.
[59] R.M. Kelly, P.L. Strick, Cerebellar loops with motor cortex and prefrontal cortex of a nonhuman primate, J. Neurosci. 23 (2003) 8432–8444.
[60] J.D. Schmahmann, The cerebrocerebellar system: anatomic substrates of the cerebellar contribution to cognition and emotion, Int. Rev. Psychiatry 13 (2001) 247–260.
[61] J.D. Schmahmann, D.N. Pandya, Projections to the basis pontis from the superior temporal sulcus and superior temporal region in the rhesus monkey, J. Comp. Neurol. 308 (1991) 224–248.
[62] J.D. Schmahmann, D.N. Pandya, Course of the fiber pathways to pons from parasensory association areas in the rhesus monkey, J. Comp. Neurol. 326 (1992) 159–179.
[63] J.D. Schmahmann, D.N. Pandya, Prelunate, occipitotemporal, and parahippocampal projections to the basis pontis in rhesus monkey, J. Comp. Neurol. 337 (1993) 94–112.
[64] J.D. Schmahmann, D.N. Pandya, Anatomic organization of the basilar pontine projections from prefrontal cortices in rhesus monkey, J. Neurosci. 17 (1997) 438–458.
[65] R.P. Dum, P.L. Strick, An unfolded map of the cerebellar dentate nucleus and its projections to the cerebral cortex, J. Neurophysiol. 89 (2003) 634–639.
[66] R.S. Dow, Some novel concepts of cerebellar physiology, Mt. Sinai J. Med. (NY) 41 (1974) 103–119.

[67] B.A. Whiting, R.A. Barton, The evolution of the cortico-cerebellar complex in primates: anatomical connections predict patterns of correlated evolution, J. Hum. Evol. 44 (2003) 3–10.
[68] N. Ramnani, T. Behrens, H. Johansen-Berg, M. Richter, M. Pinsk, J. Andersson, et al., The evolution of prefrontal inputs to the cortico-pontine system: diffusion imaging evidence from macaque monkeys and humans, Cereb. Cortex 16 (2006) 811–818.
[69] I. Sugihara, Y. Shinoda, Molecular, topographic, and functional organization of the cerebellar cortex: a study with combined aldolase C and olivocerebellar labeling, J. Neurosci. 24 (2004) 8771–8785.
[70] C. Habas, N. Kamdar, D. Nguyen, K. Prater, C.F. Beckmann, V. Menon, et al., Distinct cerebellar contributions to intrinsic connectivity networks, J. Neurosci. 29 (2009) 8586–8594.
[71] F.M. Krienen, R.L. Buckner, Segregated fronto-cerebellar circuits revealed by intrinsic functional connectivity, Cereb. Cortex 19 (2009) 2485–2497.
[72] J.X. O'Reilly, C.F. Beckmann, V. Tomassini, N. Ramnani, H. Johansen-Berg, Distinct and overlapping functional zones in the cerebellum defined by resting state functional connectivity, Cereb. Cortex 20 (2010) 953–965.
[73] R.L. Buckner, F.M. Krienen, A. Castellanos, J.C. Diaz, B.T. Yeo, The organization of the human cerebellum estimated by intrinsic functional connectivity, J. Neurophysiol. 106 (2011) 2322–2345.
[74] C.J. Stoodley, J.D. Schmahmann, The cerebellum and language: evidence from patients with cerebellar degeneration, Brain Lang. 110 (2009) 149–153.
[75] C.J. Stoodley, J.D. Schmahmann, Functional topography in the human cerebellum: a meta-analysis of neuroimaging studies, Neuroimage 44 (2009) 489–501.
[76] C.J. Stoodley, E.M. Valera, J.D. Schmahmann, An fMRI case study of functional topography in the human cerebellum, Behav. Neurol. 23 (2010) 65–79.
[77] E.A. Moulton, I. Elman, G. Pendse, J.D. Schmahmann, L. Becerra, D. Borsook, Aversion-related circuitry in the cerebellum: responses to noxious heat and unpleasant images, J. Neurosci. 31 (2011) 3795–3804.
[78] X. Guell, J.D.E. Gabrieli, J.D. Schmahmann, Triple representation of language, working memory, social and emotion processing in the cerebellum: convergent evidence from task and seed-based resting-state fMRI analyses in a single large cohort, NeuroImage 172 (2018) 437–449.
[79] X. Guell, J.D. Schmahmann, J.D.E. Gabrieli, S.S. Ghosh, Functional Gradients of the Cerebellum: a Fundamental Movement-to-Thought Principle, (2018), https://doi.org/10.1101/254326 https://www.biorxiv.org/content/early/2018/01/25/254326.
[80] M.-M. Mesulam, Principles of Behavior Neurology, 2nd edition, Oxford University Press, New York, 2000.
[81] M. Manto, J.M. Bower, A.B. Conforto, et al., Consensus paper: roles of the cerebellum in motor control–the diversity of ideas on cerebellar involvement in movement, Cerebellum 11 (2012) 457–487.
[82] J.D. Schmahmann, Cognitive and behavioral manifestations of cerebellar strokes: their relation to motor control and functional topography in the cerebellum, in: L.R. Caplan, J. van Gijn (Eds.), Stoke Syndromes, third edition, Cambridge University Press, Cambridge UK, 2012pp. 32–51.
[83] J.D. Schmahmann, J. MacMore, M. Vangel, Cerebellar stroke without motor deficit: clinical evidence for motor and non-motor domains within the human cerebellum, Neuroscience 162 (2009) 852–861.
[84] P. Trouillas, T. Takayanagi, M. Hallett, R.D. Currier, S.H. Subramony, K. Wessel, et al., International cooperative ataxia rating scale for pharmacological assessment of the cerebellar syndrome. The ataxia neuropharmacology committee of the World Federation of Neurology, J. Neurol. Sci. 145 (1997) 205–211.
[85] J.D. Schmahmann, J. Doyon, A. Toga, A. Evans, M. Petrides, MRI Atlas of the Human Cerebellum, Academic Press, San Diego, 2000.
[86] C.J. Stoodley, J.P. MacMore, N. Makris, J.C. Sherman, J.D. Schmahmann, Location of lesion determines motor vs. Cognitive consequences in patients with cerebellar stroke, Neuroimage Clin. 12 (2016) 765–775.
[87] B. Schoch, A. Dimitrova, E.R. Gizewski, et al., Functional localization in the human cerebellum based on voxelwise statistical analysis: a study of 90 patients, Neuroimage 30 (2006) 36–51.
[88] M.C. Silveri, M.G. Leggio, M. Molinari, The cerebellum contributes to linguistic production: a case of agrammatic speech following a right cerebellar lesion, Neurology 44 (1994) 2047–2050.
[89] M. Molinari, M.G. Leggio, M.C. Silveri, Verbal fluency and agrammatism, in: J.D. Schmahmann (Ed.), The Cerebellum and Cognition. Academic Press, New York. Int. Rev. Neurobiol. 41, 1997, pp. 325–339.
[90] J.A. Fiez, S.E. Petersen, M.K. Cheney, M.E. Raichle, Impaired non-motor learning and error detection associated with cerebellar damage, Brain 115 (1992) 155–178.
[91] J.D. Schmahmann, J.C. Sherman, Cerebellar cognitive affective syndrome, Int. Rev. Neurobiol. 41 (1997) 433–440.
[92] J.D. Schmahmann, J.C. Sherman, The cerebellar cognitive affective syndrome, Brain 121 (1998) 561–579.
[93] J.D. Schmahmann, The role of the cerebellum in cognition and emotion: personal reflections since 1982 on the dysmetria of thought hypothesis, and its historical evolution from theory to therapy, Neuropsychol. Rev. 20 (2010) 236–260.
[94] C.J. Stoodley, J.D. Schmahmann, Evidence for topographic organization in the cerebellum of motor control versus cognitive and affective processing, Cortex 46 (2010) 831–844.
[95] C.J. Stoodley, E.M. Valera, J.D. Schmahmann, Functional topography of the cerebellum for motor and cognitive tasks: an fMRI study, Neuroimage 59 (2012) 1560–1570.
[96] J. Malm, B. Kristensen, T. Karlsson, B. Carlberg, M. Fagerlund, T. Olsson, Cognitive impairment in young adults with infratentorial infarcts, Neurology 51 (1998) 433–440.
[97] D. Riva, C. Giorgi, The cerebellum contributes to higher function during development: evidence from a series of children surgically treated for posterior fossa tumors, Brain 123 (2000) 1051–1061.
[98] L. Levisohn, A. Cronin-Golomb, J.D. Schmahmann, Neuropsychological consequences of cerebellar tumor resection in children: cerebellar cognitive affective syndrome in a pediatric population, Brain 123 (2000) 1041–1050.
[99] J.P. Neau, E. Arroyo-Anllo, V. Bonnaud, P. Ingrand, R. Gil, Neuropsychological disturbances in cerebellar infarcts, Acta Neurol. Scand. 102 (2000) 363–370.
[100] C. Exner, G. Weniger, E. Irle, Cerebellar lesions in the PICA but not SCA territory impair cognition, Neurology 63 (2004) 2132–2135.
[101] K.S. Paulus, I. Magnano, M. Conti, P. Galistu, M. D'Onofrio, W. Satta, et al., Pure post-stroke cerebellar cognitive affective syndrome: a case report, Neurol. Sci. 25 (2004) 220–224.
[102] N.J. Van Harskamp, P. Rudge, L. Cipolotti, Cognitive and social impairments in patients with superficial siderosis, Brain 128 (2005) 1082–1092.
[103] J.D. Schmahmann, J.B. Weilburg, J.C. Sherman, The neuropsychiatry of the cerebellum - insights from the clinic, Cerebellum 6 (2007) 254–267.
[104] P. Caroppo, L. Orsi, F. D'Agata, B. Baudino, A. Boghi, F. Avidano, M. Coriasco, G.B. Bradac, G. Castellano, R. Mutani, P. Mortara, Neuropsychological and functional study in a case of partial cerebellar agenesis, Neurocase 15 (2009) 373–383.
[105] P. Mariën, H. Baillieux, H.J. De Smet, S. Engelborghs, I. Wilssens, P. Paquier, P.P. De Deyn, Cognitive, linguistic and affective disturbances following a right superior cerebellar artery infarction: a case study, Cortex 45 (2009) 527–536.
[106] P. Mariën, H. Ackermann, M. Adamaszek, C.H. Barwood, A. Beaton, J. Desmond, E. De Witte, A.J. Fawcett, I. Hertrich, M. Küper, M. Leggio, C. Marvel, M. Molinari, B.E. Murdoch, R.I. Nicolson, J.D. Schmahmann, C.J. Stoodley, M. Thürling, D. Timmann, E. Wouters, W. Ziegler, Consensus paper: language and the cerebellum: an ongoing enigma, Cerebellum 13 (2014) 386–410.
[107] H. Baillieux, H.J. De Smet, A. Dobbeleir, P.F. Paquier, P.P. De Deyn, P. Mariën, Cognitive and affective disturbances following focal cerebellar damage in adults: a neuropsychological and SPECT study, Cortex 46 (2010) 869–879.
[108] K. Wingeier, S. Bigi, M. El-Koussy, T. Heinks-Maldonado, E. Boltshauser, M. Steinlin, Long-term sequelae after acquired pediatric hemorrhagic cerebellar lesions, Childs Nerv. Syst. 27 (2011) 923–931.
[109] A.M. Tedesco, F.R. Chiricozzi, S. Clausi, M. Lupo, M. Molinari, M.G. Leggio, The cerebellar cognitive profile, Brain 134 (2011) 3672–3686.
[110] F. Hoche, E. Frankenberg, J. Rambow, M. Theis, J.A. Harding, M. Qirshi, K. Seidel, E. Barbosa-Sicard, L. Porto, J.D. Schmahmann, M. Kieslich, Cognitive phenotype in ataxia-telangiectasia, Pediatr. Neurol. 51 (2014) 297–310.
[111] L.F. Koziol, D. Budding, N. Andreasen, S. D'Arrigo, S. Bulgheroni, H. Imamizu, M. Ito, M. Manto, C. Marvel, K. Parker, G. Pezzulo, N. Ramnani, D. Riva, J. Schmahmann, L. Vandervert, T. Yamazaki, Consensus paper: the cerebellum's role in movement and cognition, Cerebellum 13 (2014) 151–177.
[112] F. Van Overwalle, K. Baetens, P. Mariën, M. Vandekerckhove, Cerebellar areas dedicated to social cognition? A comparison of meta-analytic and connectivity results, Soc. Neurosci. 10 (2015) 337–344.
[113] M. Adamaszek, F. D'Agata, R. Ferrucci, C. Habas, S. Keulen, K.C. Kirkby, M. Leggio, P. Mariën, M. Molinari, E. Moulton, L. Orsi, F. Van Overwalle, C. Papadelis, A. Priori, B. Sacchetti, D.J. Schutter, C. Styliadis, J. Verhoeven, Consensus paper: cerebellum and emotion, Cerebellum 16 (2010) 552–576.
[114] C. Hoffmann, G. Schmidt, CNF and DNT, Rev. Physiol. Biochem. Pharmacol. 152 (2004) 49–63.
[115] M. Hoffmann, L.B. Cases, Etiology of frontal network syndromes in isolated subtentorial stroke, Behav. Neurol. 20 (2008) 101–105.
[116] L.A. Kalashnikova, Y.V. Zueva, O.V. Pugacheva, N.K. Korsakova, Cognitive impairments in cerebellar infarcts, Neurosci. Behav. Physiol. 35 (2005) 773–779.
[117] L.S. Hokkanen, V. Kauranen, R.O. Roine, O. Salonen, M. Kotila, Subtle cognitive deficits after cerebellar infarcts, Eur. J. Neurol. 13 (2006) 161–170.
[118] S. Richter, B. Aslan, M. Gerwig, H. Wilhelm, S. Kramer, O. Todica, et al., Patients with chronic focal cerebellar lesions show no cognitive abnormalities in a bedside test, Neurocase 13 (2007) 25–36.
[119] T.A. Schweizer, M.P. Alexander, B.A. Susan Gillingham, M. Cusimano, D.T. Stuss, Lateralized cerebellar contributions to word generation: a phonemic and semantic fluency study, Behav. Neurol. 23 (2010) 31–37.
[120] M.G. Leggio, M.C. Silveri, L. Petrosini, M. Molinari, Phonological grouping is specifically affected in cerebellar patients: a verbal fluency study, J. Neurol. Neurosurg. Psychiatry 69 (2000) 102–106.
[121] F. Manes, A.R. Villamil, S. Ameriso, M. Roca, T. Torralva, Real life" executive deficits in patients with focal vascular lesions affecting the cerebellum, J. Neurol. Sci. 283 (2009) 95–98.
[122] S.M. Ravizza, C.A. McCormick, J.E. Schlerf, T. Justus, R.B. Ivry, J.A. Fiez, Cerebellar damage produces selective deficits in verbal working memory, Brain 129 (2006) 306–320.
[123] B. Ziemus, O. Baumann, R. Luerding, R. Schlosser, G. Schuierer, U. Bogdahn, et al., Impaired working-memory after cerebellar infarcts paralleled by changes in BOLD signal of a cortico-cerebellar circuit, Neuropsychologia 45 (2007) 2016–2024.
[124] B. Gottwald, B. Wilde, Z. Mihajlovic, H.M. Mehdorn, Evidence for distinct cognitive deficits after focal cerebellar lesions, J. Neurol. Neurosurg. Psychiatry 75 (2004) 1524–1531.
[125] F. Hoche, X. Guell, M. Vangel, J.C. Sherman, J.D. Schmahmann, The cerebellar cognitive affective / Schmahmann syndrome scale, Brain 141 (2018) 248–270.
[126] C. Karatekin, J.A. Lazareff, R.F. Asarnow, Relevance of the cerebellar hemispheres for executive functions, Pediatr. Neurol. 22 (2000) 106–112.
[127] J. Grill, D. Viguier, V. Kieffer, et al., Critical risk factors for intellectual impairment in children with posterior fossa tumors: the role of cerebellar damage, J. Neurosurg. 101 (2 Suppl) (2004) 152–158.

[128] S.B. Turkel, L. Shu Chen, M.D. Nelson, D. Hyder, F.H. Gilles, L. Woodall, et al., Case series: acute mood symptoms associated with posterior fossa lesions in children, J. Neuropsychiatry Clin. Neurosci. 16 (2004) 443–445.
[129] A. Berger, M. Sadeh, G. Tzur, et al., Task switching after cerebellar damage, Neuropsychology 19 (2005) 362–370.
[130] C. Ronning, K. Sundet, B. Due-Tonnessen, et al., Persistent cognitive dysfunction secondary to cerebellar injury in patients treated for posterior fossa tumors in childhood, Pediatr. Neurosurg. 41 (2005) 15–21.
[131] E. Vaquero, C.M. Gómez, E.A. Quintero, J.J. González-Rosa, J. Márquez, Differential prefrontal-like deficit in children after cerebellar astrocytoma and medulloblastoma tumor, Behav. Brain Funct. 4 (2008) 18.
[132] R.B. Scott, C.J. Stoodley, P. Anslow, C. Paul, J.F. Stein, E.M. Sugden, C.D. Mitchell, Lateralized cognitive deficits in children following cerebellar lesions, Dev. Med. Child Neurol. 43 (2001) 685–691.
[133] V. Gross-Tsur, D. Ben-Bashat, R.S. Shalev, M. Levav, L.B. Sira, Evidence of a developmental cerebello-cerebral disorder, Neuropsychologia 44 (2006) 2569–2572.
[134] M. Kossorotoff, C. Gonin-Flambois, C. Gitiaux, S. Quijano, N. Boddaert, N. Bahi-Buisson, et al., A cognitive and affective pattern in posterior fossa strokes in children: a case series, Dev. Med. Child. Neurol. 52 (2010) 626–631.
[135] F. Assal, N. Valenza, T. Landis, J.P. Hornung, Clinicoanatomical correlates of a Fou rire prodromique in a pontine infarction, J. Neurol. Neurosurg. Psychiatry 69 (2000) 697–698.
[136] J. Parvizi, S.W. Anderson, C.O. Martin, H. Damasio, A.R. Damasio, Pathological laughter and crying: a link to the cerebellum, Brain 124 (2001) 1708–1719.
[137] J. Parvizi, J. Joseph, D.Z. Press, J.D. Schmahmann, Pathological laughter and crying in patients with multiple system atrophy-cerebellar type, Mov. Disord. 22 (2007) 798–803.
[138] J.H. Wisoff, F.J. Epstein, Pseudobulbar palsy after posterior fossa operation in children, Neurosurgery 15 (1984) 707–709.
[139] C.E. Catsman-Berrevoets, H.R. van Dongen, C.P. Zwetsloot, Transient loss of speech followed by dysarthria after removal of posterior fossa tumour, Dev. Med. Child Neurol. 34 (1992) 1102–1109.
[140] I.F. Pollack, P. Polinko, A.L. Albright, R. Towbin, C. Fitz, Mutism and pseudobulbar symptoms after resection of posterior fossa tumors in children: incidence and pathophysiology, Neurosurgery 37 (1995) 885–893.
[141] M. Sadeh, I. Cohen, Transient loss of speech after removal of posterior fossa tumors–one aspect of a larger neuropsychological entity: the cerebellar cognitive affective syndrome, Pediatr. Hematol. Oncol. 18 (2001) 423–426.
[142] H.L. Rekate, R.L. Grubb, D.M. Aram, J.F. Hahn, R.A. Ratcheson, Muteness of cerebellar origin, Arch. Neurol. 42 (1985) 697–698.
[143] A. Kingma, J.J.A. Mooij, J.D.M. Metemaekers, J.A. Leeuw, Transient mutism and speech disorders after posterior fossa surgery in children with brain tumors, Acta Neurochir. 131 (1994) 74–79.
[144] D.D. Dietze, Jr, J.P. Mickle, Cerebellar mutism after posterior fossa surgery, Pediatr. Neurosurg. 16 (1990) 25–31 1990–1991.
[145] H.R. Van Dongen, C.E. Catsman-Berrevoets, M. van Mourik, The syndrome of' cerebellar' mutism and subsequent dysarthria, Neurology 44 (1994) 2040–2046.
[146] E.M. Wells, K.S. Walsh, Z.P. Khademian, R.F. Keating, R.J. Packer, The cerebellar mutism syndrome and its relation to cerebellar cognitive function and the cerebellar cognitive affective disorder, Dev. Disabil. Res. Rev. 14 (2008) 221–228.
[147] T. Gudrunardottir, A.T. Morgan, A.L. Lux, Iceland Delphi Group, et al., Consensus paper on post-operative pediatric cerebellar mutism syndrome: the Iceland Delphi results, Childs Nerv. Syst. 32 (2006) 1195–1203.
[148] C. Limperopoulos, J.S. Soul, H. Haidar, et al., Impaired trophic interactions between the cerebellum and the cerebrum among preterm infants, Pediatrics 116 (2005) 844–850.
[149] C. Limperopoulos, H. Bassan, K. Gauvreau, et al., Does cerebellar injury in premature infants contribute to the high prevalence of long-term cognitive, learning, and behavioral disability in survivors? Pediatrics 120 (2007) 584–593.
[150] M. Brossard-Racine, A.J. du Plessis, C. Limperopoulos, Developmental cerebellar cognitive affective syndrome in ex-preterm survivors following cerebellar injury, Cerebellum 14 (April (2)) (2015) 151–164.
[151] C.L. Hickey, J.C. Sherman, P. Goldenberg, A. Kritzer, P. Caruso, J.D. Schmahmann, M.K. Colvin, Cerebellar cognitive affective syndrome: insights from Joubert syndrome, Cereb. Ataxias 21 (March (5)) (2018) 5, https://doi.org/10.1186/s40673-018-0085-y.
[152] M. Chheda, J. Sherman, J.D. Schmahmann, Neurologic, psychiatric and cognitive manifestations in cerebellar agenesis, Neurology 58 (Suppl. 3) (2002) 356.
[153] A. Poretti, E. Boltshauser, J.D. Schmahmann, Cerebellar agenesis, in: E. Boltshauser, J.D. Schmahmann (Eds.), Cerebellar Disorders in Children. Clinics in Developmental Medicine No. 191–192, Mac Keith Press, London, 2012pp. 117–121.
[154] D.H. Geschwind, Focusing attention on cognitive impairment in spinocerebellar ataxia, Arch. Neurol. 56 (1999) 20–22.
[155] L. Orsi, F. D'Agata, P. Caroppo, A. Franco, M.M. Caglio, F. Avidano, C. Manzone, P. Mortara, Neuropsychological picture of 33 spinocerebellar ataxia cases, J. Clin. Exp. Neuropsychol. 33 (March (3)) (2011) 315–325.
[156] S. Roeske, I. Filla, S. Heim, K. Amunts, C. Helmstaedter, U. Wüllner, M. Wagner, T. Klockgether, M. Minnerop, Progressive cognitive dysfunction in spinocerebellar ataxia type 3, Mov. Disord. 28 (September (16)) (2013) 1435–1438.
[157] E. Lindsay, E. Storey, Cognitive changes in the spinocerebellar ataxias due to expanded polyglutamine tracts: a survey of the literature, Brain Sci. 7 (July (7)) (2017), https://doi.org/10.3390/brainsci7070083 pii: E83.
[158] T. Botez-Marquard, M.I. Botez, Cognitive behavior in heredodegenerative ataxias, Eur. Neurol. 33 (5) (1993) 351–357.
[159] I. Dogan, E. Tinnemann, S. Romanzetti, S. Mirzazade, A.S. Costa, C.J. Werner, S. Heim, K. Fedosov, S. Schulz, D. Timmann, I.A. Giordano, T. Klockgether, J.B. Schulz, K. Reetz, Cognition in Friedreich's ataxia: a behavioral and multimodal imaging study, Ann. Clin. Transl. Neurol. 3 (June (8)) (2016) 572–587.
[160] J.B. Weilburg, D.M. Bear, G. Sachs, Three patients with concomitant panic attacks and seizure disorder: possible clues to the neurology of anxiety, Am. J. Psychiatry 144 (1987) 1053–1056.
[161] F.A. Gondim, B.J. Parks, S. Cruz-Flores, Fou rire prodromique" as the presentation of pontine ischaemia secondary to vertebrobasilar stenosis, J. Neurol. Neurosurg. Psychiatry 71 (2001) 802–804.
[162] H. Tei, Y. Sakamoto, Pontine infarction due to basilar artery stenosis presenting as pathological laughter, Neuroradiology 39 (1997) 190–191.
[163] A. Jawaid, M.A. Rauf, U. Usman, B.A. Khealani, Post-infarct cerebellar cognitive affective syndrome: a case report, J. Pak. Med. Assoc. 58 (2008) 415–417.
[164] P.S. Dimova, V.S. Bojinova, I.G. Milanov, Transient mutism and pathologic laughter in the course of cerebellitis, Pediatr. Neurol. 41 (2009) 49–52.
[165] A. Maryniak, M. Roszkowski, Cognitive and affective disturbances in children after surgical treatment of cerebellar tumors, Neurol. Neurochir. Pol. 39 (2005) 202–206.
[166] S. Richter, A. Dimitrova, M. Maschke, E. Gizewski, A. Beck, V. Aurich, et al., Degree of cerebellar ataxia correlates with three-dimensional mri-based cerebellar volume in pure cerebellar degeneration, Eur. Neurol. 54 (2005) 23–27.
[167] S.B. Turkel, V.L. Brumm, W.G. Mitchell, C.J. Tavare, Mood and behavioral dysfunction with opsoclonus-myoclonus ataxia, J. Neuropsychiatry Clin. Neurosci. 18 (2006) 239–241.
[168] M.P. Gorman, Update on diagnosis, treatment, and prognosis in opsoclonus-myoclonus-ataxia syndrome, Curr. Opin. Pediatr. 22 (2010) 745–750.
[169] L.M. Cher, F.H. Hochberg, J. Teruya, et al., Therapy for paraneoplastic neurologic syndromes in six patients with protein A column immunoadsorption, Cancer 75 (1995) 1678–1683.
[170] S. Ohara, N. Iijima, K. Hayashida, T. Oide, S. Katai, Autopsy case of opsoclonus-myoclonus-ataxia and cerebellar cognitive affective syndrome associated with small cell carcinoma of the lung, Mov. Disord. 22 (2007) 1320–1324.
[171] H. Baillieux, H.J. De Smet, G. Lesage, P. Paquier, P.P. De Deyn, P. Mariën, Neurobehavioral alterations in an adolescent following posterior fossa tumor resection, Cerebellum 5 (2006) 289–295.
[172] R.G. Heath, D.E. Franklin, D. Shraberg, Gross pathology of the cerebellum in patients diagnosed and treated as functional psychiatric disorders, J. Nerv. Ment. Dis. 167 (1979) 585–592.
[173] R.G. Heath, J.W. Harper, Ascending projections of the cerebellar fastigial nucleus to the hippocampus, amygdala, and other temporal lobe sites: evoked potential and histological studies in monkeys and cats, Exp. Neurol. 45 (1974) 268–287.
[174] B.S. Nashold Jr., D.G. Slaughter, Effects of stimulating or destroying the deep cerebellar regions in man, J. Neurosurg. 31 (1969) 172–186.
[175] J.D. Schmahmann, Disorders of the cerebellum: ataxia, dysmetria of thought, and the cerebellar cognitive affective syndrome, J. Neuropsychiatry Clin. Neurosci. 16 (2004) 367–378.
[176] R.Y. Lo, K.P. Figueroa, S.M. Pulst, S. Perlman, G. Wilmot, C. Gomez, J.D. Schmahmann, H. Paulson, V.G. Shakkottai, S. Ying, T. Zesiewicz, K. Bushara, M. Geschwind, G. Xia, Lee L.E. Yu JT, T. Ashizawa, S.H. Subramony, S.H. Kuo, Depression and clinical progression in spinocerebellar ataxias, Parkinsonism Relat. Disord. 22 (January) (2016) 87–92.
[177] E. Brunet, Y. Sarfati, M.C. Hardy-Bayle, J. Decety, A PET investigation of the attribution of intentions with a nonverbal task, Neuroimage 11 (2000) 157–166.
[178] C. Calarge, N.C. Andreasen, D.S. O'Leary, Visualizing how one brain understands another: a PET study of theory of mind, Am. J. Psychiatry 160 (2003) 1954–1964.
[179] R.T. Loeber, C.M. Cintron, D.A. Yurgelun-Todd, Morphometry of individual cerebellar lobules in schizophrenia, Am. J. Psychiatry 158 (2001) 952–954.
[180] K.L. Parker, Y.C. Kim, R.M. Kelley, et al., Delta-frequency stimulation of cerebellar projections can compensate for schizophrenia-related medial frontal dysfunction, Mol. Psychiatry 22 (May (5)) (2017) 647–655.
[181] T. Moberget, N.T. Doan, D. Alnæs, et al., Cerebellar volume and cerebellocerebral structural covariance in schizophrenia: a multisite mega-analysis of 983 patients and 1349 healthy controls, Mol. Psychiatry 16 (May) (2017).
[182] A. Demirtas-Tatlidede, C. Freitas, J. Cromer, L. Safar, D. Ongur, W.S. Stone, L.J. Seidman, J.D. Schmahmann, A. Pascual-Leone, Safety and proof of principle study of cerebellar vermal theta burst stimulation in refractory schizophrenia, Schizophr. Res. 124 (2010) 91–100.
[183] S.K. Tikka, S. Garg, V.K. Sinha, et al., Resting state dense array gamma oscillatory activity as a response marker for cerebellar-repetitive transcranial magnetic stimulation (rTMS) in schizophrenia, J. ECT 31 (2015) 258–262.
[184] S. Garg, V.K. Sinha, S. Garg, V.K. Sinha, S.K. Tikka, P. Mishra, N.S.K. Goyal, et al., The efficacy of cerebellar vermal deep high frequency (theta range) repetitive transcranial magnetic stimulation (rTMS) in schizophrenia: a randomized rater blind-sham controlled study, Psychiatry Res. 243 (2016) 413–420.
[185] M. Bauman, T.L. Kemper, Histoanatomic observations of the brain in early infantile autism, Neurology 35 (1985) 866–874.
[186] C.J. Stoodley, A.M. D'Mello, J. Ellegood, et al., Altered cerebellar connectivity in autism and cerebellar-mediated rescue of autism-related behaviors in mice, Nat. Neurosci. 20 (2017) 1744–1751.
[187] P.T. Tsai, C. Hull, Y. Chu, E. Greene-Colozzi, et al., Autistic-like behaviour and cerebellar dysfunction in Purkinje cell Tsc1 mutant mice, Nature 488 (7413) (2012) 647–651.
[188] J.S. Beer, K.N. Ochsner, Social cognition: a multi level analysis, Brain Res. 1079 (2006) 98–105.
[189] S.T. Fiske, S.E. Taylor, Social Cognition, McGraw-Hill, New York, 1991.
[190] S. Baron-Cohen, A.M. Leslie, U. Frith, Does the autistic child have a "theory of

mind"? Cognition 21 (1985) 37–46.
[191] D.M. Amodio, C.D. Frith, Meeting of minds: the medial frontal cortex and social cognition, Nat. Rev. Neurosci. 7 (2006) 268–277.
[192] G. Rizzolatti, L. Fogassi, V. Gallese, Mirrors of the mind, Sci. Am. 295 (2006) 54–61.
[193] A.J. Calder, A.D. Lawrence, A.W. Young, Neuropsychology of fear and loathing, Nat. Rev. Neurosci. 2 (2001) 352–363.
[194] C.M. Kipps, A.J. Duggins, E.A. McCusker, A.J. Calder, Disgust and happiness recognition correlate with anteroventral insula and amygdala volume respectively in preclinical Huntington's disease, J. Cogn. Neurosci. 19 (2007) 1206–1217.
[195] R. Sprengelmeyer, M. Rausch, U.T. Eysel, H. Przuntek, Neural structures associated with recognition of facial expressions of basic emotions, Proc. Biol. Sci. 265 (1998) 1927–1931.
[196] T. Johnstone, C.M. van Reekum, T.R. Oakes, R.J. Davidson, The voice of emotion: an FMRI study of neural responses to angry and happy vocal expressions, Soc. Cogn. Affect. Neurosci. 1 (2006) 242–249.
[197] P.L. Strick, R.P. Dum, J.A. Fiez, Cerebellum and nonmotor function, Annu. Rev. Neurosci. 32 (2009) 413–434.
[198] R.S. Snider, A. Maiti, S.R. Snider, Cerebellar pathways to ventral midbrain and nigra, Exp. Neurol. 53 (1976) 714–728.
[199] A. Zanchetti, A. Zoccolini, Autonomic hypothalamic outbursts elicited by cerebellar stimulation, J. Neurophysiol. 17 (1954) 475–483.
[200] S. Bobée, E. Mariette, H. Tremblay-Leveau, J. Caston, Effects of early midline cerebellar lesion on cognitive and emotional functions in the rat, Behav Brain Res. 112 (2000) 107–117.
[201] I.F. Pollack, Posterior fossa syndrome, Int. Rev. Neurobiol. 41 (1997) 411–432.
[202] A. Tavano, R. Grasso, C. Gagliardi, F. Triulzi, N. Bresolin, F. Fabbro, et al., Disorders of cognitive and affective development in cerebellar malformations, Brain 130 (2007) 2646–2660.
[203] J. Blair, L. Cipolotti, Impaired social response reversal. A case of 'acquired sociopathy', Brain 123 (2000) 1122–1141.
[204] N. Sokolovsky, A. Cook, H. Hunt, P. Giunti, L. Cipolotti, A preliminary characterisation of cognition and social cognition in spinocerebellar ataxia types 2, 1, and 7, Behav. Neurol. 23 (2010) 17–29.
[205] P. Garrard, N.H. Martin, P. Giunti, L. Cipolotti, Cognitive and social cognitive functioning in spinocerebellar ataxia : a preliminary characterization, J. Neurol. 255 (2008) 398–405.
[206] D. Bowers, L.X. Blonder, K.M. Heiman, The role of the right hemisphere in emotional communication, Brain 114 (1991) 1115–1127.
[207] M. Adamaszek, F. D'Agata, K.C. Kirkby, M.U. Trenner, B. Sehm, C.J. Steele, et al., Impairment of emotional facial expression and prosody discrimination due to ischemic cerebellar lesions, Cerebellum 13 (2014) 338–345.
[208] M. Tamietto, M. Adenzato, G. Geminiani, B. de Gelder, Fast recognition of social emotions takes the whole brain: interhemispheric cooperation in the absence of cerebral asymmetry, Neuropsychologia 45 (2007) 836–843.
[209] F. D'Agata, P. Caroppo, B. Baudino, M. Caglio, M. Croce, M. Bergui, et al., The recognition of facial emotions in spinocerebellar ataxia patients, Cerebellum 10 (2011) 600–610.
[210] F. Hoche, X. Guell, J.C. Sherman, M.G. Vangel, J.D. Schmahmann, Cerebellar contribution to social cognition, Cerebellum 15 (2016) 732–743.
[211] P. Mariën, A. Beaton, The enigmatic linguistic cerebellum: clinical relevance and unanswered questions on nonmotor speech and language deficits in cerebellar disorders, Cereb. Ataxias 1 (2014) 12.
[212] J.E. Desmond, J.D. Gabrieli, G.H. Glover, Dissociation of frontal and cerebellar activity in a cognitive task: evidence for a distinction between selection and search, Neuroimage 7 (4 Pt 1) (1998) 368–376.
[213] D. Caplan, J.E. Hanna, Sentence production by aphasic patients in a constrained task, Brain Lang. 63 (1998) 184–218.
[214] E. Wiig, W. Secord, Test of Language Competence-Expanded Edition, 1st ed., Pearson, San Antonio, 1989.
[215] X. Guell, F. Hoche, J.D. Schmahmann, Metalinguistic deficits in patients with cerebellar dysfunction: empirical support for the dysmetria of thought theory, Cerebellum 14 (2015) 50–58.
[216] M.A. Halko, F. Farzan, M.C. Eldaief, J.D. Schmahmann, A. Pascual-Leone, Intermittent theta-burst stimulation of the lateral cerebellum increases functional connectivity of the default network, J. Neurosci. 34 (2014) 12049–12056.
[217] F. Farzan, A. Pascual-Leone, J.D. Schmahmann, M. Halko, Enhancing the temporal complexity of distributed brain networks with patterned cerebellar stimulation, Sci. Rep. 6 (2016) 23599.
[218] H.I.L. Jacobs, D.A. Hopkins, H.C. Mayrhofer, E. Bruner, F.W. van Leeuwen, W. Raaijmakers, J.D. Schmahmann, The cerebellum in Alzheimer's disease: evaluating its role in cognitive decline, Brain 141 (2018) 37–47.
[219] R.H. Tan, E. Devenney, C. Dobson-Stone, J.B. Kwok, J.R. Hodges, M.C. Kiernan, et al., Cerebellar integrity in the amyotrophic lateral sclerosis-frontotemporal dementia continuum, PLoS One 9 (2014) e105632.
[220] J.L. Whitwell, S.D. Weigand, B.F. Boeve, M.L. Senjem, J.L. Gunter, M. DeJesus-Hernandez, et al., Neuroimaging signatures of frontotemporal dementia genetics: C9ORF72, tau, progranulin and sporadics, Brain 135 (2012) 794–806.
[221] I.R. Mackenzie, P. Frick, M. Neumann, The neuropathology associated with repeat expansions in the C9ORF72 gene, Acta Neuropathol. 127 (2014) 347–357.
[222] C.C. Guo, R. Tan, J.R. Hodges, X. Hu, S. Sami, M. Hornberger, Network-selective vulnerability of the human cerebellum to Alzheimer's disease and frontotemporal dementia, Brain 139 (2016) 1527–1538.
[223] K. Parmar, C. Stadelmann, M.A. Rocca, et al., The role of the cerebellum in multiple sclerosis – 150 years after charcot, Neurosci. Biobehav. Rev. (February) (2018), https://doi.org/10.1016/j.neubiorev.2018.02.012.
[224] S.M. Tobyne, W.B. Ochoa, J.D. Bireley, V.M. Smith, J.J. Geurts, J.D. Schmahmann, E.C. Klawiter, Cognitive impairment and the regional distribution of cerebellar lesions in multiple sclerosis, Mult. Scler. (September) (2017) 1352458517730132, , https://doi.org/10.1177/1352458517730132 [Epub ahead of print].
[225] J.D. Schmahmann, Therapeutic and research implications, in: J.D. Schmahmann (Ed.), The Cerebellum and Cognition, 41 Academic Press, San Diego, 1997, pp. 637–647 Int. Rev. Neurobiol..
[226] J.D. Schmahmann, Cerebellum in Alzheimer's disease and frontotemporal dementia: not a silent bystander, Brain 139 (2016) 1314–1318.
[227] A.M. D'Mello, C.J. Stoodley, Cerebro-cerebellar circuits in autism spectrum disorder, Front. Neurosci. 9 (2015) 408.
[228] N. Makris, S.M. Hodge, C. Haselgrove, et al., Human cerebellum: surface assisted cortical parcellation and volumetry with magnetic resonance imaging, J. Cogn. Neurosci. 15 (2003) 584–599.