Authoring note workflow

NEW FLUX NOTES NOTE AUTHORING WORKFLOW CONCEPT

9.APRIL.2018

STEPS IN CLINICAL NOTE CREATION

- + NEW NOTE
- CHOOSE CUSTOM TEMPLATE
- CREATE NEW TEMPLATE
- CHOOSE EXISTING TEMPLATE (PROGRESS NOTE)
- AUTOGENERATE (MOST OF) THE CLINICAL NOTE
- MAKE MODIFICATIONS TO THE TEMPLATE
- COMPLETE THE SECTIONS THAT NEED TO BE FILLED
- UPDATE EXISTING TEMPLATE
- GENERATE NEW TEMPLATE
- CLEAN NOTE
- SIGN NOTE
- AUTO FULFILL REQUIREMENTS

KEY CHARACTERISTICS OF HIGHLIGHTED STEP FOR NOTE AUTHORING INTERACTION

Generated based on specialty, type of note template choesn, and patient condition.

Autogenerated starting points:
- Reason for visit
- HPI
- Medications
- Allergies

Provider to fill:
- Review of systems
- Physical exam
- Assessment and plan

All 5 methods for filling out a note to be used: typing, hashtags, active POS, "tracker helper" POS, shorthand phrases

Depending on section in note (ROS, physical exam, etc), the best method for filling it out will differ:

Review of systems:
- Typing (with NLP + autosuggest)
- Active POS
- "Tracker helper" POS

Physical exam:
- Typing (with NLP + autosuggest)
- Active POS
- "Tracker helper" POS

Assessment & plan:
- Typing (with NLP + autosuggest)
- Hastags (e.g. eRx)
- Active POS
- "Tracker helper" POS

Track # of unfilled data elements.

Track # of tentatively captured data.

Primarily use "tracker helper" POS to finish cleaning note, making final corrections.

Remove optional unfilled elements and sign note.

Complete and report billing

Report eCQMs

Generate and send patient data receipt to patient + patient health record.

EXAMPLES

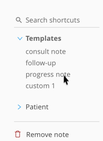



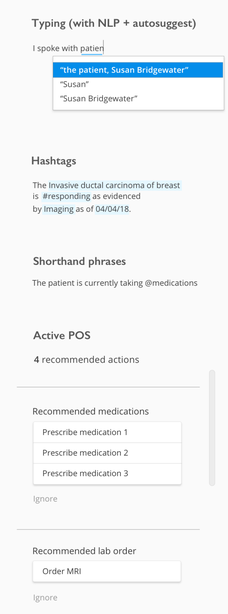

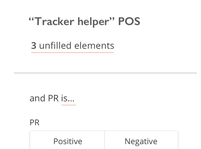

NLP based text complete

Dr. Jraker299 referred ms. Debra24 Hernandez98Aj due to pain in left breast. Dr. Jraker299 is ms. Debra24 Hernandez98Aj's primary care physician for 12 years.

Summary

Ms. Debra24 Hernandez98Aj is a 51-year-old menopausal non hispanic or latino woman with invasive ductal carcinoma of the breast, diagnosed on 13 January 2012. Her most recent status, recorded on 15 May 2017, is of worsening, disease progression based on pathology, imaging, and symptoms.

She underwent a lumpectomy. She underwent a sentinel lymph node biopsy on 20 September 2012 which revealed infiltrating poorly differentiated ductal carcinoma, stage IV, estrogen receptor 0, etc.

diagnostic mammogram on 4 October 2013 revealed a 2 cm mass in the right breast at 7 o'clock and an

follow-up regarding Ductal carcinoma of...
10 April 2018

Dr. Free2 Will
Dana Farber Cancer Institute

Close

LABORATORY AND DIAGNOSTIC DATA:

WBC: 8 (109/L); hemoglobin: 10.8%; platelet count: 208,000; neutrophil: 4 (109/L).

ASSESSMENT:

Stage IA T1c N0 Mx right breast poorly differentiated infiltrating ductal carcinoma, BRCA1/2 negative, triple-negative, estrogen 0%, progesterone receptor 1-4%, HER 2 negative 0%, Ki-67 85-95%. She underwent neoadjuvant ddAC-T from 10/20/17 to 2/23/18 (received 11/12 doses of Taxol due to neuropathy); s/p right lumpectomy with no residual disease, 0/2 SLNs; pCR, stage pT0N0.

PLAN:

enter content

Remove unfilled elements and sign

Dr. Jraker299 referred ms. Debra24 Hernandez98Aj due to pain in left breast. Dr. Jraker299 is ms. Debra24 Hernandez98Aj's primary care physician for 12 years.

Summary

Ms. Debra24 Hernandez98Aj is a 51-year-old menopausal non hispanic or latino woman with invasive ductal carcinoma of the breast, diagnosed on 13 January 2012. Her most recent status, recorded on 15 May 2017, is of worsening, disease progression based on pathology, imaging, and symptoms.

She underwent a lumpectomy. She underwent a sentinel lymph node biopsy on 20 September 2012 which revealed infiltrating poorly differentiated ductal carcinoma, stage IV, estrogen receptor 0, etc.

diagnostic mammogram on 4 October 2013 revealed a 2 cm mass in the right breast at 7 o'clock and an

follow-up regarding Ductal carcinoma of...
10 April 2018

Dr. Free2 Will
Dana Farber Cancer Institute

Close

LABORATORY AND DIAGNOSTIC DATA:

WBC: 8 (109/L); hemoglobin: 10.8%; platelet count: 208,000; neutrophil: 4 (109/L).

ASSESSMENT:

Stage IA T1c N0 Mx right breast poorly differentiated infiltrating ductal carcinoma, BRCA1/2 negative, triple-negative, estrogen 0%, progesterone receptor 1-4%, HER 2 negative 0%, Ki-67 85-95%. She underwent neoadjuvant ddAC-T from 10/20/17 to 2/23/18 (received 11/12 doses of Taxol due to neuropathy); s/p right lumpectomy with no residual disease, 0/2 SLNs; pCR, stage pT0N0.
She has minimal residual neurop

"peripheral motor neuropathy" | *Toxicity*
"neuropathy" | *Toxicity*

PLAN:

enter content

Remove unfilled elements and sign

Search shortcuts
TEMPLATES
SNIPPETS
PATIENT

Invasive ductal car...

Dr. Jraker299 referred ms. Debra24 Hernandez98Aj due to pain in left breast. Dr. Jraker299 is ms. Debra24 Hernandez98Aj's primary care physician for 12 years.

Summary

Ms. Debra24 Hernandez98Aj is a 51-year-old menopausal non hispanic or latino woman with invasive ductal carcinoma of the breast, diagnosed on 13 January 2012. Her most recent status, recorded on 15 May 2017, is of worsening, disease progression based on pathology, imaging, and symptoms.

She underwent a lumpectomy. She underwent a sentinel lymph node biopsy on 20 September 2012 which revealed infiltrating poorly differentiated ductal carcinoma, stage IV, estrogen receptor 0, etc.

diagnostic mammogram on 4 October 2013 revealed a 2 cm mass in the right breast at 7 o'clock and an

follow-up regarding Ductal carcinoma of...
10 April 2018

Dr. Free2 Will
Dana Farber Cancer Institute

Close

LABORATORY AND DIAGNOSTIC DATA:

WBC: 8 (109/L); hemoglobin: 10.8%; platelet count: 208,000; neutrophil: 4 (109/L).

ASSESSMENT:

Stage IA T1c N0 Mx right breast poorly differentiated infiltrating ductal carcinoma, BRCA1/2 negative, triple-negative, estrogen 0%, progesterone receptor 1-4%, HER 2 negative 0%, Ki-67 85-95%. She underwent neoadjuvant ddAC-T from 10/20/17 to 2/23/18 (received 11/12 doses of Taxol due to neuropathy); s/p right lumpectomy with no residual disease, 0/2 SLNs; pCR, stage pT0N0.

2 She has minimal residual peripheral motor neuropathy,

"minimal" | *infer Grade 1*

PLAN:

enter content

Remove unfilled elements and sign

Search shortcuts

- TEMPLATES
- SNIPPETS
- PATIENT

- Invasive ductal car...
  - toxicity
    - *grade*
    - grade 1
    - grade 2
    - grade 3
    - *attribution*
    - treatment
    - disease
    - error
    - unrelated
    - unknown

Dr. Jraker299 referred ms. Debra24 Hernandez98Aj due to pain in left breast. Dr. Jraker299 is ms. Debra24 Hernandez98Aj's primary care physician for 12 years.

Summary

Ms. Debra24 Hernandez98Aj is a 51-year-old menopausal non hispanic or latino woman with invasive ductal carcinoma of the breast, diagnosed on 13 January 2012. Her most recent status, recorded on 15 May 2017, is of worsening, disease progression based on pathology, imaging, and symptoms.

She underwent a lumpectomy. She underwent a sentinel lymph node biopsy on 20 September 2012 which revealed infiltrating poorly differentiated ductal carcinoma, stage IV, estrogen receptor 0, etc.

diagnostic mammogram on 4 October 2013 revealed a 2 cm mass in the right breast at 7 o'clock and an

follow-up regarding Ductal carcinoma of...
10 April 2018

Dr. Free2 Will
Dana Farber Cancer Institute

Close

LABORATORY AND DIAGNOSTIC DATA:

WBC: 8 (109/L); hemoglobin: 10.8%; platelet count: 208,000; neutrophil: 4 (109/L).

ASSESSMENT:

Stage IA T1c N0 Mx right breast poorly differentiated infiltrating ductal carcinoma, BRCA1/2 negative, triple-negative, estrogen 0%, progesterone receptor 1-4%, HER 2 negative 0%, Ki-67 85-95%. She underwent neoadjuvant ddAC-T from 10/20/17 to 2/23/18 (received 11/12 doses of Taxol due to neuropathy); s/p right lumpectomy with no residual disease, 0/2 SLNs; pCR, stage pT0N0.

She has minimal residual peripheral motor neuropathy affecting her fingers bilaterally, due to her medication.

"medication" | *infer treatment*

PLAN:

enter content

Remove unfilled elements and sign

Search shortcuts

- TEMPLATES
- SNIPPETS
- PATIENT

- Invasive ductal car...
  - toxicity
    - *attribution*
    - treatment
    - disease
    - error
    - unrelated
    - unknown

Dr. Jraker299 referred ms. Debra24 Hernandez98Aj due to pain in left breast. Dr. Jraker299 is ms. Debra24 Hernandez98Aj's primary care physician for 12 years.

Summary

Ms. Debra24 Hernandez98Aj is a 51-year-old menopausal non hispanic or latino woman with invasive ductal carcinoma of the breast, diagnosed on 13 January 2012. Her most recent status, recorded on 15 May 2017, is of worsening, disease progression based on pathology, imaging, and symptoms.

She underwent a lumpectomy. She underwent a sentinel lymph node biopsy on 20 September 2012 which revealed infiltrating poorly differentiated ductal carcinoma, stage IV, estrogen receptor 0, etc.

diagnostic mammogram on 4 October 2013 revealed a 2 cm mass in the right breast at 7 o'clock and an

follow-up regarding Ductal carcinoma of...
10 April 2018

Dr. Free2 Will
Dana Farber Cancer Institute

Close

LABORATORY AND DIAGNOSTIC DATA:

WBC: 8 (109/L); hemoglobin: 10.8%; platelet count: 208,000; neutrophil: 4 (109/L).

ASSESSMENT:

Stage IA T1c N0 Mx right breast poorly differentiated infiltrating ductal carcinoma, BRCA1/2 negative, triple-negative, estrogen 0%, progesterone receptor 1-4%, HER 2 negative 0%, Ki-67 85-95%. She underwent neoadjuvant ddAC-T from 10/20/17 to 2/23/18 (received 11/12 doses of Taxol due to neuropathy); s/p right lumpectomy with no residual disease, 0/2 SLNs; pCR, stage pT0N0.
She has minimal residual peripheral motor neuropathy affecting her fingers bilaterally, due to her medication.

PLAN:

enter content

Remove unfilled elements and sign

Assistive point of sale

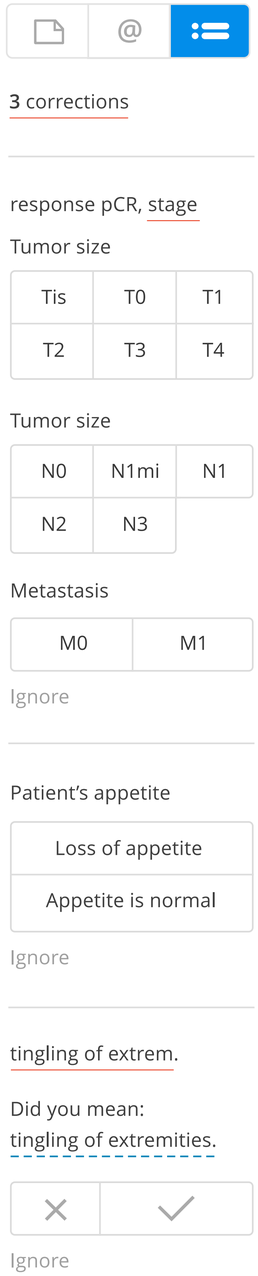

Assistive point of sale toggle. Always on in the background, augments provider to complete note.

# of corrections identified or needed.

Perhaps the system has falsely identified a correction. In these cases, the provider can "ignore" them.

Types of corrections:

1. Partially completed data capture due to incomplete attributes.

   Stage requires tumor size, node size, and metastasis.

2. Area of note requires more data to be complete.

   Provider forgot to denote patient's appetite, for Review of Systems.

3. Not a complete structured data element due to misspelling. Verifying correct spelling with provider.

Dr. Jraker299 referred ms. Debra24 Hernandez98Aj due to pain in left breast. Dr. Jraker299 is ms. Debra24 Hernandez98Aj's primary care physician for 12 years.

Summary

Ms. Debra24 Hernandez98Aj is a 51-year-old menopausal non hispanic or latino woman with invasive ductal carcinoma of the breast, diagnosed on 13 January 2012. Her most recent status, recorded on 15 May 2017, is of worsening, disease progression based on pathology, imaging, and symptoms.

She underwent a lumpectomy. She underwent a sentinel lymph node biopsy on 20 September 2012 which revealed infiltrating poorly differentiated ductal carcinoma, stage IV, estrogen receptor 0, etc.

diagnostic mammogram on 4 October 2013 revealed a 2 cm mass in the right breast at 7 o'clock and an

follow-up regarding Ductal carcinoma of...
10 April 2018

Dr. Free2 Will
Dana Farber Cancer Institute

Close

1 **Recent procedures:**
She underwent right lumpectomy with Dr. Ford on March 12, 2018. Pathology report on March 16, 2018 showed no residual disease, 0/2 SLNs, pathological complete response pCR, stage

2 **Review of systems:**
Patient denies: significant headache, blurry vision, double vision, fever, cough, shortness of breath, abdominal pain, nausea, vomiting
Patient reports: Numbness and tingling of extrem.

Allergies:
dairy

Medications:
lisinopril 20mg tablet, Take 1 tablet by mouth daily
ibuprofen 600mg tablet, Take 1 tablet by mouth three times daily as needed with food
hydrocortisone 2.5% ointment, twice daily as needed

Physical exam:
GENERAL: Very pleasant woman, appears stated age, dressed in hospital scrub

2 captured

Remove unfilled elements and sign

3 corrections

response pCR, stage

Tumor size

Tis	T0	T1
T2	T3	T4

Node size

N0	N1mi	N1
N2	N3	

Metastasis

M0	M1

Ignore

Patient's appetite

Loss of appetite
Appetite is normal

Ignore

tingling of extrem.

Dr. Jraker299 referred ms. Debra24 Hernandez98Aj due to pain in left breast. Dr. Jraker299 is ms. Debra24 Hernandez98Aj's primary care physician for 12 years.

Summary

Ms. Debra24 Hernandez98Aj is a 51-year-old menopausal non hispanic or latino woman with invasive ductal carcinoma of the breast, diagnosed on 13 January 2012. Her most recent status, recorded on 15 May 2017, is of worsening, disease progression based on pathology, imaging, and symptoms.

She underwent a lumpectomy. She underwent a sentinel lymph node biopsy on 20 September 2012 which revealed infiltrating poorly differentiated ductal carcinoma, stage IV, estrogen receptor 0, etc.

diagnostic mammogram on 4 October 2013 revealed a 2 cm mass in the right breast at 7 o'clock and an

follow-up regarding Ductal carcinoma of...
10 April 2018

Dr. Free2 Will
Dana Farber Cancer Institute

Close

Recent procedures:
She underwent right lumpectomy with Dr. Ford on March 12, 2018. Pathology report on March 16, 2018 showed no residual disease, 0/2 SLNs, pathological complete response pCR, stage pT0N0.

2 **Review of systems:**
Patient denies: significant headache, blurry vision, double vision, fever, cough, shortness of breath, abdominal pain, nausea, vomiting
Patient reports: Numbness and tingling of extrem

Allergies:
dairy

Medications:
lisinopril 20mg tablet, Take 1 tablet by mouth daily
ibuprofen 600mg tablet, Take 1 tablet by mouth three times daily as needed with food
hydrocortisone 2.5% ointment, twice daily as needed

Physical exam:
GENERAL: Very pleasant woman, appears stated age, dressed in hospital scrub

11 captured

Remove unfilled elements and sign

2 corrections

Patient's appetite

Loss of appetite

Appetite is normal

Ignore

tingling of extrem.

Did you mean:
tingling of extremities.

Ignore

Dr. Jraker299 referred ms. Debra24 Hernandez98Aj due to pain in left breast. Dr. Jraker299 is ms. Debra24 Hernandez98Aj's primary care physician for 12 years.

Summary

Ms. Debra24 Hernandez98Aj is a 51-year-old menopausal non hispanic or latino woman with invasive ductal carcinoma of the breast, diagnosed on 13 January 2012. Her most recent status, recorded on 15 May 2017, is of worsening, disease progression based on pathology, imaging, and symptoms.

She underwent a lumpectomy. She underwent a sentinel lymph node biopsy on 20 September 2012 which revealed infiltrating poorly differentiated ductal carcinoma, stage IV, estrogen receptor 0, etc.

diagnostic mammogram on 4 October 2013 revealed a 2 cm mass in the right breast at 7 o'clock and an

follow-up regarding Ductal carcinoma of...
10 April 2018

Dr. Free2 Will
Dana Farber Cancer Institute

Close

0 corrections needed

Recent procedures:
She underwent right lumpectomy with Dr. Ford on March 12, 2018. Pathology report on March 16, 2018 showed no residual disease, 0/2 SLNs, pathological complete response pCR, stage pT0N0.

Review of systems:
Patient denies: significant headache, blurry vision, double vision, fever, cough, shortness of breath, abdominal pain, nausea, vomiting, and loss of appetite
Patient reports: Numbness and tingling of extremeties.

Allergies:
dairy

Medications:
lisinopril 20mg tablet, Take 1 tablet by mouth daily
ibuprofen 600mg tablet, Take 1 tablet by mouth three times daily as needed with food
hydrocortisone 2.5% ointment, twice daily as needed

Physical exam:
GENERAL: Very pleasant woman, appears stated age, dressed in hospital scrub

13 captured

Sign note

More active use of assistive point of sale

Flux Notes
Dr. Bran24 Michel09A

Debra24 Hernandez98Aj

Date of birth	Admin. sex	Location	Workflow	Condition
5 Apr 1966 (51)	Female	Boston, MA	Pre-encounter	Ductal carcinoma of the breast

View

Debra24 search...

Summary

Timeline

Medication

Allergies

Labs

Social

Disease status

Dr. Jraker299 referred ms. Debra24 Hernandez98Aj due to pain in left breast. Dr. Jraker299 is ms. Debra24 Hernandez98Aj's primary care physician for 12 years.

Summary

Ms. Debra24 Hernandez98Aj is a 51-year-old menopausal non hispanic or latino woman with invasive ductal carcinoma of the breast, diagnosed on 13 January 2012. Her most recent status, recorded on 15 May 2017, is of worsening, disease progression based on pathology, imaging, and symptoms.

She underwent a lumpectomy. She underwent a sentinel lymph node biopsy on 20 September 2012 which revealed infiltrating poorly differentiated ductal carcinoma, stage IV, estrogen receptor 0, etc.

diagnostic mammogram on 4 October 2013 revealed a 2 cm mass in the right breast at 7 o'clock and an

follow-up regarding Ductal carcinoma of...
10 April 2018

Dr. Free2 Will
Dana Farber Cancer Institute

Close

Recent procedures:
She underwent right lumpectomy with Dr. Ford on March 12, 2018. Pathology report on March 16, 2018 showed no residual disease, 0/2 SLNs, pathological complete response pCR, stage pT0N0.

12 **Review of systems:**

Allergies:
dairy

Medications:
lisinopril 20mg tablet, Take 1 tablet by mouth daily
ibuprofen 600mg tablet, Take 1 tablet by mouth three times daily as needed with food
hydrocortisone 2.5% ointment, twice daily as needed

Physical exam:
GENERAL: Very pleasant woman, appears stated age, dressed in hospital scrub uniform, well nourished and in no acute distress.
VITAL SIGNS: Blood pressure 142/70, pulse 90 per minute, respirations 18 per minute, oxygen saturation 96% and temperature 97.4.

11 captured

Remove unfilled elements and sign

Review of Systems
12 corrections

Select problems present

- Headache
- Blurry vision
- Double vision
- Fever
- Cough
- Shortness of breath
- Abdominal pain
- Nausea
- Vomiting
- Loss of appetite
- Etc...

Finished problem selection

Dr. Jraker299 referred ms. Debra24 Hernandez98Aj due to pain in left breast. Dr. Jraker299 is ms. Debra24 Hernandez98Aj's primary care physician for 12 years.

Summary

Ms. Debra24 Hernandez98Aj is a 51-year-old menopausal non hispanic or latino woman with invasive ductal carcinoma of the breast, diagnosed on 13 January 2012. Her most recent status, recorded on 15 May 2017, is of worsening, disease progression based on pathology, imaging, and symptoms.

She underwent a lumpectomy. She underwent a sentinel lymph node biopsy on 20 September 2012 which revealed infiltrating poorly differentiated ductal carcinoma, stage IV, estrogen receptor 0, etc.

diagnostic mammogram on 4 October 2013 revealed a 2 cm mass in the right breast at 7 o'clock and an

follow-up regarding Ductal carcinoma of...
10 April 2018

Dr. Free2 Will
Dana Farber Cancer Institute

Close

Recent procedures:
She underwent right lumpectomy with Dr. Ford on March 12, 2018. Pathology report on March 16, 2018 showed no residual disease, 0/2 SLNs, pathological complete response pCR, stage pT0N0.

Review of systems:
Patient denies: headache, blurry vision, fever, cough, shortness of breath, nausea, vomiting, loss of appetite.
Patient reports: double vision and abdominal pain.

Allergies:
dairy

Medications:
lisinopril 20mg tablet, Take 1 tablet by mouth daily
ibuprofen 600mg tablet, Take 1 tablet by mouth three times daily as needed with food
hydrocortisone 2.5% ointment, twice daily as needed

Physical exam:
GENERAL: Very pleasant woman, appears stated age, dressed in hospital scrub

10 captured

Remove unfilled elements and sign

Review of Systems
0 corrections needed

Select problems present

- Headache
- Blurry vision
- **Double vision**
- Fever
- Cough
- Shortness of breath
- **Abdominal pain**
- Nausea
- Vomiting
- Loss of appetite
- Etc...

Finished problem selection