LLM Clinical Notes Project Update

April 9, 2026

To: Dr. Belfin

From: Stephen Chen, Undergraduate Research Assistant

GitHub: stephenchen06/clinical-notes-pipeline

Summary

Since the April 4 report, I upgraded the inference backend to the Mistral API (`ministral-14b-latest`) and reached **97.6% average accuracy** on the synthetic test set. However, this raises a limitation I want to flag directly: the ground truth the pipeline is evaluated against was itself generated by AI, not validated by a clinician. Before investing further in prompt tuning, I need your guidance on how to establish a reliable ground truth.

Accuracy Progression

Iteration	Model	Change	Avg Accuracy
llama3.2:3b (baseline)	3B	Initial model	~23.5%*
mistral-nemo:12b	12B	Model upgrade	72.0%
Round 1 fixes	12B	Post-processing defaults + prompt disambiguation	79.2%
Round 2 fixes	12B	Epilepsy syndrome default + myoclonus instruction	82.5%
ministral-14b-latest (API)	**14B**	**Model upgrade via Mistral la Plateforme**	**97.6%**

*Single-select fields only; checkbox 0s excluded from baseline to avoid inflation.

The jump from 82.5% → 97.6% came from upgrading the model alone, with no prompt changes. This suggests the remaining errors at 12B were largely capacity limitations, not prompt design failures.

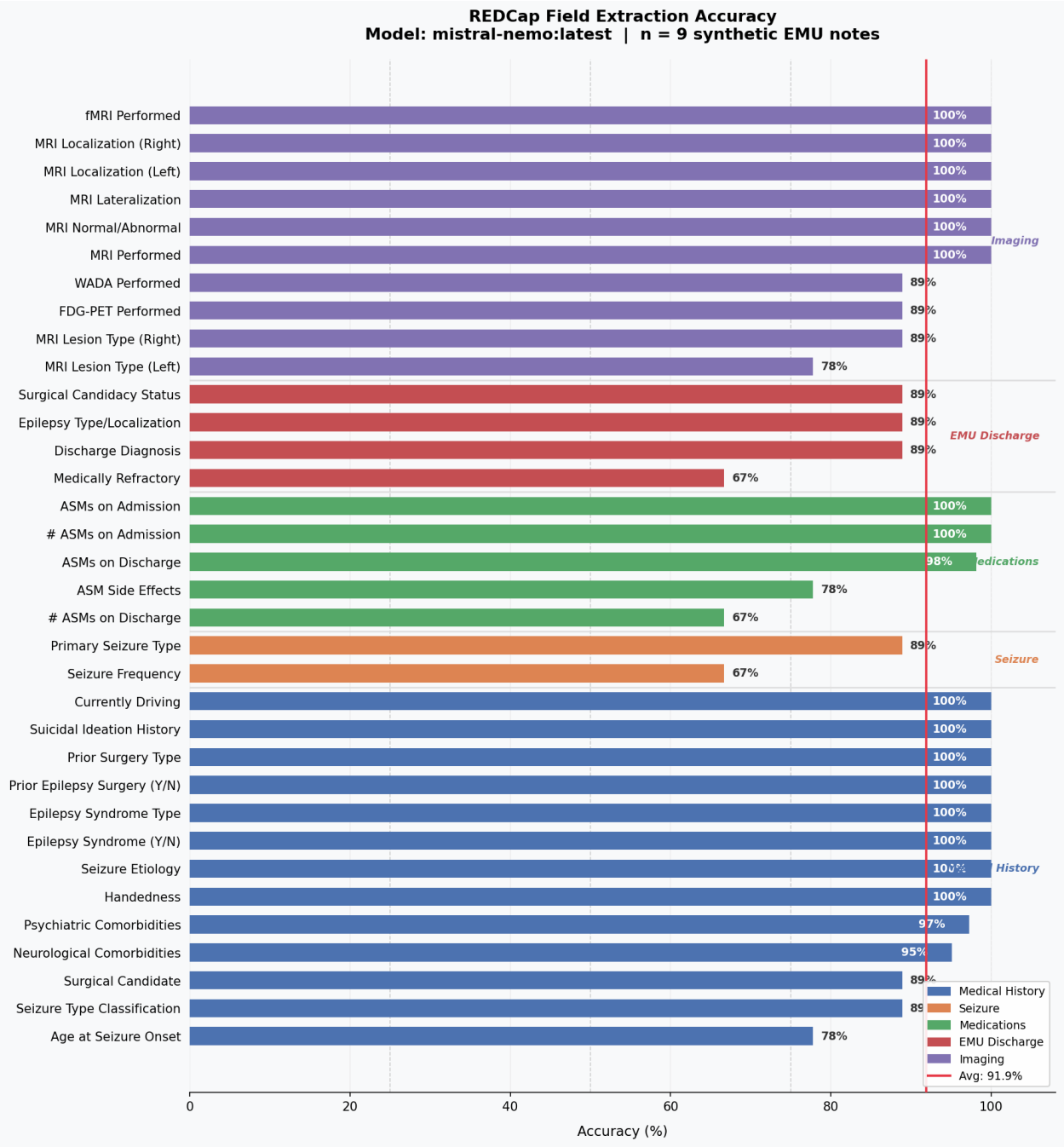

Figure 1: Field-Level Extraction Accuracy

Field-Level Accuracy

ministral-14b-latest (API), n=9 notes (8 synthetic + 1 real de-identified). Average: 97.6%.

Remaining weak fields (all at 75%): - `sz_age` — model returns current age rather than onset age when onset is stated indirectly - `emu_sz_type1_freq` — imprecise frequency language (e.g., "occasional") maps inconsistently to coded bins - `emu_asmdc_number` — conflates admission and discharge medication lists - `emu_epilepsy_intract` — ambiguous boundary between "Unclear" and "Yes" - `mri_lesion_left` — sensitive to phrasing variation in radiology reports

---

Core Limitation: The Ground Truth Problem

The 97.6% figure measures how consistently the pipeline matches an AI-generated answer key — not whether those answers are clinically correct.

How the ground truth was created:

- The 8 synthetic EMU discharge notes were generated by ChatGPT to represent distinct clinical scenarios (MTLE-HS, FND/PNEE, drug-resistant frontal epilepsy, JME, post-stroke epilepsy, mixed FND + focal, LGI1 autoimmune encephalitis, Dravet syndrome).
- The expected REDCap values for each note were also AI-generated — one model wrote the note, another coded it.
- The one real de-identified note (`real-doc-001`) was coded by Claude Opus based on the note text.

Why this matters:

At 97.6%, the pipeline and the ground truth agree almost all the time. But that agreement could reflect two models making the same mistake rather than the pipeline being correct. There is currently no human-verified answer key, so I cannot distinguish between:

1. A pipeline error that the ground truth happens to catch
2. A ground truth error that the pipeline gets right
3. Both agreeing on the same wrong answer

Continuing to tune prompts against this ground truth may improve the score without improving clinical accuracy — or, worse, overfit the pipeline to an AI's coding style rather than the research team's.

What I Need to Move Forward

I see three paths, in order of preference:

Option A — Clinician review of the ground truth CSV (lowest lift). I can share the `redcap_expected.csv` file with the full set of expected values for all 9 notes. If you or Dr. Waters could spot-check even 2–3 notes — confirming or correcting field values — that would give me a validated anchor for evaluation. I can produce a readable, per-note summary of just the fields in question to make this as fast as possible.

Option B — Real de-identified notes with research team coding. If Dr. Waters has notes from prior EMU patients that have already been coded into REDCap (or could be de-identified and coded), running

the pipeline against those would give a gold-standard evaluation set. This is the most clinically meaningful benchmark.

Option C — Walk through one note together. A 15-minute call going through a single synthetic note and its expected REDCap values would let me calibrate whether the evaluation framework matches how the team actually codes, before investing more time in tuning.

Any of these would unblock the next phase.

Local Model Plan

The API model (`ministral-14b-latest`) establishes a ceiling. The target local deployment is `ministral-3:14b` via Ollama — the same weights, Q4_K_M quantized, 9.1 GB on disk. Expected accuracy locally: ~95–96% (quantization loss). I have not pulled this yet pending a clearer validation path, since benchmarking a local model against an unvalidated ground truth compounds the uncertainty.

Next Steps (Pending Your Input)

1. **Establish validated ground truth** — via whichever option above is most feasible.
2. **Pull and benchmark `ministral-3:14b` locally** — once ground truth is confirmed.
3. **Targeted prompt fixes for remaining weak fields** — `mri_lesion_left/right`, `emu_epilepsy_intract`, `emu_sz_type1_freq`, `sz_age`.
4. **Expand test set to 20–30 notes** — get non-PHI notes from Dr. Waters; generate new synthetic notes for edge cases in weak fields.
5. **Validation on real notes** — once Epic access is established, run de-identified real notes to verify accuracy outside the synthetic environment.

Appendix: Synthetic Test Notes

The 8 synthetic EMU discharge notes used for evaluation are reproduced below in full. All are hand-crafted and contain no real patient data.

Note 1 — Left MTLE with Hippocampal Sclerosis (doc-001)

```
EPILEPSY MONITORING UNIT DISCHARGE SUMMARY

Patient: Jane D. (synthetic/de-identified)
DOB: 1988-03-14 | Age: 37 | Sex: Female
Admission: 2026-01-06 | Discharge: 2026-01-10
Attending: Dr. Waters

REFERRAL
Referred by Dr. Liu (UNC Epilepsy) for Phase 1 EMU evaluation. Patient is right-handed.
```

CHIEF COMPLAINT / REASON FOR ADMISSION
Drug-resistant focal seizures since age 19. Admitted for Phase 1 evaluation to characterize seizures and assess surgical candidacy.

HISTORY OF PRESENT ILLNESS
Ms. D. is a 37-year-old right-handed woman with an 18-year history of focal epilepsy. Seizures began at age 19 with no clear precipitant. She reports two seizure types: (1) frequent auras consisting of a rising epigastric sensation with deja vu, occurring multiple times per week; (2) focal seizures with impaired awareness approximately 2-3 times per month, characterized by behavioral arrest, oral automatisms, and left hand fumbling, lasting 60-90 seconds with post-ictal confusion for 5-10 minutes. Last convulsive seizure was over 2 years ago. She has failed four ASMs: carbamazepine (rash), valproic acid (weight gain, tremor), zonisamide (cognitive side effects), and phenytoin (inadequate control).

CURRENT MEDICATIONS
1. Levetiracetam (Keppra) 1500 mg twice daily
2. Lamotrigine (Lamictal) 200 mg twice daily

PAST MEDICAL / NEUROLOGICAL HISTORY
- No prior epilepsy surgery
- Mild depression (on sertraline 50 mg)
- Anxiety disorder
- No history of TBI, stroke, or CNS infection
- No suicidal ideation history

SOCIAL HISTORY
Currently employed as a teacher. Drives with neurologist awareness (seizure-free from GTC >2 years). Right-handed.

EMU COURSE
Four typical seizures captured over 4 days.

Interictal EEG: Frequent left anterior temporal sharp waves (F7/T3), occasionally with phase reversal at T3. No generalized discharges.

Ictal EEG: All four seizures showed left temporal rhythmic theta onset at T3, evolving to left temporal-parietal involvement. Semiology consistent with left mesial temporal onset: epigastric aura, then behavioral arrest with right hand automatisms and left hand dystonic posturing.

MRI BRAIN (3T Epilepsy Protocol, 2025-11-20)
ABNORMAL. Left hippocampal sclerosis with T2/FLAIR hyperintensity and volume loss of the left hippocampus. No other lesions identified. Lateralization: Left. Localization: Mesial temporal.

FDG-PET (2025-12-15)
Left temporal hypometabolism concordant with MRI and EEG findings.

NEUROPSYCHOLOGICAL TESTING
Modest verbal memory deficits consistent with left temporal dysfunction. Otherwise intact.

ASSESSMENT
1. Drug-resistant left mesial temporal lobe epilepsy (MTLE) with hippocampal sclerosis (MTLE-HS)
2. Concordant data: left temporal interictal and ictal EEG, left hippocampal sclerosis on MRI, left temporal hypometabolism on PET

3. Medically refractory epilepsy - failed 4 ASMs

PLAN
- Strong surgical candidate. Left ATL or SAH discussed.
- Refer to MECC.
- fMRI for language lateralization ordered.
- WADA test may be needed depending on fMRI results.
- Continue levetiracetam and lamotrigine pending surgical planning.
- Follow-up in UNC Epilepsy clinic in 6 weeks.

Note 2 — FND / Psychogenic Non-Epileptic Events (doc-002)

EPILEPSY MONITORING UNIT DISCHARGE SUMMARY

Patient: Marcus T. (synthetic/de-identified)
DOB: 1995-07-22 | Age: 30 | Sex: Male
Admission: 2026-01-13 | Discharge: 2026-01-18
Attending: Dr. Wabulya

REFERRAL
Referred by external neurology for characterization of events. Patient is right-handed.

CHIEF COMPLAINT / REASON FOR ADMISSION
Spells of unresponsiveness with shaking since age 27. Referred to differentiate epilepsy from non-epileptic events.

HISTORY OF PRESENT ILLNESS
Mr. T. is a 30-year-old right-handed man who began having episodes at age 27 following a motor vehicle accident (no head injury documented). Episodes occur 2-4 times per month: sudden unresponsiveness with bilateral asynchronous waxing-waning shaking, lasting 3-10 minutes. He sometimes recalls events partially. No post-ictal confusion. Events often triggered by emotional stress or sleep deprivation. Started on levetiracetam 1000 mg BID by outside neurology without improvement. One outside EEG was normal.

CURRENT MEDICATIONS
1. Levetiracetam (Keppra) 1000 mg twice daily
2. Escitalopram 10 mg daily

PAST MEDICAL / NEUROLOGICAL HISTORY
- PTSD (following MVA)
- Depression
- Anxiety
- No prior epilepsy surgery
- No suicidal ideation

EMU COURSE
Three typical events captured over 5 days.

Interictal EEG: Normal background. No epileptiform discharges.

Ictal EEG: All three captured events showed no EEG correlate. Muscle artifact present but

underlying rhythm remained normal. Semiology: asynchronous bilateral limb movements, eyes closed throughout (resisted opening), back arching, rapid recovery without post-ictal period.

MRI BRAIN (2025-09-10): NORMAL.

ASSESSMENT
1. FND / PNEE - all captured events non-epileptic
2. Comorbid PTSD, depression, and anxiety
3. Levetiracetam not indicated - taper and discontinue

PLAN
- Diagnosis discussed with patient and family.
- LEV taper over 4 weeks.
- Referred to UNC FND Clinic (CBT, PT).
- Not a surgical candidate.
- Cleared to drive pending 6-month event-free period.

Note 3 — Drug-Resistant Right Frontal Epilepsy, Prior VNS (doc-003)

EPILEPSY MONITORING UNIT DISCHARGE SUMMARY

Patient: Sandra K. (synthetic/de-identified)
DOB: 1979-11-05 | Age: 46 | Sex: Female
Admission: 2026-01-28 | Discharge: 2026-02-03
Attending: Dr. Sheikh

REFERRAL
Referred by Dr. Wabulya for Phase 2 evaluation planning. Left-handed.

CHIEF COMPLAINT / REASON FOR ADMISSION
Continued drug-resistant seizures despite VNS and multiple ASMs. Phase 1 re-evaluation.

HISTORY OF PRESENT ILLNESS
Ms. K. is a 46-year-old left-handed woman with 22-year history of drug-resistant focal epilepsy. Seizure onset at age 24. Failed six ASMs lifetime. VNS implanted 2018 (~30% reduction, no seizure freedom). Focal impaired awareness seizures approximately weekly, occasional secondary generalization (last GTC 4 months ago). Semiology: head version right, right arm tonic posturing.

CURRENT MEDICATIONS
1. Lacosamide (Vimpat) 200 mg twice daily
2. Clobazam (Onfi) 10 mg twice daily
3. Topiramate (Topamax) 100 mg twice daily - word-finding difficulties reported

PAST SURGICAL HISTORY
- VNS implanted 2018, currently active

PAST MEDICAL / NEUROLOGICAL HISTORY
- Depression (on bupropion)
- No suicidal ideation

EMU COURSE

VNS off on admission. Six seizures captured.

Interictal EEG: Right frontal sharp waves (F4), right anterior temporal slowing.

Ictal EEG: Right frontal onset (F4), rapid spread to right temporal. Semiology: hypermotor features at onset, then head version left, tonic right arm.

MRI BRAIN (3T, 2025-08-14)
ABNORMAL. Small area of cortical thickening and T2 signal in right posterior frontal lobe (premotor cortex), suspicious for FCD. Lateralization: Right. Localization: Frontal.

FDG-PET (2025-10-02): Right frontal hypometabolism concordant with MRI.

ASSESSMENT
1. Drug-resistant right frontal lobe epilepsy, likely FCD
2. Medically refractory - 6 ASMs failed, VNS partial response
3. Lesion concordant with ictal onset zone

PLAN
- Surgical candidate. LITT discussed as minimally invasive option.
- MECC recommendation: Phase 2 with sEEG.
- Topiramate taper; cenobamate (Xcopri) trial.
- VNS reactivated on discharge.

Note 4 — Juvenile Myoclonic Epilepsy (doc-004)

EPILEPSY MONITORING UNIT DISCHARGE SUMMARY

Patient: Derek M. (synthetic/de-identified)
DOB: 2001-04-17 | Age: 24 | Sex: Male
Admission: 2026-02-10 | Discharge: 2026-02-14
Attending: Dr. LaRoche

CHIEF COMPLAINT / REASON FOR ADMISSION
Breakthrough GTC seizures on current ASM. Medication adjustment and myoclonic characterization.

HISTORY OF PRESENT ILLNESS
Mr. M. is a 24-year-old right-handed man with JME diagnosed at age 17. Responded well to VPA initially; discontinued 2 years ago (weight gain, tremor). Transitioned to levetiracetam - partial control. Daily morning myoclonic jerks on awakening. Three GTCs in past 6 months (all sleep deprivation-related). No absences.

CURRENT MEDICATIONS
1. Levetiracetam (Keppra) 2000 mg twice daily

PAST MEDICAL / NEUROLOGICAL HISTORY
- No prior epilepsy surgery
- Mild anxiety
- No suicidal ideation

EMU COURSE

Sleep deprivation protocol. Two myoclonic events and one GTC captured.

Interictal EEG: Generalized 3-4 Hz polyspike-and-wave and spike-and-wave, maximum frontally, activated by sleep deprivation. No focal features.

Ictal EEG: GTC preceded by generalized polyspike-and-wave burst. Myoclonic jerks correlated with brief generalized polyspike bursts.

MRI BRAIN (2024-06-01): NORMAL.

ASSESSMENT
1. JME confirmed
2. Breakthrough seizures - medication switch and sleep deprivation
3. Levetiracetam providing incomplete control

PLAN
- Add lamotrigine 100 mg BID (slow titration).
- Sleep hygiene and alcohol avoidance counseling.
- NOT a surgical candidate (idiopathic generalized epilepsy).
- Driving restriction until 6 months seizure-free.

Note 5 — Post-Stroke Focal Epilepsy (doc-005)

EPILEPSY MONITORING UNIT DISCHARGE SUMMARY

Patient: Howard L. (synthetic/de-identified)
DOB: 1958-09-30 | Age: 67 | Sex: Male
Admission: 2026-02-17 | Discharge: 2026-02-22
Attending: Dr. Shin

CHIEF COMPLAINT / REASON FOR ADMISSION
New-onset focal seizures 8 months after right MCA ischemic stroke.

HISTORY OF PRESENT ILLNESS
Mr. L. is a 67-year-old right-handed man with right MCA ischemic stroke (May 2025), residual mild left hemiparesis. Focal motor seizures began ~8 months post-stroke, 2-3 times per month. Semiology: focal left face and arm twitching, retained awareness, 30-60 seconds. No secondary generalization. Started on levetiracetam by stroke team - partial improvement.

CURRENT MEDICATIONS
1. Levetiracetam (Keppra) 1000 mg twice daily
2. Aspirin 81 mg daily
3. Atorvastatin 40 mg daily
4. Lisinopril 10 mg daily

PAST MEDICAL / NEUROLOGICAL HISTORY
- Right MCA ischemic stroke (May 2025), residual mild left hemiparesis
- Hypertension, hyperlipidemia, type 2 diabetes
- No psychiatric comorbidities
- No suicidal ideation

EMU COURSE
Three focal motor seizures captured.

Interictal EEG: Right hemispheric slowing (IRDA), maximal right temporal-parietal. Occasional right temporal sharp waves.

Ictal EEG: Right centroparietal onset (C4/P4), focal rhythmic beta then theta. Semiology: contralateral left face and arm clonic movements.

MRI BRAIN (2026-01-08)
ABNORMAL. Encephalomalacia/gliosis in right MCA territory (right temporal and parietal lobes), consistent with prior ischemic stroke. Lateralization: Right. Localization: Temporal and parietal.

ASSESSMENT
1. Post-stroke focal epilepsy, right hemisphere
2. Focal motor seizures, retained awareness
3. Medically refractory on one ASM

PLAN
- Increase LEV to 1500 mg BID.
- Add lacosamide 100 mg BID → titrate to 150 mg BID.
- Not currently surgical candidate (eloquent cortex, medical comorbidities).
- RNS discussed as future option.

Note 6 — Mixed FND and Focal Epilepsy (doc-006)

EPILEPSY MONITORING UNIT DISCHARGE SUMMARY

Patient: Priya N. (synthetic/de-identified)
DOB: 1990-12-01 | Age: 35 | Sex: Female
Admission: 2026-03-01 | Discharge: 2026-03-05
Attending: Dr. Vaughn

CHIEF COMPLAINT / REASON FOR ADMISSION
Two distinct event types - one suspected epileptic, one suspected non-epileptic.

HISTORY OF PRESENT ILLNESS
Ms. N. is a 35-year-old right-handed woman with two distinct event types since age 28. Event type 1: brief right-hand tingling with visual changes, 10-20 seconds, 1-2x/week. Event type 2: prolonged unresponsiveness with bilateral shaking, 5-15 minutes, monthly, stress-triggered. On oxcarbazepine with modest improvement in type 1 only. History of sexual abuse, PTSD, depression.

CURRENT MEDICATIONS
1. Oxcarbazepine (Trileptal) 300 mg twice daily
2. Sertraline 100 mg daily
3. Clonazepam 0.5 mg PRN

PAST MEDICAL / NEUROLOGICAL HISTORY
- PTSD, depression, anxiety
- History of suicidal ideation (remote, no recent)

- No prior epilepsy surgery

EMU COURSE
Two type 1 events and one type 2 event captured.

Interictal EEG: Left occipital sharp waves (O1).

Ictal EEG - Type 1: Left occipital rhythmic alpha with evolution. Semiology: right visual field flickering, right hand paresthesias. → Focal aware seizure, left occipital onset.

Ictal EEG - Type 2: No EEG correlate. Waxing-waning bilateral asynchronous movements, eyes closed, rapid recovery. → PNEE.

MRI BRAIN (2025-06-20)
ABNORMAL. Small T2 signal change in left occipital lobe (possible small cortical dysplasia vs gliosis). Lateralization: Left. Localization: Occipital.

ASSESSMENT
1. Mixed disorder: focal aware epilepsy (left occipital) AND FND/PNEE
2. Comorbid PTSD and depression contributing to FND component

PLAN
- Continue oxcarbazepine.
- FND Clinic referral (CBT, PT).
- Not surgical candidate at this time.

Note 7 — LGI1 Autoimmune Limbic Encephalitis (doc-007)

EPILEPSY MONITORING UNIT DISCHARGE SUMMARY

Patient: Calvin R. (synthetic/de-identified)
DOB: 1972-06-14 | Age: 53 | Sex: Male
Admission: 2026-03-10 | Discharge: 2026-03-15
Attending: Dr. Liu

CHIEF COMPLAINT / REASON FOR ADMISSION
New-onset seizures with subacute cognitive decline over 4 months.

HISTORY OF PRESENT ILLNESS
Mr. R. is a 53-year-old right-handed man with 4-month subacute onset of confusion, short-term memory loss, and new focal seizures. Seizures: focal impaired awareness, staring, chewing automatisms, 1-2 minutes, occurring daily. CSF: elevated protein, mild pleocytosis. LGI1 antibody positive in serum and CSF. Started on methylprednisolone - partial cognitive improvement, seizures persist.

CURRENT MEDICATIONS
1. Levetiracetam (Keppra) 1500 mg twice daily
2. Lacosamide (Vimpat) 100 mg twice daily
3. Prednisone 40 mg daily (tapering)

PAST MEDICAL / NEUROLOGICAL HISTORY

- LGI1 autoimmune encephalitis (newly diagnosed)
- Mild cognitive impairment (secondary to encephalitis)
- Hypertension
- No prior epilepsy surgery
- No suicidal ideation

EMU COURSE
Multiple seizures captured daily.

Interictal EEG: Bilateral temporal slowing (L > R), left temporal independent sharp waves. Diffuse background slowing (encephalopathy pattern).

Ictal EEG: Left temporal rhythmic theta onset (T3), spreading bilaterally.

MRI BRAIN (2026-02-28)
ABNORMAL. T2/FLAIR hyperintensity involving bilateral hippocampi and amygdalae (L > R), consistent with limbic encephalitis. Lateralization: Bilateral. Localization: Mesial temporal.

ASSESSMENT
1. LGI1 autoimmune limbic encephalitis with focal epilepsy
2. Autoimmune/inflammatory etiology
3. Bilateral mesial temporal involvement - not surgical candidate

PLAN
- Not a surgical candidate.
- IVIG 5-day course.
- Rituximab discussed for maintenance immunotherapy.
- Continue LEV and lacosamide.

Note 8 — Dravet Syndrome, Transition to Adult Care (doc-008)

EPILEPSY MONITORING UNIT DISCHARGE SUMMARY

Patient: Leo W. (synthetic/de-identified)
DOB: 2008-02-09 | Age: 18 | Sex: Male
Admission: 2026-03-24 | Discharge: 2026-03-28
Attending: Dr. Wabulya

CHIEF COMPLAINT / REASON FOR ADMISSION
Transition from pediatric to adult epilepsy care; medication optimization.

HISTORY OF PRESENT ILLNESS
Mr. W. is an 18-year-old right-handed male with Dravet syndrome (SCN1A mutation confirmed), diagnosed at age 1. Febrile status epilepticus in infancy. Drug-resistant throughout childhood. Three seizure types: (1) GTC - monthly; (2) focal impaired awareness - weekly; (3) myoclonic jerks - daily. Significant intellectual disability and autism spectrum disorder. Failed numerous medications. Rescue: intranasal diazepam.

CURRENT MEDICATIONS
1. Valproic acid (Depakote) 750 mg twice daily
2. Clobazam (Onfi) 10 mg twice daily

3. Fenfluramine (Fintepla) 0.2 mg/kg/day
Rescue: Intranasal diazepam (Valtoco)

PAST MEDICAL / NEUROLOGICAL HISTORY
- Dravet syndrome (SCN1A mutation)
- Intellectual disability (moderate)
- Autism spectrum disorder
- No prior epilepsy surgery

EMU COURSE
One GTC on day 2; multiple myoclonic events captured.

Interictal EEG: Generalized irregular spike-and-wave and polyspike-and-wave. Background slowing. Occasional right temporal focal slowing.

Ictal EEG: GTC with generalized polyspike then tonic-clonic activity. Myoclonic jerks with brief generalized polyspike bursts.

MRI BRAIN (2024-11-15): NORMAL for age.

ASSESSMENT
1. Dravet syndrome (SCN1A) - confirmed genetic epilepsy syndrome
2. Drug-resistant generalized and focal epilepsy
3. Successful transition to adult care
4. Not a surgical candidate (genetic/generalized epilepsy)

PLAN
- Continue valproic acid, clobazam, fenfluramine.
- Discuss adding cannabidiol (Epidiolex).
- Not a surgical candidate.
- Rescue medication supply ensured.
- Cardiac monitoring for fenfluramine (annual echo).
- Follow-up UNC Epilepsy (adult) in 3 months.