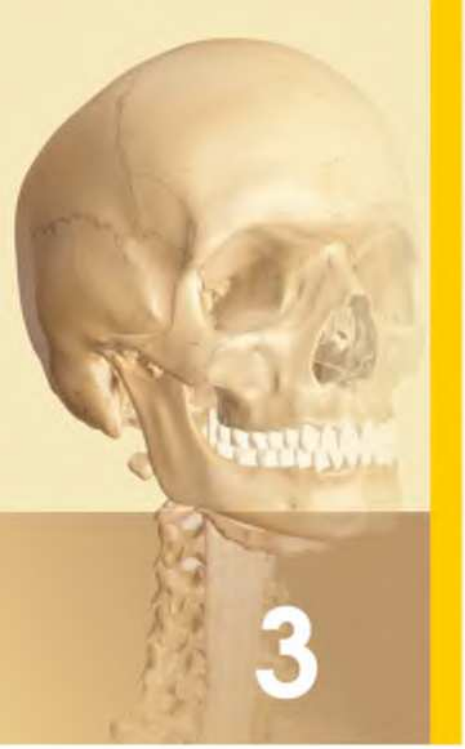

3 Joints

What I hear, I forget, What I see, I remember, What I do, I understand

Related Terms

1 Arthron (G a joint). Compare with the terms arthrology, synarthrosis, diarthrosis, arthritis, arthrodesis, etc.
2 Articulatio (L a joint); articulation (NA).
3 Junctura (L a joint).
4 Syndesmology (G syndesmosis = ligament) is the study of ligaments and related joints.

Definition

Joint is a junction between two or more bones or cartilages. It is a device to permit movements.

However, immovable joints are primarily meant for growth. Primary cartilaginous joints of long bones increase length of bone. A newborn baby is about 15″ long and length increases to 60–70″ in an adult due to growth at these joints. Fontanelles of skull may permit moulding during childbirth.

There are more joints in a child than in an adult because as growth proceeds some of the bones fuse together, e.g. the ilium, ischium and pubis to fuse form the pelvic bone. The two halves of the infant frontal bone, and of the infant mandible also fuse to form single frontal and mandible bone respectively. The five sacral vertebrae fuse to form sacrum and the four coccygeal vertebrae join to form coccyx.

Joints help to form cavities like cranial, thoracic, abdominal and pelvic cavities where the respective organs are safely kept. Joints of thoracic cage help in increasing transverse and anteroposterior diameters of the cage, helping in respiration.

CLASSIFICATION OF JOINTS

A. Structural Classification

1. *Fibrous Joints*

a. Sutures
b. Syndesmosis
c. Gomphosis

2. *Cartilaginous Joints*

a. Primary cartilaginous joints or synchondrosis
b. Secondary cartilaginous joints or symphysis or amphiarthrosis

3. *Synovial Joints*

a. Ball-and-socket or spheroidal joints
b. Sellar or saddle joints
c. Condylar or bicondylar joints
d. Ellipsoid joints
e. Hinge joints
f. Pivot or trochoid joints
g. Plane joints

B. Functional Classification (According to the Degree of Mobility)

1 Synarthroses (immovable), like sutures of the fibrous joints (Fig. 3.1), and epiphyseal plate of a young growing bone (Fig. 3.2).

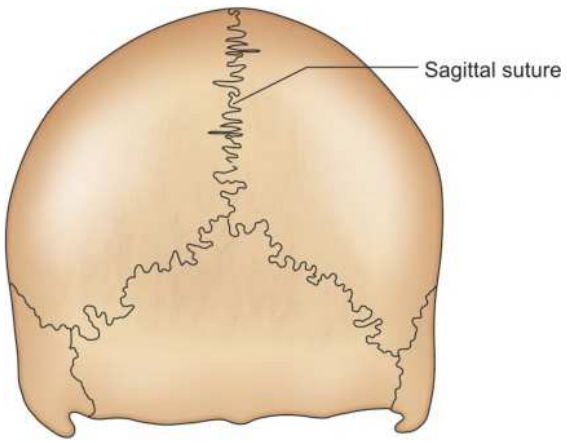

Fig. 3.1: Fibrous joint—sutures

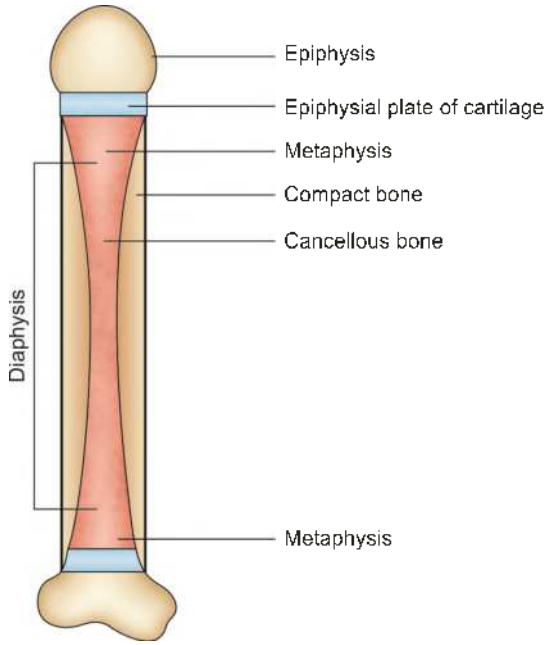

Fig. 3.2: Primary cartilaginous joint

2 Amphiarthroses (slightly movable), like secondary cartilaginous joints (Fig. 3.10).
3 Diarthroses (freely movable), like synovial joints (Fig. 3.3).

Synarthroses are fixed joints at which there is no movement. The articular surfaces are joined by tough fibrous tissue. Often the edges of the bones are dovetailed into one another as in the sutures of the skull.

Amphiarthroses are joints at which slight movement is possible. The articulating bones are covered by hyaline cartilage. A pad of fibrocartilage lies between the bone surfaces, and there are fibrous ligaments to hold the bones and cartilages in place. The cartilages of such joints also act as shock absorbers, e.g. the intervertebral discs between the bodies of the vertebrae.

Diarthroses or synovial joints are known as freely movable joints, though at some of them the movement is restricted by the shape of the articulating surfaces and by the ligaments which hold the bones together. These ligaments are of elastic connective tissue.

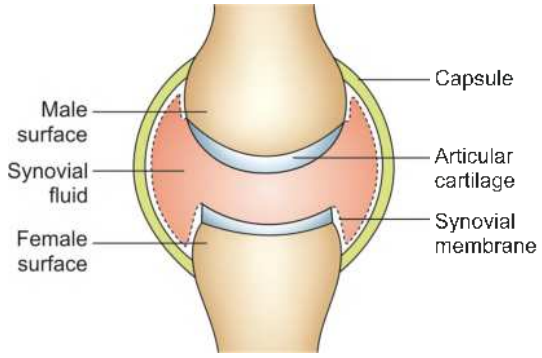

Fig. 3.3: Structure of simple synovial joint

A synovial joint has a fluid-filled cavity between articular surfaces which are covered by articular cartilage. The fluid, known as synovial fluid is produced by the synovial membrane. The synovial membrane lines the cavity except for the actual articular surfaces. It covers any ligaments or tendons which pass through the joint. Synovial fluid acts as a lubricant.

The form of the articulating surfaces controls the type of movement which takes place at any joint.

The movements possible at synovial joints are:

Angular—flexion: decreasing the angle between two bones or two parts

extension: increasing the angle between two bones or two parts

abduction: moving the part away from the midline

adduction: bringing the part towards the midline

Rotatory—rotation: rotating along the vertical axis

circumduction: moving the extremity or the part round in a circle so that the whole part inscribes a cone. When flexion, abduction, extension and adduction occur in sequence the movement is called as the circumduction

Gliding one part slides on another.

C. Regional Classification

1 *Skull type*: Immovable
2 *Vertebral type*: Slightly movable
3 *Limb type*: Freely movable

D. According to Number of Articulating Bones

1 *Simple joint*: When only two bones articulate, e.g. interphalangeal joints (Fig. 3.3).
2 *Compound joint*: More than two bones articulate within one capsule, e.g. elbow joint, radiocarpal joint (Fig. 3.4).
3 *Complex joint*: When joint cavity is divided by an intra-articular disc, e.g. temporomandibular joint (Fig. 3.5), sternoclavicular joint. Figure 3.6 is a diagrammatic representation of complex joint.

The *structural* classification is most commonly followed, and will be considered in detail in the following paragraphs.

FIBROUS JOINTS

In fibrous joints the bones are joined by fibrous tissue. These joints are either immovable or permit a slight degree of movement. These can be grouped in the following three subtypes.

1 *Sutures*: Sutures are present only in skull. Two bones are separated by connective tissue. The sutural side of each bone is covered by a layer of osteogenic cells/cambial layer, covered by capsular layer which is

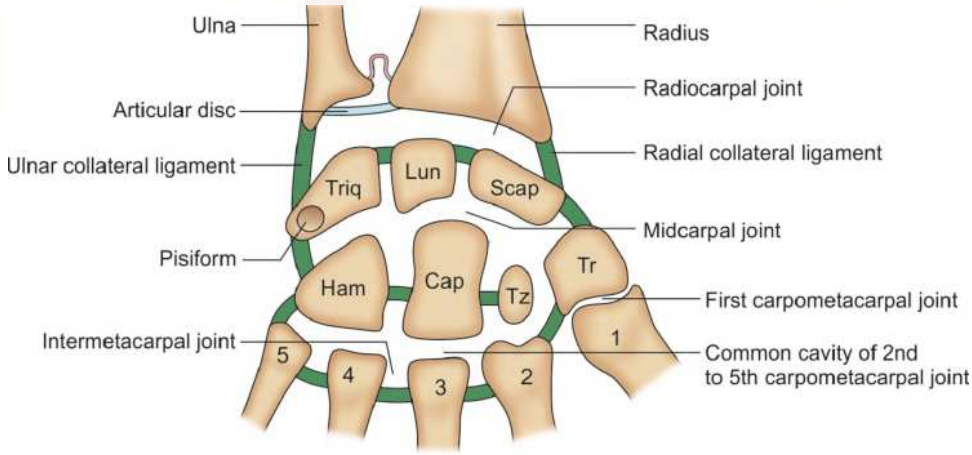

Fig. 3.4: Some simple and compound joints

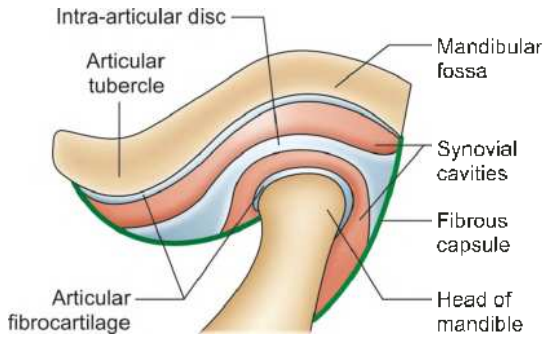

Fig. 3.5: Condylar joint—temporomandibular joint

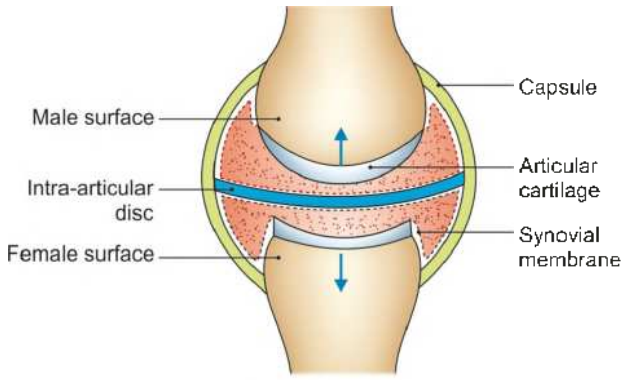

Fig. 3.6: Complex joint

continuous with the periosteum. The area between the bones decreases with age, so that osteogenic surfaces become opposed. Sutures may synostose and get obliterated as age advances.

Sutures are peculiar to skull, and are immovable. According to the shape of bony margins, the sutures can be:

i. Plane, e.g. internasal suture (Fig. 3.7)
ii. Serrate, e.g. interparietal suture
iii. Squamous, e.g. temporoparietal suture
iv. Denticulate, e.g. lambdoid suture
v. Schindylesis type, e.g. between rostrum of sphenoid and upper border of vomer.

Neonatal skull reveals fontanelles which are temporary in nature permit moulding during normal childbirth. At six specific points on the sutures (in newborn skull) are membrane filled gaps called "fontanelles". These also allow the underlying brain to increase in size. Anterior fontanelle is used to judge the hydration of the infant. All these fontanelles become bone by 18 months (Fig. 3.8).

2 *Syndesmosis*: It is a fibrous union between bones. It may be represented as interosseous ligament as in inferior tibiofibular joint.

3 *Gomphosis*: It is a peg and socket junction between the tooth and its socket. The periodontal ligament connects the dental element to the alveolar bone (Fig. 3.9).

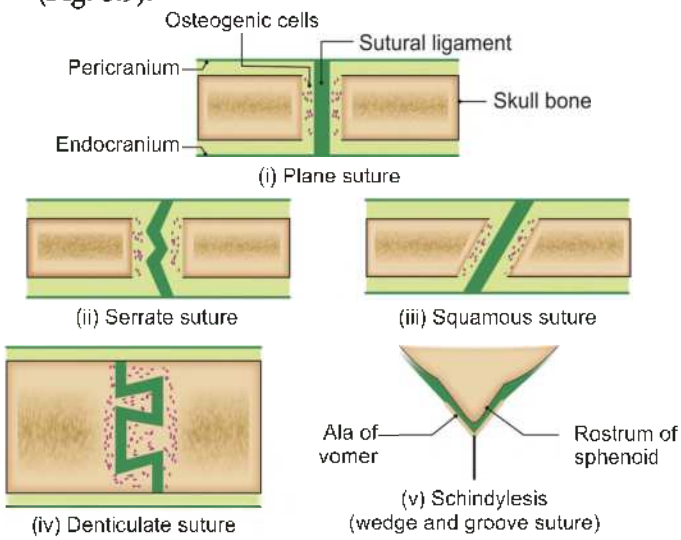

Fig. 3.7: Types of sutures

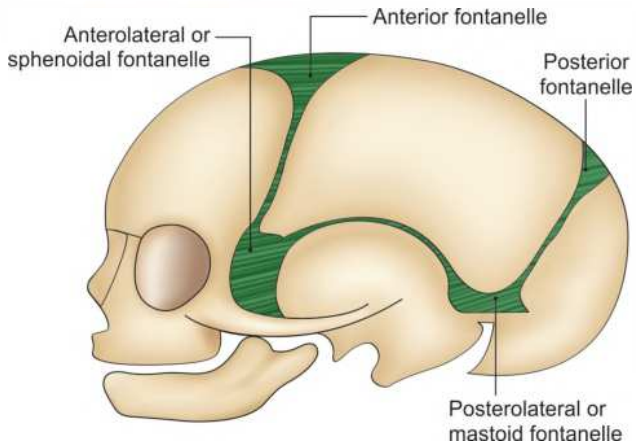

Fig. 3.8: Fontanelles of skull of a newborn baby

CARTILAGINOUS JOINTS

In this type of joints the bones are joined by cartilage. These are of the following two types:

1 *Primary cartilaginous joints* (synchondrosis, or hyaline cartilage joints): The bones are united by a plate of hyaline cartilage (epiphysial plate) so that the joint is immovable and strong.

These joints are temporary in nature because after a certain age the cartilaginous plate is replaced by bone (synostosis). These are seen in between epiphysis and diaphysis of long bone. These are associated with growth or epiphysial plates and increasing length of the bone. Primary cartilaginous joints or synchondrosis become synostosed after some age and are not identifiable.

Examples:

a. Joint between epiphysis and diaphysis of a growing long bone (Fig. 3.2)

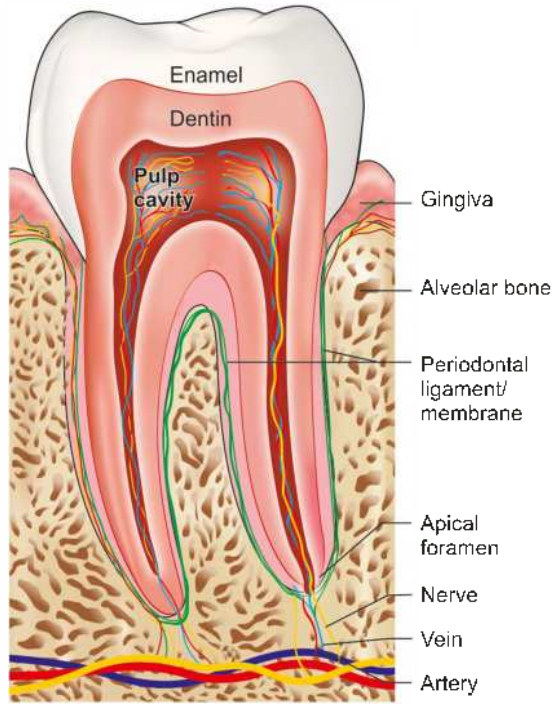

Fig. 3.9: Gomphosis

b. Spheno-occipital joint
c. First chondrosternal joint
d. Costochondral joints.

2 *Secondary cartilaginous joints* (symphyses or fibrocartilaginous joints): The articular surfaces are covered by a thin layer of hyaline cartilage, and united by a disc of fibrocartilage (Fig. 3.10).

These joints are permanent and persist throughout life. In this respect symphysis menti is a misnomer as it is a synostosis. Typically the secondary cartilaginous joints occur in the median plane of the body.

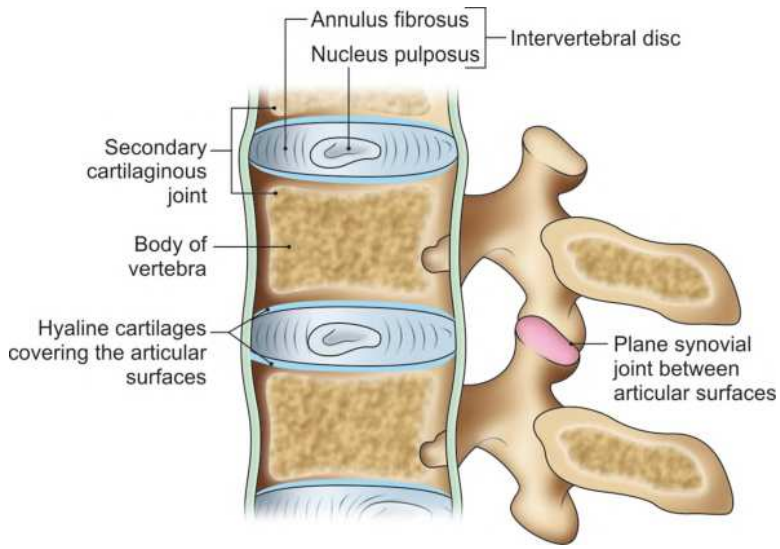

Fig. 3.10: Secondary cartilaginous joints with plane synovial joint

The thickness of fibrocartilage is directly related to the range of movement. Secondary cartilaginous joints may represent an intermediate stage in the evolution of synovial joints.

Examples:

a. Symphysis pubis
b. Manubriosternal joint
c. Intervertebral joints between the vertebral bodies (Fig. 3.10).

The disc varies from few mm to 10 mm and there is dense connective tissue with few chondrocytes.

SYNOVIAL JOINTS

Synovial joints are most evolved, and, therefore, most mobile type of joints. Table 3.1 shows classification of synovial joints and their movements.

Table 3.1: Classification of synovial joints and their movements

Type of Joint	*Movement*
A. Plane or gliding type	Gliding movement
B. Uniaxial joints	
1. Hinge joint	Flexion and extension
2. Pivot joint	Rotation only
C. Biaxial joints	
1. Condylar joint	Flexion, extension, and limited rotation
2. Ellipsoid joint	Flexion, extension, abduction, adduction, and circumduction
D. Multiaxial joints	
1. Saddle joint	Flexion and extension, abduction, adduction, and conjunct rotation
2. Ball-and-socket	Flexion and extension, abduction and adduction, (spheroidal) joint circumduction, medial and lateral rotation

Characters

1 The articular surfaces are covered with hyaline (articular) cartilage (fibrocartilage in certain membrane bones) like clavicle and mandible.

Articular cartilage is avascular, non-nervous and elastic. Lubricated with synovial fluid, the cartilage provides slippery surfaces for free movements, like 'ice on ice'.

The surface of the cartilage shows fine undulations filled with synovial fluid.

2 Between the articular surfaces there is a *joint cavity* filled with synovial fluid. The cavity may be partially or completely subdivided by an articular disc or meniscus (Fig. 3.6).

3 The joint is surrounded by an *articular capsule* which is made up of a fibrous capsule lined by synovial membrane.

Because of its rich nerve supply, the *fibrous capsule* is sensitive to stretches imposed by movements. This sets up appropriate reflexes to protect the joint from any sprain. This is called the 'watch-dog' action of the capsule.

The fibrous capsule is often reinforced by:

a. *Capsular* or *true ligaments* representing thickenings of the fibrous capsule.
b. The *accessory ligaments* (distinct from fibrous capsule) which may be intra- or extracapsular.

The *synovial membrane* lines whole of the interior of the joint, except for the articular surfaces covered by articular cartilage.

The membrane secretes a slimy viscous fluid called the synovia or *synovial fluid* which lubricates the joint and nourishes the articular cartilage. The viscosity of fluid is due to hyaluronic acid secreted by cells of the synovial membrane.

4 Varying degrees of movements are always permitted by the synovial joints.

Classification of Synovial Joints

1. Plane Synovial Joints

Articular surfaces are more or less flat (plane). They permit gliding movements (translations) in various directions.

Examples:

a. Intercarpal joints (Fig. 3.4)
b. Intertarsal joints
c. Joints between articular processes of vertebrae
d. Cricothyroid joint (*see* Fig. 2.7)
e. Cricoarytenoid joint (*see* Fig. 2.7)

2. Hinge Joints (Ginglymi)

Articular surfaces are pulley-shaped. There are strong collateral ligaments. Movements are permitted in one plane around a transverse axis.

Examples:

a. Elbow joint (Fig. 2.1)
b. Ankle joint
c. Interphalangeal joints (Fig. 2.1)

3. Pivot (Trochoid) Joints

Articular surfaces comprise a central bony pivot (peg) surrounded by an osteoligamentous ring. Movements are permitted in one plane around a vertical axis.

Examples:

a. Superior and inferior radioulnar joints
b. Median atlantoaxial joint (Fig. 3.11).

4. Condylar (Bicondylar) Joints

Articular surfaces include two distinct condyles (convex male surfaces) fitting into reciprocally concave female surfaces (which are also, sometimes, known as condyles, such as in tibia). These joints permit movements mainly in one plane around a transverse

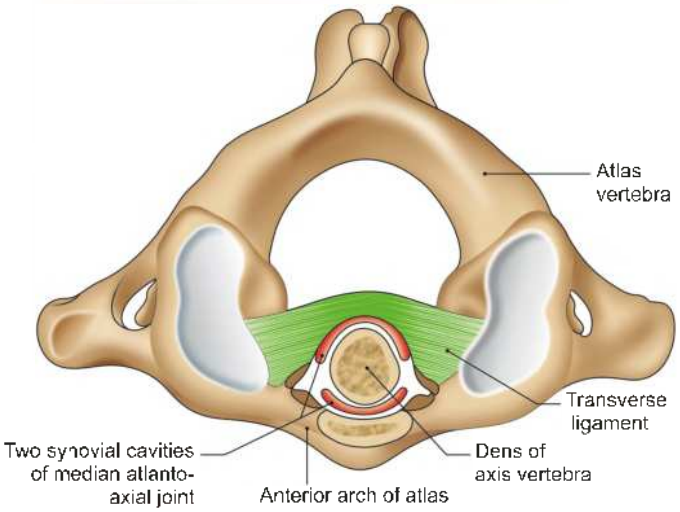

Fig. 3.11: Median atlantoaxial joint

axis, but partly in another plane (rotation) around a vertical axis.

Examples:

a. Knee joint (*see* Fig. 2.1)

b. Right and left jaw joints or temporomandibular joint (Fig. 3.5).

5. Ellipsoid Joints

Articular surfaces include an oval, convex, male surface fitting into an elliptical, concave female surface. Free movements are permitted around both the axes; flexion and extension around the transverse axis, and abduction and adduction around the anteroposterior axis. Combination of movements produces circumduction. Typical rotation around a third (vertical) axis does not occur.

Examples:

a. Atlanto-occipital joints.

b. Wrist joint (Fig. 3.4)

c. Metacarpophalangeal joints

6. Saddle (Sellar) Joints

Articular surfaces are reciprocally concavoconvex. Movements are similar to those permitted by an ellipsoid joint, with addition of some rotation (conjunct rotation) around a third axis which, however, cannot occur independently.

Examples:

a. First carpometacarpal joint (Fig. 3.4)

b. Sternoclavicular joint

c. Calcaneocuboid joint

d. Incudomalleolar joint (Fig. 3.12)

e. Between femur and patella.

7. Ball-and-Socket (Spheroidal) Joints

Articular surfaces include a globular head (male surface) fitting into a cup-shaped socket (female surface).

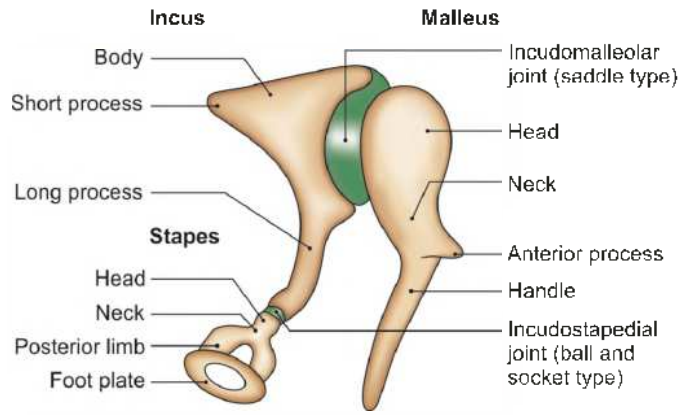

Fig. 3.12: Visceral bones ear ossicles with their joints

Movements occur around an indefinite number of axes which have one common centre. Flexion, extension, abduction, adduction, medial rotation, lateral rotation, and circumduction, all occur quite freely.

Examples:

a. Shoulder joint

b. Hip joint

c. Talocalcaneonavicular joint

d. Incudostapedial joint (Fig. 3.12)

Mechanism of Lubrication of a Synovial Joint

1. Synovial fluid, secreted by synovial membrane, is sticky and viscous due to hyaluronic acid (a mucopolysaccharide). It serves the main function of lubrication of the joint. It also nourishes the articular cartilage.
2. *Hyaline cartilage*: Covering the articular surfaces possesses inherent slipperiness, like that of the ice.
3. *Intra-articular fibrocartilages, articular discs or menisci, complete or incomplete*: Help in spreading the synovial fluid throughout the joint cavity, but particularly between the articular surfaces, e.g. temporomandibular joint (Fig. 3.5). The disc divides the joint into two cavities for diverse movements in 2 cavities. The disc strengthens the joint.

Blood Supply

The articular and epiphysial branches given off by the neighbouring arteries form a periarticular arterial plexus. Numerous vessels from this plexus pierce the fibrous capsule and form a rich vascular plexus in the deeper parts of synovial membrane. The blood vessels of the synovial membrane terminate around the articular margins in a fringe of looped anastomoses termed the circulus vasculosus (*circulus articularis vasculosus*). It supplies capsule, synovial membrane and the epiphysis. The articular cartilage is avascular.

Nerve Supply

The *capsule* and *ligaments* possess a rich nerve supply, which makes them acutely sensitive to pain. The synovial membrane has a poor nerve supply and is relatively insensitive to pain. The articular cartilage is non-nervous and totally insensitive. Articular nerves contain sensory and autonomic fibres. Autonomic fibres are vasomotor or vasosensory. The joint pain is often diffuse, and may be associated with nausea, vomiting, slowing of pulse and fall in blood pressure.

The pain commonly causes reflex contraction of muscles which fix the joint in a position of maximum comfort. Like visceral pain, the joint pain is also referred to uninvolved joints.

Lymphatic Drainage

Lymphatics form a plexus in the subintima of the synovial membrane, and drain along the blood vessels to the regional deep nodes.

Stability

The various factors maintaining stability at a joint are described here in order of their importance.

1. *Muscles*: The tone of different groups of muscles acting on the joint is the most important and indispensable factor in maintaining the stability.
2. *Ligaments*: These are important in preventing any over-movement, and in guarding against sudden accidental stresses. However, they do not help against a continuous strain, because once stretched, they tend to remain elongated. In this respect, the elastic ligaments (ligamenta flava and ligaments of the joints of auditory ossicles) are superior to the common type of white fibrous ligaments.

CLINICAL ANATOMY

- Intervertebral disc forms secondary cartilaginous joint between the bodies of the vertebrae. If the nucleus pulposus part of the disc protrudes backwards, it may press on the spinal nerve leaving out from the intervertebral foramina. The condition is known as *herniation of the disc* or disc prolapse. If disc prolapse occurs in lumbar vertebrae there is radiating pain in the lower limb, and the condition is called **sciatica**.
- The joints may get dislocated, i.e. the end of one of the bones gets out of its socket. In subluxation, the end of the bone partially leaves its socket.
- Stiffness of joints is related to weather. The viscosity of synovial fluid increases with fall in temperature. This accounts for stiffness of the joints in cold weather. Mobility of joint in itself is an important factor in promoting lubrication. Thus the stiffness of joints experienced in the morning gradually passes off as the movements are resumed.

FACTS TO REMEMBER

- Joint is a junction between two or more bones or cartilages.
- Joints are classified as fibrous, cartilaginous and synovial types.
- There are more joints in a child than in an adult. The primary cartilaginous joints at the ends of long bones after fusion disappear in the adult, decreasing the number of joints.
- Joints help in increasing the length of bones, increasing the size of cranial, thoracic and pelvic cavities.
- Joints in thorax help in respiratory movements.
- Joints are vital for locomotion.
- The secondary cartilaginous joints are in midline of the body.
- Joints in ossicles of middle ear are synovial joints.
- Joints chiefly suffer in osteoarthritis and rheumatoid arthritis.
- Joints in the laryngeal cartilages help us in speech.

MULTIPLE CHOICE QUESTIONS

1. Which of the following joint contains an intra-articular disc?
   a. Ankle joint
   b. Sternoclavicular joint
   c. Elbow joint
   d. Shoulder joint
2. Condylar joints are:
   a. Uniaxial, b. Biaxial
   c. Multiaxial d. Symphysis
3. Which is not a fibrous joint?
   a. Sutures b. Gomphosis
   c. Xiphisternal d. Inferior tibiofibular

ANSWERS

1. b 2. b 3. c