Evaluating the Global Consensus on Keratoconus and Ectatic Diseases Agreements Reached on Subclinical Keratoconus

J. BRADLEY RANDLEMAN, BIANCA N. SUSANNA, BASSEL HAMMOUD, BARBARA A.L. DUTRA, GIULIANO SCARCELLI, MARCONY R. SANTHIAGO, WILLIAM J. DUPPS JR, AND DOUGLAS D. KOCH

• PURPOSE: To evaluate the consensus agreements reached in the Global Consensus on Keratoconus and Ectatic Diseases project for subclinical keratoconus, specifically that posterior corneal elevation abnormalities must be present to diagnose mild or subclinical keratoconus.

• DESIGN: Literature review.

• METHODS: Database review (PubMed) was performed on January 2, 2024, to identify studies evaluating the ability of posterior corneal surface metrics to identify subclinical keratoconus using the following search terms: posterior corneal elevation; keratoconus screening; corneal ectasia; subclinical keratoconus; keratoconus suspect; and asymmetric keratoconus. Articles were included for final analysis if they evaluated the ability of the posterior corneal surface to identify subclinical keratoconus compared to anterior corneal surface and/or thickness metrics and reported area under the receiver operating curve (AUROC) data for multiple variables to allow for metric comparison. Metrics evaluated in each manuscript were categorized as anterior surface, thickness, or posterior surface. The relative discriminative performance of anterior surface (A), thickness (T), posterior surface (P), and the multimetric D score (D) metrics were evaluated based on AUROC, sensitivity, and specificity in differentiating subclinical keratoconus from normal controls were evaluated.

• RESULTS: There were 29 articles identified that met the inclusion criteria and were evaluated. In intrastudy comparison, anterior surface metrics (37.9%) and thickness metrics (39.2%) performed best at differentiating subclinical keratoconus from normal corneas, while only 4 out of 29 studies (13.8%) reported posterior metrics outperforming all metrics. In the subgroup analysis including the multimetric D score ($n = 15$), anterior surface metrics performed best (33.3%), followed by the D score (26.7%). In this D subgroup, no paper reported superior posterior metric performance.

• CONCLUSIONS: In aggregate, posterior corneal surface metrics performed worse than anterior corneal and thickness metrics in differentiating subclinical keratoconic eyes from normal controls. These results demonstrate a lack of evidence to support the consensus claim that posterior elevation abnormalities must be present to diagnose subclinical keratoconus. (Am J Ophthalmol 2025;275: 27–35.
© 2025 The Author(s). Published by Elsevier Inc. This is an open access article under the CC BY-NC-ND license (http://creativecommons.org/licenses/by-nc-nd/4.0/))

Accepted for publication March 7, 2025.

From the Cole Eye Institute (J.B.R., B.N.S., B.H., B.A.L.D., W.J.D.), Cleveland Clinic, Cleveland, Ohio, USA; Cleveland Clinic Lerner College of Medicine of Case Western Reserve University (J.B.R.), Cleveland, Ohio, USA; Department of Ophthalmology (B.N.S., B.A.L.D., M.R.S.), University of Sao Paulo, Sao Paulo, Brazil; Sorocaba Eye Hospital (B.N.S.), Sorocaba, Brazil; Fischell Department of Bioengineering (W.J.D.), University of Maryland, Maryland, USA; Department of Biomedical Engineering (W.J.D.), Case Western Reserve University, Cleveland, Ohio, USA; Cullen Eye Institute (D.D.K.), Baylor College of Medicine, Houston, Texas, USA

Inquiries to J. Bradley Randleman, MD, Cleveland Clinic Cole Eye Institute, 9500 Euclid Ave. i-32, Cleveland, Ohio, USA, 44195.; e-mail: randlej@ccf.org

Keratoconus detection at the earliest possible stage has significant implications for the preservation of visual function in patients with progressive ectatic disease[1,2] and for the safest performance of corneal refractive surgery by screening out candidates who are at increased risk for developing postoperative corneal ectasia.[3,4] This is particularly important as the prevalence of visually significant myopia is rising worldwide and is expected to surpass 50% in most countries by 2050,[5] while keratoconus prevalence has risen as diagnostic techniques have advanced.[6-8]

In 2015, four supranational corneal societies (Asia Cornea Society, Cornea Society, EuCornea, and PanCornea) utilized a modified Delphi technique, with panels of individuals selected by assigned coordinators, to arrive at consensus opinions regarding keratoconus and other ectatic diseases, which culminated in the Global Consensus on Keratoconus and Ectatic Diseases report.[9] Three panels were formed, including one specifically tasked with keratoconus definition/diagnosis. Consensus was achieved when two thirds of panel members reached the same opinion.

© 2025 The Author(s). Published by Elsevier Inc.
This is an open access article under the CC BY-NC-ND license
(http://creativecommons.org/licenses/by-nc-nd/4.0/)

0002-9394/$36.00
https://doi.org/10.1016/j.ajo.2025.03.013

Consensus agreements reached included the following:

- Abnormal posterior elevation and abnormal corneal thickness distribution are mandatory to diagnose keratoconus.
- Posterior corneal elevation abnormalities must be present to diagnose mild or subclinical keratoconus.

The report did not provide any specific data to support these agreements, nor did it provide a list of the references used to reach the consensus.[10-12] Given the controversy surrounding this topic and the need for greater understanding of its clinical implications, the purpose of this paper was to conduct an extensive literature review to evaluate the accuracy of the consensus statements regarding the identification of subclinical keratoconus (SKC), specifically the claim that "posterior corneal elevation abnormalities must be present to diagnose mild or subclinical keratoconus."[9]

METHODS

Literature review was performed to identify published studies that could serve to evaluate the relative efficacy of posterior corneal surface metrics in the identification of subclinical keratoconus. As this project included only literature review, no IRB approval was required. To generate the article list for evaluation, PubMed database review was performed on January 2, 2024, using the following search terms: posterior corneal elevation; keratoconus screening; corneal ectasia; subclinical keratoconus; keratoconus suspect; and asymmetric keratoconus. This resulted in 1,245 identified results. This list was screened by article title for potential relevance for subclinical keratoconus identification by one of the authors (Figure 1). Articles were excluded from further review if their focus was any of the following topics: endothelial disease, cataract surgery, corneal transplantation, or other topics not related to keratoconus. Articles with a primary focus on corneal cross-linking that did not evaluate keratoconus detection were also excluded at this juncture. The remaining article list was then cross-referenced with two recent review articles by Moshirfar and colleagues regarding tomography for refractive surgery screening[13,14] as well as the Ophthalmic Technology Assessment paper on advanced corneal imaging in keratoconus by the American Academy of Ophthalmology.[15] These additional identified publications were again screened by title. After this step, 397 papers were further evaluated by abstract review to determine if they pertained to keratoconus imaging or refractive surgery screening. After abstract review, 212 articles were accessed and reviewed in detail. Articles were included for final analysis if they met all of the following criteria:

1. Study included a group that could be considered "subclinical keratoconus" regardless of the specific terminology used (ie, forme fruste keratoconus, keratoconus suspect, asymmetric keratoconus, subclinical keratoconus, or other).[16]
2. Evaluated the ability of the posterior corneal surface to identify subclinical keratoconus compared to anterior corneal surface and/or thickness metrics.
3. Reported area under the receiver operating curve (AUROC) data for multiple variables to allow for intrastudy metric comparison.

This final search resulted in 29 articles that met these criteria and were analyzed.[17-45]

• **SUBCLINICAL KERATOCONUS CRITERIA AND CLASSIFICATIONS ACROSS STUDIES:** The term subclinical is typically defined as a disease state not yet sufficiently advanced to present definite or readily observable symptoms. In reviewing the literature, however, there were multiple disparate methodologies used to classify eyes as subclinical rather than clinical keratoconus. We did not create any unique classifications in this study but merely identified the criteria reported in each manuscript. In general, these classification systems could be categorized as the fellow eye of a patient with manifest keratoconus in one eye and: 1) clear distinct abnormalities on the anterior corneal surface that are well described in the Methods section that served as inclusion for SKC eyes and exclusion for control eyes (eg, inferior–superior asymmetry and/or a bowtie pattern with skewed radial axes detected on tangential Placido disk–based topography, or *KISA index*[46] *between 60% and 100%*,), or 2) indistinct anterior curvature findings described in the Methods section that would thus not necessarily differentiate normal controls from subclinical eyes (eg, no topographic or clinical signs of keratoconus in one eye).

• **METRIC SUBGROUP CLASSIFICATIONS:** A variety of individual metrics were assessed across studies; however, few studies reported efficacy of all potential metrics available from the imaging device used, and numerous studies focused only on select metrics for evaluation. Due to this heterogeneity of individual metrics reported from each study that limited individual metrics comparisons across studies, we categorized metrics evaluated in each manuscript into three subgroups: anterior surface metrics (A), thickness metrics (T), and posterior surface metrics (P). One parameter, the final "D" score, from the Pentacam device (Oculus), was also reported in numerous studies. As this metric is a multimetric variable utilizing anterior surface, thickness, and posterior surface data, it was evaluated as an independent metric in our analysis. We also identified articles that utilized only the final D score in their evaluations. These articles were not included in comparative data analysis. But were used to evaluate the efficacy of the D metric over time.

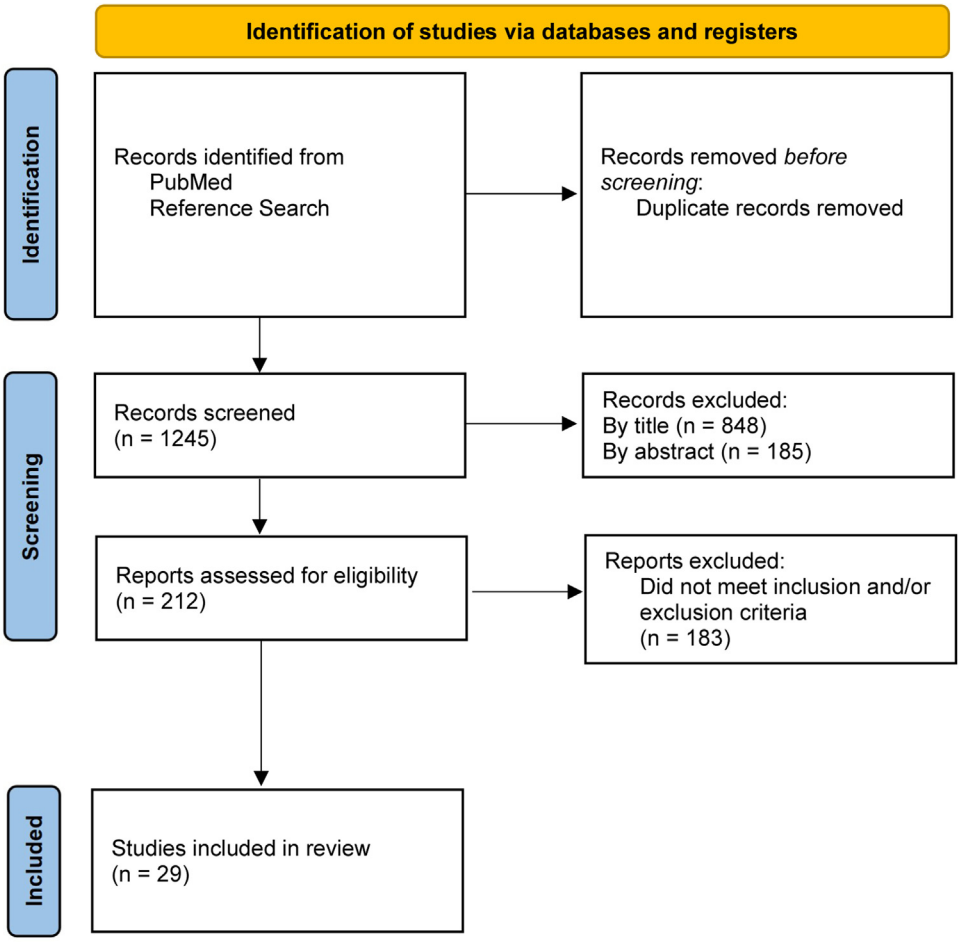

FIGURE 1. Flow diagram showing the studies selection process.

When determining which metric performed best in each paper, we used the reported AUROC values followed by sensitivity values. AUROC values within 0.03 were considered equivalent unless there was > 5% difference in sensitivity, in which case the more sensitive metric with equivalent AUROC was considered the best at identifying subclinical keratoconus and distinguishing between normal and subclinical groups. We did not perform a de novo statistical analysis on this data set but rather relied on the AUROC, sensitivity, and specificity values reported in each study.

Given the heterogeneity of metrics evaluated and definitions used to define the subclinical cohorts, it was not feasible to combine data from different studies. Rather, we evaluated the relative efficacy of the metrics reported within each study, aggregated by anterior surface, thickness, or posterior surface, and reported the best metric category (anterior, posterior, or thickness) for each article separately. This methodology allowed us to compare the best performing A, T, and P metric for each study regardless of the individual metrics utilized in that study and aggregate results based on subgroup efficacy.

RESULTS

We identified 29 articles that met our criteria and were analyzed.[17-45] There were fifteen papers within this cohort that also reported AUROC data for the final D score value from the Pentacam device.[22,25-27,29,32-36,39,41-44] We also identified ten articles that utilized only the final D score in their evaluations.[47-56] Among the 29 articles analyzed, only six studies (20.6%) used corrected distance visual acuity (CDVA) of 20/20 or better as an inclusion criteria for subclinical keratoconus.[34,38,40,42-44]

Table 1 shows the various metrics that performed best at identifying subclinical keratoconus in one or more studies organized by A, T, or P subgroup categories. Multiple studies identified the same metric/s as being most effective in their studies. The final list of articles included for analysis is shown in Table 2. The best performing anterior surface, thickness, and posterior surface metric within each article, with their corresponding AUROC, sensitivity, and specificity values, are listed as well as the same values for the overall D score for papers that included this metric. Studies

TABLE 1. Best Subcategory Metrics Reported Across Literature Cohort for Identifying Subclinical Keratoconus

Anterior Curvature	Thickness Absolute Values	Posterior Curvature
Astig	CTmin	Ks (p)
Ks	CCT	Rc (p)
Km	CCT diff	
Kf[a]		
Kmax (T)		
Asymmetry indexes	**Pachymetry indexes**	**Asymmetry indexes**
ISV	PPImax	AAI-P[b]
I-S	ARTmax	
IVA	PPIavg	
IHD	ARTavg	
SRI[a]	ARTmin	
KI	Dt	
Elevation	**Location**	**Elevation**
AE BFS (t)	Thin loc Y	BED
AE BFS (m)	Thin loc X	PE BFS (t)
AE BFTE (t)		PE BFS (m)
AE BFS loc Z[a]		Radius post. BFS[a]
		PE BFS loc Z[a]
		Db

[a]Metrics obtained specifically from Galilei dual Scheimpflug system (Ziemer Ophthalmic System AG, Port, Switzerland).
[b]Metric obtained specifically from Sirius device (C.S.O, Italy).
Anterior: AE BFS = anterior elevation best fit sphere; AE BFS loc *Z* = AE BFS in the z direction; AE BFS (t) = AE BFS at the thinnest location; AE BFS (m) = AE BFS at maximum elevation; AE BFTE (t) = AE best fit toric ellipsoid at the thinnest location; Astig = central astigmatism from the anterior corneal surface; IHD = index of height decentration; ISV = index of surface variance; I-S: inferior-superior asymmetry; IVA: index of vertical asymmetry; Kf = flat keratometry; KI = keratoconus index; Km = mean keratometry; Kmax (T) = maximum tangential keratometry; Ks = steep keratometry; SRI = surface regularity index.
Posterior: AAI-p = posterior asymmetry and asphericity index; BED = back elevation difference; BFS = best fit sphere; BFTE = best fit toric ellipsoid; Db = deviation of normality of the back elevation; Ks (p): posterior curvature-steep keratometry; PE BFS (m) = maximum posterior elevation on the best-fit sphere; PE BFS (t) = PE BFS at the thinnest location; PE BFS loc *Z* = PE BFS in the z direction; Rad Post BFS = BFS radius of curvature; Rc (p) = posterior radius of curvature.
Thickness: ART = Ambrósio relational thickness; ARTavg = average ART; ARTmax = ART maximum; ARTmin = minimum ART; CCT = corneal thickness at the apex of the cornea; CCTdiff = difference from the corneal thickness at the apex and the thinnest point; CTmin = thinnest corneal thickness; Dt = deviation of normality of corneal thinnest point at BAD; PPI = pachymetric progression index; PPIavg = average PPI; PPImax = maximum PPI; Thin loc *X* = location of the thinnest point in the X axis (horizontal); Thin loc *Y* = location of the thinnest point in the Y axis (vertical).

that used only the final D score in their analysis are listed in Table 3. Among these studies, only two (20%) used CDVA of 20/20 or better as an inclusion criteria for subclinical keratoconus.[54,55]

Table 4 shows the cumulative relative performance for anterior surface, thickness, and posterior surface metrics reported based on intrastudy comparison. Across the entire article cohort, anterior surface and thickness metrics performed best at differentiating subclinical keratoconus from normal eyes, followed by thickness metrics. Only 4/29 (13.8%) papers reported posterior metrics outperforming all other metrics. In subgroup analysis for papers reporting D scores ($n = 15$), anterior surface metrics still performed best, followed by the D score, with 4/15 papers showing equivalence between metrics (Table 4).

Figure 2 shows the cumulative performance of anterior, thickness, and posterior metrics from 2011 to 2022 grouped into four-year intervals. Anterior surface and thickness metrics outperformed posterior surface metrics during each time period.

DISCUSSION

Among the various metrics reported in the literature, posterior corneal surface metrics performed worse than anterior corneal and thickness metrics in differentiating subclinical keratoconic eyes from normal controls. When the Pentacam final D score was included in analysis, anterior surface

TABLE 2. List of Published Studies that Evaluated the Efficacy of the Posterior Corneal Surface in Identifying Subclinical Keratoconus

Yr/Ref	Anterior Best	AUC	Sens	Spec	Thickness Best	AUC	Sens	Spec	Posterior Best	AUC	Sens	Spec	D AUC	Sens	Spec
2011[17]	ISV	0.80	86	67	PPI max	0.84	84	78	PE BFS	0.79	82	67			
2012[18]	N/S	N/S	N/S	N/S	CTmin	0.95	91	89	PE BFTE	0.91	83	90			
2013[19]	Ks	0.79			Thin loc Y	0.82			PE BFS	0.92					
2013[20]	AE BFS	0.90	84	86					PE BFS	0.92	80	94			
2013[21]	Kmax (T)	0.86	84	70	PPImax	0.81	78	65	BED	0.76	74	65			
2014[22]	I-S	0.80	86	74	N/S	N/S	N/S	N/S	BED	0.74	57	88	N/S	N/S	N/S
2014[23]	Ks	0.68	96	39	CTmin	0.79	70	80	Ks	0.64	35	75			
2015[24]	AE BFS	0.77	71	82	CTmin	0.85	78	81	PE BFS	0.88	71	94			
2015[25]	I-S	0.61			ARTmin	0.74	68	73	BED	0.76	51	85	0.83	60	90
2015[26]	AE BFS	0.68	55	68	ARTmax	0.73	69	69	PE BFS	0.70	64	63	0.71	66	66
2016[27]	IVA	0.86	82	73	N/S	N/S	N/S	N/S	N/S	N/S	N/S	N/S	0.86	81	73
2016[28]	IHD	0.88	80	75	PPI	0.79	67	69	PE BFS	0.75	73	71			
2017[29]	Km	0.82	64	80	ARTmax	0.88	82	70	BED	0.60	53	80	0.67	71	60
2017[30]	Astig	0.92	85	93	CCT	0.80	72	78	Ks	0.87	88	90			
2017[31]	AE BFS	0.81	72	73	CTmin	0.70	92	47	PE BFS	0.86	93	67			
2018[32]	IVA	0.84	92	53	PPImax	0.84	97	58	PE BFS	0.89	96	76	0.90	96	74
2018[33]	AE BFS	0.94	96	70	CCTdiff	0.85	89	59	PE BFS	0.90	93	64	0.88	93	71
2018[34]	ISV	0.75	53	87	CTmin	0.74	53	87	N/S	N/S	N/S	N/S	0.75	80	67
2018[35]	IHD	0.78	53	86	ARTmax	0.89	78	84	PE BFS	0.80	78	70	0.89	55	95
2018[36]	IHD	0.79			CTmin	0.64			PE BFS	0.55			0.62		
2019[37]	ISV	0.88	80	80	CCTdiff	0.79	70	70	N/S	N/S	N/S	N/S			
2019[38]	AE BFS	0.72	52	85	Thin loc y	0.78	71	75	PE BFS	0.76	61	87			
2020[39]	ISV	0.79	77	73	ARTavg	0.91	81	91	BED	0.76	73	80	0.93	84	94
2020[40]	I-S	0.73	81	52	Thin loc y	0.76	65	78	AAI	0.83	92	58			
2020[41]	IVA	0.88	85	85	ARTmax	0.87	92	78	BED	0.74	69	67	0.95	100	90
2020[42]	AE BFS	0.76	77	65	PPImax	0.81	82	69	PE BFS	0.78	75	64	0.86	85	67
2021[43]	KI	0.85	72	84	Dt	0.74	82	53	Db	0.67	72	63	0.80	72	82
2021[44]	AE BFS	0.94	87	93	PPImax	0.75	74	71	PE BFS	0.89	87	79	0.82	71	77
2022[45]	AE BFTE	0.93	81	89	N/S	N/S	N/S	N/S	PE BFTE	0.84	60	91			

N/*S*= Not significant.

A = anterior metrics; Anterior Best= best anterior metric; AUC = area under the curve; Best overall= best metric overall, including final D score; *D* = final D score; *E* = equivalent (two metrics with similar performance); N/*E* = not evaluated; N/*R* = not reported; N/*S* = not significant; Posterior best = best posterior metric; Sens = sensitivity; Spec = specificity; *T* = Thickness metrics; Thickness best = best thickness metric.

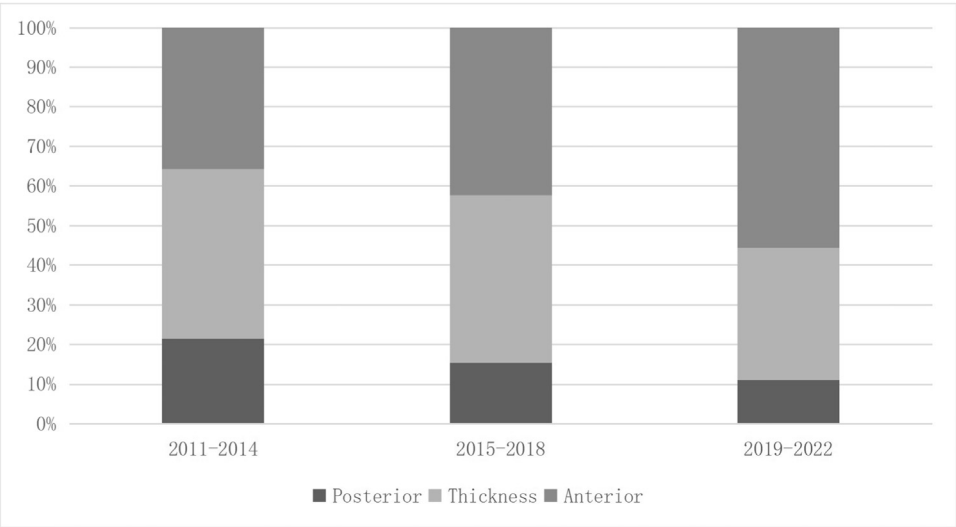

FIGURE 2. Best metric reported by article over time.

TABLE 3. List of Published Studies that Evaluated the Efficacy of the Posterior Corneal Surface in Identifying Subclinical Keratoconus by Reporting Only the Total D Score

D Score Only	AUC	Sens	Spec
2017[47]	0.84	81	72
2017[48]	0.79	65	85
2018[49]	0.75	69	79
2019[50]	0.84	68	85
2019[51]	0.81	87	66
2019[52]	0.67	61	86
2021[53]	0.68	42	93
2022[54]	0.65	74	58
2023[55]	0.66	76	57
2023[56]	0.81	89	57

TABLE 4. Best Performing Metric by Paper

	Anterior ($n = 29$)	Thickness ($n = 28$)	Posterior ($n = 29$)	D ($n = 15$)	Equivalent
Overall ($n = 29$)	11 (37.9%)	11 (39.2%)	4 (13.8%)	—	3 (10.3%)
D Subgroup ($n = 15$)	5 (33.3%)	2 (3.3%)	0 (0%)	4 (26.7%)	4 (26.7%)

metrics still performed best, while posterior surface metrics never outperformed the final D score. As these results demonstrate, there is no evidence in the peer reviewed literature that posterior elevation abnormalities must be present to diagnose subclinical keratoconus. There is no timeframe during which the posterior corneal surface demonstrated superiority at identifying subclinical disease despite early enthusiasm for this idea[57,58] (Figure 2).

• **SUBCLINICAL KERATOCONUS CLASSIFICATION:** Reported inclusion criteria for what we have termed "subclinical keratoconus" in this study varied substantially in both nomenclature and corneal morphology. The variability in use of common terminology related to keratoconus, such as forme fruste, subclinical, asymmetric, and suspect, was anticipated.[16] We found remarkable, however, the range in morphologic findings used to define the subclinical cohort. Many of the classification systems used would not exclude the inclusion of clinical keratoconus cases. Further, while the definition of subclinical is open for discussion, we feel strongly that reduced best corrected acuity should disqualify an eye or patient as being classified as subclinical. Among the 29 papers evaluated, only roughly 1 in 5 studies used CDVA as a criteria for subclinical categorization. The majority of papers (64.1%) included no corneal imaging, while only five papers (12.8%) submitted images for most/all of their subclinical cohort.[34,38,40,47,49] This was unfortunate, as it limited opportunities for further comparative analysis, since there was no way to evaluate the veracity regarding claims of topographic normalcy when the methodology listed was limited to a description such as no topographic or clinical signs of keratoconus.

While multiple metrics were evaluated across the entire study cohort (Table 1), few studies reported efficacy from all metrics, and some studies reported only a small number of metrics that were evaluated. We therefore did not feel it would be accurate to attempt to delineate best metric performance across the entire cohort or attempt to draw any conclusions regarding the relative strength of individual metrics in identifying subclinical disease.

• **POSTERIOR CORNEAL SURFACE EVALUATION FOR SUBCLINICAL KERATOCONUS:** In 2000, Tomidokoro and colleagues[57] reported changes in both anterior and posterior curvature in eyes deemed keratoconus suspects. In 2002, Rao and colleagues[58] found significantly larger anterior and posterior elevations in keratoconus suspects and proposed that "posterior corneal elevation may be the earliest sign of FFKC (forme fruste keratoconus)." The authors, however, acknowledged that "there is no conclusive direct evidence that patients with high posterior elevation are at increased risk of ectasia."[58]

In 2008, de Sanctis and colleagues[59] first formally evaluated the ability of posterior elevation to discriminate between normal eyes and eyes with subclinical KC. While posterior elevation performed well in identifying eyes with clinically manifest keratoconus, sensitivity (68%), and thus overall discriminative performance, was significantly worse in eyes with subclinical KC. The authors concluded that while "it has been suggested that an increase in posterior elevation may be the earliest sign of subclinical keratoconus, indices derived from Placido disk-based videokeratography may be more sensitive in discriminating this condition."[59]

• **PAPERS REPORTING POSTERIOR SURFACE METRICS AS BEST IDENTIFIERS:** In this analysis, 4/29 papers (13.7%) found the posterior surface to be best at identifying eyes with subclinical keratoconus.[19,31,32,40] In reviewing these studies, there were no obvious commonalities useful in identifying why their findings differed from the majority of studies. Each study was performed in a different country by different authors, and four separate Scheimpflug imaging devices were used. Two of the papers utilized custom posterior surface metrics that were and remain unavailable for clinical use.[19,40] The remaining papers did not include visual acuity criteria to differentiate clinical from subclinical keratoconus, used subclinical group inclusion criteria that would not exclude clinical keratoconus eyes, and provided no corneal imaging for review.[31,32] Xu and colleagues[31] evaluated only maximum anterior elevation, thinnest corneal thickness, and maximum posterior elevation. Huseynli and colleagues[32] evaluated 27 Scheimpflug metrics and reported multiple metrics achieving sensitivities >90% including the D score, posterior elevation, ante-

rior elevation, pachymetric progression index, and index of vertical asymmetry (IVA). None of these metrics, however, achieved 80% specificity, with most achieving specificities <58%. The authors defined subclinical KC using criteria that could lead to inclusion of definite keratoconus patients, which could explain the higher AUC in this study compared to other studies.

• **D SCORE PERFORMANCE:** In subgroup analysis, the final D score did not perform better than other metrics in identifying subclinical keratoconus, particularly as compared to metrics arising from the anterior surface. There were numerous articles that evaluated only the final D score (Table 3). While it was not feasible to compare metric efficacy across studies given the variability in subclinical keratoconus cohort classifications, based on evaluation across all cohorts, we found no evidence that the final D score reported in this series of articles performed better than other reported metrics in the full article group. Thus, based on this extensive literature review, it is clear that multiple metrics, particularly anterior and thickness metrics, remain important in the identification of subclinical keratoconus.

• **KISA% INDEX USE FOR SUBCLINICAL KERATOCONUS CLASSIFICATION:** There were numerous studies that incorporated the KISA% index[46] in some form for subclinical keratoconus classification. Among papers using only the multimetric D score, seven (70%) used the KISA index <60 as part of their classification of subclinical keratoconus. Numerous articles have highlighted the lack of sensitivity of the KISA% index to identify manifest keratoconus[48,60-63] and have demonstrated that neither KISA% index <60 in isolation nor combining KISA% <60 with IS value <1.4 excludes clinical keratoconus cases from being classified as subclinical.[64] Since this classification system cannot exclude clinical keratoconic disease as being classified as normal topography, we do not recommend its use for subclinical disease classification.

• **LIMITATIONS:** There are limitations to this work, including its retrospective nature and reliance on database search. It is possible that relevant articles were missed; however, given the number of articles reviewed, there would need to be a significant number of missed articles to alter the conclusions presented herein. The aforementioned variability in subclinical cohort nomenclature and morphologic features used for inclusion or exclusion criteria for classification complicated data aggregation to the point we felt we risked generating inaccuracies if further data aggregation were attempted. The lack of adequate consistency in terminology and criteria used for keratoconus classification not only limits the conclusions reachable through our study but also significantly impact ongoing and future research in the field. Finally, all of the studies evaluated relied on purely morphologic metrics for fellow eyes of patients with clinical keratoconus in the contralateral eye without data to demonstrate disease progression.

CONCLUSIONS

In conclusion, posterior surface metrics performed worse than anterior surface and total thickness metrics in identifying subclinical keratoconus. There is no evidence to support the claim that posterior elevation abnormalities must be present to diagnose subclinical keratoconus and significant evidence that the evaluation of anterior surface asymmetry and thickness remains critical in the detection of subclinical keratoconus.

CREDIT AUTHORSHIP CONTRIBUTION STATEMENT

J. Bradley Randleman: Writing – review & editing, Writing – original draft, Supervision, Methodology, Funding acquisition, Formal analysis, Data curation, Conceptualization. **Bianca N. Susanna:** Writing – original draft, Formal analysis, Data curation. **Bassel Hammoud:** Writing – original draft, Methodology, Formal analysis, Data curation. **Barbara A.L. Dutra:** Writing – original draft, Formal analysis, Data curation. **Giuliano Scarcelli:** Writing – review & editing, Writing – original draft, Formal analysis. **Marcony R. Santhiago:** Writing – review & editing, Writing – original draft, Methodology. **William J. Dupps Jr:** Writing – review & editing, Writing – original draft, Methodology. **Douglas D. Koch:** Writing – review & editing, Writing – original draft, Methodology.

Funding/Support: Supported in part by an unrestricted departmental grant to the Cole Eye Institute, Cleveland Clinic, from Research to Prevent Blindness (New York, NY, USA) Cleveland Clinic, from Research to Prevent Blindness (New York, NY, USA), NIH R01EY028666, NIH R01EY032537, NIH R01EY028667, NIH R01EY032633. **Financial Disclosures:** *JBR, BNS, BH, BLD and MRS* have no financial interests to disclose. *GS* is consultant for Intelon Optics and CellSense and has intellectual property unrelated to this work through Massachusetts General Hospital and the University of Maryland. *WJD* is on medical advisory boards for Alcon and has intellectual property unrelated to this work through Cleveland Clinic Innovations. *DDK is* a consultant for Alcon Laboratories, Bausch & Lomb, Carl Zeiss Meditec, and Johnson & Johnson Vision. The authors declare that they have no known competing financial interests or personal relationships that could have appeared to influence the work reported in this paper.

REFERENCES

1. Roberts CJ, Dupps Jr WJ. Biomechanics of corneal ectasia and biomechanical treatments. *J Cataract Refract Surg*. 2014;40(6):991–998.
2. Randleman JB, Khandelwal SS, Hafezi F. Corneal cross-linking. *Surv Ophthalmol*. 2015;60(6):509–523.
3. Randleman JB, Russell B, Ward MA, et al. Risk factors and prognosis for corneal ectasia after LASIK. *Ophthalmology*. 2003;110(2):267–275.
4. Randleman JB, Woodward M, Lynn MJ, Stulting RD. Risk assessment for ectasia after corneal refractive surgery. *Ophthalmology*. 2008;115(1):37–50.
5. Holden BA, Fricke TR, Wilson DA, et al. Global prevalence of myopia and high myopia and temporal trends from 2000 through 2050. *Ophthalmology*. 2016;123(5):1036–1042.
6. Godefrooij DA, de Wit GA, Uiterwaal CS, et al. Age-specific incidence and prevalence of keratoconus: a nationwide registration study. *Am J Ophthalmol*. 2017;175:169–172.
7. Torres Netto EA, Al-Otaibi WM, Hafezi NL, et al. Prevalence of keratoconus in paediatric patients in Riyadh, Saudi Arabia. *Br J Ophthalmol*. 2018;102(10):1436–1441.
8. Chan E, Chong EW, Lee SS, et al. Incidence and prevalence of keratoconus based on Scheimpflug imaging. *Ophthalmology*. 2023;130(4):445–448.
9. Gomes JA, Tan D, Rapuano CJ, et al. Global consensus on keratoconus and ectatic diseases. *Cornea*. 2015;34(4):359–369.
10. Randleman JB, Dupps Jr WJ, Santhiago MR, et al. Screening for keratoconus and related ectatic corneal disorders. *Cornea*. 2015;34(8):e20–e22.
11. Gomes JA, Rapuano CJ, Belin MW, Ambrósio Jr R. Global consensus on keratoconus diagnosis. *Cornea*. 2015;34(12):e38–e39.
12. Saad A, Gatinel D. Screening for keratoconus: lack of a scientific base regarding the global consensus? *Cornea*. 2015;34(11):e33–e34.
13. Moshirfar M, Motlagh MN, Murri MS, et al. Galilei corneal tomography for screening of refractive surgery candidates: a review of the literature, part II. *Med Hypothesis Discov Innov Ophthalmol*. 2019;8(3):204–218.
14. Motlagh MN, Moshirfar M, Murri MS, et al. Pentacam® corneal tomography for screening of refractive surgery candidates: a review of the literature. *Part I. Med Hypothesis Discov Innov Ophthalmol*. 2019;8(3):177–203.
15. Kuo AN, Cortina MS, Greiner MA, et al. Advanced corneal imaging in keratoconus: a report by the American Academy of Ophthalmology. *Ophthalmology*. 2024;131(1):107–121.
16. Henriquez MA, Hadid M, Izquierdo Jr L. A systematic review of subclinical keratoconus and forme fruste keratoconus. *J Refract Surg*. 2020;36(4):270–279.
17. Uçakhan Ö, Cetinkor V, Özkan M, Kanpolat A. Evaluation of Scheimpflug imaging parameters in subclinical keratoconus, keratoconus, and normal eyes. *J Cataract Refract Surg*. 2011;37(6):1116–1124.
18. Kozobolis V, Sideroudi H, Giarmoukakis A, et al. Corneal biomechanical properties and anterior segment parameters in forme fruste keratoconus. *Eur J Ophthalmol*. 2012;22(6):920–930.
19. Fukuda S, Beheregaray S, Hoshi S, et al. Comparison of three--dimensional optical coherence tomography and combining a rotating Scheimpflug camera with a Placido topography system for forme fruste keratoconus diagnosis. *Br J Ophthalmol*. 2013;97(12):1554–1559.
20. Jafarinasab MR, Feizi S, Karimian F, Hasanpour H. Evaluation of corneal elevation in eyes with subclinical keratoconus and keratoconus using Galilei double scheimpflug analyzer. *Eur J Ophthalmol*. 2013;23(3):377–384.
21. Muftuoglu O, Ayar O, Ozulken K, et al. Posterior corneal elevation and back difference corneal elevation in diagnosing forme fruste keratoconus in the fellow eyes of unilateral keratoconus patients. *J Cataract Refract Surg*. 2013;39(9):1348–1357.
22. Bae GH, Kim JR, Kim CH, et al. Corneal topographic and tomographic analysis of fellow eyes in unilateral keratoconus patients using Pentacam. *Am J Ophthalmol*. 2014;157(1):103-9.e1.
23. Reddy JC, Rapuano CJ, Cater JR, et al. Comparative evaluation of dual Scheimpflug imaging parameters in keratoconus, early keratoconus, and normal eyes. *J Cataract Refract Surg*. 2014;40(4):582–592.
24. Du XL, Chen M, Xie LX. Correlation of basic indicators with stages of keratoconus assessed by Pentacam tomography. *Int J Ophthalmol*. 2015;8(6):1136–1140.
25. Muftuoglu O, Ayar O, Hurmeric V, et al. Comparison of multimetric D index with keratometric, pachymetric, and posterior elevation parameters in diagnosing subclinical keratoconus in fellow eyes of asymmetric keratoconus patients. *J Cataract Refract Surg*. 2015;41(3):557–565.
26. Steinberg J, Aubke-Schultz S, Frings A, et al. Correlation of the KISA% index and Scheimpflug tomography in 'normal', 'subclinical', 'keratoconus-suspect' and 'clinically manifest' keratoconus eyes. *Acta Ophthalmol*. 2015;93(3):e199–e207.
27. Hashemi H, Beiranvand A, Yekta A, et al. Pentacam top indices for diagnosing subclinical and definite keratoconus. *J Curr Ophthalmol*. 2016;28(1):21–26.
28. Kovács I, Miháltz K, Kránitz K, et al. Accuracy of machine learning classifiers using bilateral data from a Scheimpflug camera for identifying eyes with preclinical signs of keratoconus. *J Cataract Refract Surg*. 2016;42(2):275–283.
29. Awad EA, Abou Samra WA, Torky MA, El-Kannishy AM. Objective and subjective diagnostic parameters in the fellow eye of unilateral keratoconus. *BMC Ophthalmol*. 2017;17(1):186.
30. Naderan M, Rajabi MT, Zarrinbakhsh P. Intereye asymmetry in bilateral keratoconus, keratoconus suspect and normal eyes and its relationship with disease severity. *Br J Ophthalmol*. 2017;101(11):1475–1482.
31. Xu Z, Li W, Jiang J, et al. Characteristic of entire corneal topography and tomography for the detection of sub-clinical keratoconus with Zernike polynomials using Pentacam. *Sci Rep*. 2017;7(1):16486.
32. Huseynli S, Abdulaliyeva F. Evaluation of Scheimpflug tomography parameters in subclinical keratoconus, clinical keratoconus and normal Caucasian eyes. *Turk J Ophthalmol*. 2018;48(3):99–108.
33. Huseynli S, Salgado-Borges J, Alio JL. Comparative evaluation of Scheimpflug tomography parameters between thin non-keratoconic, subclinical keratoconic, and mild keratoconic corneas. *Eur J Ophthalmol*. 2018;28(5):521–534.
34. Hwang ES, Perez-Straziota CE, Kim SW, et al. Distinguishing highly asymmetric keratoconus eyes using combined

scheimpflug and spectral-domain OCT analysis. *Ophthalmology*. 2018;125(12):1862–1871.
35. Lopes BT, Ramos IC, Salomão MQ, et al. Enhanced tomographic assessment to detect corneal ectasia based on artificial intelligence. *Am J Ophthalmol*. 2018;195:223–232.
36. Shajari M, Jaffary I, Herrmann K, et al. Early tomographic changes in the eyes of patients with keratoconus. *J Refract Surg*. 2018;34(4):254–259.
37. Değirmenci C, Palamar M, İsmayilova N, et al. Topographic evaluation of unilateral keratoconus patients. *Turk J Ophthalmol*. 2019;49(3):117–122.
38. Golan O, Piccinini AL, Hwang ES, et al. Distinguishing highly asymmetric keratoconus eyes using dual scheimpflug/placido analysis. *Am J Ophthalmol*. 2019;201:46–53.
39. Atalay E, Özalp O, Erol MA, et al. A combined biomechanical and tomographic model for identifying cases of subclinical keratoconus. *Cornea*. 2020;39(4):461–467.
40. Golan O, Levinger S, Barequet IS, et al. Differentiating highly asymmetric keratoconus eyes using a combined Scheimpflug/Placido device. *J Cataract Refract Surg*. 2020;46(12):1588–1595.
41. Itoi M, Kitazawa K, Yokota I, et al. Anterior and posterior ratio of corneal surface areas: a novel index for detecting early stage keratoconus. *PLoS One*. 2020;15(4):e0231074.
42. Koc M, Tekin K, Kiziltoprak H, et al. Topometric and tomographic evaluation of subclinical keratoconus. *Ophthalmic Epidemiol*. 2020;27(4):289–297.
43. Donoso R, Rodríguez Á, Esteffan K, et al. Analysis of OPD-scan and pentacam parameters for early keratoconus detection. *Am J Ophthalmol*. 2021;226:235–242.
44. Ozkan HH, Koc M, Kiziltoprak H, et al. Evaluation of topographic, tomographic, topometric, densitometric, and aberrometric features of cornea with pentacam HR system in subclinical keratoconus. *Int Ophthalmol*. 2021;41(5):1729–1741.
45. Kim KY, Lee S, Jeon YJ, Min JS. Anterior segment characteristics in normal and keratoconus eyes evaluated with a new type of swept-source optical coherence tomography. *PLoS One*. 2022;17(9):e0274071.
46. Rabinowitz YS, Rasheed K. KISA% index: a quantitative videokeratography algorithm embodying minimal topographic criteria for diagnosing keratoconus. *J Cataract Refract Surg*. 1999;25(10):1327–1335.
47. Ambrósio Jr R, Lopes BT, Faria-Correia F, et al. Integration of Scheimpflug-based corneal tomography and biomechanical assessments for enhancing ectasia detection. *J Refract Surg*. 2017;33(7):434–443.
48. Pahuja N, Shroff R, Pahanpate P, et al. Application of high resolution OCT to evaluate irregularity of Bowman's layer in asymmetric keratoconus. *J Biophotonics*. 2017;10(5):701–707.
49. Steinberg J, Siebert M, Katz T, et al. Tomographic and biomechanical scheimpflug imaging for keratoconus characterization: a validation of current indices. *J Refract Surg*. 2018;34(12):840–847.
50. Ferreira-Mendes J, Lopes BT, Faria-Correia F, et al. Enhanced ectasia detection using corneal tomography and biomechanics. *Am J Ophthalmol*. 2019;197:7–16.
51. Kataria P, Padmanabhan P, Gopalakrishnan A, et al. Accuracy of Scheimpflug-derived corneal biomechanical and tomographic indices for detecting subclinical and mild keratectasia in a South Asian population. *J Cataract Refract Surg*. 2019;45(3):328–336.
52. Koh S, Ambrósio Jr R, Inoue R, et al. Detection of subclinical corneal ectasia using corneal tomographic and biomechanical assessments in a Japanese population. *J Refract Surg*. 2019;35(6):383–390.
53. Guo LL, Tian L, Cao K, et al. Comparison of the morphological and biomechanical characteristics of keratoconus, forme fruste keratoconus, and normal corneas. *Semin Ophthalmol*. 2021;36(8):671–678.
54. Lu NJ, Elsheikh A, Rozema JJ, et al. Combining spectral-domain OCT and air-puff tonometry analysis to diagnose keratoconus. *J Refract Surg*. 2022;38(6):374–380.
55. Lu NJ, Koppen C, Hafezi F, et al. Combinations of Scheimpflug tomography, ocular coherence tomography and air-puff tonometry improve the detection of keratoconus. *Cont Lens Anterior Eye*. 2023;46(3):101840.
56. Wallace HB, Vellara HR, Gokul A, et al. Comparison of ectasia detection in early keratoconus using Scheimpflug-based corneal tomography and biomechanical assessments. *Cornea*. 2023;42(12):1528–1535.
57. Tomidokoro A, Oshika T, Amano S, et al. Changes in anterior and posterior corneal curvatures in keratoconus. *Ophthalmology*. 2000;107(7):1328–1332.
58. Rao SN, Raviv T, Majmudar PA, Epstein RJ. Role of Orbscan II in screening keratoconus suspects before refractive corneal surgery. *Ophthalmology*. 2002;109(9):1642–1646.
59. de Sanctis U, Loiacono C, Richiardi L, et al. Sensitivity and specificity of posterior corneal elevation measured by Pentacam in discriminating keratoconus/subclinical keratoconus. *Ophthalmology*. 2008;115(9):1534–1539.
60. Li Y, Meisler DM, Tang M, et al. Keratoconus diagnosis with optical coherence tomography pachymetry mapping. *Ophthalmology*. 2008;115(12):2159–2166.
61. Li X, Yang H, Rabinowitz YS. Keratoconus: classification scheme based on videokeratography and clinical signs. *J Cataract Refract Surg*. 2009;35(9):1597–1603.
62. Twa MD, Parthasarathy S, Roberts C, et al. Automated decision tree classification of corneal shape. *Optom Vis Sci*. 2005;82(12):1038–1046.
63. Bühren J, Kook D, Kohnen T. Suitability of various topographic corneal parameters for diagnosis of early keratoconus]. *Ophthalmologe*. 2012;109(1):37–44.
64. Hammoud B, Dupps Jr WJ, Scarcelli G, Randleman JB. Misclassification of eyes with progressive keratoconus using the KISA% index. *J Refract Surg*. 2024;40(9):e614–ee24.