1. A 42-year-old woman comes to the physician for evaluation of persistently increased blood pressures. At her last two office visits during the past 3 months, her blood pressure has ranged between 150–170/105–115 mm Hg. During this period, she has had occasional headaches. In addition, she has had an increased urine output over the past 6 weeks that she attributes to a diet high in sodium. She is otherwise healthy and takes no medications. Her blood pressure today is 168/115 mm Hg, pulse is 68/min, and respirations are 14/min. Funduscopic examination shows mild arteriovenous nicking. The point of maximal impulse is not displaced. There is no edema, abdominal bruits, or masses. Serum studies show:

Na^+	144 mEq/L
Cl^-	90 mEq/L
K^+	2.9 mEq/L
HCO_3^-	32 mEq/L
Urea nitrogen	20 mg/dL
Creatinine	1.2 mg/dL

Which of the following is the most likely underlying cause of this patient's hypertension?

- A) Autonomous production of aldosterone
- B) Catecholamine-producing tumor
- C) Decreased arterial distensibility caused by atherosclerosis
- D) Excess production of atrial natriuretic peptide
- E) Juxtaglomerular cell hypertrophy and sclerosis

2. A 32-year-old woman who is HIV positive has a CD4+ T-lymphocyte count of 800/mm^3 (Normal≥500). Her health maintenance regimen should include immunization against which of the following pathogens?

- A) *Haemophilus influenzae* type b
- B) Hepatitis A
- C) Influenza virus
- D) *Neisseria meningitidis*
- E) *Streptococcus pyogenes* (group A)

3. A 2-year-old boy is brought to the physician because of fever and cough for 2 days. He had *Streptococcus pneumoniae* meningitis at the age of 1 year, *S. pneumoniae* bacteremia at the age of 18 months, and pneumonia at the age of 22 months. Two maternal uncles died before the age of 2 years from "infection." His temperature is 39.8°C (103.6°F), pulse is 150/min, and respirations are 60/min. Examination shows subcostal retractions on inspiration. Laboratory studies show:

Hemoglobin	10 g/dL
Leukocyte count	36,000/mm³
Segmented neutrophils	70%
Bands	20%
Lymphocytes	8%
Monocytes	2%
Platelet count	240,000/mm³
Serum	
IgA	<5 mg/dL
IgG	30 mg/dL
IgM	<5 mg/dL

An x-ray of the chest shows an infiltrate in the left upper lobe. Which of the following is the most appropriate next step in management?

- A) Reexamination in 12 weeks
- B) Prednisone therapy only
- C) Prednisone, vincristine, doxorubicin, asparaginase, and methotrexate therapy
- D) Zidovudine (AZT), lamivudine (3TC), and ritonavir therapy
- E) Intravenous immunoglobulin infusion
- F) Bone marrow transplantation
- G) Thymus transplantation

4. A 19-year-old man is brought to the emergency department 45 minutes after sustaining a single, large stab wound to the right upper quadrant of the abdomen. He is obtunded. His blood pressure is 60/palpable mm Hg, and pulse is 148/min. Breath sounds are equal bilaterally. Examination shows a 4-cm laceration in the right upper quadrant in the midclavicular line. The abdomen is distended. Which of the following is the most appropriate next step in management?

- A) X-rays of the abdomen and pelvis
- B) Angiography
- C) Contrast study of the wound tract
- D) CT scan of the abdomen
- E) CT scan of the chest
- F) Laparoscopy
- G) Peritoneal lavage
- H) Laparotomy
- I) Local wound exploration

5. A 17-year-old boy is brought to the emergency department by his parents because of bizarre behavior for 6 hours. Last night he was out with friends, and since returning, he has been confused and has "trashed" his room. His blood pressure is 165/95 mm Hg. He is hypervigilant, has little spontaneous speech, and is disoriented to place and time. He appears catatonic but abruptly becomes assaultive two times and needs to be restrained. Which of the following is the most likely substance taken?

- A) Cocaine
- B) Ecstasy
- C) LSD
- D) Methaqualone
- E) PCP

6. A previously healthy 67-year-old man is admitted to the hospital because of lethargy, confusion, muscle cramps, and decreased appetite for 7 days. He appears ill. His temperature is 37°C (98.6°F), blood pressure is 120/70 mm Hg, pulse is 98/min, and respirations are 20/min. Breath sounds are diminished at the right lung base. Neurologic examination shows no abnormalities except for lethargy. Serum studies show:

Na^+	114 mEq/L
K^+	4.3 mEq/L
Creatinine	1 mg/dL
Thyroid-stimulating hormone	4.1 μU/mL

An x-ray of the chest shows a 2-cm nodule in the right lower lobe and mediastinal adenopathy. A biopsy specimen of the nodule is most likely to show which of the following?

- A) Adenocarcinoma
- B) Clear cell carcinoma
- C) Mesothelioma
- D) Small cell carcinoma
- E) Squamous cell carcinoma

7. A previously healthy 62-year-old man comes to the emergency department because of abdominal pain for 48 hours. His temperature is 38.6°C (101.5°F), blood pressure is 130/80 mm Hg, pulse is 110/min, and respirations are 15/min. Abdominal examination shows diffuse left lower quadrant tenderness with no peritoneal signs. Rectal examination shows no abnormalities; test of the stool for occult blood is negative. His leukocyte count is 14,700/mm^3. Which of the following is the most appropriate next step in diagnosis?

- A) Barium enema
- B) CT scan of the abdomen
- C) Colonoscopy
- D) Cystoscopy
- E) Exploratory laparotomy

8. A 37-year-old woman, gravida 2, para 1, at 12 weeks' gestation comes to the physician for her first prenatal visit. She has hypertension treated with a β-adrenergic blocking agent. Her first pregnancy was complicated by premature rupture of membranes at 26 weeks' gestation, followed rapidly by a preterm vaginal delivery. She is a carrier of the sickle cell trait. She has a history of an appendectomy at the age of 14 years. She does not smoke cigarettes, drink alcohol, or use illicit drugs. Her blood pressure is 130/82 mm Hg; other vital signs are within normal limits. Examination shows a uterus consistent in size with a 12-week gestation. Which of the following is the greatest risk factor for preterm delivery in this patient?

- A) History of an abdominal operation
- B) Maternal age
- C) Maternal hypertension
- D) Previous preterm delivery
- E) Sickle cell status

9. A newborn is in severe respiratory distress immediately following delivery. She was born at 35 weeks' gestation to a 35-year-old woman, gravida 2, para 1, aborta 1, who did not receive prenatal care. The newborn's pulse is 60/min, and respirations are irregular and labored. Examination shows pallor with perioral cyanosis, anasarca, hepatosplenomegaly, and scattered petechiae. Cord blood hemoglobin is 4 g/dL, and reticulocyte count is 18%. A direct antiglobulin (Coombs') test is positive. Which of the following sets of blood groups is most likely in the mother and her newborn?

	Mother	Newborn
○ A)	A, Rh-positive	O, Rh-positive
○ B)	A, Rh-positive	O, Rh-negative
○ C)	A, Rh-negative	O, Rh-negative
○ D)	O, Rh-positive	O, Rh-negative
○ E)	O, Rh-negative	O, Rh-positive

10. A 32-year-old man receiving intensive chemotherapy for Hodgkin's disease has a temperature of 39°C (102.2°F). His respirations are 40/min. Widespread crackles are heard in all lung fields. An x-ray of the chest shows a diffuse alveolar and interstitial pattern. Which of the following is the most likely causal organism?

- A) *Aspergillus* species
- B) *Candida albicans*
- C) *Coccidioides immitis*
- D) *Pneumocystis jiroveci* (formerly *P. carinii*)
- E) *Streptococcus pneumoniae*

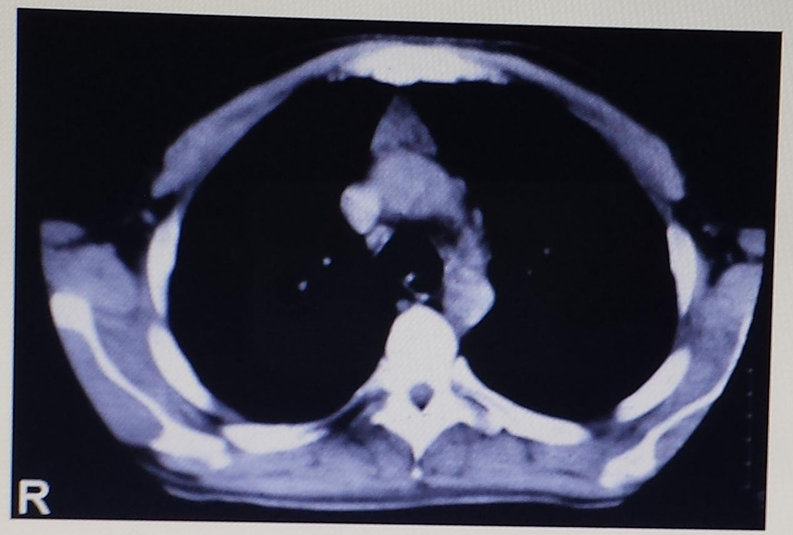

11. A 67-year-old man comes to the physician because of a 6-month history of double vision, slurred speech, and difficulty swallowing liquids. Initially, his symptoms were intermittent but now occur daily and are worse at the end of the day. Over the past week, he has had shortness of breath with exertion. He has pernicious anemia treated with monthly vitamin B_{12} (cyanocobalamin) injections and autoimmune thyroid disease currently treated with thyroid replacement therapy. Examination shows bilateral ptosis and disconjugate gaze. There is bilateral facial weakness and hypernasal speech. The tongue is weak, and the gag reflex is reduced. Muscle strength is 4/5 in the proximal muscles of the upper and lower extremities. Deep tendon reflexes are 2+ diffusely. Babinski's sign is absent. Sensory examination shows no abnormalities. A CT scan of the chest is shown. Which of the following is the most likely diagnosis of this patient's intrathoracic lesion?

- A) Aspiration pneumonia
- B) Bronchogenic carcinoma
- C) Lung metastasis
- D) Sarcoidosis
- E) Thymoma
- F) Thyroid carcinoma

12. A 67-year-old man has had shortness of breath on exertion for 3 months; he has had an 11.3-kg (25-lb) weight loss during this period. He has smoked two packs of cigarettes daily for 25 years. He appears chronically ill. Examination shows decreased breath sounds on the left; heart sounds are normal. An x-ray of the chest shows a large left-sided pleural effusion. Which of the following is the most appropriate next step in diagnosis?

- A) Bronchoscopy
- B) Thoracoscopy
- C) Closed pleural biopsy
- D) Open pleural biopsy
- E) Thoracentesis

13. The genetic disease institute at a university hospital has developed a rapid screening test for a serious but treatable inherited metabolic disorder. Although this disorder is predominantly found in a particular ethnic group, it is also found sporadically throughout the entire population. The screening test has a sensitivity of 95% and a specificity of 90%. When used in an ethnically prescreened population where the prevalence of this disorder is 30%, the positive predictive value is 80% and the negative predictive value is 96%. The institute proposes to use this screening test on the general population where the prevalence of this disease is 0.1%. Which of the following is the most likely result of this screening program?

- A) Negative predictive value decreases
- B) Positive predictive value decreases
- C) Sensitivity decreases
- D) Specificity decreases

14. A 16-year-old girl is brought to the physician because of episodes of palpitations over the past 6 months. The episodes occur when she runs or plays basketball. She is otherwise asymptomatic. Her blood pressure is 124/46 mm Hg, pulse is 78/min, and respirations are 18/min. She weighs 55 kg (121 lb) and is 180 cm (71 in) tall. Her arm span is 188 cm (74 in), and the upper segment to lower segment ratio is 0.85. Her fingers appear long and are hyperextensible. A grade 4/6, early diastolic murmur is heard along the upper and middle left sternal border with radiation to the apex. Peripheral pulses are bounding. Which of the following is the most likely cause of these findings?

- A) Aortic incompetence
- B) Aortic stenosis
- C) Mitral incompetence
- D) Mitral stenosis
- E) Pulmonary incompetence
- F) Pulmonary stenosis
- G) Tricuspid incompetence
- H) Tricuspid stenosis

15. A previously healthy 16-year-old high school wrestler comes to the physician because of a rash on his forearms and the back of his legs for 1 week. He is allergic to pollen and dust. Examination shows patches of erythema with mild lichenification over the antecubital and popliteal fossae. There are clusters of painful umbilicated vesicles at sites of active skin inflammation. Which of the following is the most likely diagnosis?

- A) Eczema herpeticum
- B) Herpes zoster
- C) Keratosis pilaris
- D) Lichen planus
- E) Pityriasis rosea

16. Three days after being hospitalized for treatment of a hip fracture sustained in a fall, a 62-year-old woman becomes acutely short of breath and coughs up a small amount of blood-tinged sputum. She appears anxious. Her blood pressure is 110/70 mm Hg, pulse is 110/min, and respirations are 24/min. Examination shows no other abnormalities. Arterial blood gas analysis on 40% oxygen by face mask shows:

pH	7.40
Pco_2	38 mm Hg
Po_2	70 mm Hg

Ventilation-perfusion lung scans show multiple segmental areas of mismatch on the right. Which of the following is the most appropriate next step in management?

- A) Pulmonary angiography
- B) Dopamine therapy
- C) Heparin therapy
- D) Urokinase therapy
- E) Intubation

17. A 28-year-old man is brought to the emergency department by police because of severe pain in the right lower quadrant of the abdomen for 36 hours. He has been incarcerated in the county jail, and his court hearing is scheduled in 12 hours. He takes no medications. Abdominal examination shows no rebound. Complete blood count, liver tests, and erythrocyte sedimentation rate are within normal limits. An x-ray of the abdomen shows a normal gas pattern. Test of the stool for occult blood is negative. Which of the following is the most likely diagnosis?

- A) Adjustment disorder
- B) Conversion disorder
- C) Depressive disorder not otherwise specified
- D) Factitious disorder
- E) Hypochondriasis
- F) Malingering
- G) Somatization disorder

18. A 52-year-old man comes to the physician for a routine health maintenance examination. He has smoked one pack of cigarettes daily for 20 years and does not drink alcohol. He has a sedentary lifestyle and requests advice about beginning a regular exercise program. His father died of a myocardial infarction at the age of 62 years. His 77-year-old mother and 51-year-old sister are healthy. He is 178 cm (5 ft 10 in) tall and weighs 80 kg (176 lb); BMI is 25 kg/m². His pulse is 80/min, respirations are 12/min, and blood pressure is 140/90 mm Hg. Examination shows no other abnormalities. In addition to measurement of serum cholesterol concentration, which of the following is the most appropriate next step prior to starting this patient on an exercise program?

- A) Complete blood count
- B) Measurement of serum homocysteine concentration
- C) Exercise stress test
- D) Spirometry
- E) Cardiac catheterization

19. A 6-month-old girl is brought to the physician for a routine health maintenance examination. She was born with a lumbosacral myelomeningocele which was successfully repaired at 2 days of age. The anterior fontanelle is 6 x 8 cm and bulging, and the posterior fontanelle is 3 x 4 cm and bulging. She has severe motor and sensory deficits involving both lower extremities. A head growth chart shows the following values:

Age	Head circumference (cm)
Birth	34.2
1 month	36.6
2 months	38
4 months	44
6 months	47

Which of the following is the most likely cause of increased intracranial pressure?

- A) Acute cerebral edema
- B) Decreased absorption of cerebrospinal fluid
- C) Dilation of cerebral arteries
- D) Intracranial mass lesion
- E) Obstruction of lateral sinus
- F) Obstruction of superior vena cava
- G) Obstruction of cerebrospinal fluid flow
- H) Overproduction of cerebrospinal fluid

20. A 47-year-old man comes to the physician because of fever and chills for 1 day. He has a 20-year history of alcoholism and cirrhosis of the liver. One month ago, he underwent evacuation of a subdural hematoma. His postoperative course was complicated by generalized tonic-clonic seizures; he has been receiving carbamazepine therapy since then. He continues to drink 12 beers daily. His temperature is 38.9°C (102°F), and blood pressure is 120/80 mm Hg. Examination shows scleral icterus, ascites, and splenomegaly. Laboratory studies show:

Hematocrit	39%
Mean corpuscular volume	102 μm³
Leukocyte count	1200/mm³
Segmented neutrophils	6%
Eosinophils	1%
Basophils	1%
Lymphocytes	80%
Monocytes	12%
Platelet count	210,000/mm³

Which of the following is the most likely cause of this patient's decreased leukocyte count?

- A) Carbamazepine therapy
- B) Folic acid deficiency
- C) Hypersplenism
- D) Sepsis
- E) Suppression of bone marrow by alcohol

21. A 32-year-old woman comes to the physician because of vaginal discharge for 2 weeks. She has been sexually active with one female partner for 5 years. Her last Pap smear was 6 years ago when she was sexually active with a male partner. She has not used illicit drugs or alcohol. Examination shows a grayish vaginal discharge with a pH greater than 4.5. A wet mount preparation of the vaginal discharge is most likely to show which of the following?

- A) Budding yeast
- B) Clue cells
- C) Ferning
- D) Leukocytes in sheets
- E) *Trichomonas vaginalis*

The response options for the next **2** items are the same. Select one answer for each item in the set.

For each patient with weakness, select the most appropriate test to establish the cause of the condition.

- A) Brain stem auditory evoked potentials
- B) Carotid ultrasonography
- C) Chromosomal analysis for trinucleotide repeat
- D) EEG
- E) Electromyography and nerve conduction studies
- F) MRI of the spine
- G) Muscle biopsy
- H) Repetitive nerve stimulation
- I) Somatosensory evoked potentials
- J) SPECT scan
- K) Temporal artery biopsy
- L) Visual evoked potentials

22. A 57-year-old man is brought to the emergency department 6 hours after the onset of weakness of his right face, arm, and leg. Three days ago, he had an episode of sudden visual loss in his left eye that he describes as "a shade coming down." The episode resolved completely within 10 minutes. He has hypertension and type 2 diabetes mellitus, both poorly controlled with lisinopril and glyburide. Examination shows expressive aphasia and right lower facial droop. There is moderate weakness on the right, worse in the upper extremity than the lower extremity. Deep tendon reflexes are 3+ in the right extremities and 2+ in the left extremities. Babinski's sign is present on the right. Sensory examination shows no abnormalities.

For each patient with weakness, select the most appropriate test to establish the cause of the condition.

- A) Brain stem auditory evoked potentials
- B) Carotid ultrasonography
- C) Chromosomal analysis for trinucleotide repeat
- D) EEG
- E) Electromyography and nerve conduction studies
- F) MRI of the spine
- G) Muscle biopsy
- H) Repetitive nerve stimulation
- I) Somatosensory evoked potentials
- J) SPECT scan
- K) Temporal artery biopsy
- L) Visual evoked potentials

23. A previously healthy 27-year-old woman is brought to the emergency department because of a 2-day history of weakness of her arms and legs and numbness of her hands and feet and a 4-hour history of mild shortness of breath while supine. The weakness began in her feet and has progressed to involve the hands. She describes a sensation of "electrical shocks" extending from the buttocks to the feet. Today, she tripped and fell several times and was unable to button clothes or hold utensils. Three weeks ago, she had a mild upper gastrointestinal illness that resolved within 5 days. Her respirations are 20/min and shallow. There is mild facial weakness; cranial nerves are otherwise intact. Muscle strength in the upper and lower extremities is 4/5 proximally and 2/5 distally. There is areflexia. Babinski's sign is absent bilaterally. Sensation to vibration is slightly decreased at the fingers and toes.

24. A 72-year-old man with hypertension has had increasingly severe back pain over the past 2 months. He had a myocardial infarction 4 years ago. He has marked tenderness over T11, T12, L1, and L2. An x-ray of the lumbosacral spine shows osteoblastic lesions in these vertebrae. Which of the following is the most likely diagnosis?

- A) Abdominal aneurysm
- B) Fibrosarcoma
- C) Metastatic prostate carcinoma
- D) Multiple myeloma
- E) Osteosarcoma

25. A 47-year-old man is admitted to the hospital after threatening to harm a radio announcer he believed was broadcasting his thoughts. Over the past 20 years, he has had multiple psychiatric hospitalizations for threatening people who he believed were plotting against him, trying to control his mind, or causing him to hear voices by implanting devices in his head. Past symptoms improved with neuroleptic therapy; after discharge, he discontinued the medication and his symptoms worsened. Which of the following is the most appropriate pharmacotherapy to decrease this patient's risk for future hospitalization?

- A) Clozapine
- B) Fluphenazine hydrochloride
- C) Haloperidol decanoate
- D) Risperidone
- E) Trifluoperazine hydrochloride

26. A 38-year-old woman, gravida 2, para 1, at 38 weeks' gestation has had no fetal movement for 36 hours. Her prenatal course, prenatal tests, and fetal growth have been normal. Fetal heart tones are heard by Doppler. Which of the following is the most appropriate next step in management?

- A) Routine prenatal visit in 1 week
- B) Maternal hydration
- C) Nonstress test
- D) Immediate induction of labor
- E) Amniocentesis

27. A 3-year-old boy is brought for a follow-up examination. He just completed a 10-day course of amoxicillin that has not resolved his right ear pain. He appears irritable. His temperature is 38.9°C (102°F). Examination shows downward and lateral displacement of the right auricle with tenderness to palpation of the posterior auricular area; his neck is supple. Which of the following is the most appropriate next step in diagnosis?

- A) Bone scan
- B) CT scan of the head
- C) Tympanometry
- D) Lumbar puncture
- E) Tympanocentesis

28. An 18-year-old man comes for an examination prior to participation in school sports. He states that he has had a dull ache in the scrotum since being hit in that area during a basketball game 2 months ago. Examination shows a 2-cm, hard, nontender mass in the right testicle. The mass does not transilluminate or change in size when the patient is placed in the supine position. Which of the following is the most likely cause?

- A) Cystic dilations of the efferent ductules
- B) Dilated pampiniform venous plexus
- C) Fluid accumulation within the tunica vaginalis testis
- D) Germinal cell tumor
- E) Vascular trauma

29. A 32-year-old man with alcoholism is brought to the emergency department by friends because he has been unable to stand without support and has had "funny eye movements"; they report that he has been drinking approximately 18 beers daily over the past month and has been increasingly confused over the past 5 days. He is awake and confused but is noncombative. His speech is slurred, and his breath smells of alcohol. His temperature is 37.2°C (99°F), blood pressure is 180/60 mm Hg, pulse is 110/min, and respirations are 18/min. Physical examination shows sixth cranial nerve palsy, horizontal diplopia, strabismus, and an asymmetric horizontal-gaze evoked nystagmus. Neurologic examination shows no focal weakness or numbness. When helped up and told to walk, he has a broad-based, uncertain gait. When asked how he arrived at the emergency department, he relates that "I drove to this place to visit some friends." The most likely cause of these findings is a deficiency of which of the following?

- A) Folic acid
- B) Magnesium
- C) Vitamin B_1 (thiamine)
- D) Vitamin B_{12} (cyanocobalamin)
- E) Zinc

30. A 67-year-old man with long-standing signs and symptoms of congestive heart failure is admitted to the hospital because of progressive shortness of breath. Examination shows no other abnormalities. An x-ray of the chest shows cardiomegaly, cephalization of blood vessels, and a right-sided pleural effusion. Which of the following sets of pleural fluid findings is most likely in this patient?

	Protein (g/dL)	Glucose (mg/dL)	Leukocyte count (/mm³)	Segmented neutrophils (%)	Monocytes (%)
○ A)	2.5	10	10,000	50	50
○ B)	2.5	90	2000	60	40
○ C)	3.8	40	30,000	80	20
○ D)	4.5	60	10,000	20	80
○ E)	4.5	90	2000	50	50

The response options for the next **2** items are the same. Select one answer for each item in the set.

For each patient with peripheral nerve dysfunction, select the most likely site of nerve injury.

- A) Axillary nerve
- B) Cervical nerve root at the cervical foramen
- C) Long thoracic nerve
- D) Median nerve above the elbow
- E) Median nerve at the elbow
- F) Median nerve at the wrist
- G) Musculocutaneous nerve above the elbow
- H) Musculocutaneous nerve at the elbow
- I) Musculocutaneous nerve at the wrist
- J) Radial nerve above the elbow
- K) Radial nerve at the elbow
- L) Radial nerve at the wrist
- M) Suprascapular nerve
- N) Thoracodorsal nerve
- O) Ulnar nerve above the elbow
- P) Ulnar nerve at the elbow
- Q) Ulnar nerve at the wrist

31. A previously healthy 42-year-old carpenter comes to the physician because of a 6-month history of pain and numbness in his dominant hand that awakens him at night. He describes numbness in his long and index fingers after driving for extended periods of time. Examination shows minimal atrophy of the thenar muscles. There is normal sensation to light touch on the little finger and the palm of the right hand. Sensation to light touch is decreased at the tip of the thumb, index finger, and long finger. X-rays of the right elbow and wrist show no abnormalities.

For each patient with peripheral nerve dysfunction, select the most likely site of nerve injury.

- A) Axillary nerve
- B) Cervical nerve root at the cervical foramen
- C) Long thoracic nerve
- D) Median nerve above the elbow
- E) Median nerve at the elbow
- F) Median nerve at the wrist
- G) Musculocutaneous nerve above the elbow
- H) Musculocutaneous nerve at the elbow
- I) Musculocutaneous nerve at the wrist
- J) Radial nerve above the elbow
- K) Radial nerve at the elbow
- L) Radial nerve at the wrist
- M) Suprascapular nerve
- N) Thoracodorsal nerve
- O) Ulnar nerve above the elbow
- P) Ulnar nerve at the elbow
- Q) Ulnar nerve at the wrist

32. A previously healthy 37-year-old man comes to the physician because of a 2-month history of pain in the forearm and little finger of his dominant hand; he has been working as a receptionist for 6 months. He describes numbness in his little finger and weakness of his grip. There is decreased sensation to light touch at the tip of the little finger. Paresthesias are elicited with compression of the cubital tunnel.

33. A 77-year-old woman is brought to the physician by her son for a routine health maintenance examination. She says that she feels well. Her son reports that 1 month ago, she got lost while driving home from the local supermarket. Two weeks ago, she forgot to turn off the stove after cooking dinner. She has been wearing bilateral hearing aids since audiometry 2 years ago showed bilateral high-frequency hearing loss. Her visual acuity corrected with glasses is 20/25 in both eyes. Neurologic examination shows mild fine tremors of the hands when the arms are outstretched; the tremor is not present at rest. Muscle strength is 5/5 in all extremities. Deep tendon reflexes are decreased at the ankles and 2+ elsewhere. Her gait is normal. Sensation to vibration is mildly decreased over the toes. On mental status examination, she is awake, alert, and conversant. Her language function is normal. She is oriented to person, place, and time and recalls one out of three objects after 10 minutes. Which of the following findings in this patient warrants further evaluation?

- A) Decreased deep tendon reflexes at the ankles
- B) Decreased sensation to vibration over the toes
- C) High-frequency hearing loss
- D) Memory loss
- E) Tremor of the outstretched hands

34. An asymptomatic 32-year-old woman comes for a routine health maintenance examination. Her mother and sister have a history of low back pain and disc herniation. The patient is a postal worker. She weighs 86 kg (190 lb) and is 165 cm (65 in) tall. Her blood pressure is 130/78 mm Hg, pulse is 74/min, and respirations are 16/min. Range of motion of the spine is normal and without pain. There is no scoliosis or excessive kyphosis of the back. Which of the following is the most effective strategy to decrease this patient's risk for developing low back pain?

- A) Change in job
- B) Limit physical activity
- C) Stretching exercises
- D) Weight-loss program
- E) Nonsteroidal anti-inflammatory drug therapy
- F) Prophylactic brace

35. A 42-year-old man comes to the emergency department because of a 2-week history of increasingly severe headaches and a 2-day history of nausea, vomiting, neck stiffness, and unsteadiness. He has type 2 diabetes mellitus treated with glyburide. His temperature is 38.1°C (100.5°F). Funduscopic examination shows bilateral papilledema. Neurologic examination shows mild meningismus and diffusely brisk deep tendon reflexes. He walks with a moderately broad-based gait. He is able to recall two out of three objects after 5 minutes and makes several errors on serial sevens. A CT scan of the head shows no abnormalities. Cerebrospinal fluid analysis shows a glucose concentration of 18 mg/dL, a protein concentration of 108 mg/dL, and a leukocyte count of 59/mm^3 (1% segmented neutrophils and 99% lymphocytes); a cryptococcal antigen assay is positive. Which of the following is the most appropriate pharmacotherapy for this patient?

- A) Acyclovir
- B) Amphotericin B
- C) Itraconazole
- D) Penicillin
- E) Vancomycin

36. A 40-year-old man is brought to the emergency department 1 hour after a high-speed motor vehicle collision. On arrival, he is awake and alert but has severe pain over the sternum. His systolic blood pressure is 80 mm Hg, pulse is 80/min, and respirations are 10/min. An ECG shows multifocal premature ventricular contractions but no ST-segment changes. His Po_2 is 100 mm Hg. After 1 L of lactated Ringer's solution is administered, his Po_2 decreases to 60 mm Hg while breathing 4 L/min of oxygen by nasal cannula. Pulmonary capillary wedge pressure has increased from 14 mm Hg to 24 mm Hg (N=1–10). Which of the following is the most likely explanation for the patient's poor response to fluid resuscitation?

- A) Inadequate administration of fluids
- B) Myocardial contusion
- C) Myocardial infarction
- D) Pulmonary contusion
- E) Traumatic rupture of the aorta

37. A county health officer investigates an outbreak of illness among persons attending a church picnic. The illness is characterized by the onset of nausea and vomiting 3 to 4 hours after attending the picnic. All affected persons recover without specific therapy. The investigation implicates egg salad as the vehicle of transmission. This episode is consistent with a foodborne outbreak caused by which of the following?

- A) *Clostridium perfringens*
- B) *Giardia lamblia*
- C) *Salmonella* species
- D) *Staphylococcus aureus*

38. A 62-year-old woman comes to the physician because of bloating and cramping abdominal pain and intermittent diarrhea over the past 5 years. Her symptoms have increased over the past month since she started a new diet that emphasizes yogurt and cottage cheese as low-fat sources of calcium and protein. Vital signs are within normal limits. Abdominal examination shows diffuse tenderness to palpation with no rebound tenderness; there are no masses or organomegaly. Bowel sounds are increased. Test of the stool for occult blood is negative. Which of the following is the best explanation for this patient's diarrhea?

- A) Impaired intestinal motility
- B) Inflammatory process
- C) Malabsorption
- D) Secretory process

39. A 52-year-old woman comes to the physician because of a 3-month history of intermittent bloody discharge from the right breast. She does not perform regular monthly breast self-examinations. She has a 3-year history of major depressive disorder treated with fluoxetine. Examination of the breasts shows no abnormalities. No masses are noted on palpation. Serosanguineous fluid can be expressed from the nipple of the right breast by pressing on the left side of the areola. Which of the following is the most likely diagnosis?

- A) Cystosarcoma phyllodes
- B) Fat necrosis
- C) Fibroadenoma
- D) Fibrocystic changes of the breast
- E) Galactorrhea
- F) Hyperprolactinemia
- G) Intraductal papilloma
- H) Mastitis
- I) Paget's disease of the breast

40. A 42-year-old woman comes to the physician because of right-sided abdominal cramps and nausea. During this period, she has noticed that her eyes are yellow. She has not had any other symptoms and has no other history of jaundice. Two months ago, she underwent a laparoscopic cholecystectomy for acute cholecystitis; intraoperative cholangiography was not performed at that time. She currently takes no medications. Vital signs are within normal limits. Examination shows scleral icterus. Cardiopulmonary examination shows no abnormalities. The abdomen is nondistended with mild right upper quadrant tenderness. There are no peritoneal signs. Bowel sounds are normal. Serum studies show:

Bilirubin, total	8 mg/dL
Direct	5 mg/dL
Alkaline phosphatase	650 U/L
AST	20 U/L
ALT	18 U/L

Abdominal ultrasonography shows dilation of the intrahepatic biliary ducts. Which of the following is the most appropriate next step in management?

- A) CT scan of the abdomen
- B) HIDA scan
- C) Intravenous antibiotic therapy
- D) Endoscopic retrograde cholangiopancreatography
- E) Surgical exploration of the abdomen

41. A 26-year-old woman is brought to the emergency department because of marked confusion for 2 hours; she also has had a flu-like illness for 3 days. Over the past 6 weeks, she has had increased fatigue, weakness, and nausea. She recently started thyroid hormone replacement therapy for autoimmune thyroiditis; 1 week ago, her serum thyroid-stimulating hormone concentration was 3 μU/mL. Her temperature is 38°C (100.4°F), blood pressure is 80/40 mm Hg, and pulse is 140/min. She appears confused and lethargic. Examination shows cool, mottled skin. There is generalized hyperpigmentation, especially involving the palmar creases. The lungs are clear to auscultation. Abdominal examination shows diffuse mild tenderness and no rebound. Laboratory studies show:

Hemoglobin	10 g/dL
Leukocyte count	9000/mm³
Segmented neutrophils	55%
Eosinophils	20%
Lymphocytes	25%
Serum	
Na^+	124 mEq/L
Cl^-	92 mEq/L
K^+	6.4 mEq/L
HCO_3^-	16 mEq/L

An x-ray of the chest and urinalysis show normal findings. An ECG shows sinus tachycardia with peaked T waves. Which of the following is most likely to confirm the primary cause of this patient's condition?

- A) Measurement of pulmonary artery pressure
- B) Measurement of right atrial pressure
- C) Measurement of serum antithyroglobulin antibody concentration
- D) Measurement of serum lactate dehydrogenase activity
- E) Measurement of serum thyroid-stimulating hormone concentration
- F) ACTH stimulation test
- G) Dexamethasone suppression test
- H) Blood cultures
- I) Echocardiography

41. A 26-year-old woman is brought to the emergency department because of marked confusion for 2 hours; she also has had a flu-like illness for 3 days. Over the past 6 weeks, she has had increased fatigue, weakness, and nausea. She recently started thyroid hormone replacement therapy for autoimmune thyroiditis; 1 week ago, her serum thyroid-stimulating hormone concentration was 3 μU/mL. Her temperature is 38°C (100.4°F), blood pressure is 80/40 mm Hg, and pulse is 140/min. She appears confused and lethargic. Examination shows cool, mottled skin. There is generalized hyperpigmentation, especially involving the palmar creases. The lungs are clear to auscultation. Abdominal examination shows diffuse mild tenderness and no rebound. Laboratory studies show:

Hemoglobin	10 g/dL
Leukocyte count	9000/mm³
Segmented neutrophils	55%
Eosinophils	20%
Lymphocytes	25%
Serum	
Na^+	124 mEq/L
Cl^-	92 mEq/L
K^+	6.4 mEq/L
HCO_3^-	16 mEq/L

An x-ray of the chest and urinalysis show normal findings. An ECG shows sinus tachycardia with peaked T waves. Which of the following is most likely to confirm the primary cause of this patient's condition?

- A) Measurement of pulmonary artery pressure
- B) Measurement of right atrial pressure
- C) Measurement of serum antithyroglobulin antibody concentration
- D) Measurement of serum lactate dehydrogenase activity
- E) Measurement of serum thyroid-stimulating hormone concentration
- F) ACTH stimulation test
- G) Dexamethasone suppression test
- H) Blood cultures
- I) Echocardiography

42. An 18-year-old man comes to the physician for an initial examination because of a 3-year history of fatigue and migrating joint pain. He has brought a large folder containing information about previous medical consultations, laboratory tests, and x-rays. He takes no medications. He weighs 50 kg (110 lb) and is 173 cm (68 in) tall. Physical examination shows no other abnormalities. On mental status examination, he is preoccupied with his symptoms. When asked about his mood, he states that the future appears bleak, and that he is too tired to think about it. Which of the following is the most appropriate next step in management?

- A) Ask about further symptoms of obsessions and compulsions
- B) Ask about sexual history including sexual orientation and practices
- C) Ask about suicidal feelings
- D) Ask about travel history over the past 6 months
- E) Obtain a detailed exercise history
- F) Measurement of serum Lyme (*Borrelia burgdorferi*) antibody concentration
- G) Urine toxicology screening

43. A 50-year-old woman has had progressive dyspnea over the past 2 weeks and constant, sharp chest pain for 4 days. The pain is localized to the center of the chest and is worse while supine. She underwent a right, modified radical mastectomy and adjuvant chemotherapy for breast cancer 3 years ago. She has a history of hypothyroidism treated with thyroid replacement therapy. She has smoked one pack of cigarettes daily for 30 years and drinks two ounces of alcohol daily. She is dyspneic and diaphoretic. Her temperature is 37.2°C (99°F), blood pressure is 90/70 mm Hg with a pulsus paradoxus of 20 mm Hg, pulse is 110/min, and respirations are 28/min. Examination shows jugular venous distention to the angle of the mandible. The liver span is 14 cm with 4 cm of shifting abdominal dullness. Arterial blood gas analysis on room air shows a pH of 7.50, Pco_2 of 30 mm Hg, and Po_2 of 70 mm Hg. An x-ray of the chest shows an enlarged cardiac silhouette with a globular configuration. An ECG shows sinus tachycardia with nonspecific ST-segment changes diffusely. Which of the following is the most appropriate next step in management?

- A) Echocardiography
- B) CT scan of the abdomen
- C) Ventilation-perfusion lung scans
- D) Bronchoscopy
- E) Paracentesis

44. A previously healthy 67-year-old man comes to the physician because of a 3-month history of right leg pain after walking two blocks. He has smoked two packs of cigarettes daily for 50 years. He is 165 cm (5 ft 5 in) tall and weighs 77 kg (170 lb); BMI is 28 kg/m². Examination of the right lower extremity shows shiny skin and decreased hair growth. Peripheral pulses are:

	Femoral	Popliteal	Dorsalis Pedis	Posterior Tibial
Right	3+	2+	0	0
Left	3+	2+	2+	2+

The right ankle brachial index is 0.6 (N>1), and the left is 0.9. In addition to smoking cessation, which of the following is the most appropriate next step in management?

- A) Daily exercise program
- B) Angioplasty
- C) Arteriography
- D) Femoropopliteal bypass grafting

45. A 64-year-old woman has moderately severe postoperative pain 1 day after a total abdominal hysterectomy and bilateral salpingo-oophorectomy. Which of the following is the most appropriate analgesic pharmacotherapy?

- A) Oral aspirin-codeine compound
- B) Oral diazepam
- C) Oral ibuprofen
- D) Intermittent intravenous naloxone
- E) Patient-controlled intravenous morphine
- F) Transcutaneous administration of fentanyl

46. Two days after admission to the hospital for treatment of severe left lower lobe pneumonia, a 72-year-old man has increasingly worse renal function. On admission, his blood pressure was 80/40 mm Hg. Serum studies showed a urea nitrogen concentration of 14 mg/dL and a creatinine concentration of 0.7 mg/dL. He received 4 L of intravenous fluids. He has been receiving ceftriaxone and azithromycin therapy since admission. He has hypertension, type 2 diabetes mellitus, and osteoarthritis. Medications also include glyburide, hydrochlorothiazide, and naproxen. His temperature is 37.8°C (100°F), pulse is 92/min, respirations are 18/min, and blood pressure is 126/80 mm Hg. Skin turgor is normal. Jugular venous pressure is 4 cm H_2O. Pulmonary examination shows egophony in the left posterior lung field. Serum studies today show a urea nitrogen concentration of 32 mg/dL and a creatinine concentration of 1.9 mg/dL. His urinary fractional excretion of sodium is 3%. His urine output is 300 mL/24 h. His postvoid residual volume is 70 mL. Urinalysis shows muddy brown casts. Renal ultrasonography shows no abnormalities. Which of the following is the most likely cause of this patient's increasingly worse renal function?

- A) Acute interstitial nephritis
- B) Acute tubular necrosis
- C) Intravascular volume depletion
- D) Obstructive uropathy
- E) Progression of diabetic nephropathy