The Remotoscope: Easier Diagnosis of Pediatric Earaches

Matthew Kim

Stanford University

BIOE 70Q: Medical Device Innovation

Mr. Ryan Pierce and Dr. Joseph Mandato

May 2, 2024

Background Information

Earache is a term to describe pain in the ear, which is more formally defined as otalgia (Murtagh, 1991). They are a very common occurrence in all ages but present especially in the emergency department setting in pediatric patients (Conover, 2013). There are many different causes of otalgia, which can originate from the ear directly or surrounding anatomic sites. Primary otalgia is ear pain originating from the ear itself while secondary or referred otalgia originates from outside the ear (Majumdar et al., 2009). In one study, out of 294 patents, 208 (70.7%) had primary otalgia and 86 (29.3%) had secondary otalgia (Kim et al., 2015). Additionally, primary otalgia was more frequent in men, whereas referred otalgia was more frequent in women and adults, suggesting that the type of otalgia may be dependent on age and gender (Kim et al., 2015).

Of the diagnoses, the most common is acute otitis media (AOM), an infection of the middle ear space (El Feghaly et al., 2023). AOM is the most common reason for prescribed antibiotics in children and affects approximately 80% of children by five years of age (Kim et al., 2015). Another prevalent diagnosis is acute otitis externa (AOE), also known as swimmer's ear, which is inflammation of the external ear canal from primarily bacterial infections of *Pseudomonas aeruginosa* and *Staphylococcus aureus* (Jackson et al., 2023). Of patients with earaches, around 77% are expected to have AOM and 12% AOE (Murtagh, 1991).

Identification of Problems

I identified current persisting problems related to pediatric earaches from publications, physicians, parents of children with earaches, and people who have had earaches as children. This section will describe the problems identified from each of the aforementioned sources.

Problems from Publications

Many of the publications I read detailed how the diagnosis and treatment of earaches are an immediate and complex challenge due to the diverse nature of their causes. In many cases, the precise diagnosis is hard to make due to the possibility of pain caused by disorders of the ear or by neighboring structures. The physician must take a detailed, thorough history for a working diagnosis. This requires much information to be retained by the physician and many connections between symptoms to be made to narrow down potential causes. There may also be debris in the ear canal that prevents the tympanic membrane from being visible, complicating the diagnosis. This can particularly arise in the form of earwax impaction, which can prevent assessment of both the tympanic membrane and ear canal (Adegbiji et al., 2014). Treatment for earwax impaction includes cerumenolytic agents and manual removal (Sevy et al., 2023). Such treatment may not be taken well by a child and could be traumatizing if this is one of the child's first medical visits. In addition, especially with AOM, there is a concern of overprescribing antibiotics and a belief that this needs to be diminished to prevent increases in antibiotic resistance (Vergison et al., 2010). These scenarios illustrate the variety of factors physicians need to consider with earaches.

Outside the clinic, the experience can be just as challenging for parents and children alike. Cases usually appear as late night calls from worried parents of a screaming child or infants with no obvious symptoms except screaming attacks, malaise, and vomiting. An experience like this can be distressing for both the parents and child, especially if a similar incident has not occurred in the past. If continual, unnecessary anxiety or trauma may result due to prevalence of the issue.

Problems from Physicians

I conducted interviews with emergency physicians and pediatricians for their anecdotal experiences that may be gleaned over by publications. Much of what they said corroborated problems identified from publications, but there were some additional ones that were worth noting.

One of the common challenges was the pediatric patient being uncooperative. One emergency physician specifically detailed that two year olds were the most difficult as they are big enough to fight and kick but not mature enough to be reasoned with. Another described how children can be really squirmish. They try to get help from the parents, but it is often futile. As a result, the actual examination becomes a major hurdle as it is difficult to get close to the child's ear while the child is still. Oftentimes, there is only a second or two window to observe the ear with the otoscope. The only solution to mitigate the issue was to wrap the child in a blanket, but this still had limitations as the child's head would move around.

Another challenge is the presence of so much earwax that they cannot look beyond to see the tympanic membrane. If there is no infection, the tympanic membrane should be shiny and semi-translucent. With an infection, the tympanic membrane is very dull, bulging with pressure, and red. Thus, just seeing the tympanic membrane can elucidate crucial details that can aid in diagnosis. Without being able to see it, this information cannot be obtained.

Problems from Parents

Interviews with parents reiterated what was mentioned previously of how distressing the experience can be, but there are other overlooked tangential side effects. For the majority, their children would start screaming in the middle of the night, prompting them to take their children to the emergency room. Due to anxiety, some parents took the next day off from work to

continue to care for their children, emphasizing the toll it can take on the parents' daily lives. For the parents in which their child was diagnosed with AOM or AOE, treatment consisted of administering the medication, which was another task they needed to remember.

A big challenge experienced by the parents was making their child more cooperative, especially during examination by the physician. Some of the parents experienced continued defiance when administering medication after the emergency room visit. In addition, some also tried prevention methods like suctioning their child's nose, but this was usually not just for preventing earaches. The reason was more so to alleviate congestion, but there was mild frustration with suctioning due to the constant build up of mucous.

Problems from People Who Have Had Earaches

Interviews from people who have had earaches ranged from children who more recently had them to young adults who have memories of them from the past. Despite their diversity, common themes emerged that reveal problems they faced. Foremost was that they felt they lacked the necessary communication skills to talk about their pain or the maturity to understand the situation. For some, they were just learning how to speak. This not only prevents them from sharing their experience at the time, but it also complicates how the physician can effectively treat them. They also expressed fear during their experience as this was often one of the first times they visited a physician for a health concern that was not just a check-up. As a result, they became more reluctant as to what to do.

The Need Statement

From the problems I identified, I was most intrigued by the problem physicians face of the pediatric patient being uncooperative. After more research about this problem on Internet forums, such as Reddit, I discovered that this is an issue nearly all physicians that deal with have

learned to simply accept and work around rather than address directly. Especially for newer physicians, dealing with uncooperative pediatric patients requires a lot of time and practice to get used to. A device that can alleviate this stress would be beneficial for both newer and experienced physicians since more effort can be placed on the actual diagnosis. As a result, I decided to focus on this problem and created the following need statement: a way to examine the tympanic membrane and ear canal in uncooperative pediatric patients with earaches in order to have an easier diagnosis experience for physicians.

Desirable Attributes of a Solution

While a complete and accurate diagnosis may be a tangential outcome, my main focus is on creating an easier diagnosis experience. Thus, the solution needs to be at the minimum the same as an otoscope. The physician must be able to examine the tympanic membrane and ear canal in their entirety with clear viewing, assuming no ear wax present. In addition, the solution must be straightforward to use and easy to understand for physicians to be convinced to make the switch from a typical otoscope.

Since the main problem lies in the movement of the uncooperative pediatric patients, the physician must be able to examine and make the diagnosis somewhat removed from the patient. In other words, the physician should not have to actively engage with the patient to examine the ear, removing the need to have to reason with or restrain the patient to gain access to the ear. The solution should allow for the physician to observe as remotely as possible, which would also reduce anxiety and optimize comfort for the patient.

Nice to haves include being simple in design and built from cheap materials. This would allow for greater distribution and accessibility of the solution and support an obvious, straightforward use. Manufacturability would also be more feasible if put on the market.

The Solution

The solution I devised to address the need statement is what I call the remotoscope: a remote otoscope that allows the physician to examine a patient's ear while being away from the patient. Specifically, the design is essentially a pair of goggles that the patient wears. Near the location of the ear, there is a small endoscope camera attached to the goggles strap that is inserted into the patient's ear. The endoscope is attached to the physician's phone for easy viewing, allowing for pictures and recording to be possible as well. To keep the camera steady, the endoscope camera is attached to a rigid base on the goggles strap that is kept tightly against the patient's head by tightening the strap. This allows the patient to still move the head around but keep the camera in place. As a result, even if the patient is uncooperative and desires to move, this poses no problem for the physician, who can still view the inside of the ear through the phone. This solution is illustrated in Figure 1.

Figure 1

Sketch of the Remotoscope

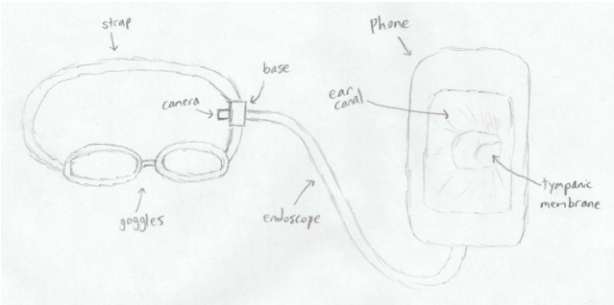

Other solution designs were considered before deciding on the final solution. My first solution idea was to have a set of headphones that can be placed over the patient's ears (Figure 2). One of the ear coverings would have the endoscope through it, allowing the camera to enter the patient's ear. The endoscope would still be connected to the physician's phone for viewing. Along with this was the possibility of allowing music to play in the patient's ears as the

physician is examining, which may soothe, calm, and distract the patient. However, I opted out of this idea because the headphones will not be secure to the patient's head. As a result, if movement of the head occurs, it is possible the headphones can slip off, meaning the camera can exit the patient's ear. This is resolved in the chosen solution as the goggles strap wraps around the entire head and can be tightened securely to prevent slipping.

Figure 2

Sketch of the Headphones Remotoscope

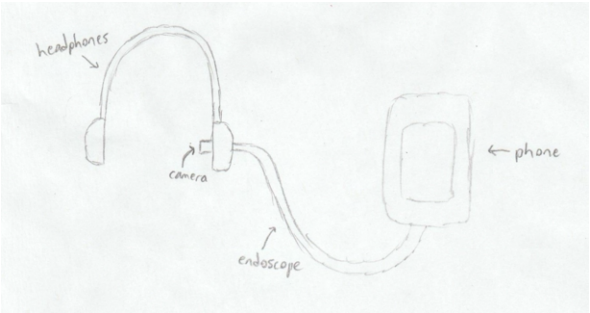

The second solution idea was to have a completely wireless remotoscope, eliminating the need for an endoscope and a direct connection to the phone. This would allow for complete remoteness as the remotoscope would essentially be similar to a wireless earbud except with a small camera attached to it. This can then be inserted into the patient's ear. The remotoscope can then connect via Bluetooth to the physician's phone and display the camera feed. My main issue with this solution was feasibility and complexity. As a bluetooth device, there are more complications that can occur, such as the Bluetooth signal not being recognized or a glitchy camera display. In addition, I have no knowledge in electronics to construct a device like this, so I decided a simpler, more feasible solution that suits my engineering abilities would better suffice.

Figure 3

Sketch of the Wireless Remotoscope

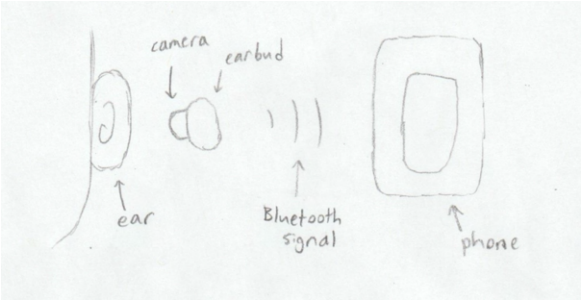

Prototyping

My prototyping experience was an intensely iterative process that involved frequent cycles of evaluation then adjustments. My prototype went through multiple stages of development before its current state. In this section, I will start from the beginning of my prototyping up to what the complete prototype looks like as of now.

Development of an Ear Testing Model

My first task in prototyping was developing an ear model that I could use for testing. I wanted to know if a small camera could fit snugly inside of an ear. Instead of putting materials in my own ear, I wanted to observe how the materials would exactly interact with the inside of the ear, which required me to develop my own benchtop testing model to do so. In the Biodesign Collaboratory, I found a block of squishy rubber that looked to have been used for practicing suturing and tubing. The rubber block had a consistency similar to human skin and flesh, and the tubing appeared a similar size and shape to the external ear canal. Thus, I poked a hole in the rubber block and inserted the tube to create my ear model (Figure 4).

Figure 4

The Benchtop Testing Ear Model

Material to Insert Camera

At this stage in prototyping, I did not yet acquire a camera, so I improvised by using conical glue dispensing tips as mock cameras to test what materials could be used to make a snug fit inside the ear. In the Biodesign Collaboratory, I identified three types of materials as candidates: a cotton ball, foam, and thick rubber (Figure 5).

Figure 5

The Candidate Materials

Note. Pictured from left to right: cotton ball, foam, and thick rubber.

I surrounded each of the conical tips with the material and inserted each into the tube. My first guess was that the thick rubber would be the best material as it would prevent any movement of the conical tip in the tube. The cotton ball lacked any structural integrity and was easily scrunched (Figure 6). As a result, the conical tip was able to move within the tube with some shaking. On the other hand, the thick rubber was too rigid and provided no flexibility at all (Figure 7). It was very difficult to even insert it into the tube, which raised concerns about whether it would be able to fit inside an actual ear canal. I also determined it would most likely be uncomfortable within the ear. The best material turned out to be the foam (Figure 8). It provided enough softness to be comfortable, enough flexibility to be inserted into the tube, and enough structure to keep the conical tip from moving too much within the tube.

Figure 6

Testing the Cotton Ball



Note. Left: Side view. Middle: Front view. Right: Side view with tube extruded to show interior.

Figure 7

Testing the Thick Rubber

Note. Left: Side view. Middle: Front view. Right: Side view with tube extruded to show interior.

Figure 8

Testing the Foam

Note. Left: Side view. Middle: Front view. Right: Side view with tube extruded to show interior.

The Camera Base

As part of the design, I needed an exterior base that would attach to the camera to keep it steady by being pressed against the patient's head. At this stage, I did acquire the endoscope camera (Figure 9).

Figure 9

The Endoscope with Camera

Note: This is the MATRIXCAMP 16.4ft Endoscope Camera with Light from Amazon.

I decided to first try a base design from chopsticks in a lattice arrangement that allowed it to wrap around the pen using yarn and rubber bands (Figure 10). My thought process was that the chopsticks wood was sturdy and the yarn and rubber bands would provide enough tension to prevent slippage. I quickly realized that the geometric shape of the chopsticks as a smooth cylinder reduced friction with the endoscope, allowing the base to slide along the endoscope.

I switched the chopsticks with colored craft sticks, keeping the same lattice design (Figure 10). When I slid the endoscope through this new base, I found that the craft sticks would buckle due to tension by the rubber bands. As a result, this design also failed.

Figure 10

Failed Base Designs



Note. Left: The chopsticks lattice base. Right: The colored craft sticks lattice base.

I then thought about whether the camera even needed to be inserted into the patient's ear. I altered the base design to instead be a tongue depressor with a hole cut out in the middle, big enough for the camera to see and light to shine through but small enough for the camera to not slide through (Figure 11). In addition, I figured instead of testing on the ear model, I can test on my actual ear since I can see the camera feed from my phone. I attached the base to the goggles strap. When I wore the goggles with the camera aligned to my right ear, I soon realized that attaching the camera to the exterior of the base allows shifting to occur if movement persists, making part of the base block the camera view (Figure 11).

Figure 11

Failed Tongue Depressor Base



Note. Left: The camera hole. Middle: The camera attached to the base. Right: The camera view in the ear.

This result led me to believe that I must insert the camera in the ear in order to have a clear view of the tympanic membrane and ear canal. To test this, I inserted the freed camera into my ear and was able to see both the tympanic membrane and ear canal in clear view, confirming my belief (Figure 12).

Figure 12

View of Freed Endoscope Camera

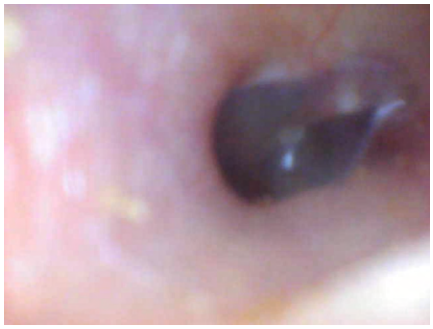

I altered my base design again with the tongue depressor length shortened to fit more comfortably on the ear and the hole large enough for the camera to slide through (Figure 13). I also surrounded the camera with the form I tested earlier, securing it with yarn as rubber bands might pose more irritation to the ear (Figure 13). However, to my surprise, the foam actually added too much thickness to the camera, preventing it from being able to be inserted into the ear enough for the tympanic membrane to be seen (Figure 13). Reducing the thickness of the foam and securing it further with tape did not resolve the issue (Figure 14). I did add exterior ear padding for greater comfort and to better angle the camera (Figure 14).

Figure 13

Shortened Base with Foam Covered Camera

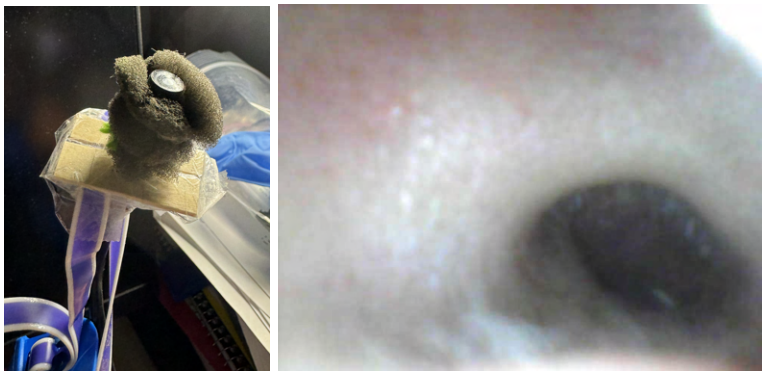

Note. Left: Updated base and camera. Right: Camera view of new design.

Figure 14

Camera with Reduced Foam Thickness and Exterior Ear Padding

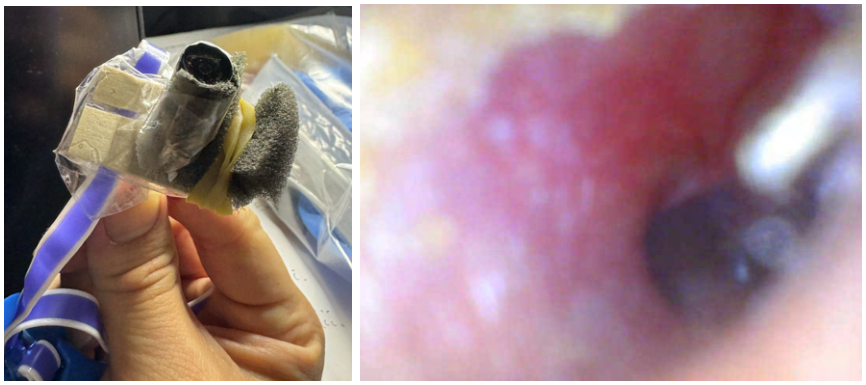

Note. Left: Updated camera with exterior ear padding. Right: Camera view of new design.

I removed all foam around the camera and worked on optimizing the angle at which the camera is inserted into the ear. I put the goggles on and would move the camera while attached to the strap until the tympanic membrane was in sight. Once this was done, I made note of the positioning of the camera and adjusted the angle of the base and camera using tape, extended portions of the base against the head, and rubber bands, repeating the cycle of observing in the ear and adjusting afterwards (Figure 15). Eventually, I achieved my current complete prototype (Figure 16) that can view the tympanic membrane and ear canal hands free (Figure 17).

Figure 15

Adjusted Camera



Note. Left: Front view. Middle: Side view. Right: Top view.

Figure 16

Complete Prototype



Note. Left: The complete prototype. Middle: Prototype worn front view. Right: Prototype worn side view.

Figure 17

Complete Prototype Camera View

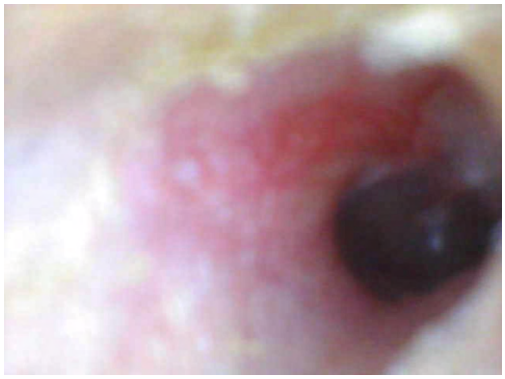

Strengths and Weaknesses of the Remotoscope

The strengths of the remotoscope are many, but the major strength is that it works. When I shook my head mildly, the camera would shake along, but it would return for the most part to its original position after the shaking stops, which means in effect that the camera is relatively locked in its position. In addition, the camera allows for continuous viewing of the tympanic membrane and ear canal, and the ability to take pictures and videos can aid in the diagnosis and treatment process. For example, pictures and videos can be referenced again later, or the parents

can be more involved in the health of their child if the physician chooses to show the parents the pictures and videos. The length of the endoscope enables the physician to be able to examine from a distance away, and the goggles work as intended to make sure the whole device is kept securely in place, even with movement.

Along with strengths, the remotoscope also has many weaknesses. The camera is impacted by debris such as ear wax or hair in the ear that can make it go out of focus. It is especially rendered useless if the issue is hair in the ear, which cannot be removed as easily as ear wax. The device is also not immune to aggressive movement since the camera position will then begin to shift. In addition, while the goggles are securely strapped, the patient may possibly try to remove the device with their hands, meaning there may be some level of restraint still needed to ensure everything works properly. The solution as it stands only accommodates the right ear, but it is possible that the earache may be in the left ear or both. While the camera is in the ear, the lights heat up quickly, posing a potential hazard, and the plastic of the camera can be uncomfortable. It can also be somewhat awkward to put the goggles on as the camera and base are a little bulky and need to be stretched out to the side until ready to be placed into the ear.

Next Steps in Development

The strengths and weaknesses of the current iteration of the remotoscope can dictate what next steps need to be taken. I believe the biggest issue that needs to be addressed is that only the right ear can be examined. A separate camera needs to be installed for the left ear, which then brings the question of whether it is better to examine both ears at once or one ear at a time. In addition, the base needs to be more securely and robustly constructed. At the moment, the base is somewhat fragile due to being held together with rubber bands and tape. From this design, a 3-D printed piece could be made as a replacement.

It would also be ideal if the remotoscope can eventually become a completely wireless system. The endoscope does provide some limitations and hindrance which a wireless device would eliminate. The next step to work towards this would be to learn how to send camera feed wirelessly to another device and how to incorporate a small camera into its own earbud-like device.

References

Adegbiji, Waheed Atilade; Alabi, Biodun Sulyman1,; Olajuyin, Oyebanji Anthony; Nwawolo, C.C.2. Earwax Impaction: Symptoms, Predisposing Factors and Perception among Nigerians. Journal of Family Medicine and Primary Care 3(4):p 379-382, Oct–Dec 2014. | DOI: 10.4103/2249-4863.148116

Conover K. Earache. Emerg Med Clin North Am. 2013 May;31(2):413-42. doi: 10.1016/j.emc.2013.02.001. PMID: 23601480.

El Feghaly RE, Nedved A, Katz SE, Frost HM. New insights into the treatment of acute otitis media. Expert Rev Anti Infect Ther. 2023 May;21(5):523-534. doi: 10.1080/14787210.2023.2206565. Epub 2023 Apr 28. PMID: 37097281; PMCID: PMC10231305.

Jackson EA, Geer K. Acute Otitis Externa: Rapid Evidence Review. Am Fam Physician. 2023 Feb;107(2):145-151. PMID: 36791445.

Kim SH, Kim TH, Byun JY, Park MS, Yeo SG. Clinical Differences in Types of Otalgia. J Audiol Otol. 2015 Apr;19(1):34-8. doi: 10.7874/jao.2015.19.1.34. Epub 2015 Apr 17. PMID: 26185789; PMCID: PMC4491947.

Majumdar S, Wu K, Bateman ND, Ray J. Diagnosis and management of otalgia in children. Arch Dis Child Educ Pract Ed. 2009 Apr;94(2):33-6. doi: 10.1136/adc.2007.117994. PMID: 19304897.

Murtagh J. The painful ear. Aust Fam Physician. 1991 Dec;20(12):1779-83. PMID: 1805782.

Sevy JO, Hohman MH, Singh A. Cerumen Impaction Removal. [Updated 2023 Mar 1]. In: StatPearls [Internet]. Treasure Island (FL): StatPearls Publishing; 2024 Jan-. Available from: https://www.ncbi.nlm.nih.gov/books/NBK448155/

Vergison A, Dagan R, Arguedas A, Bonhoeffer J, Cohen R, Dhooge I, Hoberman A, Liese J, Marchisio P, Palmu AA, Ray GT, Sanders EA, Simões EA, Uhari M, van Eldere J, Pelton SI. Otitis media and its consequences: beyond the earache. Lancet Infect Dis. 2010 Mar;10(3):195-203. doi: 10.1016/S1473-3099(10)70012-8. PMID: 20185098.

Appendix A

An Overview of Earaches and Their Challenges

Matthew Kim

Background Information

Earache is a term to describe pain in the ear, which is more formally defined as otalgia.[1] They are a very common occurrence in all ages but present especially in the emergency department setting in pediatric patients.[2] There are many different causes of otalgia, which can originate from the ear directly or surrounding anatomic sites. Primary otalgia is ear pain originating from the ear itself while secondary or referred otalgia originates from outside the ear.[3] In one study, out of 294 patents, 208 (70.7%) had primary otalgia and 86 (29.3%) had secondary otalgia.[4] Additionally, primary otalgia was more frequent in men, whereas referred otalgia was more frequent in women and adults, suggesting that the type of otalgia may be dependent on age and gender.

Of the diagnoses, the most common is acute otitis media (AOM), an infection of the middle ear space.[5] AOM is the most common reason for prescribed antibiotics in children and affects approximately 80% of children by five years of age.[4] Another prevalent diagnosis is acute otitis externa (AOE), also known as swimmer's ear, which is inflammation of the external ear canal from primarily bacterial infections of *Pseudomonas aeruginosa* and *Staphylococcus aureus*.[6] Of patients with earaches, around 77% are expected to have AOM and 12% AOE.[1]

Challenges

Due to the diverse nature of the causes of earaches, their diagnosis and treatment are an immediate and complex challenge. In many cases, the precise diagnosis is hard to make due to the possibility of pain caused by disorders of the ear or by neighboring structures.[1] There may also be debris in the ear canal that prevents the tympanic membrane from being visible, complicating the diagnosis.[1] The physician must take a detailed, thorough history for a working diagnosis.[3] Cases often appear as late night calls from worried parents of a screaming child or infants with no obvious symptoms except screaming attacks, malaise, and vomiting.[1] These scenarios illustrate the difficulty that comes with earaches.

---

[1] Murtagh J. The painful ear. Aust Fam Physician. 1991 Dec;20(12):1779-83. PMID: 1805782.
[2] Conover K. Earache. Emerg Med Clin North Am. 2013 May;31(2):413-42. doi: 10.1016/j.emc.2013.02.001. PMID: 23601480.
[3] Majumdar S, Wu K, Bateman ND, Ray J. Diagnosis and management of otalgia in children. Arch Dis Child Educ Pract Ed. 2009 Apr;94(2):33-6. doi: 10.1136/adc.2007.117994. PMID: 19304897.
[4] Kim SH, Kim TH, Byun JY, Park MS, Yeo SG. Clinical Differences in Types of Otalgia. J Audiol Otol. 2015 Apr;19(1):34-8. doi: 10.7874/jao.2015.19.1.34. Epub 2015 Apr 17. PMID: 26185789; PMCID: PMC4491947.
[5] El Feghaly RE, Nedved A, Katz SE, Frost HM. New insights into the treatment of acute otitis media. Expert Rev Anti Infect Ther. 2023 May;21(5):523-534. doi: 10.1080/14787210.2023.2206565. Epub 2023 Apr 28. PMID: 37097281; PMCID: PMC10231305.
[6] Jackson EA, Geer K. Acute Otitis Externa: Rapid Evidence Review. Am Fam Physician. 2023 Feb;107(2):145-151. PMID: 36791445.

From the aforementioned situations, it is obvious that the physician, parents, and affected child are immediate stakeholders in the issue of earaches. The physician needs to manage with a possibly uncooperative child or one that is not old enough to communicate about the pain in addition to considering all the factors that could be causing the earache. The parents undergo a distressing experience with their child spontaneously screaming in the middle of the night and the urgency of getting help and treatment as soon as possible. The affected child might lack the necessary communication skills to talk about their pain or the maturity to understand the situation, which can complicate how the physician can effectively treat the child. Thus, the physician, parents, and affected child all face difficult challenges.

Physician Interview

I interviewed Dr. Kihyun Kim, an emergency physician, to discuss his experiences in the emergency department with earaches. Much of what he said reaffirmed what is present in the literature. He described patients with earaches as “bread and butter” type cases, especially with children who come in the emergency room with a cold and fever.

The most common case he sees is AOM, but AOE cases also appear. The scenario of a typical case he gave is a child screaming in pain, crying extensively, holding their ear, and coming to the emergency room at 1 AM or 2 AM in the morning. When determining between AOM and AOE, he primarily uses an otoscope to examine the ear. For AOM, a very bright red tympanic membrane is usually indicative of inflammation and infection of the inner ear. The tympanic membrane may also appear bulging out due to being under a lot of pressure. Sometimes, a layer of fluid can be seen on the other side of the membrane, which is called effusion, and means the patient likely has otitis media with effusion. When making a diagnosis and the child has a cold with a lot of nasal congestion, all that snot can lead to inflammation due to fluid collecting in the inner ear and not being properly drained since the nose is connected to the inner ear by the eustachian tube. Thus, one of the first questions he asks a parent is if the child has been sick recently. For AOM, he usually prescribes antibiotics by mouth in the liquid form since children cannot swallow pills. This antibiotic is very commonly amoxicillin, which as a liquid comes in a pink solution and is very popular with kids due to its bubblegum flavor. For AOE, the inflammation and infection is present in the ear canal. The reason AOE is known as swimmer’s ear is due to water getting into the ear and the wetness remaining in there. Since children do not realize water is in their ears and do not attempt to get it out, inflammation and infection of the ear canal can result. Another way he diagnoses AOE is when manipulating the ears and pulling it. Since the pinna is an extension of the ear canal, when pulled, the ear canal also gets pulled, so the child experiences pain. To treat AOE, he prescribes antibiotic ear drops.

Other scenarios he described of earaches are less serious in origin. One is when parents bring their child worried something is going on after noticing their child tugging and messing with their ear. In the context of no recent cold symptoms or no fever and sudden tugging, the typical cause is ear wax. Another scenario is on a plane ride with altitude change. Children, not

knowing about pressure changes, cannot equilibrate the pressure or pop their ears, which can sometimes lead to pain.

The most significant challenge he faces is when attempting to examine a two year old child. For children younger than two, since they are small, if not cooperating, the parents can help to restrain the child as he observes the affected ear or ears with the otoscope. For children older than two, they are often mature enough for him to reason with them that the examination will not hurt at all. He often shows them the otoscope to play around with and shows it is harmless and talks with the parents to make the child feel more comfortable. However, for children at two years old, he described it as very difficult to diagnose. They are often crying and very uncooperative, big enough to fight and kick their parents and him due to distrust. In addition, they are young enough that reasoning does not work as effectively. He emphasized that the examination is truly the biggest challenge as he has to get really close to the child's ear while the child is staying still. Oftentimes, there is only a second or two window for him to observe the ear with the otoscope.

Another challenge he faces is the presence of so much wax, he cannot look beyond that to see the tympanic membrane. If there is no infection, the tympanic membrane should be shiny and semi-translucent. With an infection, the tympanic membrane is very dull, bulging with pressure, and red.

He also explained some common prevention methods for earaches. If the child is very congested with a snotty nose, since children cannot blow their nose, the parents have to actively suction their nose. This is commonly done with a plastic bulb or electronic suctioning device. However, the child can become congested again very quickly, so this method is often a losing fight. Another way is using saline drops to loosen up the mucous. He also mentioned decongestants are not recommended for children due to the side effects, such as drowsiness which can affect breathing.

Parent Interviews

In addition to interviewing Dr. Kim, I talked with several parents who have had experience dealing with their children who had earaches. There were common trends and patterns in their experiences that also reaffirm what has been described previously. Often, their children would start screaming in the middle of the night, prompting them to take their children to the emergency room. Due to anxiety, some parents took the next day off from work to continue to care for their children. For the parents in which their child was diagnosed with AOM or AOE, treatment consisted of administering the medication. A big challenge experienced by the parents was making their child more cooperative, especially during examination by the physician. Some of the parents experienced continued defiance when administering medication after the emergency room visit. In addition, some also tried prevention methods like suctioning their child's nose but not just for preventing earaches. The reason was more so to alleviate congestion, but there was mild frustration with suctioning due to the constant build up of mucous.