Eye Disease Classification from OCT Scan Images Using Deep Learning

Tsolmon Gunaabazar

March 2026

1 Introduction

Eye diseases such as diabetic macular edema (DME), choroidal neovascularization (CNV), and drusen are the leading cause of vision loss around the world. Many of these diseases affect the retina and can be detected using medical imaging techniques such as Optical Coherence Tomography (OCT). OCT scans produce high-resolution cross-sectional images of the retina that allow doctors to observe structural changes in eye tissue [1]. However, analyzing these scans requires specialized expertise and can be time-consuming when large numbers of images must be examined. Because of this, automated classification systems that can assist with identifying retinal diseases from OCT images could help reduce the workload for clinicians and support earlier detection of vision-threatening conditions. The goal of this project is to develop a deep learning model that can automatically classify OCT images into four categories: *Normal*, *CNV*, *DME*, and *Drusen*. The input to the model is a grayscale OCT image, and the output is the predicted disease class associated with that image. The task can therefore be formulated as an image classification problem where the model maps an OCT image to one of four diagnostic labels. Figure 1 shows the overall workflow of the system. This problem is well suited for deep learning because it is fundamentally an image classification task. Convolutional Neural Networks (CNNs) are designed to learn visual patterns directly from images by identifying features such as edges, textures, and structural shapes. In OCT scans, diseases often appear as subtle structural changes in the retinal layers, which makes CNNs particularly effective at detecting these patterns automatically. In this project, deep learning models will be used to learn these visual features from OCT images and classify different types of retinal disease.

2 Notable Contribution

2.1 Data Processing

The dataset used in this project is derived from the publicly available retinal OCT dataset introduced by Kermany et al. [1]. This dataset contains OCT scans categorized into four diagnostic classes: *Normal*, *CNV*, *DME*, and *Drusen*. Each image represents a cross-sectional view of the retina and provides structural information that can be used to identify pathological changes associated with retinal disease. Due to computational constraints during development, a smaller subset of the dataset obtained from a publicly available Kaggle repository [2]was used containing 4289 images. Table 1shows the class distribution of the dataset. Using a smaller subset allowed faster experimentation and model

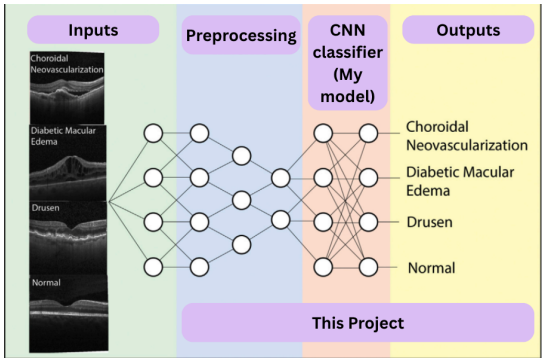

Figure 1: Workflow diagram for retinal OCT disease classification (adapted from [1]).

iteration while still providing sufficient data to train and evaluate the models. All images were preprocessed before being used for training. First, each image was resized to 128×128 pixels to ensure a consistent input dimension for the neural network models. The images were then converted to grayscale to reduce input dimensionality while preserving the structural retinal features necessary for classification. Finally, the images were converted into tensor format compatible with the PyTorch deep learning framework. The dataset was divided into training, validation, and test sets using a 70/15/15 split. The training set is used to learn model parameters, the validation set is used to monitor performance during training and tune model settings, and the test set is reserved for evaluating the final model performance on unseen data. During preprocessing, one challenge encountered was the presence of variations in image orientation and cropping. Some OCT scans contained slight tilting or triangular borders (Figure 2) resulting from the imaging process. These variations were retained in the dataset because CNNs are generally robust to small spatial transformations and maintaining these variations can improve model generalization. For the final stage of the project, the trained model will also be evaluated on additional OCT images that were not used during training in order to further assess its ability to generalize to new data.

Class	Number of Images
CNV	1245
DME	888
Drusen	1064
Normal	1092
Total	4289

Table 1: Distribution of image across diagnostic classes.

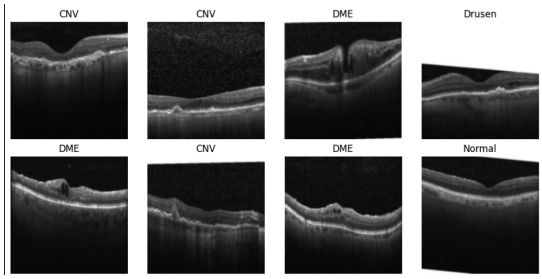

Figure 2: Example OCT scan used as input to the model.

2.2 Baseline Model

To establish a reference point for model performance, a simple multilayer perceptron (MLP) was used as the baseline model. The baseline architecture takes a 128×128 grayscale OCT image and flattens it into a one-dimensional vector of length 16384. This vector is then passed through a fully connected layer containing 256 hidden units followed by a ReLU activation function. A final fully connected layer produces four outputs corresponding to the four disease classes. Although this model is straightforward to implement and requires minimal hyperparameter tuning, it has a major limitation. Flattening the image removes the spatial relationships between neighboring pixels, preventing the model from capturing structural patterns that are important for identifying retinal diseases. The baseline model was trained using cross-entropy loss and the Adam optimizer. After training, the model achieved 48.67% validation accuracy. The confusion matrix (Figure 3) indicates that the baseline model frequently confuses disease classes that share similar visual characteristics, particularly DME and Drusen. Interestingly, the baseline architecture contains approximately 4.2 million trainable parameters, which is larger than the CNN implemented later in this project. Despite having more parameters, the baseline performs significantly worse because it cannot effectively use the spatial structure of the input images. These results demonstrate the limitations of fully connected architectures for image classification tasks and motivate the use of CNNs, which are specifically designed to capture spatial patterns in images.

2.3 Primary Model

The primary model used in this project is a CNN designed to capture spatial features from OCT images. CNNs are well suited for this task because they preserve spatial relationships between pixels and can learn hierarchical

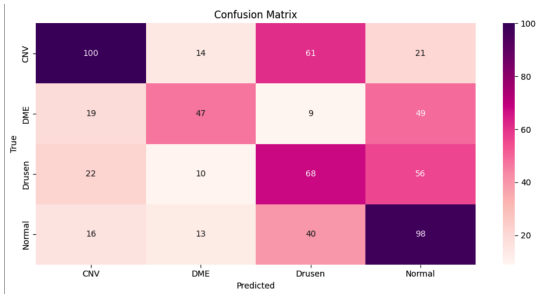

Figure 3: Confusion matrix for the baseline model

visual features directly from image data. The CNN architecture consists of three convolutional blocks. Each block contains a convolutional layer followed by a ReLU activation function and a max-pooling operation. The number of feature channels increases progressively from 16 to 32 and then 64 across the convolutional layers, allowing the network to learn increasingly complex visual representations of retinal structures. After the convolutional feature extraction layers, the resulting feature maps are flattened and passed through two fully connected layers. The first fully connected layer contains 128 hidden units, and the final layer outputs four values corresponding to the four disease classes. The CNN contains approximately 2.1 million trainable parameters, which is fewer than the baseline MLP model. Despite having fewer parameters, the CNN achieves significantly better performance because it preserves spatial information and learns meaningful visual features from the OCT images. The model was trained using the Adam optimizer with cross-entropy loss. After training for 15 epochs, the CNN achieved 80.09% validation accuracy and 81.05% test accuracy. The confusion matrix (Figure 4) shows that the model performs particularly well on the CNV class, which often exhibits strong structural abnormalities in OCT scans. The Drusen class remains more challenging to classify because the associated retinal changes can be more subtle. Overall, these results demonstrate that the CNN architecture is capable of learning useful visual representations for retinal disease classification. The performance achieved in the current experiments suggests that the proposed approach is feasible and can likely be further improved through additional training data, model tuning, or more advanced architectures.

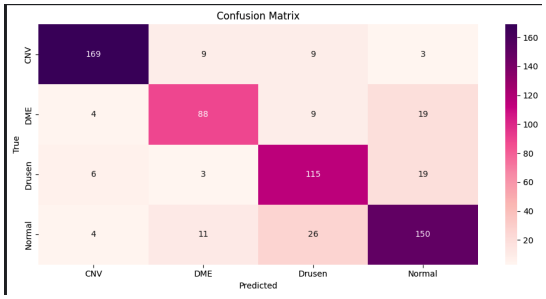

Figure 4: Confusion matrix of test accuracy.

Google Colab: https://colab.research.google.com/drive/1HaOPuf7k0s5v5q4qH8L88KroH3f0ZQVq?usp=sharing

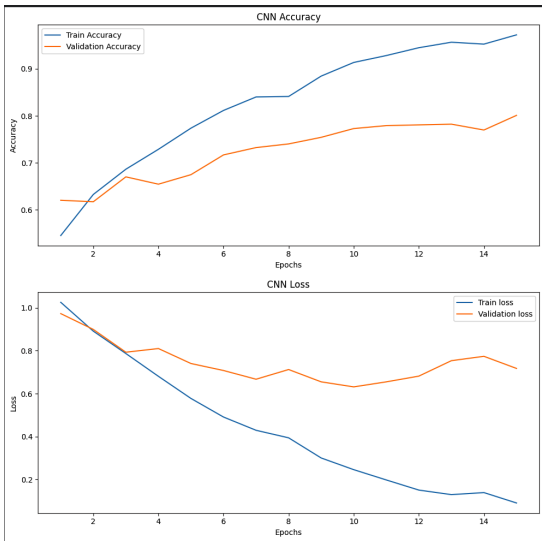

Figure 5: Training and validation accuracy for the CNN model.

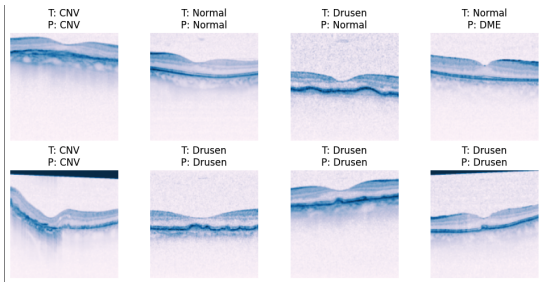

Figure 6: Example predictions from the CNN model.

References

[1] D. S. Kermany *et al.*, "Identifying Medical Diagnoses and Treatable Diseases by Image-Based Deep Learning," *Cell*, vol. 172, no. 5, pp. 1122-1131.e9, Feb. 2018, doi: 10.1016/j.cell.2018.02.010.

[2] Pires Jorge, "Retinal OCT Images [Small version]." Accessed: Mar. 13, 2026. [Online]. Available: https://www.kaggle.com/datasets/jorgeguerrapires/retinal-oct-images-small-version