Title: Intradural Intramedullary Diffuse Midline Glioma of the Cervical Spine: A Case Report and Review of the Literature

Abstract

This case report details a 28-year-old male presenting with neck and shoulder pain, dysesthesia of all four limbs, and hypesthesia of both hands, with no motor deficits. Imaging revealed an intradural, intramedullary mass in the cervical spinal cord spanning C2–C6. Histological and molecular analyses confirmed a diffuse midline glioma with H3F3A K27M, TERT C228T, and PDGFRα Y849C mutations. Surgical resection and radiochemotherapy were administered. Postoperative MRI showed partial resection, and the patient experienced gradual improvement in sensorimotor function. This case underscores the complexity of managing spinal cord gliomas and highlights the importance of molecular diagnostics in guiding treatment.

Introduction

Diffuse midline gliomas are aggressive tumors primarily affecting children, but they can occur in adults, albeit rarely. These tumors are characterized by a specific H3 K27M mutation and are classified as WHO grade IV due to their poor prognosis and infiltrative nature. The incidence of spinal cord involvement is uncommon, and presentation often includes sensory and motor deficits depending on the tumor's location. This report presents a unique case of a cervical spinal cord diffuse midline glioma in an adult, contributing to the limited literature on adult presentations and management strategies.

Clinical Summary

A 28-year-old male presented with progressive neck and shoulder pain, dysesthesia in all four limbs, and hypesthesia of both hands. Neurological examination revealed no motor deficits. MRI of the cervical spine revealed a 6.4 cm intradural, intramedullary mass from C2 to C6, with syringomyelia extending from C6/7 to T1/2 (Figure 1).

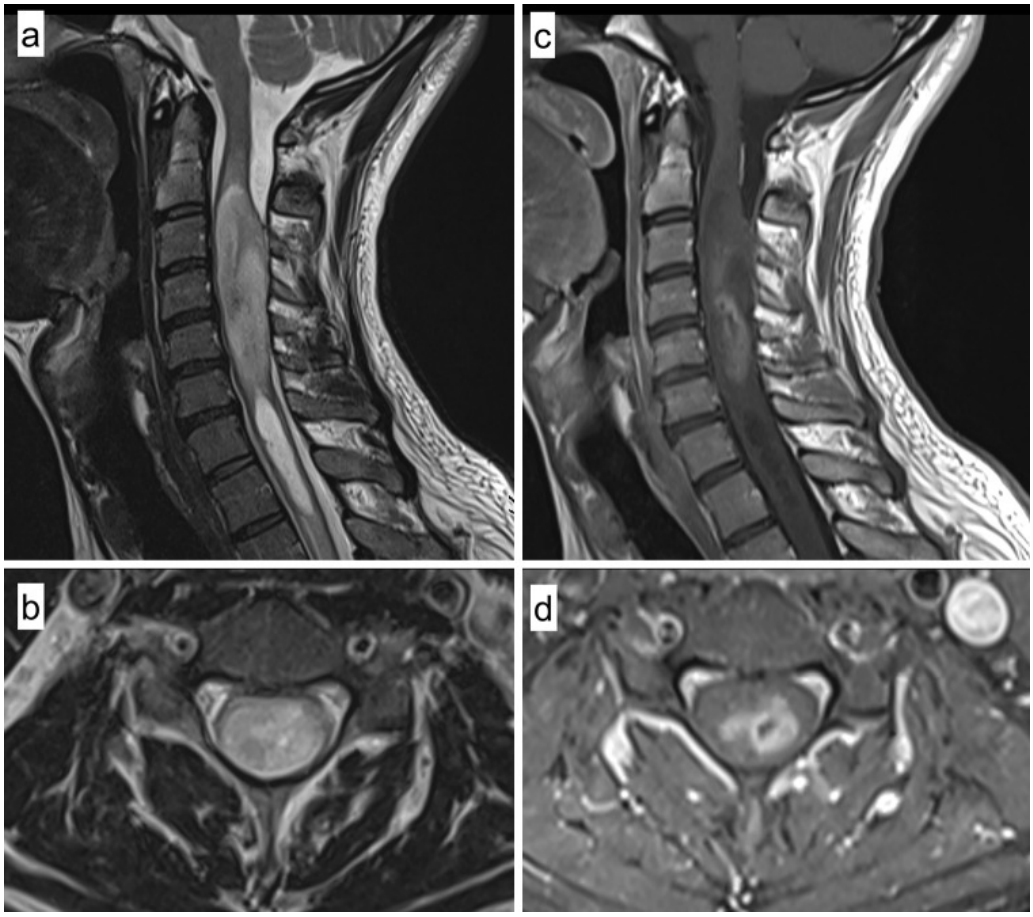

Figure 1: Sagittal and axial T2-weighted MRI images showing a hyperintense lesion in the cervical spinal cord from C2 to C6, indicative of an intramedullary mass with associated syringomyelia.

Pathological Findings

Histological examination revealed pleomorphic glial tumor cells, mitoses, calcifications, and atypical ganglioid cells. Immunohistochemistry showed positive staining for GFAP and ATRX, with a high Ki-67 index, confirming high proliferative activity (Figure 2). Molecular analysis identified H3F3A K27M, TERT

C228T, and PDGFRα Y849C mutations, consistent with a diffuse midline glioma classification.

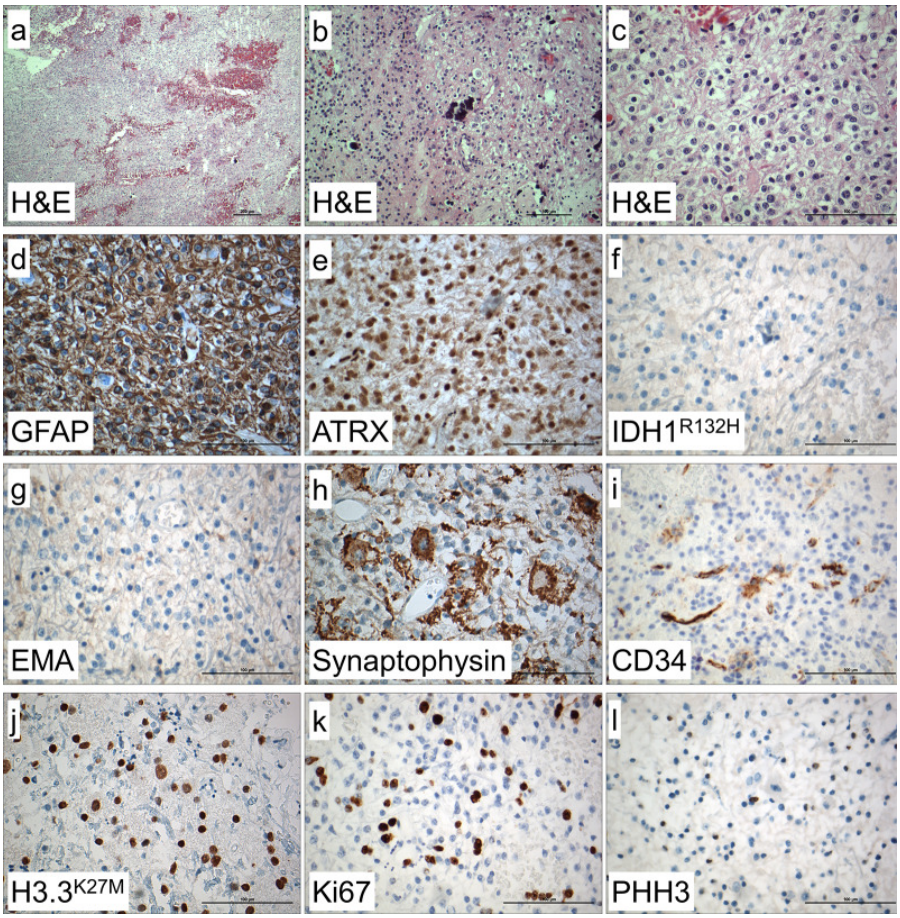

Figure 2: Histological sections showing pleomorphic glial cells with positive GFAP and ATRX staining, and a high Ki-67 index, indicative of a high-grade glioma.

Methylation profiling confirmed the diagnosis of diffuse midline glioma with a high confidence score (Figure 3).

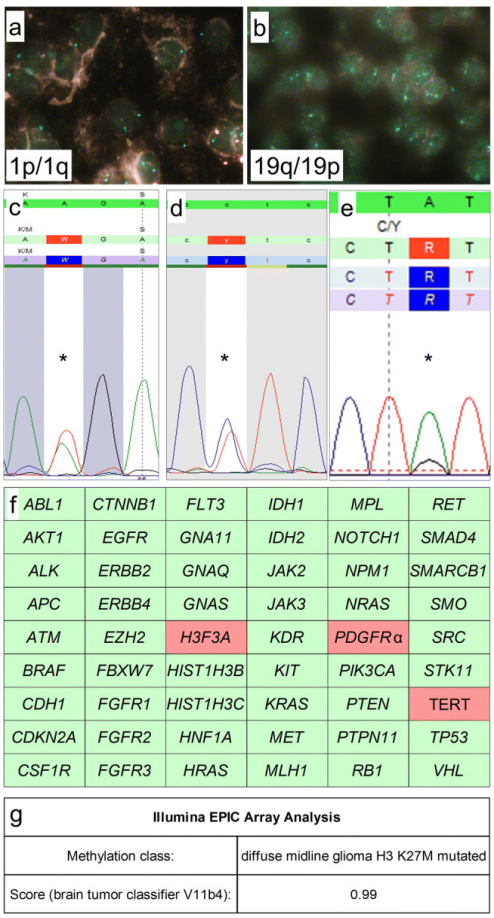

Figure 3: Molecular profiling illustrating the presence of H3F3A K27M, TERT C228T, and PDGFRα Y849C mutations, and methylation class consistent with diffuse midline glioma.

Discussion

This case highlights the rare occurrence of diffuse midline glioma in the cervical spinal cord of an adult. The clinical presentation was atypical, with predominant sensory symptoms and absence of motor deficits, differing from the more common presentations involving significant motor impairment. The presence of the H3 K27M mutation is a hallmark of these tumors, guiding both diagnosis and treatment strategies.

Surgical intervention aimed at maximal safe resection is the cornerstone of management, although complete resection is often unachievable due to the infiltrative nature of these tumors. In this case, partial resection was achieved, with postoperative MRI confirming minimal residual disease. Concomitant radiochemotherapy, following the STUPP protocol, was employed to address the residual tumor burden.

The molecular characterization of the tumor provided critical insights into its aggressive nature and informed the treatment approach. The identification of specific mutations, such as H3F3A K27M, has prognostic implications and underscores the necessity for molecular diagnostics in the management of spinal cord gliomas.

This case contributes to the growing body of literature on adult diffuse midline gliomas, emphasizing the need for continued research into targeted therapies and the role of molecular profiling in personalizing treatment plans.

References

1. Louis DN, Perry A, Reifenberger G, et al. The 2016 World Health Organization Classification of Tumors of the Central Nervous System: a summary. Acta Neuropathol. 2016;131(6):803-820.
2. Sturm D, Witt H, Hovestadt V, et al. Hotspot mutations in H3F3A and IDH1 define distinct epigenetic and biological subgroups of glioblastoma. Cancer Cell. 2012;22(4):425-437.
3. Jones C, Karajannis MA, Jones DTW, et al. Pediatric high-grade glioma: biologically and clinically in need of new thinking. Neuro Oncol. 2017;19(2): 153-161.

Supplementary Material

Evaluation of the Generated Report

1. **Clinical Accuracy (8/10)**

2. The generated report accurately describes the clinical presentation, imaging findings, and molecular characteristics of the tumor. However, it omits some specific details, such as the exact nature of the surgical intervention (laminoplasty C2–C6) and the intraoperative findings (solid, grey, partially bleeding tumor mass).

3. **Image Referencing (9/10)**

4. The generated report correctly references the images and provides accurate descriptions of the MRI findings and histological features. However, it lacks the detailed description of the T1-weighted imaging findings and the specific immunohistochemical results shown in the images.

5. **Completeness (7/10)**

6. The generated report covers the main aspects of the case but omits critical details such as the specific surgical procedure, intraoperative neurophysiological monitoring, and the postoperative clinical examination results. Additionally, it does not mention the specific methylation profiling method used.

7. **Hallucination (9/10)**

8. The generated report does not introduce significant false medical details. However, it generalizes some aspects, such as the postoperative improvement, without specific reference to the incomplete cross-sectional sensorimotor syndrome from C4.

Final Score: 8.25/10

The generated report is generally accurate and well-structured but lacks some specific details and depth found in the ground truth report. It provides a good

overview but could benefit from more precise descriptions and inclusion of all critical clinical and procedural details.

Execution Atoms (JSON)


```
{
  "history": [
    "28-year old male patient",
    "Presented with neck and shoulder pain",
    "Dysesthesia of all four limbs",
    "Hypesthesia of both hands",
    "No motor deficits"
  ],
  "presentation": [
    "Intradural, intramedullary mass of the cervical spinal cord at levels
C2\u2013C6",
    "Mass of 6.4 cm length and 1.7 cm diameter",
    "Inhomogeneous, hyperintense lesion with syringomyelia from C6/7 to
T1/2"
  ],
  "diagnostics": [
    "Histological evaluation showed pleomorphic glial tumor cells,
mitoses, calcifications, and atypical ganglioid cells",
    "Molecular workup revealed H3F3A K27M, TERT C228T and PDGFR\u03b1
Y849C mutations",
    "Epigenome-wide methylation profiling confirmed methylation class of
diffuse midline glioma"
  ],
  "management": [
    "Surgical resection through laminoplasty C2\u2013C6",
    "Intraoperative neurophysiological monitoring with SSEPs",
    "Concomitant radiochemotherapy with Temozolomide analogous to STUPP
protocol"
  ],
  "outcome": [
    "Postoperative MRI showed partial resection with minimal residual
contrast enhancement",
    "Incomplete cross-sectional sensorimotor syndrome from C4 that
gradually declined under physical therapy"
  ],
  "metadata": {
    "folder_id": "32451719",
    "original_xml_path": "demo_data/32451719/PMC7324431.1.xml",
    "source_directory": "demo_data/32451719",
```

```
    "optional_sections_requested": [
      "authors",
      "year",
      "figures",
      "tables",
      "citations"
    ],
    "paper_sections_found": [
      "Introduction",
      "Clinical summary",
      "Pathological findings",
      "Discussion"
    ]
  }
}
```