

# HCP Subjects with Segmentation flags

## Part 2

These are HCP (Young Adult) subjects that have an error in their FreeSurfer output that was found during Surface QC. These errors can be seen in the volume surface outlines, parcellations and/or on the surfaces in the sulcal maps and myelin maps.

The following slides show the processed data results in Connectome Workbench wb\_view.

The slides showing errors in the hippocampus segmentation and parcellation are displaying the `aparc+aseg.nii.gz` parcellation file in which the hippocampus is supposed to be colored yellow.

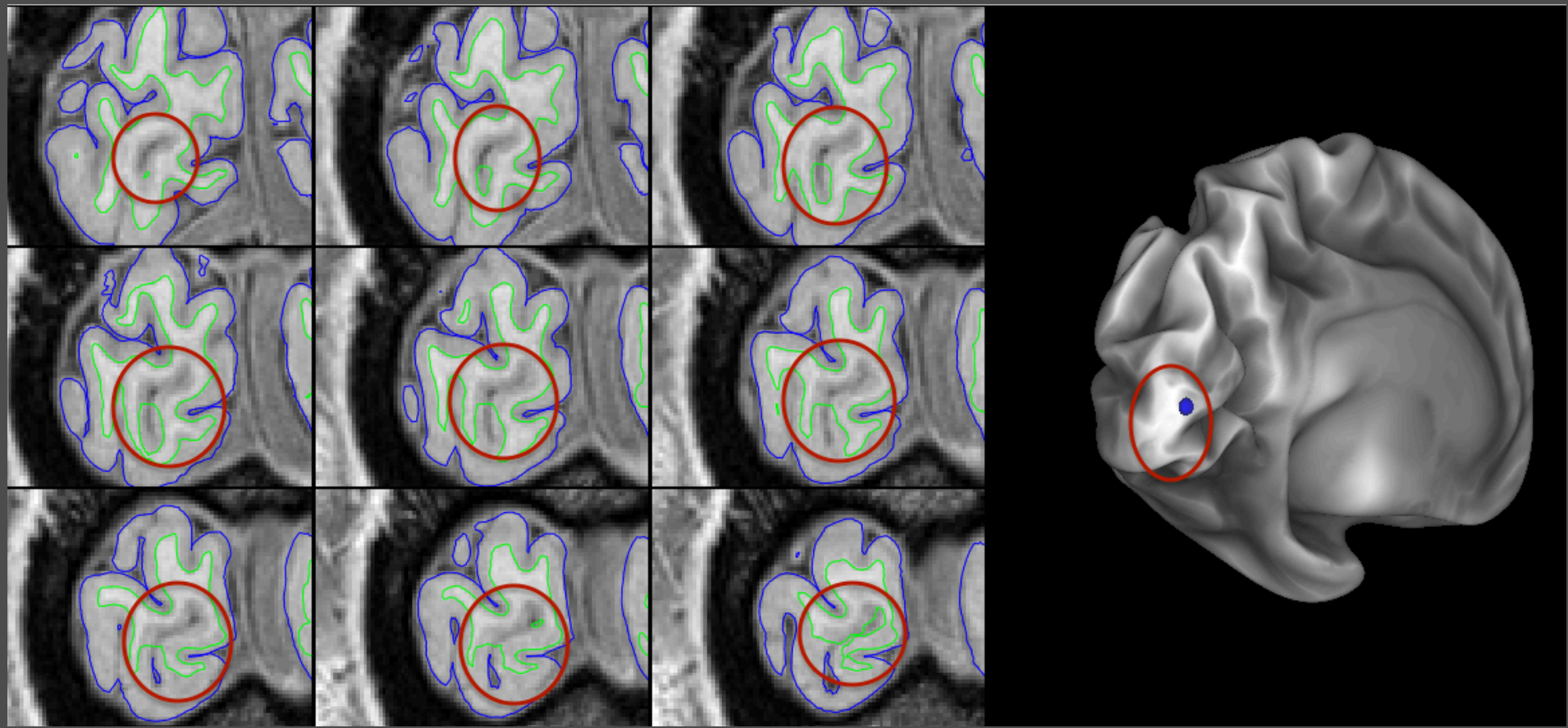
The files for the surface maps are:

Sulcal map = {Subject}.sulc.164k\_fs\_LR.dscalar.nii

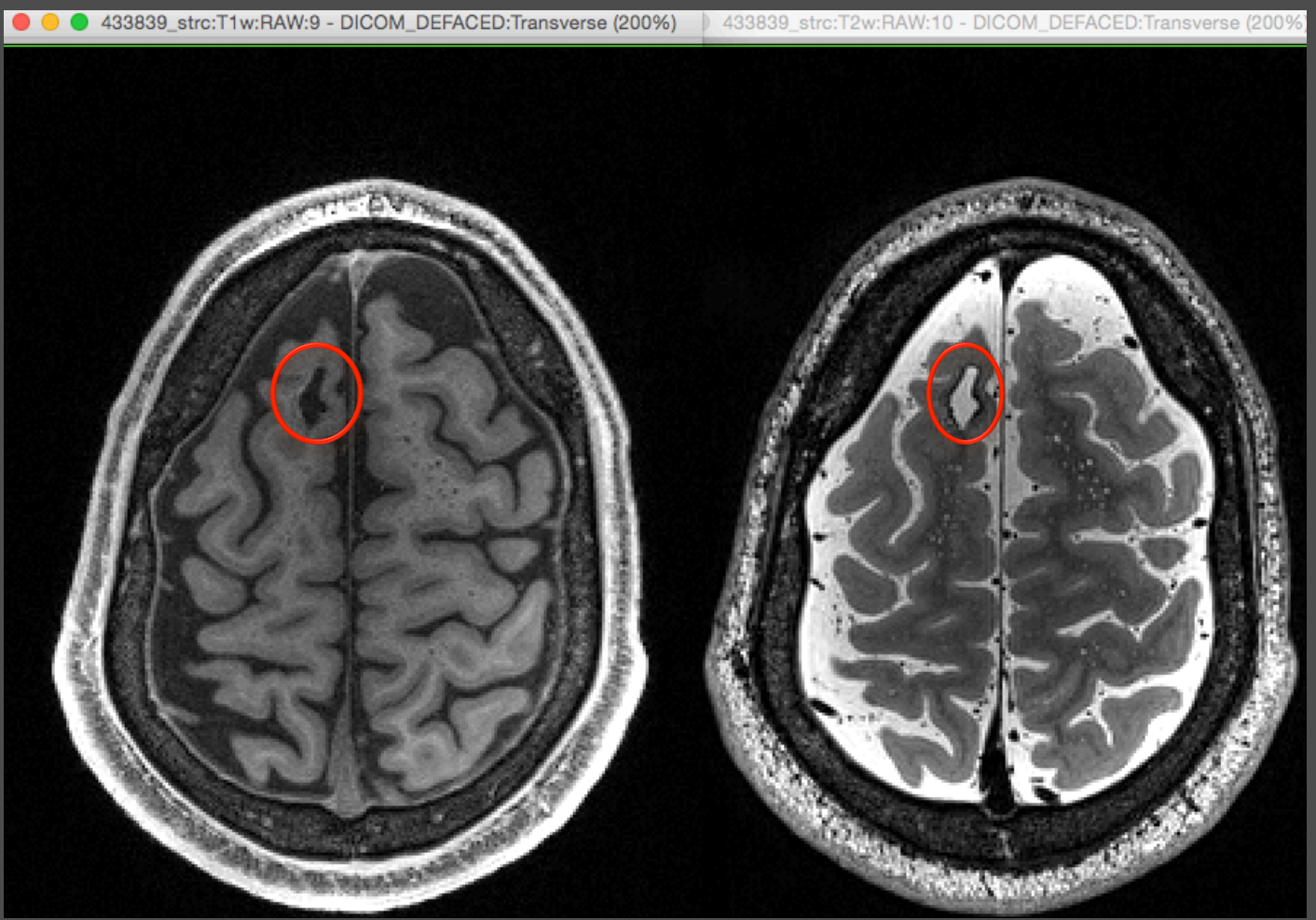Areal Distortion map = {Subject}.ArealDistortion\_MSMSulc.164k\_fs\_LR.dscalar.nii

Myelin map = {Subject}.SmoothedMyelinMap\_BC.164k\_fs\_LR.dscalar.nii

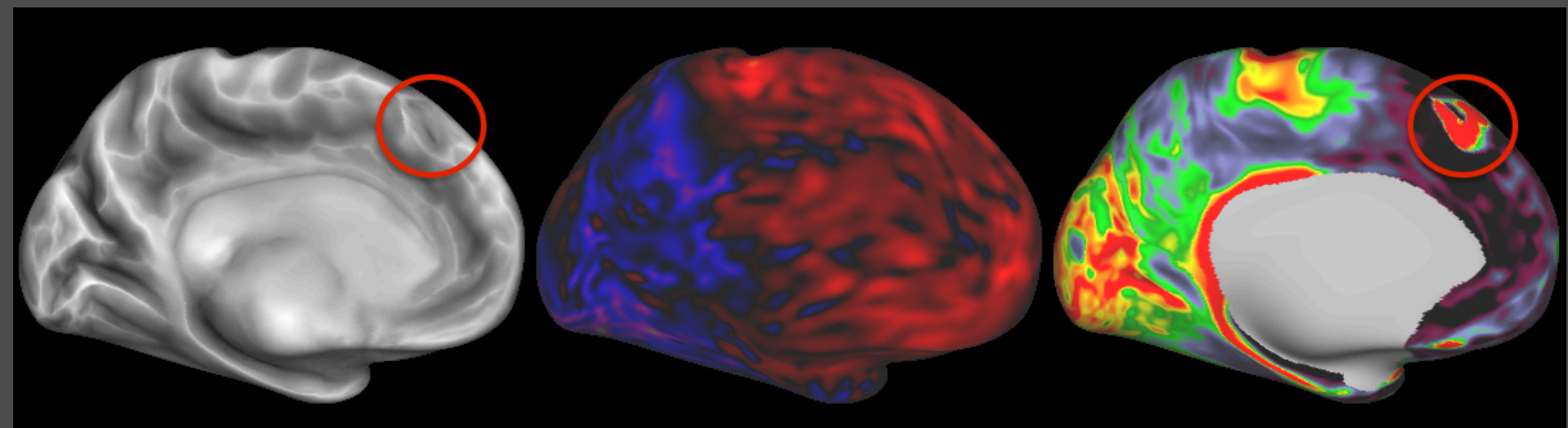
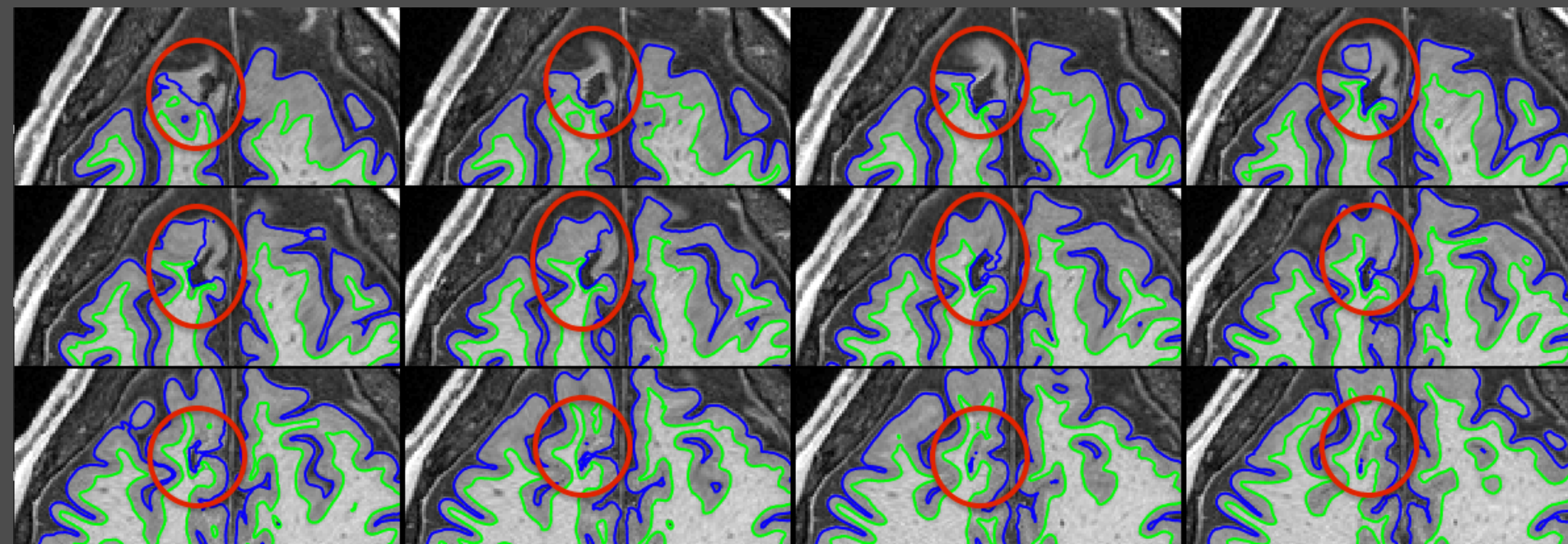
415837 - 500 release - Occipital sulcus error



# 433839 - Small lacuna left frontal lobe

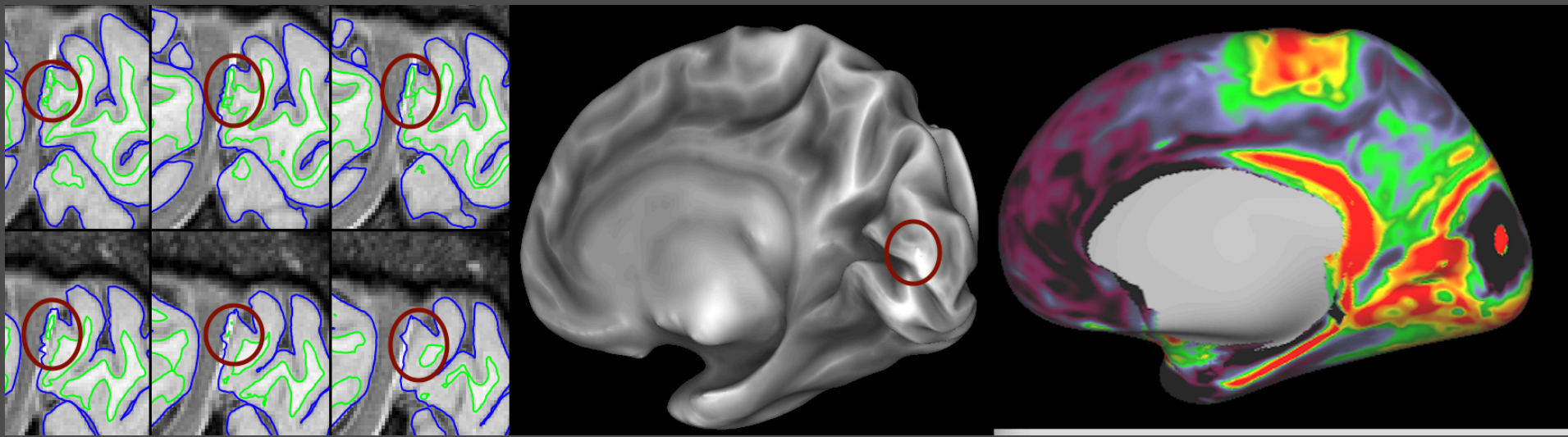


433839 - 500 release - Retest subject

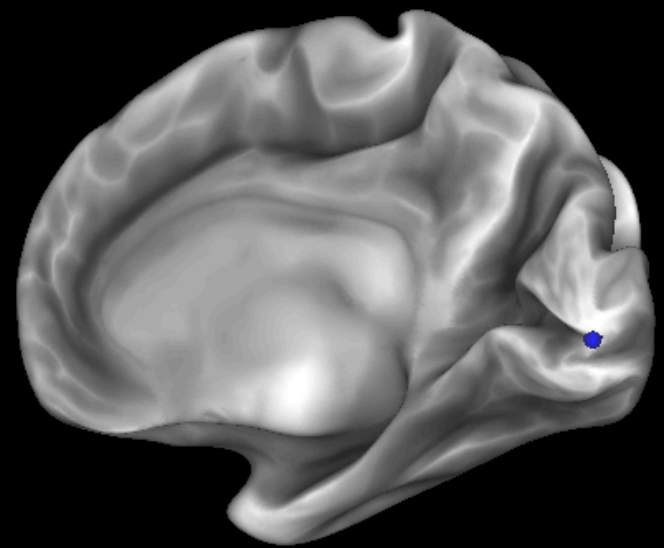
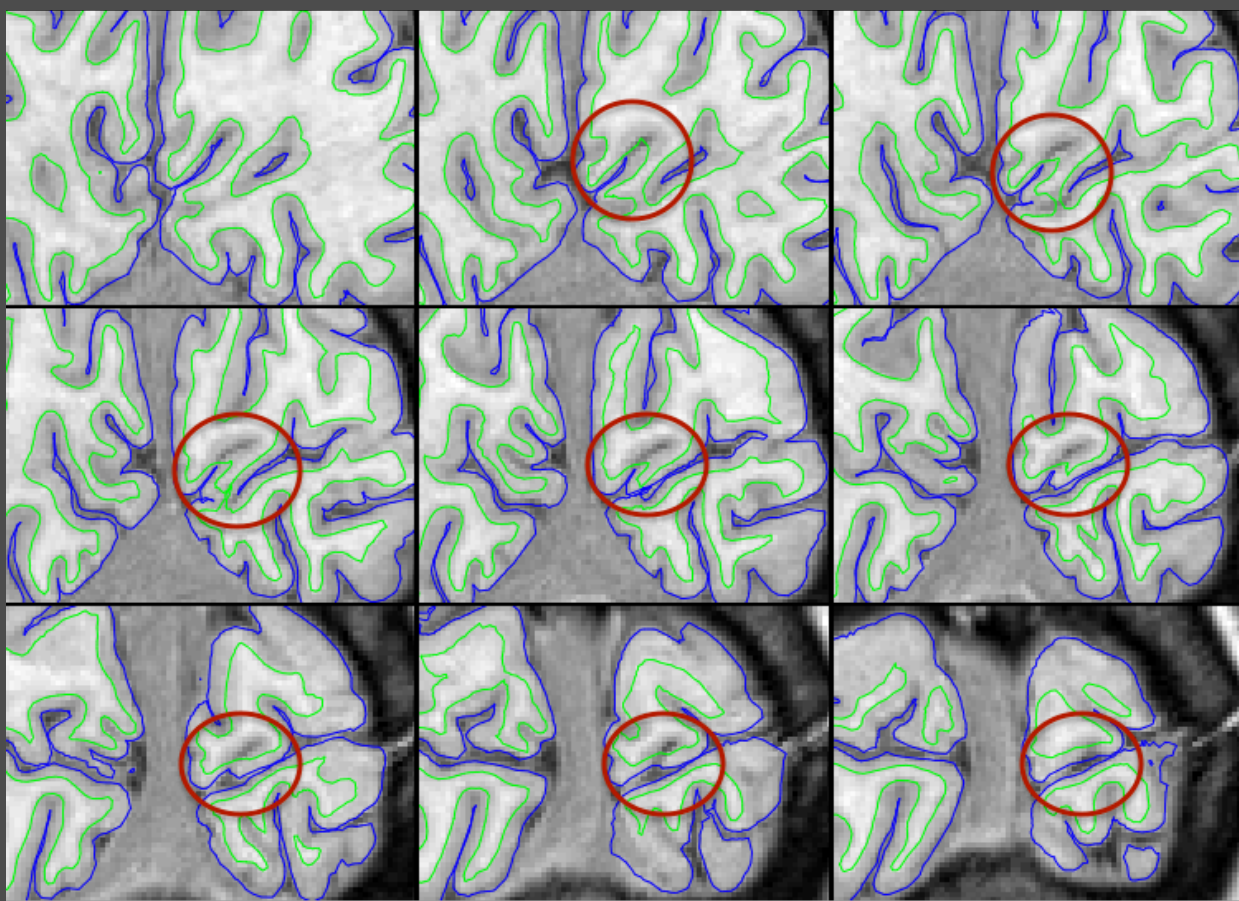




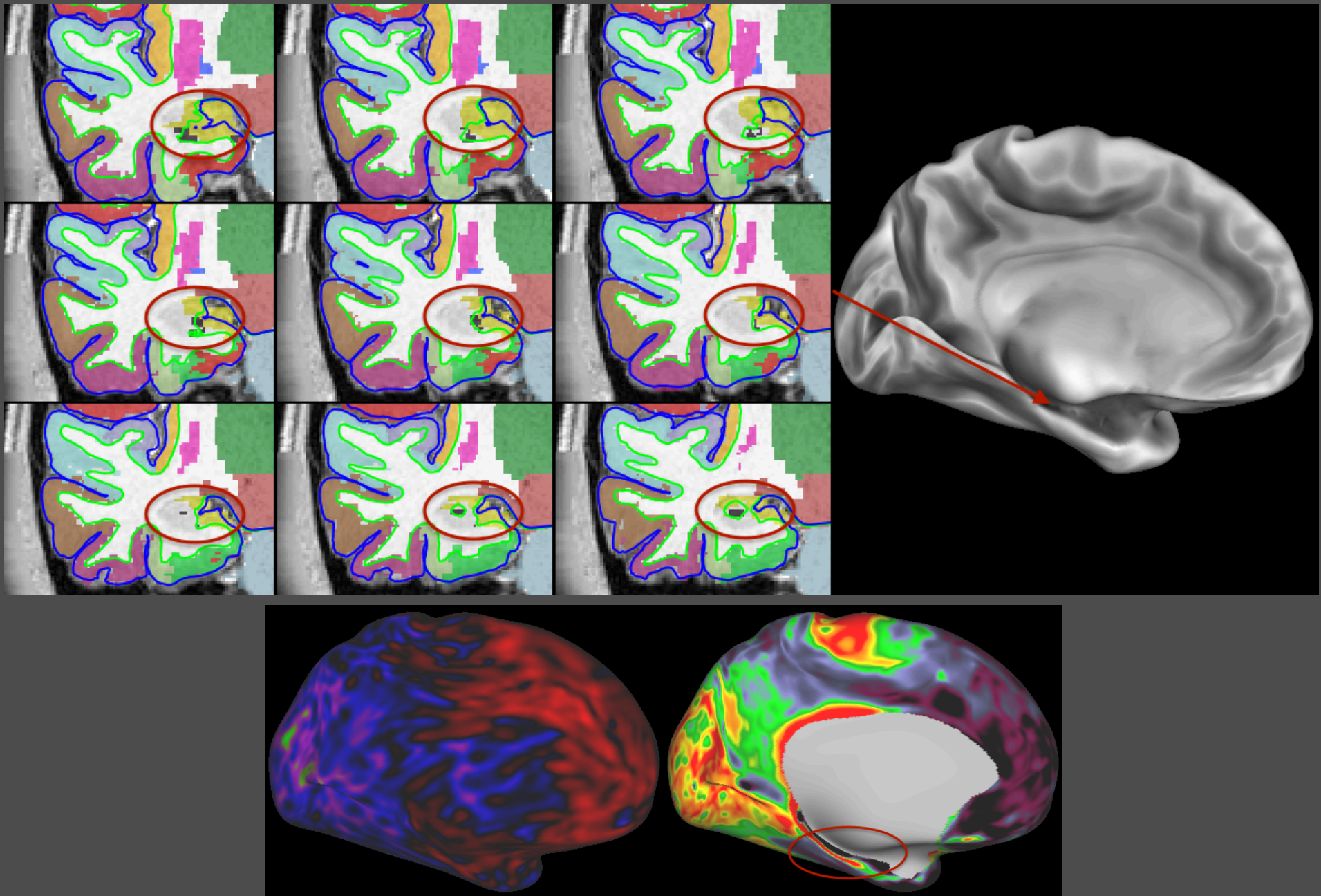
462139 - 1200 release - Myelin map error due to blood vessel inclusion



465852 - 500 release - Occipital sulcus error

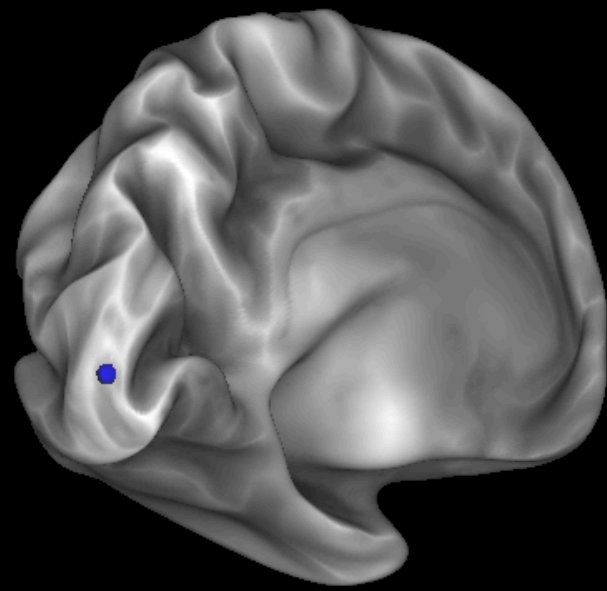
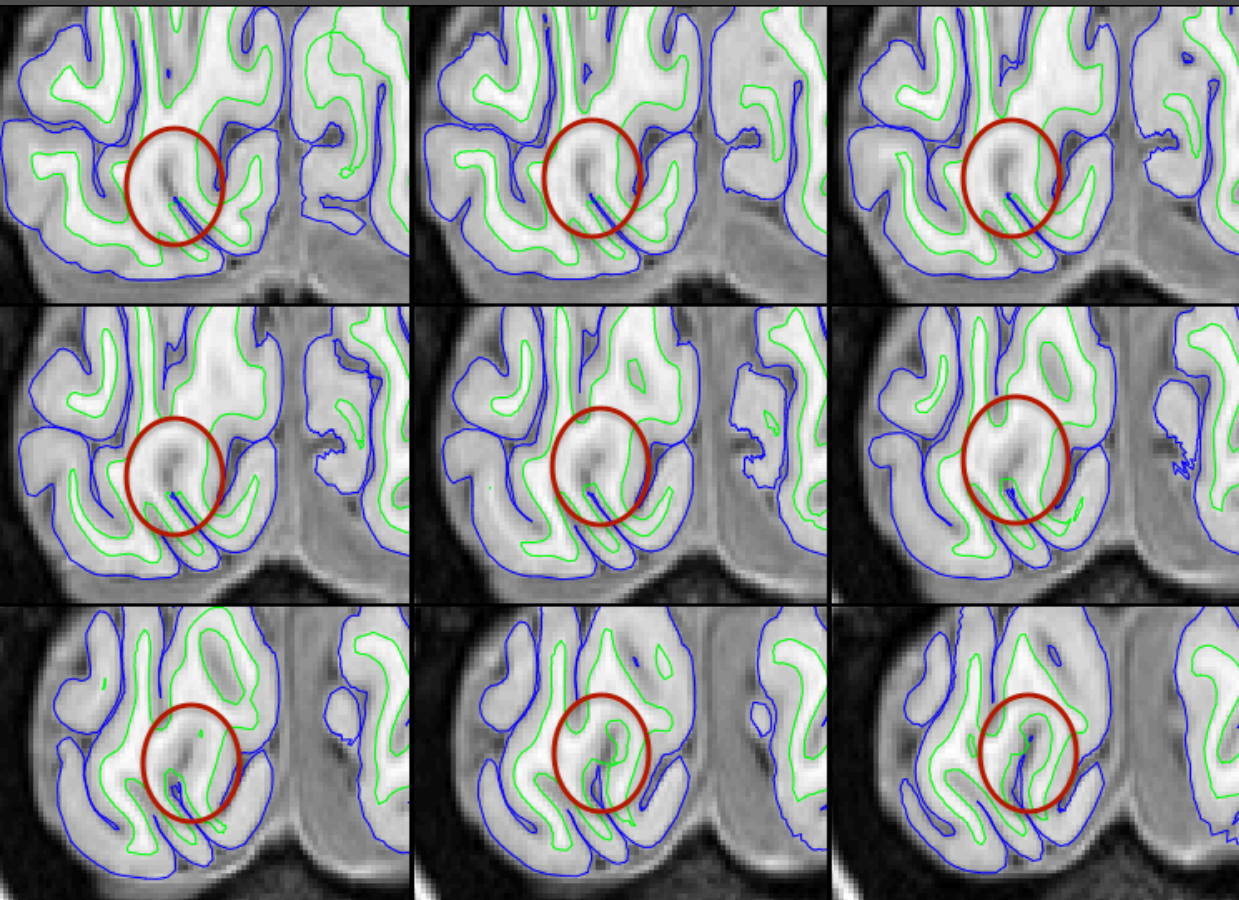


469961 - 1200 release - Inaccurate hippocampal segmentation





644246 - 1200 release - Occipital sulcus error

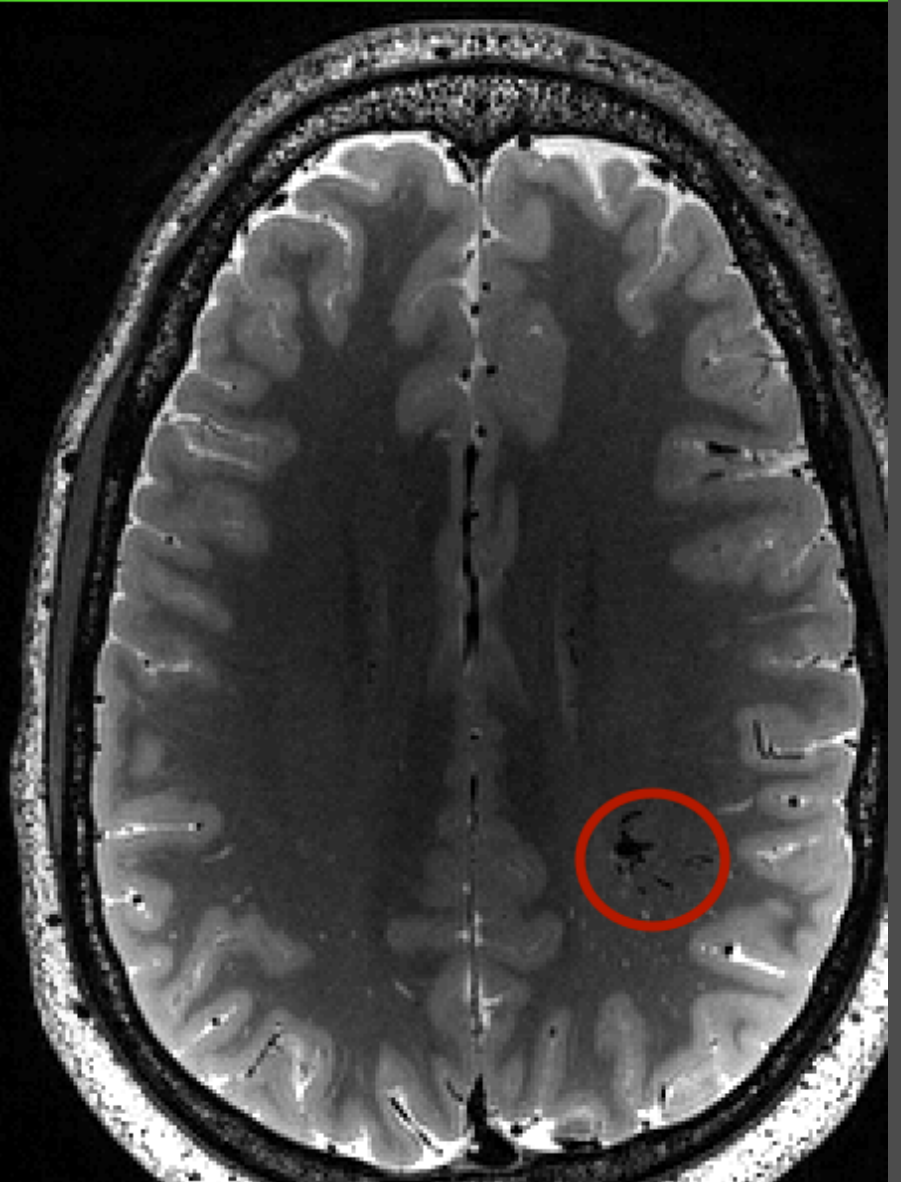
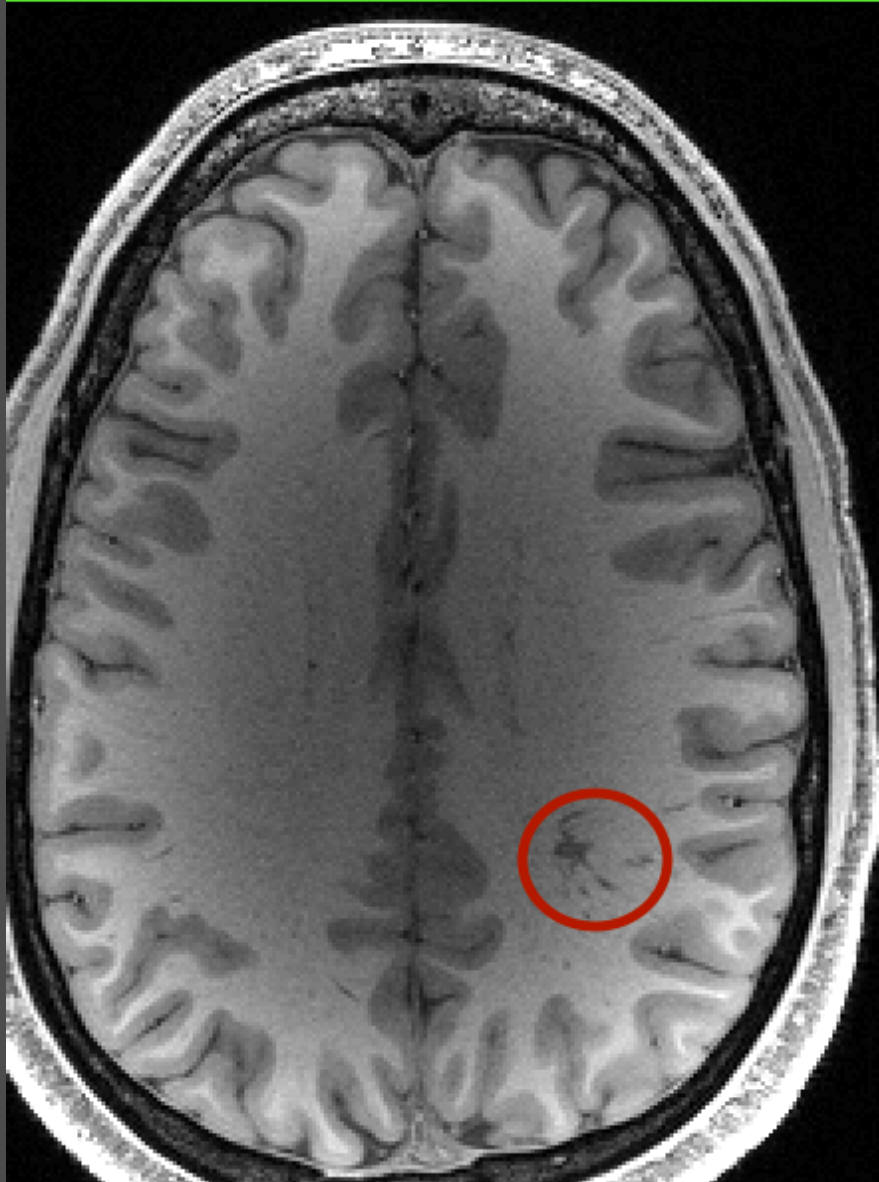



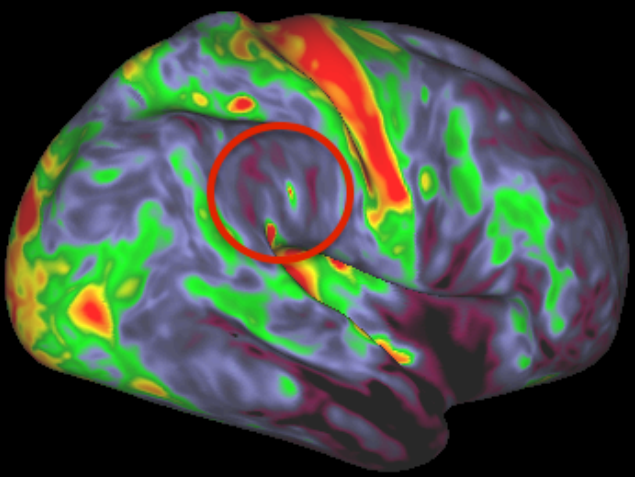
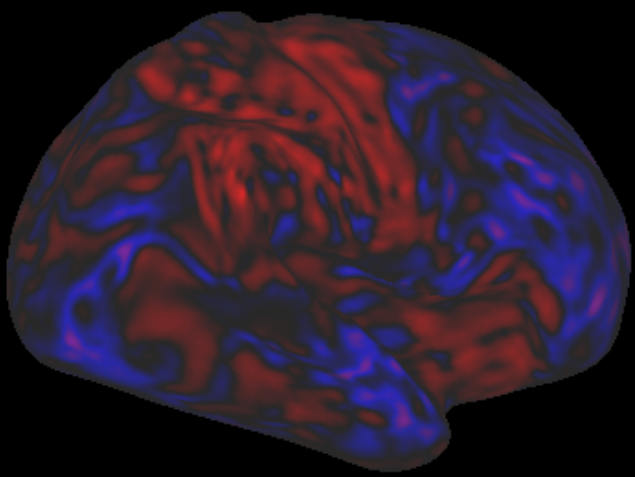
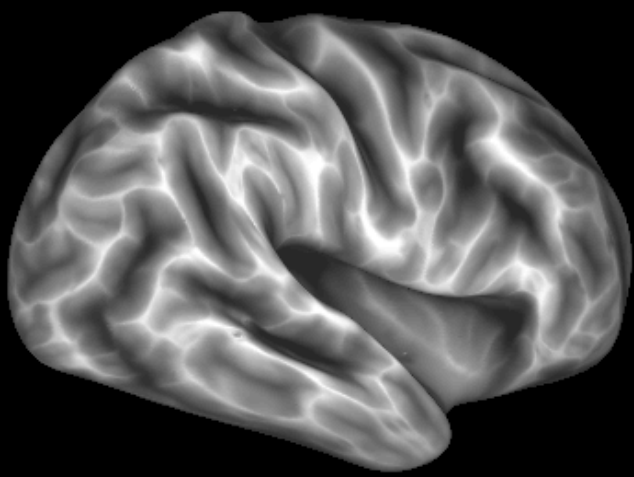
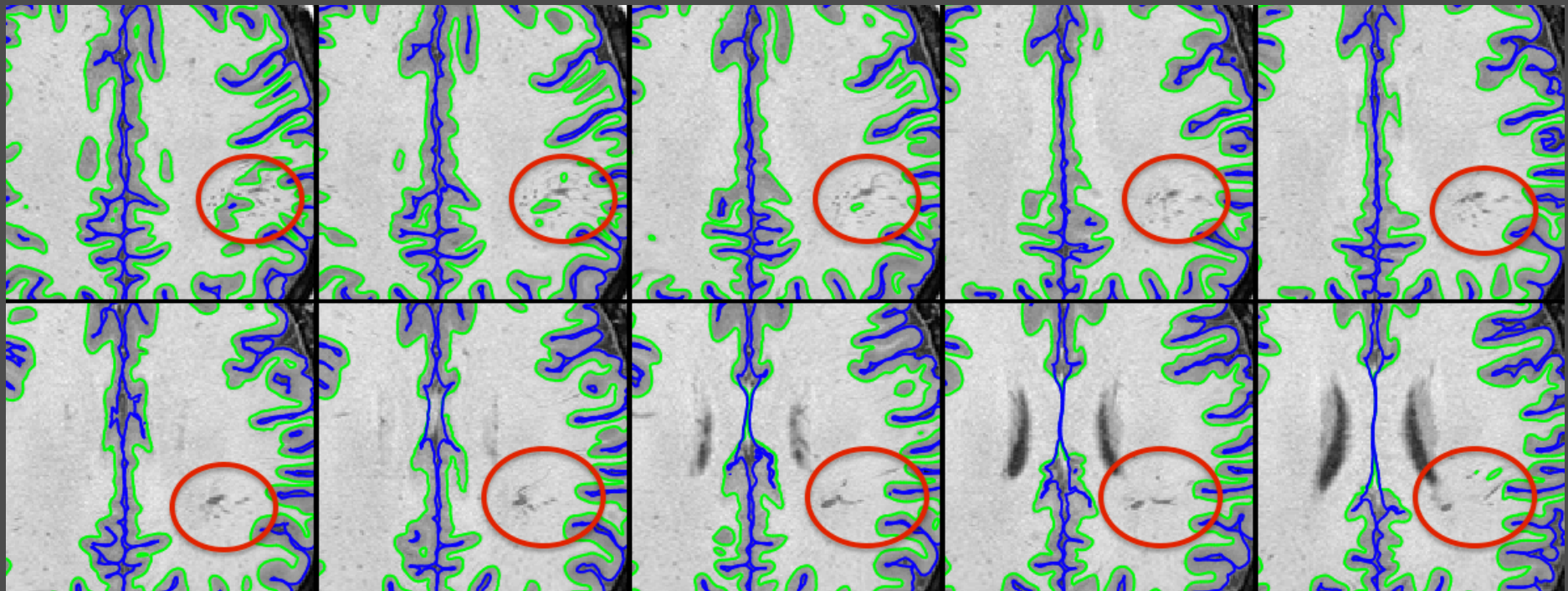
656657 - DVA right parietal

656657\_strc:T1w:RAW:9 - DICOM\_DEFACED:Transverse (200%)

656657\_strc:T2w:RAW:10 - DICOM\_DEFACED:Transverse (200%)

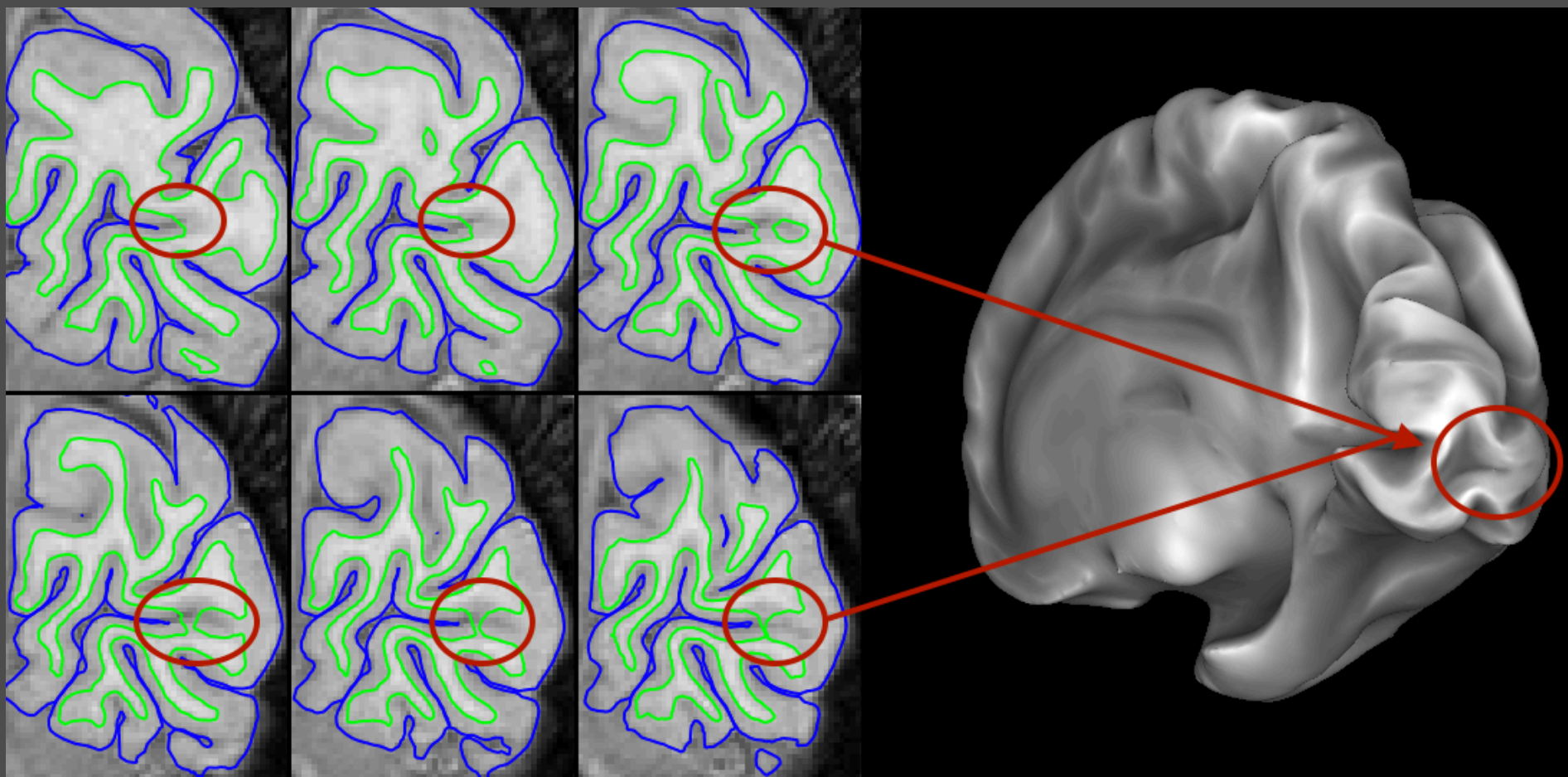


656657 - 900 release

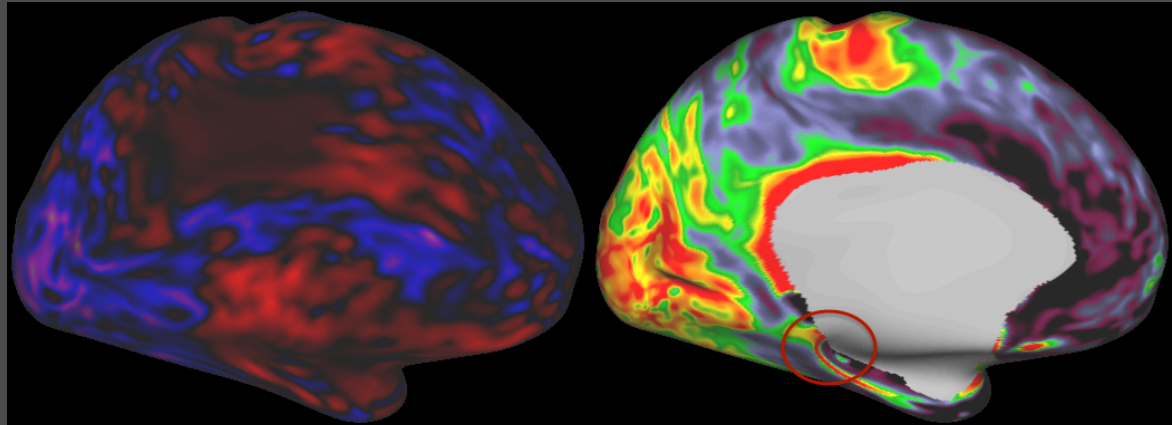
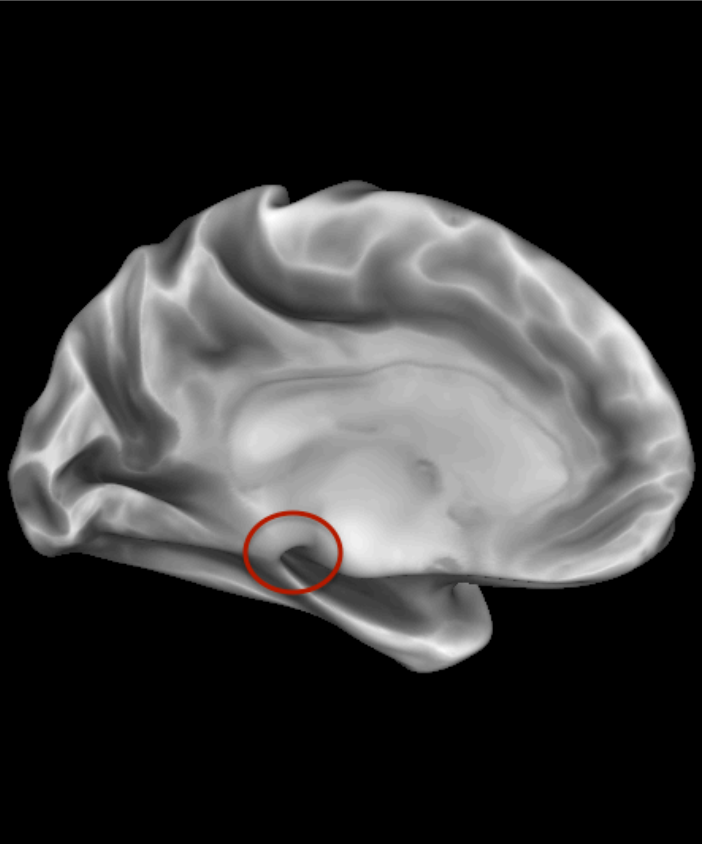
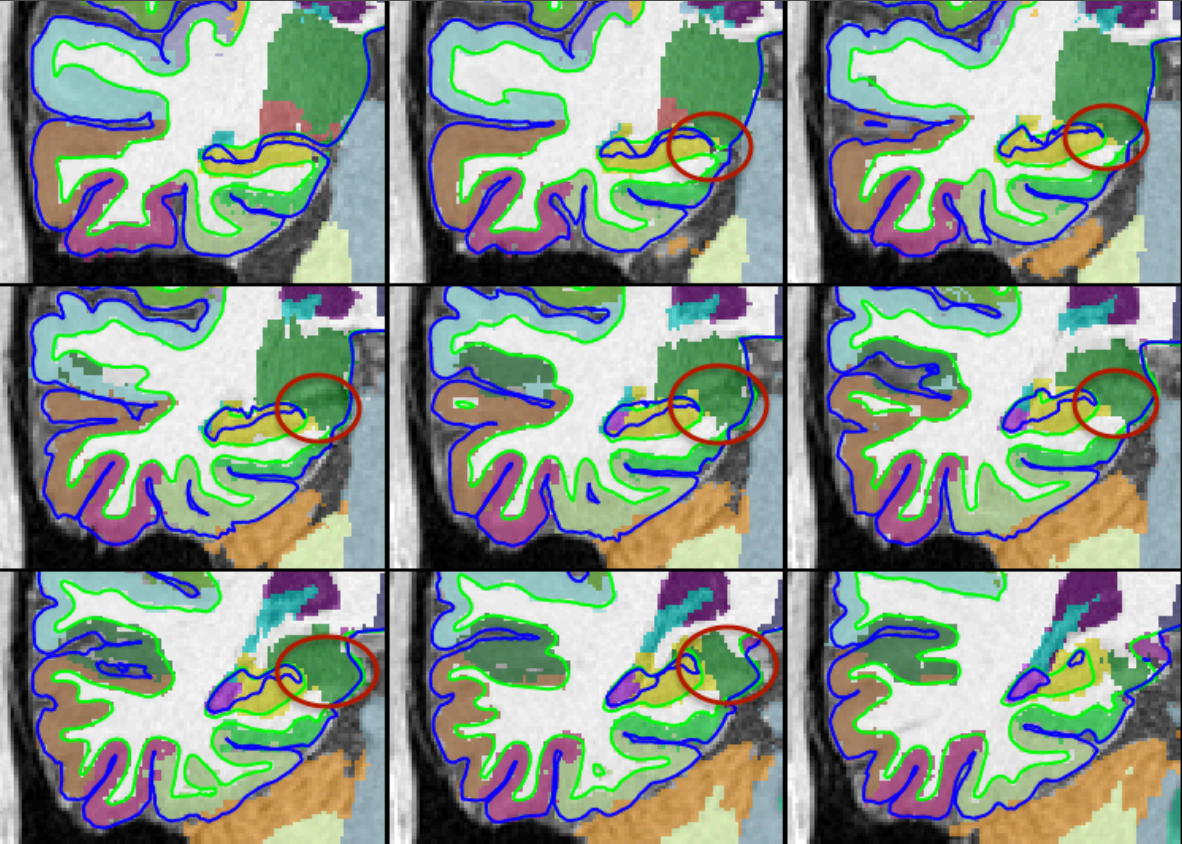




688569 - 900 release - Occipital sulcus error



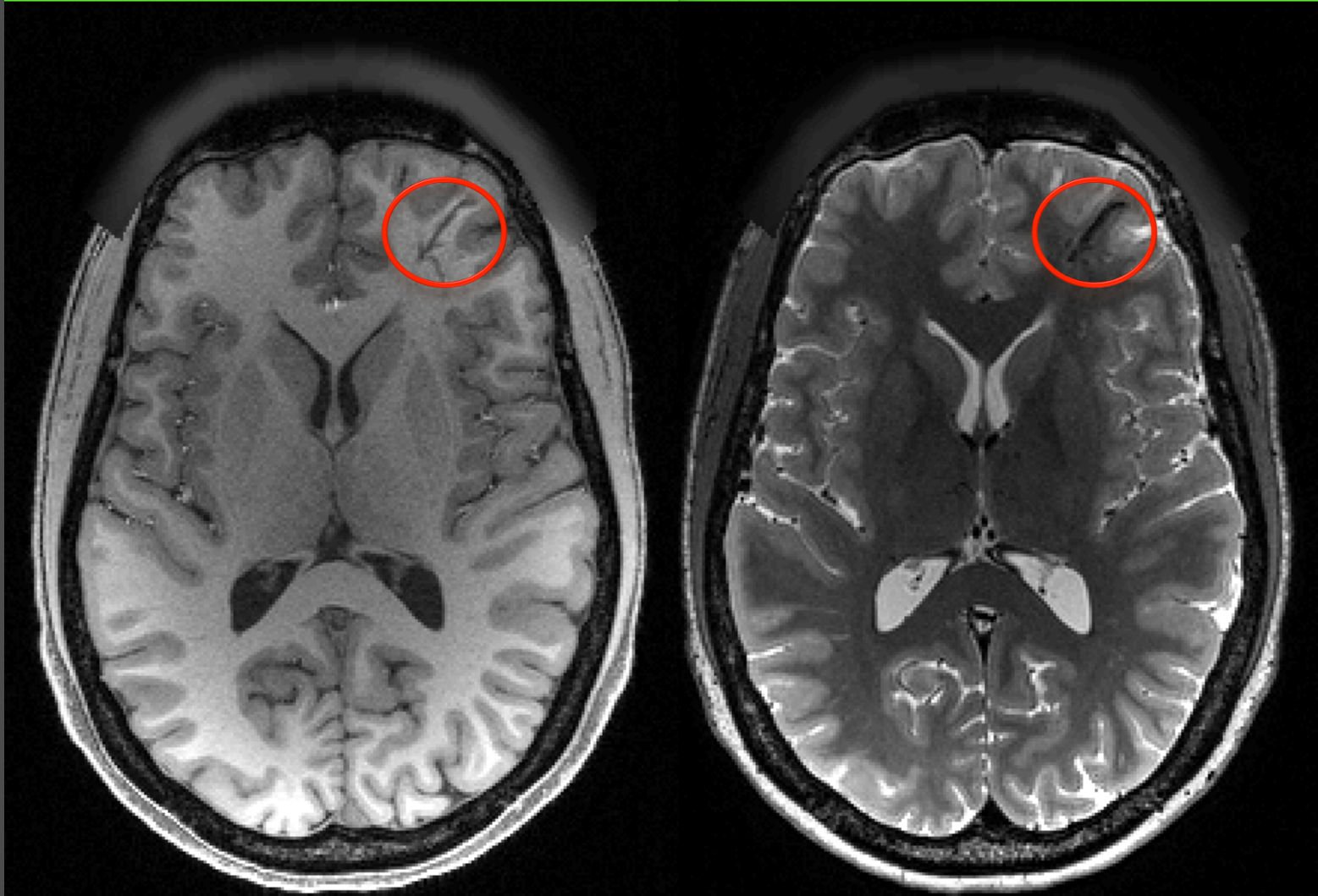
723141 - 1200 release - Inaccurate hippocampal segmentation

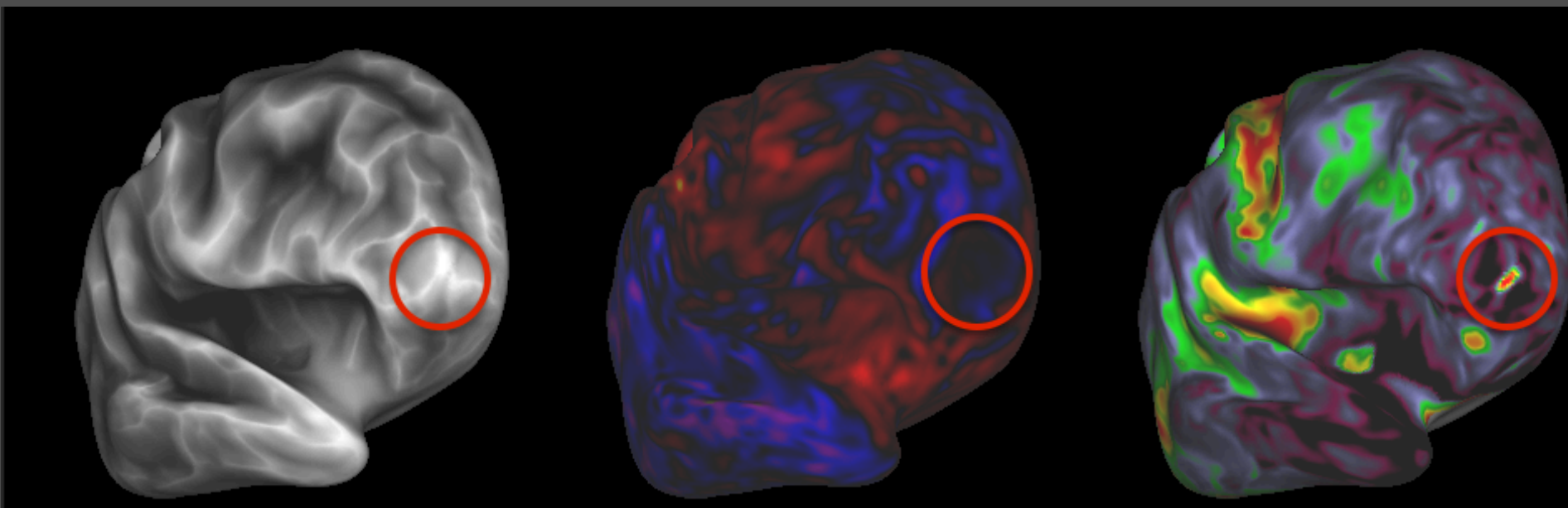
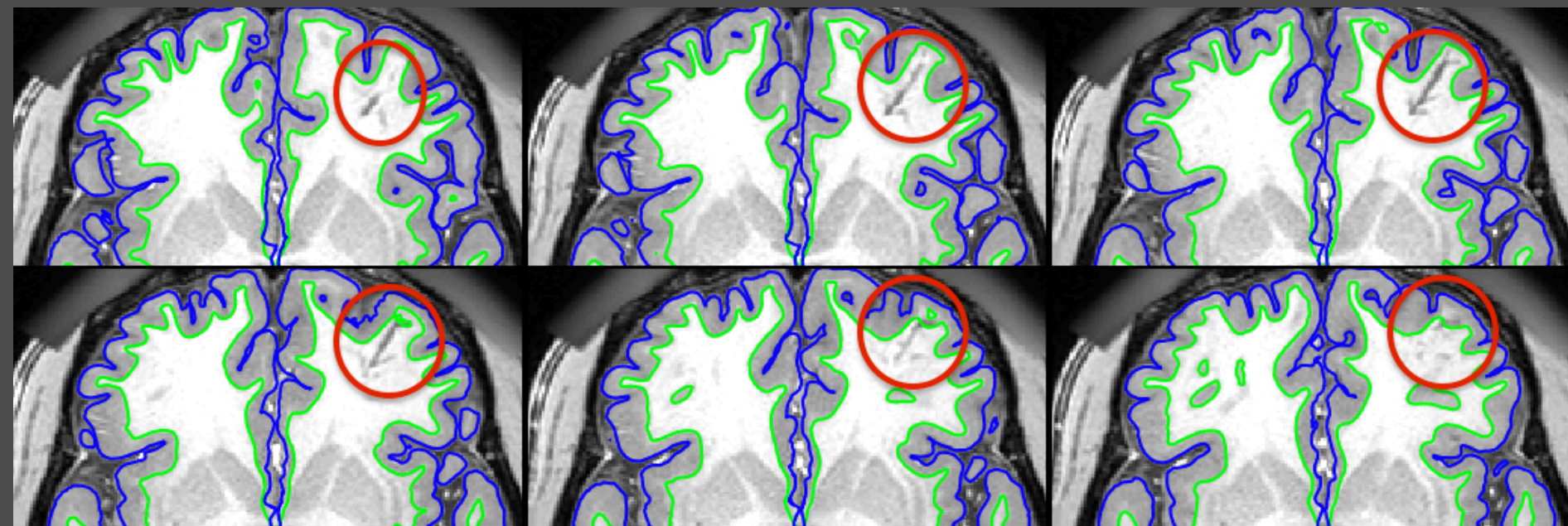




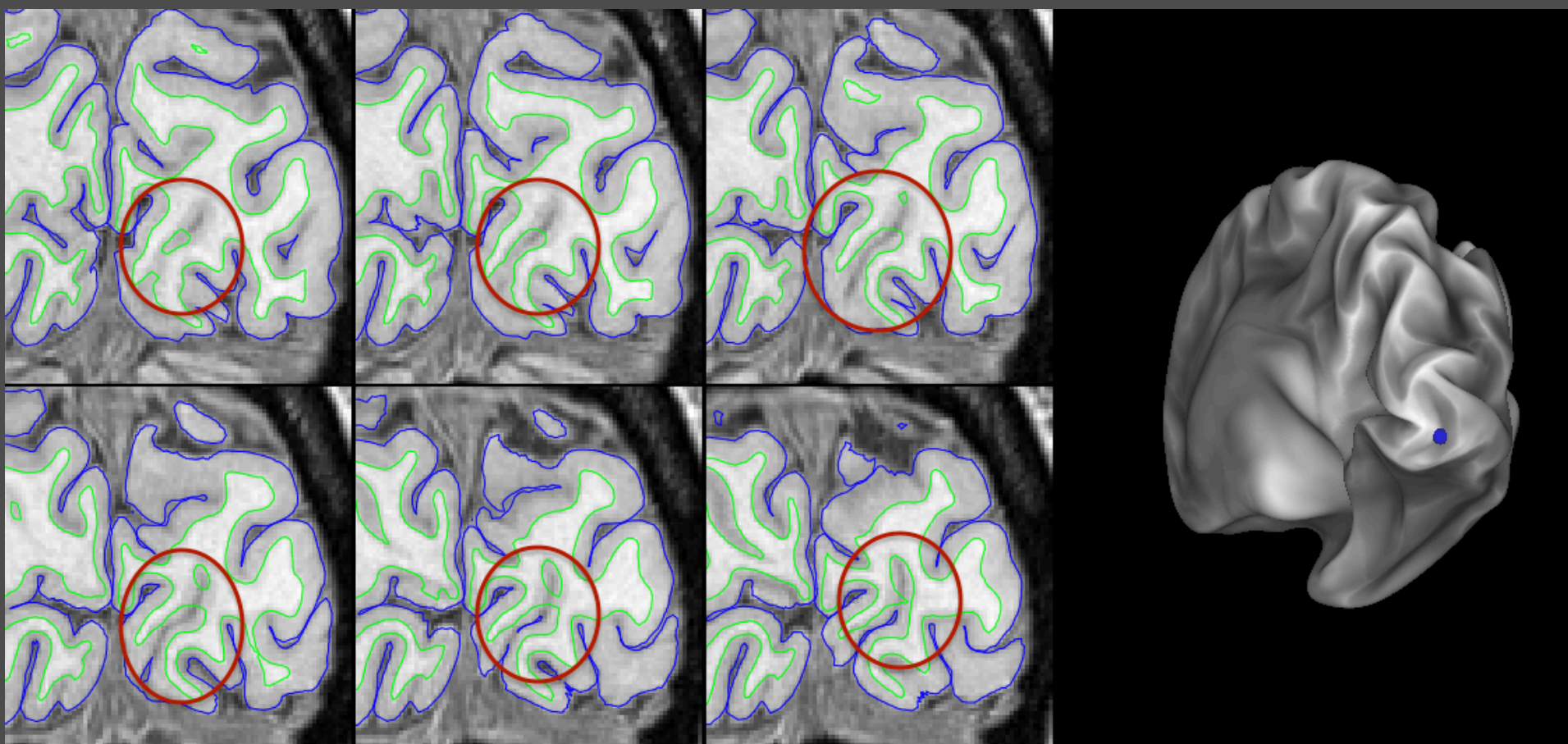
# 767464 - DVA right frontal

767464\_strc:T1w:RAW:9 - DICOM\_DEFACED:Transverse (200%) 767464\_strc:T2w:RAW:10 - DICOM\_DEFACED:Transverse (200%)



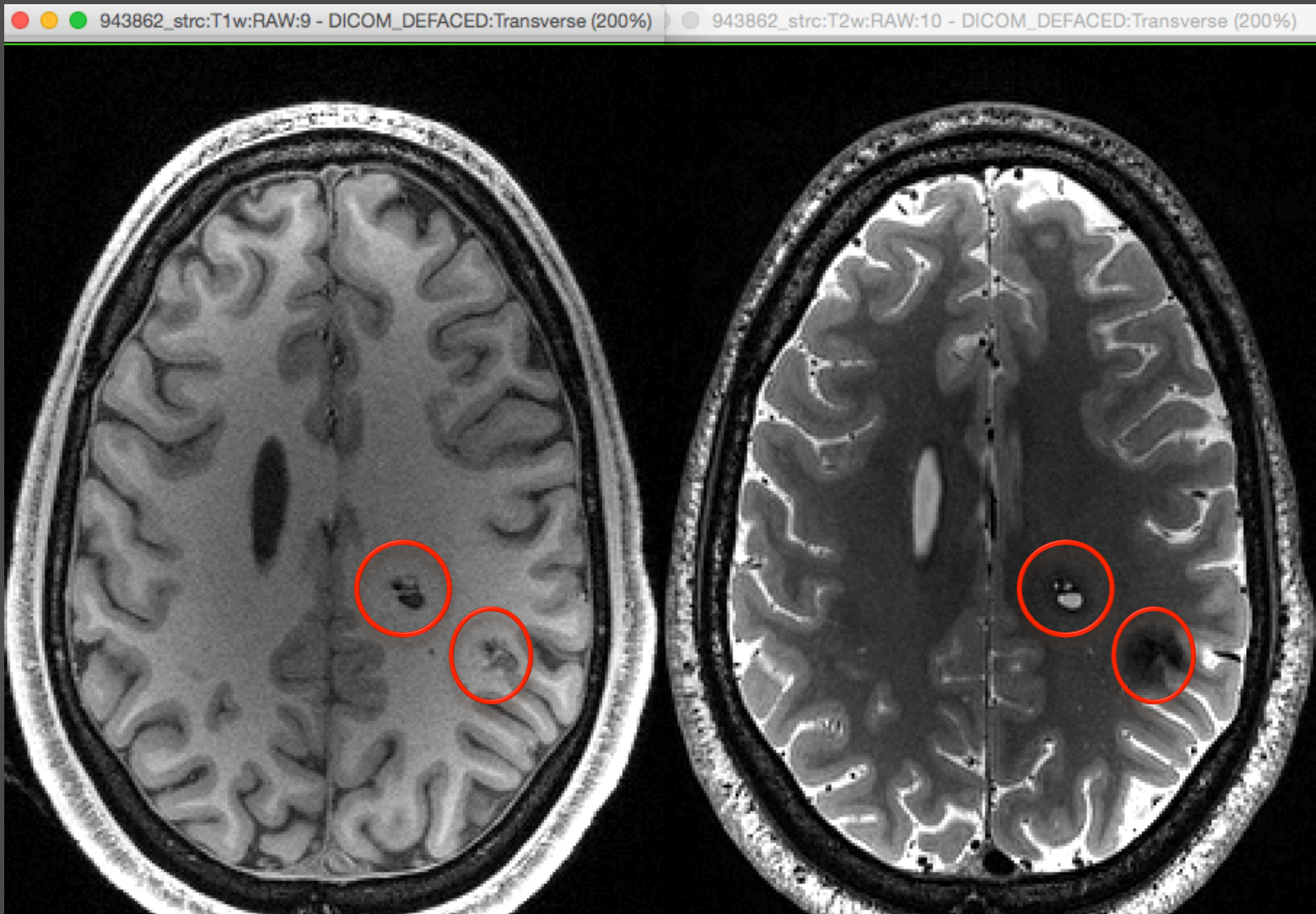


872764 - 500 release - Occipital sulcus error



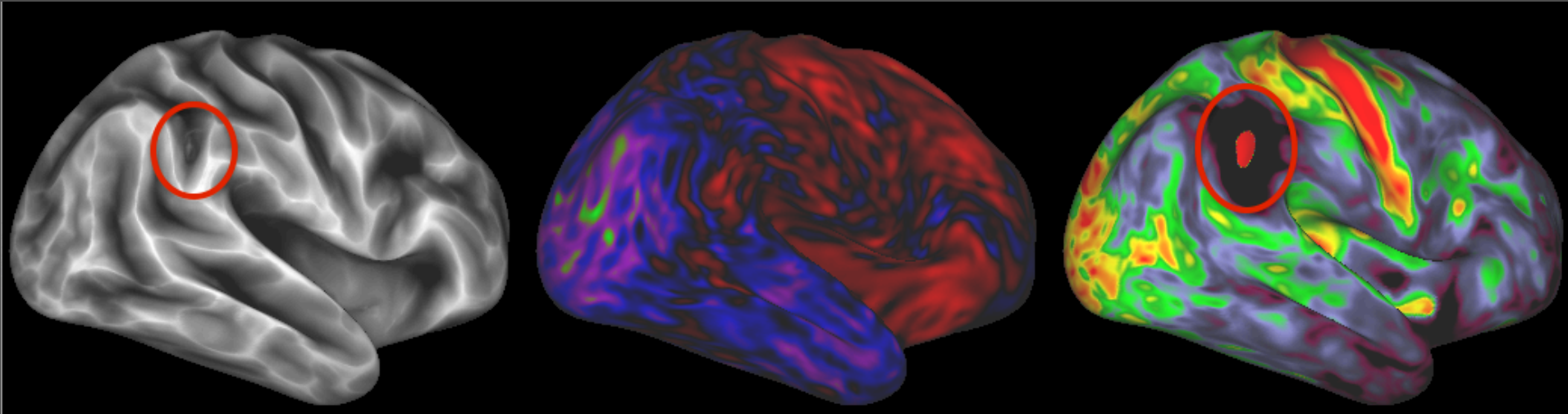
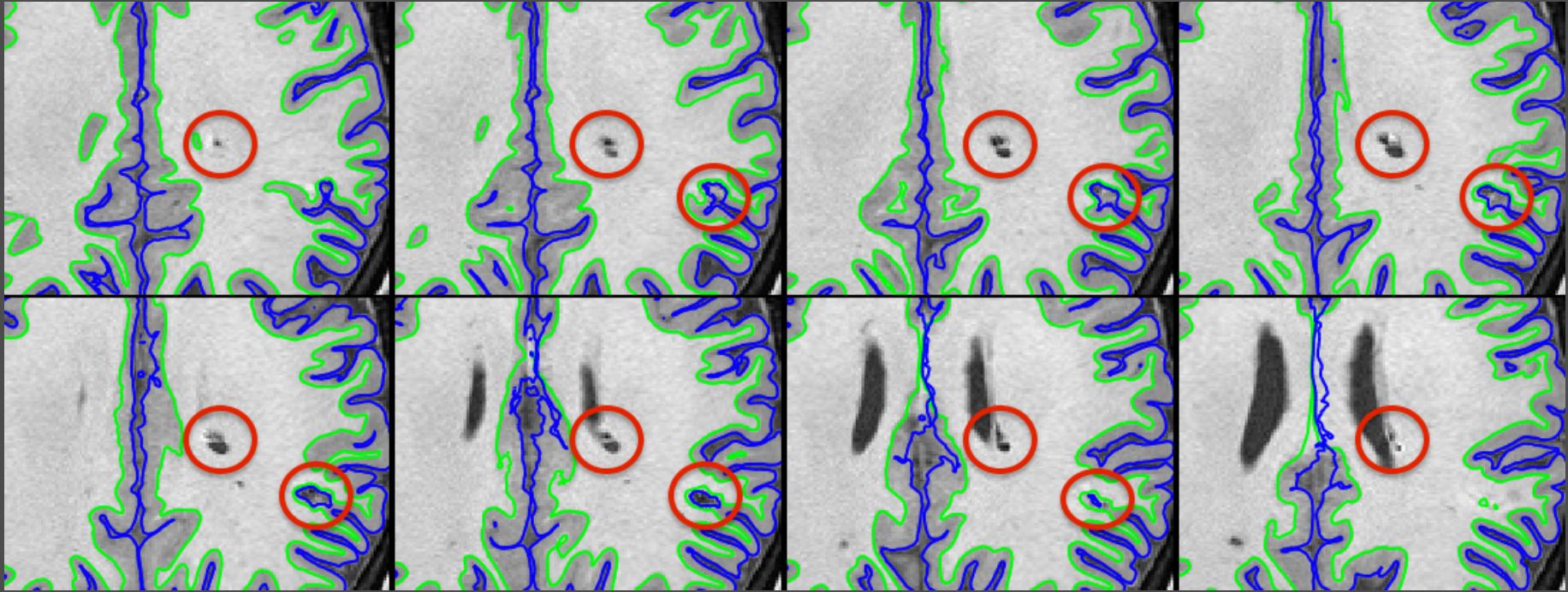


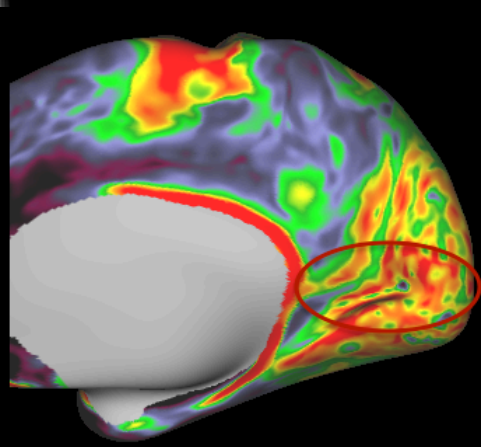
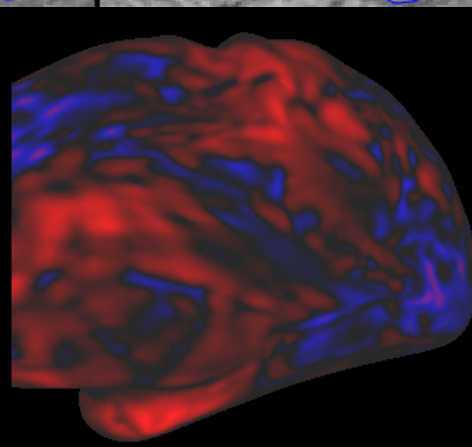
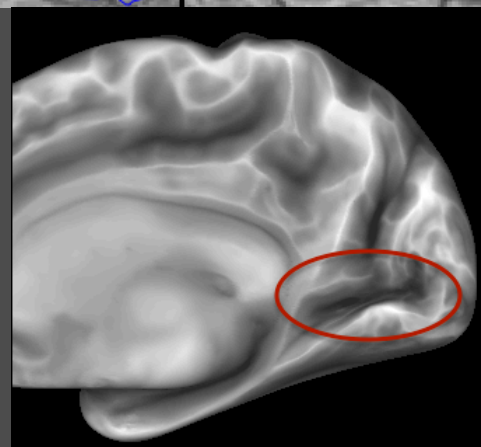
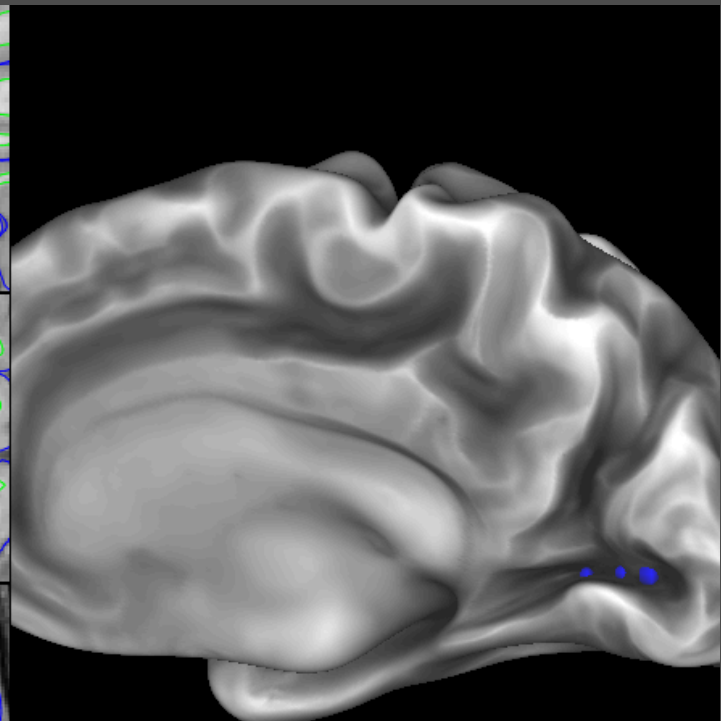
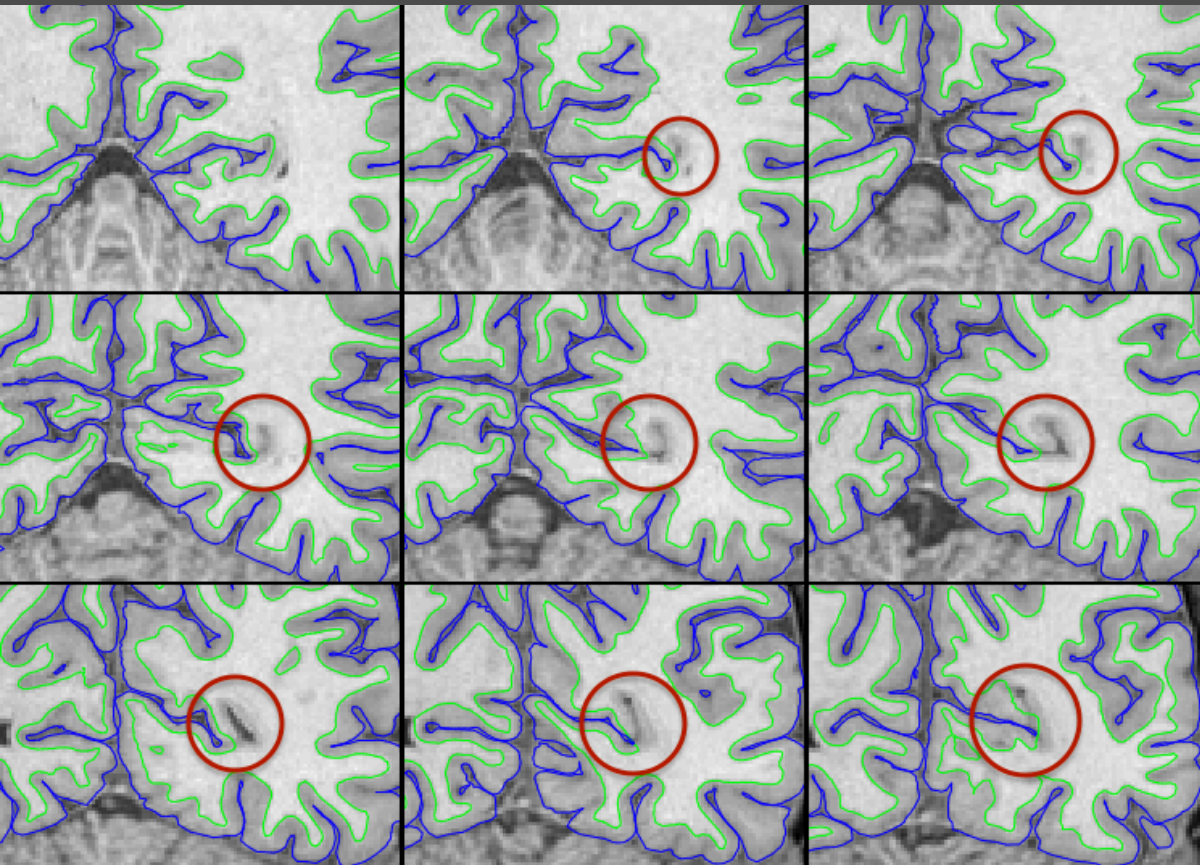
# 943862 - Small cavernomas in right parietal





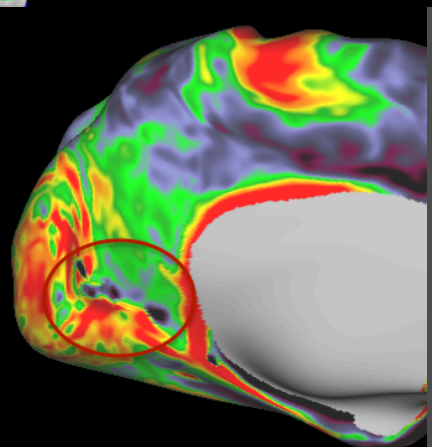
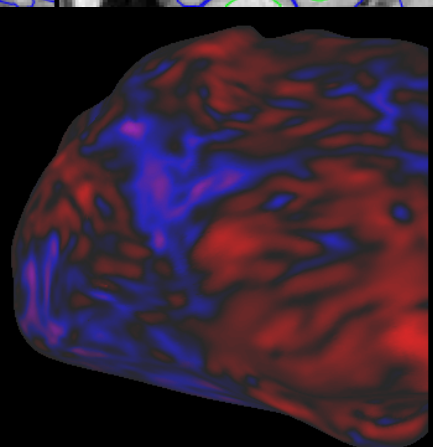
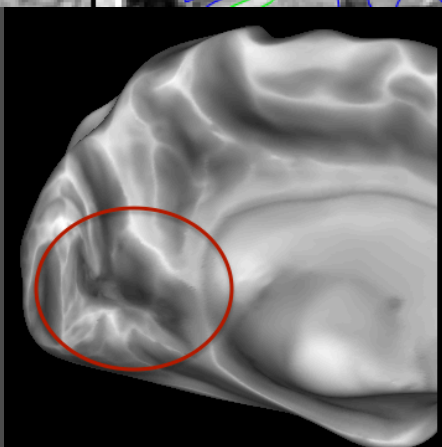
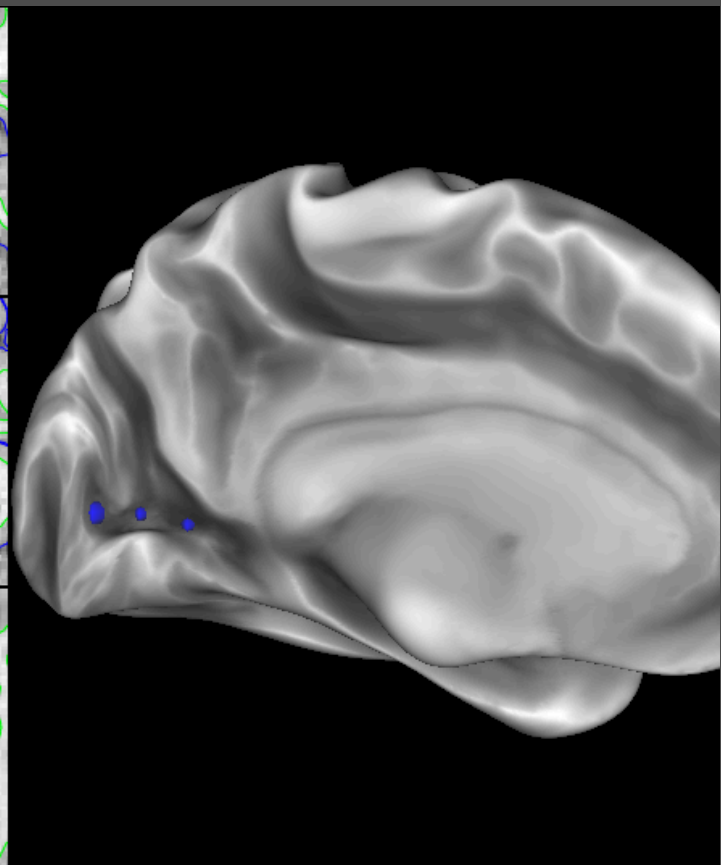
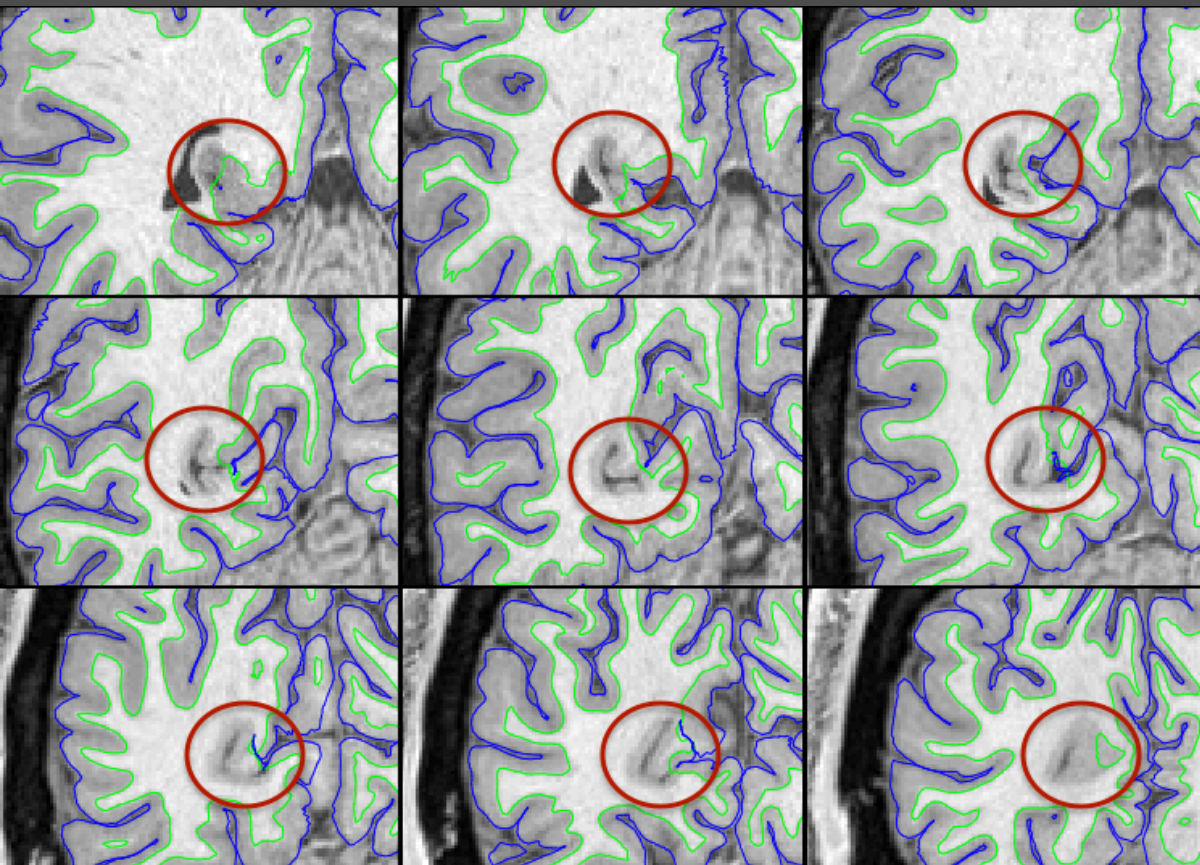
943862 - 1200 release







969476 - 1200 release - Calcarine sulcus error



987983 - 500 release - Myelin map error due to blood vessel inclusion

