Indian Journal of Traditional Knowledge
Vol. 17(4), October 2018, pp. 707-715

Hepatoprotective effects of *Ilex paraguariensis* St. Hilaire (Yerba mate) extract in rats

Seung-Hee Jang[1,2], Md. Akil Hossain[1,3], Jong Suk Lee[4], Md. Ahsanur Reza[5], Sam-Pin Lee[6], JeongWoo Kang[3] & Seung-Chun Park[1]*

[1]College of Veterinary Medicine, Kyungpook National University, Daegu 702-701, Korea;

[2]Institute of Clean Bio, Daejeon 301-212, Korea;

[3]Veterinary drugs & Biologics Division, Animal and Plant Quarantine Agency (QIA), 177, Hyeoksin 8-ro, Gimcheon-si, Gyeongsangbuk-do 39660, Korea;

[4]Biocenter, Gyeonggido Business & Science Accelerator (GBSA), Suwon 16229, Korea;

[5]Faculty of Animal Science and Veterinary Medicine, Patuakhali Science and Technology University (Outer Campus), Babugonj, Barisal-8210, Bangladesh;

[6]The Center for Traditional Microorganism Resources (TMR), Keimyung University, Daegu 704-701, Korea

E-mail: parksch@knu.ac.kr

Received 25 September 2017, revised 31 July 2018

Ilex paraguariensis St. Hilaire has been revealed as an antioxidant, diuretic, hypocholesterolemic, and obesity preventive agent. The objective of the present study was to investigate the hepatoprotective effect of *Ilex paraguariensis* 70 % ethanol extract (IPEE) against carbon tetrachloride-induced liver injury in an animal model. IPEE (200 and 400 mg/kg/day) were administered to rats for 7 days prior to a single dose of CCl_4. Organs were collected for biochemical, histological, and molecular study after 24 h of CCl_4 application. Chromatographic analyses of IPEE were accomplished. The GGT, ALP, ALT and AST in CCl_4-treated control were 9, 32, 401 and 168 % increased, correspondingly than in non-treated control. The SOD, GSH and GPx levels in IPEE-pre-treated rats were similar to non-toxicated control, but were seriously affected in CCl_4-treated control. The IPEE pre-treatment reduced hepatic lesions and necrosis, and expressions of *PPARα* and *CYP4A2* were recovered about 48 % by 400 mg/kg/day of IPEE-pre-treatment. We found 6 major compounds, including cynarine and chlorogenic acid, and the extract was appeared to be non-toxic in acute toxicity study. This study indicates the protective effect of IPEE against CCl_4-associated liver injury by attributing its control on *PPARα*, *CYP4A2* regulation, and thereby it could be an opportunistic agent.

Keywords: Hepatoprotective activity, Antioxidant activity, *Ilex paraguariensis,* Yerba Mate, Oxidative stress.

IPC Int. Cl.[8]: A61K 36/00, A61P 1/16, C09K 15/00, Bo1J 19/16, A01D 7/31, A01D 7/54

The liver is one of the major organs in the body that predominantly controls the metabolism of endogenous as well as exogenous agents. This vital organ performs a significant function in the evacuation and detoxification of drug materials. The impaired function of liver associated with the exposure of xenobiotics, drug substances, toxins is known as hepatotoxicity[1]. Hepatotoxicity is the major health problem worldwide which represents 38 % of all hepatic disorders[2]. Hepatotoxic agents can react with the basic cellular components and consequently induce almost all types of liver lesions. Thus, hepatotoxicity has become a global problem since we are exposed to various toxic chemicals, and about 20000 deaths occur every year because of liver disorders[3].

The treatment options of hepatotoxicity are not sufficient enough even though, the incidence is occurring frequently with a high rate of morbidity and mortality. To date, the progression of hepatic failure associated with hepatotoxicity could not be efficiently prevented by means of a particular drug therapy. Although, there are some drugs using currently to manage chronic liver diseases are not free of side effects. It was reported that oxidative stress plays an important role in drug induce hepatotoxicity, and antioxidants appear to act against disease processes by increasing the levels of endogenous antioxidant

*Corresponding author

enzymes and by reducing lipid peroxidation[4]. Plants are the vital source of natural antioxidants that might be an opportunistic treatment option for the effective suppression of liver toxicity. Moreover, the investigation of suitable herbal drug that might be capable to replace the chemical one is the crucial exploration[5].

Ilex paraguariensis St. Hilaire ("Mate"or "Yerba mate") is a widely consumed non-alcoholic beverage in countries of South America, including Paraguay, Argentina, southern Brazil and Uruguay, and is gaining rapid introduction into the world market, either as tea itself or as an ingredient in formulated foods or dietary supplements[6]. *Ilex paraguariensis* tea, an infusion made from the leaves of the plant, is rich in many phytochemical compounds including caffeine (matein), theobromine, luteolin, rutin, saponins, quercetin, and derivatives of caffeoylquinic acid and dicaffeoylquinic acid[7]. It is used as a traditional medicine in Paraguay and Brazil, Spain and Portugal for the treatment ranging from arthritis to digestive disorders[8]. The scientific literature has been reporting the health benefits of *Ilex paraguariensis*, which include choleretic, diuretic, hypocholesterolemic, antirheumatic, antithrombotic, anti-inflammatory, antiobesity, cardioprotective effects and DNA oxidation[9]. Recently, it was reported that an extract of the plant inhibited copper-induced low density lipoprotein oxidation in human plasma, suggesting that some compounds present in the extract could increase the plasma aqueous-phase antioxidant capacity[10].

Thus, the present study was designed to determine the effect of *Ilex paraguariensis* extract in the protection of CCl_4-induced liver damage in rat. The possible mechanism of hepatoprotective effect of this plant extract was also aimed to evaluate in this investigation. Moreover, the *in vivo* acute toxicity study of this extract in rat and the identification of major components from the extract were carried out.

Materials and methods

Chemicals and reagents

Ethanol, sylimarin (SM) and carbon tetrachloride (CCl_4) were purchased from Sigma-Aldrich Chemical Co. (St Louis, MO) and preserved at their respective storage conditions.

Plant material and preparation of IPEE

The dried leaf (1.5 mm cut) of *Ilex paraguariensis* St. Hilaire which is locally known as "*Mate*"or "*Yerba mate*" was collected from Nature Industry Co., LTD (Jeollanamdo, Korea). The specimen voucher number was LVPP2016010, and the specimen was checked and confirmed by Sang Jae Lee of Department of Horticulture. One part of dried *Ilex paraguariensis* was suspended in 10 parts of 70 % ethanol, and boiled at 85 °C for 5 h. The supernatant was collected by passing through a filter paper. The extract was concentrated in a rotary evaporator (BüchiRotavapor R-114, BÜCHI Labortechnik AG, Flawil, Switzerland) at 80 °C. The concentrated extract was then solidified in a vacuum freeze drier (BioTron, Gangneung, Korea) and stored at -20 °C for further experiments.

Housing of animals

Six weeks old 50 male Sprague-Dawley rats (135 ± 15 g) were obtained from Orient BioInc. (Gyeonggi-do, *Korea*). The animals were acclimatized in a controlled room at 23 ± 3 °C temperature, and 50 ± 10 % of relative humidity with 12 h light/dark cycles for 7 days before experimentation. The animals were allowed to assess the sterile water and standard pellet diet (Hyochang science, Daegu, Korea) *ad libitum*. The animal experimental protocol was approved by the Animal Care and Use Committee of Kyungpook National University, Daegu, Korea (Approval number: KNU2010-3).

Animal experimental design

A total of 50 healthy male rats were randomly divided into 5 experimental groups (10 rats per group) and successively labeled as vehicle control, CCl_4 (Carbon tetrachloride), CCl_4+SM 200, CCl_4+IPEE200, and CCl_4+IPEE 400. The test agents were prepared freshly just before the administration by dissolving the IPEE in distilled water; and CCl_4 in olive oil as 20 % (v/v). IPEE (200 and 400 mg/kg/day), and SM (200 mg/kg/day) were administered orally to rats of respective groups for a period of 7 days. After 1 h of the final drug application, a single dose of CCl_4 was administered to rats of all groups except the vehicle control group. The application volumes of IPEE, SM and CCl_4 (1 mL/kg/day) were calculated earlier, according to the most recently recorded body weight of individual animal.

Necropsy, serum and tissue sampling

All animals after 24 h of CCl_4 treatment were anesthetized with ether, where we intended to evaluate the hepatoprotective effects of the extract in

this study. Despite the many advantages, ether has been gradually replaced by other non-inflammable inhalable anaesthetics[11]. But, the halothane and other halogenated inhalational anesthetic agents, such as enflurane, isoflurane, sevoflurane, and desflurane, are known to cause severe hepatotoxicity[12]. This property of currently using anesthetic agents may hamper the exact outcome of this study. Meanwhile, the injectable anaesthetics require repeated dosing due to their shorter duration of action which can cause a long recovery time and thus inhalable anaesthetics are advantageous compared to injectable anaesthetics particularly for use in laboratory animals[11]. So, without following the current trend, ether is used in our study to support the prime objective. After anesthetizing, blood samples were collected from the abdominal aorta of rats. Blood was centrifuged at 1200 ×*g*, for 10 min in 4 °C temperature to get serum. The separated rat's serum was stored at -20 °C refrigerator prior to biochemical analysis. Afterwards, rats were sacrificed by cervical dislocation and the liver was removed. Extraneous tissues were removed immediately from the liver and carefully dissected into parts. A part of the liver was instantly transferred into 10 % formalin for histopathological study and other parts were preserved in -70 °C refrigerator for further experiments.

Determination of liver function and antioxidant defense enzymes

Hepatotoxicity was assessed by measuring various serum enzymes which are used commonly to evaluate liver functions as gamma glutamyltransferase (GGT), alkaline phosphatase (ALP), alanine transaminase (ALT) and aspartate transaminase (AST). The effect of IPEE on liver function enzymes were determine by using an auto serum analyzer (Thermo Electron, Santa Cruz, CA, United States) according to the instructions of manufacturer.

Liver was thawed, weighed and homogenized in Tris–HCl (5 mmol/L containing 2 mmol/L EDTA, *p*H 7.4) to evaluate the activity of antioxidant defense enzymes include superoxide dismutase (SOD), glutathione (GSH), and glutathione peroxidase (GPx). Homogenates were centrifuged at 10000 ×*g*, for 10 min in 4 °C temperature and the supernatant was used immediately for the analysis of SOD, GSH, and GPx activity. All enzymes were determined by using the diagnostic kit of Randox Laboratories Ltd. (County Antrim, UK) following their instructions.

Histopathological study

The liver sections stored in 10 % solution of buffered formalin were cut into 5 µm thick sections and stained with hematoxylin and eosin (H&E). The stained tissue sections were examined under a light microscope for the determination of histopathological changes. The samples were scanned and analyzed by a pathologist who was blinded to the different treatments in the experiment.

Isolation of hepatic RNA and reverse transcription-PCR (RT-PCR) analysis

Tissue samples of 100 mg from liver sections stored in -70 °C refrigerator were homogenized in 1 mL of trizol reagent by using a Scilogex D160 power homogenizer (Scilogex, LLC., Rocky Hill, CT) and the RNA was extracted. Each sample was reverse-transcribed to cDNA using an AccuPower® RT PreMix (Bio-NEER, Daejeon, Korea). The resultant cDNA products were subjected PCR amplification in presence of specific primers using AccuPower® PCR PreMix (Bio-NEER, Daejeon, Korea). Nucleotide sequences for sense and antisense primers were 5'-TGGAGTCCACGCATGTGAAG-3' and 5'-CGCCAGCTTTAGCCGAATAG-3' for *PPARα*, 5'-GTTATGAAGTGTGCTTTCAGCCA-3' and 5'-CAACAGCCTTGGTGTAGGACC-3' for *CYP4A2*, and 5'-TGGTAACCAACTGGGACGATATGG-3' and 5'-GATCTTGATCTTCATGGTGCTAGG-3' for β-actin, where β-actin was used as internal standard. Each cycle consisted of de-naturation at 94 °C for 60 s, annealing at 50 to 60 °C for 60 s, and extension at 72 °C for 60 s for 35 cycles.

***In vivo* acute toxicity study**

Ten female and ten male Sprague-Dawley rats of 5 weeks old were obtained from Orient BioInc. (Gyeonggi-do, *Korea*). The accommodation and facilities of animals were same as stated in "Housing of animals" section. The acute toxicity study was performed by slightly modifying a previously reported method[13]. Rats of each gender were randomly assigned into control and test groups (5 rats in each group). The single administered dose of IPEE was 5000 mg/kg of body weight which were applied intra-gastrically to the animals. Standard pellet diet (Hyochang science, Daegu, Korea) and tap water were provided as 300 g, and 500 mL, respectively, for each day.

The animals were in constant observation for abnormal signs and symptoms for first 12 h after

the administration of IPEE. They were also observed once a day for 2 weeks. The body weight of each animal was recorded just before the administration of IPEE. The changes of body weight, food and water consumption weight were measured two times in a week for 14 days afterward the treatment. Animals were sacrificed after the experimental period, and major organs were collected and inspected for gross lesions.

Liquid chromatography-mass spectrometry (LC-MS) assay

LC-MS analysis of IPEE was accomplished by Agilent 1100 series LC system (Agilent Technologies, Santa Clara, CA) equipped with a Varian 500MS masss pectrometer (Agilent Technologies, Santa Clara, CA). A Pursuit XRs C18 (2.0 mm × 150 mm, 3 μm) column was utilized at a flow rate of 0.2 mL/min at 40 °C. The mobile phase consist of A (0.1 % formic acid in water) and B (0.1 % formic acid in acetonitrile). The run time for each sample was 60 min, and the mobile phase started with 95 % "A" and 5 % "B" in the first 2 min, then "A" was decreased gradiantly to 0 % until 50 min and held for an additional 5 min. Thereafter, the proportion of "A" was increased to 95 % within 5 min. Compounds were detected by absorption at 254 nm.

Statistical analysis

Results are expressed as mean ± SD of triplicate analysis. Statistical differences among groups were achieved by one way analysis of variance following the Turkey's multiple comparison test by means of Statistical Analysis System (SAS, version: 9.4). Significant differences were indicated by a p-value of less than 0.05.

Results

Effect on liver function enzymes

The outflow of liver function enzymes namely, ALP, ALT, AST and GGT into the serum indicates hepatotoxicity which initiates the damage of liver. The severity of hepatic damage is determined by the amount of these enzymes in serum. Table 1 shows the effect of IPEE pre-treatment on hepatic enzymes in rats that exposed to CCl_4. The treatment of CCl_4 in rats exhibited a significant elevation in the level of ALP, ALT, AST and GGT compared to control animals (not treated with CCl_4). A remarkable suppression in the level of liver function enzymes were observed in CCl_4-treated rats which were pre-treated with IPEE (200 and 400 mg/kg) and SM (200 mg/kg).

Effects on antioxidant activity

The levels of antioxidant enzymes (SOD, GSH and GPx) were determine from the supernatant of rat's liver homogenate in order to verify the effects of IPEE on the activity of these enzymes. The effects of IPEE on different antioxidant enzymes are presented in Table 2. The levels of SOD, GSH and GPx in hepatic tissue of CCl_4-treated rats were lower than CCl_4-nontreated control rats. The antioxidant enzymes were not suppressed in rats pre-treated with SM (200 mg/kg) before CCl_4 intoxication. Similarly,

Table 1 — The effect of IPEE on the level of liver function enzymes of rats

Treatment groups	GGT (U/L)	ALP (U/L)	ALT (U/L)	AST (U/L)
Control	5.77 ± 0.66^{b}	40.15 ± 4.23^{b}	34.22 ± 4.22^{b}	111.12 ± 17.54^{b}
CCl_4	6.30 ± 0.87^{a}	53.19 ± 5.56^{a}	171.28 ± 32.38^{a}	297.89 ± 42.78^{a}
CCl_4+SM (200 mg/kg)	5.97 ± 1.00^{b}	41.87 ± 4.11^{b}	66.97 ± 30.14^{ab}	263.78 ± 54.70^{ab}
CCl_4+IPEE (200 mg/kg)	6.04 ± 0.96^{b}	47.19 ± 6.81^{b}	133.30 ± 41.89^{ab}	302.88 ± 29.87^{a}
CCl_4+IPEE (400 mg/kg)	5.65 ± 1.70^{b}	42.56 ± 6.28^{b}	104.31 ± 20.86^{ab}	202.27 ± 51.21^{ab}

ALP, alkaline phosphatase; ALT, alanine transaminase; AST, aspartate transaminase; GGT, gamma glutamyltransferase; IPEE, *Ilex paraguariensis* 70 % ethanol extract; SM, sylimarin. [a] different from control ($p < 0.05$), [b] different from CCl_4 group ($p < 0.05$).

Table 2 — The effect of IPEE on hepatic antioxidant enzymes in CCl_4-treated rats

Treatment Groups	SOD (%)	GSH (μmol NADPH/min/μg protein)	GPx (mmol NADPH/min/μg protein)
Control	47.2 ± 1.6^{b}	62.3 ± 9.9^{b}	2.09 ± 0.18^{b}
CCl_4	16.9 ± 3.5^{a}	12.1 ± 3.3^{a}	0.14 ± 0.012^{a}
CCl_4+SM (200 mg/kg)	33.6 ± 3.3^{b}	39.8 ± 9.7^{ab}	1.87 ± 0.52^{b}
CCl_4+IPEE (200 mg/kg)	28.4 ± 6.5^{a}	82.5 ± 13.8^{b}	1.12 ± 0.43^{ab}
CCl_4+IPEE (400 mg/kg)	47.2 ± 8.4^{b}	81.3 ± 3.9^{b}	1.85 ± 0.23^{b}

GPx, glutathione peroxidase; GSH, glutathione; IPEE, *Ilex paraguariensis* 70 % ethanol extract; NADPH, nicotinamide adenine dinucleotide phosphate; SOD, superoxide dismutase; SM, sylimarin. [a]Different from control ($p < 0.05$), [b]Different from CCl_4 group ($p < 0.05$).

compared to CCl_4-treated rats the levels of SOD, GSH and GPx were not significantly suppressed in IPEE (400 mg/kg), IPEE (200 and 400 mg/kg) and IPEE (200 and 400 mg/kg) pre-treated rats, respectively. Even, the GSH level was higher in IPEE (200 and 400 mg/kg)-treated rats than CCl_4-non-treated control rats. More specifically, the levels of SOD, GSH and GPx were about 3-, 7-, and 13-fold higher, respectively, in (CCl_4+ IPEE 400 mg/kg) treated animals compared to CCl_4-treated control, which were similar in CCl_4-nontreated control animals.

Histopathological evaluation

Histopathological assessment of liver section from the control group showed normal hepatic tissue with regular shape of cells and sinusoid around central vein. In contrast, the animals treated with CCl_4 showed prominent changes typical of liver damage, including disruption of cell and sinusoid, necrosis, infiltration of macrophages and fatty change, (Fig. 1). Qualitatively, the hepatic lesion treated with IPEE (200, 400 mg/kg) showed a less severe lobular pattern with a mild degree of necrosis, infiltration of macrophages almost comparable to the silymarin-treated group.

Effects on mRNA expression

A semi-quantitative RT-PCR was conducted to determine the genetic mechanism of IPEE against CCl_4-associated liver toxicity in rats, and is presented in Fig. 2. The mRNA expression of *PPARα* was noticeably reduced in CCl_4-treated hepatotoxic group (Fig. 2B). The expression of *PPARα* was increased significantly in (CCl_4 + IPEE 400 mg/kg) and (CCl_4 + SM 200 mg/kg) treated groups, but there was no change in (CCl_4 + IPEE 200 mg/kg) rats compared with hepatotoxic (CCl_4) group. The mRNA level of *PPARα* was increased 4-fold in (CCl_4 + IPEE 400 mg/kg) treated rats than CCl_4 group, and up to 64 % of control rats. In contrast, the mRNA expression of *CYP4A2* was substantially increased in CCl_4-treated rats (Fig. 2C). The mRNA expression of *CYP4A2* was significantly decreased by 48 % and 70 %, respectively, in (CCl_4 + IPEE 400 mg/kg)- and (CCl_4 + SM 200 mg/kg)-treated rats compared to the CCl_4-treated hepatotoxic rats. There was no significant change of *CYP4A2* expression in (CCl_4 + IPEE 200 mg/kg)-treated rats in contrast to CCl_4-treated group.

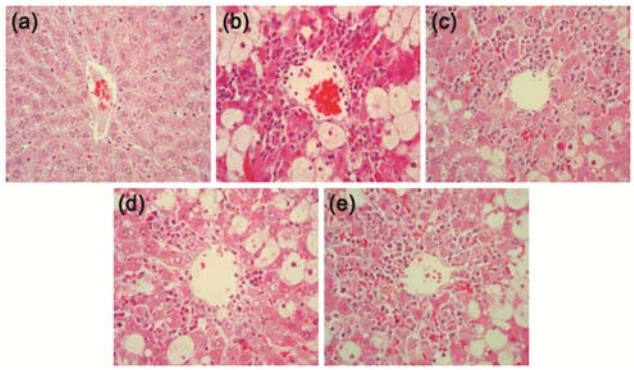

Fig. 1 — The effect of IPEE on histological structure of rat's liver. The liver tissue of (A) non-treated control, (B) CCl_4, (C) CCl_4 + Silymarin 200 mg/kg, (D) CCl_4 + IPEE 200 mg/kg, (E) CCl_4 + IPEE 400 mg/kg, treated rats. The data represents an average of three experiments in which hepatocytes were analyzed to determine necrosis, fatty change, hepatocyte ballooning, and inflammatory cells infiltration. 400X magnification.

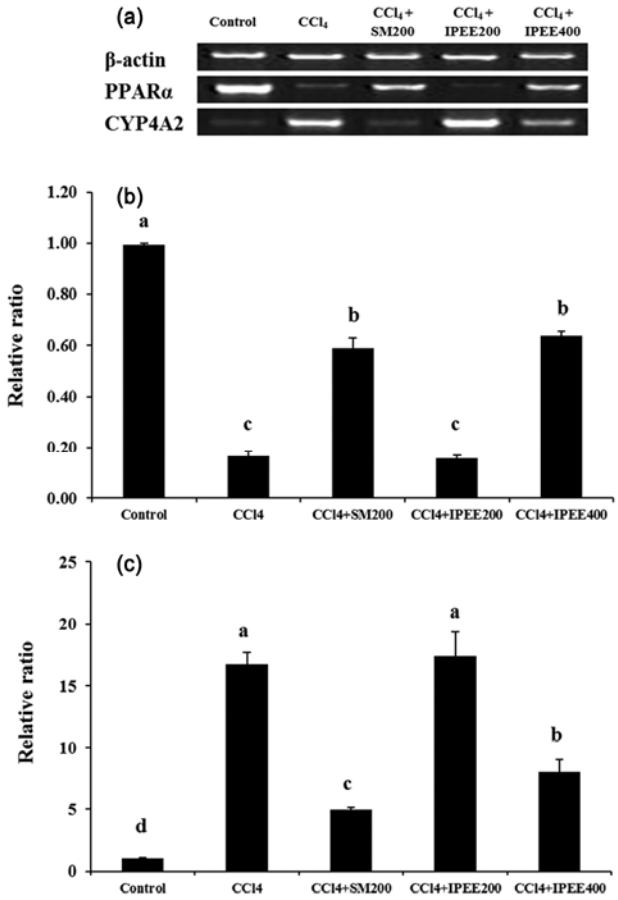

Fig. 2 — The effect of IPEE on mRNA expression of *PPARα* and *CYP4A2*. The mRNA expression of *PPARα* and *CYP4A2* were assessed by semi-quantitative RT-PCR. (A) Relative expression of *PPARα* and *CYP4A2* against control β-actin. Quantitative representation of (B) *PPARα* and (C) *CYP4A2* mRNA expression in rat. All values are expressed as mean ± SD from three independent experiments, and different alphabets indicate a significant difference ($p < 0.05$) by one-way ANOVA.

***In vivo* acute toxicity study**

The death of rat was not observed with the treatment of IPEE throughout the experimental period. Abnormal signs and symptoms in response to the treatment of IPEE were not detected in the first 12 h of observation. Every rat appeared to be apparently healthy during the observation period of 14 days. The body weight of animals, and the weight of their feed and water consumption were recorded for 2 weeks after the administration of IPEE. Irrespective of groups, body weight was increased throughout the experimental period, and there was no difference of mean body weight within same sex at the last day of observation (Fig. 3A). The mean weight of feed and water consumption were relatively different within same sex, except the feed consumption in female groups (Fig. 3B). All major organs were collected at the last day of experiment and grossly inspected for clinical lesions. The weight of spleen, kidneys and liver were measured after sacrificing the animals. There was neither abnormal lesion in animal's organ nor remarkable variations in organ weight between treated and control animals of both sexes (Fig. 3C).

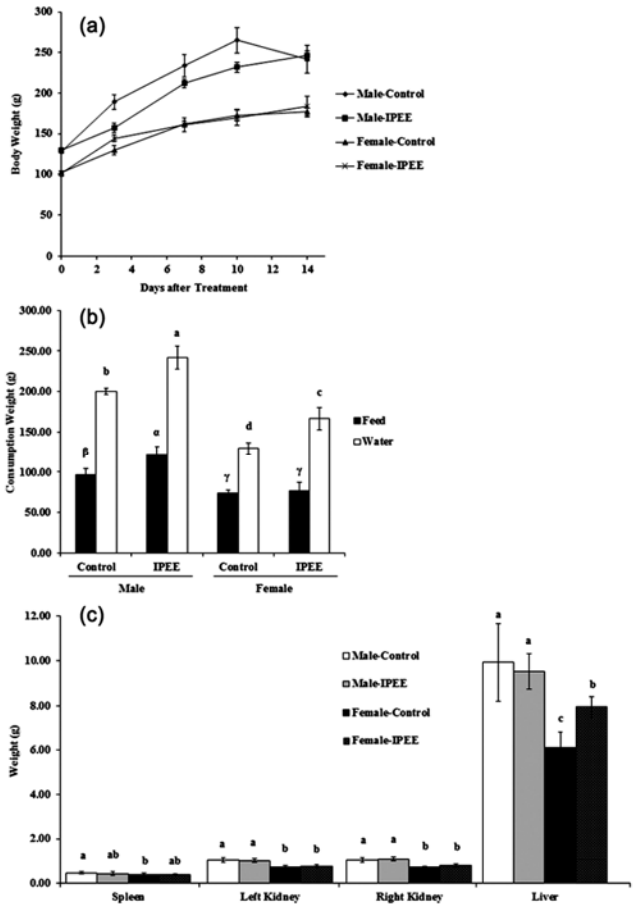

Fig. 3 — The effect of IPEE on (A) body weight, (B), feed and water consumption weight, and (C) major organ weight of rats. Feed and water consumptions are presented as gram per animal for 14 days of experimental period after IPEE administration. All values are expressed as mean ± SD of five rats of each group. Different letters and symbols indicate significant differences ($p < 0.05$) by one-way ANOVA.

LC-MS analysis of IPEE

The major compounds of IPEE were identified by LC-MS analysis. As shown in Fig. 4, six major compounds including chlorogenic acid (4.22 min), cynarin (10.46 min), flavonol (9.28 min) and their analogs were detected in IPEE. The results from LC-MS analysis of the 70 % ethanol extract revealed soluble chlorogenic acid, cynarin, chlorogenic acid analog and cynarin analogs as the major components.

Discussion

The present study describes the protective effect of IPEE against CCl_4-induced hepatotoxicity in an animal model. Liver became the most common target organ of toxicity because of the unique metabolic function. Liver injury can be generated by the direct action of a variety of toxic chemicals, viruses and drugs, and/or the toxic metabolites of endogenous products[14]. Carbon tetrachloride (CCl_4) is an established chemical hepatotoxin, commonly uses to induce hepatic injury in animal model, in which the clinical features associated with this toxicity are similar to those of acute hepatitis in human.

Carbon tetrachloride produces in the body by the formation of free radicals (CCl_3^+, CCl_3OO^+) which subsequently metabolizes in the liver, and causes necrosis and steatosis in centrilobular hepatic region[15]. Hence, effects on the formation and scavenge of free radical provide important means to protect CCl_4-induced liver injury. Cells have a number of defensive mechanisms against the toxic effects of CCl_4, including free radical scavenging and chain reaction terminating by maintaining SOD, GSH, and GPx systems[16]. The levels of SOD, GSH and GPx were remarkably decreased in CCl_4-treated animals (Table 2). The pre-treatment of IPEE in CCl_4-treated animals could preserve the normal levels of those enzymes as observed in CCl_4-non-treated control. The results indicate that IPEE may able to prevent oxidative damages in CCl_4-injured liver.

The GGT, ALP, ALT and AST have been the most commonly used parameters in laboratory testing for the evaluation of liver function, because these

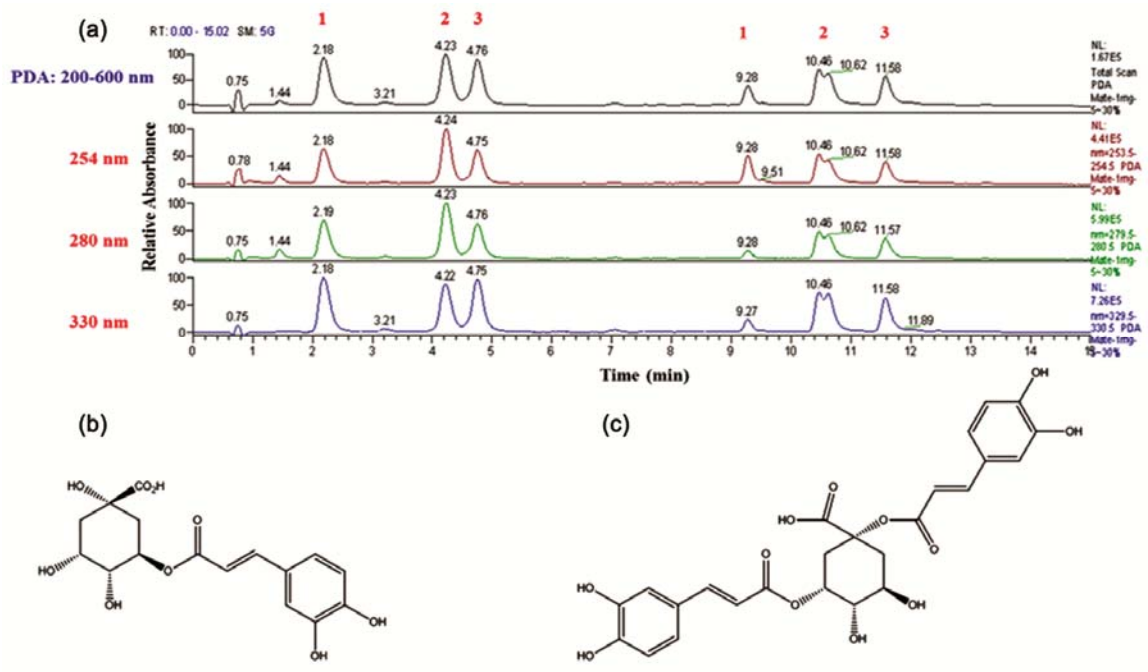

Fig. 4 — Determination of the major compounds of IPEE by LC-MS analysis. The figure represents (A) LC-MS chromatogram of IPEE, and chemical structures of (B) chlorogenic acid, and (C) cynarin, two major compounds of IPEE. In chromatogram, the peak of chlorogenic acid, cynarin, flavonol are indicated at 4.22, 10.46, and 9.28 min, respectively.

enzymes are cytoplasmic in location and are released into circulation after cellular damage[17]. IPEE (200 and 400 mg/kg) pre-treatment significantly ($p < 0.05$) inhibited the CCl_4-associated elevation of GGT, and ALP (Table 1). The level of ALT and AST were reduced with the treatment of IPEE (200 and 400 mg/kg) and IPEE (400 mg/kg), respectively compared to CCl_4 (only)-treated group. However, the pre-treatment of IPEE couldn't completely restore ALT and AST to their normal levels as they were observed in control group. These results propose that IPEE can maintain the stability of hepatic cell membrane in injured condition. In the current study, a diverse histopathological change of liver tissue, including inflammation and steatosis were occurred with the treatment of CCl_4. The pre-treatment of IPEE remarkably prevented the occurrence of these conditions (Fig. 1). The histological observations of rat's liver tissue are supported by the biochemical examinations of their serum. Moreover, the hepatoprotective effect of IPEE seemed to be as beneficial as that of silymarin, which has been used as a potent hepatoprotective agent[18].

The mRNA expressions of *PPARα* and *CYP4A2* in the current study were up-regulated and down-regulated, respectively by the pretreatment of IPEE in CCl_4-treated animal (Fig. 2). Carbon tetrachloride causes hepatotoxicity by producing highly reactive free radicals through the metabolism of cytochrome P450. This hepatotoxic compound (CCl_4) activates the members of P4504A sub-family, such as *CYP4A2*. The improved expression of *CYP4A2* and/or other members of this sub-family promote peroxisome proliferation and subsequently initiate oxidative stress. The stimulation of cytochrome P450 enzymes associated with CCl_4 intoxication also reduces the expression of *PPARα* remarkably and results to hepatic inflammation and fibrosis. The reduction in the level of *PPARα* was observed more in subjects having severe hepatitis and steatosis[19]. It was reported that the tissue oxygenation, microvascular potency and redox status in steatotic livers can be improved by the activation of *PPARα*[20]. The more interesting attitude of *PPARα* agonists is that they can reduce the expression of other hepatic inflammatory genes[21]. Moreover, the expressions of hepatic *CYP4A* genes are mostly reliant on the regulation of *PPARα*[22]. Thus, the development of *PPARα* agonist is desirable in the treatment of hepatic steatosis. The IPEE may exhibit its hepatoprotective effect by preventing the CCl_4-mediated degradation in the mRNA expression of *PPARα* and *CYP4A2* genes.

An *in vivo* cytotoxicity of IPEE was conducted in this study as it is desirable and recommended to

determine the possible toxic properties of natural products along with the evaluation of medicinal properties. IPEE was administered orally to both sexes of rats with a dose of 5000 mg/kg of body weight which is more than the heights approved dose for *in vivo* acute toxicity study according to "Organization for Economic Co-operation and Development" guideline[23]. No animal was died, and abnormal sign was not observed throughout the experimental period. This indicates the oral LD_{50} of IPEE, although it could not be determined precisely, is greater than 5000 mg/kg. The body weight gain was not affected within the same sex of rats by the administration of IPEE (Fig. 3A), which considers as reliable indicator of the general health status of animals[24]. The relative weight of water and food consumption, and liver were quite different among animal groups which may be because of the inter-animal variability[25]. Thus, the IPEE can be considered as a non-toxic agent due to the absence of harmful effects of this extract in animal.

The major compounds identified from IPEE are chlorogenic acid and cynarin (Fig. 4). The chlorogenic acid is known to have antioxidant as well as hepatoprotective effect and was effectively studied in the protection of CCl_4-induced liver damage[26,27]. Moreover, this compound was reported for the DNA damage inhibitory potentials[28]. The other major compound "cynarin" is also a phenolic acid compound and was reported for its choleretic and cholagogue properties. These two actions are very essential for the better functioning of liver. Cynarin was also described to have hepatoprotective effect in CCl_4-induced hepatotoxicity[29]. Hence, the CCl_4-associated hepatotoxicity in rat was prevented by IPEE-pre-treatment might be because of the presence of these potent hepatoprotective agents in extract.

Conclusion

In conclusion, IPEE appears to exert antioxidant and hepatoprotective effect against CCl_4-mediated hepatic injury in rats. This effect may be attributed by maintaining the regulation of *PPARα* and *CYP4A2* genes. The existence of chlorogenic acid and cynarin in IPEE were also confirmed, which might be performing the major role in its hepatoprotection. This extract might be a reliable option in the prevention of hepatic injury. Further study is needed for determining the efficacy of the fractions of IPEE to explore a precise hepatoprotective agent.

Acknowledgement

This work was supported in part by the National Foundation of Korea (NRF) grant funded by the Korea Government (2016R1A2B4013507), in part by the Technology Commercialization Support Program (314082-3), Ministry of Agriculture, Food and Rural Affairs and in part by a grant the Technology Development Program for Forestry (S111515L050130), Korea forest service.

Declaration of interest

All authors declare that there are no conflicts of interest in this study.

References

1 Sharma YK, Singh H & Mehra BL, Hepatoprotective effect of few Ayurvedic herbs in patients receiving antituberculus treatment, *Indian J Tradit Knowle*, 3 (2004) 391-396.

2 Khan RA, Khan MR, Sahreen S & Shah NA,. Hepatoprotective activity of *Sonchus asper* against carbon tetrachloride-induced injuries in male rats: a randomized controlled trial, *BMC Comple Altern Med*, 12 (2012) 90.

3 Afroudakis AP, Alcoholic liver disease-an overview, *Ann Gastroenterol*, 13 (2000) 290-298.

4 Bansal AK, Bansal M, Soni G & Bhatnagar D, Protective role of Vitamin E pre-treatment on N-nitrosodiethylamine induced oxidative stress in rat liver, *Chem Biol Interact*, 156 (2005) 101-111.

5 Mustafa K, Sinem K, Hasan Ö & Selami S, An ethnobotanical study on medicinal plants in Erzincan, Turkey, *Indian J Tradit Knowle*, 15 (2016) 192-202.

6 Heck CI & de Mejia EG, Yerba Mate Tea (*Ilex paraguariensis*): a comprehensive review on chemistry, health implications, and technological considerations, *J Food Sci*, 72 (2007) 138-151.

7 Puangpraphant S & de Mejia EG, Saponins in yerba mate tea (*Ilex paraguariensis* A. St.-Hil) and quercetin synergistically inhibit iNOS and COX-2 in lipopolysaccharide-induced macrophages through NFkappaB pathways, *J Agric Food Chem*, 57 (2009) 8873-8883.

8 Leonard SS, Hogans VJ, Coppes-Petricorena Z, Peer CJ, Vining TA, Fleming DW & Harris GK, Analysis of free-radical scavenging of Yerba Mate (*Ilex paraguriensis*) using electron spin resonance and radical-induced DNA damage, *J Food Sci*, 75 (2010) 14-20.

9 Vieira MA, Maraschin M, Pagliosa CM, Podesta R, de Simas KN, Rockenbach II, Amboni RD & Amante ER, Phenolic acids and methylxanthines composition and antioxidant properties of mate (*Ilex paraguariensis*) residue, *J Food Sci,* 75 (2010) 280-285.

10 Schinella GR, Troiani G, Davila V, de Buschiazzo PM & Tournier HA, Antioxidant effects of an aqueous extract of *Ilex paraguariensis*, *Biochem Biophys Res Commun*, 269 (2000) 357-360.

11 Furtado KS & Andrade FO, Comparison of the beneficial and adverse effects of inhalable and injectable anaesthetics in animal models: a mini-review, *OA Anaesthetics,* 1 (2013) 20.

12 Safari S, Motavaf M, Siamdoust SAS & Alavian SM, Hepatotoxicity of halogenated inhalational anesthetics, *Iran Red Crescent Med J*, 16 (2014) e20153.

13 Hossain MA, Lee SJ, Park JY, Reza MA, Kim TH, Lee KJ, Suh JW & Park SC, Modulation of quorum sensing-controlled virulence factors by *Nymphaea tetragona* (water lily) extract, *J Ethnopharmacol*, 174 (2015) 482-491.

14 Kuntz E & Kuntz HD, *Hepatology, Principles and Practice: History, Morphology, Biochemistry, Diagnostics, Clinic, Therapy*, (Springer, Berlin), 2005.

15 Lee CH, Park SW, Kim YS, Kang SS, Kim JA, Lee SH & Lee SM, Protective mechanism of glycyrrhizin on acute liver injury induced by carbon tetrachloride in mice, *Biol Pharm Bull*, 30 (2007) 1898-1904.

16 Abd El-Ghffar EA & Mohamed SS, Antioxidant and anti-inflammatory effects of *Acrocarpus fraxinifolius* on hyperglycemia, hyperlipidemia and liver/kidney dysfunctions against alloxan induced Type 1 diabetes in rats, *Indian J Tradit Knowle*, 17 (2018) 223-232.

17 Hossain MA, Lee SJ, Park NH, Birhanu BT, Mechesso AF, Park JY, Park EJ, Lee SP, Youn SJ & Park SC, Enhancement of lipid metabolism and hepatic stability in fat-induced obese mice by fermented *Cucurbita moschata* extract, *Evid Based Comple Altern Med*, 2018 (2018) 3908453.

18 Jia R, Cao L, Du J, Xu P, Jeney G & Yin G, The protective effect of silymarin on the carbon tetrachloride (CCl_4)-induced liver injury in common carp (*Cyprinus carpio*), *In Vitro Cell Dev Biol Anim*, 49 (2013) 155-161.

19 Ip E, Farrell GC, Robertson G, Hall P, Kirsch R & Leclercq I, Central role of PPAR alpha-dependent hepatic lipid turnover in dietary steatohepatitis in mice, *Hepatology*, 38 (2003) 123-132.

20 Kondo K, Sugioka T, Tsukada K, Aizawa M, Takizawa M, Shimizu K, Morimoto M, Suematsu M & Goda N, Fenofibrate, a peroxisome proliferator-activated receptor alpha agonist, improves hepatic microcirculatory patency and oxygen availability in a high-fat-diet-induced fatty liver in mice, *Adv Exp Med Biol*, 662 (2010) 77-82.

21 Stienstra R, Mandard S, Patsouris D, Maass C, Kersten S & Muller M, Peroxisome proliferator-activated receptor alpha protects against obesity-induced hepatic inflammation, *Endocrinology*, 148 (2007) 2753-2763.

22 Barclay TB, Peters JM, Sewer MB, Ferrari L, Gonzalez FJ & Morgan ET, Modulation of cytochrome P-450 gene expression in endotoxemic mice is tissue specific and peroxisome proliferator-activated receptor-alpha dependent, *J Pharmacol Exp Ther*, 290 (1999) 1250-1257.

23 Organization for Economic Co-operation and Development (OECD), *OECD Guideline for the testing of chemicals: Acute oral toxicity-acute toxic class method*, (Paris, France) 2001.

24 Ping KY, Darah I, Chen Y, Sreeramanan S & Sasidharan S, Acute and subchronic toxicity study of *Euphorbia hirta* L. methanol extract in rats, *Biomed Res Int*, 2013 (2013) 182064.

25 Michael B, Yano B, Sellers RS, Perry R, Morton D, Roome N, Johnson JK, Schafer K & Pitsch S, Evaluation of organ weights for rodent and non-rodent toxicity studies: a review of regulatory guidelines and a survey of current practices, *Toxicol Pathol*, 35 (2007) 742-750.

26 Sato Y, Itagaki S, Kurokawa T, Ogura J, Kobayashi M, Hirano T, Sugawara M & Iseki K, *In vitro* and *in vivo* antioxidant properties of chlorogenic acid and caffeic acid, *Int J Pharm*, 403 (2011) 136-138.

27 Shi H, Dong L, Bai Y, Zhao J, Zhang Y & Zhang L, Chlorogenic acid against carbon tetrachloride-induced liver fibrosis in rats, *Eur J Pharmacol*, 623 (2009) 119-124.

28 Kasai H, Fukada S, Yamaizumi Z, Sugie S & Mori H, Action of chlorogenic acid in vegetables and fruits as an inhibitor of 8-hydroxydeoxyguanosine formation in vitro and in a rat carcinogenesis model, *Food Chem Toxicol*, 38 (2000) 467-471.

29 Nermeen FF, Enas HA, Shadia MA & El-Sayeda AEK, Protective Effect of *Chrysanthemum pacificum* against CCl4-induced injury on the human hepatoma cell line (Huh7), *J Pharm Sci Res*, 7 (2015) 633-639.