Streamlined Forensic Medical Report SFR2 - Forensic Issues

Patients Name	[redacted]	Patients DOB	[redacted]
Date of Presentation	[redacted]	Date of Discharge	[redacted]
Place of Examination	[redacted]	Police Reference Number	[redacted]
Time of First Examination	[redacted]	Police Tracker Number	[redacted]
Medical Examiner	**TRAUMA CALL TEAM**		

Criminal Procedure Rules, r 16. 2; Criminal Justice Act 1967, s. 9

STATEMENT OF: [redacted]

This report (consisting of **8** pages signed by me) is true to the best of my knowledge and belief and I make it knowing that, if it is tendered in evidence, I shall be liable to prosecution if I have wilfully stated anything in it which I know to be false, or that I do not believe to be true.

Insofar as this statement contains expert opinion evidence, I believe that its contents also reflect my obligations to include any relevant matter required by Crim. PR 19.4. I understand and expect that Crim. PR 19.6ll apply, should another party disagree with my conclusions.

Qualifications, Experience and relevant Accreditation

I have been qualified as a medical doctor for nine years.
I graduated from the [redacted] with a BMBS degree.

Additional Case information

An SFR1 was completed by [redacted].

Prosecution/Defence SFR1 Issues

1.	**Were the patient's injuries life-threatening?**
2.	**What was the diagnosis of the patient's condition?**
3.	**What is the prognosis of the patient?**

Medical Transcriber's Response to the SFR1 Issues

1.
On reviewing the medical notes, it was noted that the patient first attended the Emergency Department at [redacted].
At the Emergency Department at [redacted] it was noted that:

- **the blood pressure was unrecordable**
- **the pulses in the arms and legs were present but weak**
- **an x-ray of the chest showed a collection of blood in the right lung (haemothorax).**

The Emergency Medicine team then inserted a chest drain into the right lung, administered one blood transfusion (one unit of whole blood) and Tranexamic acid (medication to aid clotting).
The patient was then transferred to the Emergency Department at the [redacted]

At the Emergency Department at the [redacted] was noted that:

- **there was a 5mm wound to the right side of the chest**

Signature [redacted] **Date** [redacted]

- a Computerised Tomography scan of the chest showed, amongst other findings, a collection of blood within the right lung (haemothorax) and a puncture to the right lung (pneumothorax).

The injury to the right lung that the patient sustained was life-threatening.
This is evident from several points in the medical notes:
- "the blood pressure was unrecordable" is noted when the patient attends the Emergency Department at [redacted]
- it is noted that an x-ray of the chest showed a collection of blood in the right lung (haemothorax), when the patient attends the Emergency Department at [redacted]
- the systolic blood pressure of the patient dropped from 100mmHg to 70mmHg in the Emergency Department at the [redacted] which suggests active bleeding.
- the haemoglobin level (as haemoglobin is contained within red blood cells, the level of haemoglobin in the blood positively correlates to blood loss from the blood vessels of the body) dropped from 130g/dL to 115g/dL. This rapid drop in haemoglobin level suggests active bleeding.
- the patient required blood transfusions (two units of packed red cells) and blood products (two units of Fresh Frozen Plasma) to stabilise the blood pressure.
- as a direct result of the injury the patient sustained to the right lung, the patient subsequently developed an "empyema" (a collection of pus) within the right lung. The patient ultimately required an operation performed at [redacted] on [redacted] (to remove the empyema).
- it is noted that the Consultant for Interventional Radiology stated that the injury to the liver was unlikely to be the main cause of the unstable blood pressure.
With the above points noted, it is evident that without the treatment administered by the medical professionals at [redacted] the patient would have died. I can therefore conclude that the injury sustained by the patient to the right lung *was* life-threatening.

2. The diagnosis of the patient's condition can be stated as the findings on the Computerised Tomography scan of the chest, abdomen and pelvis performed at the Emergency Department at the [redacted] on [redacted]:

- a single penetrating injury with the entry wound to the right side of the front of the chest cavity
- bullet fragments lodged in the back wall of the right side of the back of the chest cavity; a metallic fragment was lodged just in front of the 10th rib at the back of the right side of the ribcage and a larger metallic fragment near the spine in the upper back (at the level of T8/T9 spinous processes). Please see Figure One, Figure Two, Figure Three and Figure Four.
- bruising at the site of the penetrating injury
- a collection of blood in the right side of the lung (haemothorax)
- the right lung had been punctured, resulting in partial collapse of the right lung (pneumothorax). Please see Figure Five.
- a fracture of the sixth rib at the front of the right side of the ribcage
- evidence of injury to the right side of the diaphragm
- an injury to the liver, with evidence of active bleeding
- blood within the abdominal cavity (an abnormal finding)

Signature [redacted]

Date [redacted]

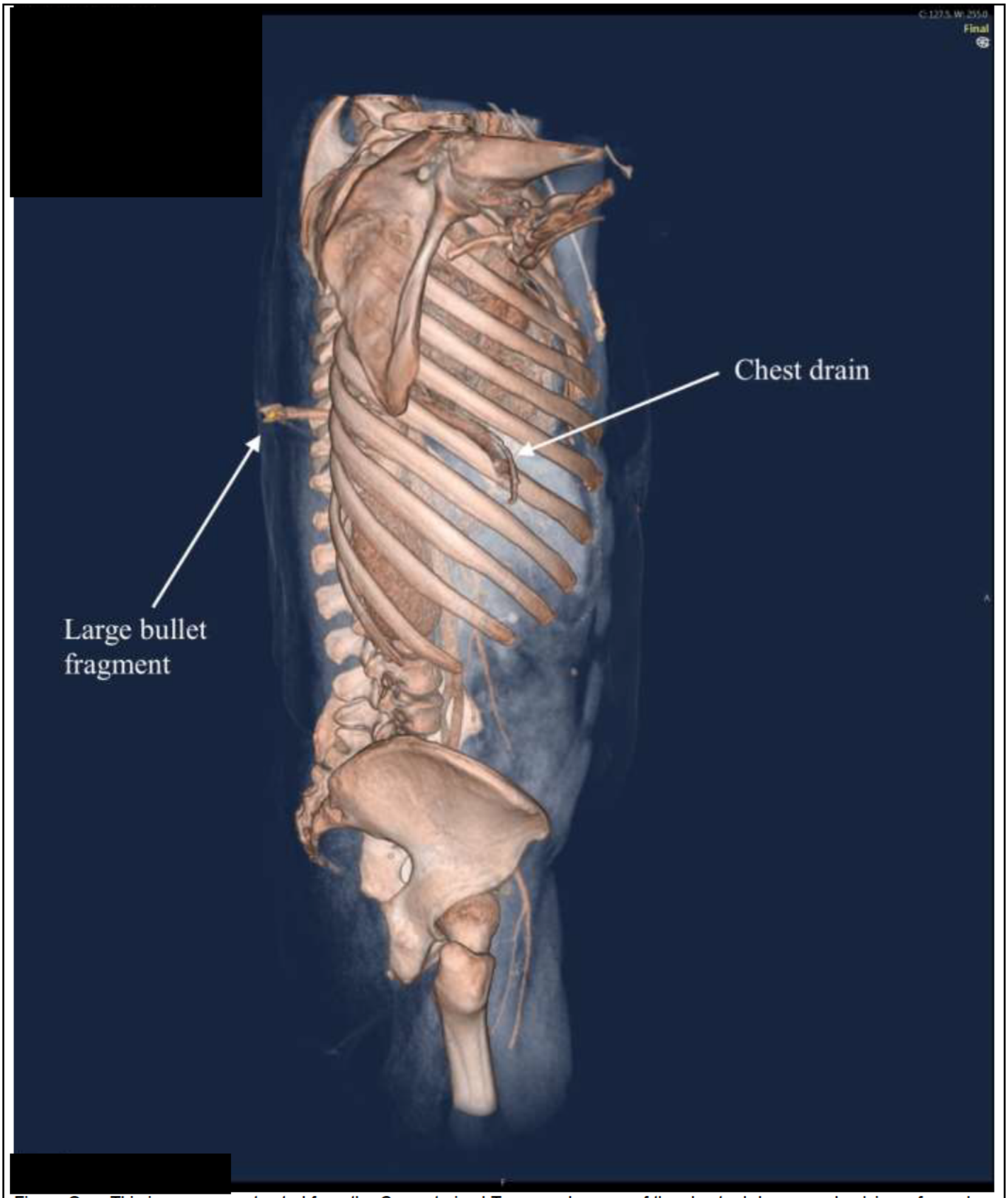

Figure One: This image was extracted from the Computerised Tomography scan of the chest, abdomen and pelvis performed on the patient at [redacted] This image demonstrates the location of the larger metallic fragment near the spine in the upper back (at the level of T8/T9 spinous processes). This image also demonstrates the location of the chest drain that was inserted into the right lung by the Emergency Medicine team at [redacted]

Signature [redacted] **Date** [redacted]

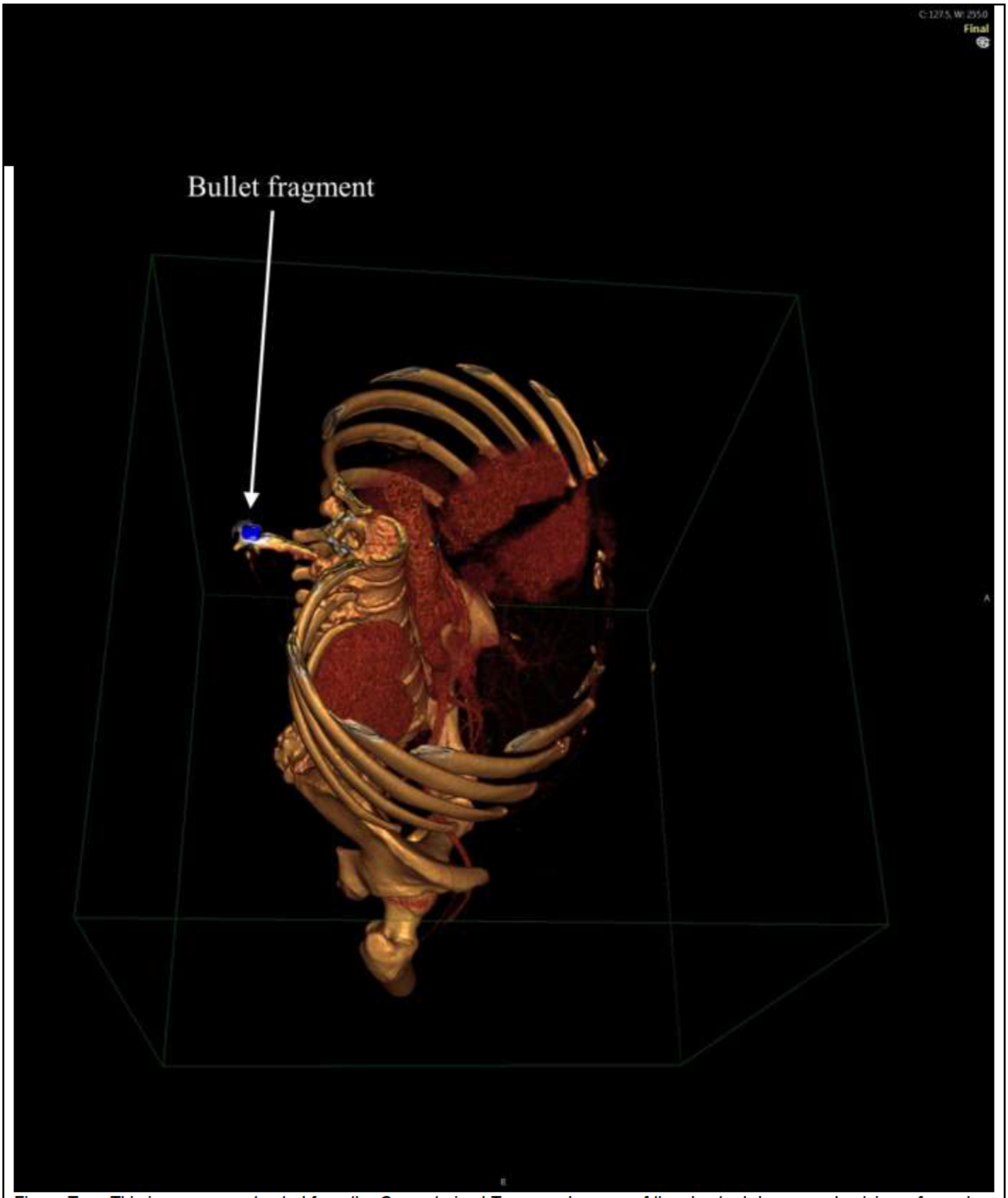

Figure Two: This image was extracted from the Computerised Tomography scan of the chest, abdomen and pelvis performed on the patient at [redacted] This image demonstrates the location of the larger metallic fragment near the spine in the upper back (at the level of T8/T9 spinous processes).

Signature [redacted]

Date [redacted]

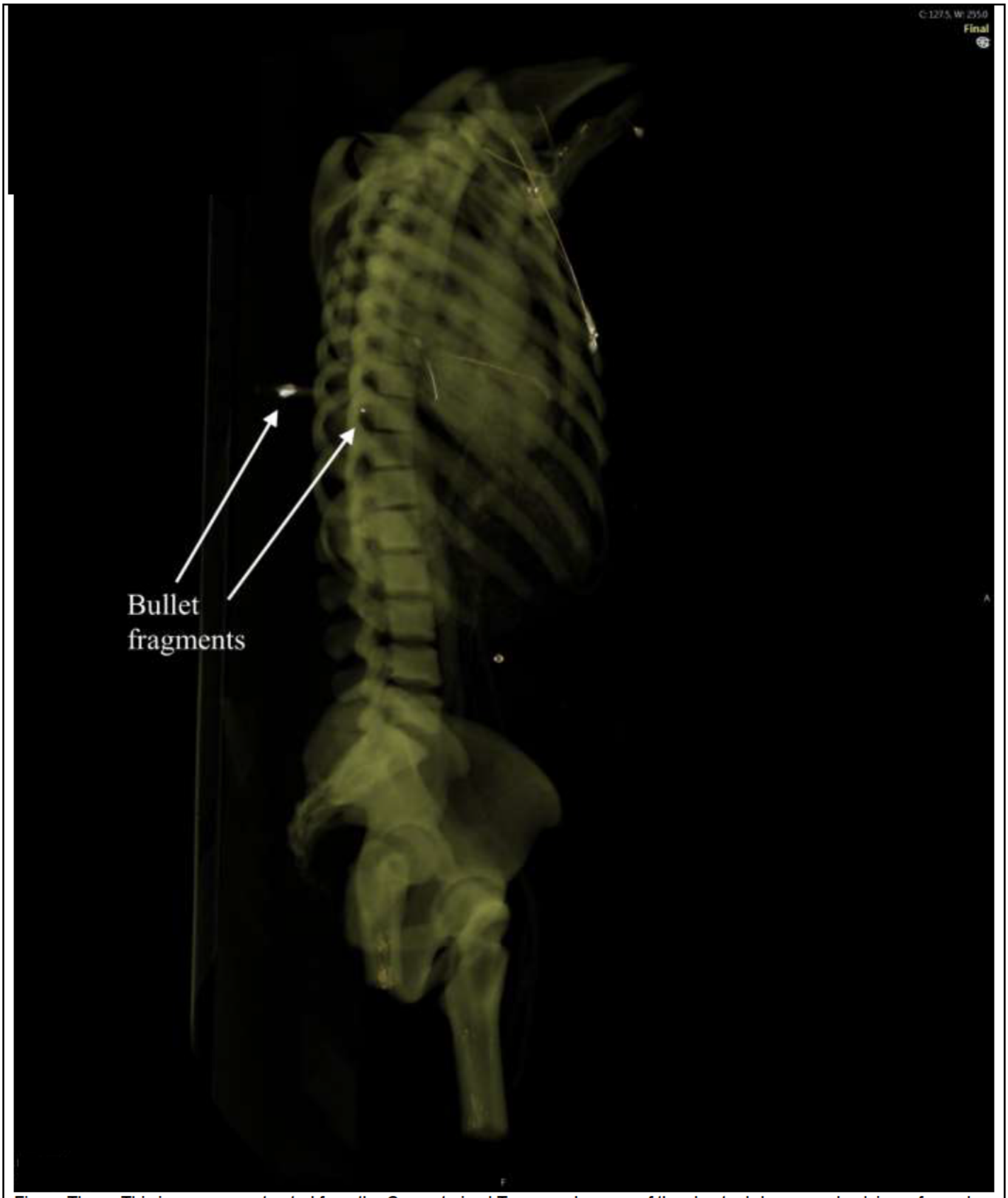

Figure Three: This image was extracted from the Computerised Tomography scan of the chest, abdomen and pelvis performed on the patient at [redacted] This image demonstrates the bullet fragments lodged in the back wall of the right side of the back of the chest cavity; a metallic fragment was lodged just in front of the 10th rib at the back of the right side of the ribcage and a larger metallic fragment near the spine in the upper back (at the level of T8/T9 spinous processes).

Signature [redacted]

Date [redacted]

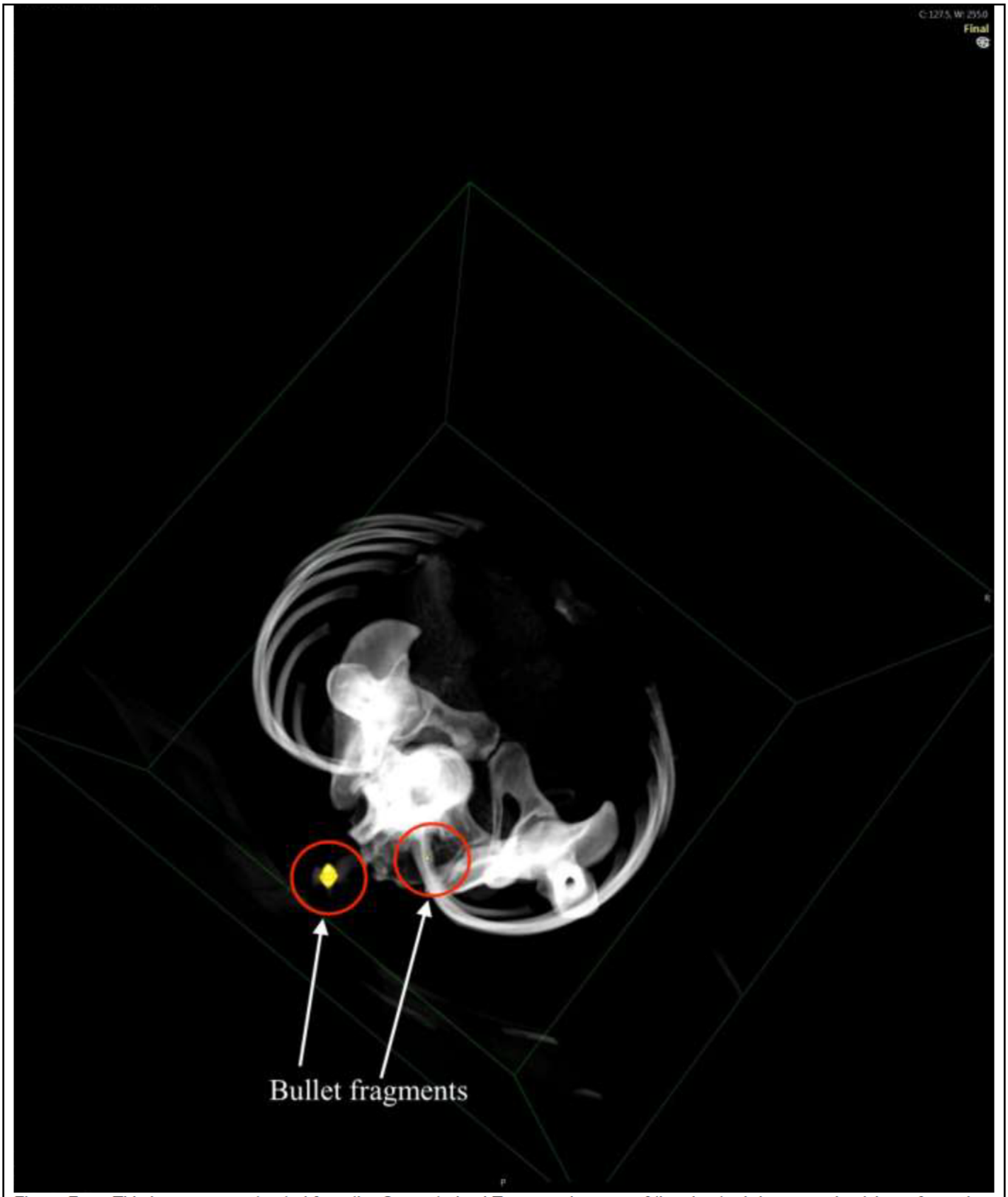

Figure Four: This image was extracted from the Computerised Tomography scan of the chest, abdomen and pelvis performed on the patient at [redacted] This image demonstrates the bullet fragments lodged in the back wall of the right side of the back of the chest cavity; a metallic fragment was lodged just in front of the 10th rib at the back of the right side of the ribcage and a larger metallic fragment near the spine in the upper back (at the level of T8/T9 spinous processes).

Signature [redacted]

Date [redacted]

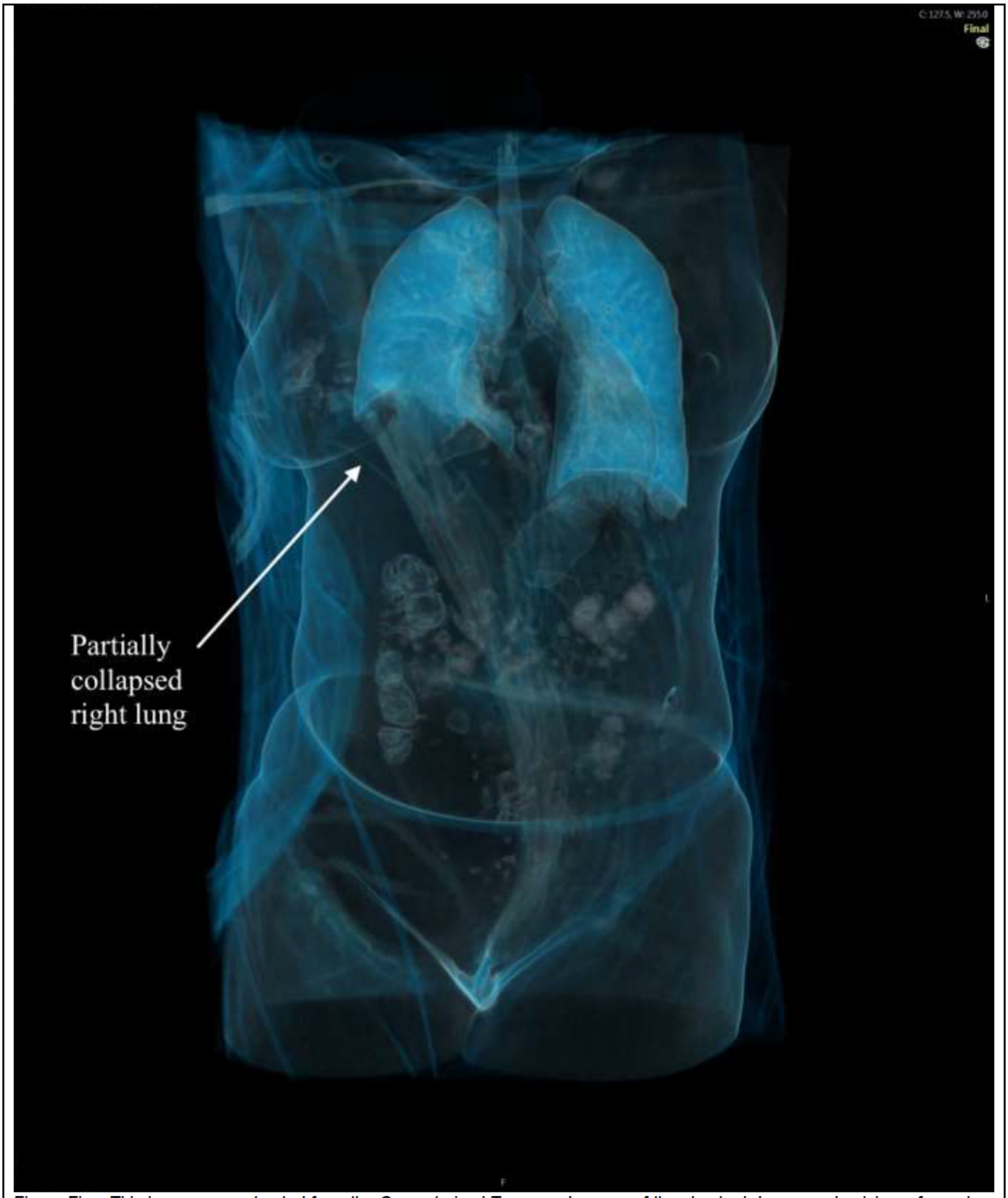

Figure Five: This image was extracted from the Computerised Tomography scan of the chest, abdomen and pelvis performed on the patient at [redacted] This image demonstrates the puncture of the right lung resulting in partial collapse of the right lung (pneumothorax).

Later in the patient's stay at [redacted] a repeat Computerised Tomography scan of the chest on [redacted] showed:

- **an increase in the size of the collection of blood within the right lung**
- **the collection of blood within the right lung had formed several pockets (was loculated) within the collection, and that the collection of blood was now mostly solid, precluding effective drainage of the c[redacted]ung**

Signature [redacted] **Date** [redacted]

- evidence of an "empyema" (collection of pus) within the collection of blood within the right lung (haemothorax) was noted

These repeat Computerised Tomography scan findings and the fact that the patient developed a fever on [redacted] requiring a course of antibiotics, diagnoses the patient with an empyema.

3. The prognosis of the patient is that:

- she is likely to experience shortness-of-breath until all the fluid in the right lung has been reabsorbed by the body
- she will be left with lifelong scarring in her right lung
- she will be more susceptible to contracting chest infections in the future
- she is at risk of developing Post-Traumatic Stress Disorder from the incident and treatment that she underwent.

It is also noted that no future treatment is planned from the Thoracic surgeons at [redacted], as after a review in Thoracic surgery clinic [redacted] the patient was discharged from the care of the Thoracic surgical team at [redacted]

If more information regarding the patient's prognosis is required, an expert witness will be required to comment.

Role/Registration No:	MEDICAL TRANSCRIBER

Signature [redacted]

Date [redacted]