

Figure Re-1. Failure case under severe degradation, where the image contains many tiny and complex faces that are difficult to faithfully super-resolve.

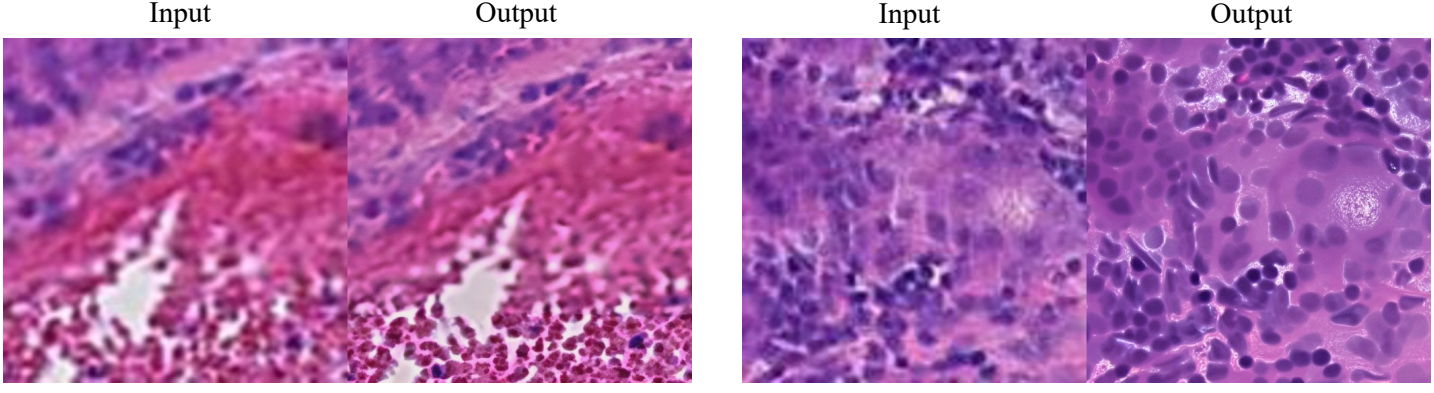

Figure Re-2. Failure case on medical-domain pathology images, where recovering fine-grained tissue details remains challenging.