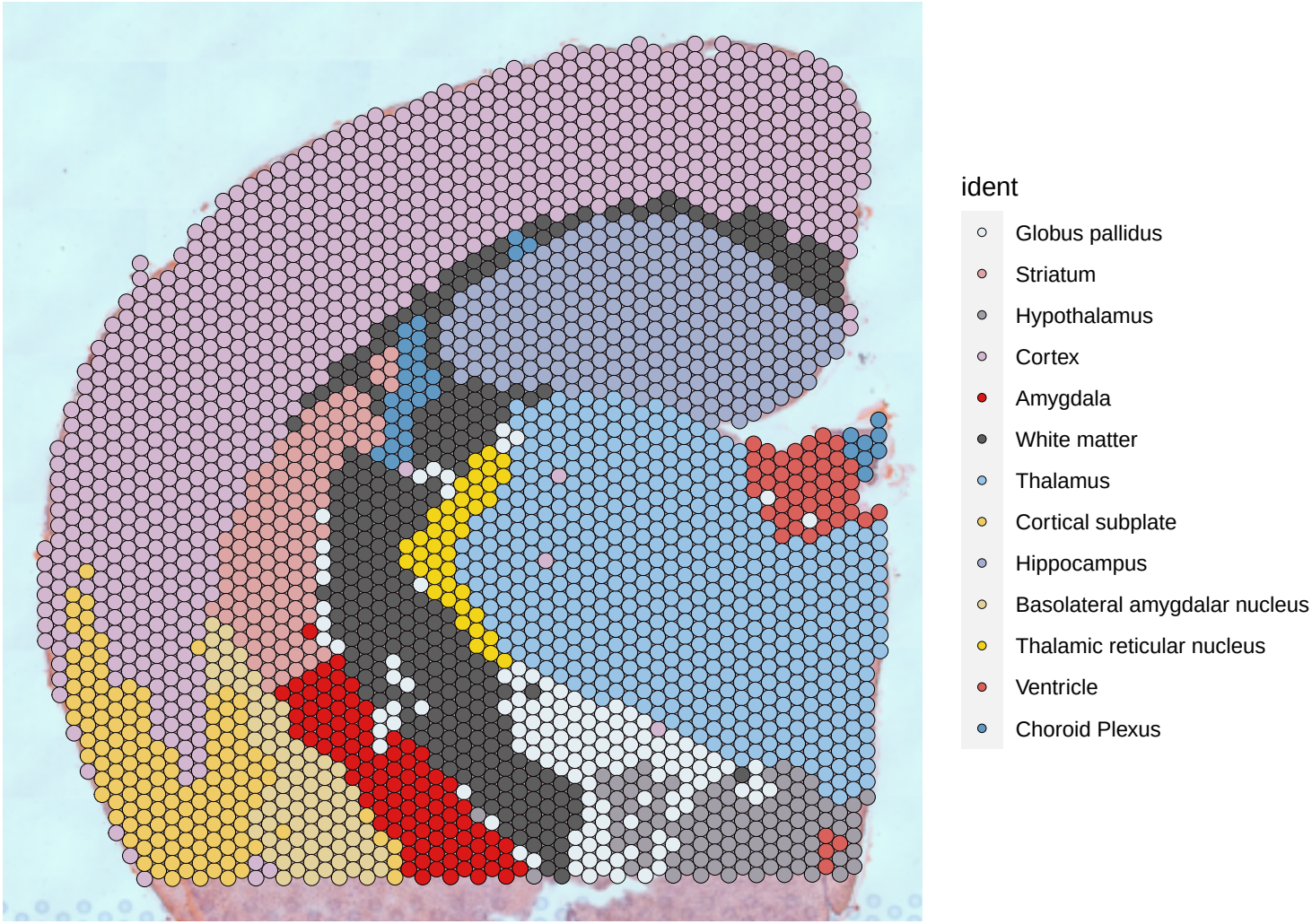
ident
Globus pallidus
Striatum
Hypothalamus
Cortex
Amygdala
White matter
Thalamus
Cortical subplate
Hippocampus
Basolateral amygdalar nucleus
Thalamic reticular nucleus
Ventricle
Choroid Plexus