Note: This copy is for your personal non-commercial use only. To order presentation-ready copies for distribution to your colleagues or clients, contact us at *www.rsna.org/rsnarights*.

Case 215[1]

Tina D. Tailor, MD
Michael L. Richardson, MD

History

A 74-year-old woman presented with multifocal bone pain, including pain in multiple ribs, bilateral shoulders, and bilateral hips. The pain began several months before presentation and was quite severe, ultimately necessitating control with narcotics. At examination, strength in both lower extremities was slightly reduced, sensation and reflexes were intact, and range of motion was full, though painful. There were no notable constitutional symptoms of fever or weight loss. Laboratory work-up was remarkable for elevated alkaline phosphatase level (277 U/L [4.6 μkat/L]).

The patient had undergone left lung transplantation 8 years prior for pulmonary fibrosis. A thorough pulmonary work-up for the cause of fibrosis, which included gathering an exposure, occupational, allergy, and previous infectious history, and a rheumatoid work-up were negative. The patient's posttransplantation course was complicated by bronchiolitis obliterans from chronic rejection and by recent pulmonary embolism, for which she was undergoing anticoagulation therapy at the time of presentation. Additionally, the patient experienced repeated pulmonary infections with *Aspergillus*, leading to multiple hospitalizations and long-term antifungal prophylaxis with voriconazole.

A bone scan from an outside hospital was reviewed, and further imaging was performed (Figs 1–3).

2014 Diagnosis Please Learning Objectives

In submitting a diagnosis for this case, participants demonstrate the ability to

- Recognize normal and abnormal findings as presented in the diagnostic images
- Identify pathologic conditions indicated in the diagnostic images
- Use clinical reasoning skills to generate a list of differential diagnoses

Accreditation and Designation Statement

The RSNA is accredited by the Accreditation Council for Continuing Medical Education (ACCME) to provide continuing medical education for physicians. The RSNA designates this journal-based SA-CME activity for a maximum of 1.0 *AMA PRA Category 1 Credit*™. Physicians should claim only the credit commensurate with the extent of their participation in the activity.

Disclosure Statement

The ACCME requires that the RSNA, as an accredited provider of CME, obtain signed disclosure statements from authors, editors, and reviewers for this case. For this educational activity the authors, editors, and reviewers have indicated that they have no relevant relationships to disclose.

Published online
10.1148/radiol.12122693 **Content code:** MK

Radiology 2014; 273:619–621

[1] From the Department of Radiology, University of Washington Medical Center, 1959 Pacific St, Box 357115, Seattle, WA 98195-7115. Received December 18, 2012; revision requested December 27; revision received March 2, 2013; final version accepted March 15. **Address correspondence to** T.D.T. (e-mail: *tailort@uw.edu*).

Conflicts of interest are listed at the end of this article.

© RSNA, 2014

Submit Diagnosis

Submit the most likely diagnosis to *http://rsna.org/dxplease* (use only for submission of diagnosis). Select the case from the Active Case List for which you are submitting a diagnosis. Only one case, one name, and one diagnosis per e-mail submission. Multiple diagnoses and multiple submissions will not be considered. ***Deadline:*** Midnight U.S. Central Time, January 10, 2015. Answer will appear in the March 2015 issue. Authors wishing to submit cases for Diagnosis Please should first write to the Editor to obtain approval for the case and further information.

Figure 1

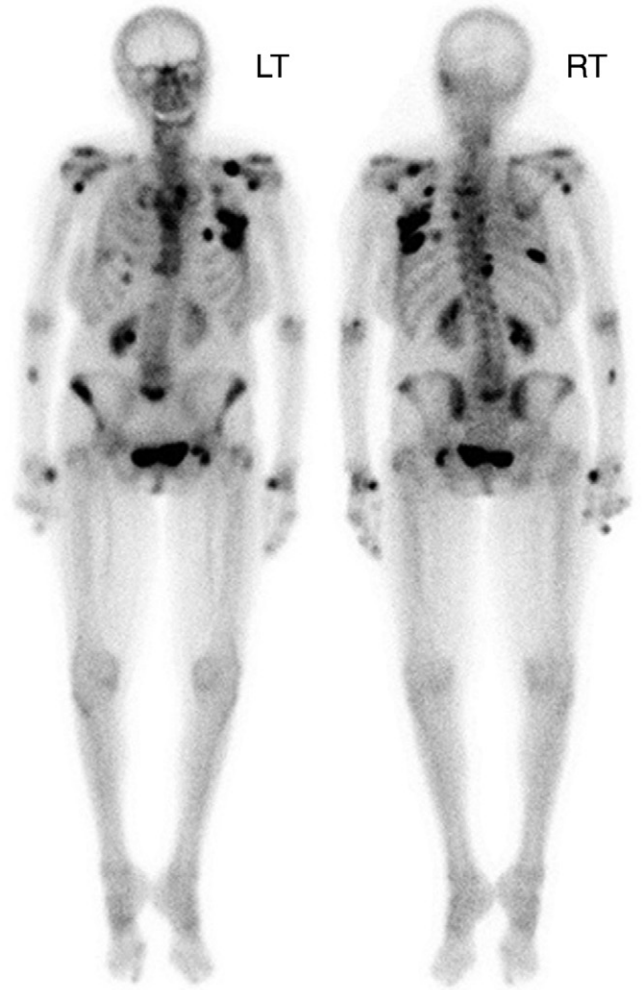

Figure 1: Whole-body technetium-99m methylene diphosphonate bone scan.

Figure 2

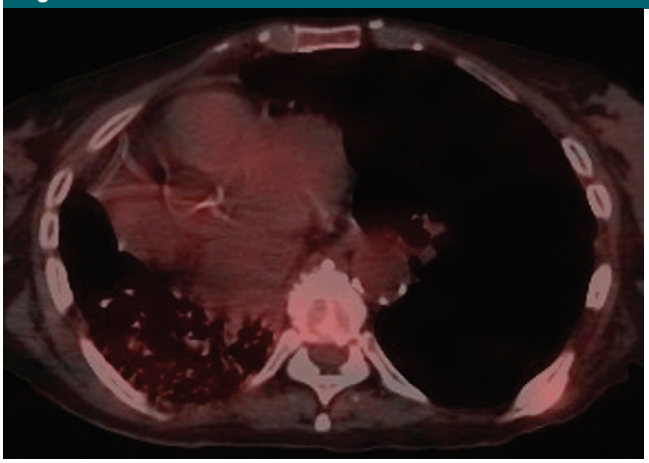

Figure 2: Representative axial section obtained with fused fluorodeoxyglucose positron emission tomography and computed tomography (CT).

Figure 3

a. b. c.

Figure 3: **(a–c)** Axial CT images through the chest obtained with bone window settings.

Disclosures of Conflicts of Interest: T.D.T. disclosed no relevant relationships. **M.L.R.** disclosed no relevant relationships.